Interventional Treatment of Ilio-Popliteal Artery Disease

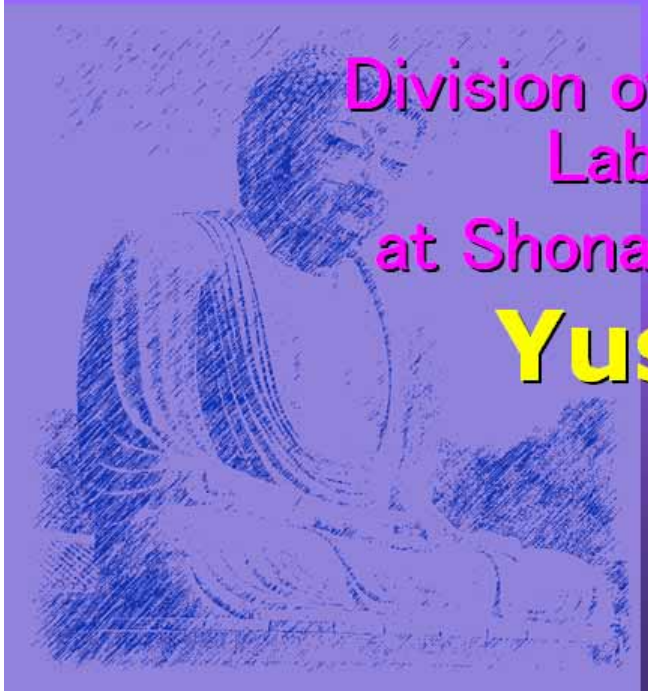

Division of Cardiology & Catheterization Laboratories, Heart Center
at Shonan Kamakura General Hospital
Yusuke Miyashita

ACC/AHA Guidelines for the Management of Patients With Peripheral Arterial Disease (Lower Extremity, Renal, Mesenteric, and Abdominal Aortic): A Collaborative Report from the American Association for Vascular Surgery/ Society for Vascular Surgery,* Society for Cardiovascular Angiography and Interventions, Society for Vascular Medicine and Biology, Society of Interventional Radiology, and the ACC/AHA Task Force on Practice Guidelines (Writing Committee to Develop Guidelines for the Management of Patients With Peripheral Arterial Disease)

Endorsed by the American Association of Cardiovascular and Pulmonary Rehabilitation; National Heart, Lung, and Blood Institute; Society for Vascular Nursing; TransAtlantic Inter-Society Consensus; and Vascular Disease Foundation

WRITING COMMITTEE MEMBERS

Alan T. Hirsch, MD, FACC, FAHA, *Chair*
Ziv J. Haskal, MD, FAHA, FSIR, *Co-Chair*
Norman R. Hertzer, MD, FACS, *Co-Chair*

Curtis W. Bakal, MD, MPH, FAHA
Mark A. Creager, MD, FACC, FAHA
Jonathan L. Halperin, MD, FACC, FAHA†
Loren F. Hiratzka, MD, FACC, FAHA, FACS
William R.C. Murphy, MD, FACC, FACS
Jeffrey W. Olin, DO, FACC
Jules B. Puschett, MD, FAHA
Kenneth A. Rosenfield, MD, FACC
David Sacks, MD, FACR, FSIR§
James C. Stanley, MD, FACS, FACR, FSIR‡
Lloyd M. Taylor, Jr., MD, FACS‡
Christopher J. White, MD, FACC, FAHA, FESC, FSCAI‖
John White, MD, FACS‡
Rodney A. White, MD, FACS‡

TASK FORCE MEMBERS

Elliott M. Antman, MD, FACC, FAHA, *Chair*
Sidney C. Smith, Jr., MD, FACC, FAHA, *Vice-Chair*

Cynthia D. Adams, MSN, APRN-BC, FAHA
Jeffrey L. Anderson, MD, FACC, FAHA
David P. Faxon, MD, FACC, FAHA**
Valentin Fuster, MD, PhD, FACC, FAHA, FESC**
Raymond J. Gibbons, MD, FACC, FAHA††
Jonathan L. Halperin, MD, FACC, FAHA
Loren F. Hiratzka, MD, FACC, FAHA**
Sharon A. Hunt, MD, FACC, FAHA
Alice K. Jacobs, MD, FACC, FAHA
Rick Nishimura, MD, FACC, FAHA
Joseph P. Ornato, MD, FACC, FAHA
Richard L. Page, MD, FACC, FAHA
Barbara Riegel, DNSc, RN, FAHA

Ilio-Popliteal Artery Disease

- Claudicator
- Critical Limb Ischemia (CLI)

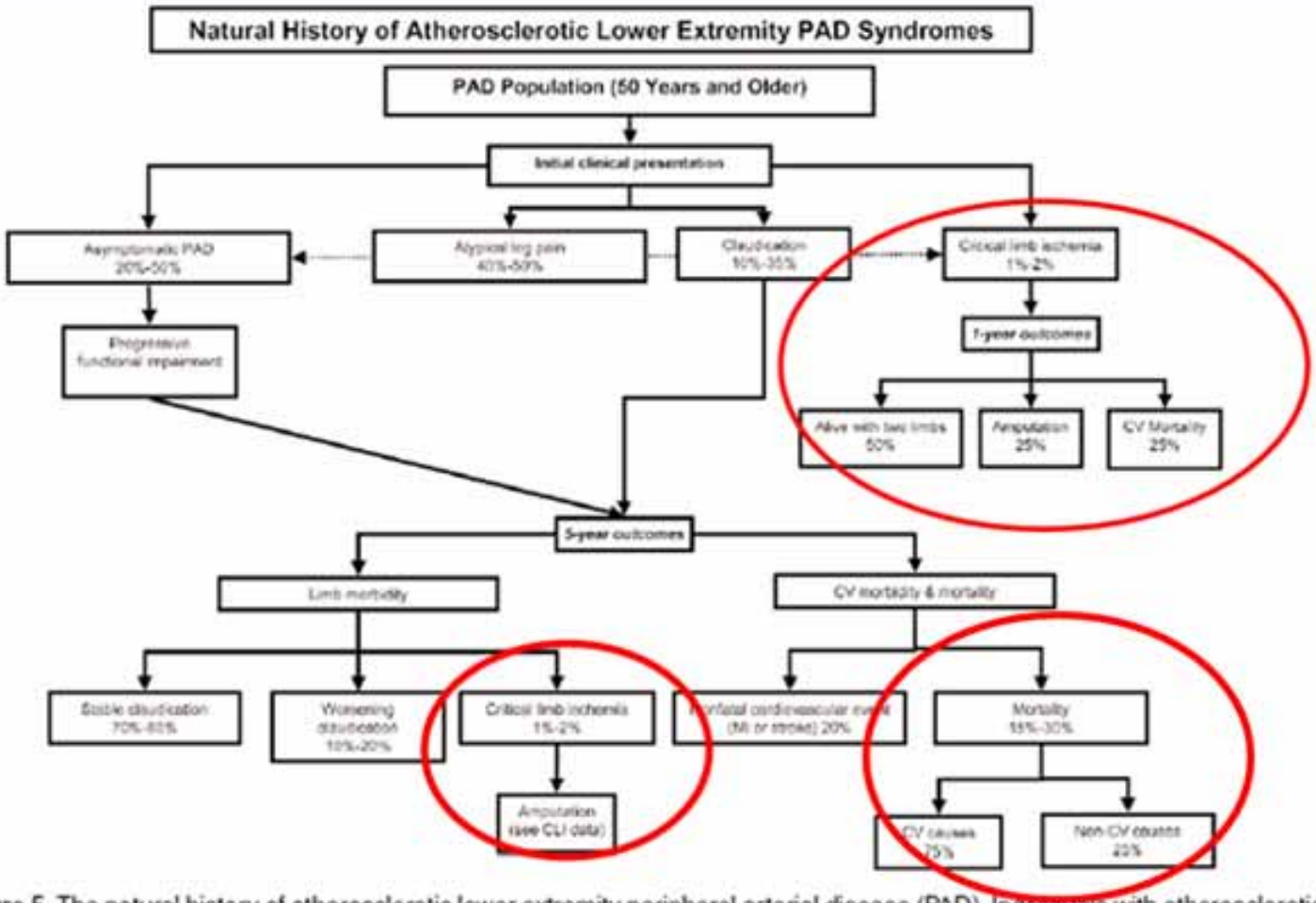

Figure 5. The natural history of atherosclerotic lower extremity peripheral arterial disease (PAD). Individuals with atherosclerotic lower extremity PAD may be: (a) asymptomatic (without identified ischemic leg symptoms, albeit with a functional impairment); (b) present with leg symptoms (classic claudication or atypical leg symptoms); or (c) present with critical limb ischemia. All individuals with PAD face a risk of progressive limb ischemic symptoms, as well as a high short-term cardiovascular ischemic event rate and increased mortality. These event rates are most clearly defined for individuals with claudication or critical limb ischemia (CLI), and less well defined for individuals with asymptomatic PAD. CV indicates cardiovascular; MI, myocardial infarction. Adapted with permission from Weitz JL et al. Circulation. 1996;94:3026-49 (93).

Summary

- CLI patients are 1-2% of all PAD patients
- 5yr mortality is 15-30%
  - Main causes are CV event (MI or stroke)
- Only 1-2% patients of claudicator will lose their limbs after 5years.

Claudicator

- Indication of the Interventional Therapy of the claudicator should be considered

2.6.2.4. Endovascular Treatment for Claudication

RECOMMENDATIONS

Class I

1. Endovascular procedures are indicated for individuals with a vocational or lifestyle-limiting disability due to intermittent claudication when clinical features suggest a reasonable likelihood of symptomatic improvement with endovascular intervention and (a) there has been an inadequate response to exercise or pharmacological therapy and/or (b) there is a very favorable risk-benefit ratio (e.g., focal aortoiliac occlusive disease). *(Level of Evidence: A)*
2. Endovascular intervention is recommended as the preferred revascularization technique for TASC type A (see Tables 20 and 21 and Figure 8) iliac and femoropopliteal arterial lesions. *(Level of Evidence: B)*
3. Translesional pressure gradients (with and without vasodilation) should be obtained to evaluate the significance of angiographic iliac arterial stenoses of 50% to 75% diameter before intervention. *(Level of Evidence: C)*
4. Provisional stent placement is indicated for use in the iliac arteries as salvage therapy for a suboptimal or failed result from balloon dilation (e.g., persistent translesional gradient, residual diameter stenosis greater than 50%, or flow-limiting dissection). *(Level of Evidence: B)*
5. Stenting is effective as primary therapy for common iliac artery stenosis and occlusions. *(Level of Evidence: B)*
6. Stenting is effective as primary therapy in external iliac artery stenoses and occlusions. *(Level of Evidence: C)*

Ilio-Popliteal Artery Disease

- Claudicator
- Critical Limb Ischemia (CLI)

CLI

- Limb loss of the patient changes the patient's life dramatically.
- Such a kind of patients always have the risks of surgical treatment.
  - Wound infection, Renal failure, Diabetes, Ischemic heart disease, Cerebrer vascular disease

2.6.3.2. Endovascular Treatments for CLI

RECOMMENDATIONS

Class I

1. **For individuals with combined inflow and outflow disease with CLI, inflow lesions should be addressed first.** ***(Level of Evidence: C)***
2. **For individuals with combined inflow and outflow disease in whom symptoms of CLI or infection persist after inflow revascularization, an outflow revascularization procedure should be performed.** ***(Level of Evidence: B)***

Ilio-Popliteal Artery Disease

- Iliac artery
- Femoral-Popliteal artery

Iliac artery

- Anatomical feature
  - Intra abdominal space
  - Large artery
  - Much plaque
  - Internal iliac artery
  - Good access
    - Brachial, bi-lateral femoral, popliteal

Holy side of iliac Intervention

- High Success Rate

- High Patency Rate
  - Any stent is suitable to iliac

Dark side of illiac PPI

- The Risks of the distal embolism
- The Risks of the intestinal necrosis
- The Risk of the Life thereating bleeding
  - Keep the special device in your cathe. Labo
    - (i.e. stent graft, occluder, and good sergeant)

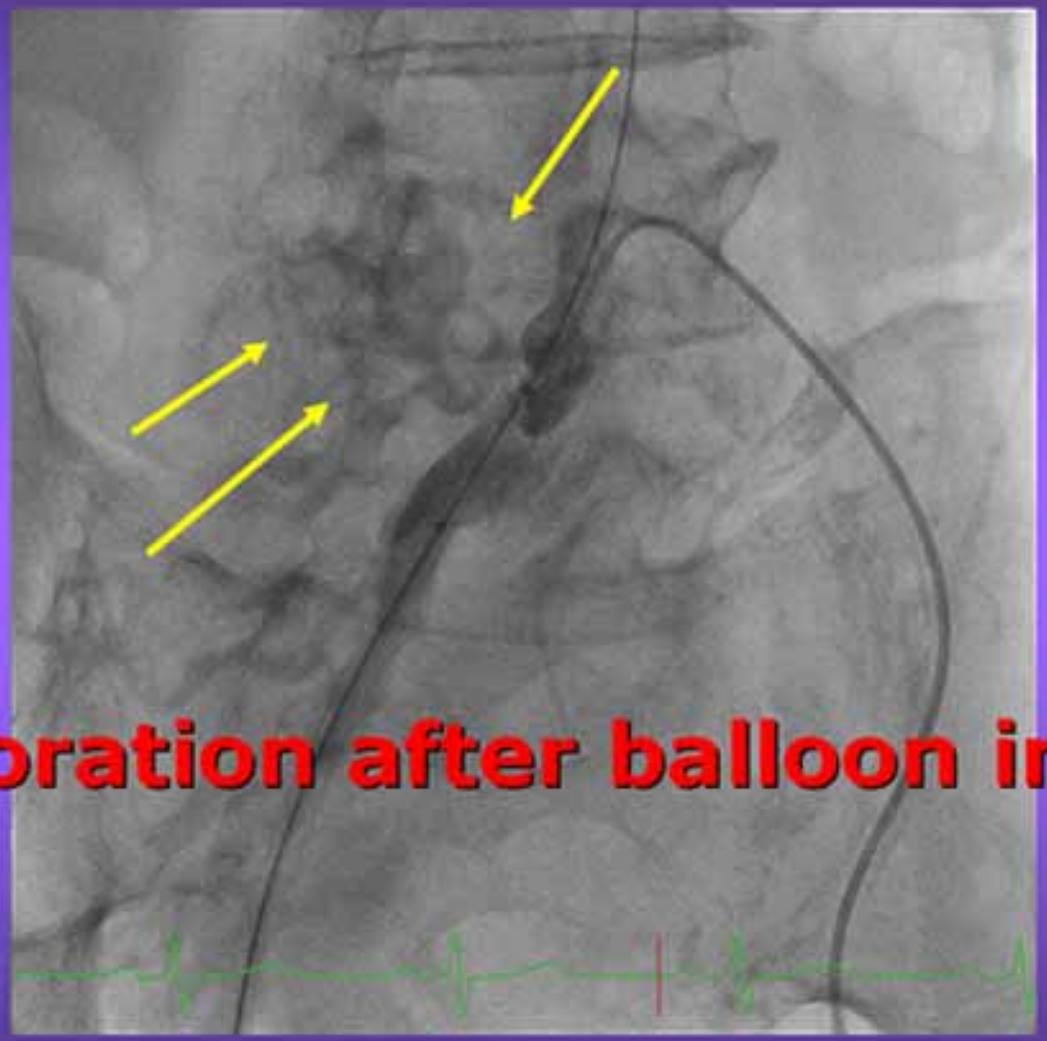

Perforation after balloon inflation

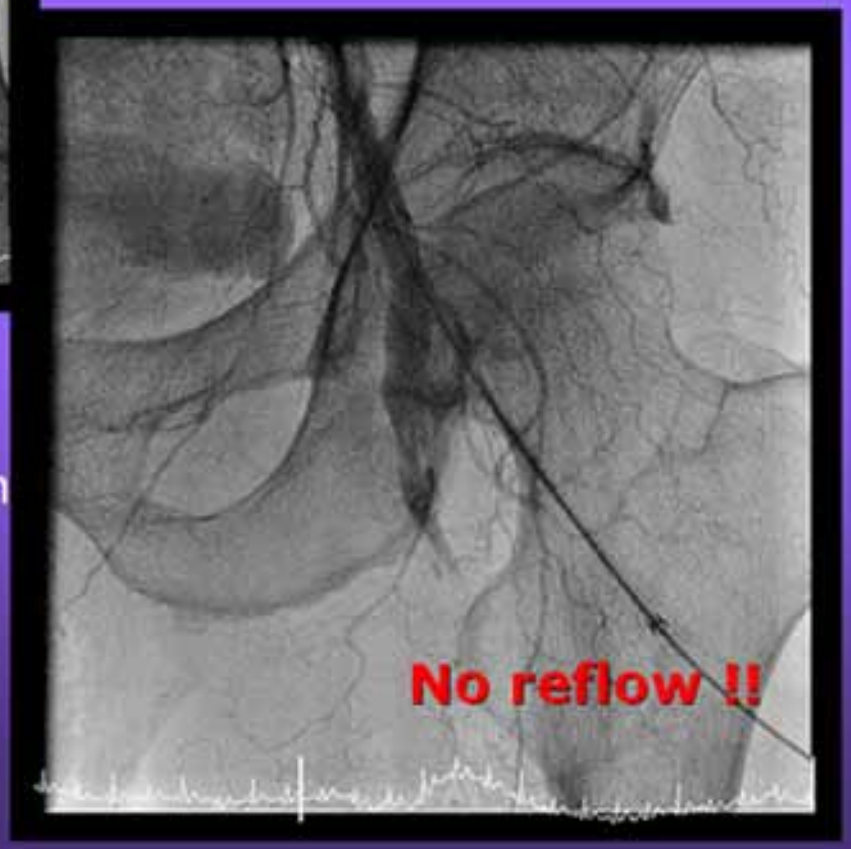

7mm balloon inflation
after LUMINEXX stent implantatin

Bilateral Iliac occlusion

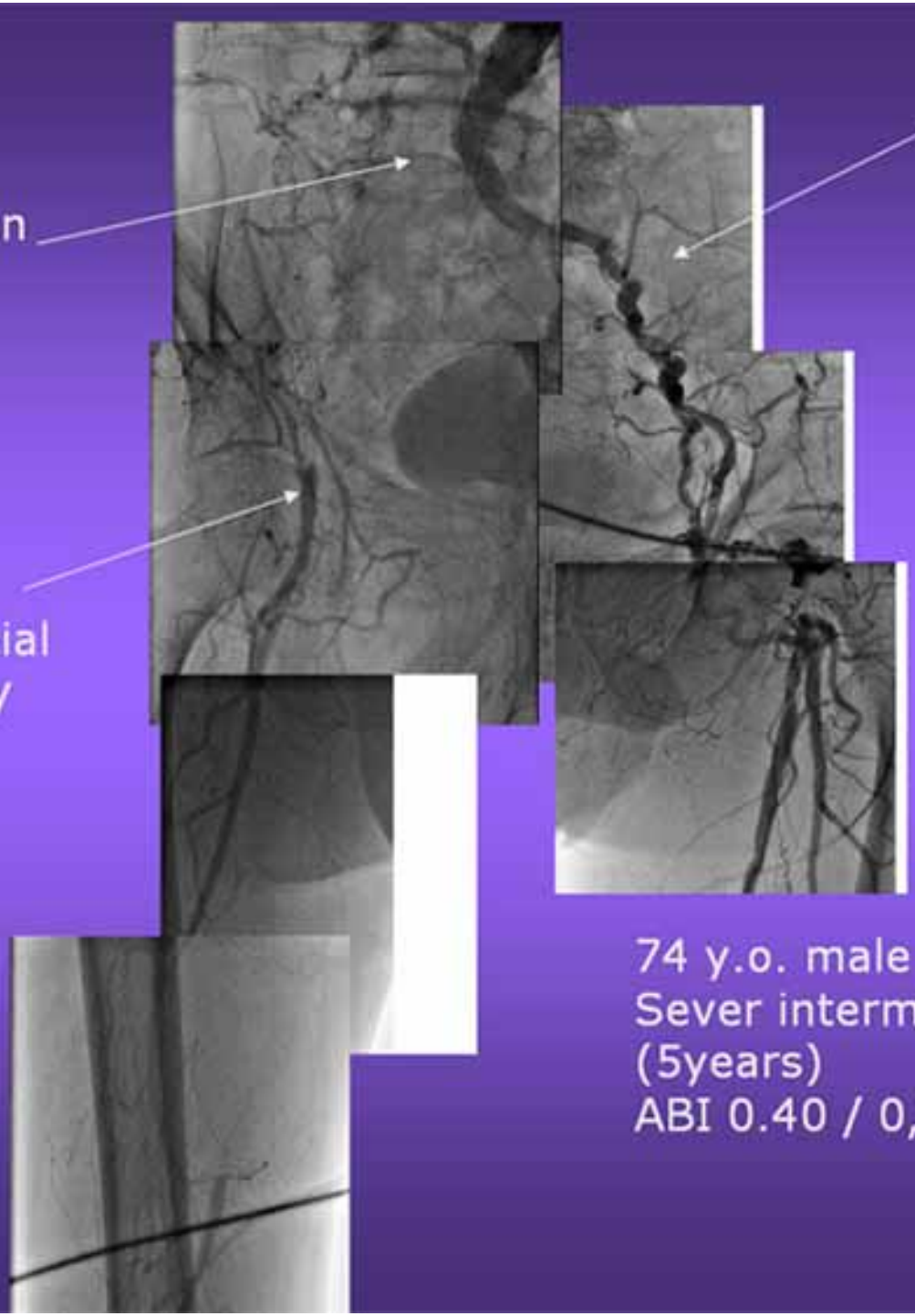

Right common iliac artery occlusion

Left external iliac artery occlusion

Right superficial femoral artery occlusion

74 y.o. male
Sever intermittent caludication (5years)
ABI 0.40 / 0,57

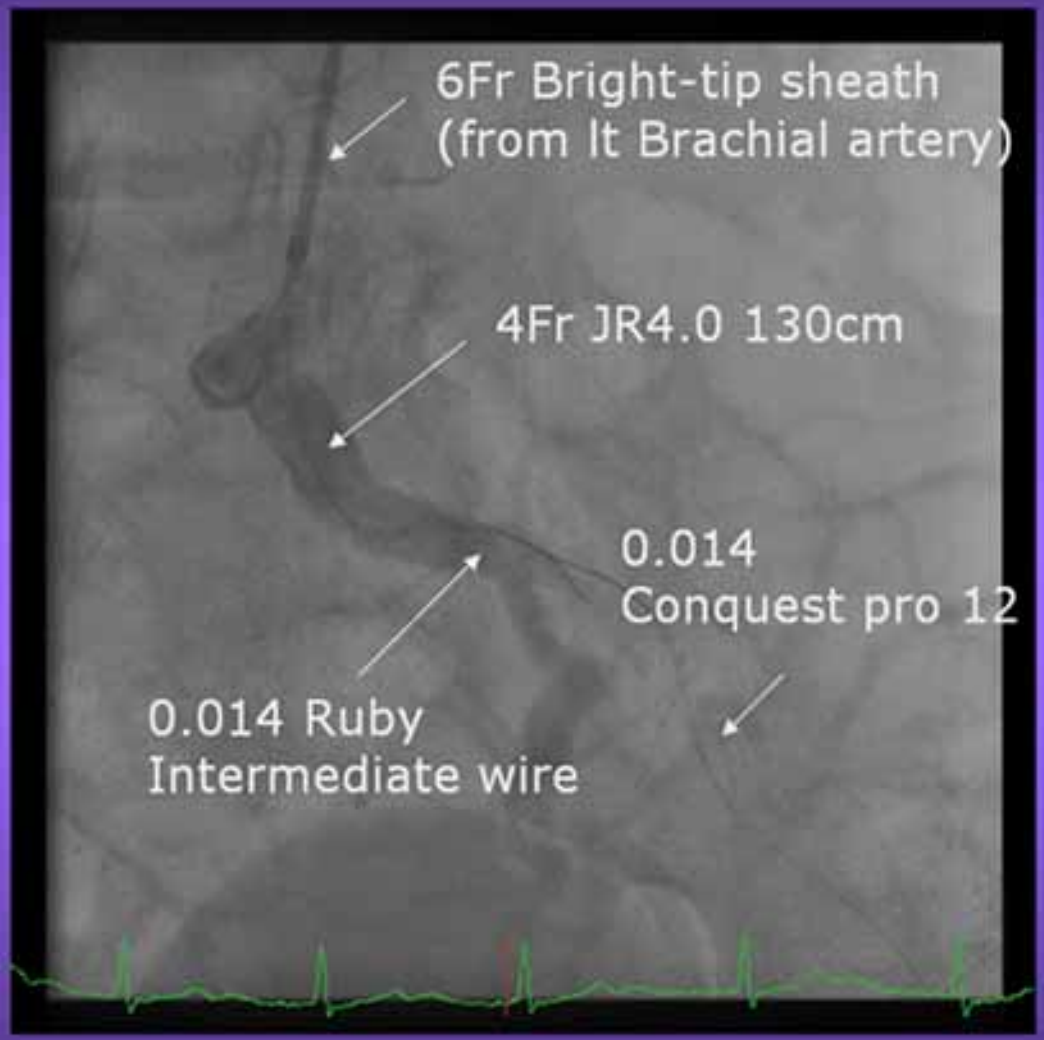
6Fr Bright-tip sheath
(from lt Brachial artery)
4Fr JR4.0 130cm
0.014
Conquest pro 12
0.014 Ruby
Intermediate wire


0.014 Conquest
Pro 12
0.014 Ruby
Intermediate
0.0
Inte
Savvy 2.0-20
(J&J)
From lt Popliteal artery

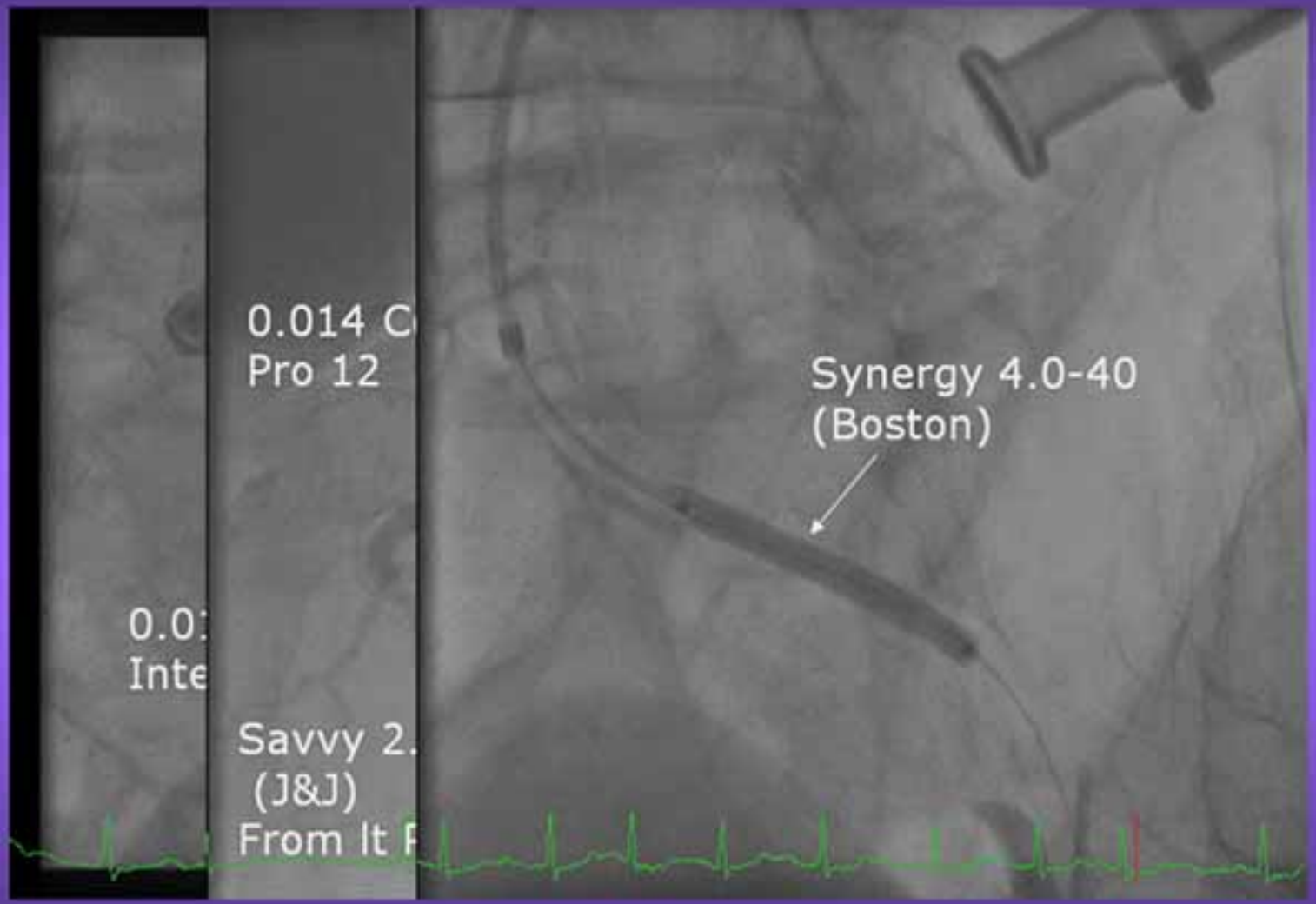
0.014 C
Pro 12
Synergy 4.0-40
(Boston)
0.0
Inte
Savvy 2.
(J&J)
From It F

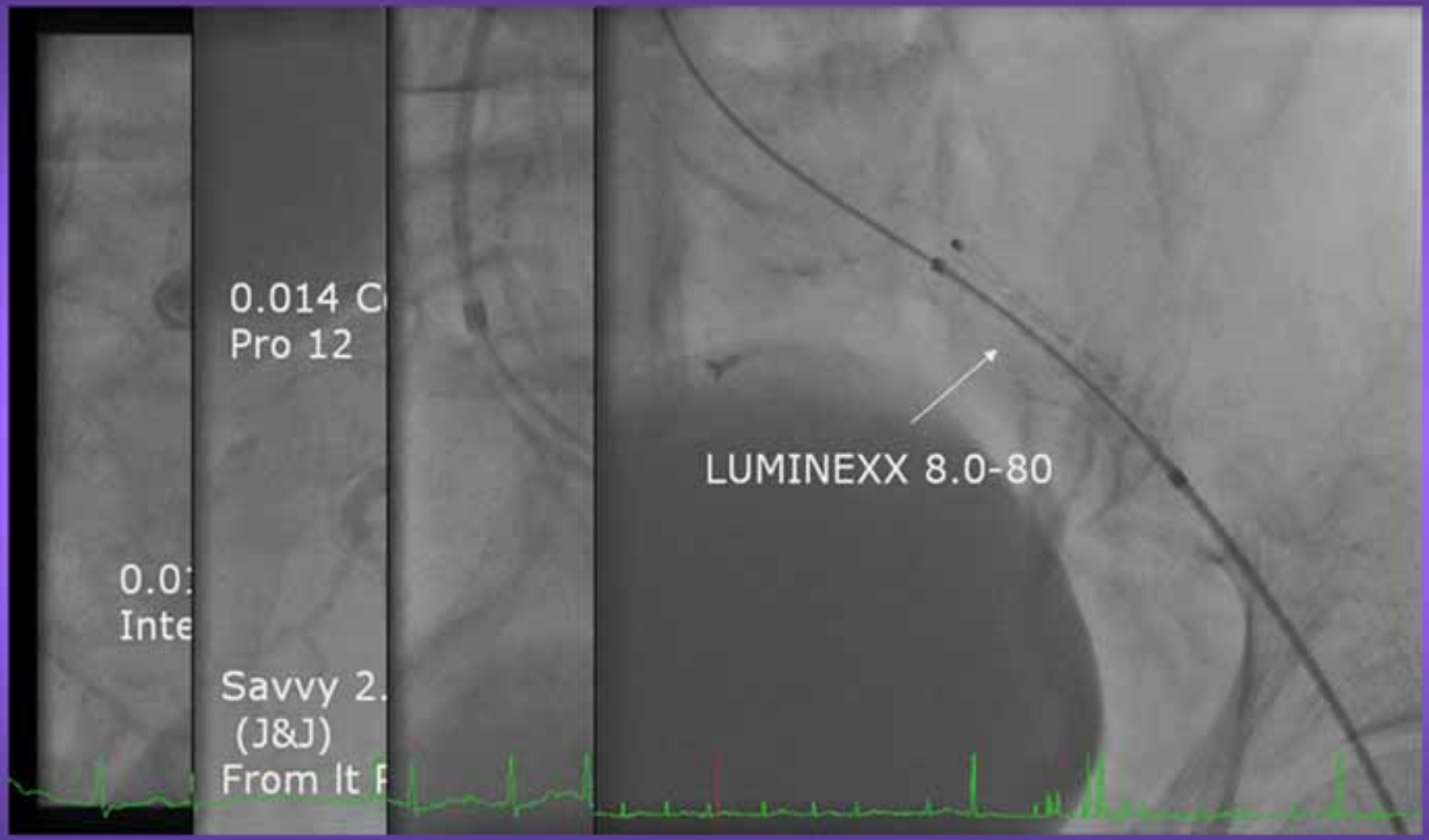
0.014 C
Pro 12
LUMINEXX 8.0-80
0.0
Inte
Savvy 2.
(J&J)
From It

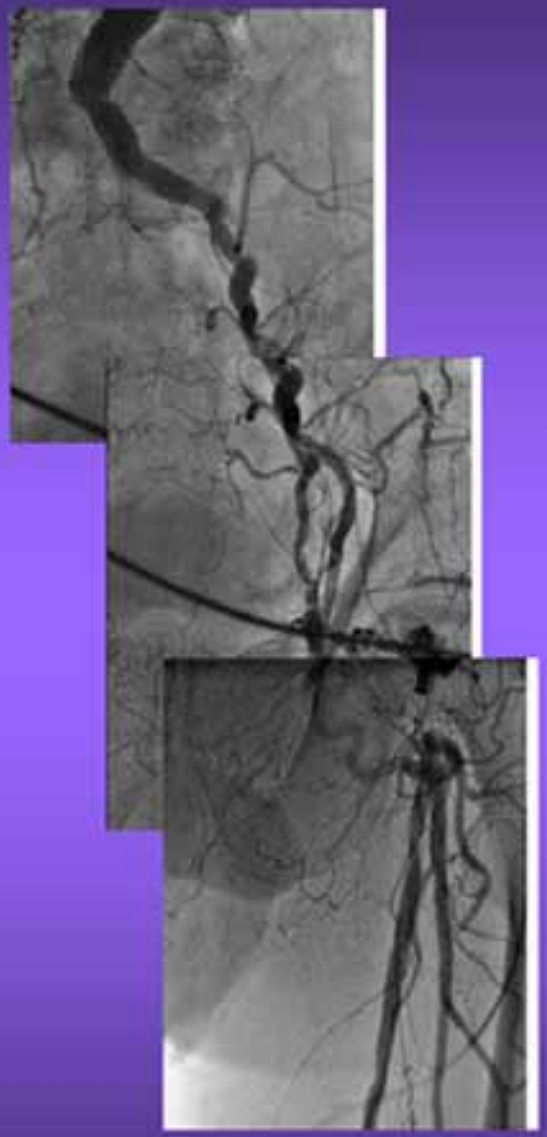

Pre PPI
ABI 0.57

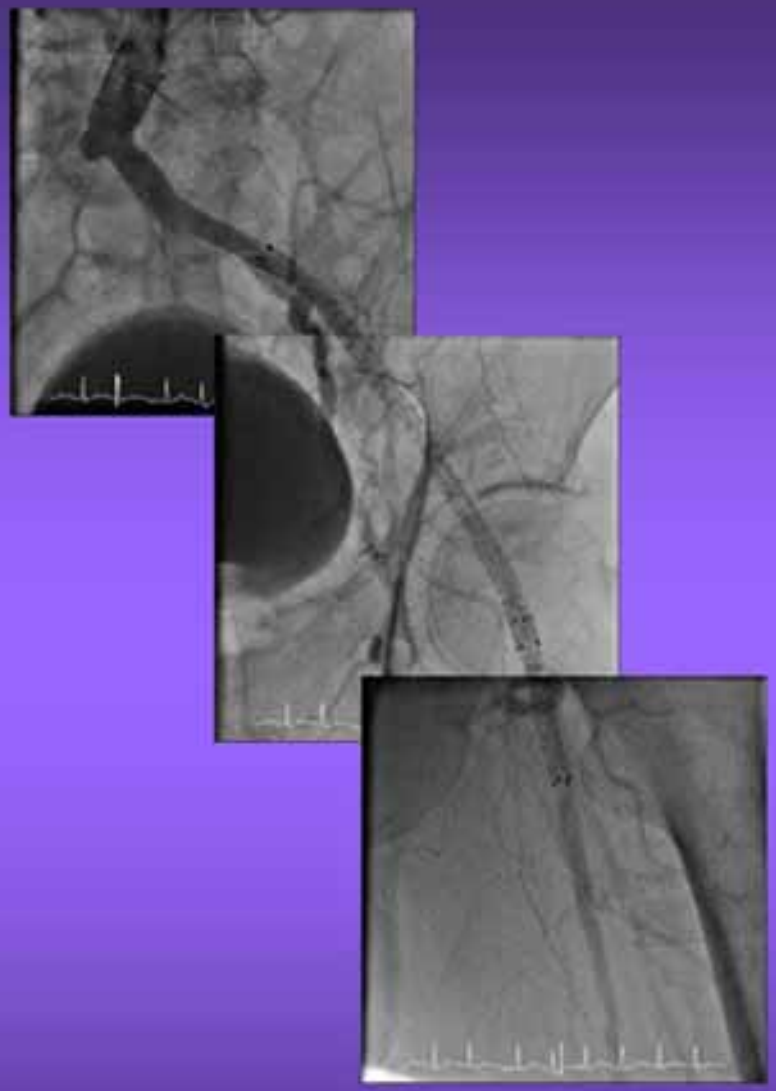

Post PPI
ABI 1.06

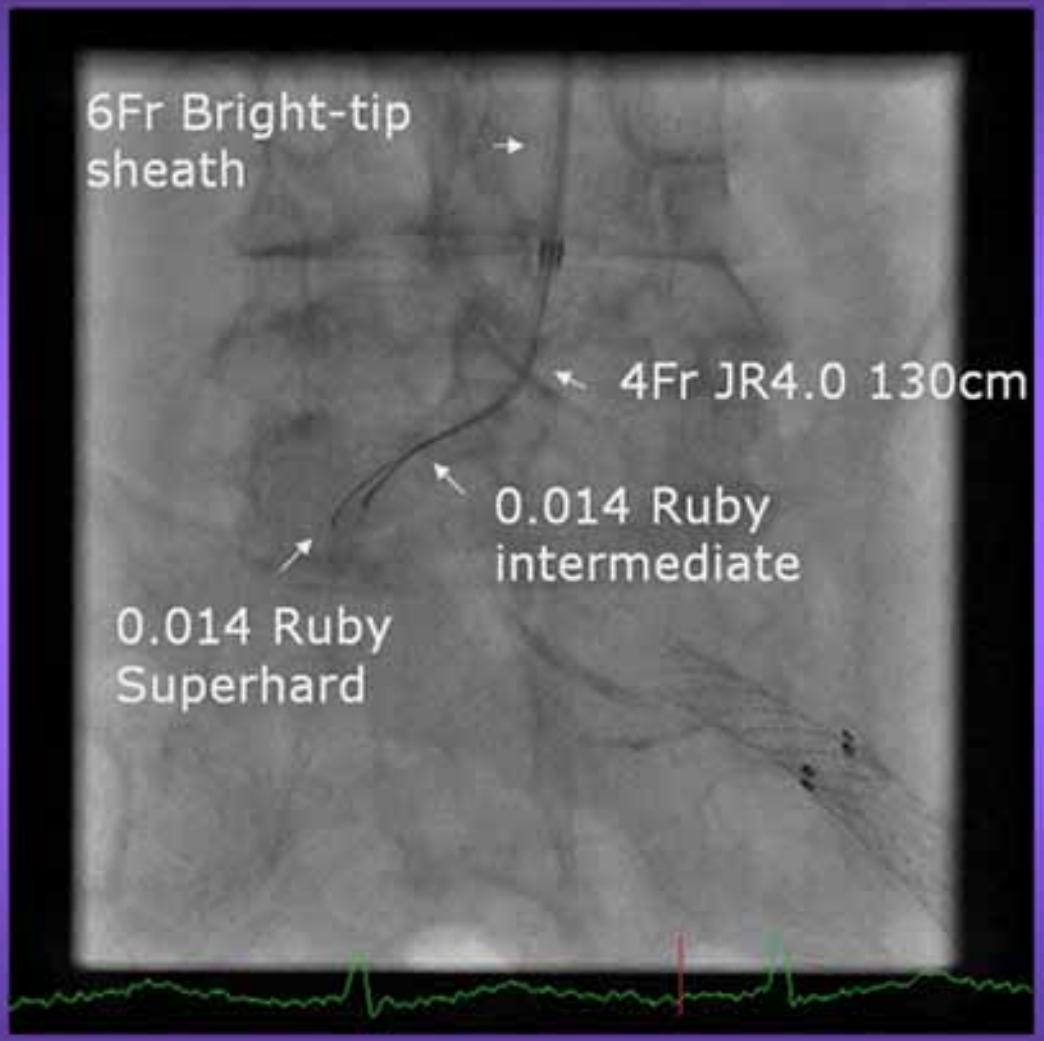
6Fr Bright-tip
sheath
4Fr JR4.0 130cm
0.014 Ruby
intermediate
0.014 Ruby
Superhard

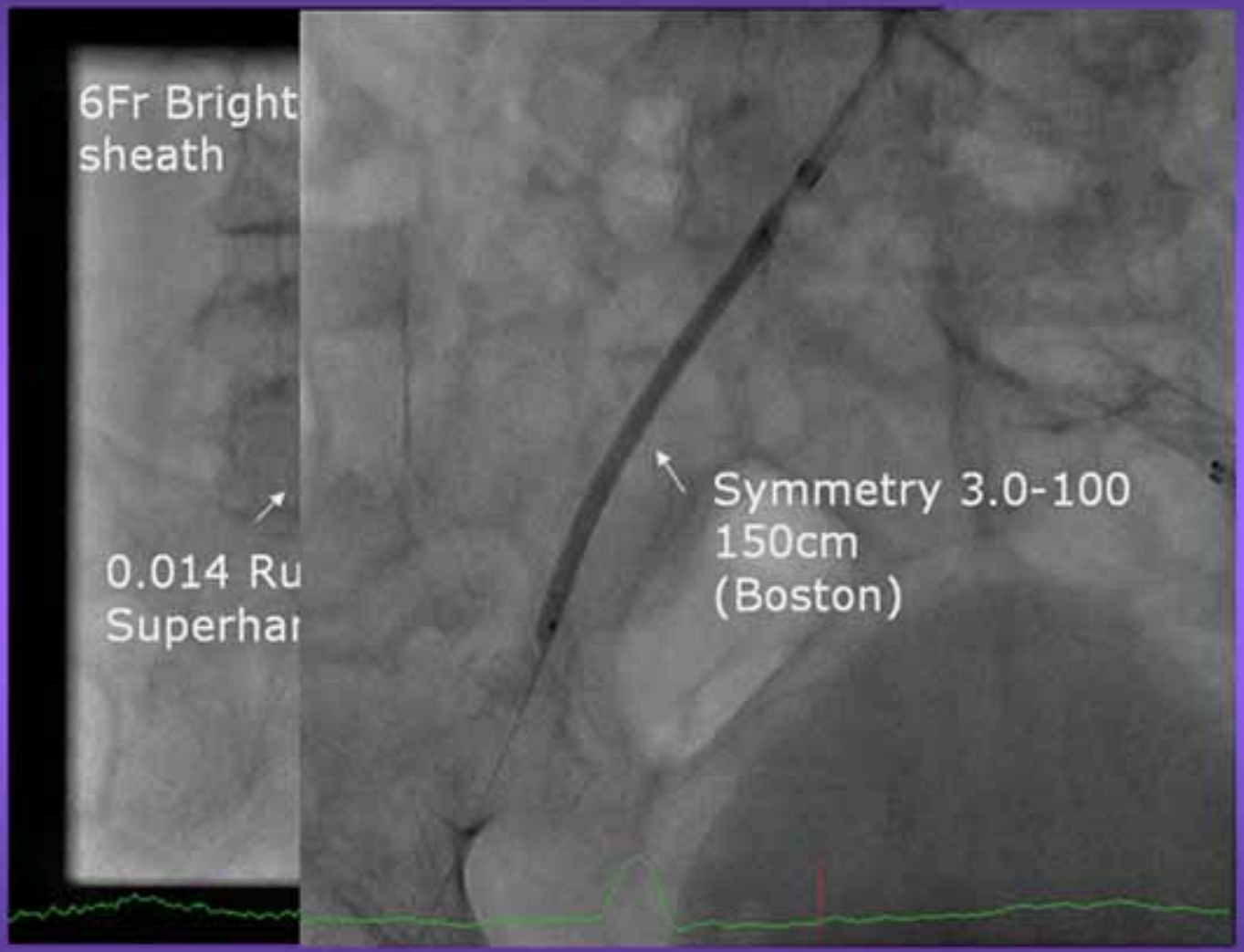
6Fr Bright
sheath
0.014 Ru
Superhar
Symmetry 3.0-100
150cm
(Boston)

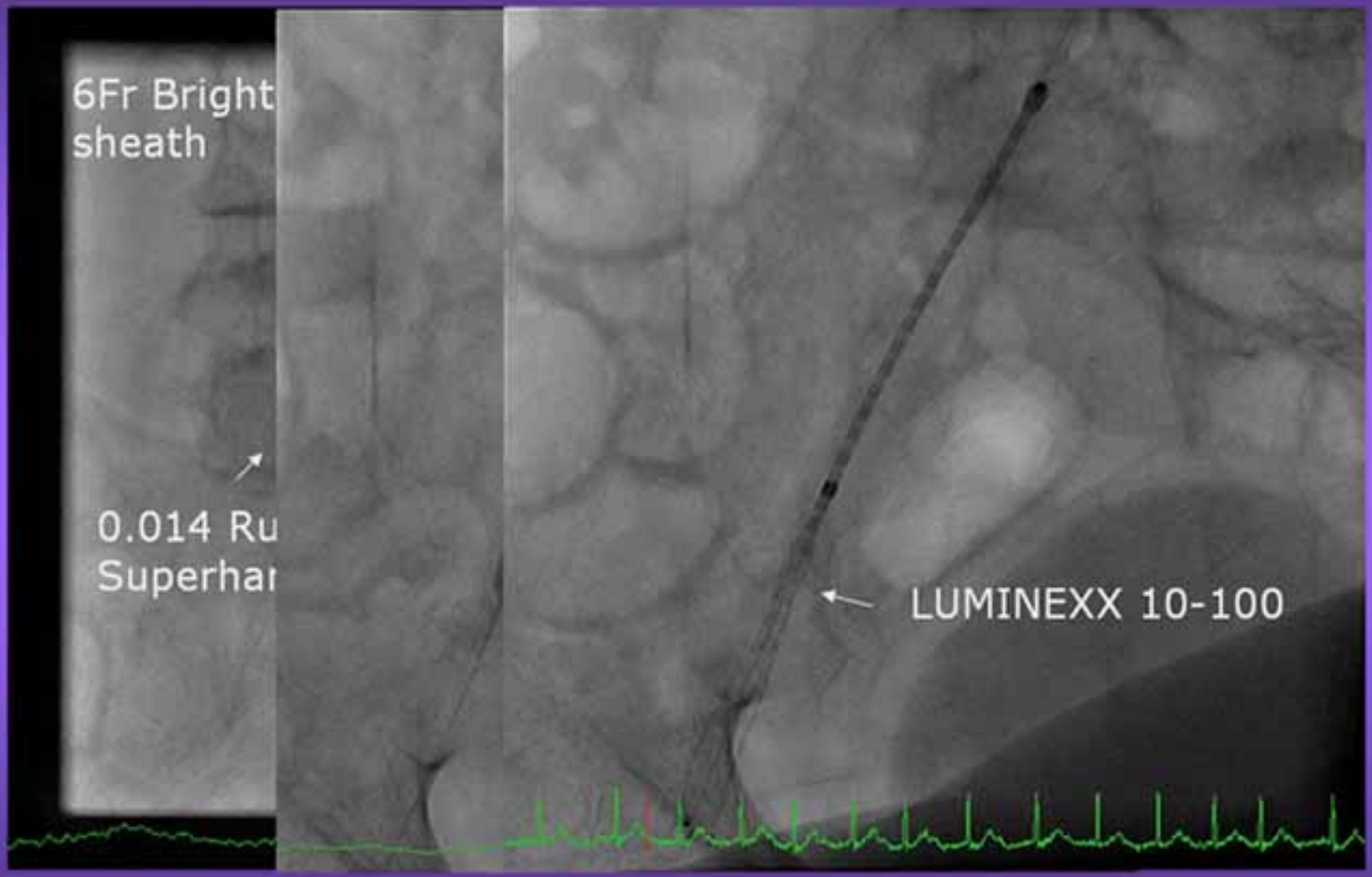
6Fr Bright
sheath
0.014 Ru
Superhar
LUMINEXX 10-100


Pre PPI
ABI 0.40
Post PPI
ABI 0.73

Summary, Iliac artery intervention

- Stent already has the enough clinical evidences with the good long term result
- Keep the mind to avoid the complication during the procedure.

Ilio-Femoral Disease

- Iliac artery
- Femoral-Popliteal artery

Femoral-Popliteal artery

- Anatomical feature
  - Extra abdominal space
  - Long and medium artery
  - Deep Femoral artery
  - Access
    - Bi-lateral femoral, popliteal

Holy side of SFA PPI

- Poor risk of life threating complication

- Easy to access
  - Antero-, or retro- approach (ipsi-lateral, pop. A approach, or contra lateral)

Dark side of SFA PPI

- Low Success Rate
  - Because of CTO
- Low Patency Rate
  - Because of the stent fracture

Chronic total occlusion

Success rate of CTOs in our hospital (Jun. 2004－May 2005)

Iliac artery	14 / 15 (93%)
Superficial Femoral Artery	29 / 40 (73%)
Below Knee	8 / 9 (89%)
Total	51 / 64 (80%)

Impairment of the strategy of the treatment of SFA CTOs

- Changes the Guide wire
  Radiforcus wire(0.035)
  ->Treasure12(0.018)
  ->Ruby series(0.014)
- US(Duplex) guidance
- Popliteal approach

Success rate of CTOs in our hospital (April 2005－March 2006）

◆ Iliac artery	22 / 22 (100%)
◆ Superficial Femoral Artery	32 / 40 (80%)
◆ Below Knee	22 / 23 (96%)
◆ Total	76 / 85 (89%)

Success rate of CTOs in our hospital (April 2005－March 2006）

◆ Iliac artery	22 / 22 (100%)
◆ Superficial Femoral Artery	32 / 40 (80%)
◆ Below Knee	22 / 23 (96%)
◆ Total	76 / 85 (89%)

New Device, for sub-intima methods



Lumed(J&J) Outback

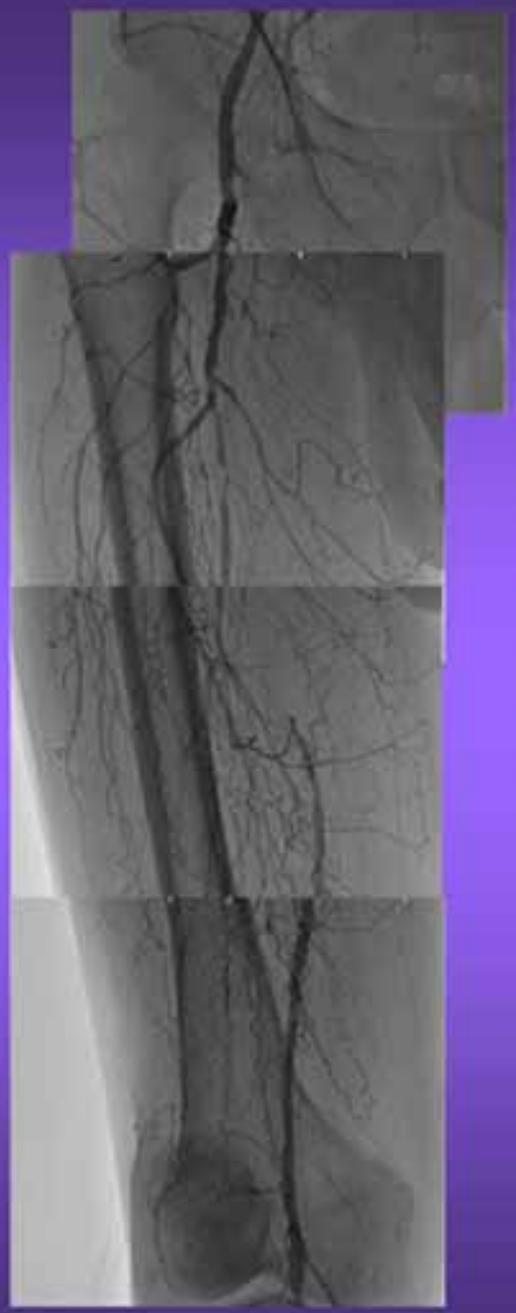

67 y.o. male

Bilateral SFA total occlusion

Rt F-P bypass was done 5years ago, but occluded immediately.

ABI decreased to 0.45

Fontaine IIb

0.018 Treasure 12 wire crossed the occluded lesion, and three LUMINEXX stents were implanted.

ABI increased to 0.86

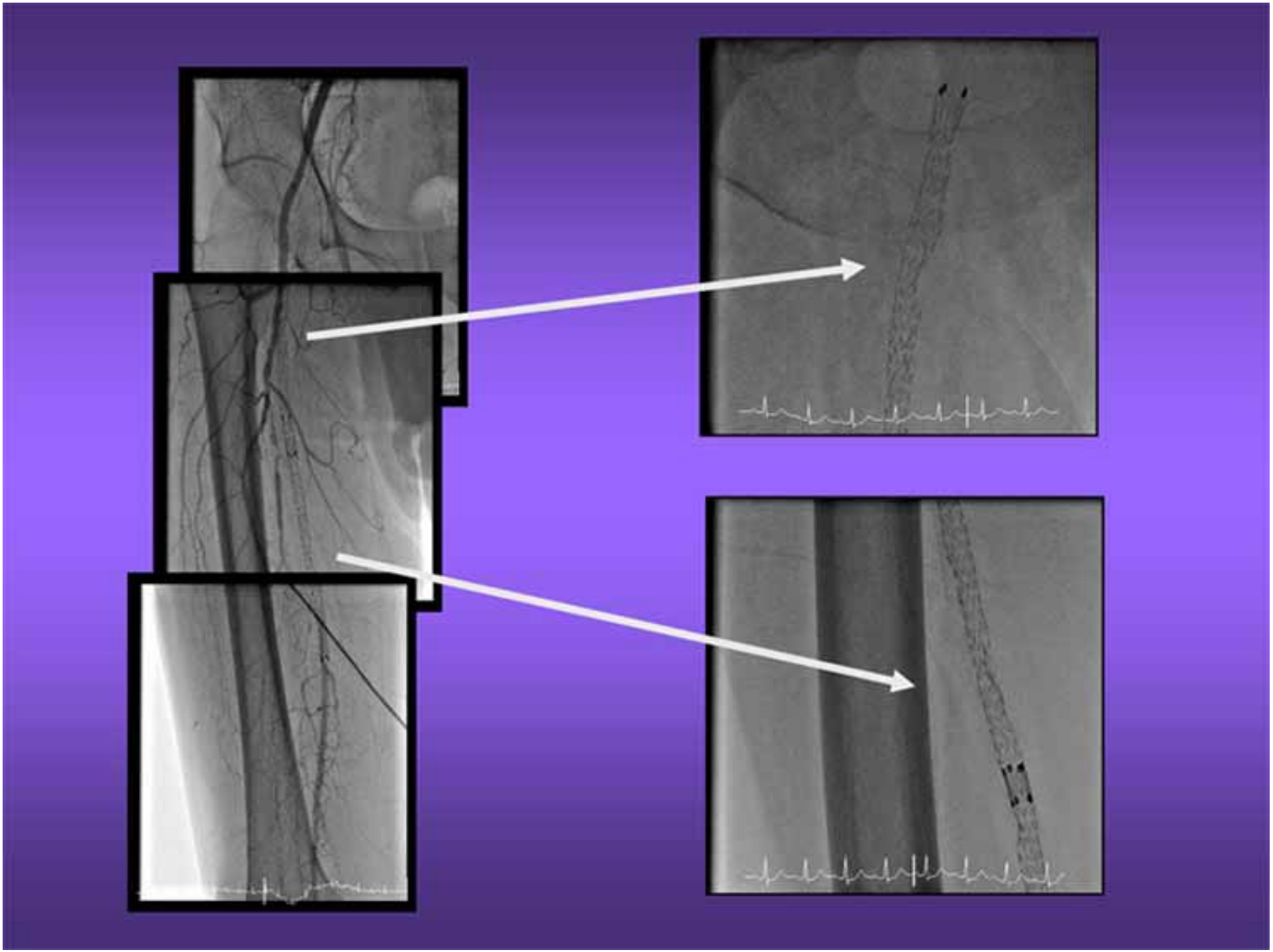

Stent Fracture

Stent Fracture

- **Prevalence and clinical impact of stent fractures after femoropopliteal stenting**
  - Dierk Scheinert, MD*, Susanne Scheinert, MD, Jacqueline Sax, Christopher Piorkowski, MD, Sven Bräunlich, MD, Matthias Ulrich, MD, Giancarlo Biamino, MD and Andrej Schmidt, MD
  - J Am Coll Cardiol, 2005; 45:312-315, doi:10.1016/j.jacc.2004.11.026
  - stent fractures were detected in 45 of 121 treated legs (37.2%).

Fracture and TLR ratio of SFA stenting in our hospital

	n	Average stent size	ABI Pre / Post (6 month)	TLR (6 month)	Stent frature (6 month)	Amputation (6 month)
Short NSES	38	7.6±1,1 – 44.3±9.59	0.69±0.12 / 0.86±0.16	1 (2.6%)	3 (7.9%)	1(2.6%)
Long NSES	48	7.7±0.9 – 145±70.1	0.62±0.19 / 0.84±0.19	7 (14.6%)	8 (16.6%)	1(2.1%)

Long NSES > total stent length 100mm
NSES = SMART + LUMINEXX

New Device, SFA

- New Device
  - Atherectomy (Laser, or mechanical)
  - SFA stent (Biovahn, Life stent)
  - DESES (SMART, Zilver)
  - Cryoplasty
  - CBA

Atherectomy

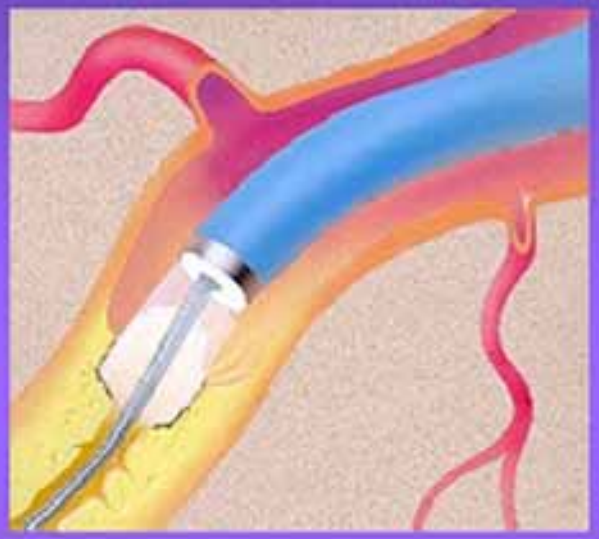

Laser

FoxHollow
SilverHawk

New Device, Cryoplasty

Step 1

Under image guidance, the doctor passes a very small balloon through a thin tube (catheter) into the blood vessel to the site of the blockage.



Step 2

The CryoPlasty balloon is filled with liquid nitrous oxide, which turns into a gas. The balloon expands and cools the plaque as it opens up the blockage.

Step 3

Once the blood vessel is opened, the gas is released and the balloon is deflated and removed.

New device v.s. POBA

- New Device
  - Athelectomy (Laser, or mechanical)
    - No evidence (equal)
  - SFA stent (Biovahn, Life stent)
  - DESES (SMART, Zilver)
  - Cryoplasty
  - CBA

New device v.s. POBA

- New Device
  - Athelectomy (Laser, or mechanical)
  - SFA stent (Biovahn, Life stent)
    - No evidence
  - DESES (SMART, Zilver)
  - Cryoplasty
  - CBA

New device v.s. POBA

- New Device
  - Athelectomy (Laser, or mechanical)
  - SFA stent (Biovahn, Life stent)
  - DESES (SMART, Zilver)
    - No evidence (equal)
  - Cryoplasty
  - CBA

New device v.s. POBA

- New Device
  - Athelectomy (Laser, or mechanical)
  - SFA stent (Biovahn, Life stent)
  - DESES (SMART, Zilver)
  - Cryoplasty
    - Slightly better than POBA
  - CBA

New device v.s. POBA

- New Device
  - Athelectomy (Laser, or mechanical)
  - SFA stent (Biovahn, Life stent)
  - DESES (SMART, Zilver)
  - Cryoplasty
    - Slightly better than POBA
  - CBA
    - No evidence
      - Compare with simple POBA

Summary, Femoral-Popliteal Artery

- Interventional treatment of SFA-Popliteal artery is safe.
- Chronic total occlusion limits the acute outcomes.
- Stent fracture limits the long term outcomes.
- Fracture and TLR ratio of short NSES are relatively low.

→ **New devices may improve these limitation**