Assessment of vulnerable plaque by OCT

Comparison with histology and possible clinical applications

Takashi Akasaka, M.D.
Department of Cardiovascular Medicine
Wakayama Medical University
Wakayama, Japan

Identification of vulnerable plaque

- Plaque prone to rupture

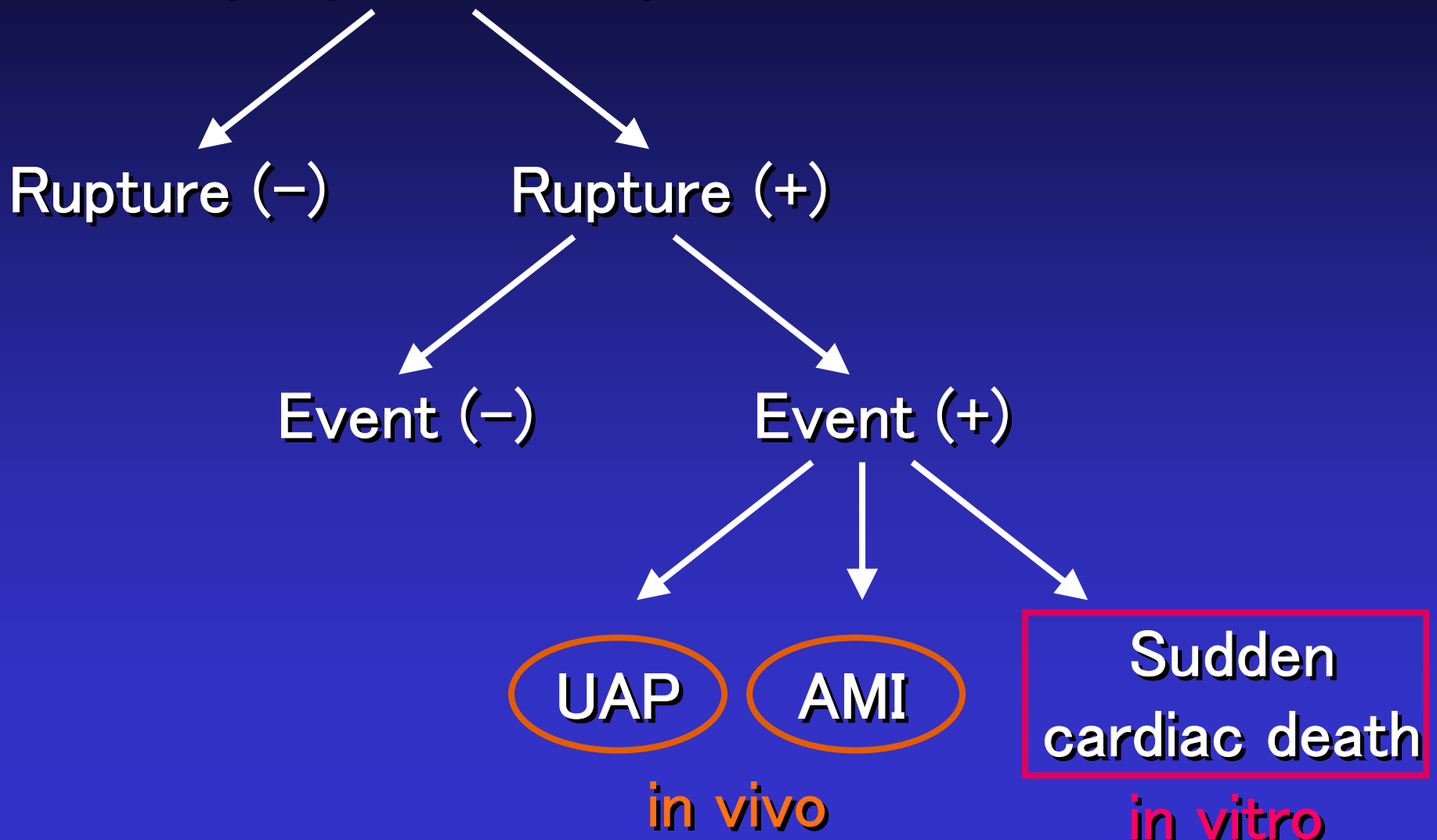

Pathohistology of vulnerable plaque（HE stain）

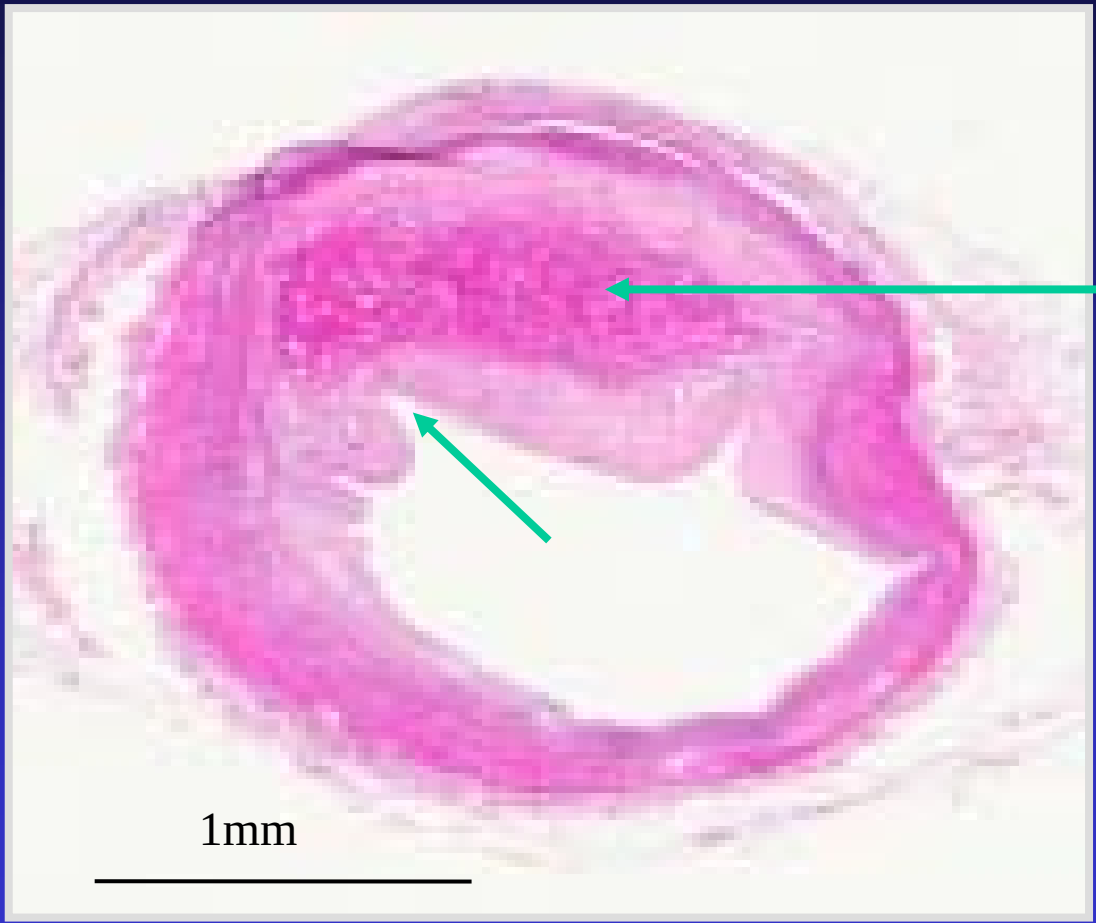

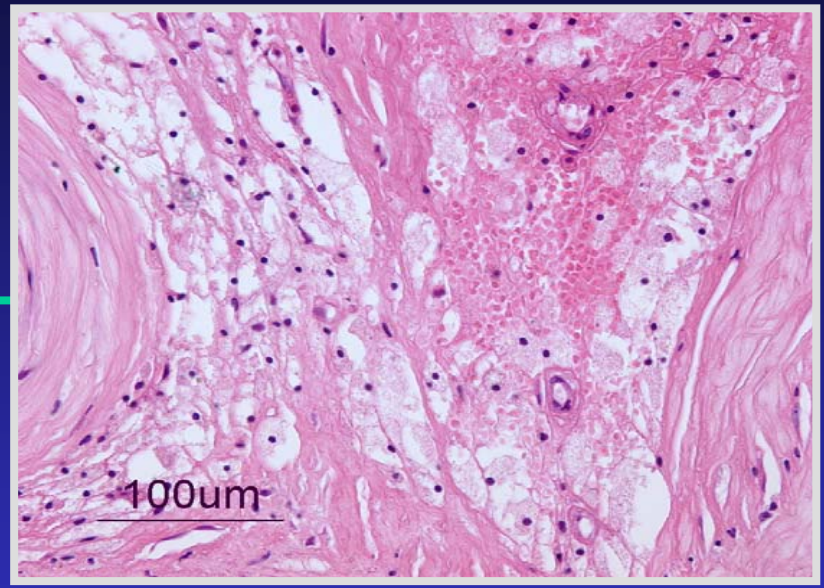

Thin fibrous cap

Large lipid core

Advanced atherosclerosis

Pathohistology of vulnerable plaque

- Positive remodeling
- Eccentric plaques
- Lipid-rich plaques (necrotic core)
- Thin fibrous cap (< 65 μm)
- Rupture (60%) or ulceration (30～40%) of fibrous caps
- Thrombus formation
- Macrophage accumulation

Pathohistology of vulnerable plaque

- Positive remodeling
- Eccentric plaques
- Lipid-rich plaques (necrotic core)
- Thin fibrous cap
- Rupture or ulceration of fibrous caps
- Thrombus formation
- Macrophage accumulation

OCT vs histology

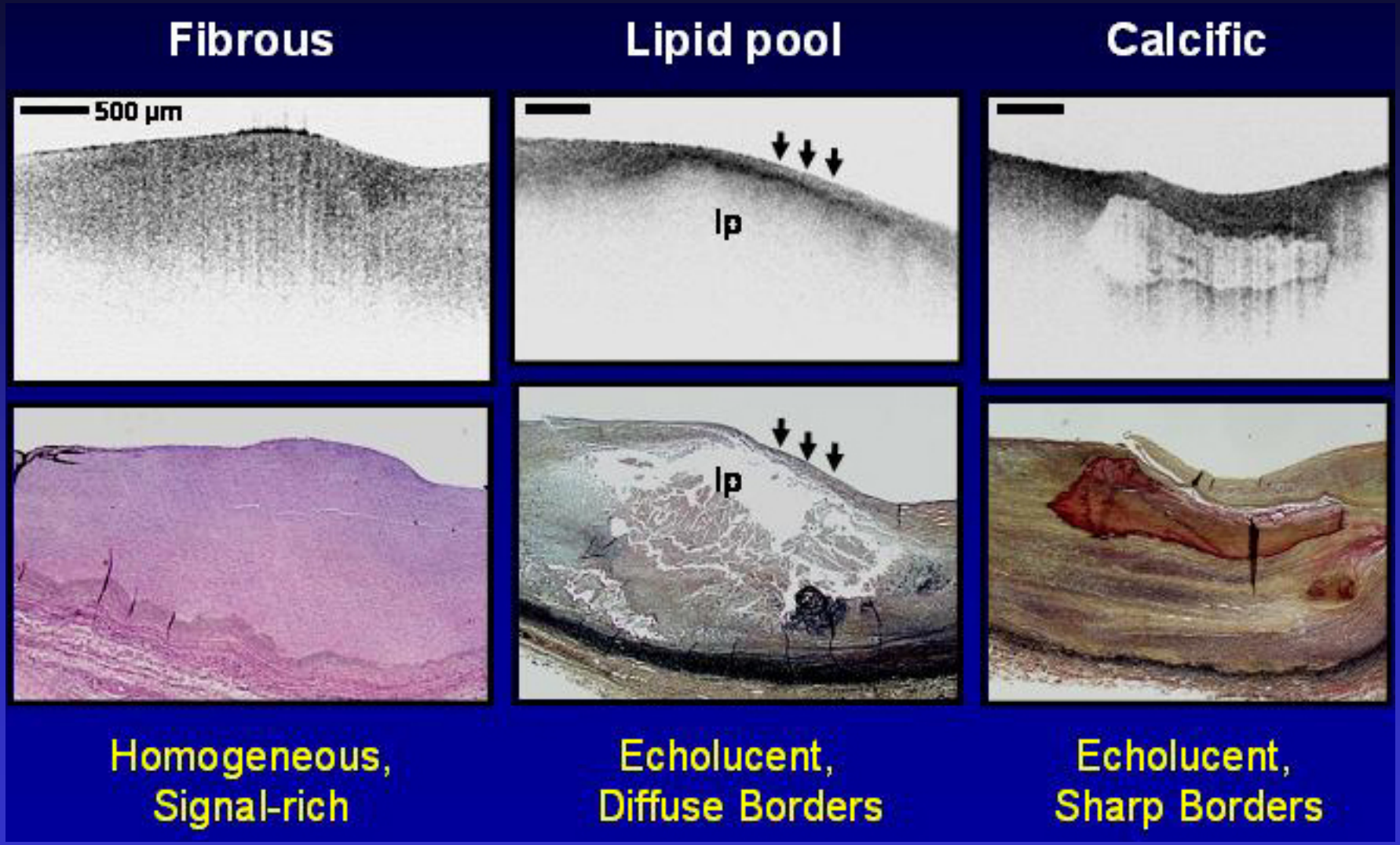

Yabushita et al. Circulation, 2002

Fibrous plaque

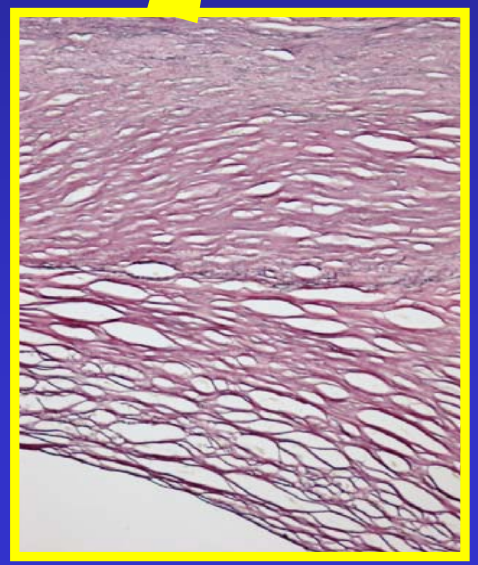

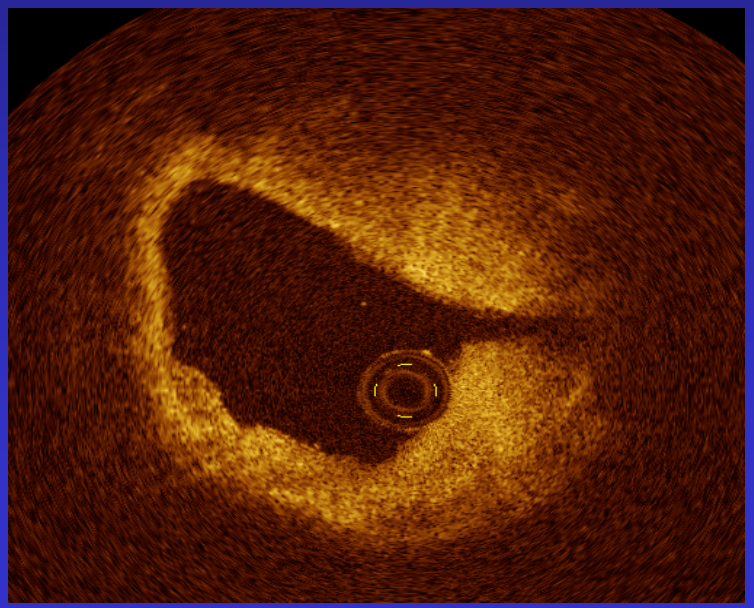

Fibrocalcific plaque

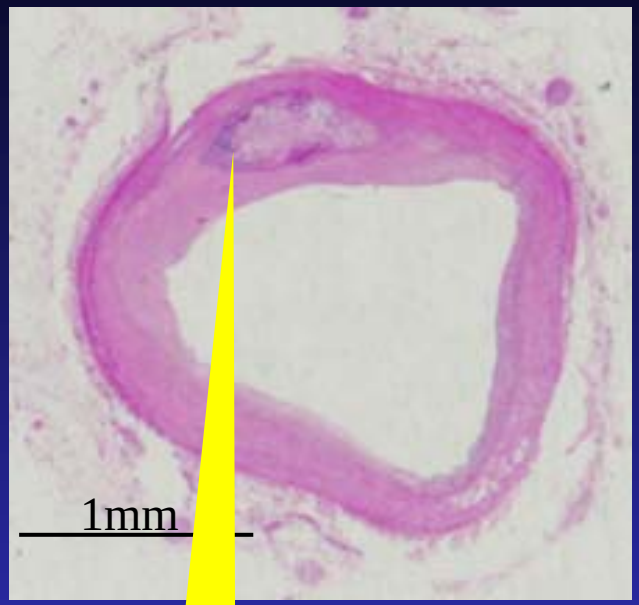

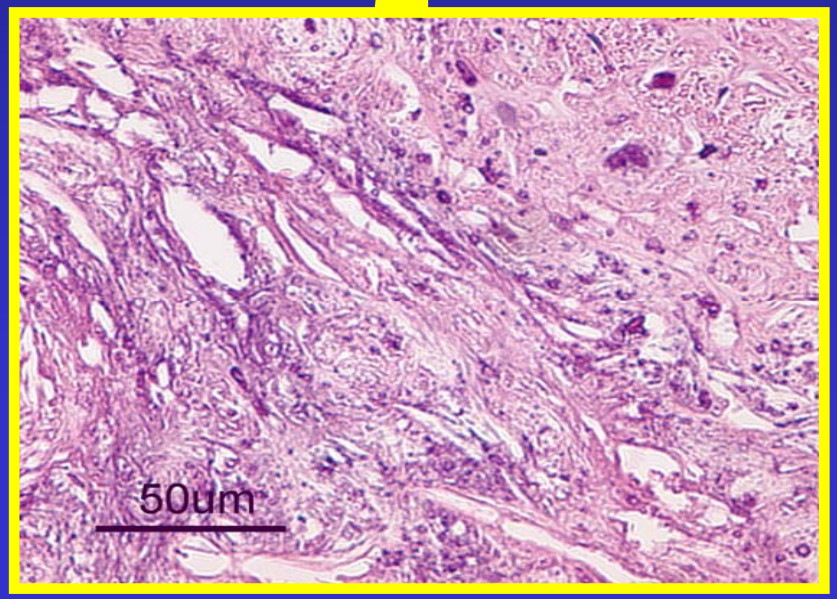

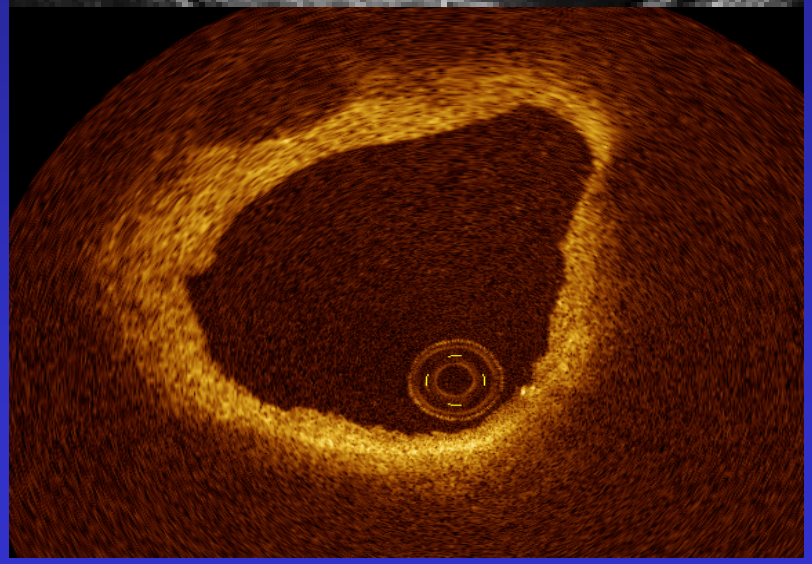

Fibro-lipidic plaque

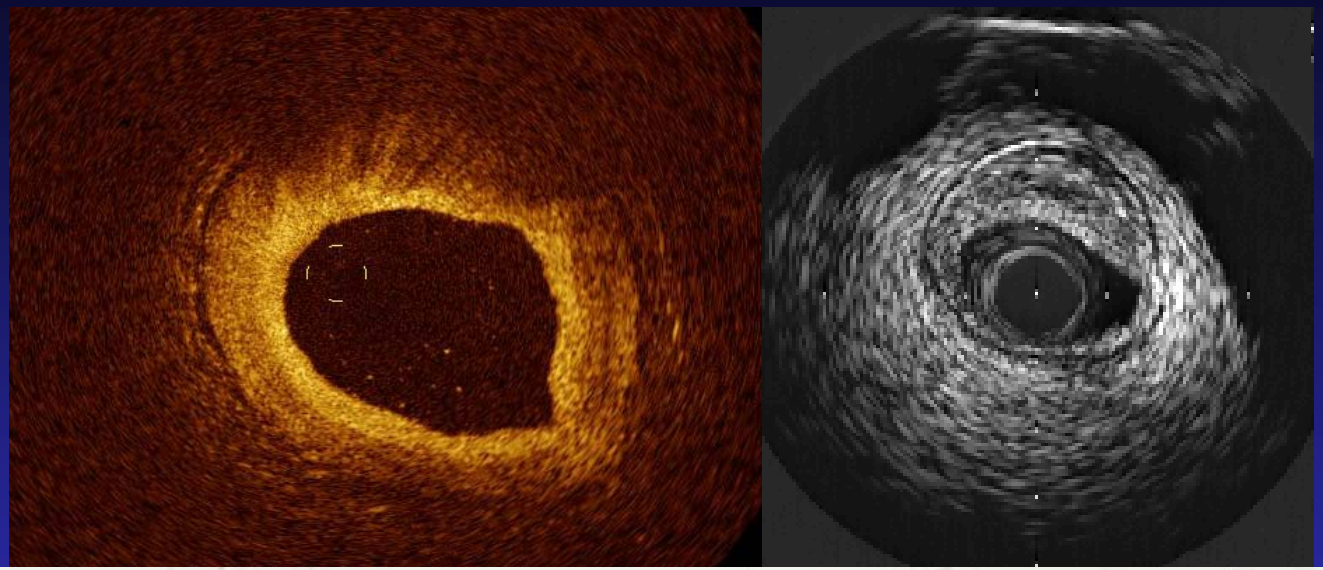

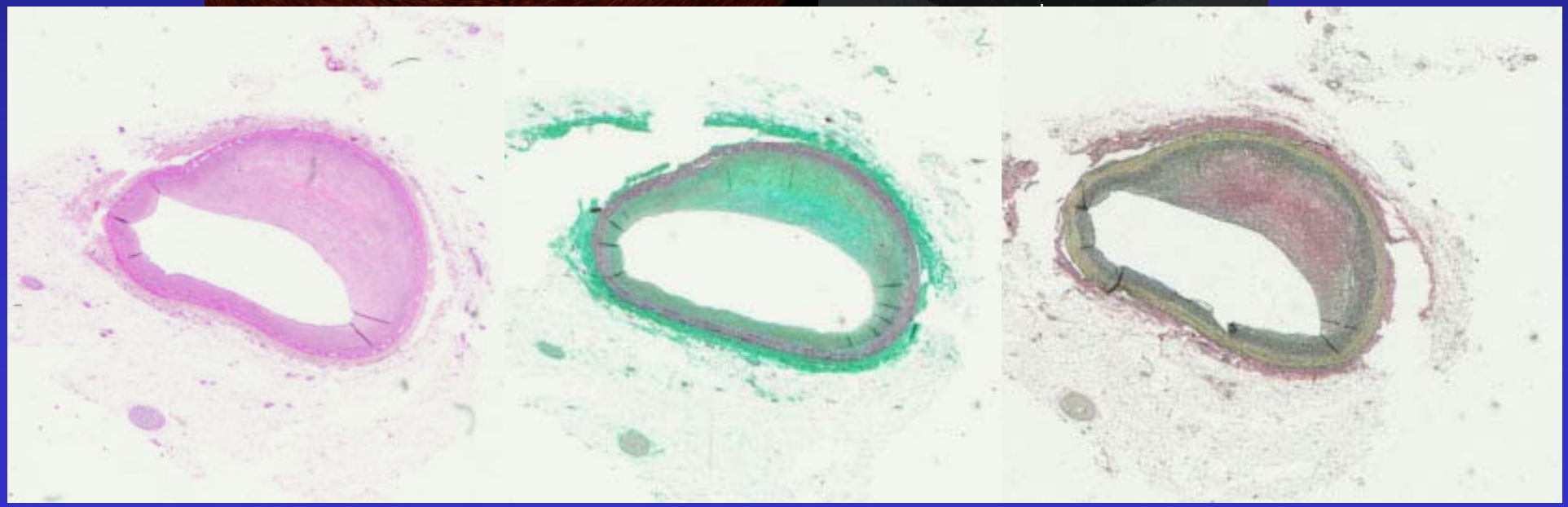

Tissue characterization by OCT and IVUS

Kume T, Akasaka T, et al (Am J Cardiol 97 : 1172 - 1175, 2006)

Pathohistological Diagnosis	Sensitivity	Specificity	Predictive Value Positive	Predictive Value Negative
OCT image				
Fibrous (n=43)	79	99	97	93
Fibrocalcific (n=82)	96	88	89	96
Lipid (n=41)	85*	94	83	95
IVUS image				
Fibrous (n=43)	88	86	69	95
Fibrocalcific (n=82)	98	96	96	98
Lipid (n=41)	59	97	86	87

Data are demonstrated as percentages. *$p<0.05$ vs IVUS

Pathohistology of vulnerable plaque
Assessment by OCT

- Positive remodeling △
- Eccentric plaques △
- Lipid-rich plaques (necrotic core) ○
- Thin fibrous cap
- Rupture or ulceration of fibrous caps
- Thrombus formation
- Macrophage accumulation

Pathohistology of vulnerable plaque
Assessment by OCT

- Positive remodeling △
- Eccentric plaques △
- Lipid-rich plaques (necrotic core) ○
- Thin fibrous cap
- Rupture or ulceration of fibrous caps
- Thrombus formation
- Macrophage accumulation

Study Design

Oral aspirin (162 mg) and intravenous heparin (100 U/kg) were administered before PCI.

Cardiac catheterization was performed by the femoral approach, using a 7F sheath and catheters.

- **Thrombectomy** ***(Export catheter ® Medtronic Japan)***

↓ **TIMI grade III**

- **IVUS** ***(Atlantis SR Pro® 2.5F, 40-MHz; Boston Scientific, Natick, MA, USA)***

↓

- **CAS** ***(Angioscope MC-800E and the optic fiber AS-003, Nihon Kohden)***

↓

- **OCT** ***(ImageWire®; LightLab Imaging, Westford, MA, USA)***

Inferior AMI（71y. M）

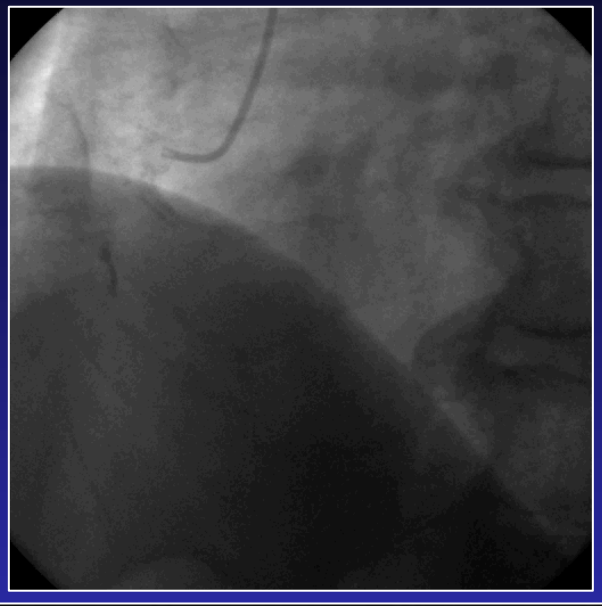

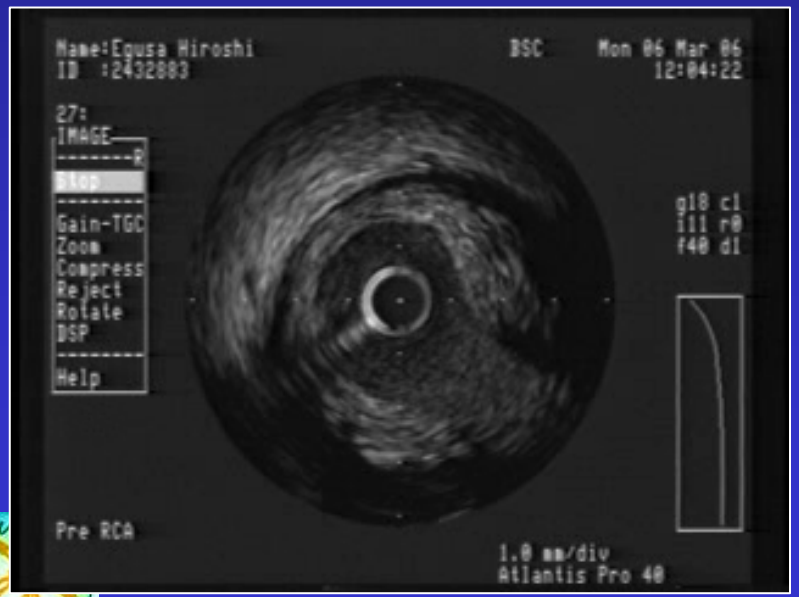

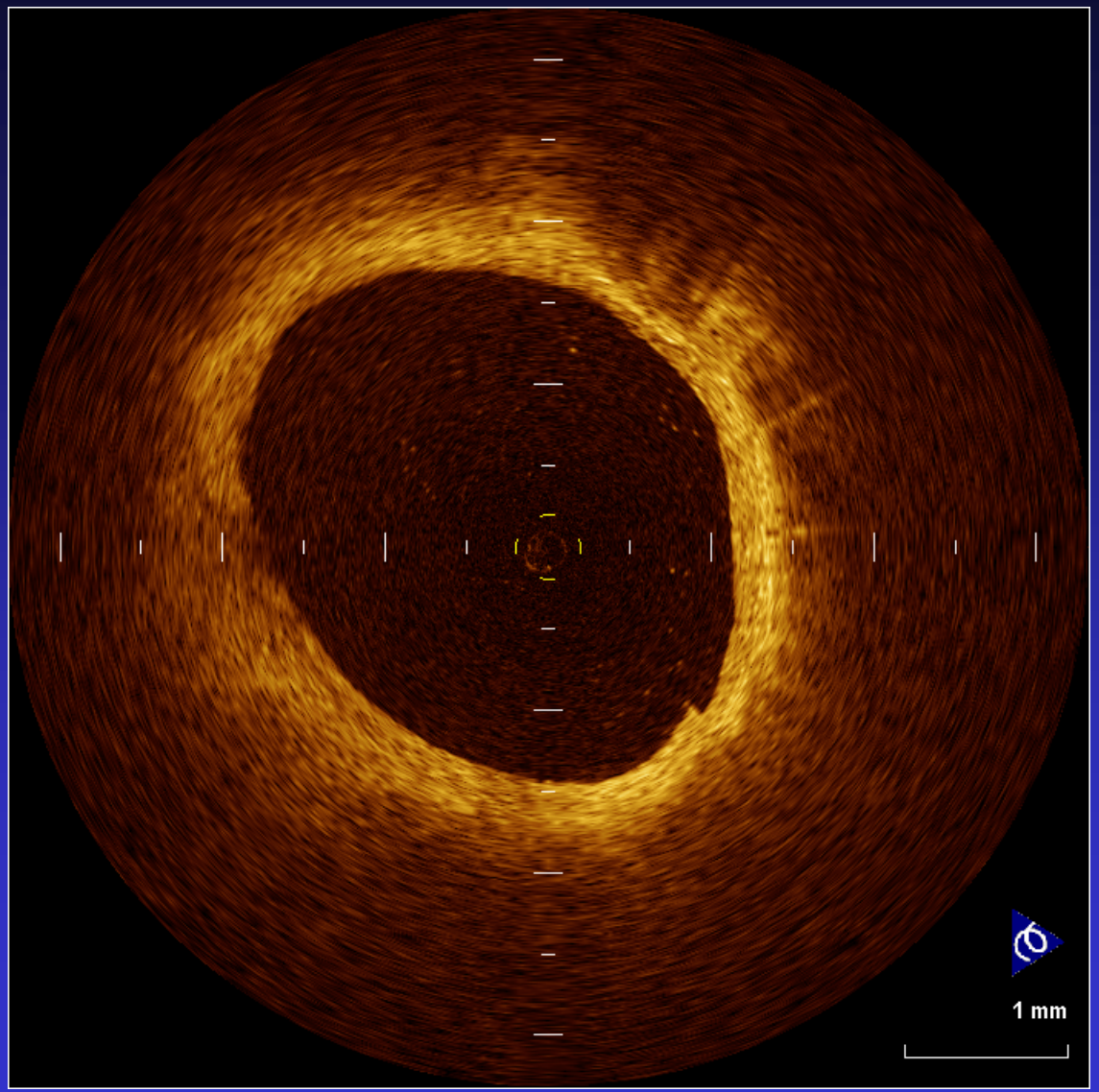

Inferior-AMI（71y.o., M） Plaque Rupture

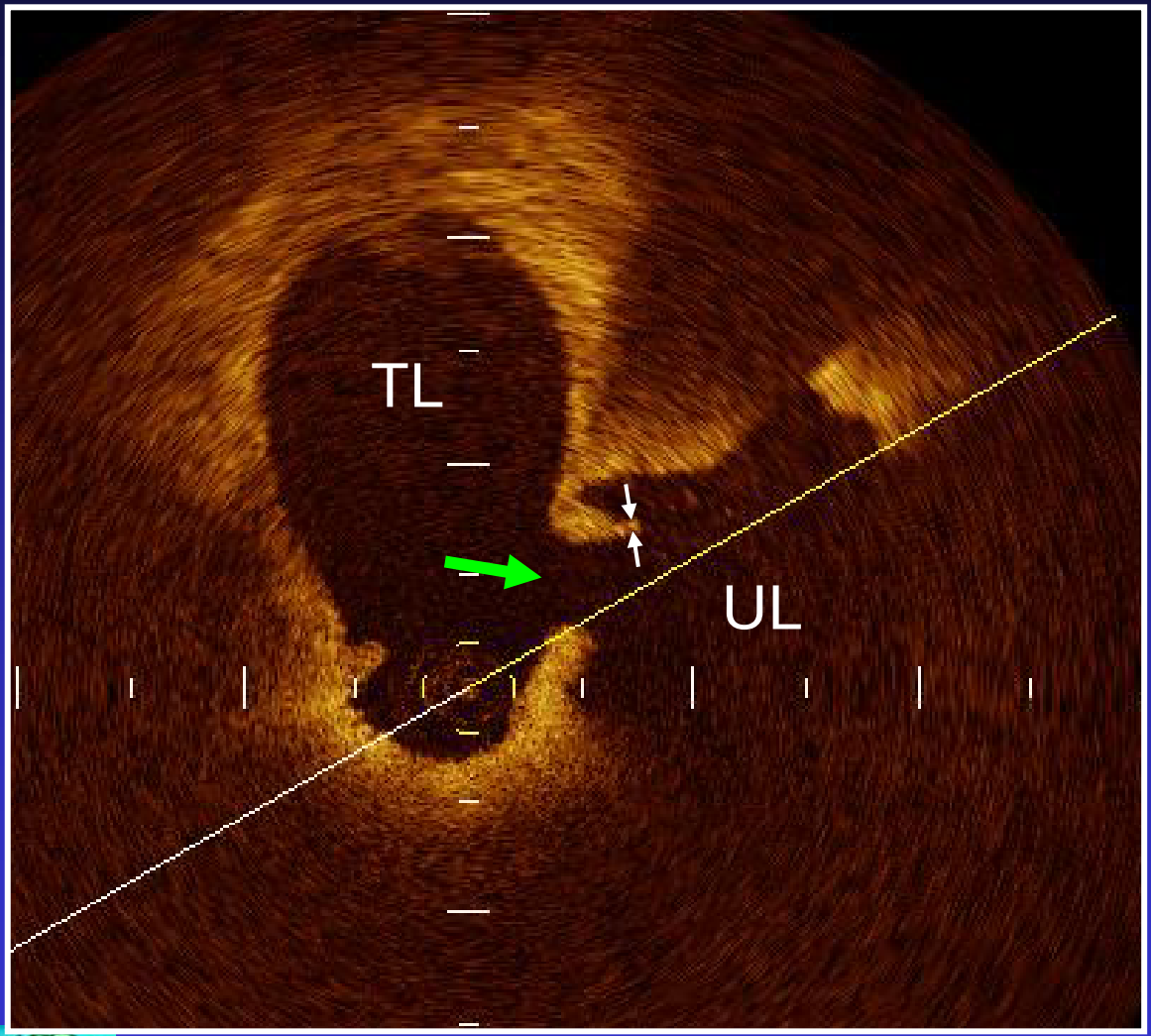

Ruptured Fibrous Cap

Fibrous Cap Thickness
= 40μm

TL : True Lumen

UL : Ulceration



Anteroseptal AMI （80y.o., M）

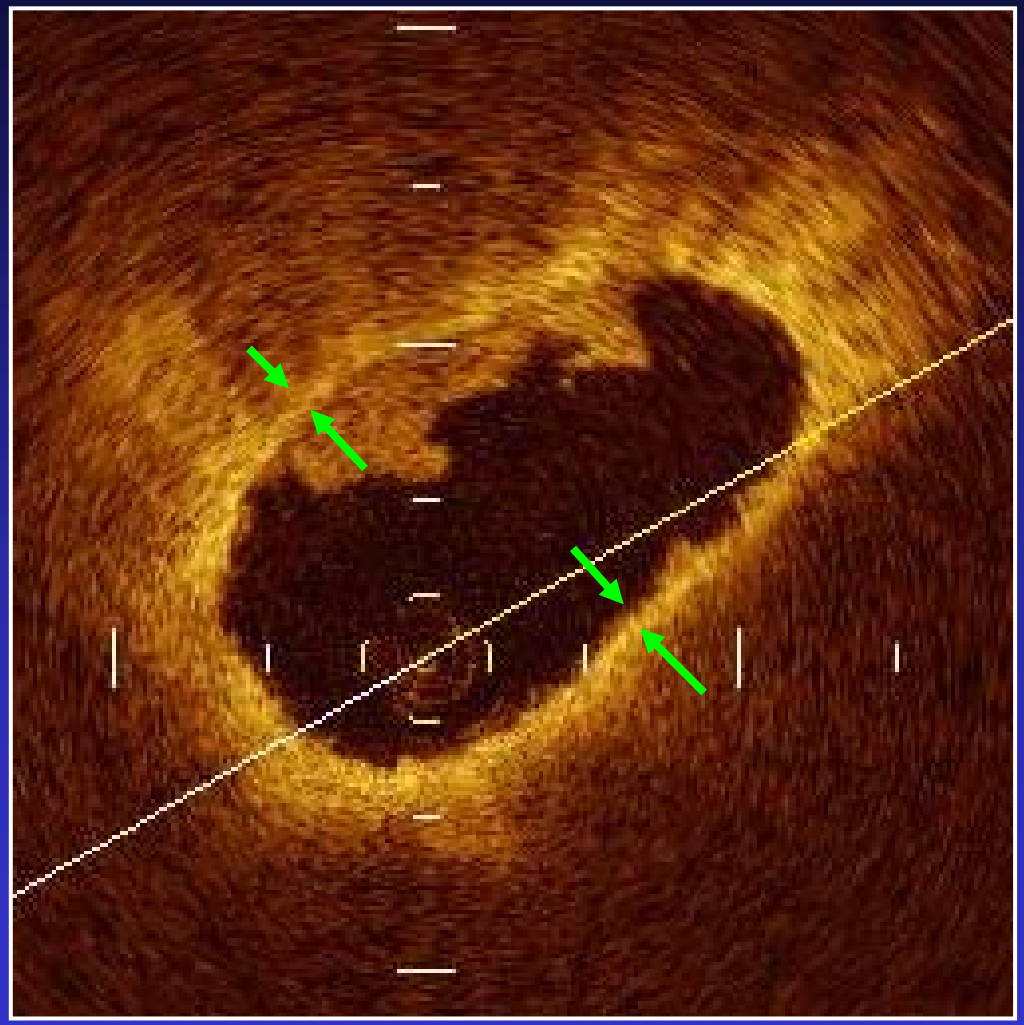

Fibrous cap thickness = 60 μm

Thickness of fibrous caps
Histology vs OCT

Kume T, Akasaka T, et al (Am Heart J . 152:755, 2006)

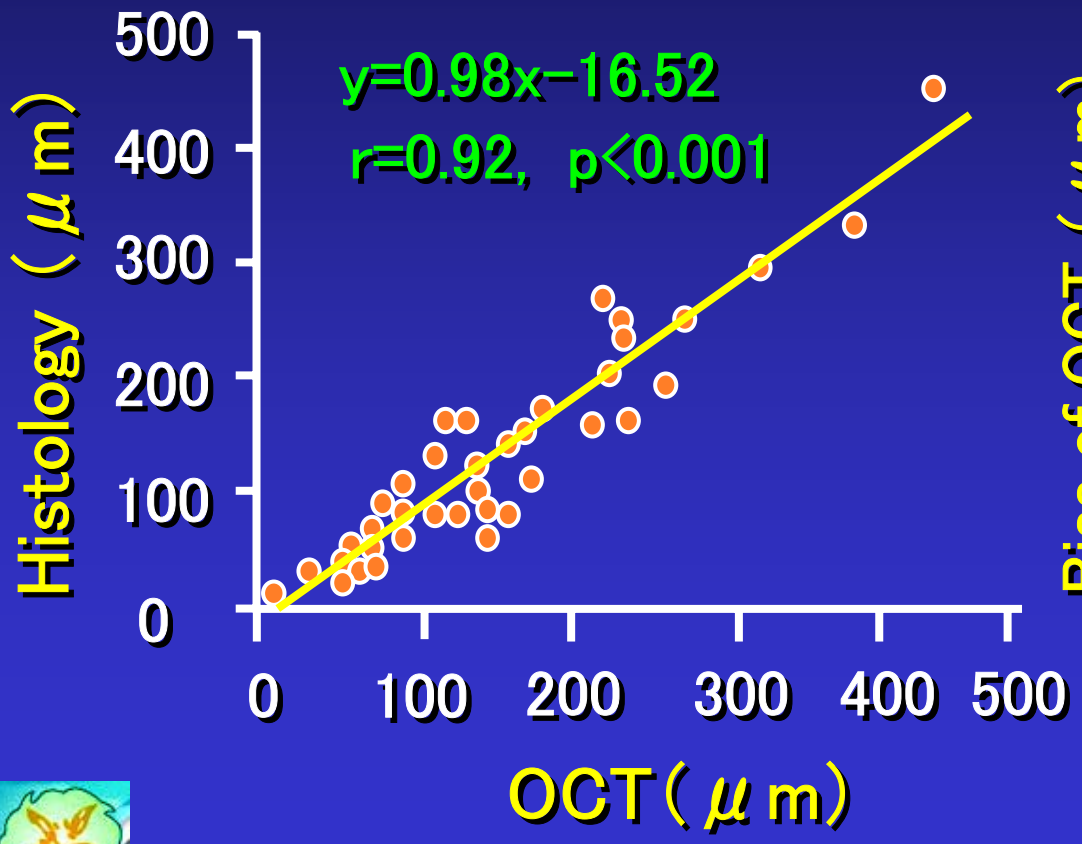

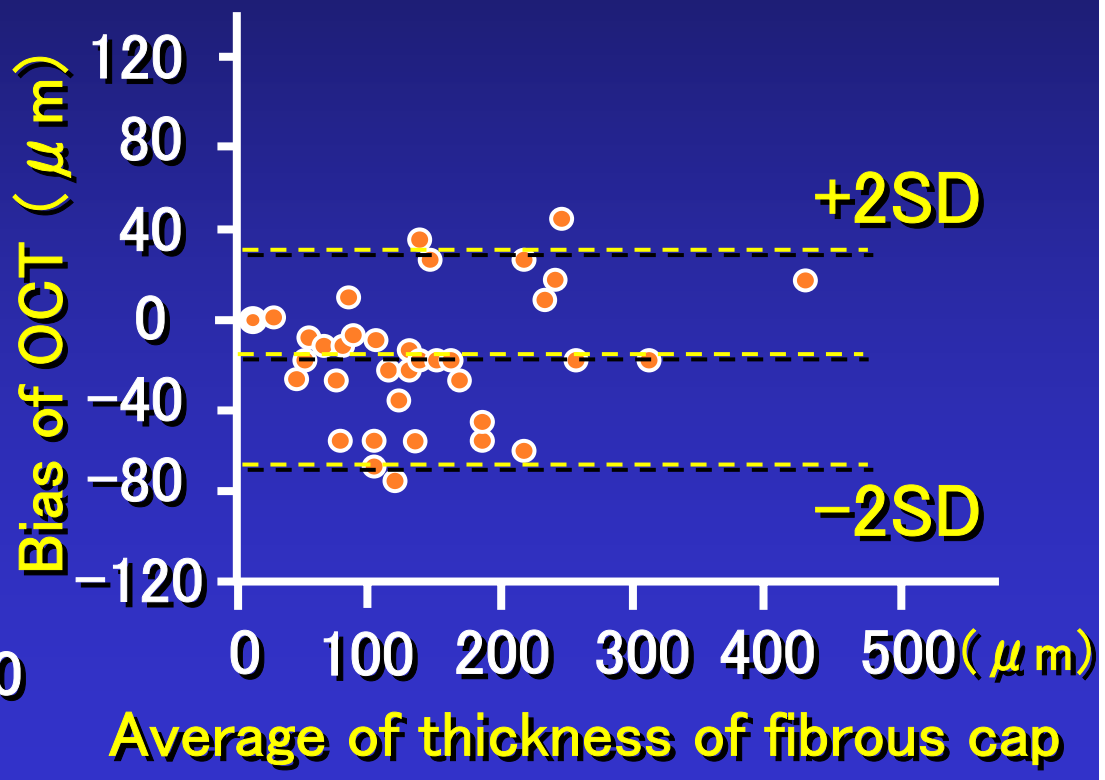

Wakayama Medical University

Anteroseptal AMI （80y.o., M）

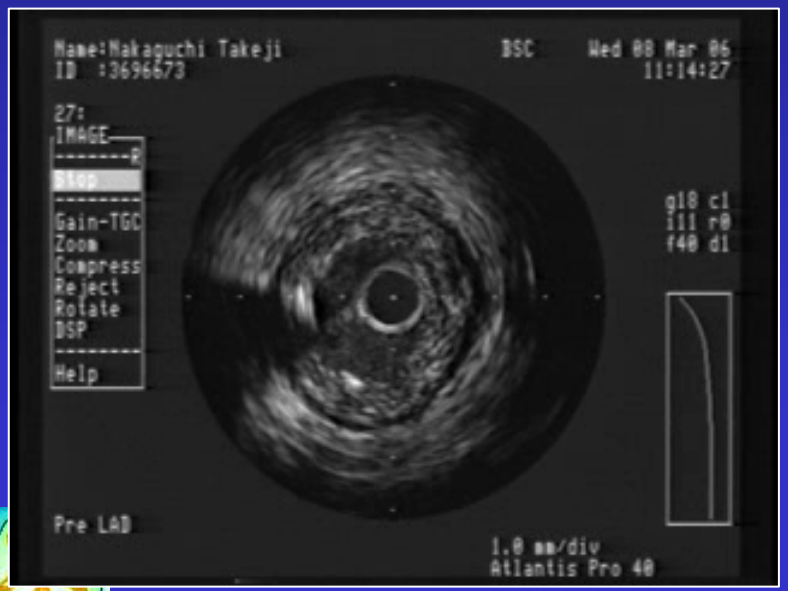

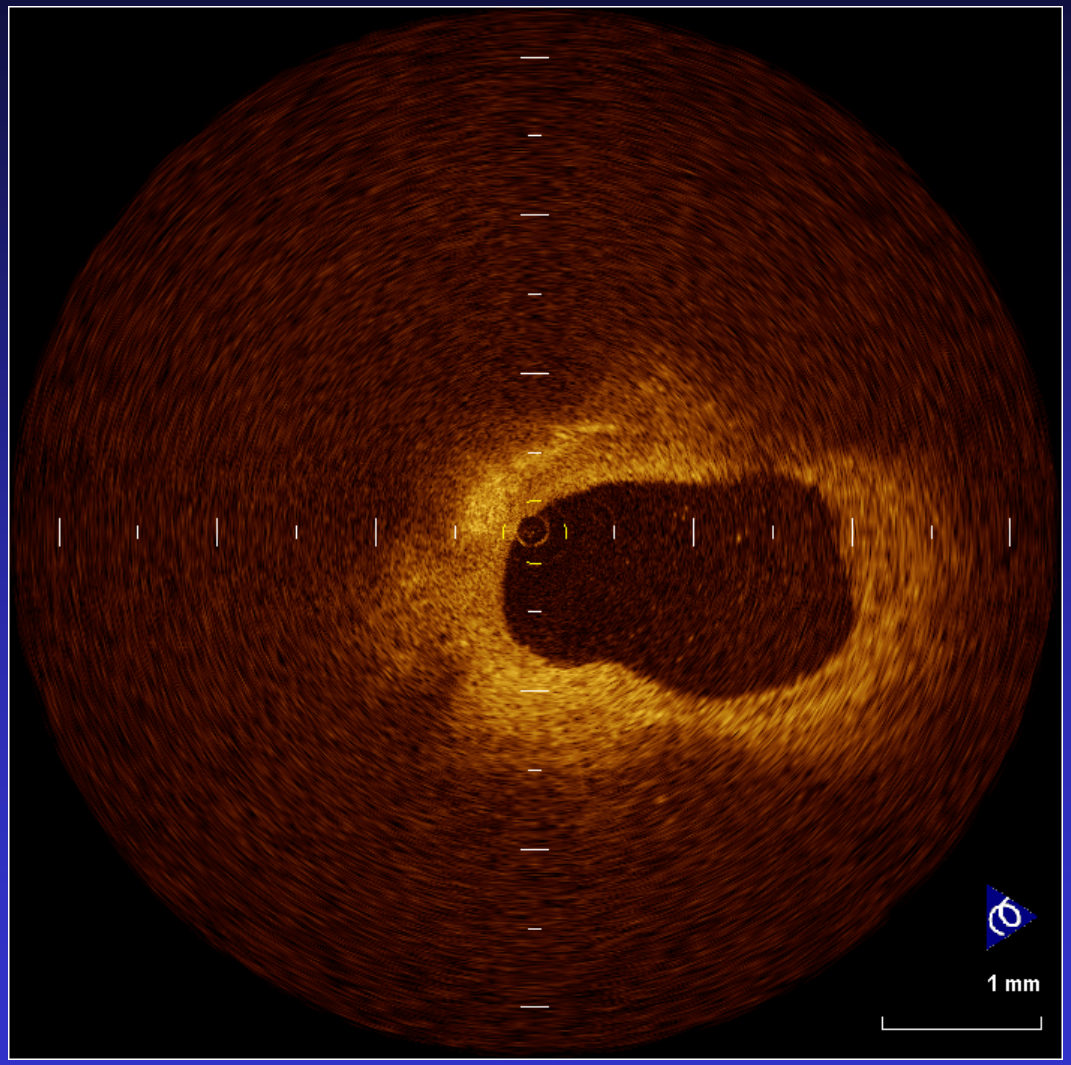

Anteroseptal AMI （80y.o., M）

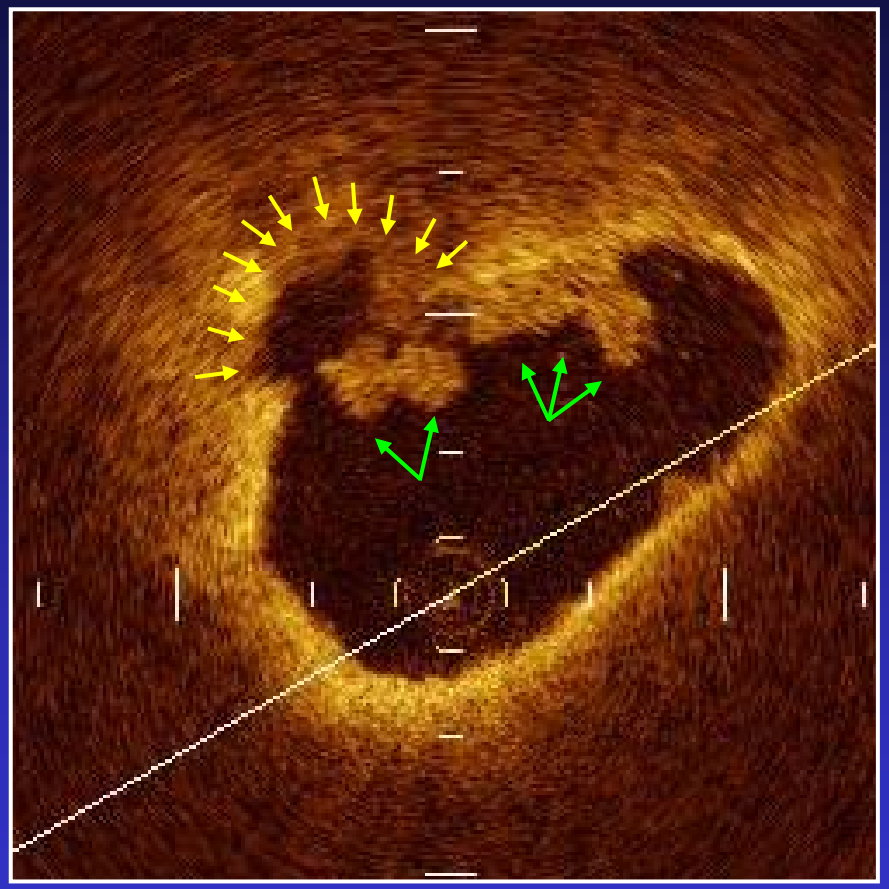

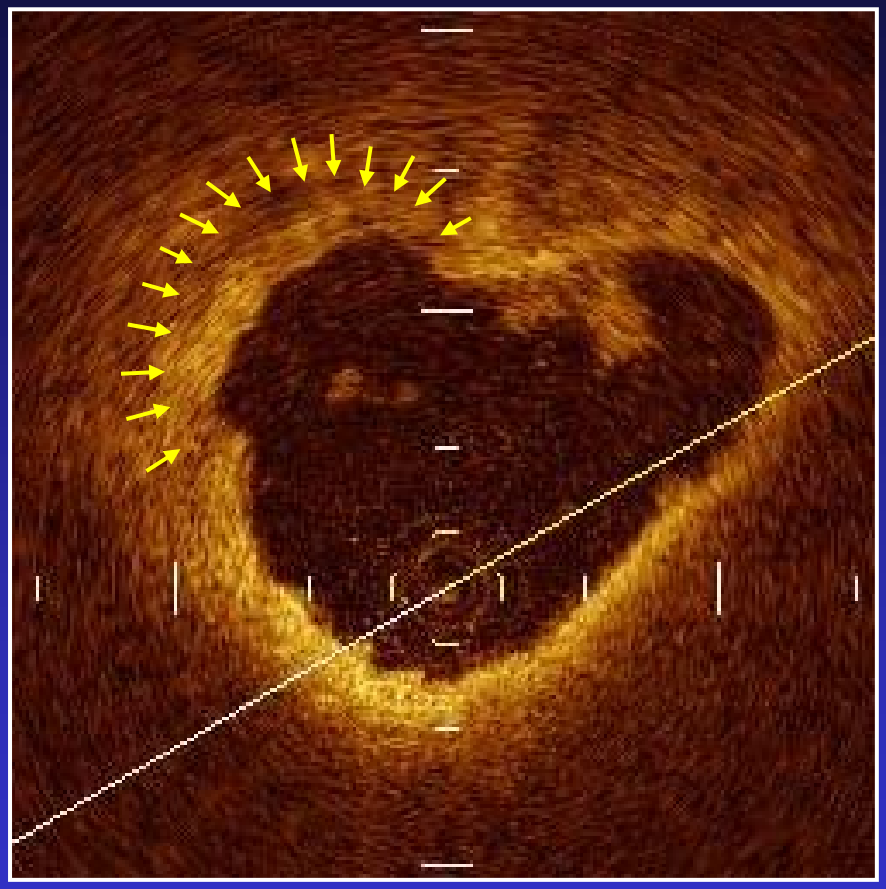

↑ Erosion (Ulceration)

↑ Thrombus

Inf-AMI （71y.o., M） Thrombus

Red Thrombus

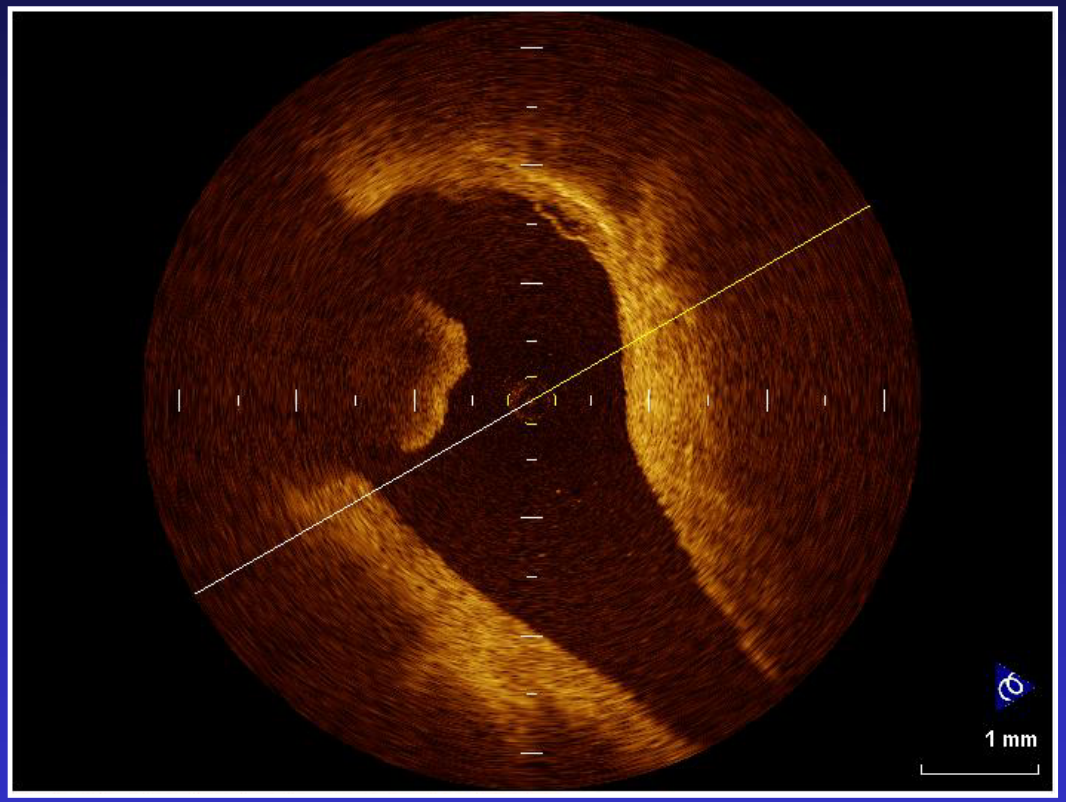

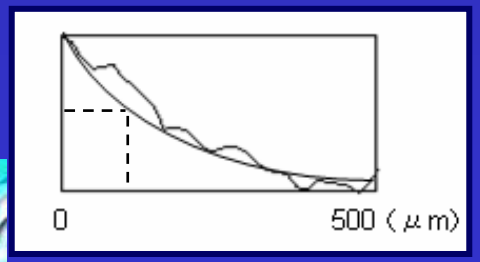

Intensity Half Distance
= 135 μm

Thrombectomy

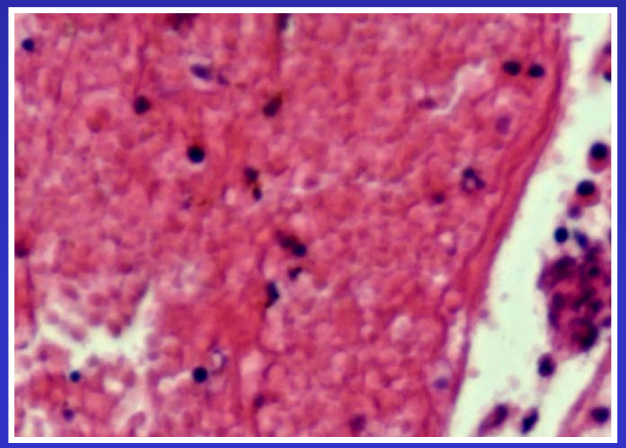

Thrombus

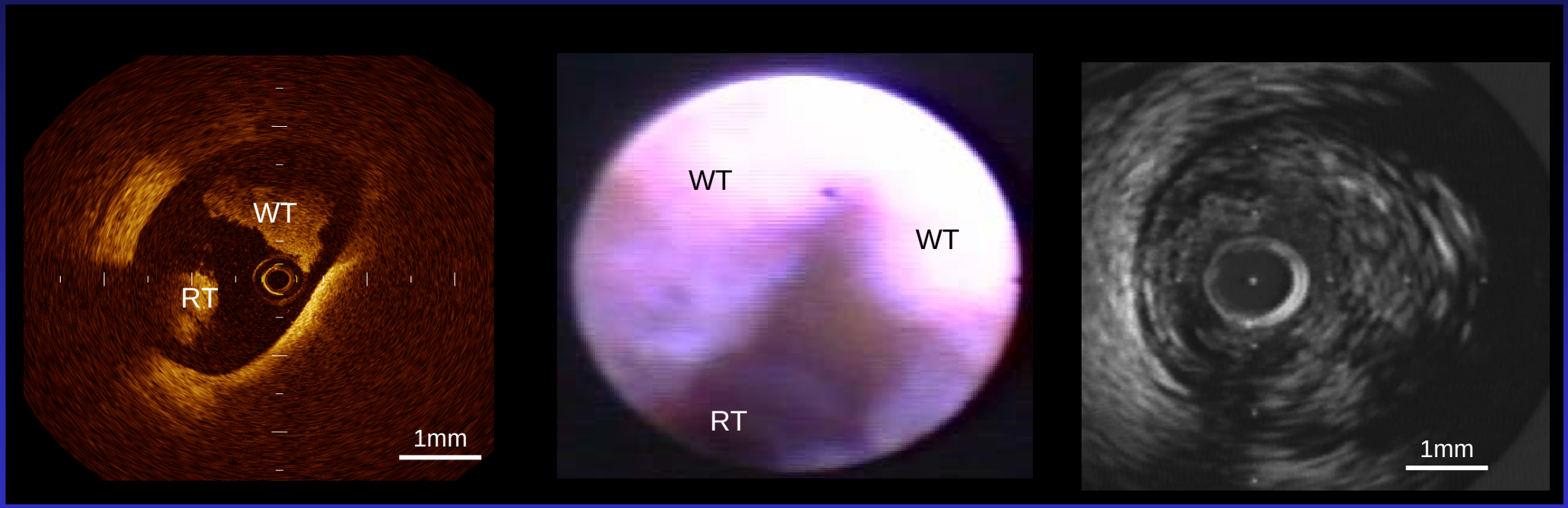

OCT CAS IVUS

Differentiation between red and white thrombus

Peak intensity

Distance from peak to half intensity

Red thrombus

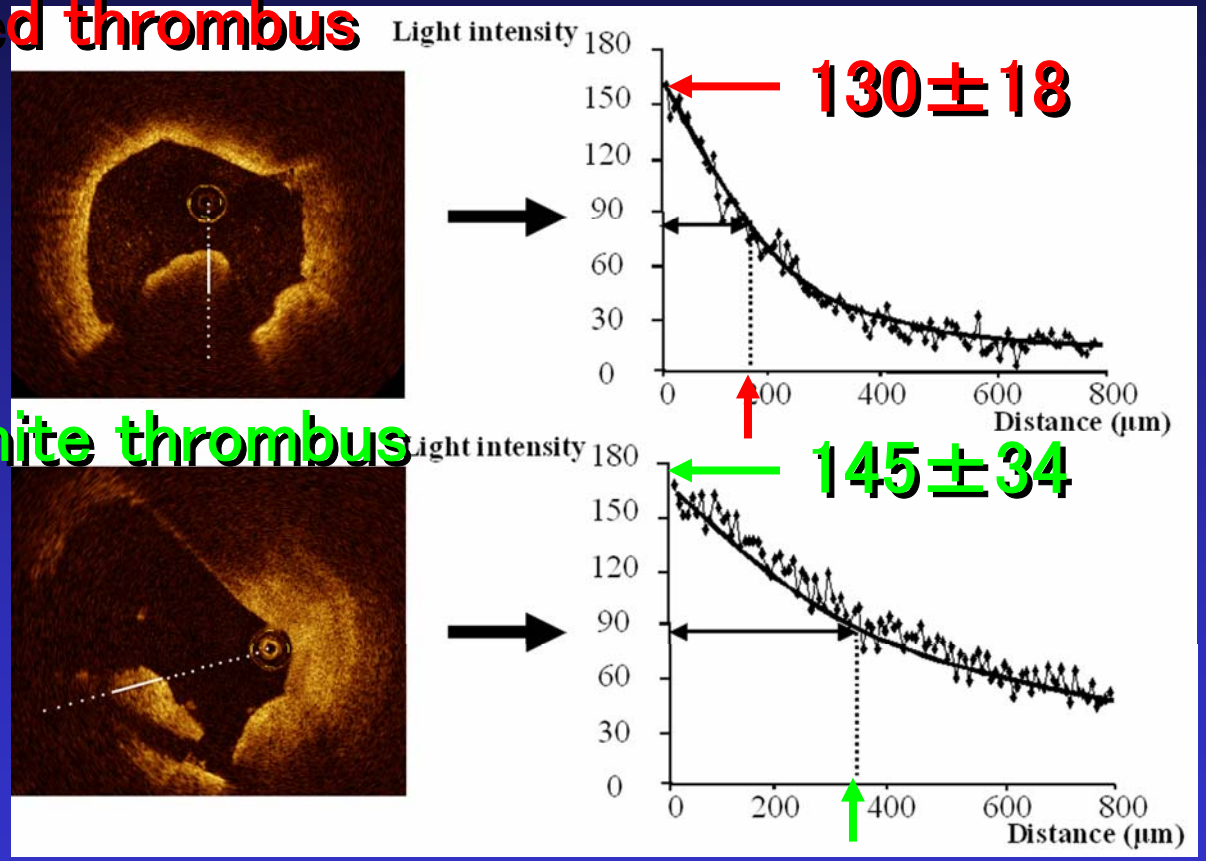

183±42

White thrombus

324±50 *

* p = 0.0001

Comparison of plaque Images in AMI (OCT vs. CAS vs. IVUS) n=30

（Kubo T, Akasaka T, et al. J Am Coll Cardiol in press）

	OCT	*CAS	**IVUS	*p	**p
Plaque Rupture (%)	73	47	40	0.035	0.009
Ulceration (erosion) (%)	23	3	0	0.022	0.005
Thrombus (%)	100	100	33	1.000	<0.001
Red thrombus (%)	100	90	-	0.076	-
White thrombus (%)	100	93	-	0.150	-
TCFA（≦65μm）(%)	85	-	-	-	-
Fibrous cap thickness (μm)	59±13	-	-	-	-
LRP (Lipid Arch＞120°) (%)	57	-	67	-	NS

TCFA; Thin Cap Fibro-Atheroma, LRP; Lipid Rich Plaque

Pathohistology of vulnerable plaque
Assessment by OCT

- Positive remodeling △
- Eccentric plaques △
- Lipid-rich plaques (necrotic core) ○
- Thin fibrous cap ○
- Rupture or ulceration of fibrous caps ○
- Thrombus formation ○
- Macrophage accumulation

OCT findings

	Low Mϕ	High Mϕ
OCT	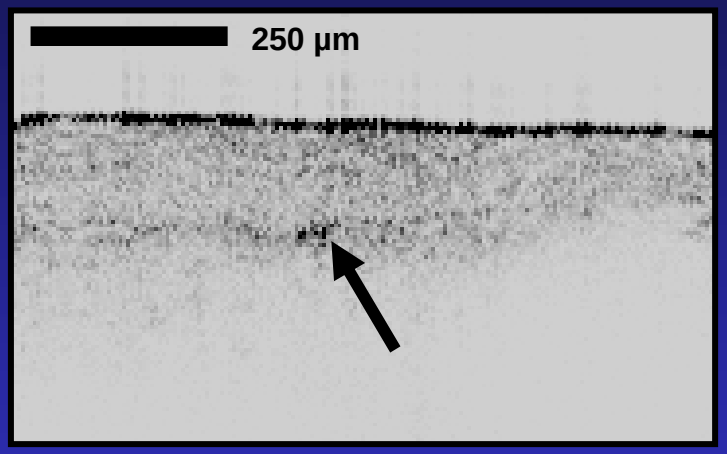	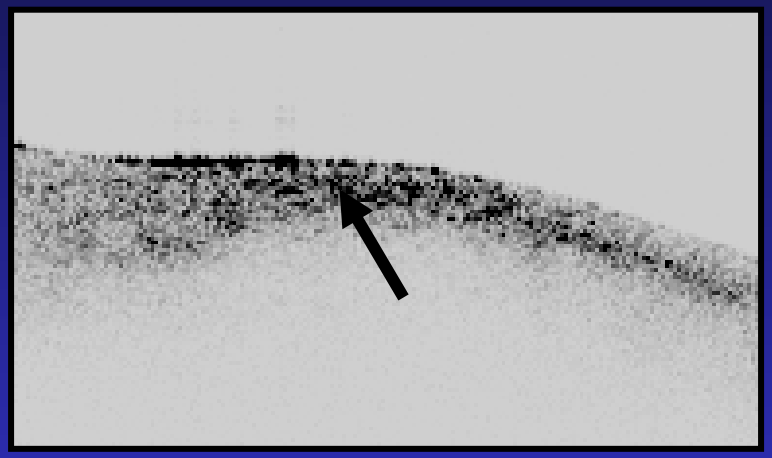
CD68 (macrophage)		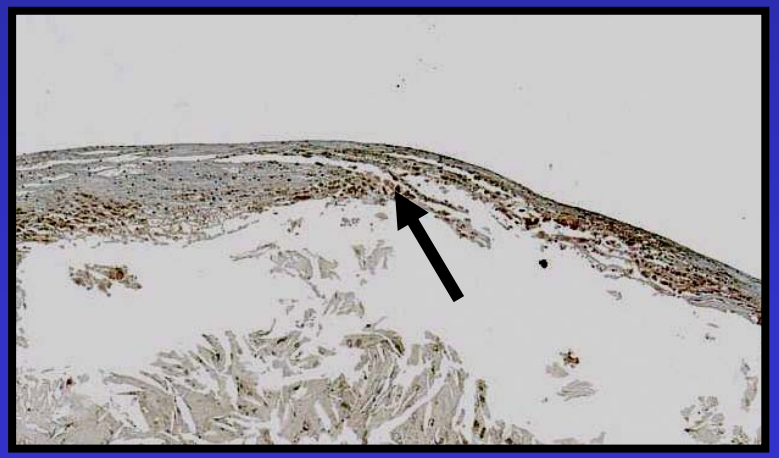

Macrophages

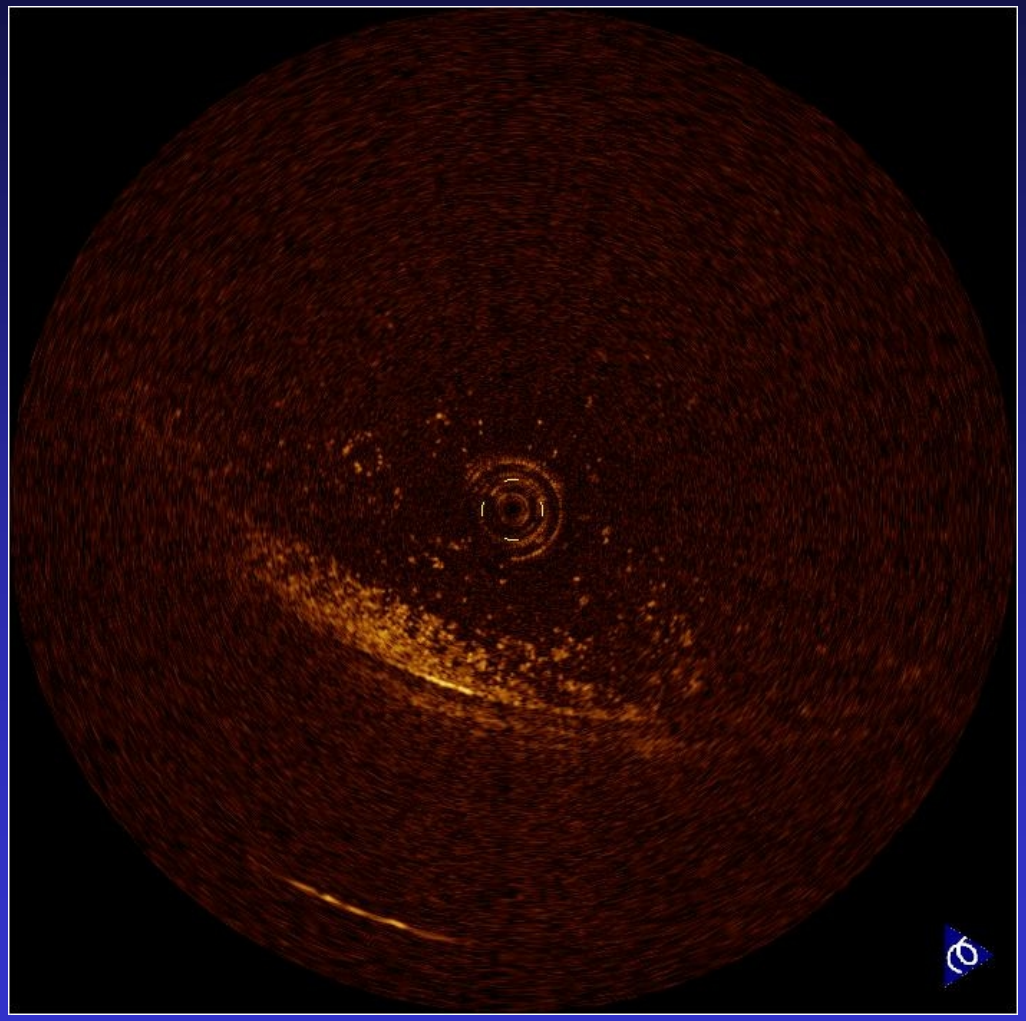

Pathohistology of vulnerable plaque
Assessment by OCT

- Positive remodeling △
- Eccentric plaques △
- Lipid-rich plaques (necrotic core) ○
- Thin fibrous cap ○
- Rupture or ulceration of fibrous caps ○
- Thrombus formation ○
- Macrophage accumulation ○

Summary
Pathohistology of vulnerable plaque
Assessment by OCT

- Positive remodeling △
- Eccentric plaques △
- Lipid-rich plaques (necrotic core) ○
- Thin fibrous cap ○
- Rupture or ulceration of fibrous caps ○
- Thrombus formation ○
- Macrophage accumulation ○

Conclusions

- OCT can identify lipid-rich plaques more sensitively compared with IVUS.
- OCT can demonstrate rupture or erosion of fibrous cap with higher detection rate than that of IVUS and CAS.
- OCT could detect intracoronary thrombus almost exclusively which was confirmed by CAS.
- OCT may estimate macrophage accumulation within fibrous caps.