Detection of vulnerable plaque by OCT

Takashi Akasaka, M.D.

Department of Cardiovascular Medicine

Wakayama Medical University

Wakayama, Japan

Disclosure Statement of Financial Interest

I (Takashi Akasaka) do not have a financial interest/arrangement or affiliation with one or more organizations that could be perceived as a real or apparent conflict of interest in the context of the subject of this presentation.

Pathohistology of vulnerable plaque（HE stain）

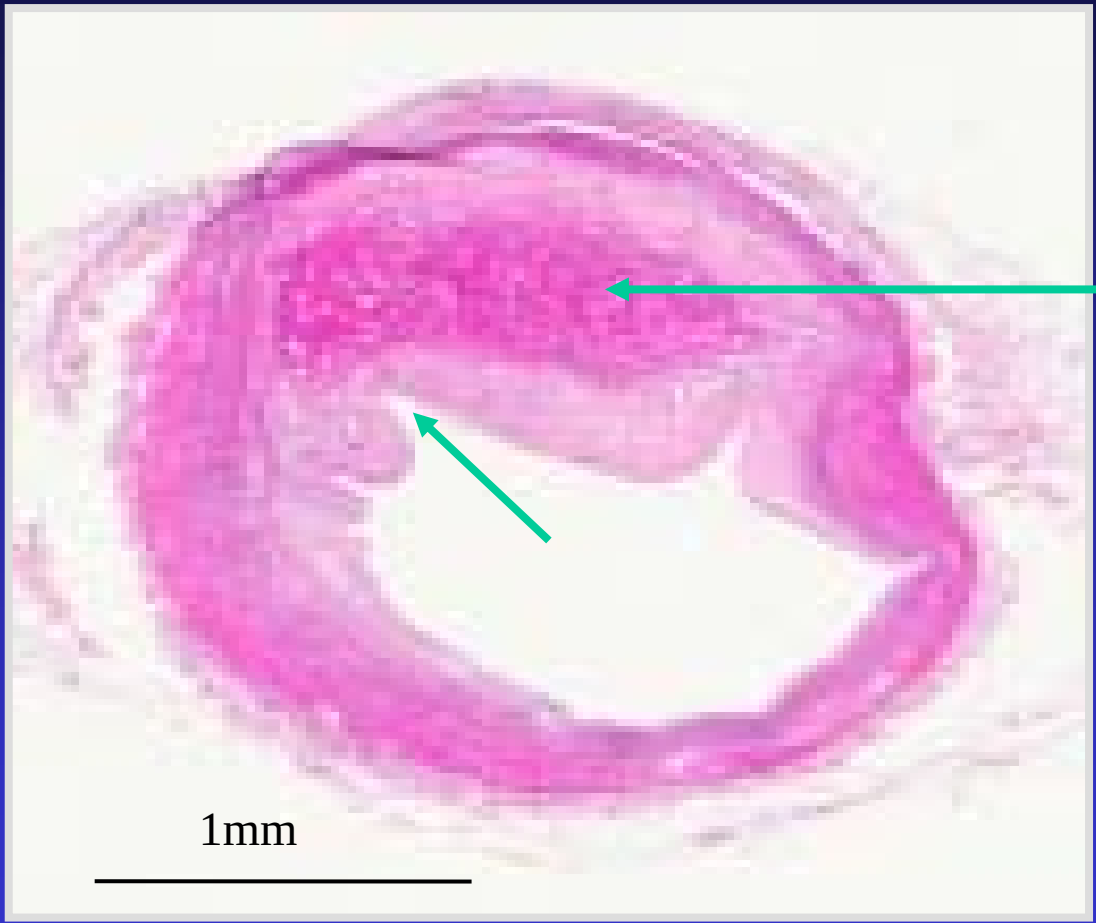

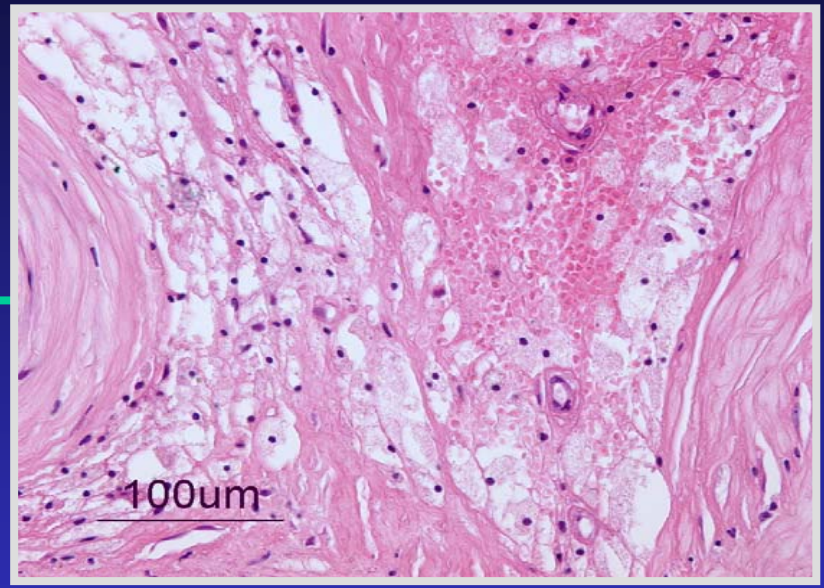

Thin fibrous cap

Large lipid core

Advanced atherosclerosis

Pathohistological characteristics of vulnerable plaque

- Positive remodeling
- Eccentric plaques
- Lipid-rich plaques (necrotic core)
- Thin fibrous cap (< 65 μm)
- Rupture (60%) or ulceration (30～40%) of fibrous caps
- Thrombus formation
- Macrophage accumulation

Identification of vulnerable plaque

- Plaque prone to rupture

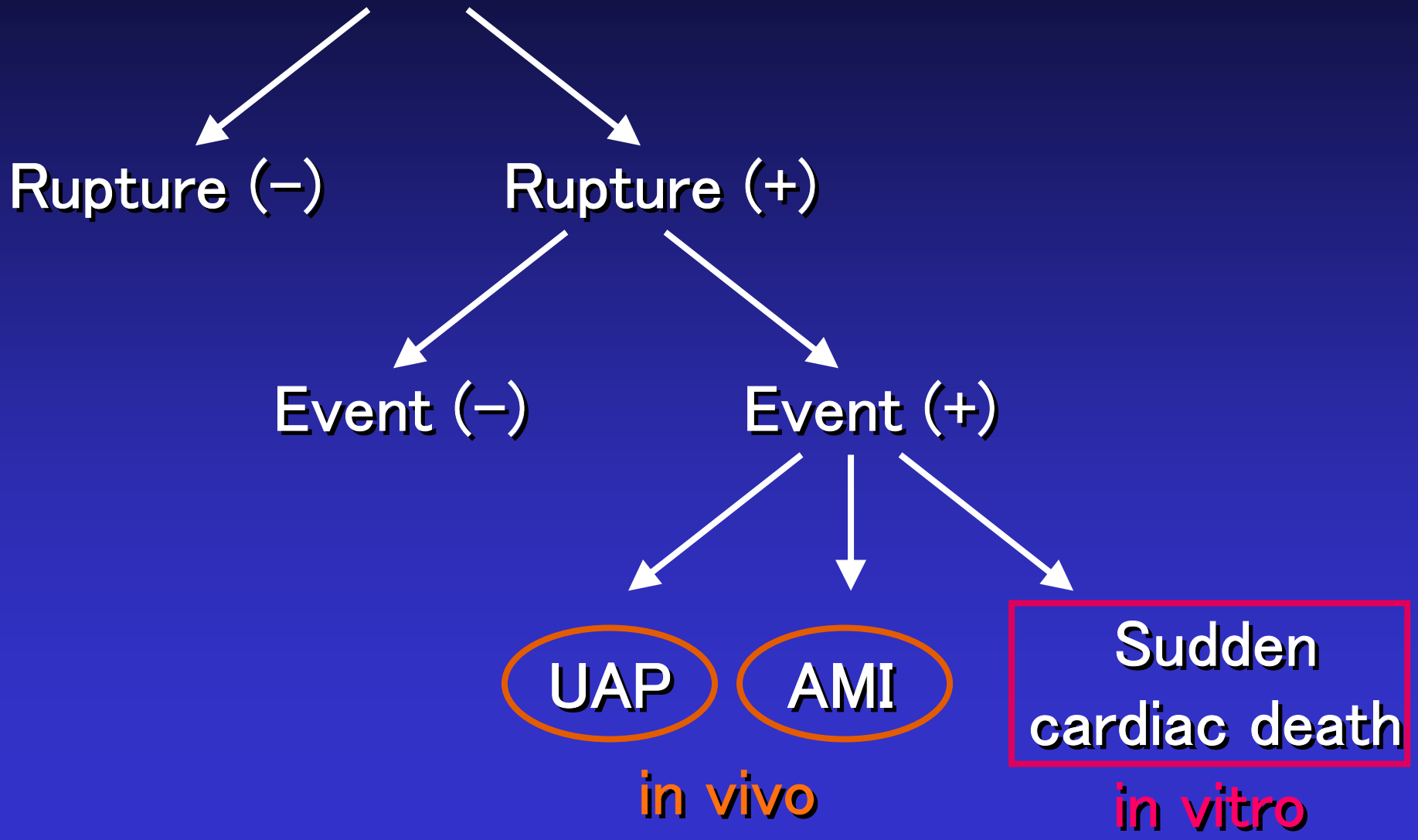

Study Population

Inclusion criteria

Acute Myocardial Infarction

continuous chest pain lasted > 30 minutes,

arrival within 6 hours from the onset of chest pain

ST elevation ≧ 0.1 mV in 2 or more contiguous leads

culprit lesion with diameter stenosis ≧ 75%

TIMI flow ≦ 2 identified by CAG

Exclusion criteria

left bundle-branch block
pacemaker rhythm
a culprit lesion in the left main coronary artery
history of prior MI
cardiogenic shock
unsuccessful reperfusion < TIMI III flow by thrombectomy

Study Design

Oral aspirin (162 mg) and intravenous heparin (100 U/kg) were administered before PCI.

Cardiac catheterization was performed by the femoral approach, using a 7F sheath and catheters.

- **Thrombectomy** *(Export catheter ® Medtronic Japan)*

↓ TIMI grade III

- **IVUS** *(Atlantis SR Pro® 2.5F, 40-MHz; Boston Scientific, Natick, MA, USA)*

↓

- **CAS** *(Angioscope MC-800E and the optic fiber AS-003, Nihon Kohden)*

↓

- **OCT** *(ImageWire®; LightLab Imaging, Westford, MA, USA)*

OCT system (LightLab Co.)



OCT vs histology

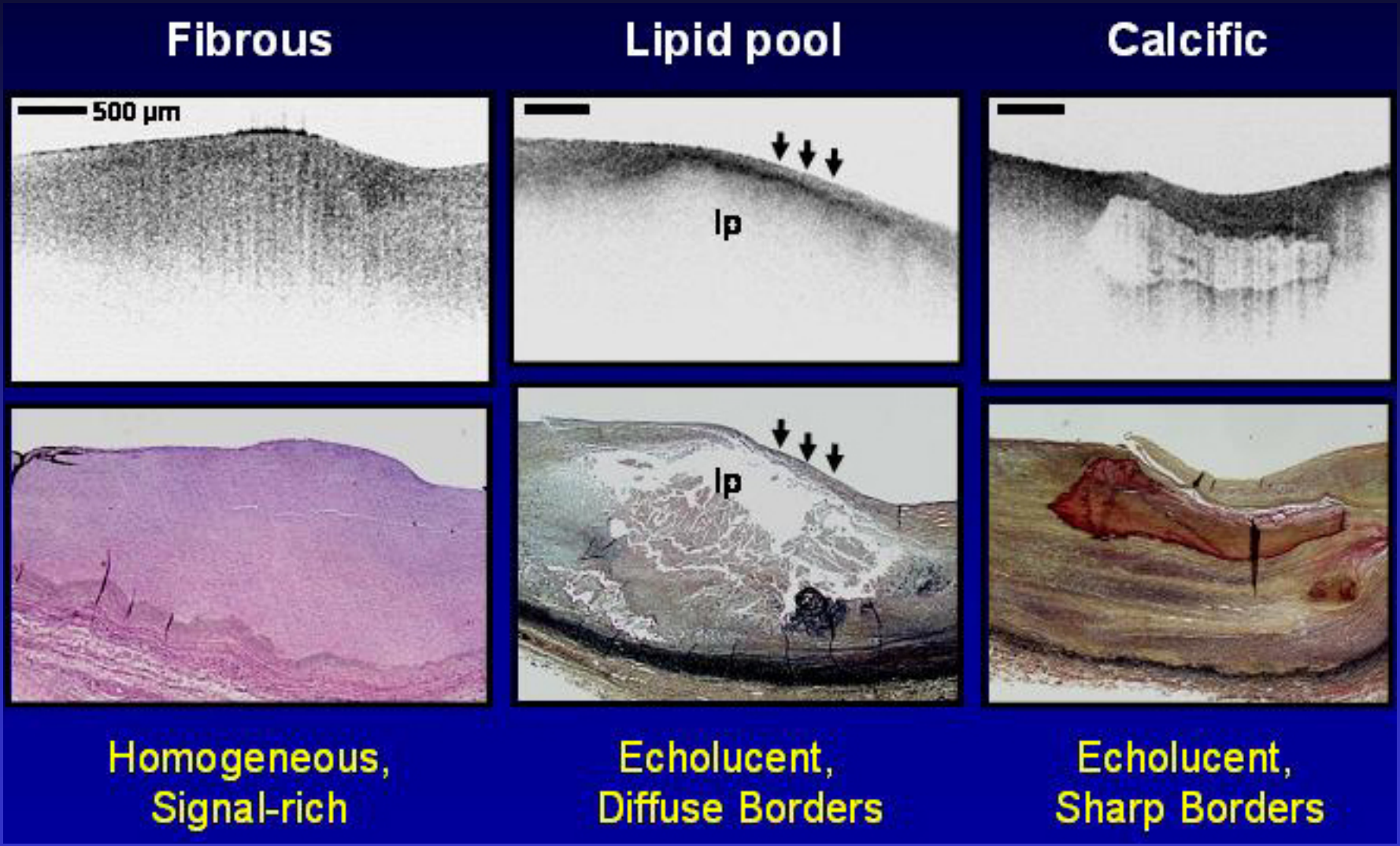

Yabushita et al. Circulation, 2002

Tissue characterization by OCT and IVUS

Kume T, Akasaka T, et al (Am J Cardiol 97 : 1172 - 1175, 2006)

Pathohistological Diagnosis	Sensitivity	Specificity	Predictive Value Positive	Predictive Value Negative
OCT image				
Fibrous (n=43)	79	99	97	93
Fibrocalcific (n=82)	96	88	89	96
Lipid (n=41)	85*	94	83	95
IVUS image				
Fibrous (n=43)	88	86	69	95
Fibrocalcific (n=82)	98	96	96	98
Lipid (n=41)	59	97	86	87

Data are demonstrated as percentages. *$p<0.05$ vs IVUS

Pathohistological characteristics of vulnerable plaque

Assessment by OCT

- Positive remodeling △
- Eccentric plaques △
- Lipid-rich plaques (necrotic core) ○
- Thin fibrous cap
- Rupture or ulceration of fibrous caps
- Thrombus formation
- Macrophage accumulation

Pathohistological characteristics of vulnerable plaque

Assessment by OCT

- Positive remodeling △
- Eccentric plaques △
- Lipid-rich plaques (necrotic core) ○
- Thin fibrous cap
- Rupture or ulceration of fibrous caps
- Thrombus formation
- Macrophage accumulation

Inferior-AMI（71y.o., M） Plaque Rupture

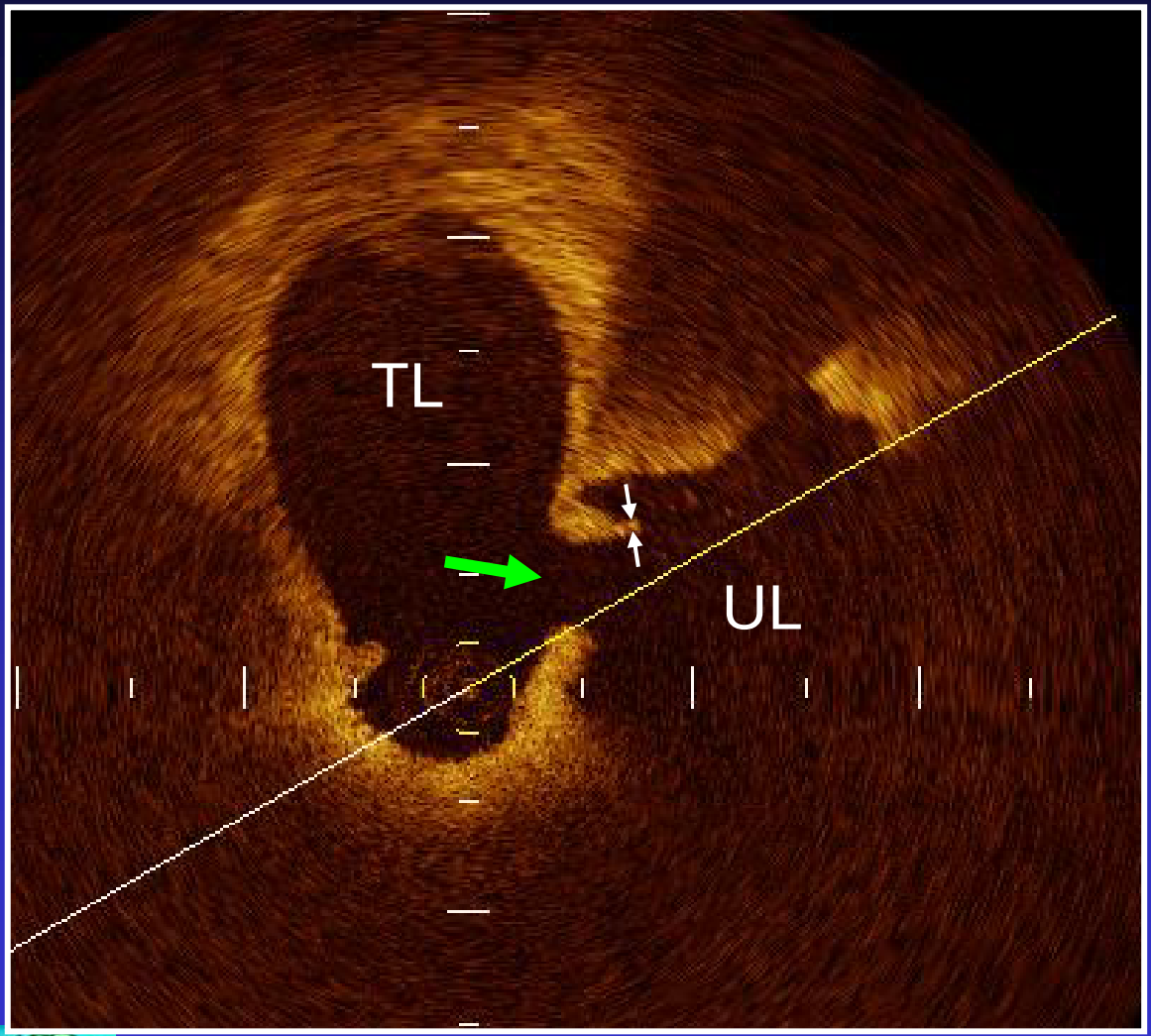

Ruptured Fibrous Cap

Fibrous Cap Thickness
= 40μm

TL : True Lumen

UL : Ulceration



Anteroseptal AMI （80y.o., M）

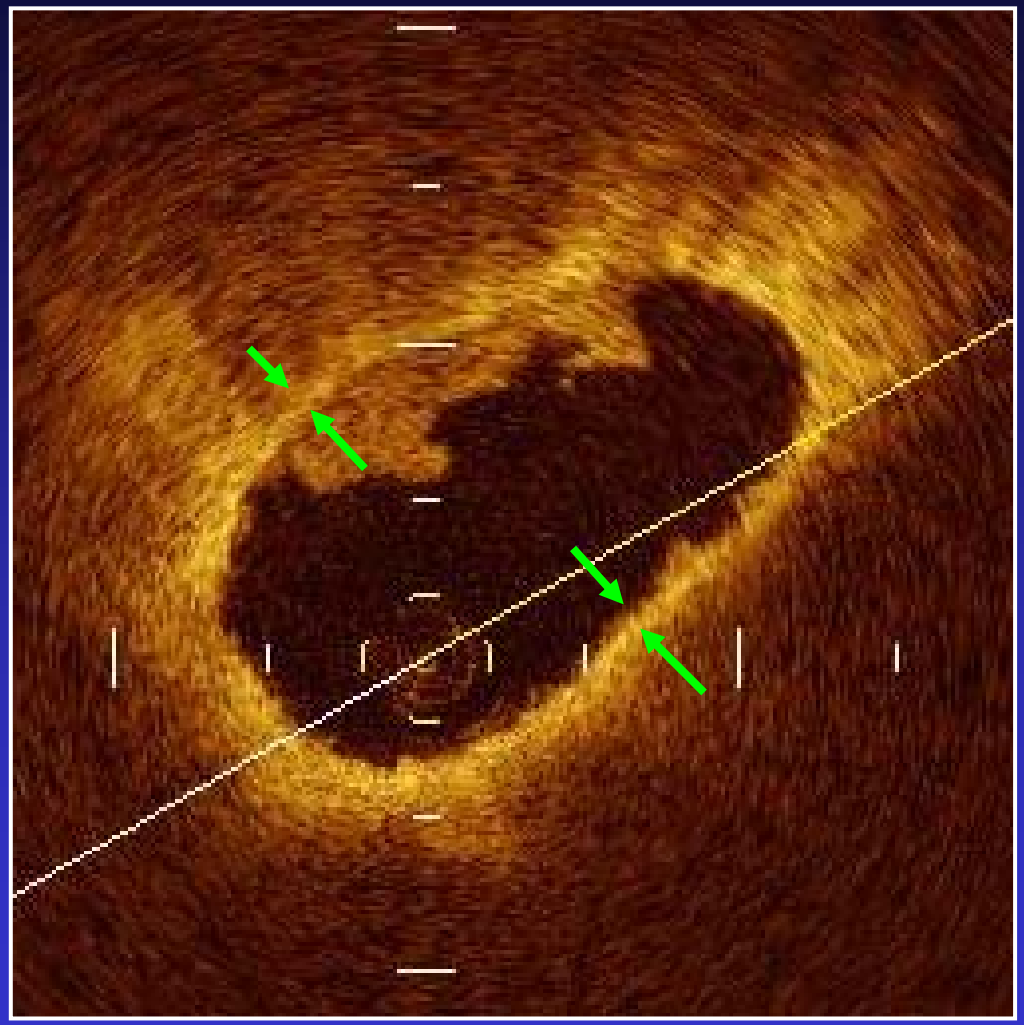

Fibrous cap thickness = 60 μm

Thickness of fibrous caps
Histology vs OCT

Kume T, Akasaka T, et al (Am Heart J . 152:755, 2006)

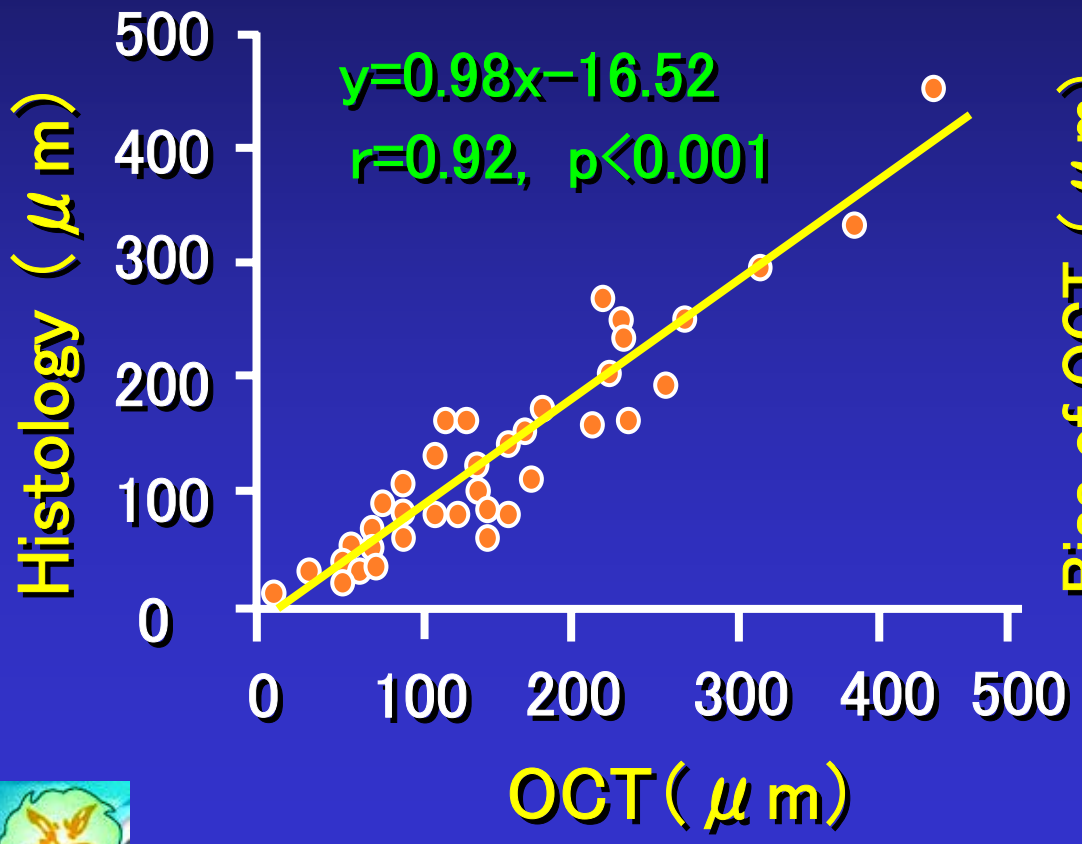

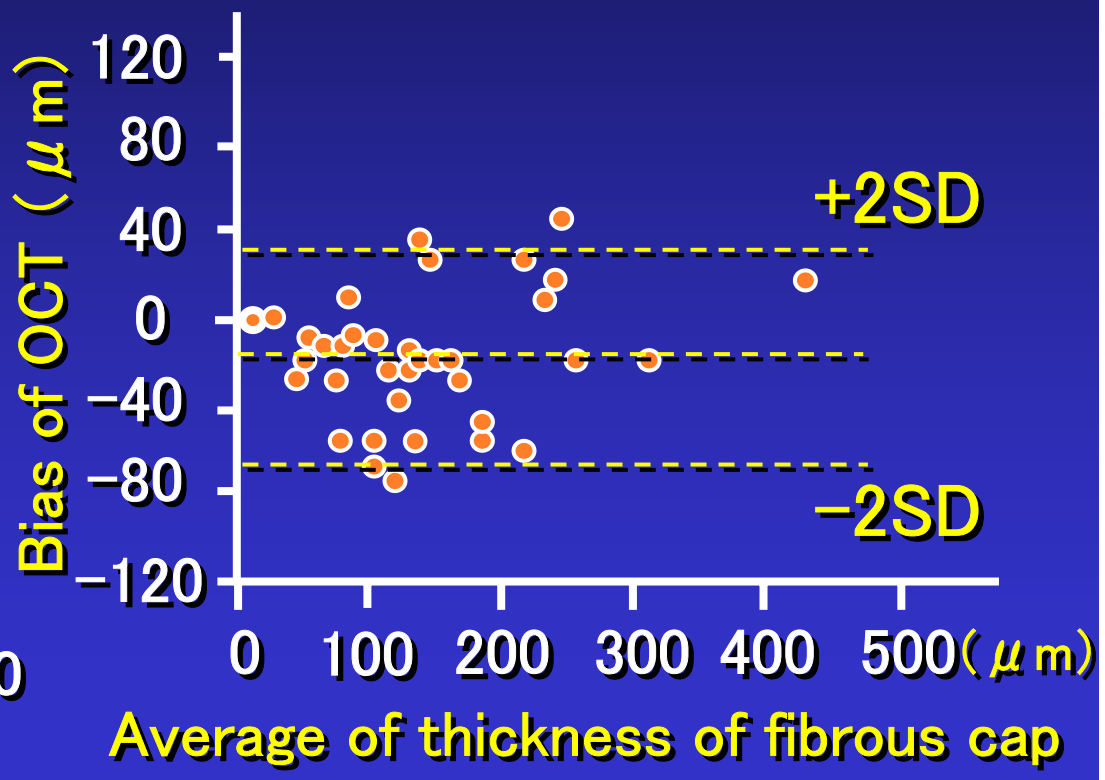

Wakayama Medical University

Anteroseptal AMI （80y.o., M）

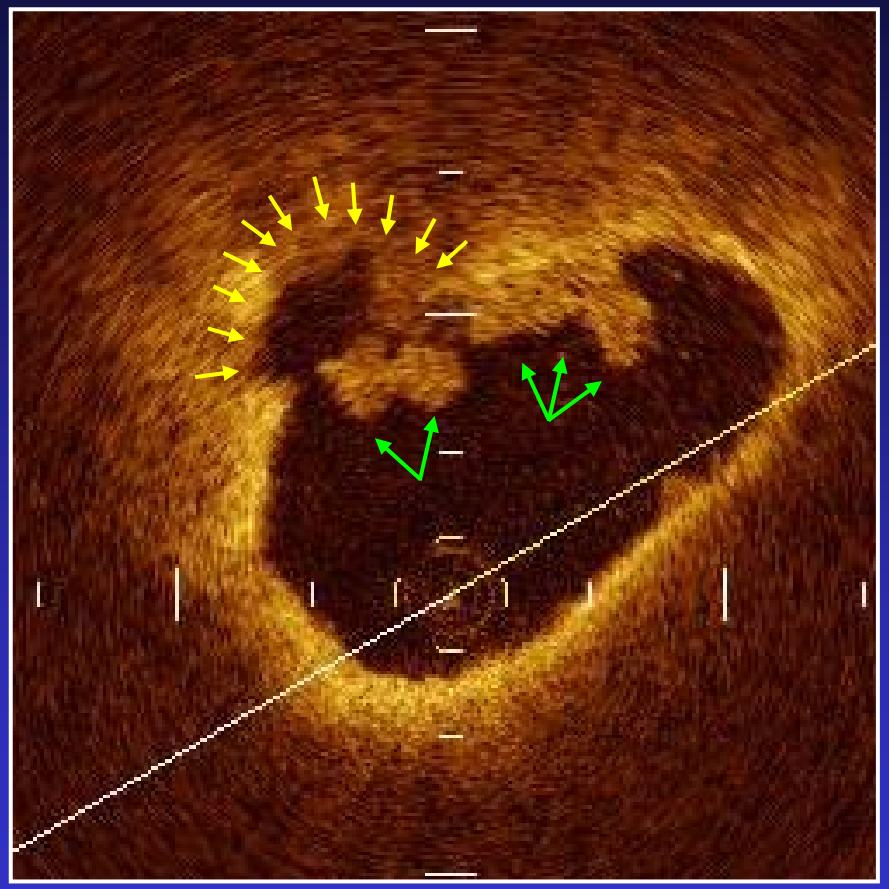

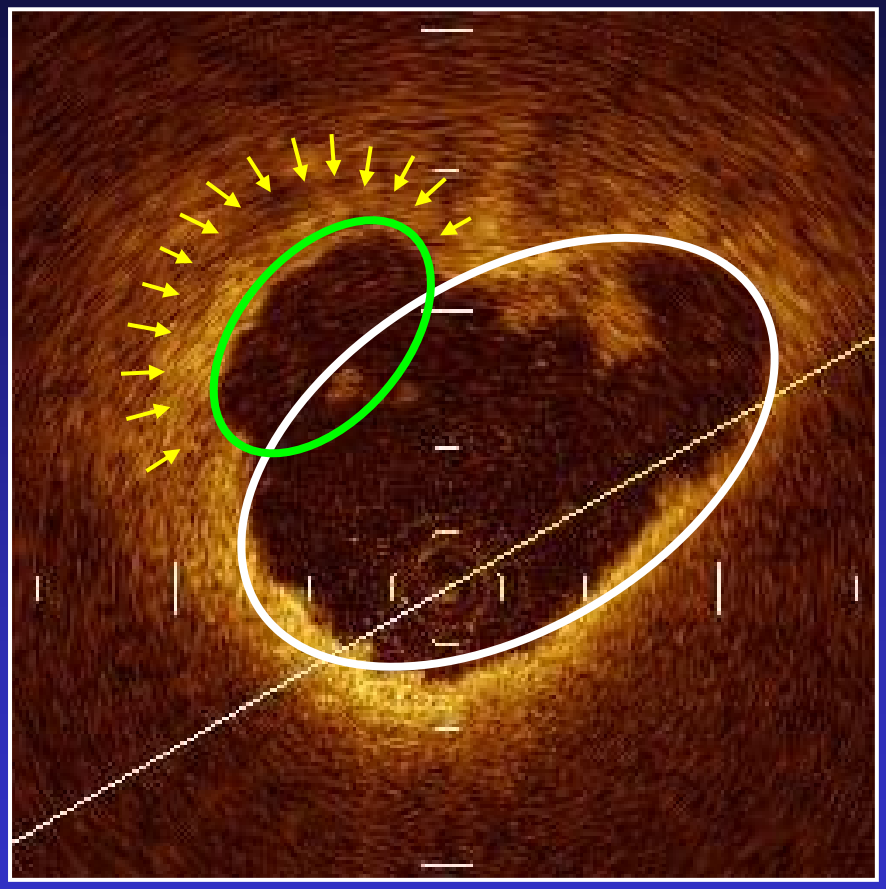

↑ Erosion (Ulceration)

↑ Thrombus

Inf-AMI （71y.o., M） Thrombus

Red Thrombus

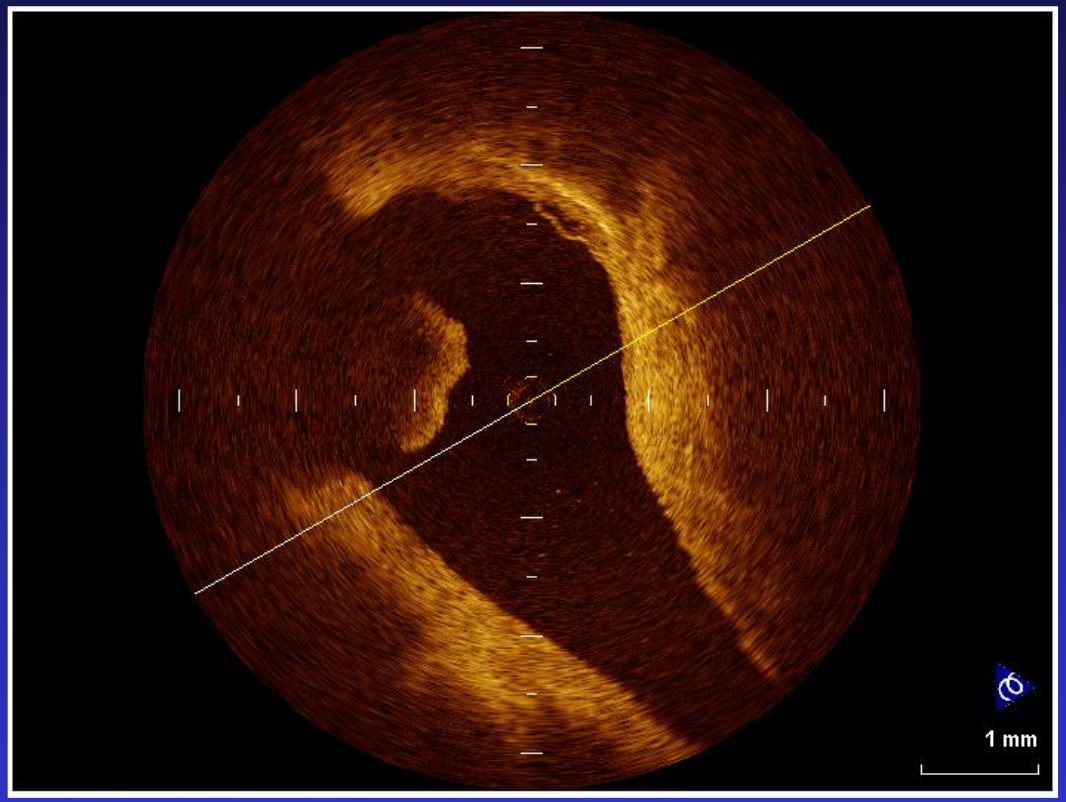

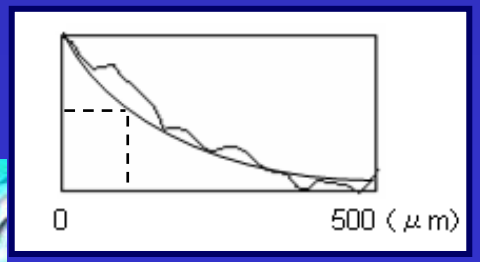

Intensity Half Distance
= 135 μm

Thrombectomy

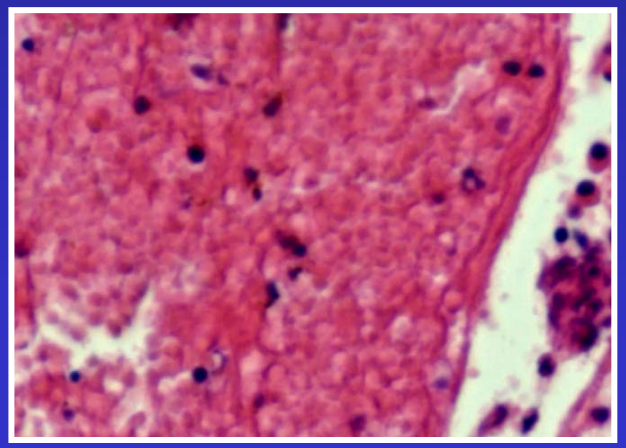

Differentiation between red and white thrombus

	Peak intensity	Intensity half distance
Red thrombus	130±18	183±42
White thrombus	145±34	324±50 *

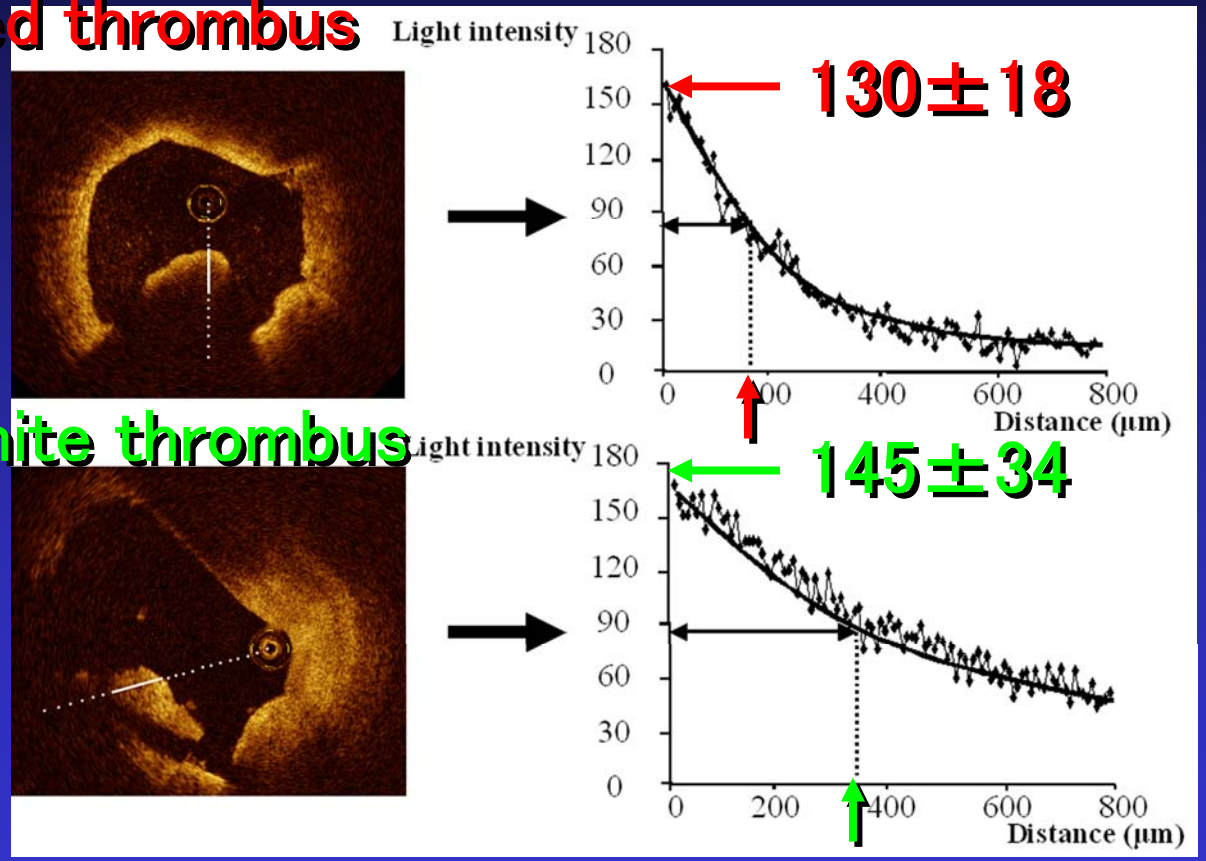

* p = 0.0001

Kume T, Akasaka T, et al (Am J Cardiol . 2006, 97:1713-1717)

Differentiation between red and white thrombus

White thrombus — Red thrombus

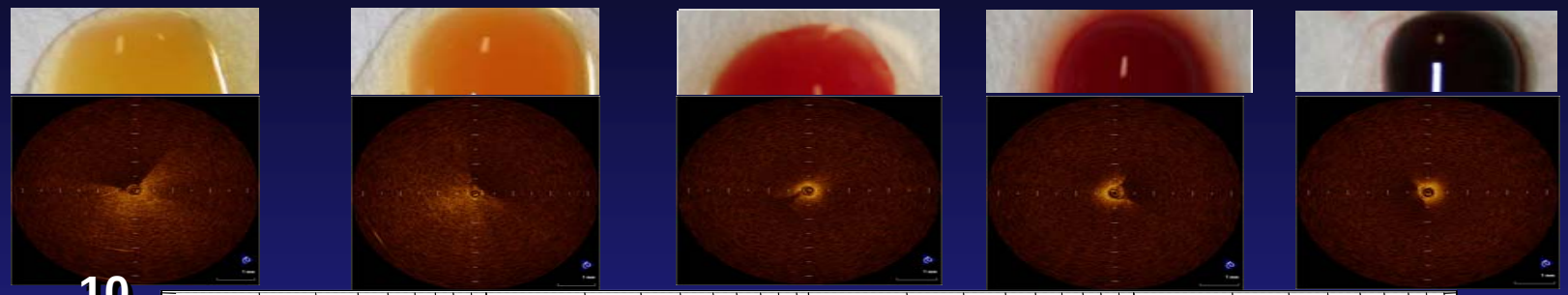

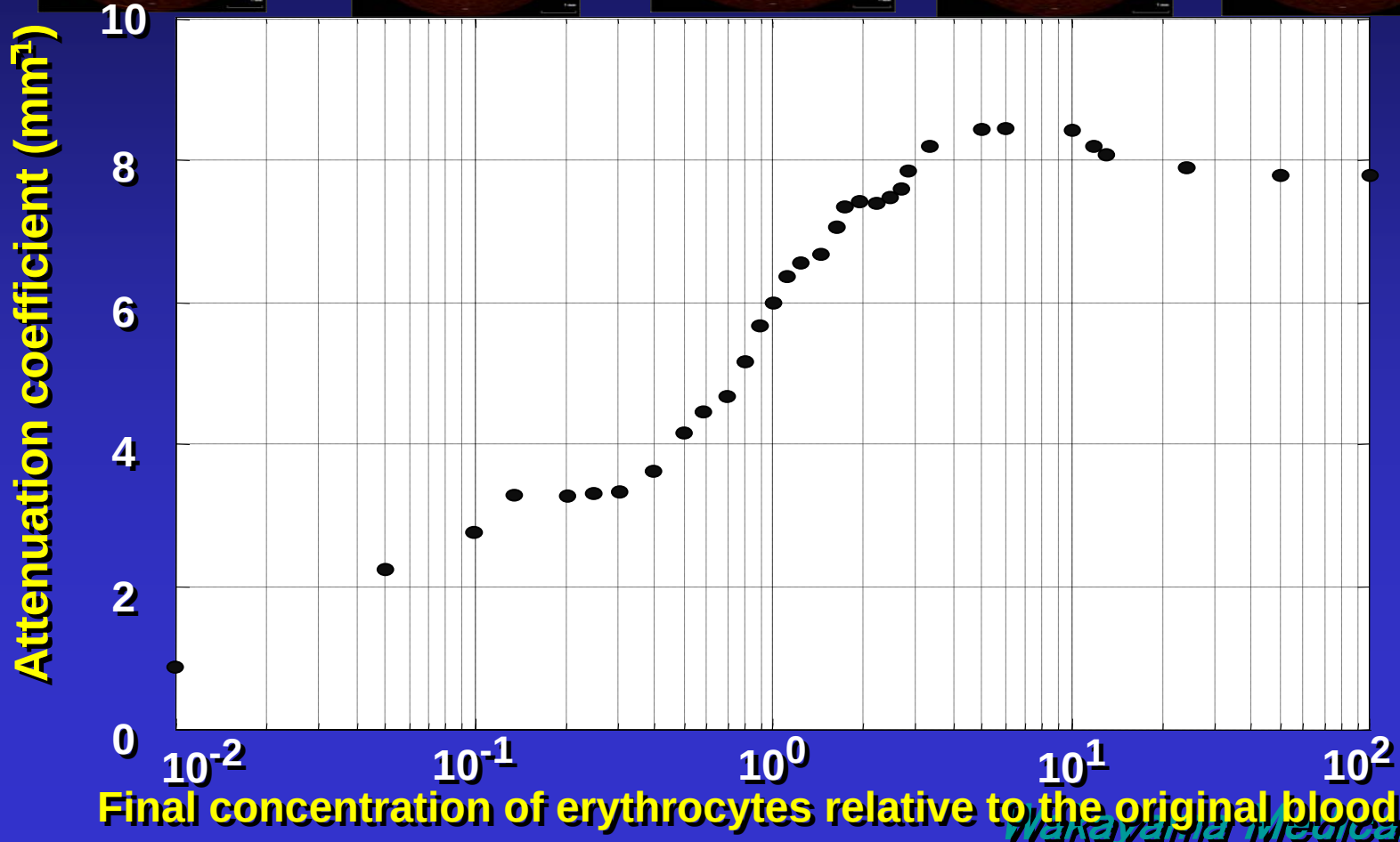

Comparison of plaque Images in AMI (OCT vs. CAS vs. IVUS) n=30

（Kubo T, Akasaka T, et al. J Am Coll Cardiol 50:933-999,2007）

	OCT	*CAS	**IVUS	*p	**p
Plaque Rupture (%)	73	47	40	0.035	0.009
Ulceration (erosion) (%)	23	3	0	0.022	0.005
Thrombus (%)	100	100	33	1.000	<0.001
Red thrombus (%)	100	90	-	0.076	-
White thrombus (%)	100	93	-	0.150	-
TCFA（≦65μm）(%)	83	-	-	-	-
Fibrous cap thickness (μm)	49±21	-	-	-	-
LRP (Lipid Arch＞180°) (%)	83	-	67	-	NS

TCFA; Thin Cap Fibro-Atheroma, LRP; Lipid Rich Plaque

Pathohistological characteristics of vulnerable plaque

Assessment by OCT

- Positive remodeling △
- Eccentric plaques △
- Lipid-rich plaques (necrotic core) ○
- Thin fibrous cap ○
- Rupture or ulceration of fibrous caps ○
- Thrombus formation ○
- Macrophage accumulation

OCT findings

	Low Mϕ	High Mϕ
OCT	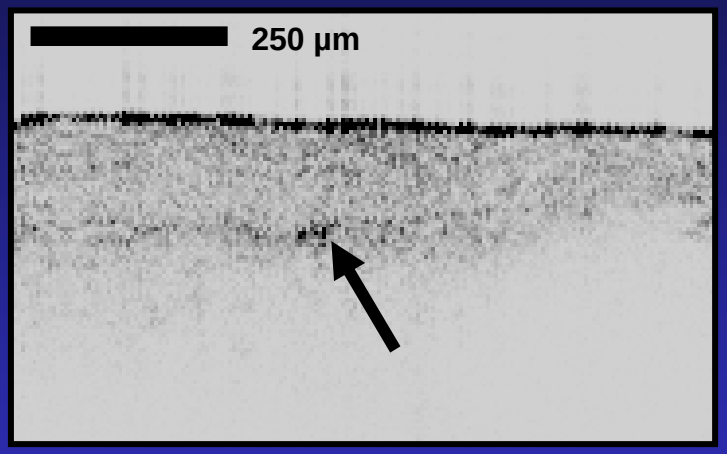	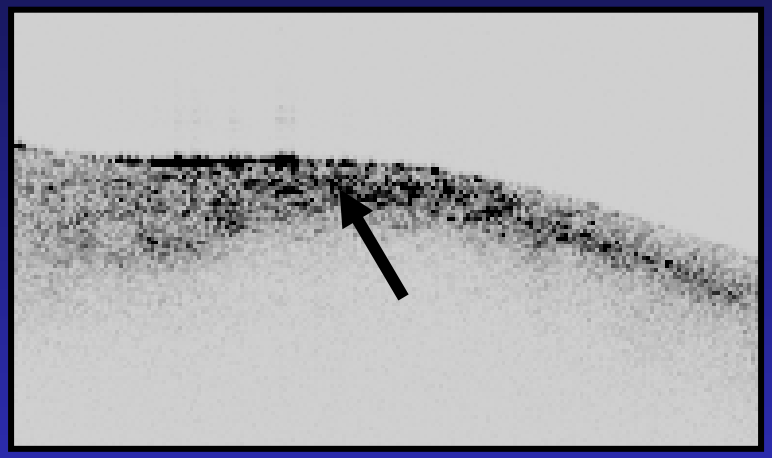
CD68 (macrophage)		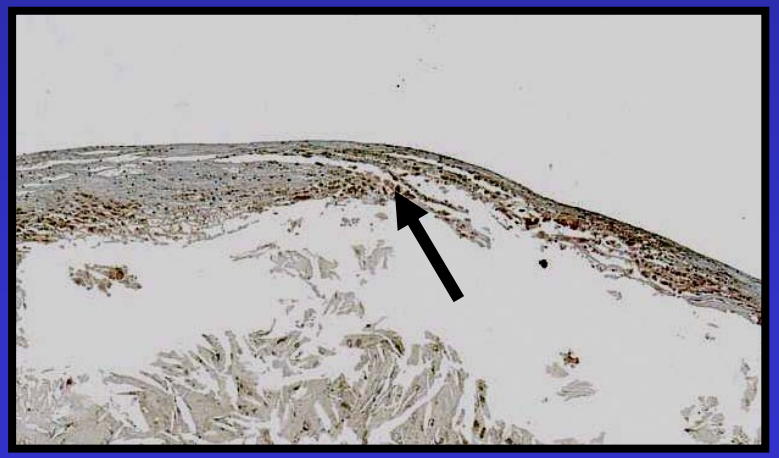

Macrophages

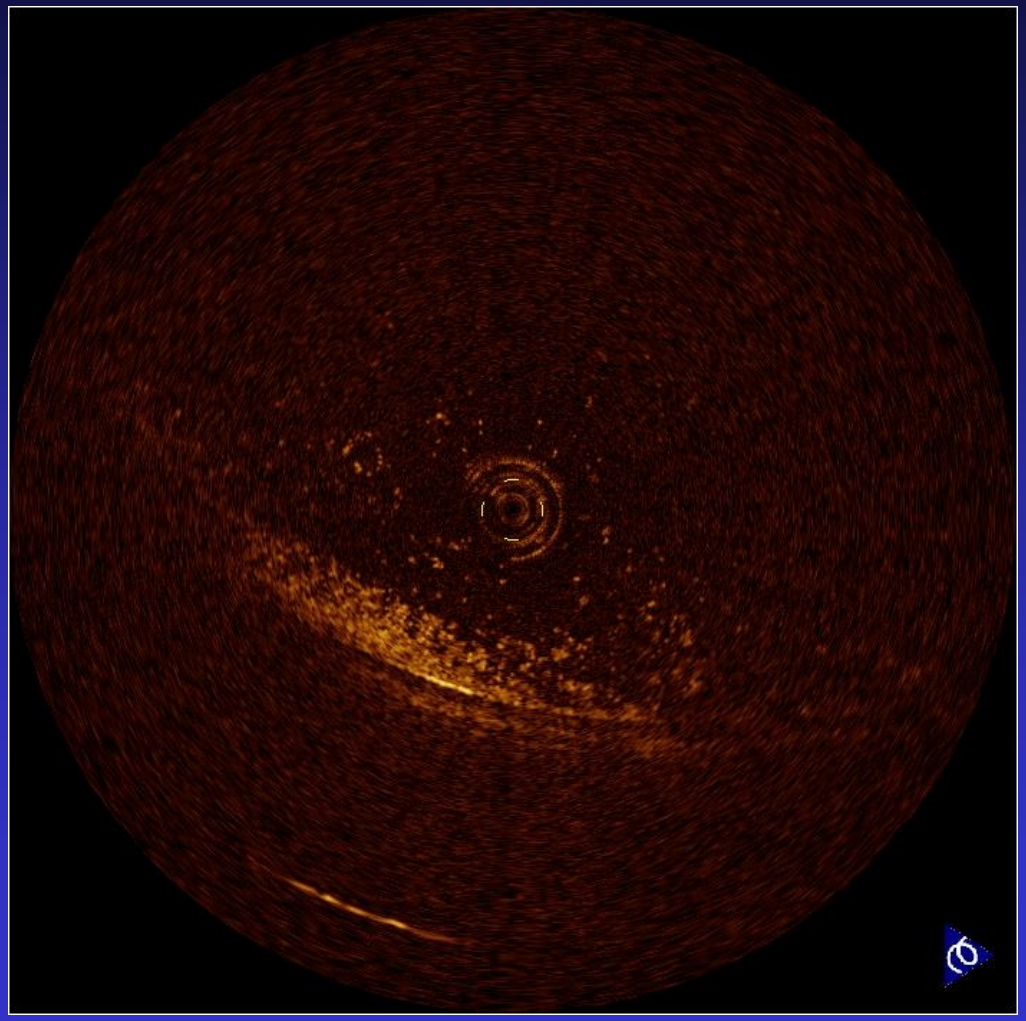

Pathohistological characteristics of vulnerable plaque

Assessment by OCT

- Positive remodeling △
- Eccentric plaques △
- Lipid-rich plaques (necrotic core) ○
- Thin fibrous cap ○
- Rupture or ulceration of fibrous caps ○
- Thrombus formation ○
- Macrophage accumulation △

Summary
Assessment of vulnerable plaque by OCT
Comparison with pathohistology

- Positive remodeling △
- Eccentric plaques △
- Lipid-rich plaques (necrotic core) ○
- Thin fibrous cap ○
- Rupture or ulceration of fibrous caps ○
- Thrombus formation ○
- Macrophage accumulation △

Unstable AP

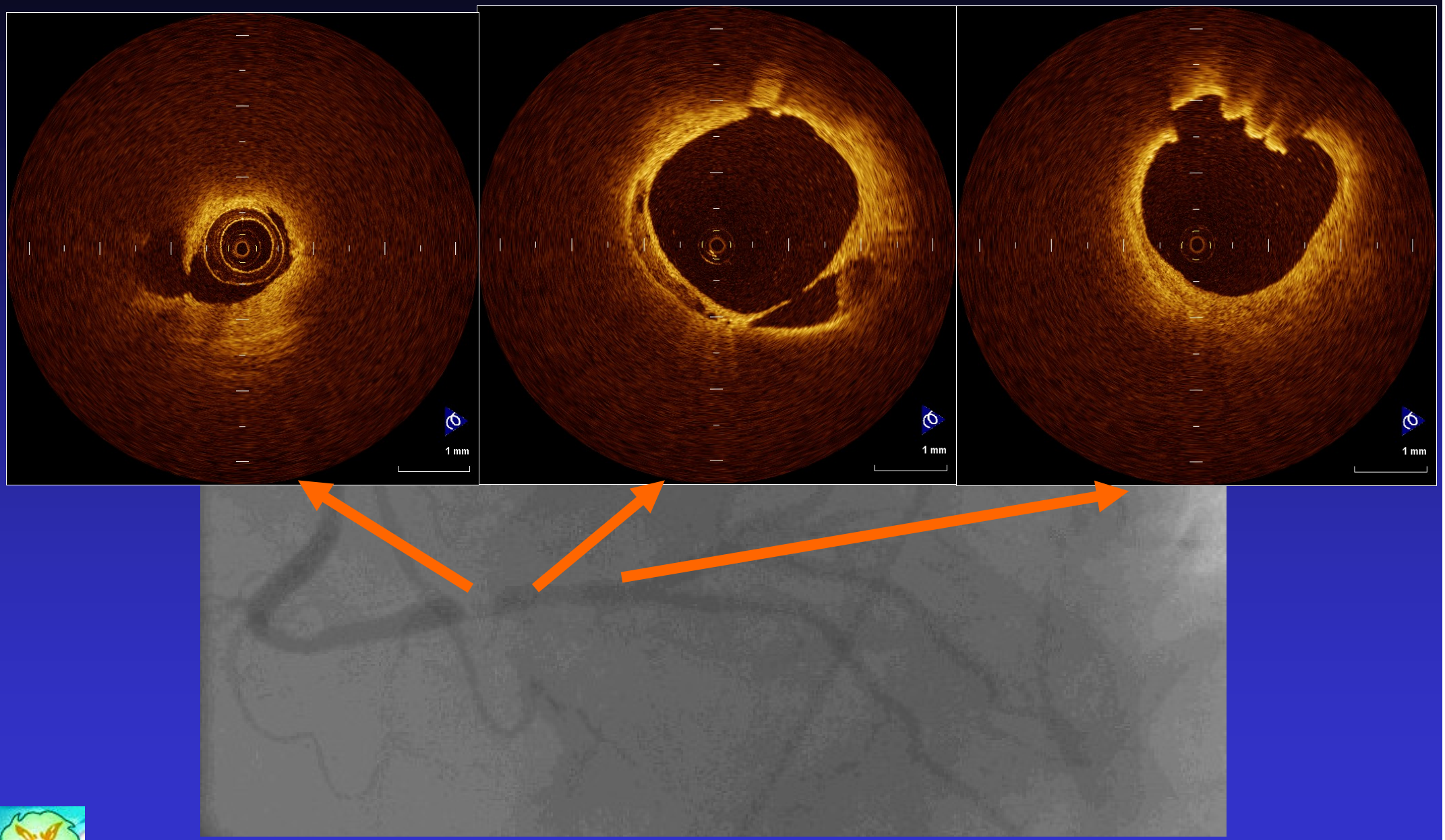

Three vessel OCT examinations in a patient with posterior AMI

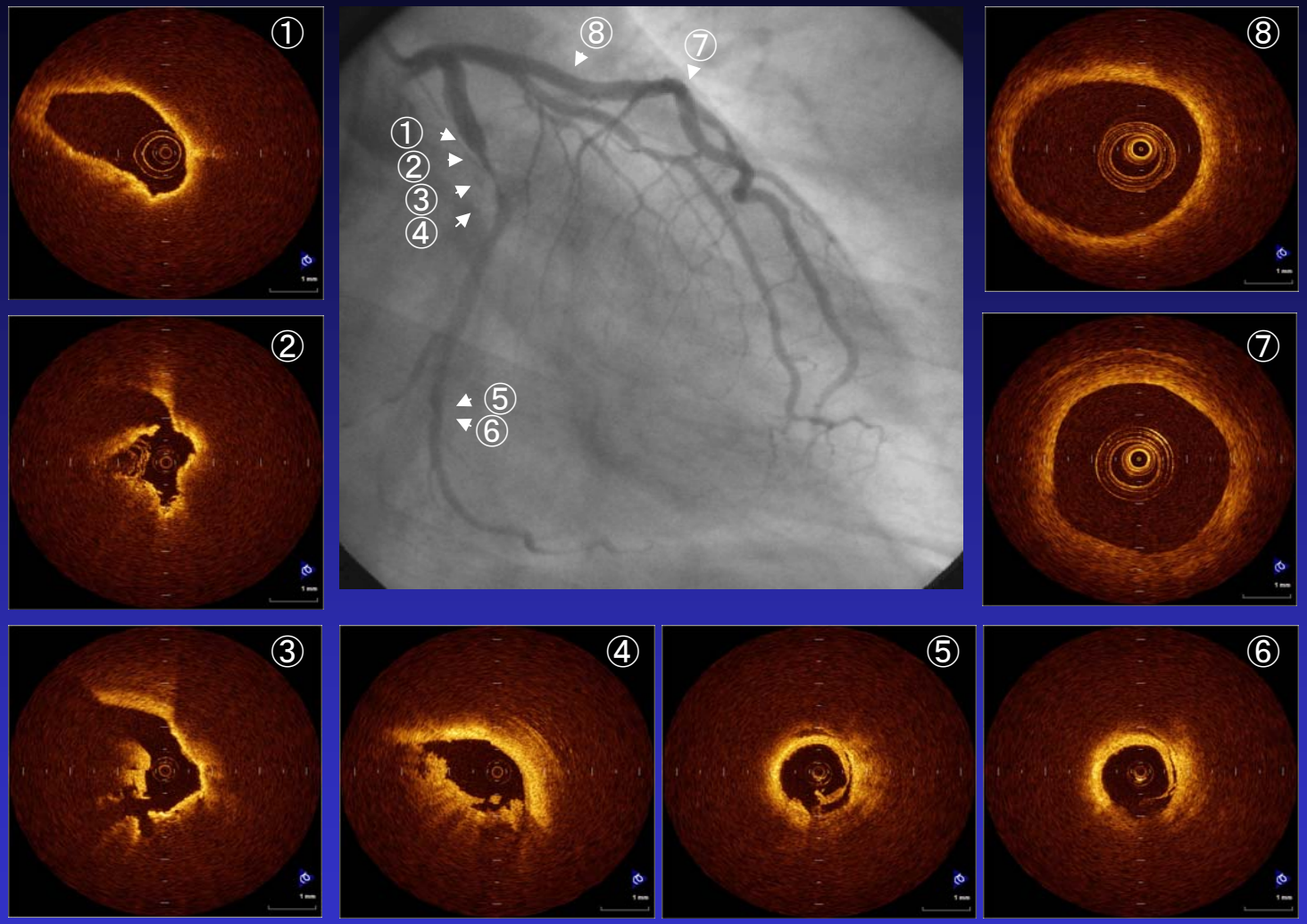

The culprit lesion was LCX (#11), and TCFA (①), plaque rupture (②,③) and intracoronary thrombus (②, ③, ④) were observed by OCT. Although the plaques in LAD (⑦, ⑧) were not observed, plaque rupture (⑤, ⑥) were detected by OCT in the non-culprit lesions of LCX (#13).

Three vessel OCT examinations in a patient with posterior AMI

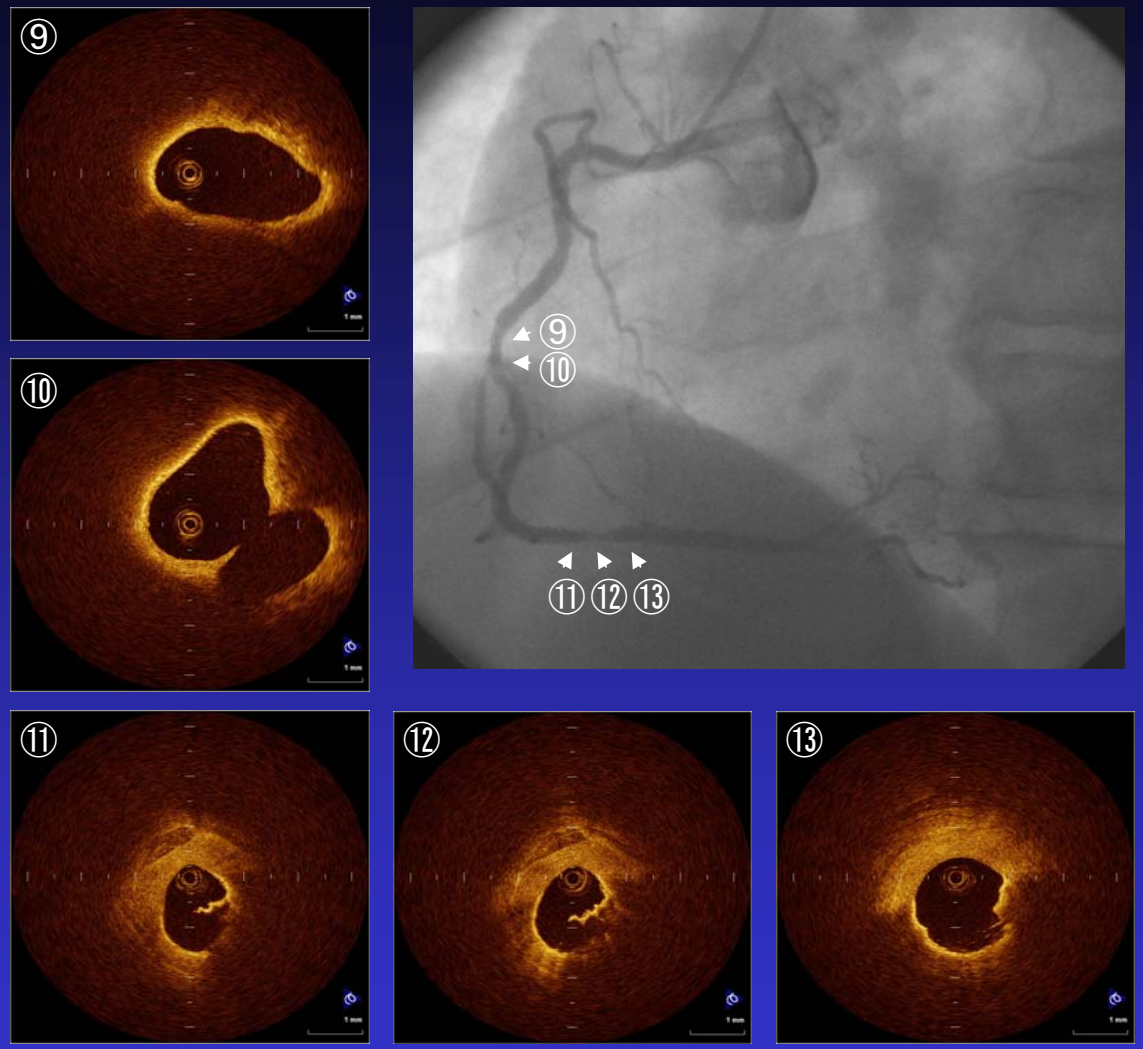

Also OCT revealed TCFA (⑨-⑬) and plaque rupture(⑪,⑫,⑬) in the non-culprit lesions of RCA.

OCT analysis of the non-culprit plaques

	Non-culprit plaque		p-value
	AMI (n=43)	SAP (n=25)	
Plaque rupture (n, %)	10 (24)	1 (4)	0.035
Plaque ulceration (n, %)	1 (2)	0 (0)	0.632
Intracoronary thrombus (n, %)	11(26)	0 (0)	0.006
Fibrous cap thickness (μm)	109±55.5	194±81.9	<0.001
Lipid arc > 90° (n, %)	18 (42)	12 (48)	0.623
TCFA (n, %)	15(35)	2 (8)	0.012

Conclusions

- OCT can identify lipid-rich plaques more sensitively compared with IVUS.
- OCT can demonstrate rupture or ulceration of fibrous cap with higher detection rate than that of IVUS or CAS.
- OCT could detect intracoronary thrombus almost exclusively which was confirmed by CAS.
- OCT may estimate macrophage accumulation within fibrous caps.

Conclusion

OCT should be the most ideal tool in the assessment of vulnerable plaques among various intravascular imaging modalities .

Corresponding Images of OCT and Angioscopy

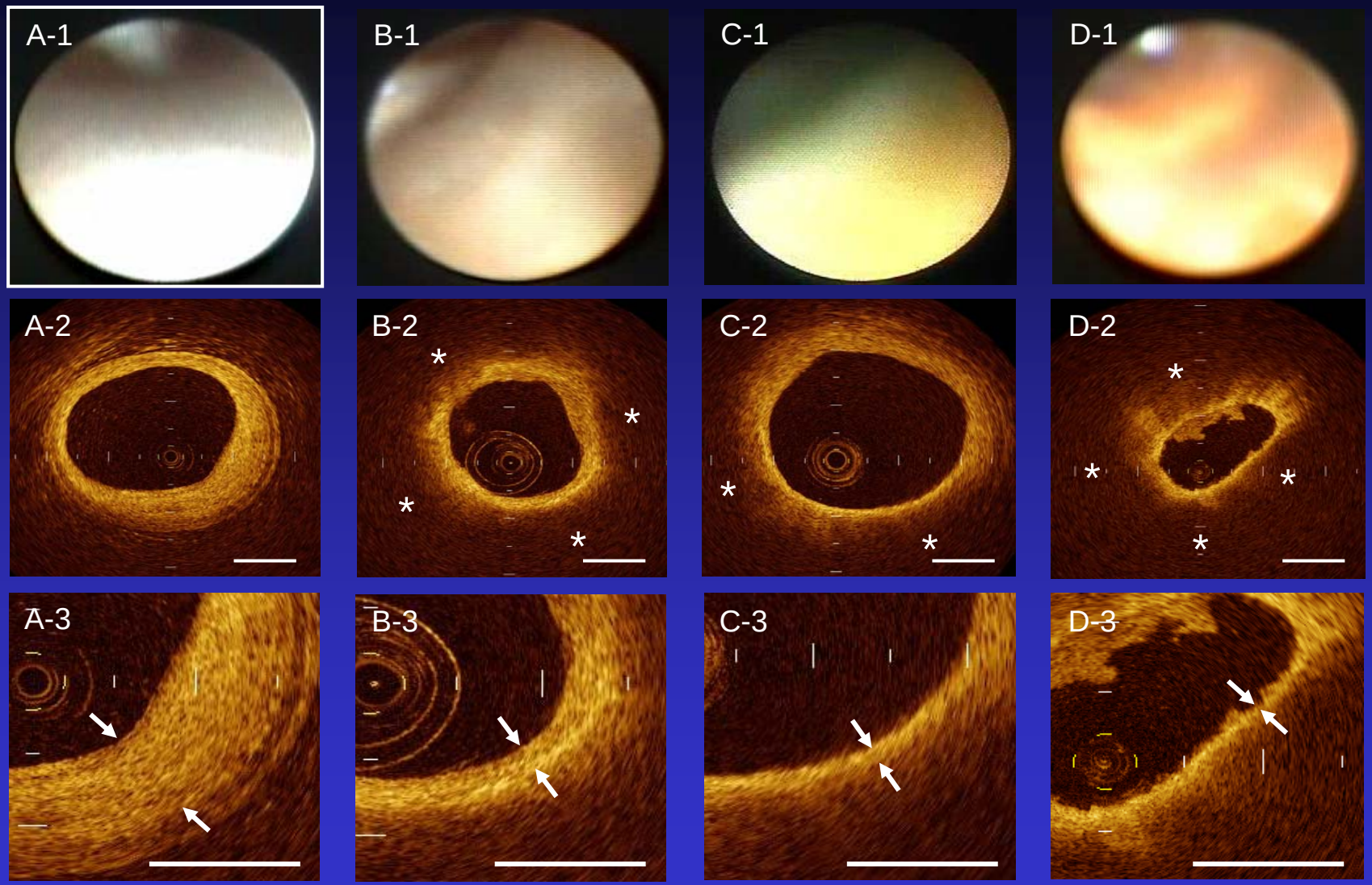

（Kubo T, et al. J Am Coll Cardiol Intv 1:74-80,2008）

Figure. 1

Wakayama Medical University

Angioscopy vs OCT

Plaque color vs lipid size

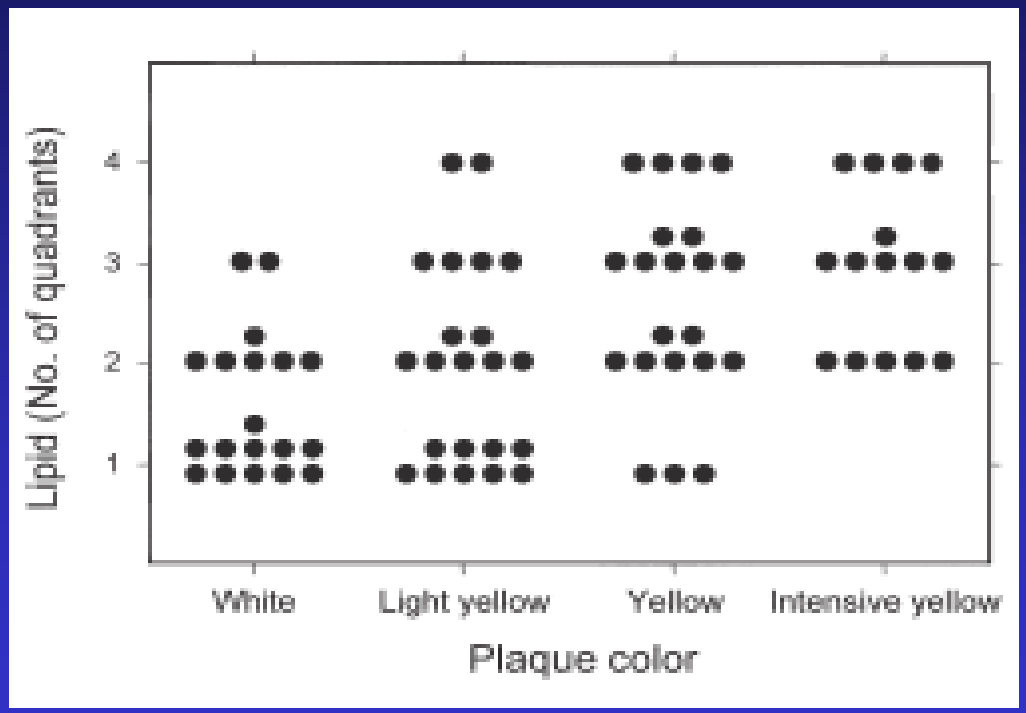

Plaque color vs fibrous cap thickness

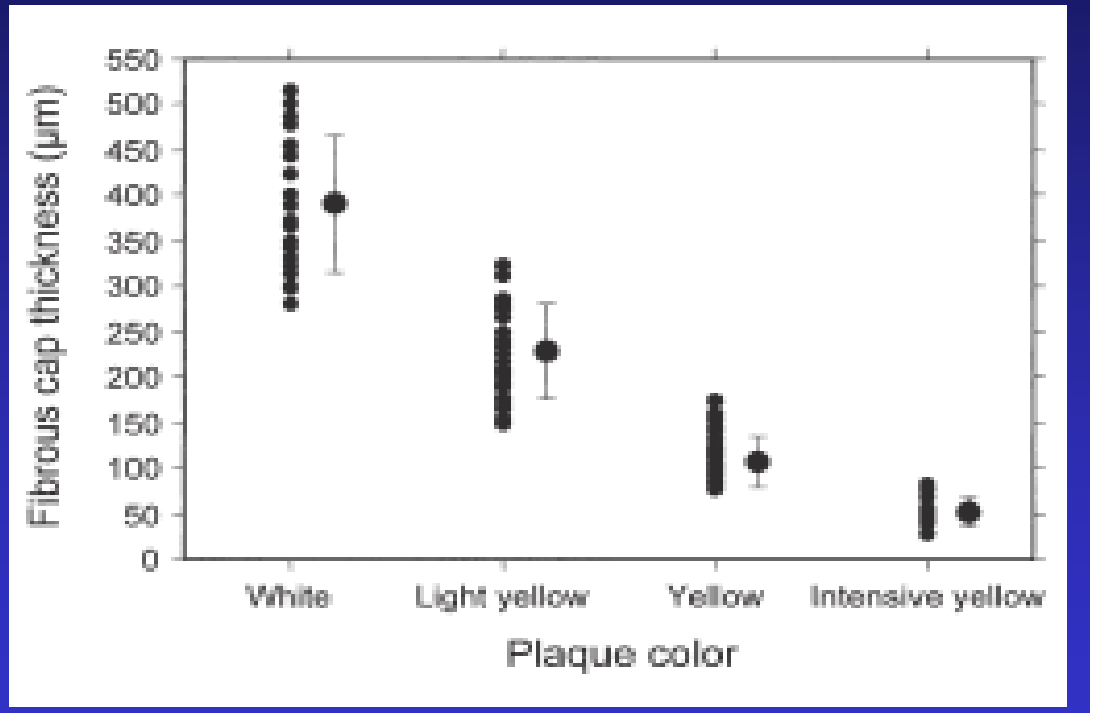

（Kubo T, et al. J Am Coll Cardiol Intv 1:74-80,2008）

IVUS-derived TCFA

(Rodriguez-Granillo GA, et al. J Am Coll Cardiol 46:2038-2042, 2005)

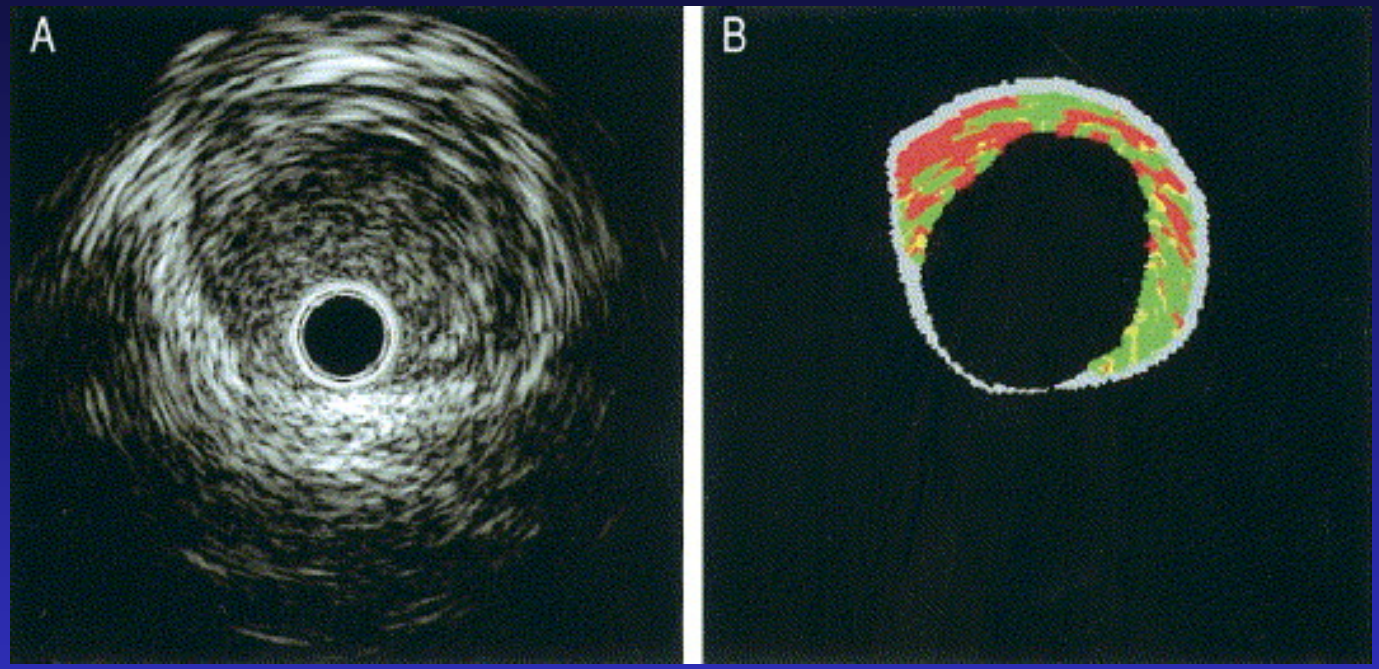

- Percent atheroma volume = (EEM area – Lumen area)/EEM area x100≧40%
- Nectrotic core≧10%
- Without evident overlying fibrous tissue

VH-IVUS vs OCT

Figure 2

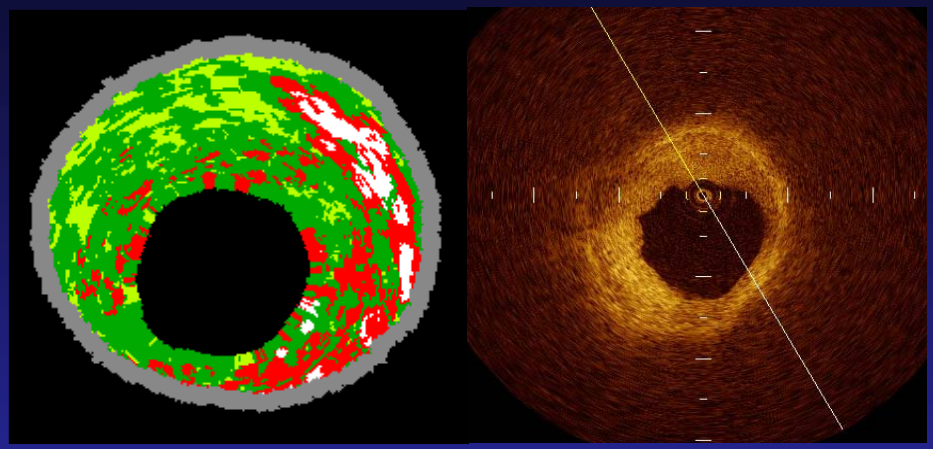

Without evident overlying fibrous tissue

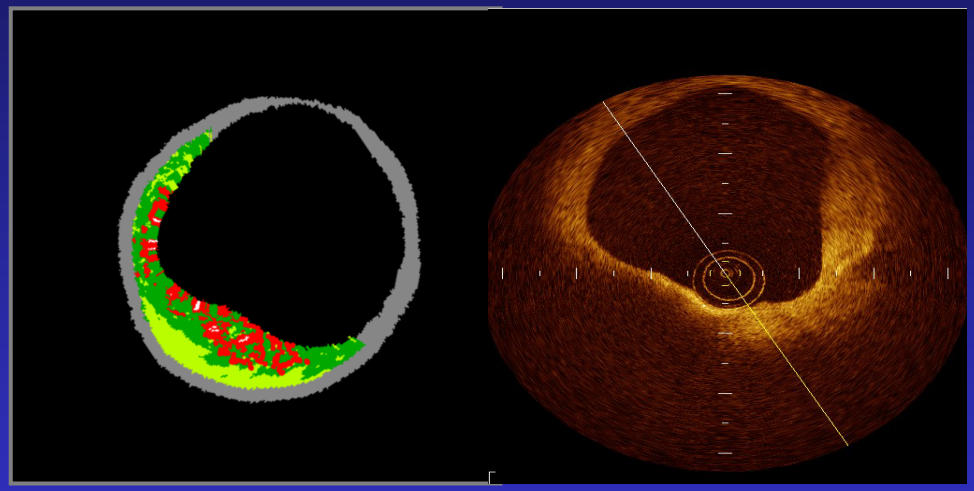

Without evident overlying fibrous tissue

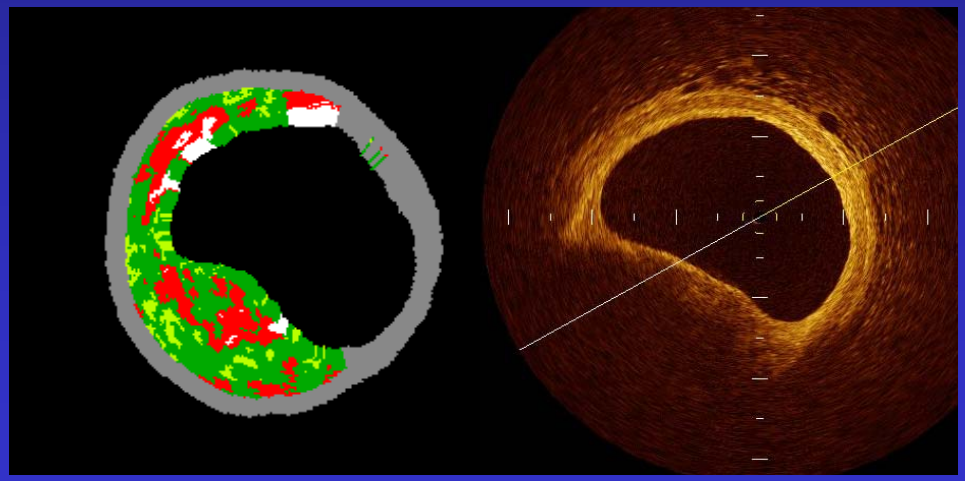

With evident overlying fibrous tissue

Concordance & discordance between VH-IVUS and OCT in the assessment of TCFA

Table 4

IVUS-VH Diagnosis \ OCT Diagnosis	TCFA (n=11)	Not TCFA (n=36)
VH-TCFA (n=31)	9	22
Not VH-TCFA (n=16)	2	14

Pathohistological characteristics of vulnerable plaque

- Positive remodeling
- Eccentric plaques
- Lipid-rich plaques (necrotic core)
- Thin fibrous cap
- Rupture or ulceration of fibrous caps
- Thrombus formation
- Macrophage accumulation

Thrombus

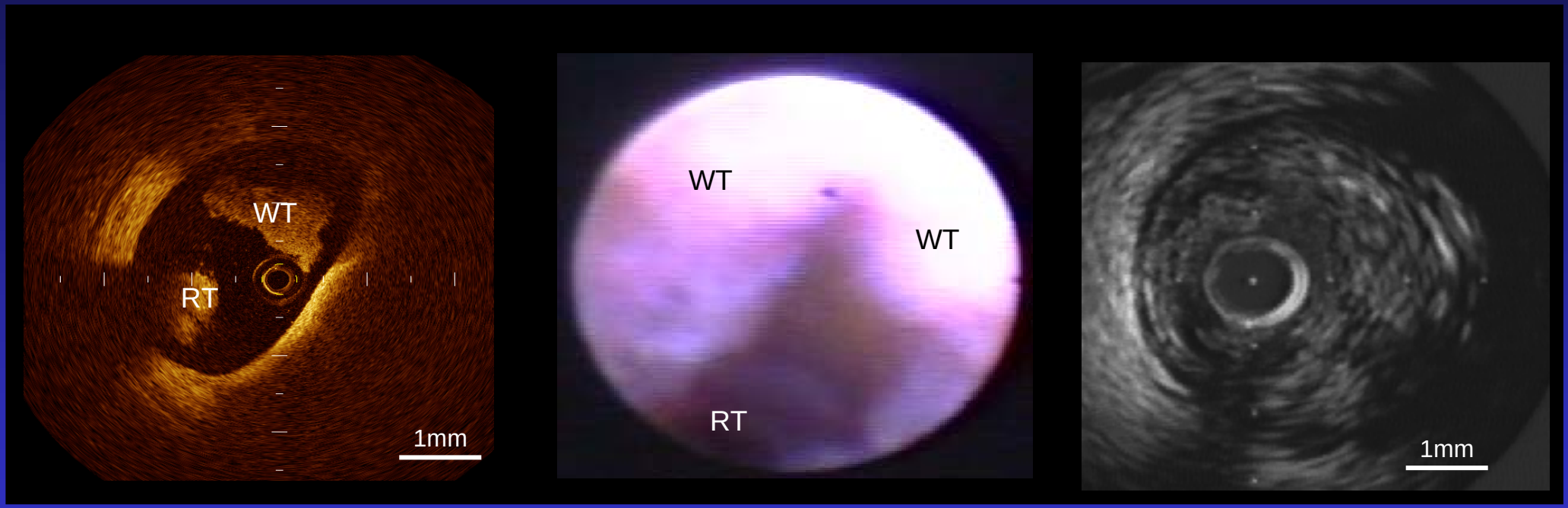

OCT CAS IVUS

Optical Coherence Tomography (OCT)

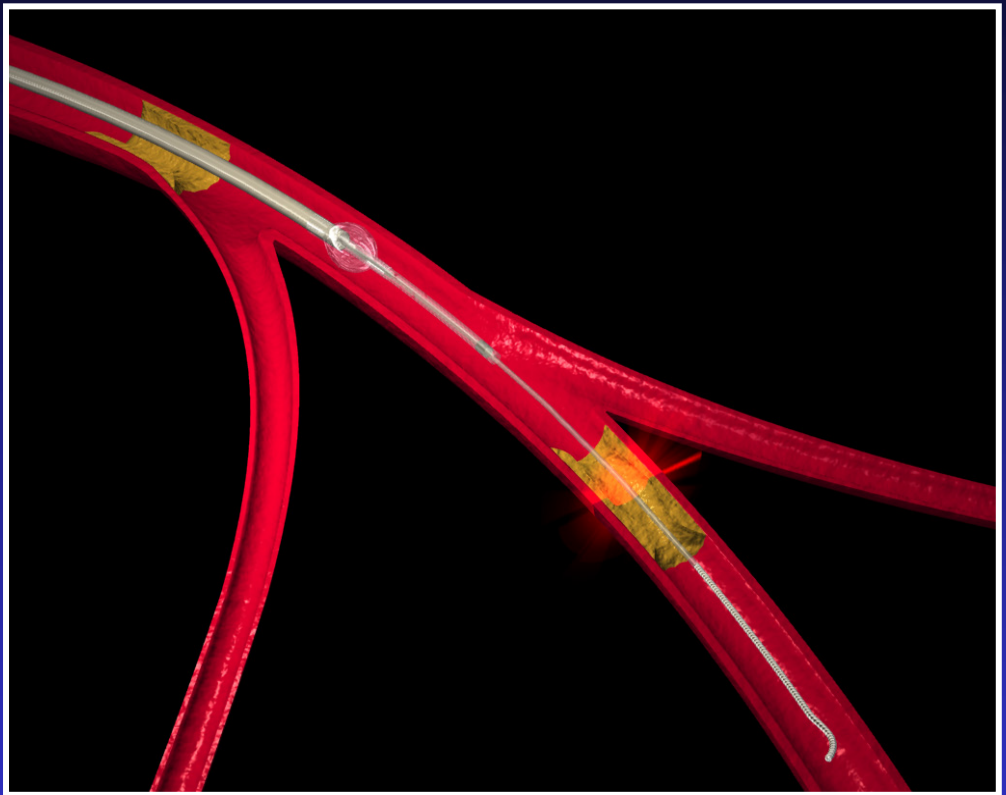

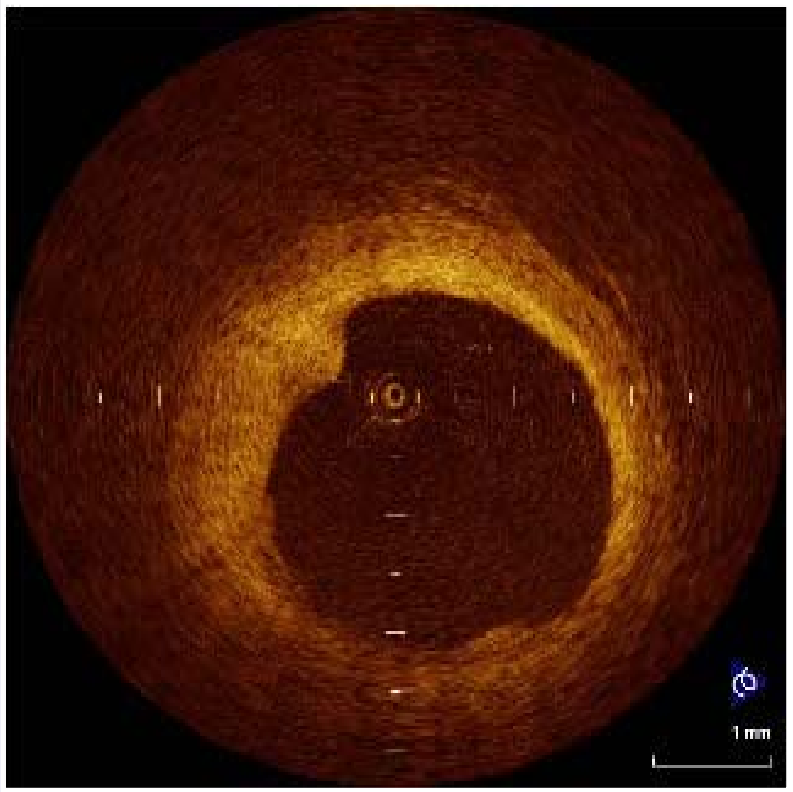

- Size of imaging core (0.4 mm)
- Microscopic resolution (10-20 μm)
- Real time Imaging (15 frames/s)

Fibrous plaque

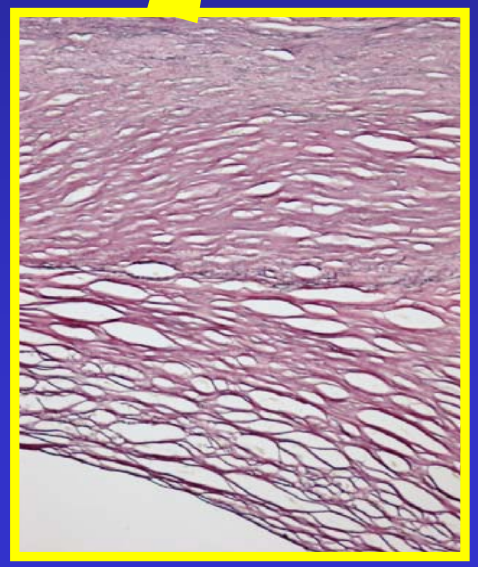

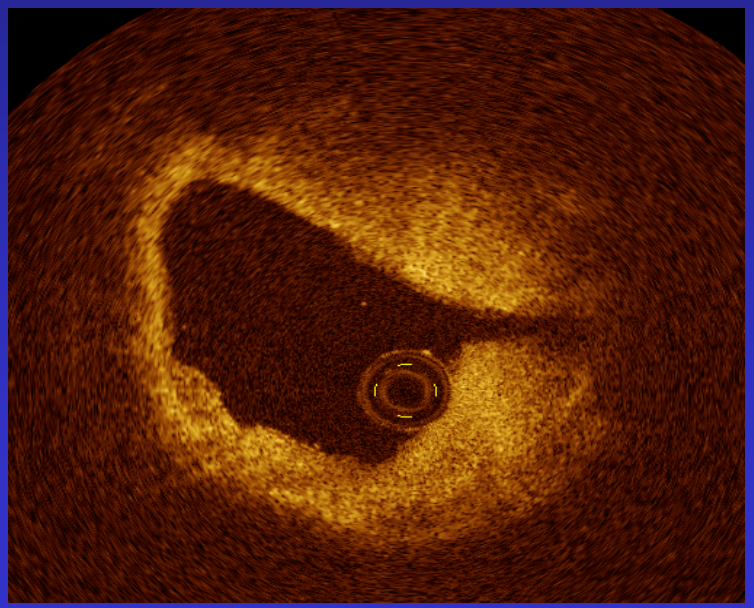

Fibrocalcific plaque

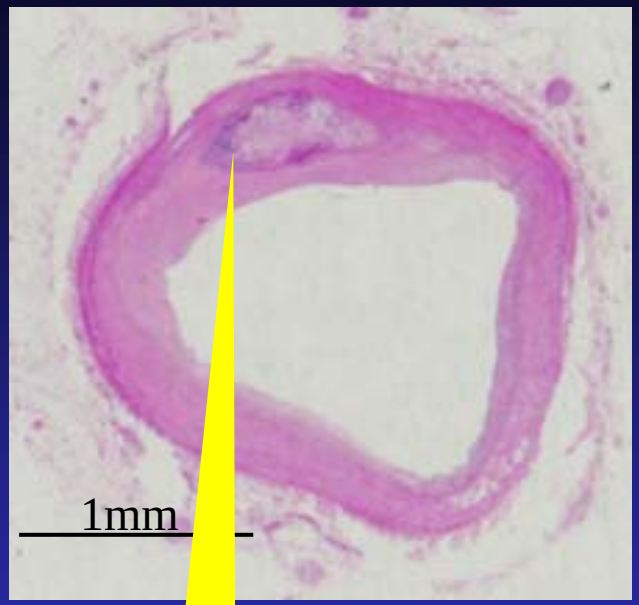

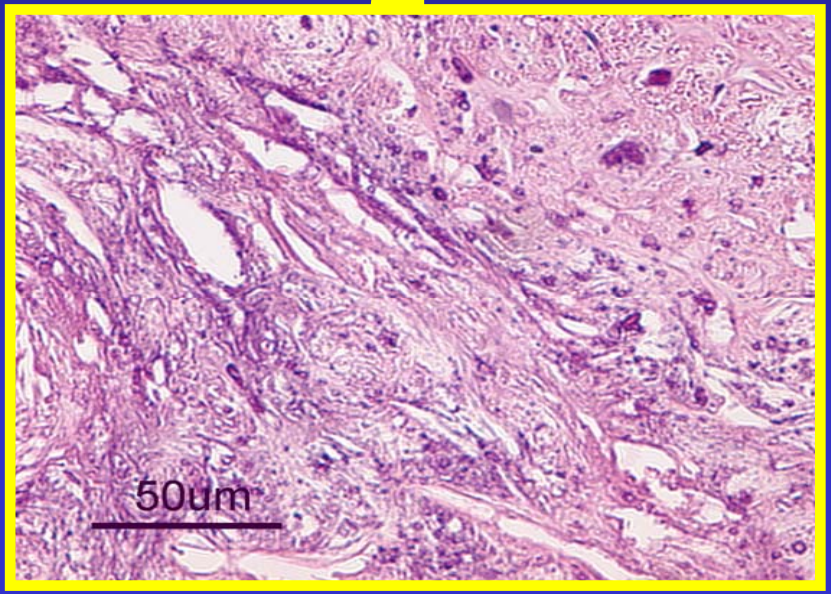

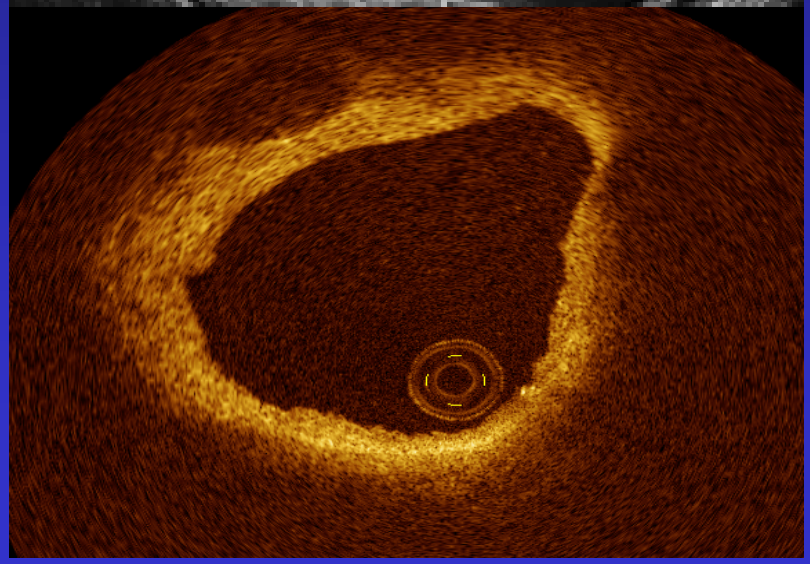

Fibro-lipidic plaque

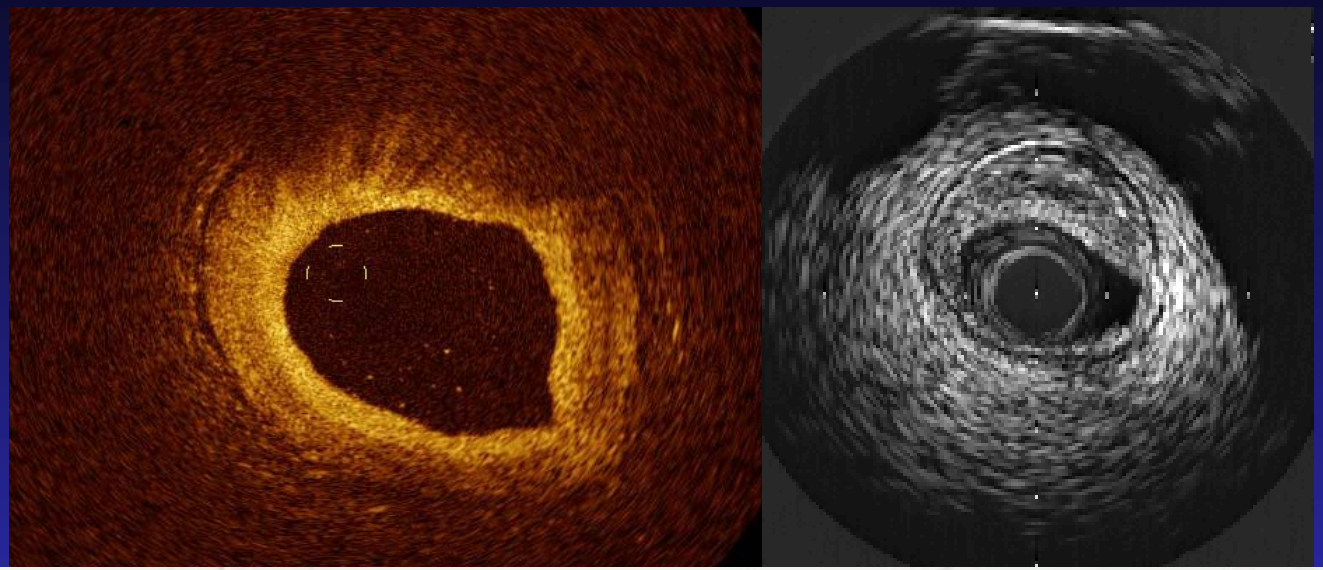

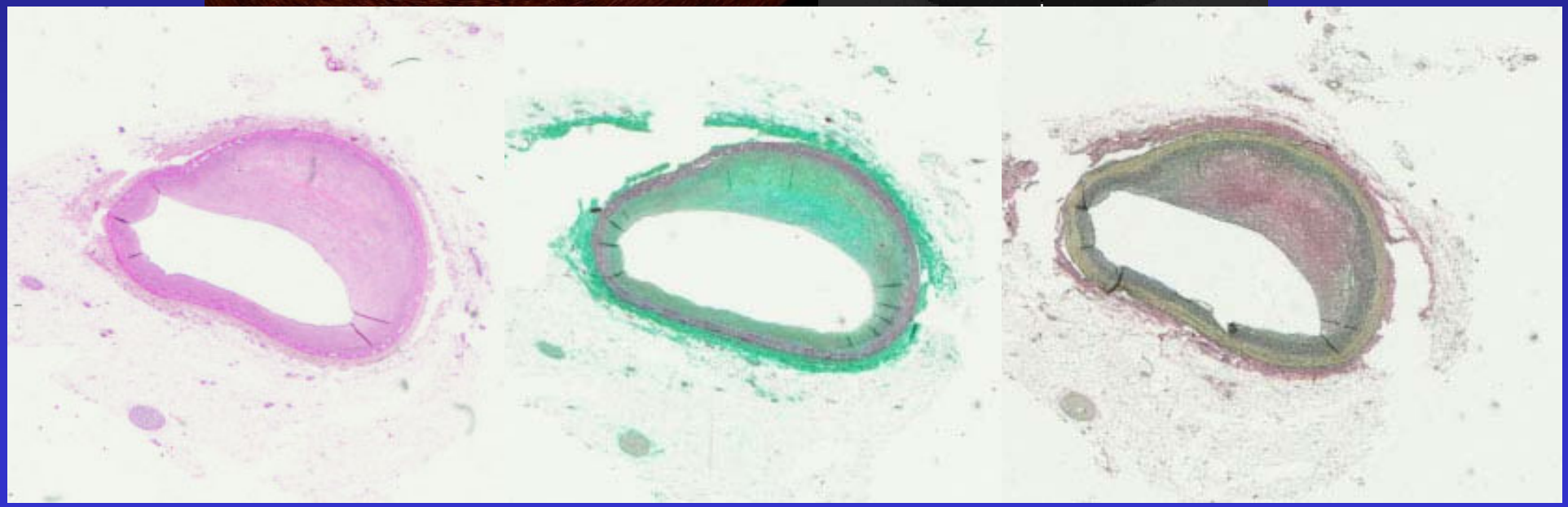

Comparison between IVUS and OCT

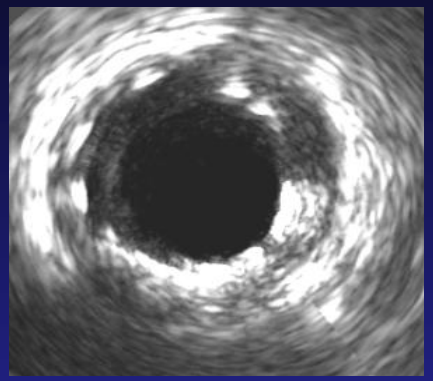

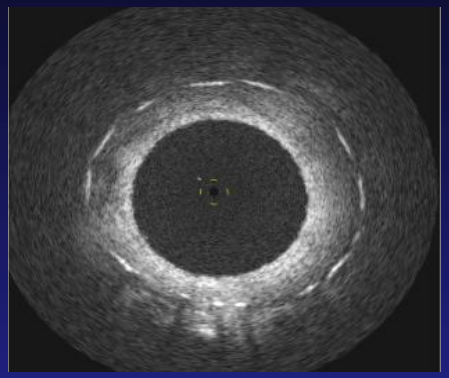

	IVUS	OCT
Resolution	*(axial)* 100 - 150 μm *(lateral)* 150 - 300 μm	15 - 20 μm 25 - 40 μm
Size of imaging core	0.8 mm	0.4 mm
Dynamic range	40 - 60 dB	90 - 110 dB
Frame rate	30 frames/s	15 frames/s

Optical Coherence Tomography (OCT)

Comparison between IVUS and OCT

	IVUS	OCT
Scan area	10 - 15 mm	7.0 mm
Max. penetration depth	4 - 8 mm	1 – 1.5 mm
Blood clearing To obtain images	Not required	Required