Basics and Techniques
Optical Coherence Tomography

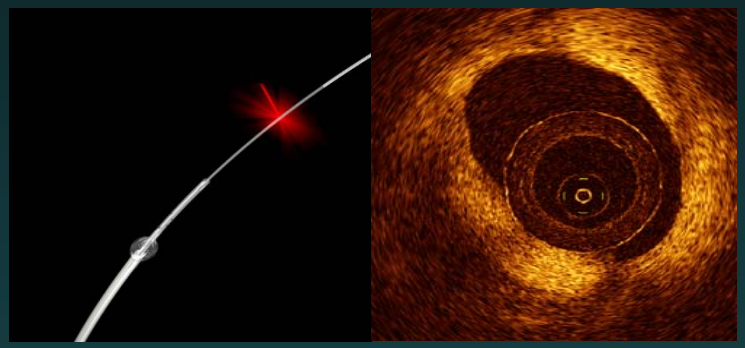

So-Yeon Choi, MD., PhD.

Ajou University School of Medicine, Suwon, Korea
Cardiovascular Research Foundation, New York, USA

What is OCT?

- **Optical Coherence Tomography (OCT) is a high-resolution imaging technology that employs near-infrared light (1.3 μM) to probe micrometer-scale structures inside biological tissues.**

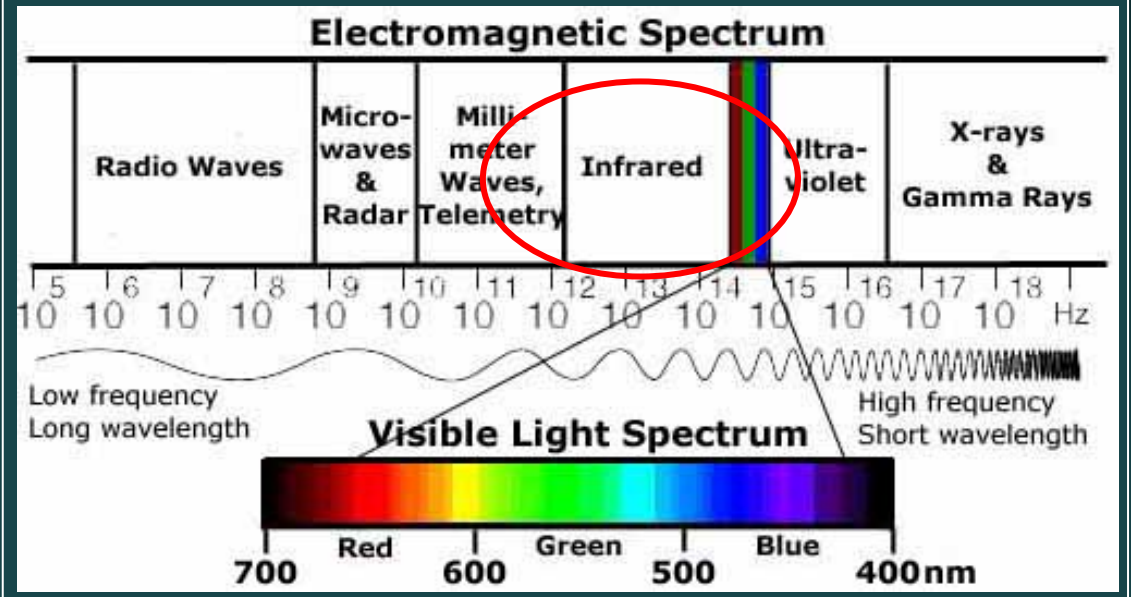

Near-infrared light

0.77-3μm, biologically safe

Property of particle and wave

•Goes straightly

•Reflection, refraction, interference, diffraction

•Doppler effect

OCT System: Interferometry

Interferometer Schematic

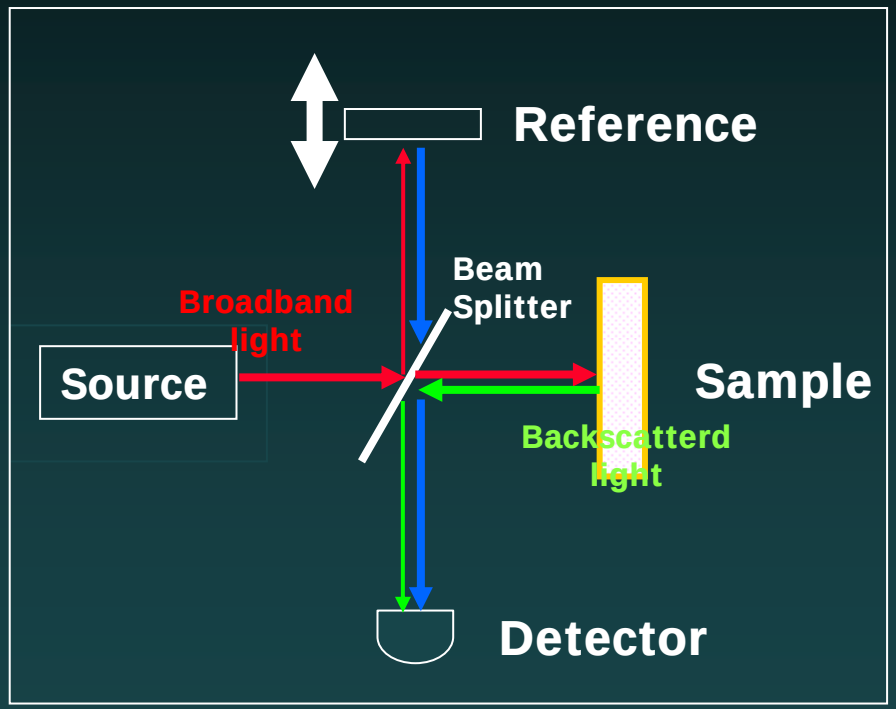

- When the back-reflected optical intensities of the sample and reference are measured and compared, the optical properties of the tissue is deduced.

Why Use OCT ?

1. Real time image for intravascular structure
2. High Resolution
3. Tissue characterization

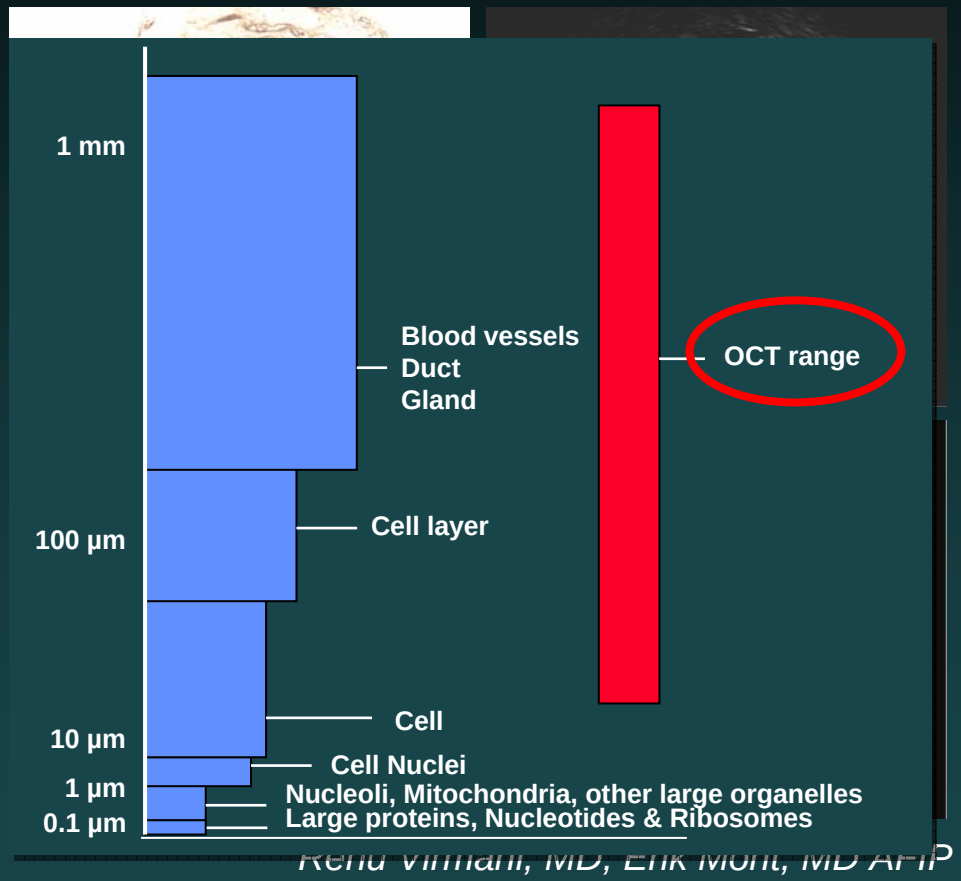

Comparison of IVUS and OCT

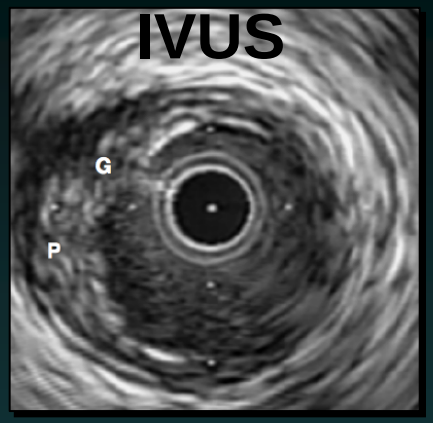

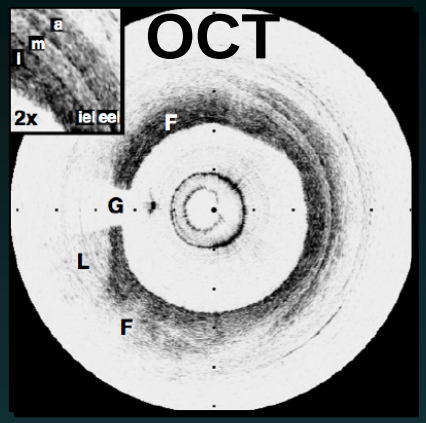

"First-in-man OCT"
Jang et al.
JACC, 2002

		IVUS	OCT
Resolution	*(axial)*	100 - 150 μm	10 - 20 μm
	(lateral)	150 - 300 μm	25 - 40 μm
Dynamic range			60 - 100 dB
Frame rate		30 frames/s	15 frames/s
Scan area		10 - 15 mm	7.0 mm
		Blood clearing not required	Requires blood clearing

Higher resolution almost 10 times more
Imaging core size is a half of that in IVUS

Scan area is smaller and penetration depth is more shallow
Requiring blood clearing to avoid the attenuation

Plaque Characterization by OCT

Ex Vivo Study

Fibrous | Lipid-rich | Calcified

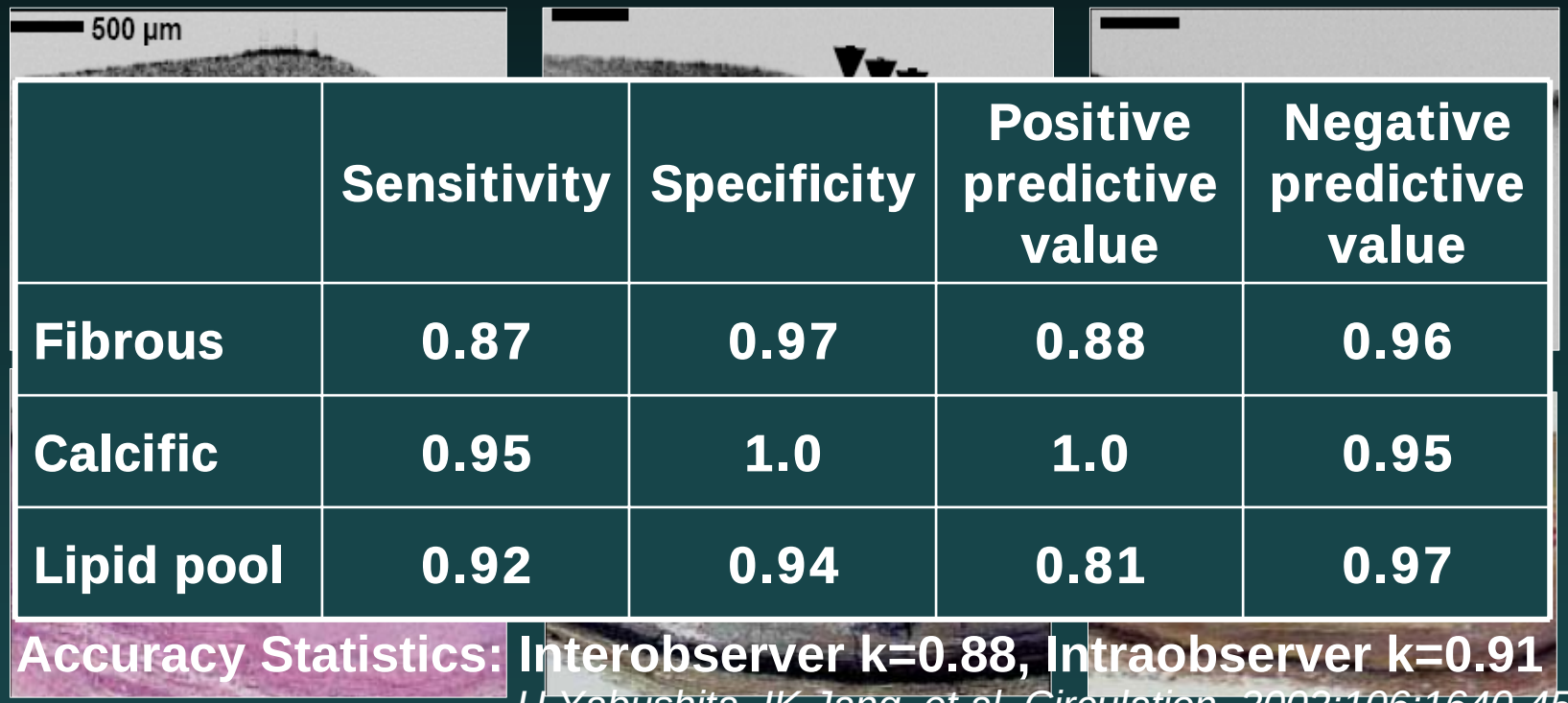

	Sensitivity	Specificity	Positive predictive value	Negative predictive value
Fibrous	0.87	0.97	0.88	0.96
Calcific	0.95	1.0	1.0	0.95
Lipid pool	0.92	0.94	0.81	0.97

Accuracy Statistics: Interobserver k=0.88, Intraobserver k=0.91

H Yabushita, IK Jang, et al. Circulation. 2002;106:1640-45

Presented by IK Jang in 2002 TCT

Plaque Characterization by OCT

Three Types of Plaque

Fibrous

- High reflectivity
- Homogenous
- Finely textured

Lipid-rich

- Low reflectivity
- Homogenous
- Diffuse margins

Calcified

- Low reflectivity
- Inhomogeneous
- Sharp margins
- Isolated, strong reflections in dark background

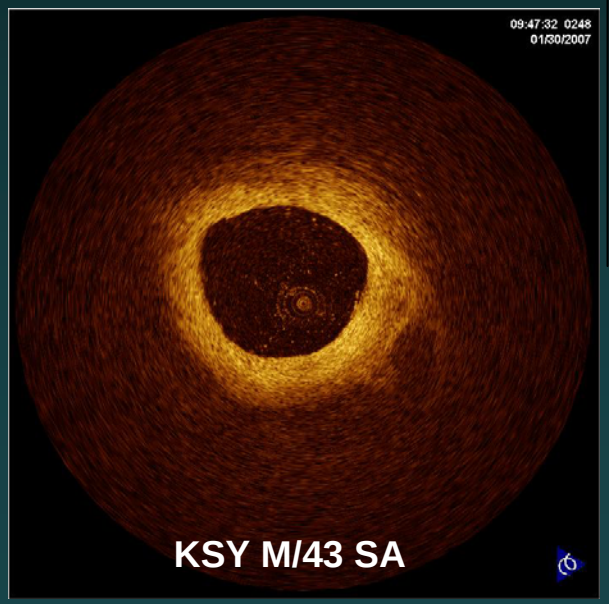

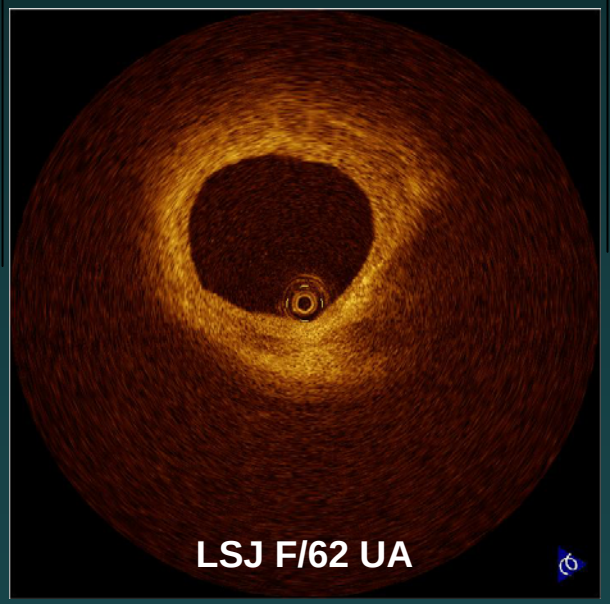

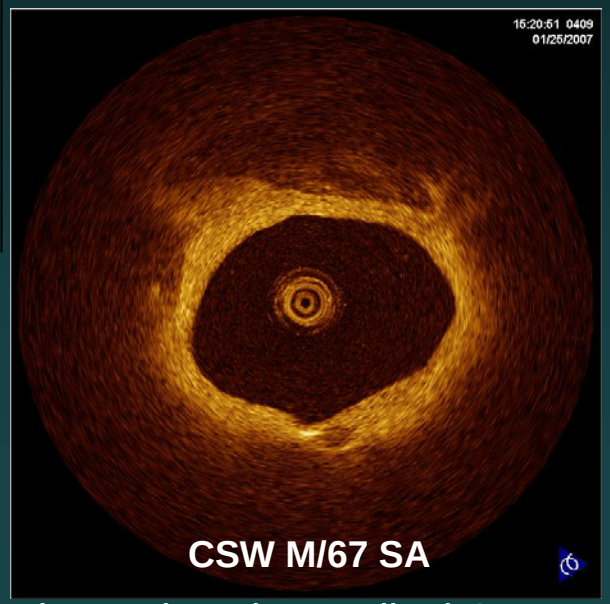

Ajou University Medical Center

Potential Applications of OCT

Vulnerable Plaque

OCT may provide better understand the natural progression of coronary artery disease and the answers longstanding questions about the relationship between vulnerable plaque and the risk of heart attack.

Therapeutic Guidance
Evaluation of Therapeutic Results

The technique is poised to play an important role in the guidance of therapeutic interventions and assessment of the results of medical and interventional treatment.

OCT for Detecting Vulnerable Plaque

Based on previously presented autopsy study

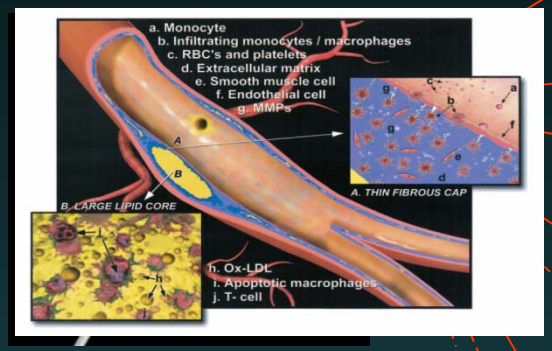

The vulnerable plaque characterized by thin fibrous cap, extensive macrophage infiltration, and large lipid core.

Major criteria

- **Active inflammation (monocyte/macrophage and T-cell infiltration)**
- **Thin cap with large lipid core**
- **Endothelial denudation with superficial platelet aggregation**
- **Fissured plaque**
- **Stenosis 90%**

Minor criteria

- **Superficial calcified nodule**
- **Glistening yellow**
- **Intraplaque hemorrhage**
- **Endothelial dysfunction**
- **Outward (positive) remodeling**

Circulation. 2003;108:1664-1672

Detection of VP in OCT

Macrophage Accumulation

There was a high degree of positive correlation between OCT and histological measurements of fibrous MQ density r=0.84, p<0.0001.

OCT Image **MQ Density**

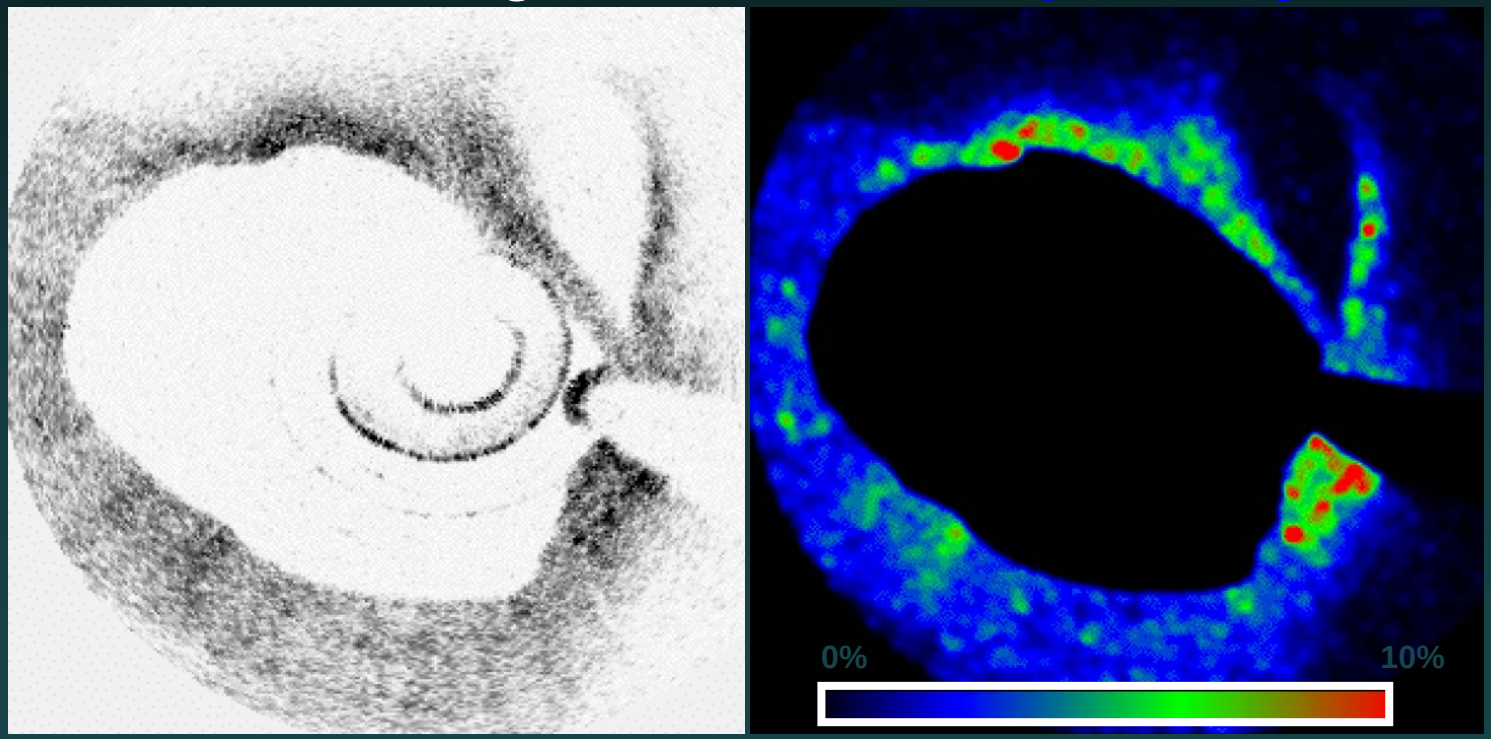

GJ Tearney, et al. Circulation 2003;107:113-9

Briain D. MacNeill, et al. J Am Coll Cardiol 2004;44:972–9

Detection of VP in OCT

Thin Fibrous Cap

57 patients: 20 AMI, 20 ACS, 17 SAP

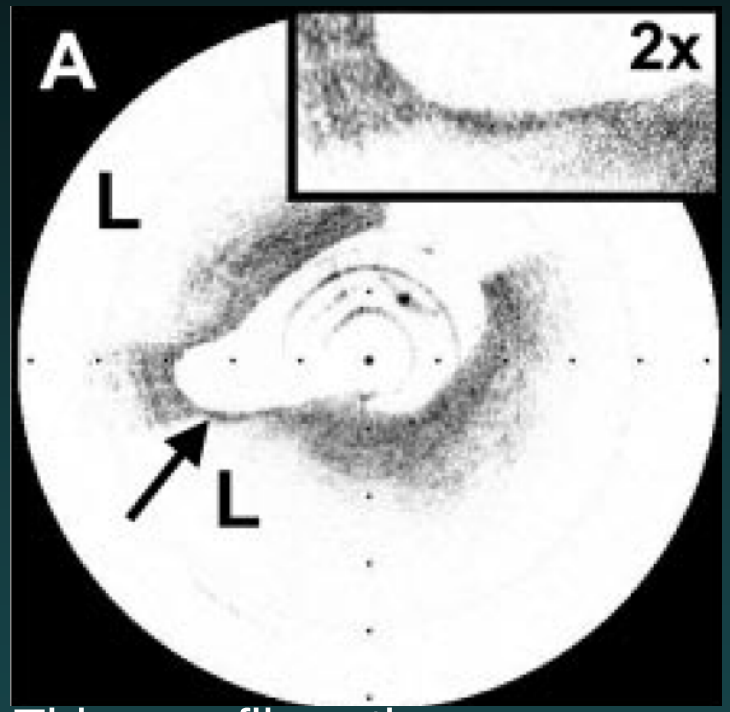

Thin-cap fibroatheroma was defined by lipid-rich plaque with cap thickness 65 μm

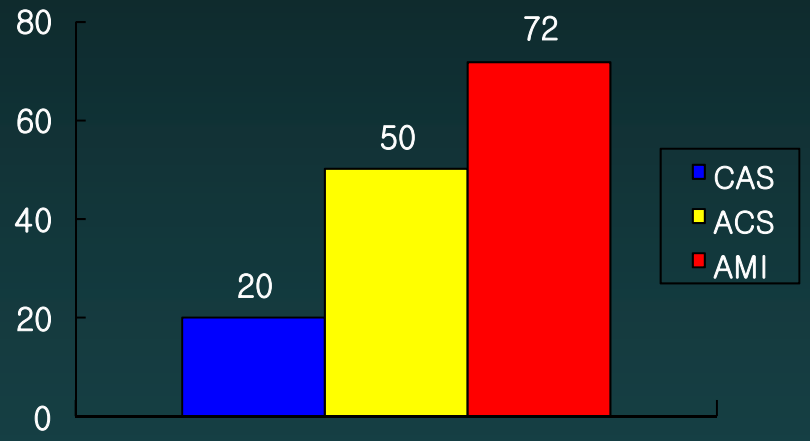

Thin-cap Fibroatheroma

Thin-cap fibroatheroma was more frequently observed in patients with AMI or ACS than SAP.

IK Jang, et al. Circulation. 2005;111:1551-5

Detection of VP in OCT

Superficial Lesion of Plaque

Intimal Tear

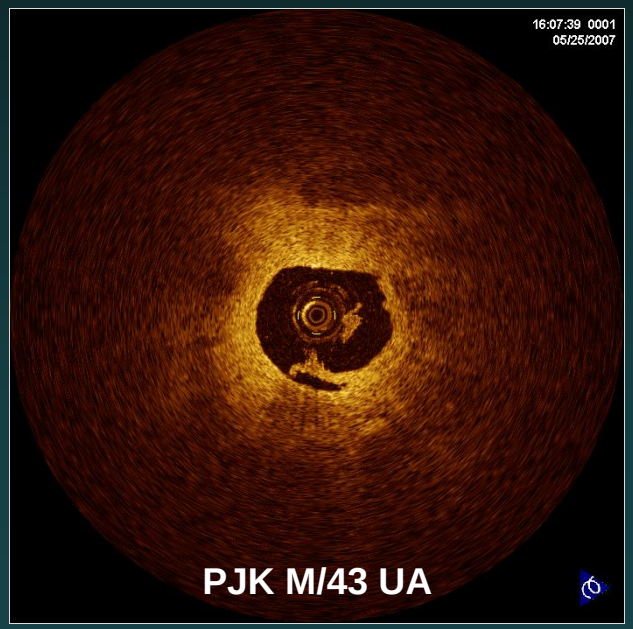

Plaque rupture

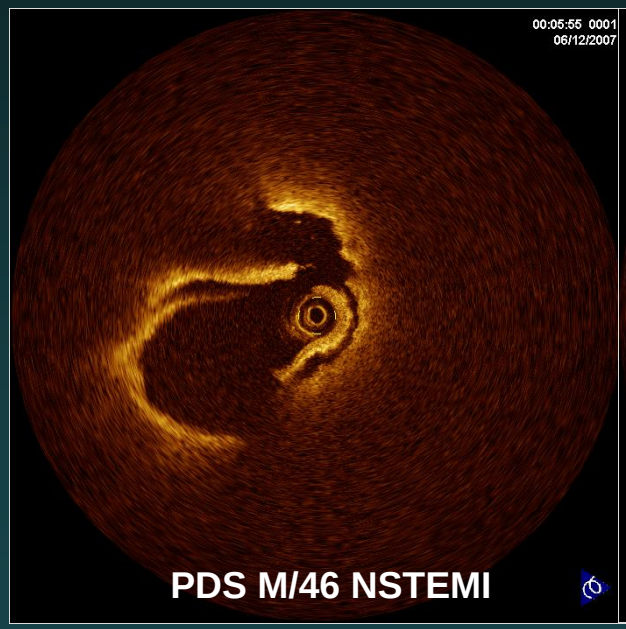

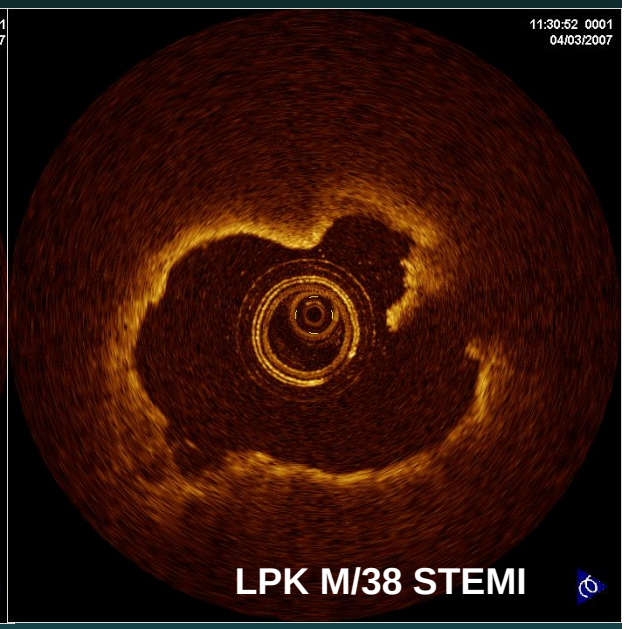

Ajou University Medical Center

Detection of VP in OCT

Thrombus

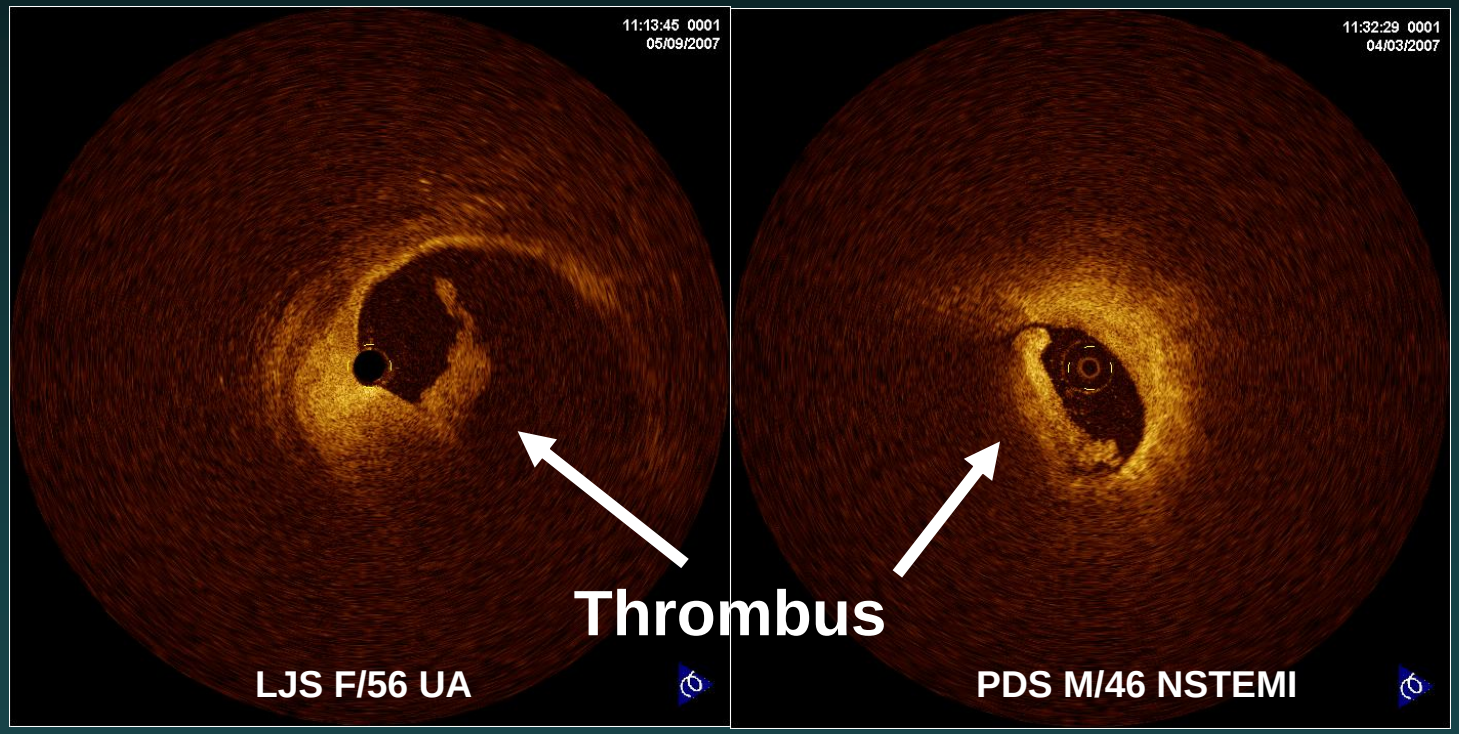

Ajou University Medical Center

Detection of VP in OCT

IVUS vs. VH-IVUS vs. OCT

The Major and Minor Criteria for Vulnerable Plaque

- 48 Patients (48 lesions) were enrolled and categorized according to their clinical presentation into SAP (n=15) and ACS (n=33).

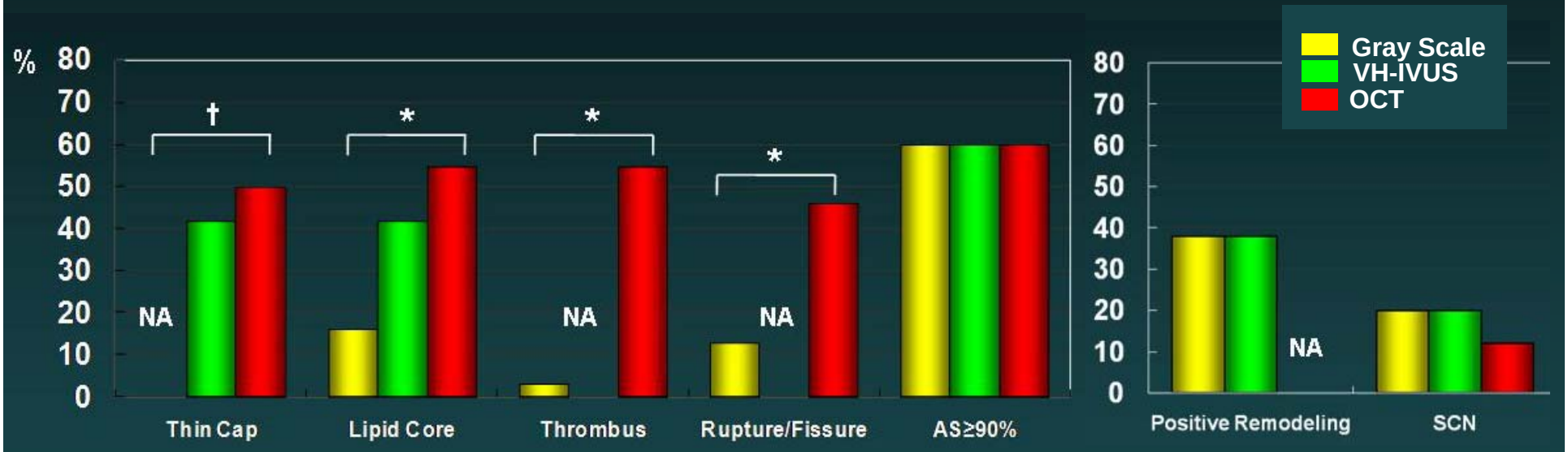

Major Criteria **Minor Criteria**

*p<0.05 among 3 modalities, †p<0.05 between GS vs. OCT, ‡p<0.05 between VH-IVUS vs. OCT

Choi et al, TCT 2008

Case

LCS
065699
56/M
NSTEMI

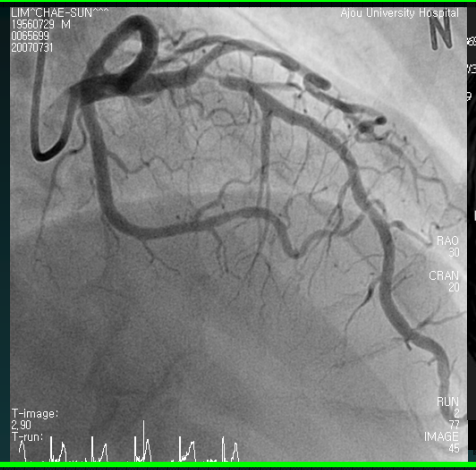

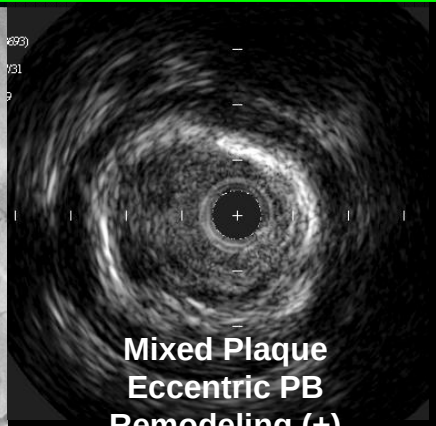

Mixed Plaque
Eccentric PB
Remodeling (+)

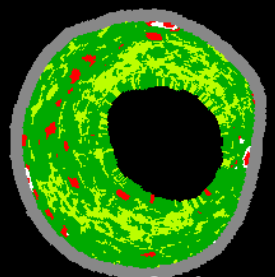

NC 5%
FF 20%
TCFA(-)

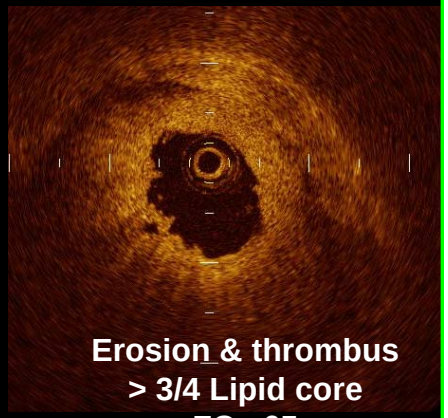

Erosion & thrombus
> 3/4 Lipid core
FC <65

Angiogram | **Grayscale** | **VH -IVUS** | **OCT**

SJW
0247337
59/F
UA

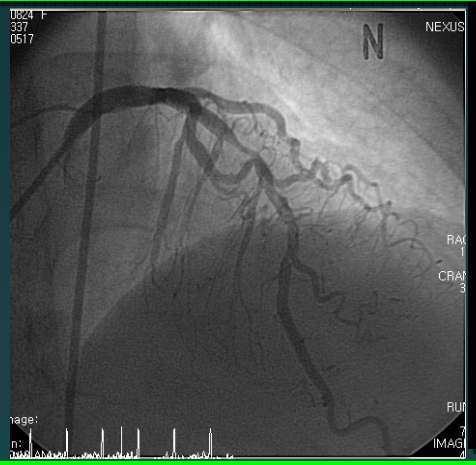

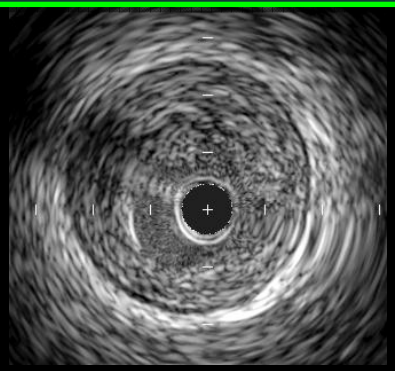

Soft Plaque
Remodeling (-)

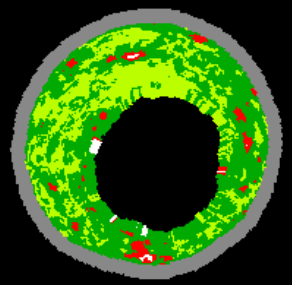

NC 2%
FF 37%
TCFA(-)

Erosion
> 2/4 Lipid core
FC<65

Ajou University Medical Center

Potential Applications of OCT

Vulnerable Plaque

OCT may provide better understand the natural progression of coronary artery disease and the answers longstanding questions about the relationship between vulnerable plaque and the risk of heart attack.

Therapeutic Guidance
Evaluation of Therapeutic Results

The technique can play an important role in the guidance of therapeutic interventions and assessment of the results of medical and interventional treatment.

OCT as a Tool for PCI

Understanding PCI Mechanism

After Cutting Balloon

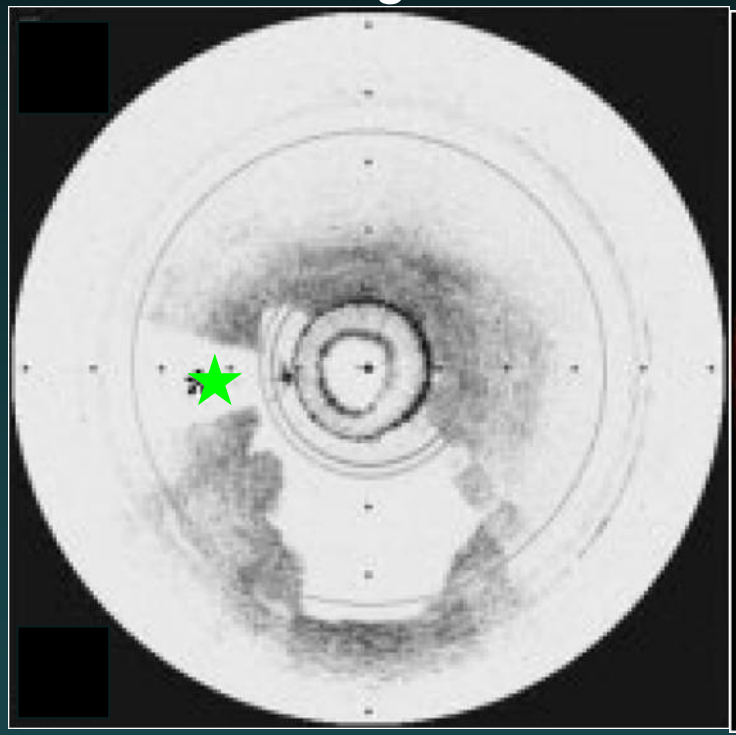

LJ. Diaz-Sandoval, IK Jang et al.
Cath Cardio Interv. 2005:65:492-6

After DCA

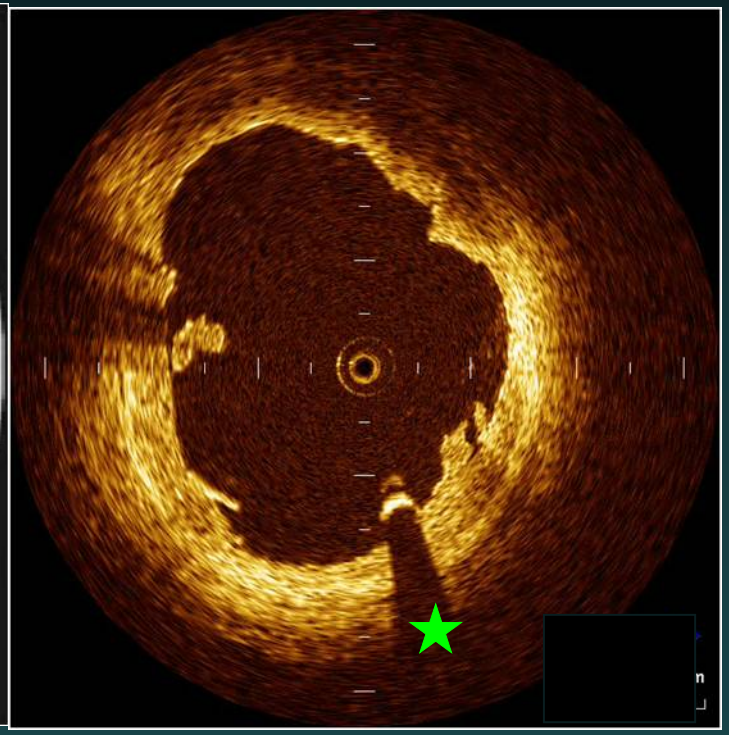

Suzuki
Toyohashi Heart Center, Japan

OCT as a Tool for PCI

Immediate Results after PCI

Well-apposed stent

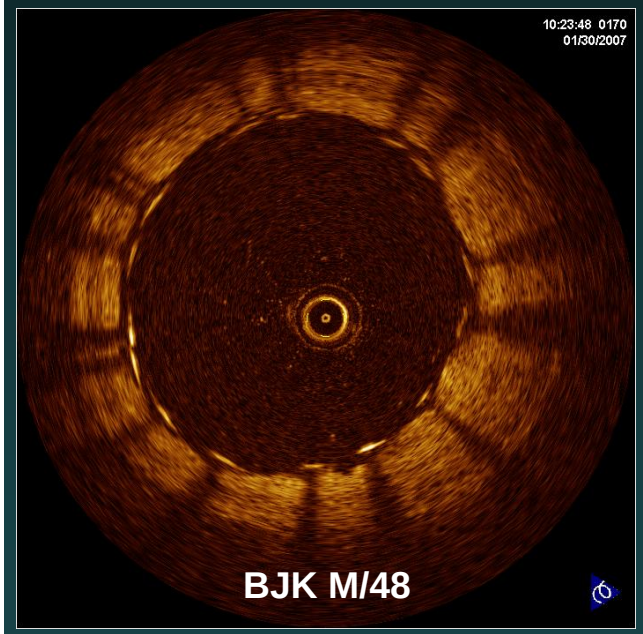

Cypher 4.0 x 23 mm
Ajou University Medial Center

Mal-apposed stent

Cypher 3.5 x 28 mm
Suzuki, Japan

Minor prolapse of plaque after stenting

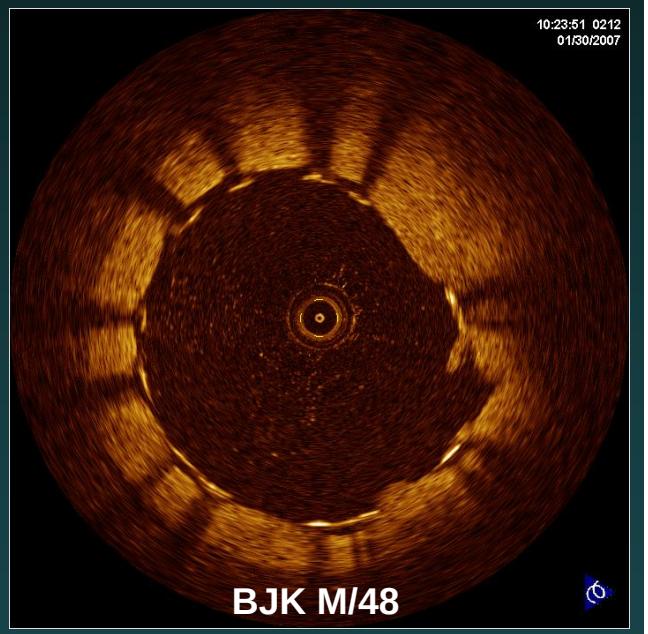

Cypher 4.0 x 23 mm
Ajou University Medial Center

Evaluation of Therapeutic Results

Long-term Results after PCI

Complete Tissue Coverage

Incomplete Tissue Coverage

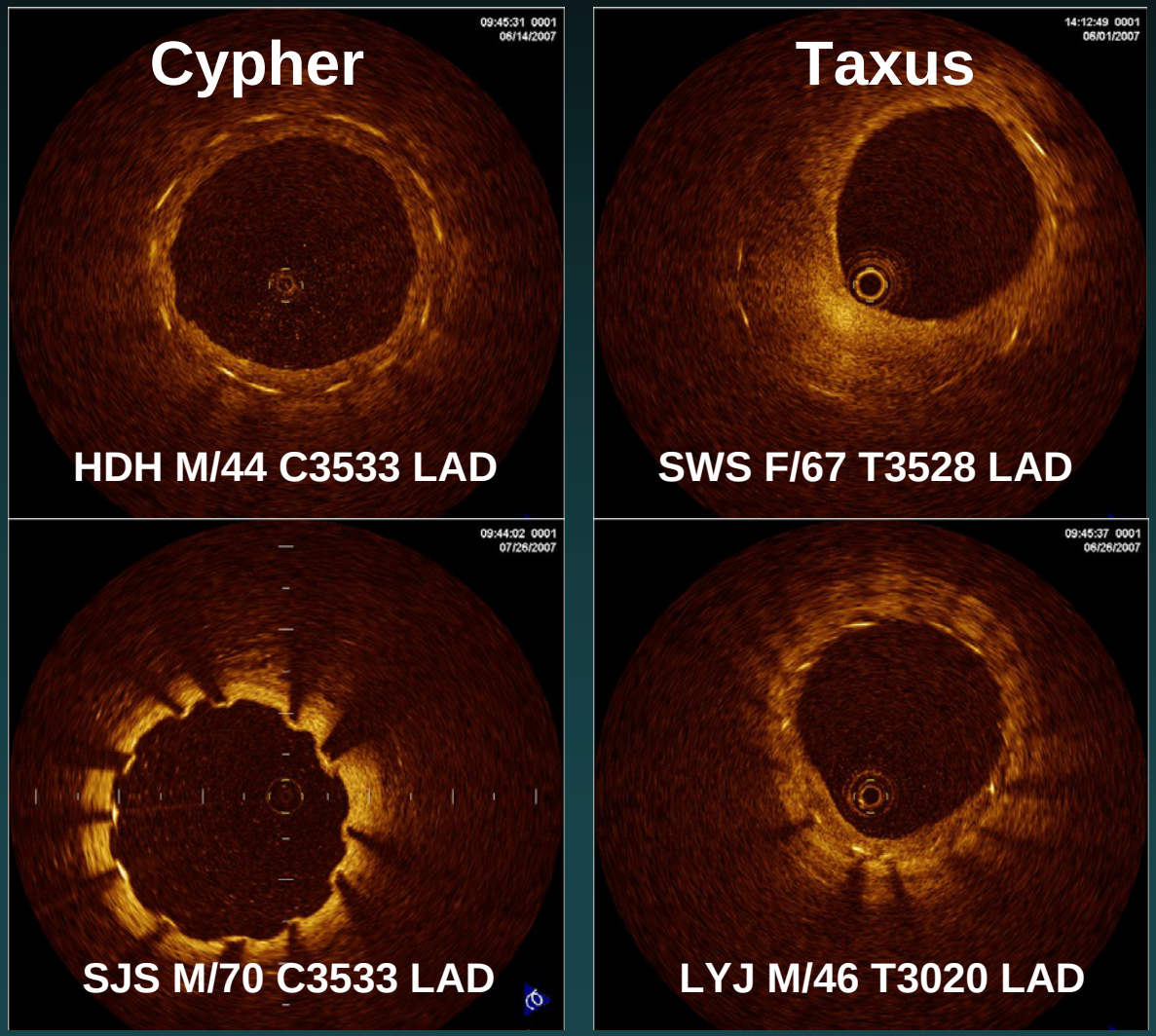

Ajou University Medical Center

Evaluation of Therapeutic Results

Incomplete Tissue Coverage

1936 Cross Sectional Images from 57 patients

Age 56±11, 43 males
(51 Cypher, 21 Taxus)
Average follow up period:
13.4±1.1 months

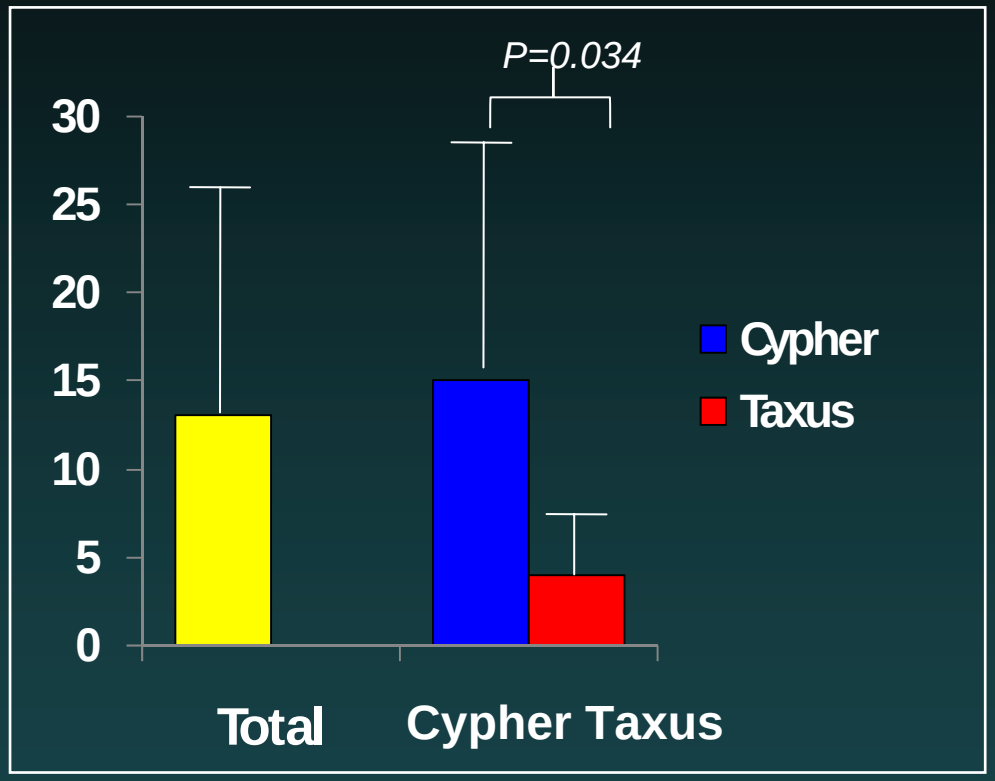

The uncovered strut index (USI) of total observed stent strut was 0.13±0.12. The USI of Cypher stent was significantly increased than Taxus stent (Cypher 0.15±0.04, Taxus 0.04±0.03, p=0.034).

Choi et al, TCT 2008

Evaluation of Therapeutic Results

OCT in Complex Lesion

F/U after Crushing with DESs in Bifurcation

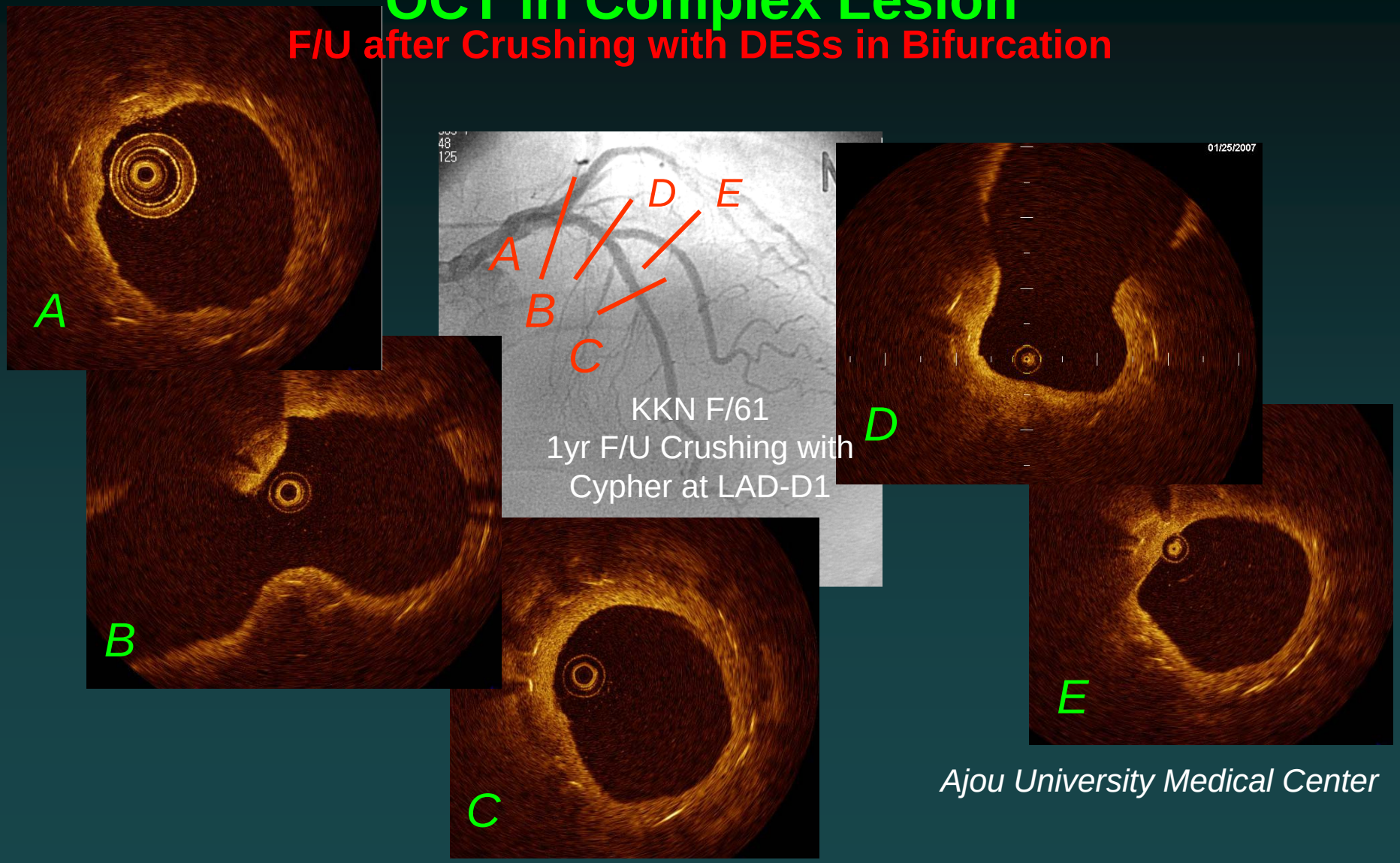

Ajou University Medical Center

OCT and PCI

	IVUS	OCT
Preinterventional lesion assessment		
Assessment of severity and clinical impact	☺	😐
Detect Vulnerable Plaque	😐	☺
During intervention		
Device sizing	☺	☹
Decision of strategies for the lesion	☺	😐
Understanding mechanism of intervention	☺	☺
Decision of ending of precedure	☺	☺
Recognition of complications	☺	☺
Serial follow-up		
Understanding for atherosclerosis	☺	☺
Mechanisms, prevention and Tx of restenosis	☺	☺
Assessment for long-term complication	☺	☺

OCT could be used as a tool for PCI by providing useful information in detecting VP and assessing PCI result and complication and evaluating long-term outcomes.

Limitation of OCT

1. OCT imaging needs blood free zone to avoid attenuation by blood flow.

2. OCT devices has some technical limitation in some lesions including left main disease, ostial disease, very tortuous lesion and so on.

3. Penetration through the arterial wall is in the range of 2–3 mm. The entire plaque cannot be imaged and only superficial anatomic information is obtained.

4. OCT could not detect lipid pools or calcium behind thick fibrous caps, and by an inability to distinguish calcium deposits from lipid pools or the opposite.

Complications of OCT

Experience in Ajou University Medical Center

Total 117 patients (male 73, age 57±9), 126 lesions
Successful image acquisition : 121 lesions (96%)
(3 wire passage failure, 2 incomplete occlusion)

Complication	number	%
Air embolization	0	0
Transient ischemia : ECG change with pain	57	49
Pulmonary edema due to volume overloading	0	0
Ventricular arrhythmia	1	0.01
Post PCI Infarction	0	0
Death	0	0

Limitation of OCT

1. OCT imaging is attenuated by blood and needs to create blood free zone.

2. OCT devices has some technical limitation, so there are some limited lesions including left main disease, ostial disease, very tortuous lesion and so on.

3. Penetration through the arterial wall is in the range of 2–3 mm. Sometimes, the entire plaque cannot be obtained.

4. OCT could not detect lipid pools or calcium behind thick fibrous caps, and by an inability to distinguish calcium deposits from lipid pools or the opposite.

Currently Evolving OCT

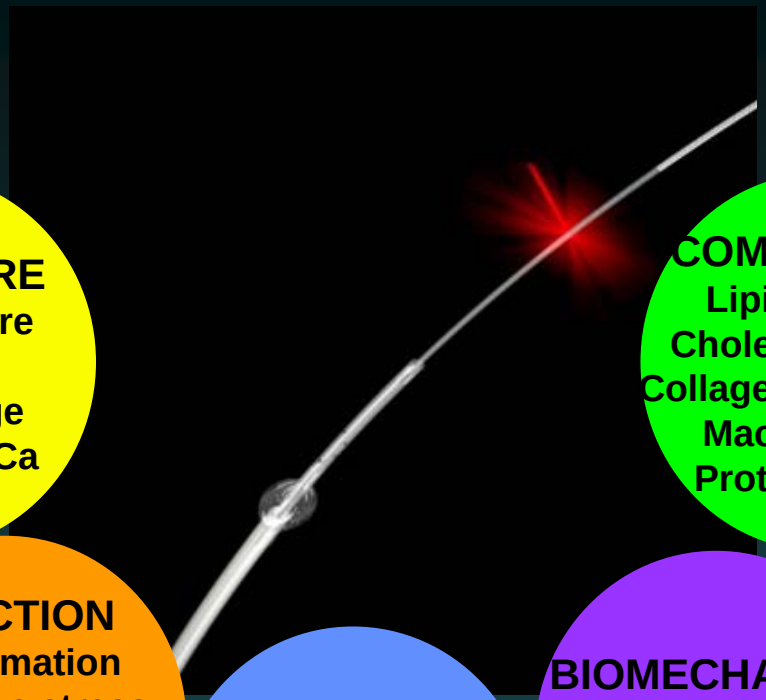

OCT, OFDI
LSI

STRUCTURE
Necrotic core
Thin cap
Macrophage
Superficial Ca

Raman
PS-OFDI

COMPOSITION
Lipid content
Cholesterol ester
Collagen component
Macrophages
Proteoglycans

FUNCTION
Inflammation
Oxidative stress
Endothelial dysfuction
Angiogenesis
Apoptosis

Raman
PS-OFDI

MOLECULAR

Fluorescence EEM,
Lifetimes

BIOMECHANICS
Cap stiffness
Core stiffness
Shear stress

LSI, OCE

G Tearney, TCT 2008

Currently Evolving OCT

Toward easy practice with OCT

Fourier-Domain OCT (FD-OCT)

Swept-Source OCT (SS-OCT)
Frequency-Domain OCT (FD-OCT)
Spectral-Domain OCT (SD-OCT)

Time-Domain OCT
M3 system (Light Lab)

Frequency Domain OCT
M4 Prototype (Light Lab)

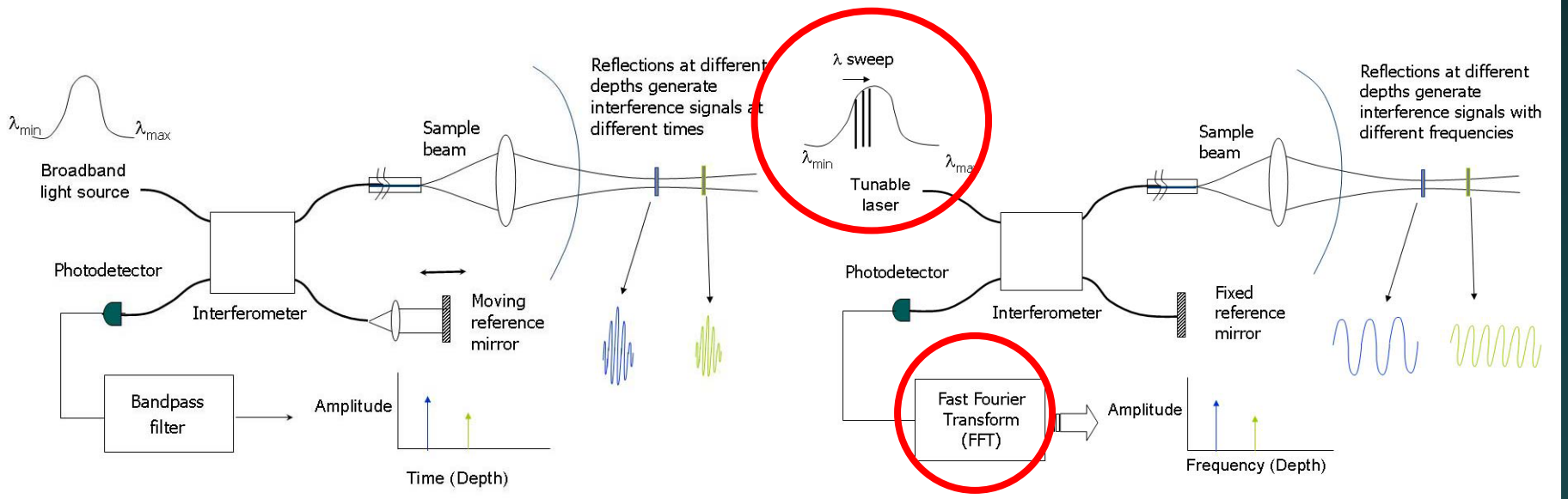

From GOODMAN Co.Ltd

OCT Imaging Systems

The First Generation

MGH OCT system

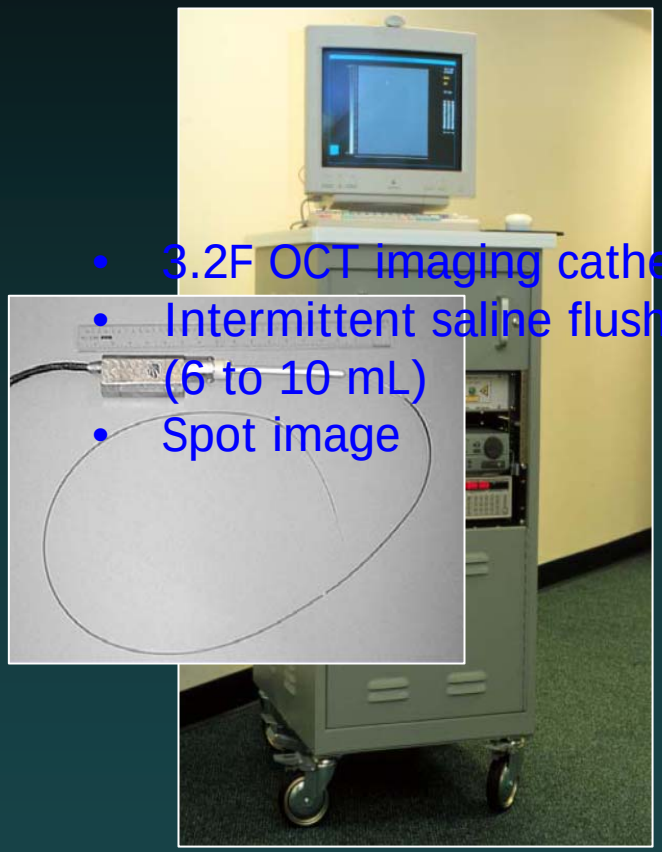

- 3.2F OCT imaging catheter
- Intermittent saline flush (6 to 10 mL)
- Spot image

LightLab system

- 1.4F OCT image wire
- Over-the–wire soft occlusion balloon catheter.
- Pullback image through continuous saline infusion
- in speed of 0.5ml/sec.

Optical source: Broadband light
Frame rate: 10-20/s
Pullback speed: 1.5~3 mm/s
Ranging of depth: 4-6 mm

OCT Imaging Systems

The Second Generation

MGH OCT system

- 2.6 F OD rapid exchange
- Helical scanning inner core
- 7 µm axial, 30 µm transverse resolutions
- 2-fold larger (5-6 mm) imaging range
- 100 fps; 512 A-lines/image

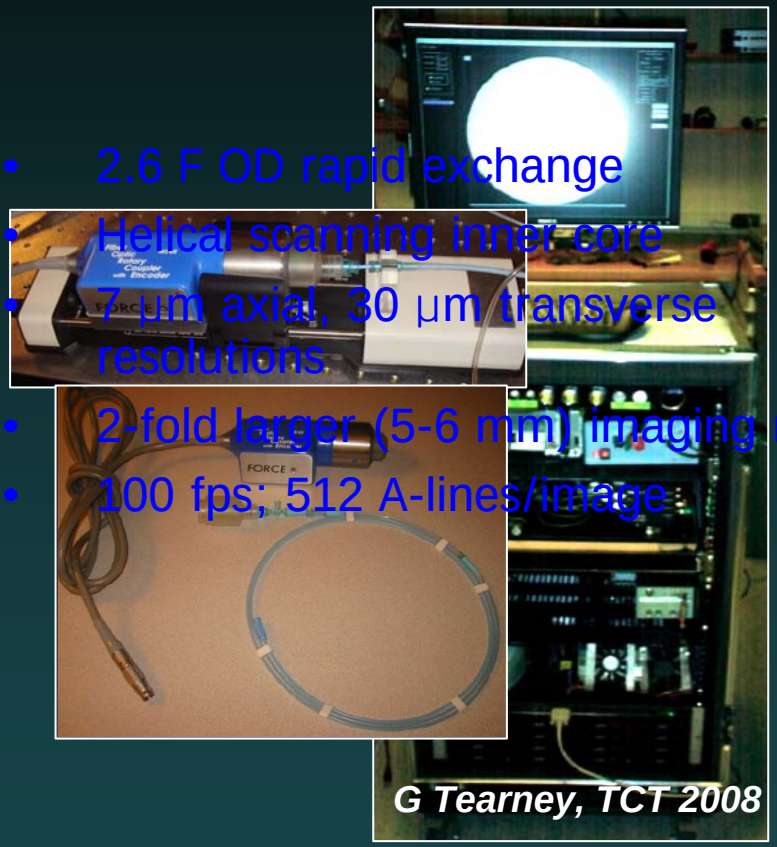

G Tearney, TCT 2008

LightLab system

- Guide flush and local flush designs
- R_x delivery
- Torque-wire based
- compatible with 6F guide

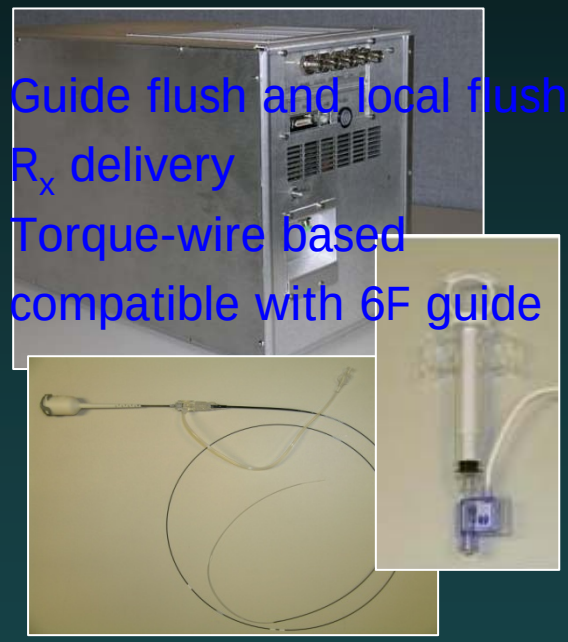

From GOODMAN Co.Ltd

Optical wavelength: Swept-frequency
Frame rate: 100-200/s
Pullback speed: 5~20 mm/s
Ranging of depth: 7-8 mm

Time-domain OCT vs Fourier-domain OCT



Next generation OCT has imaging acquisition speeds of 10 times faster and resolution 3 times greater.
It dose not require occlusion of the patient's blood flow during procedure.

From GOODMAN Co.Ltd

Case

First in human FD-OCT

Imaging conducted at Lahey Clinic (S. Waxman)

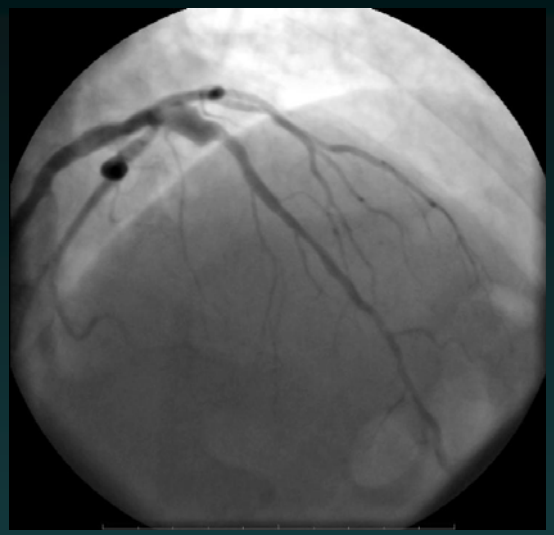

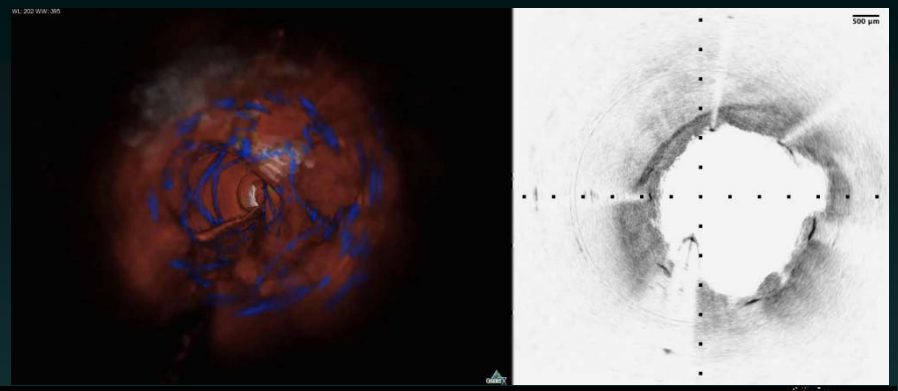

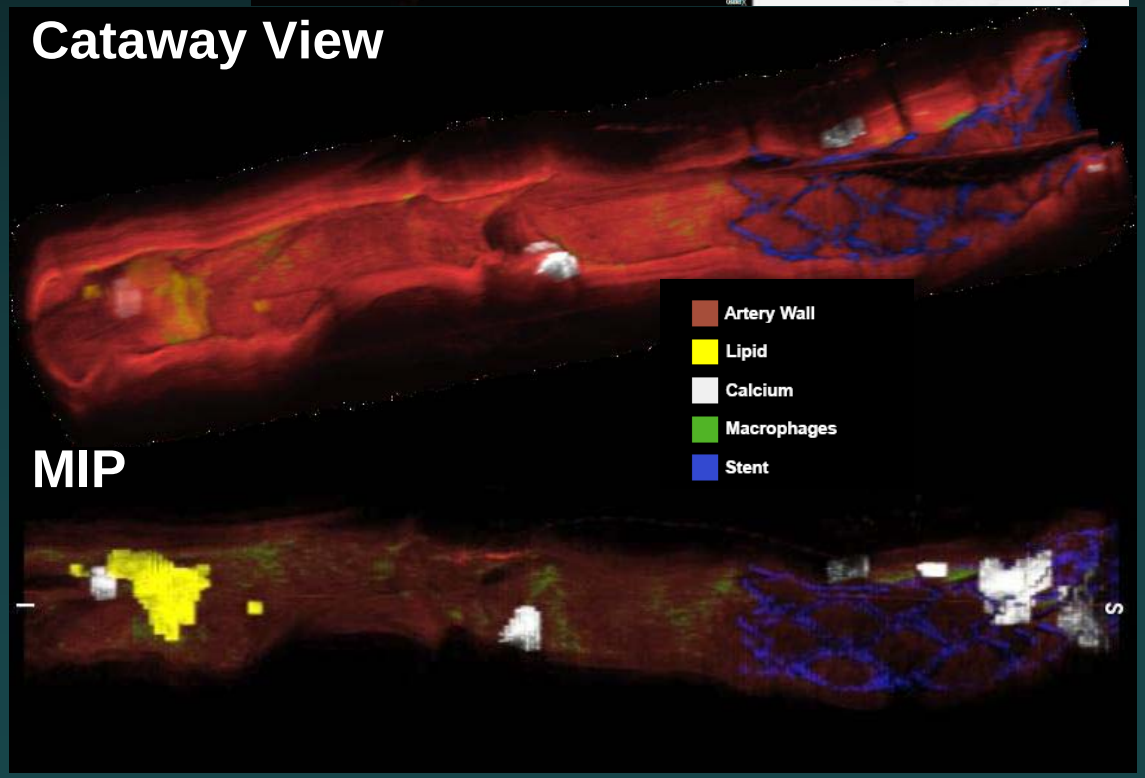

68 y/o male
Risk factors: hypertension, dyslipidemia
Chest pain on exertion
Positive stress test showing ST elevation in two leads
Prox. LAD stented with DES

G Tearney, TCT 2008

Currently Evolving OCT

Toward complete lesion characterization with OCT

New platform modality and combine with other modality

Morphological	Lesion size Lesion shape % stenosis Cap thickness	Backscatter / Gray Scale
Biochemical composition	Lipid, collagen, proteoglycans, calcium	Spectroscopy Polarization
Physiological	Flow disturbances CFR, FFR	Doppler
Mechanical	Plaque stiffness	Elastography

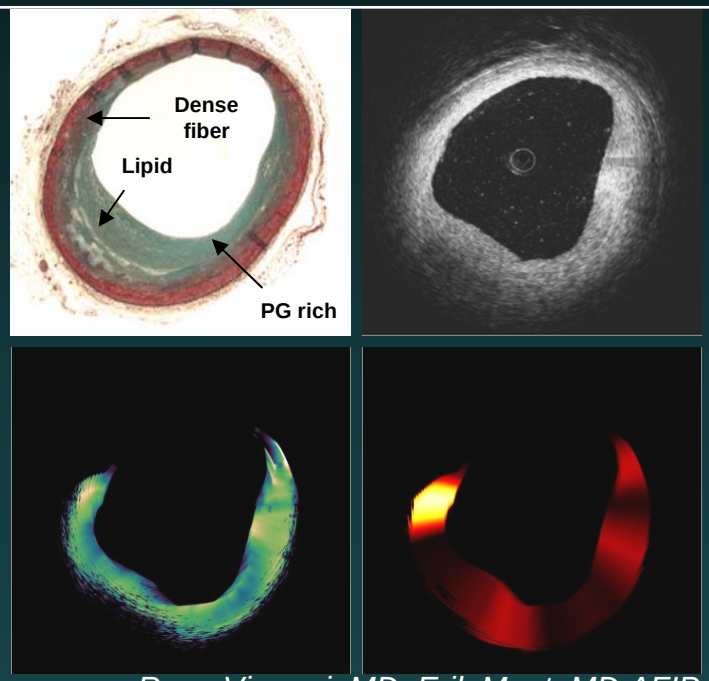

Renu Virmani, MD, Erik Mont, MD AFIP

Take Home Massages

OCT is feasible as an intravascular imaging tool and it could be conducted safely in cath Lab.

OCT has a high resolution, it could assess the tissue characterization more accurately than IVUS.
OCT has a potential benefit to identify vulnerable plaques and also provides superficial information of the vessel during and after PCI.

OCT has major limitations in need of blood clear zone and low penetrating depth. Evolving OCT image moves closer to becoming a powerful diagnostic tool that will provide new insights into the etiology and treatment of coronary artery disease.