High-Risk Plaques Evaluated by Multi-Modal Images: Attenuated Plaques, Echolucent Plaques, and Calcified Nodules

Gary S Mintz, MD

Cardiovascular Research Foundation

New York City, NY

OCT vs Histology

Fibrous

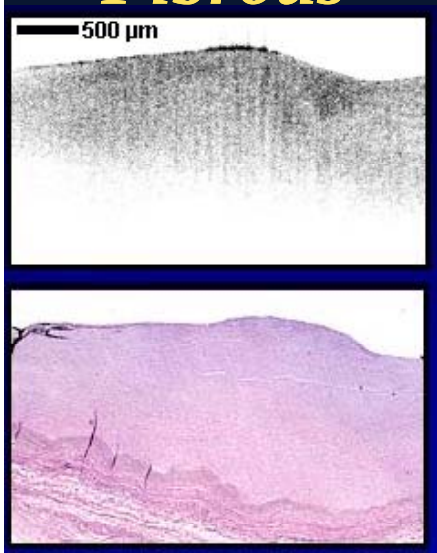

- *High reflectivity*
- *Homogenous*
- *Finely textured*

Lipid-rich



- *Low reflectivity*
- *Homogenous*
- *Diffuse margins*

Calcific

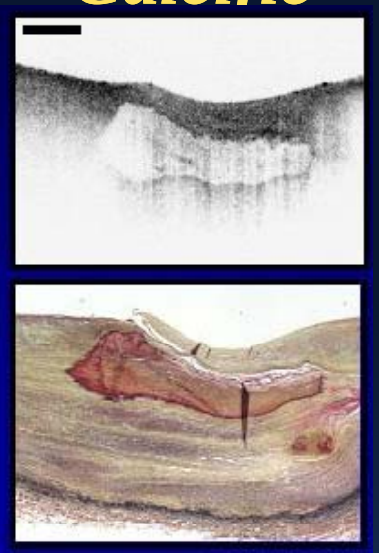

- *Low reflectivity*
- *Inhomogenous*
- *Sharp margins*

Macrophages

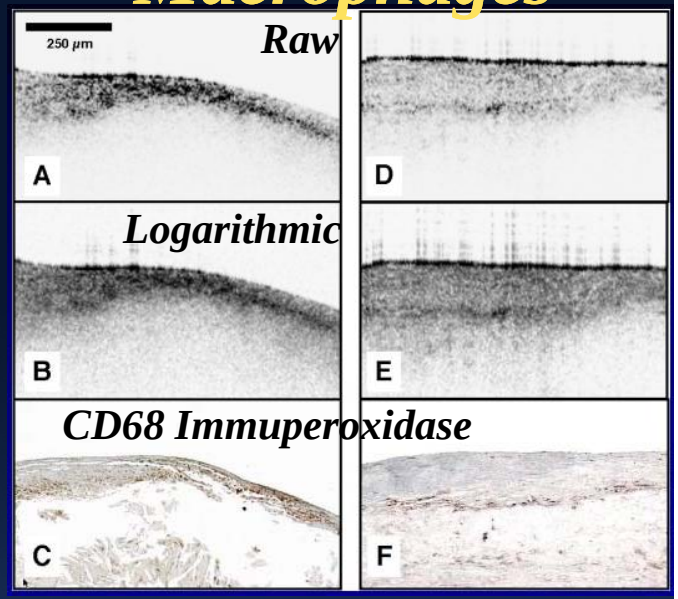

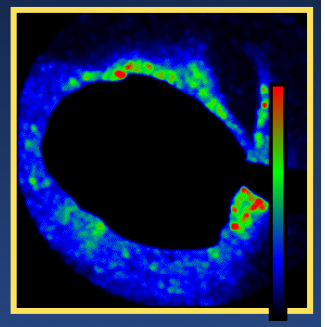

	Sensitivity	Specificity	PPV	NPV
Fibrous	.87	.97	.88	.96
Calcific	.95	1.0	1.0	.95
Lipid	.92	.94	.81	.97

Interobserver k = 0.88; Intraobserver k = 0.91

Yabushita et al. Circulation 2002;106:1640-5
Tearney et al. Circulation 2003;107:113-9

NIR Spectroscopy can identify the chemical composition of unknown substances and distinguish cholesterol from collagen. ROC Analysis of Validation of NIR Spectroscopy in 51 Autopsy Hearts (algorithm for detection of confluent [>0.2mm thick and >60°] and relatively superficial necrotic core [overlying mean fibrous cap thickness <0.45microns])

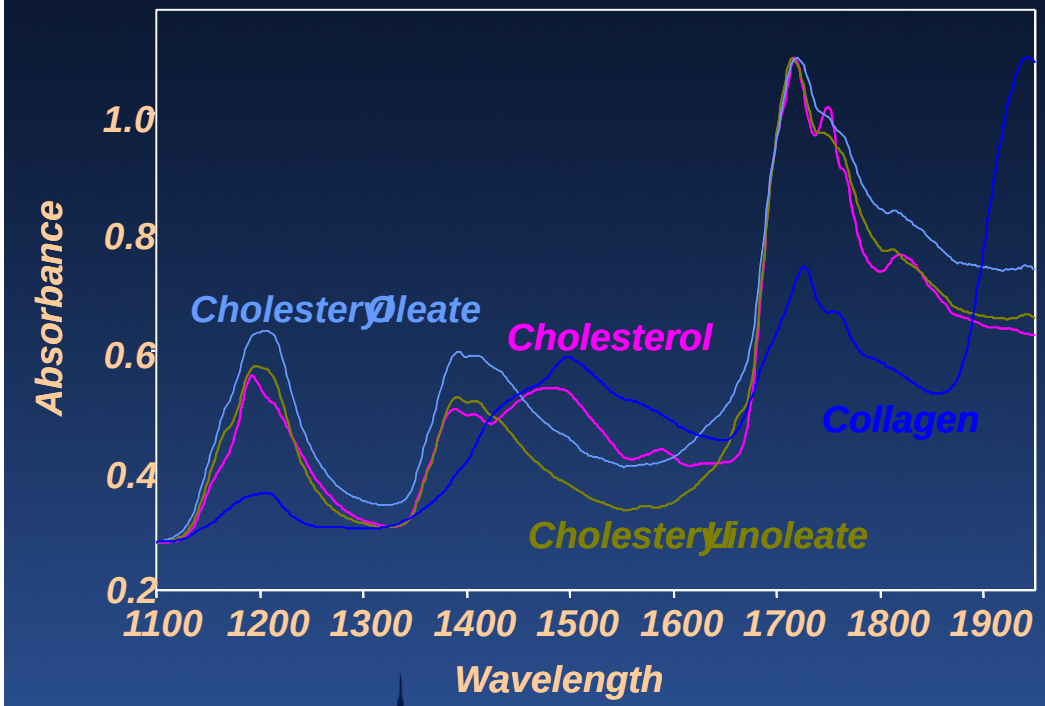

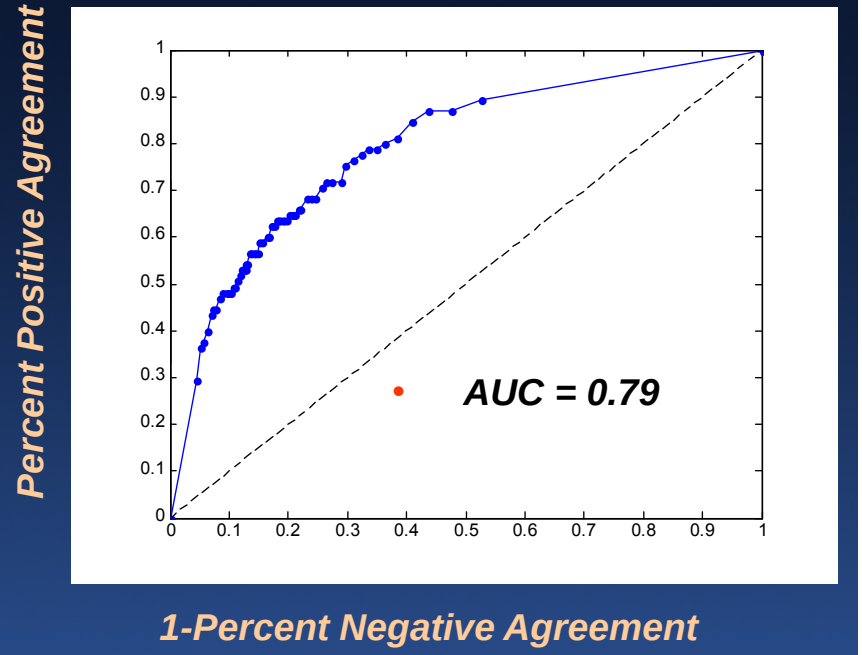

LipiScan vs Histology

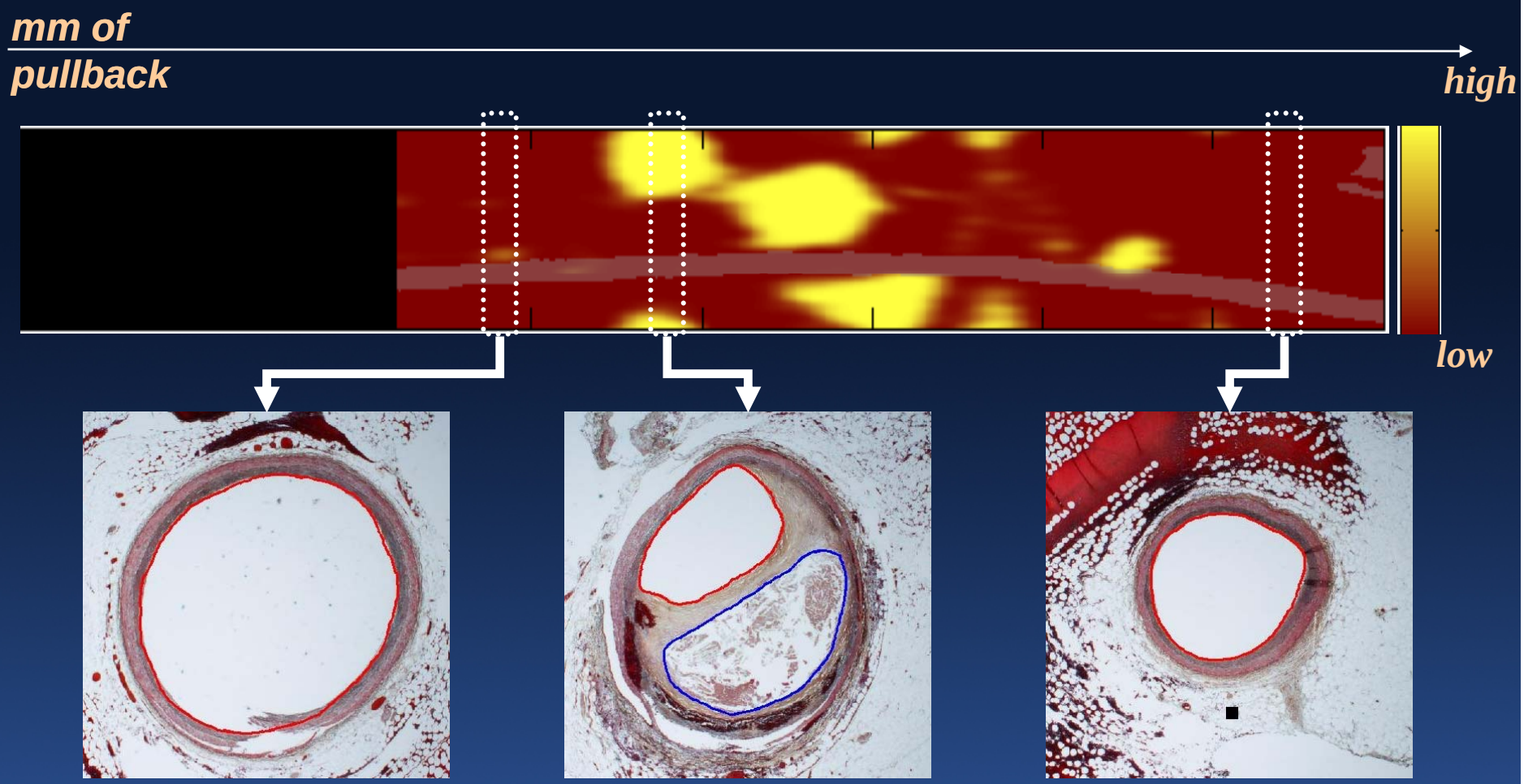

NIR Spectroscopy Validated Against Histology

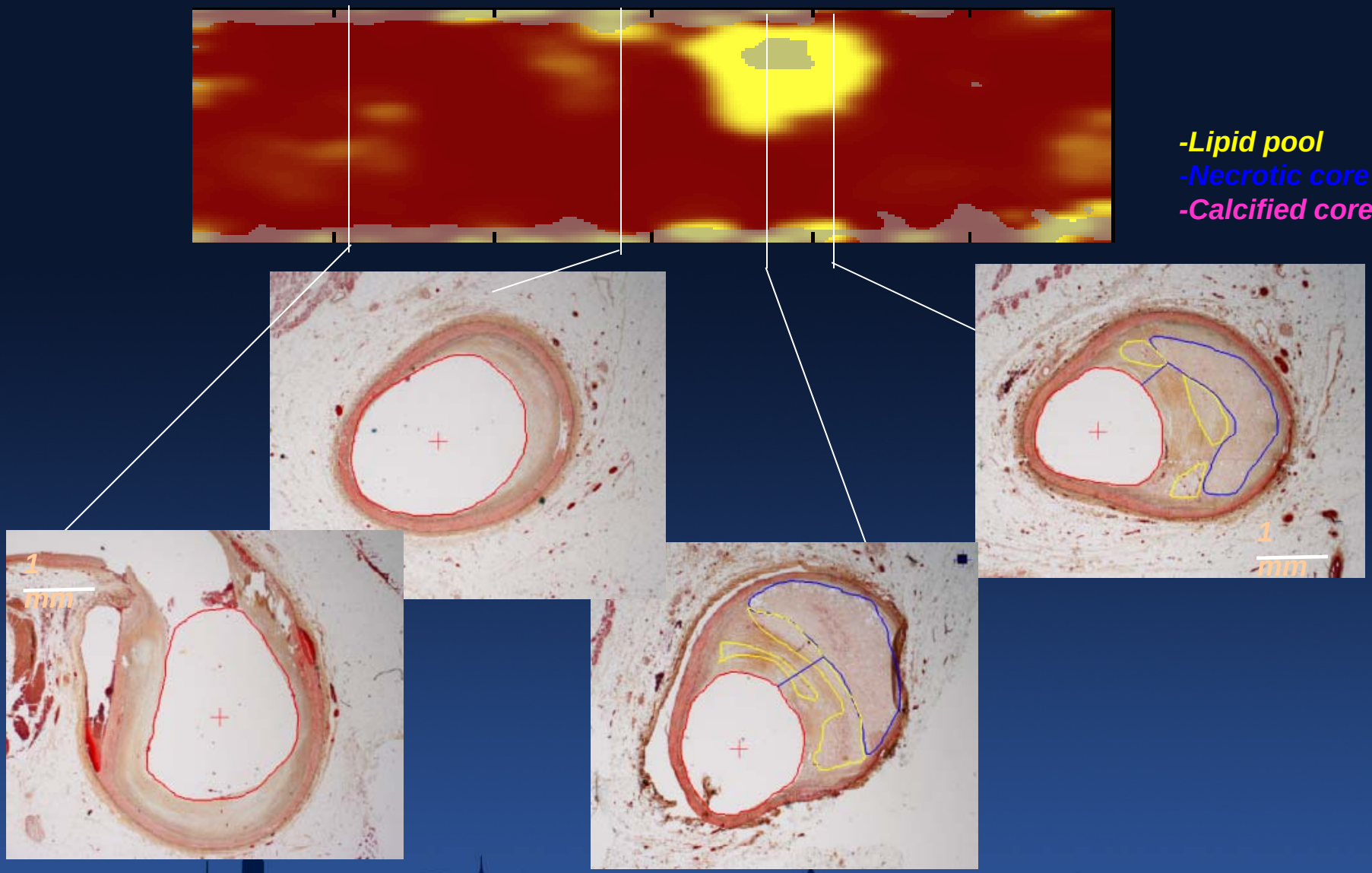

Attenuated Plaque

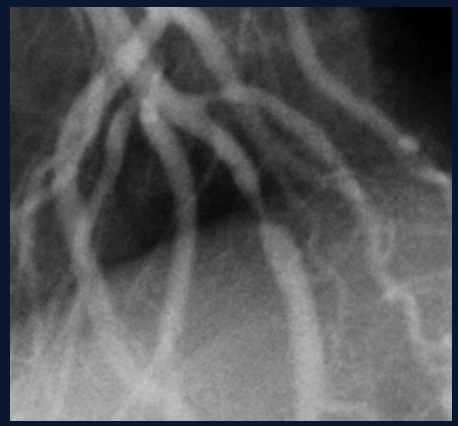

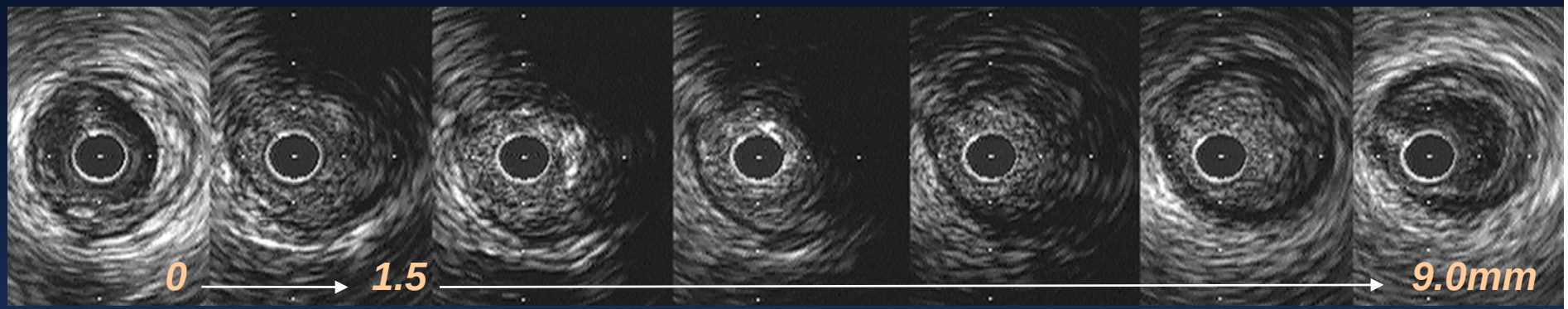

- *Attenuated plaques were observed in 39.6% of STEMI, 17.6% of NSTEMI, and 0% of stable angina.*
- *Attenuate plaques were associated with more fibroatheromas and a larger necrotic core (on VH-IVUS).*
- *In ACS patients with attenuated plaques (1) the level of CRP was higher, (2) angiographic thrombus and initial coronary flow <TIMI 2 were more common, and (3) no-reflow or flow deterioration post-PCI were more common.*

Lee et al. JACC Cardiovasc Interv. 2009;2:65-72
Wu et al, Am J Cardiol 2010;105:48-53

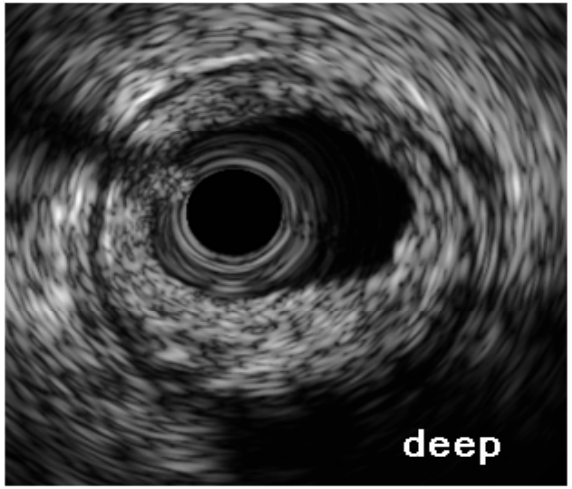

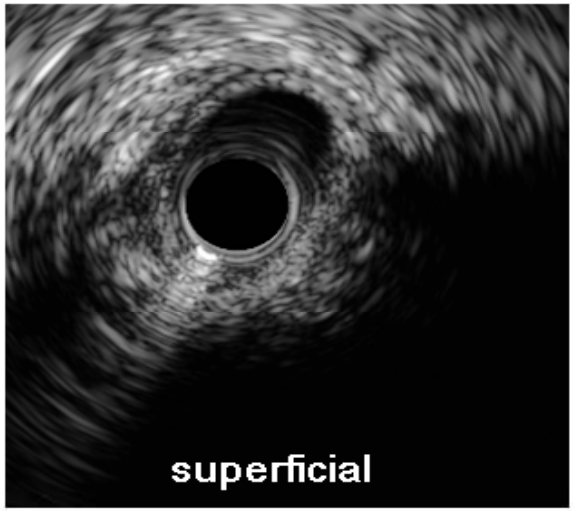

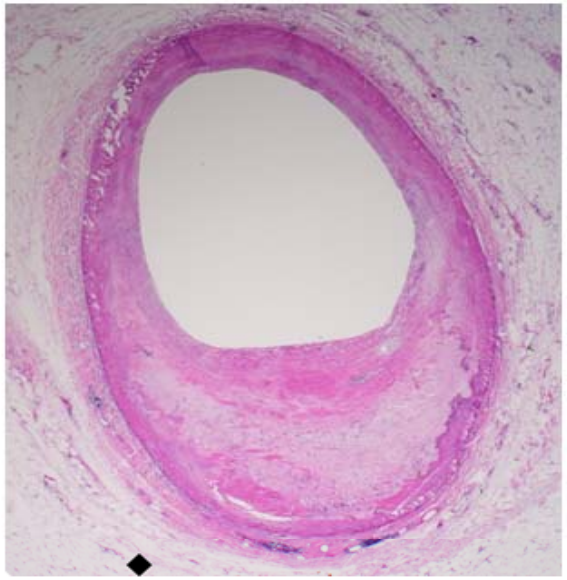

Pathological intimal thickening

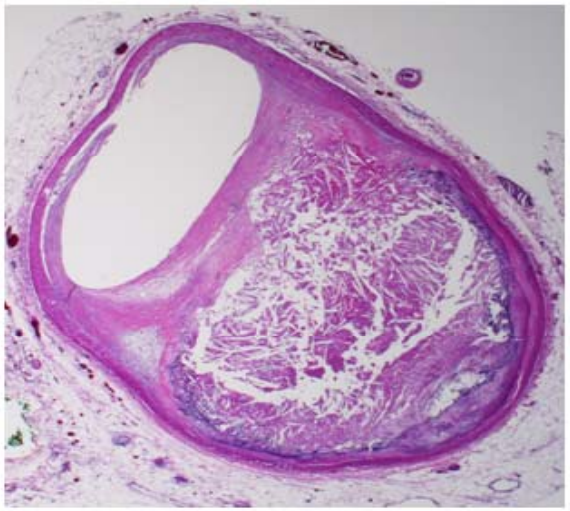

Late fibroatheroma

Numerous studies have shown a relationship between VH-IVUS plaque composition and post-PCI distal embolization

vs Nectoric Core

- Kawaguchi et al. J Am Coll Cardiol. 2007;50:1641-6
  - ST re-elevation in 71 pts with STEMI
- Kawamoto et al. J Am Coll Cardiol. 2007;50:1635-40
  - Doppler FloWire high intensity transit signals in 44 pts undergoing elective stenting resulting in poor recovery of CVFR
- Park et al. VH Summit 2007 (unpublished)
  - Largest NC independent predictor of CK-MB release (n=332)
- Hong et al. J Am Coll Cardiol Img, 2009;2:458-468
  - Troponin post elective stenting in 80 pts (29 stable and 51 unstable angina)
- Bose et al. Basic Res Cardiol 2008;103:587-97
  - CK and TnI in 55 pts undergoing direct stenting. Patients in the 4th quartile of NC volume had a particularly high increase in biomarkers.
- Higashikuni et al. Circ J 2008; 72: 1235-41
  - No reflow in 49 pts with ACS undergoing PCI
- Hong et al. Eur Heart J, in press
  - No reflow in 190 pts with ACS undergoing stenting

vs Fibrotic or Fibrofatty Plaque

- *Bae et al. Heart. 2008;94:1559-64.*
  - *Multivariate analysis revealed that fibrofatty volume over the entire lesion length was the only independent predictor for slow flow during primary PCI in 57 pts with STEMI*
- *Nakamura et al. J Interv Cardiol. 2007;20:335-9*
  - *“Marble"-like image, mainly consisting of fibro-fatty and fibrous plaque was associated with angiographic no-reflow in 50 STEMI pts undergoing primary PCI*

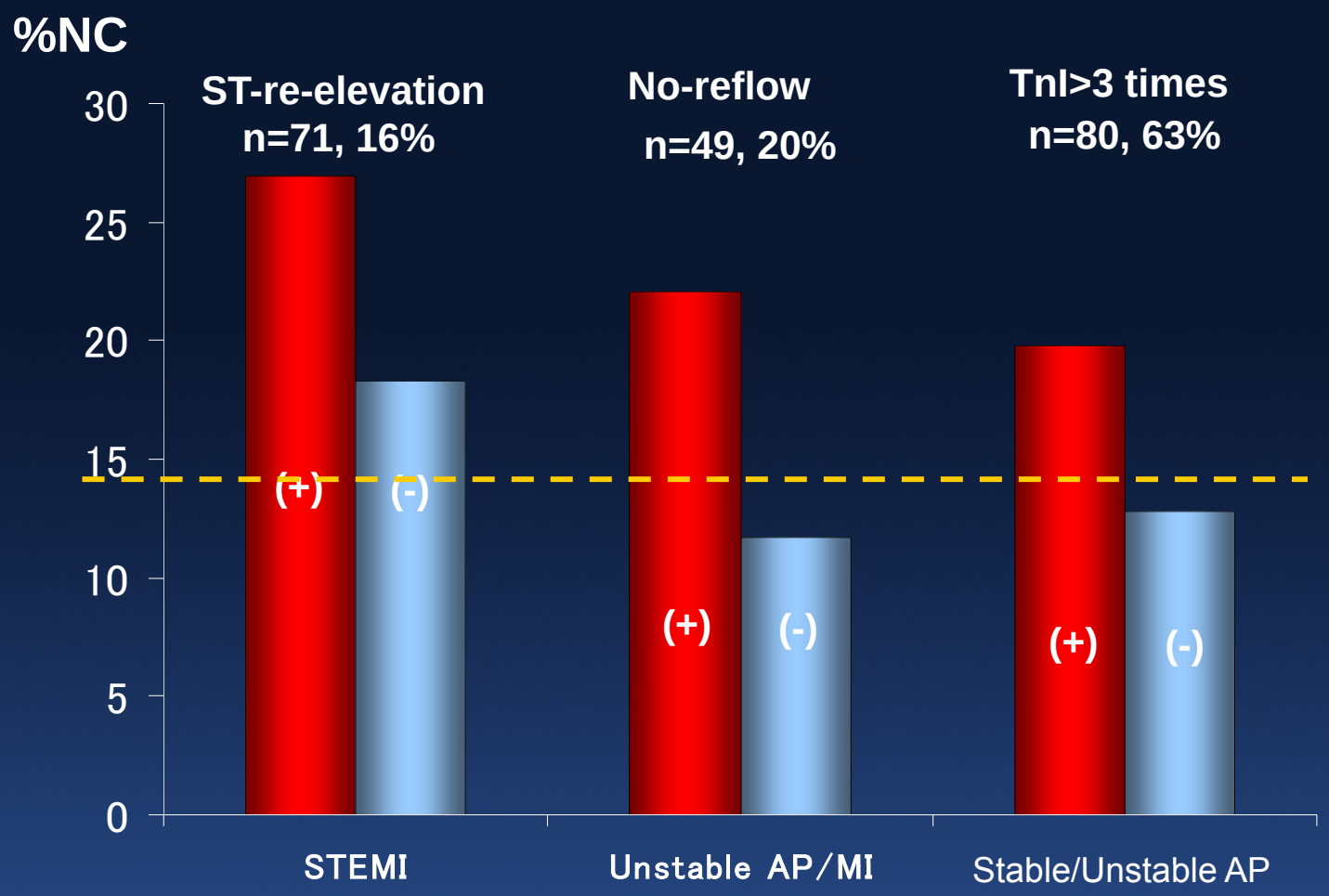

Kawaguchi et al. J Am Coll Cardiol. 2007;50:1641-6.

Hong et al. JACC Cardiovasc Imaging. 2009;2:458-68

Higashikuni et al. Circ J 2008;72:1235-41

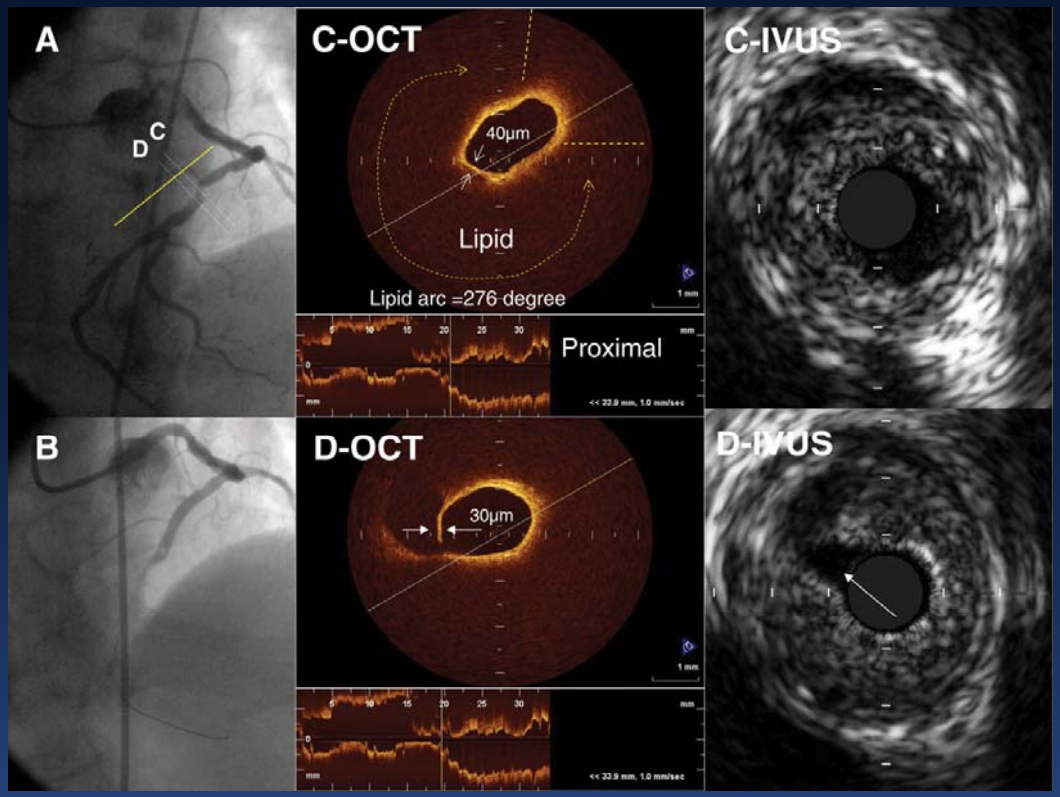

- *Patients with NSTE ACS who underwent OCT and successful emergent primary stenting were divided into two groups on the basis of post-stent TIMI flow: no-reflow group (n = 14) and reflow group (n = 69).*
- *Thin-cap fibroatheroma were more frequently observed in the no-reflow group than in the reflow group (50% vs. 16%, P = 0.005)*
- *The frequency of the no-reflow phenomenon increased according to the size of the lipid arc in the culprit plaque.*
- *Final TIMI blush grade also deteriorated according to the increase in the lipid arc.*

Tanaka, A. et al. Eur Heart J 2009;30:1348-1355

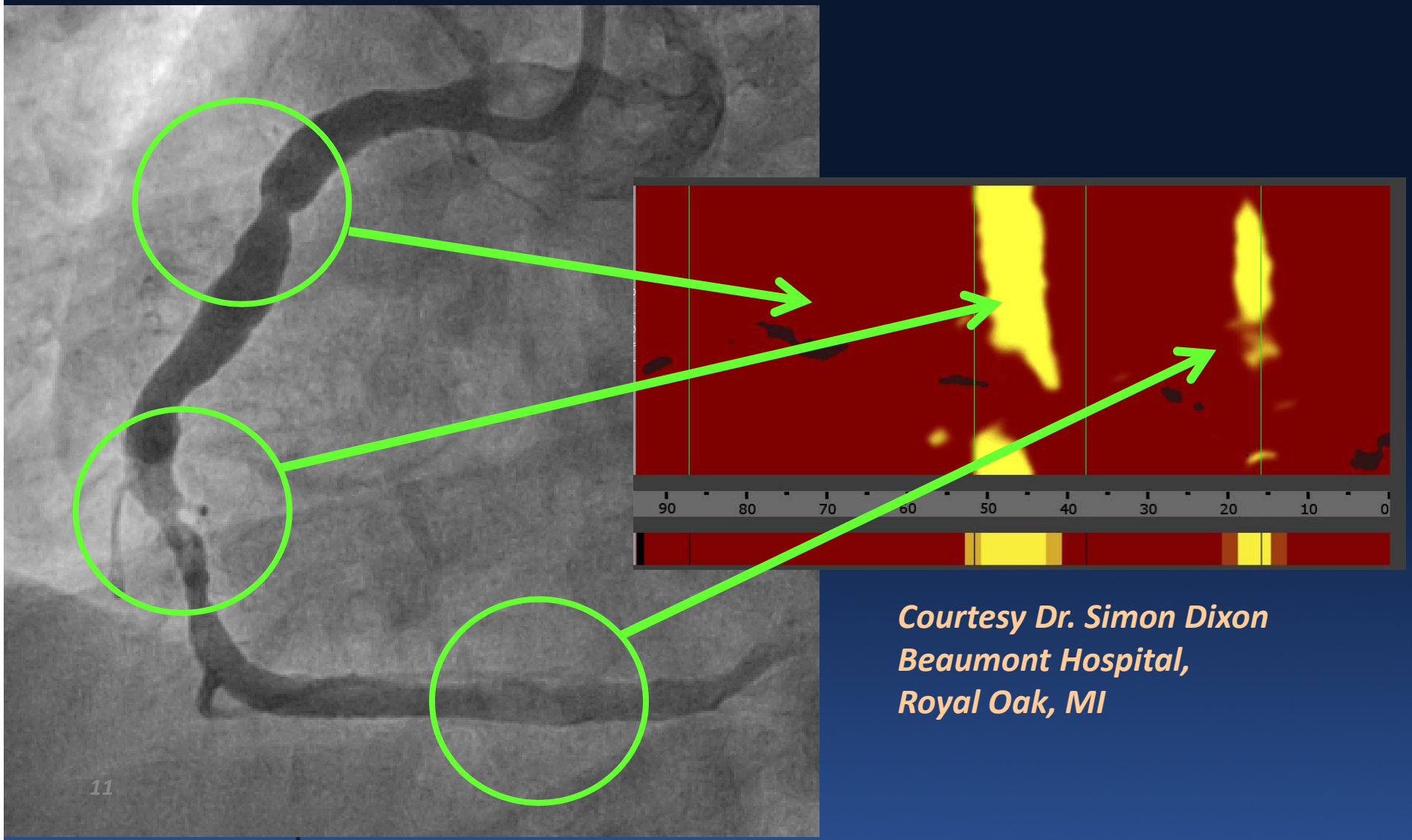

Courtesy Dr. Simon Dixon
Beaumont Hospital,
Royal Oak, MI

Goldstein et al, JACC Cardiovasc Imaging. 2009;2:1420-4

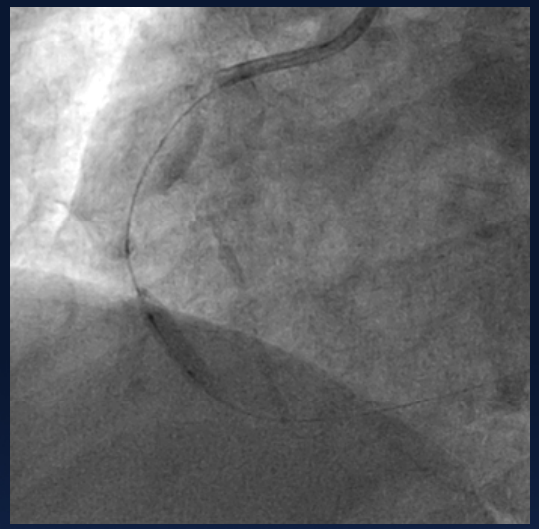

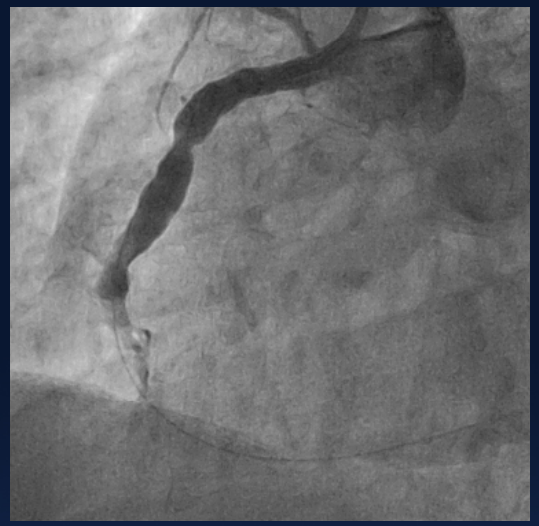

Goldstein et al, JACC Cardiovasc Imaging. 2009;2:1420-4

Predictors of No-Flow

	Grayscale IVUS	VH IVUS	OCT	NIR Spectroscopy	MDCT
Necrotic Core Burden	Attenuated Plaque	Necrotic Core	Lipidic Plaque	Lipid Core Burden Index	Low Hounsfield Unit

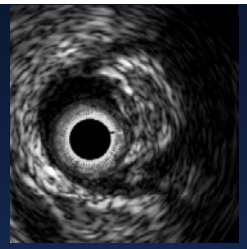
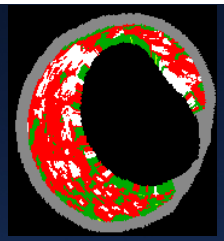
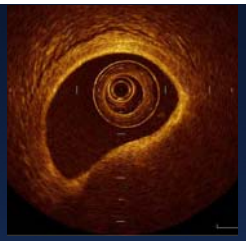

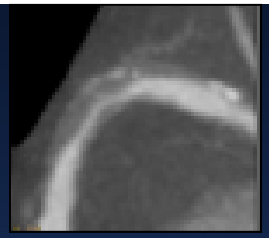

Predictor of No-reflow in HORIZONS-AMI

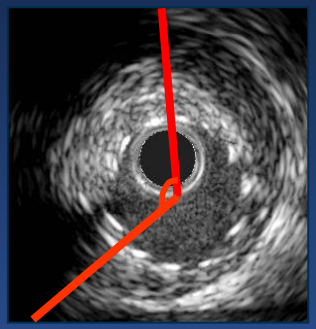

	Odds Ratio	P-value
Mean Attenuation Score ≥2	6.6 (2.7-16.2)	<0.001
Pre Angio Thrombus	9.1 (1.2-70.7)	0.034

Wu et al, JACC Cardiovascular Interventions, in press

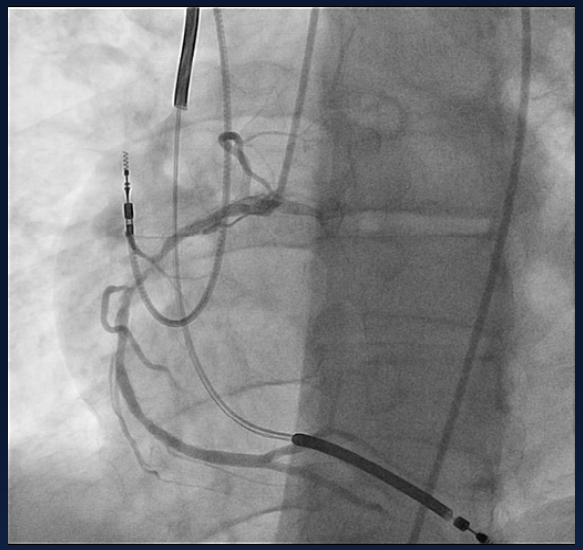

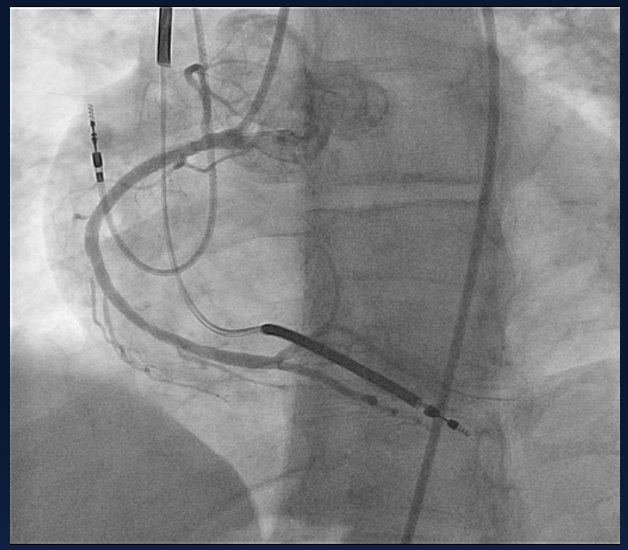

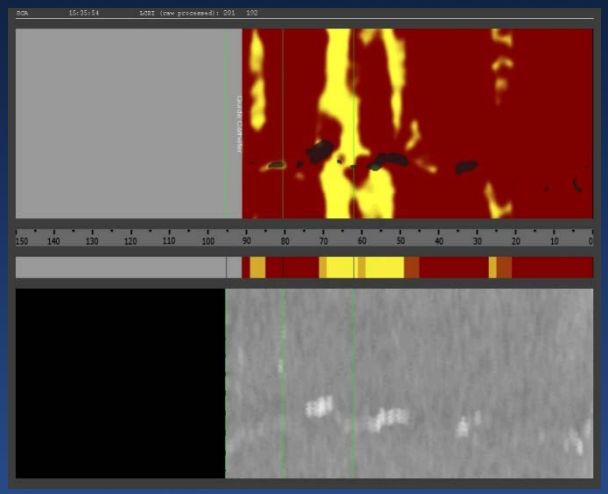

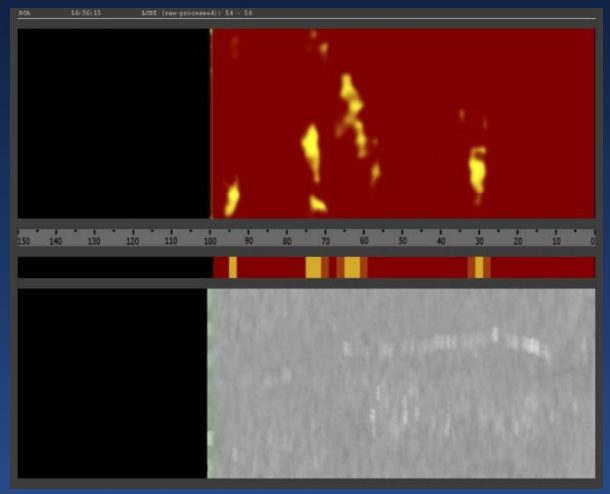

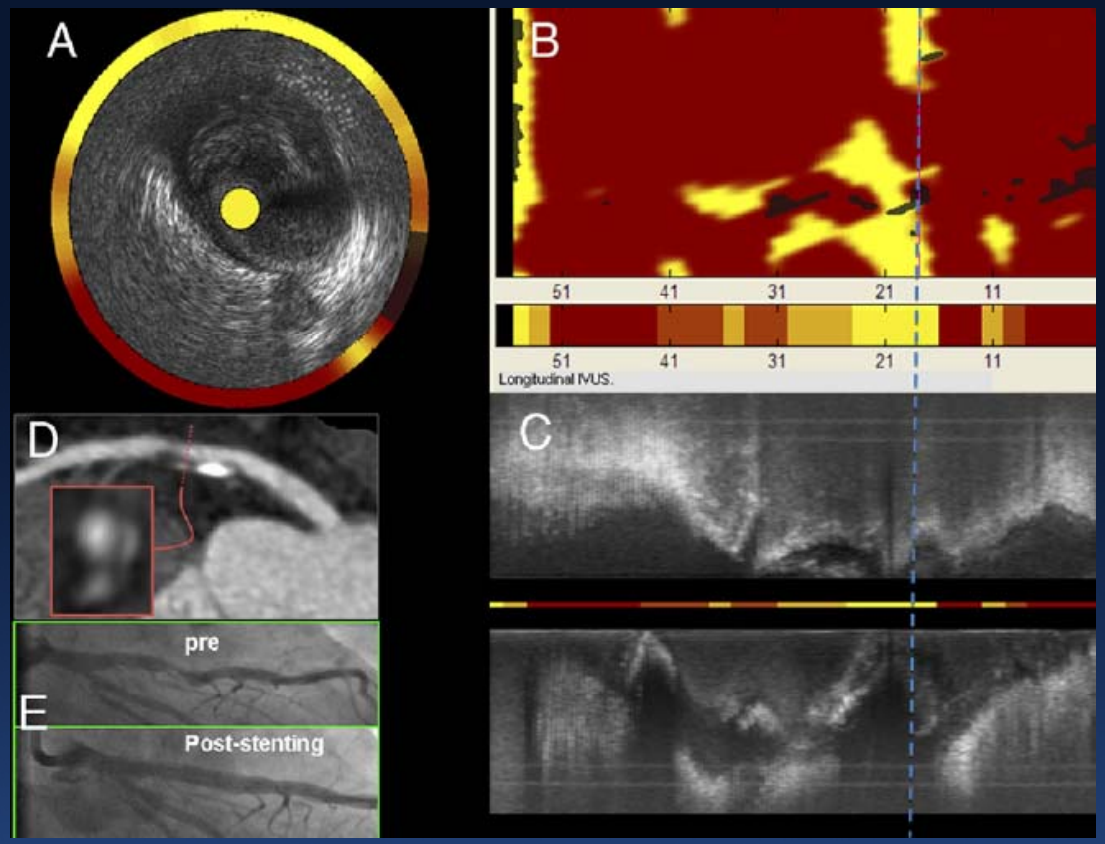

Lipiscan IVUS documented a 270° napkin ring LCP. Direct stenting resulted in a peri-procedural MI.

Schultz et al. J Am Coll Cardiol 2010;56;314.

COLOR Registry
Lipid core plaque and post-stent MI



COLOR Registry
Lipid core plaque and post-stent MI

HR-LCP: LCBI >600

★ **Post PCI MI**

Association of NIRS-Detected LCP with Peri-Procedural MI (MB >3x NL)

65 COLOR Patients with Normal Baseline Enzymes

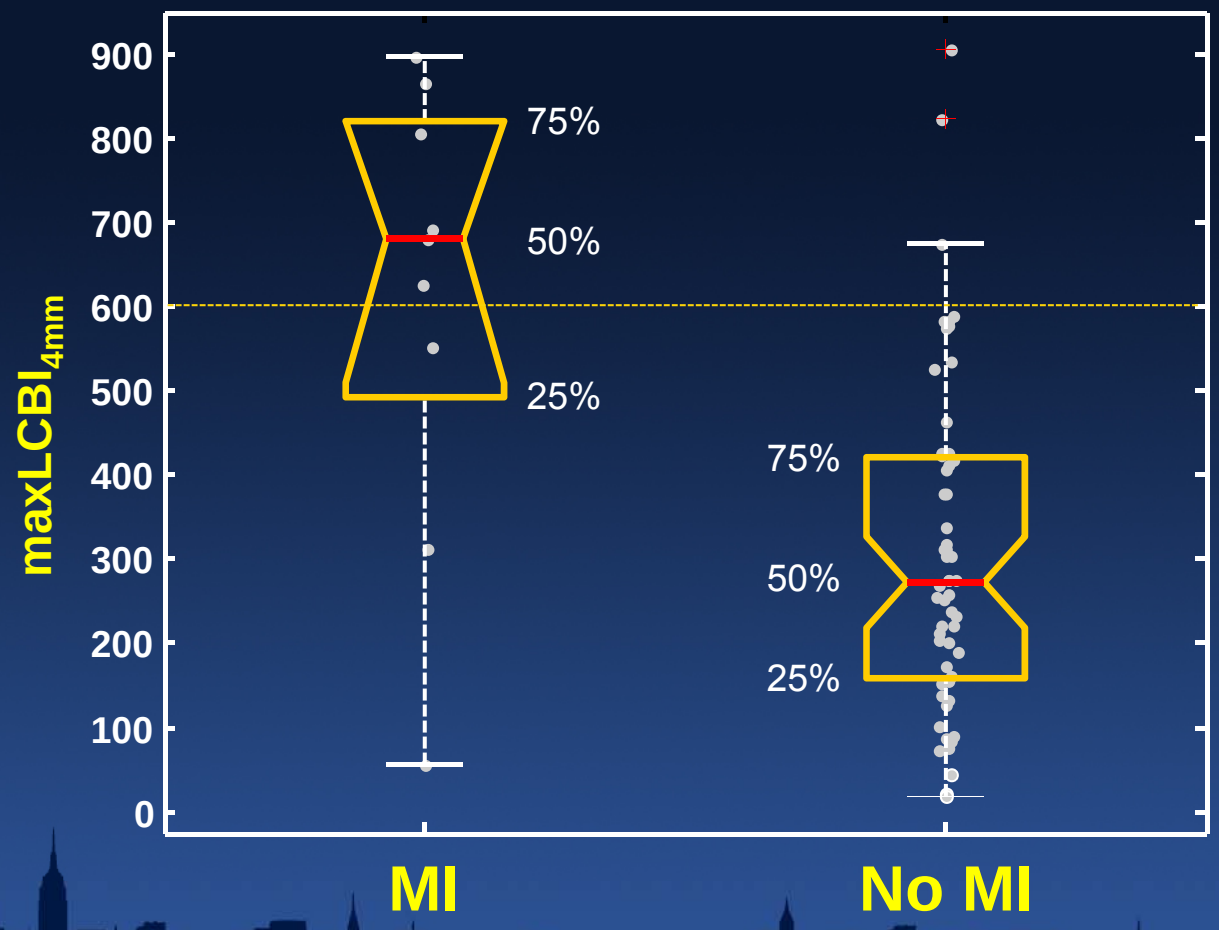

Systematic Definition of HR-LCP

Maximum 4mm subsegment LCBI ($mxLCBI_{4mm}$)

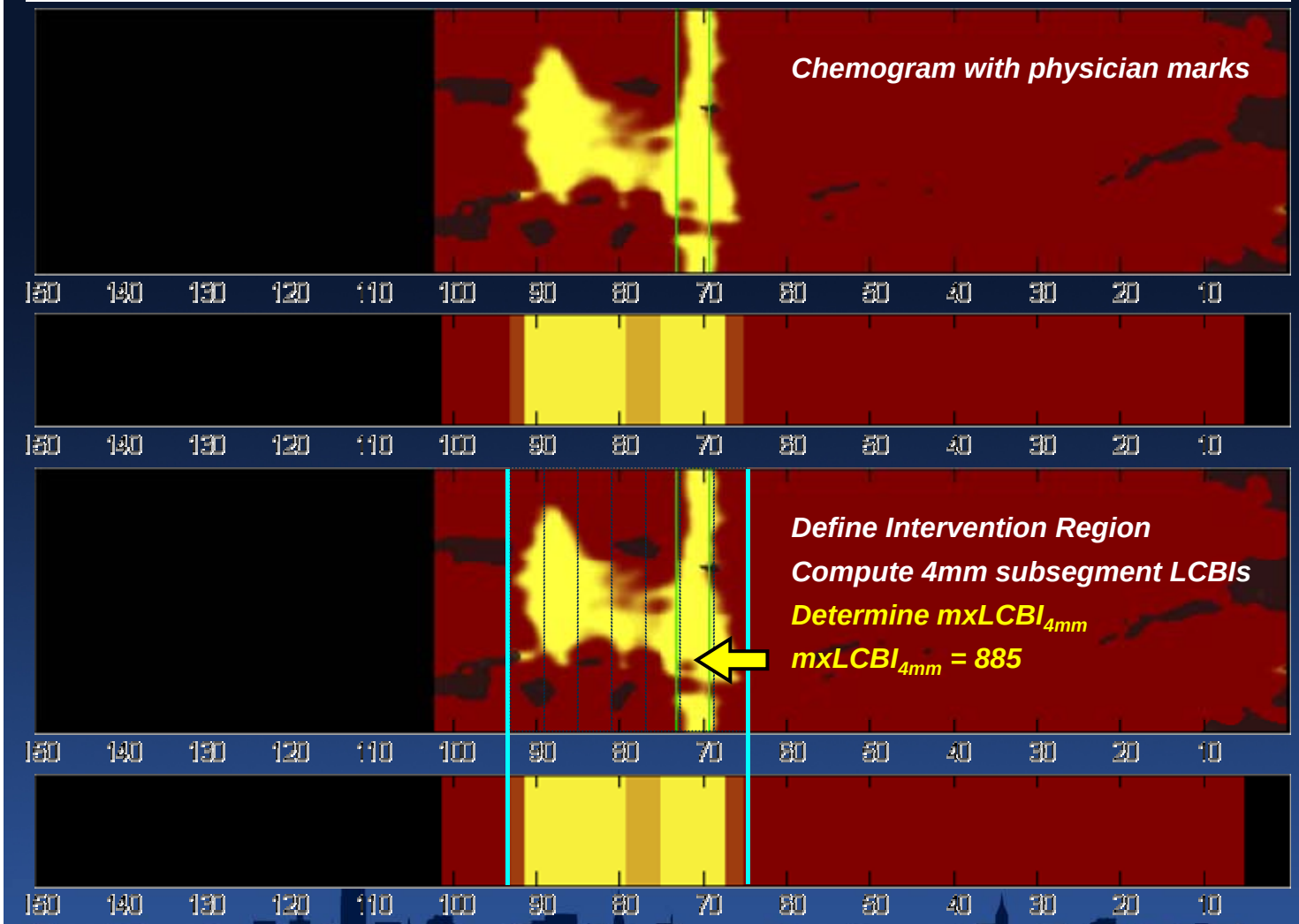

$mxLCBI_{4mm}$ >600

High-risk LCP

CANARY Pilot

Coronary Assessment by Near-infrared of Atherosclerotic Rupture-prone Yellow

Prospective, multicenter, randomized, non-blinded trial in 50 HR-LCP native coronary artery lesions undergoing PCI

Lipiscan IVUS NIRS assessment ▸ Randomization of lesions with $mxLCBI_{4mm}$ >600 to distal protection with the BSC FilterWire EZ vs. control

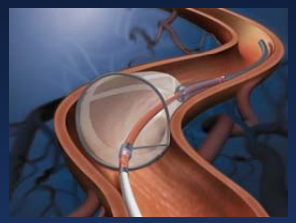

5 -10 sites in the US; Sponsor: InfraReDx

Study Endpoints and Objectives:

1. Primary endpoint: Peri-procedural MI (troponin >3xULN)
2. Powered for a reduction from 56% to 12% (2-sided α=0.05)
3. Meant to inform a pivotal randomized trial

Attenuated Plaque	Echolucent Plaque	Calcified Plaque

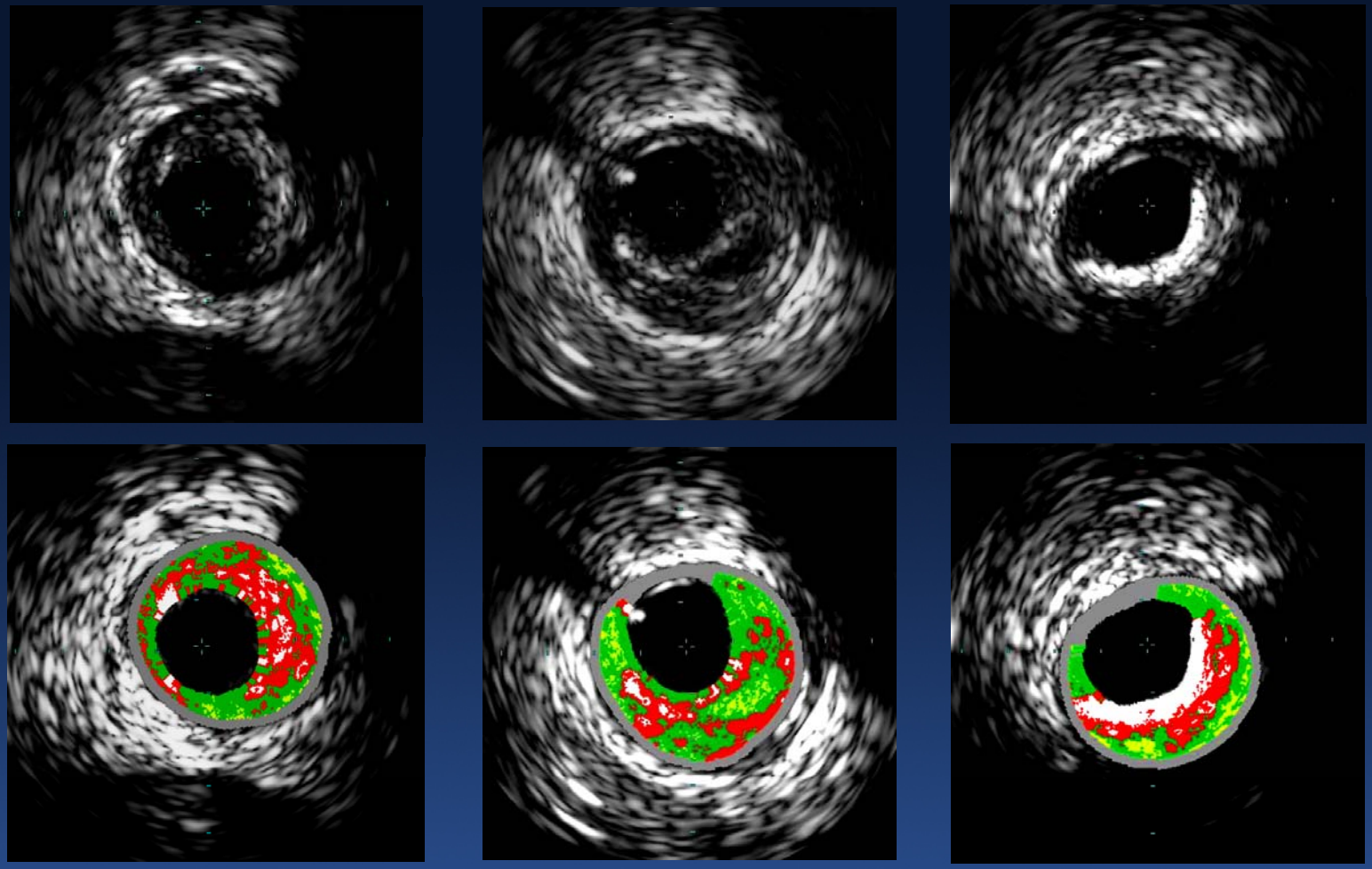

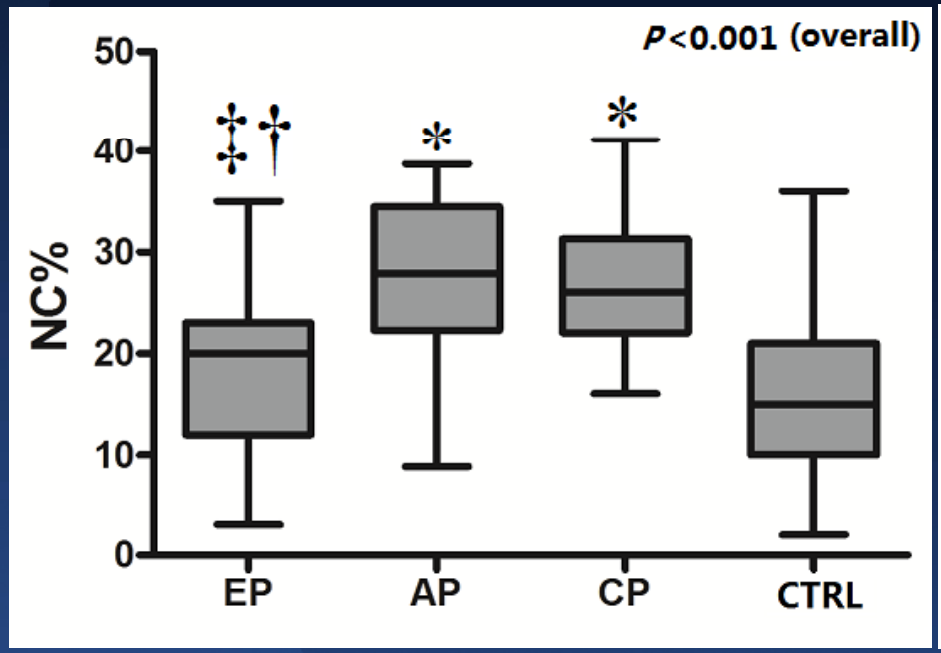

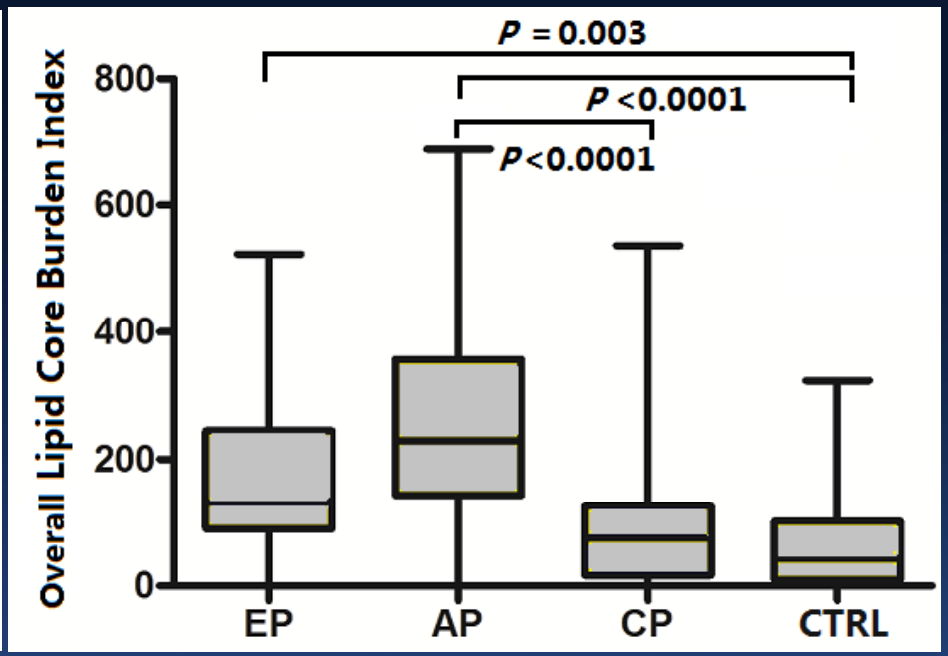

"Vulnerable Plaque" = thrombosis-prone plaque and plaque with a high probability of undergoing rapid progression

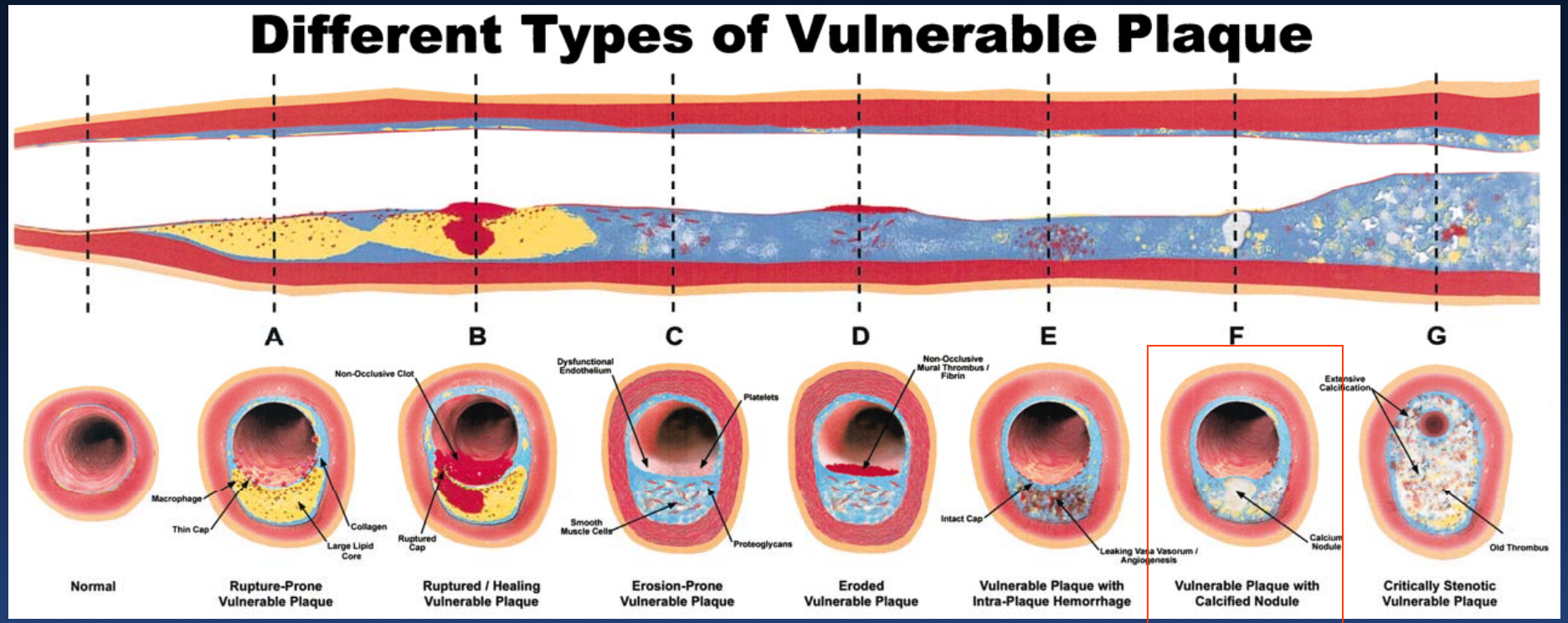

5% of ACS culprit lesions

Naghavi et al. Circulation 2003;108:1664-72

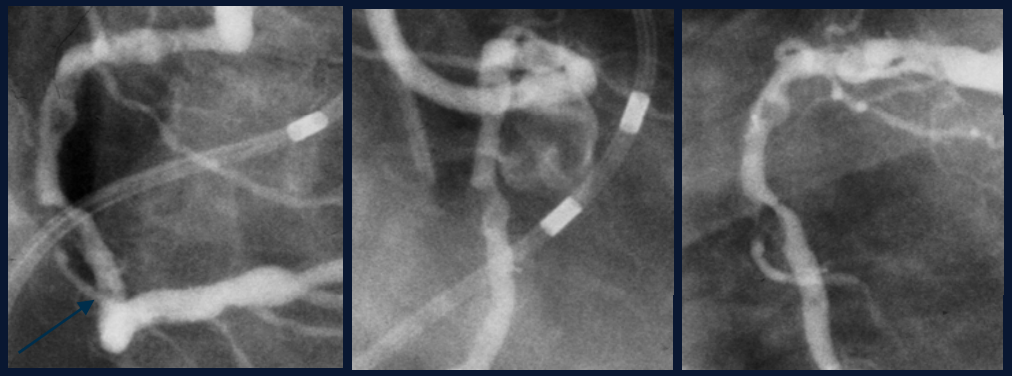

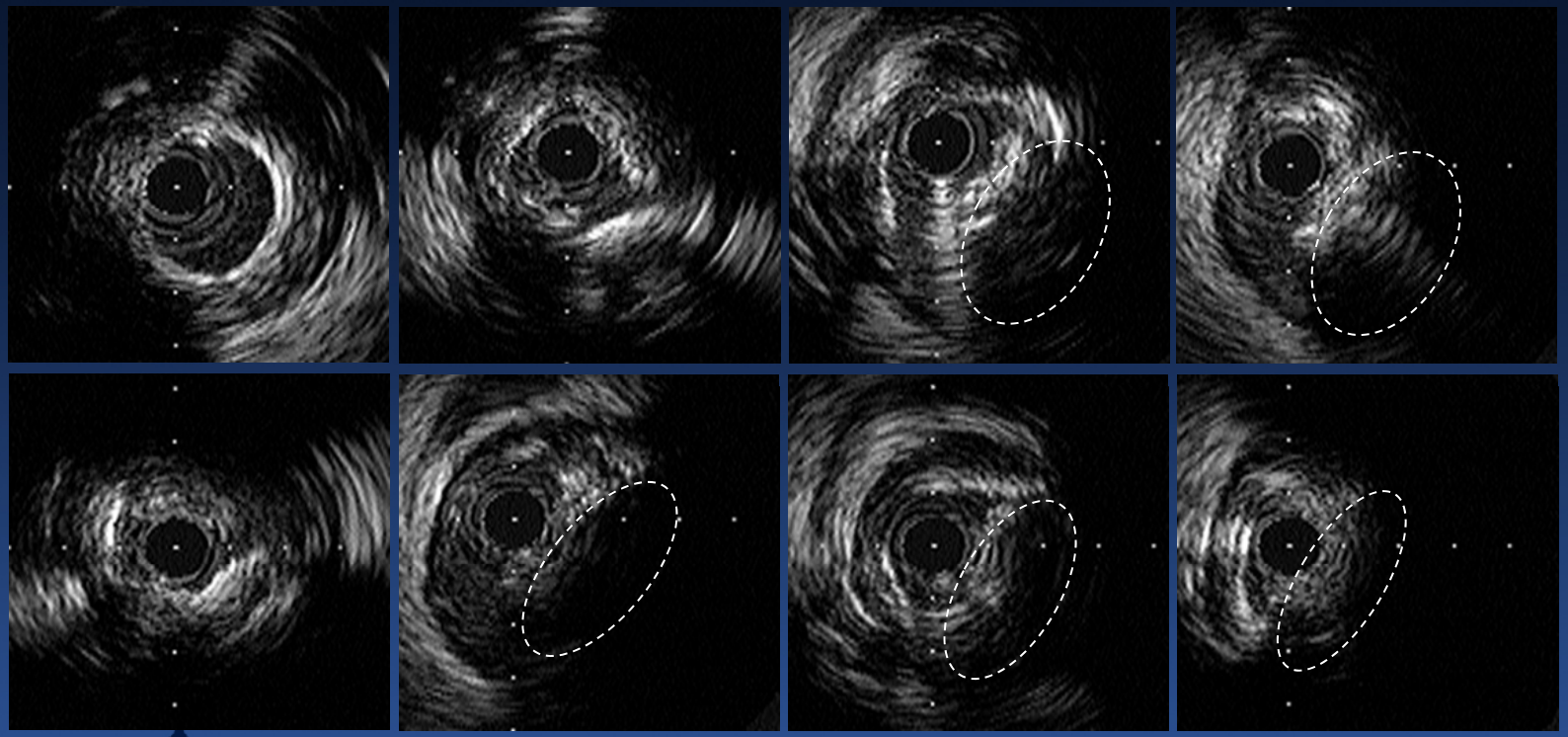

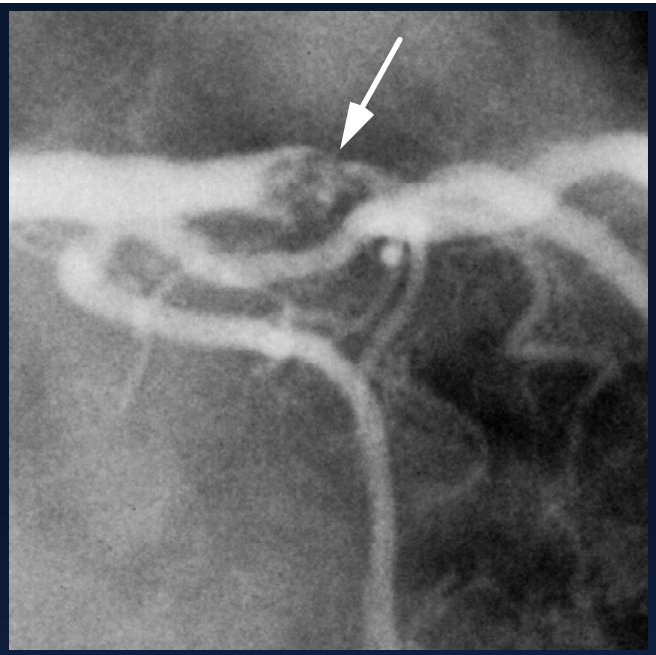

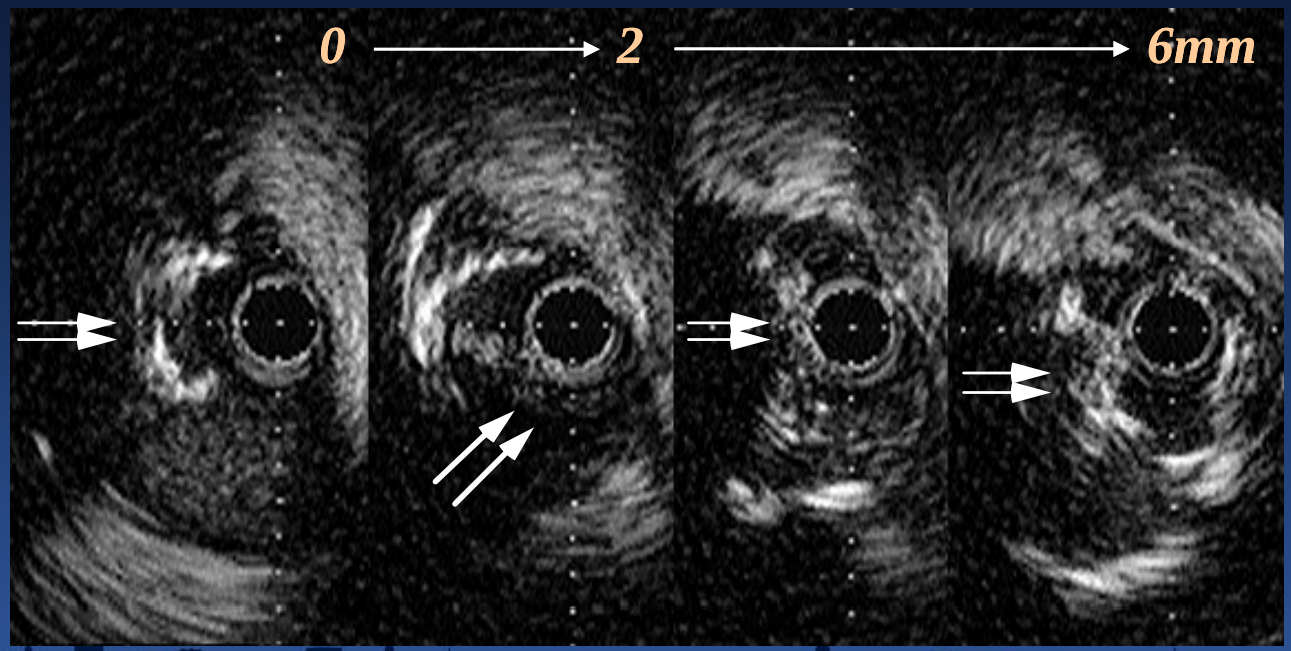

IVUS detected calcification in 285/856 slices of 41 coronary arteries frames; 17 (6.0%) were calcified nodules, and 268 (94.0%) were non-nodular calcium by histopathology.

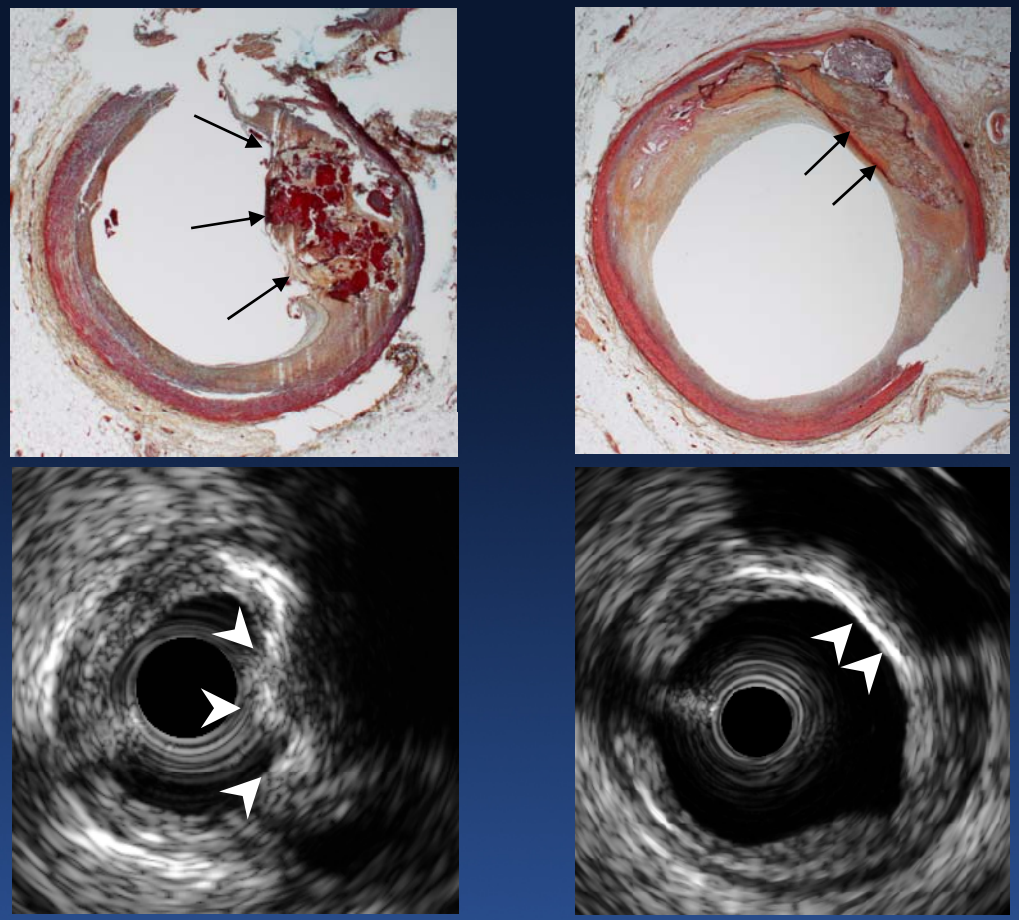

Lee et al. Circulation (in press)

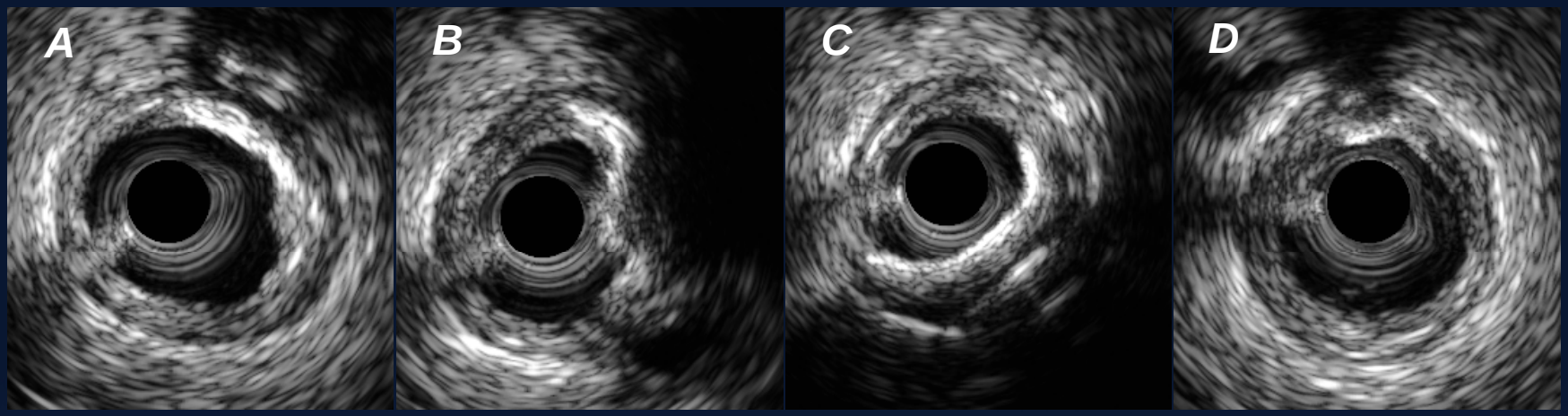

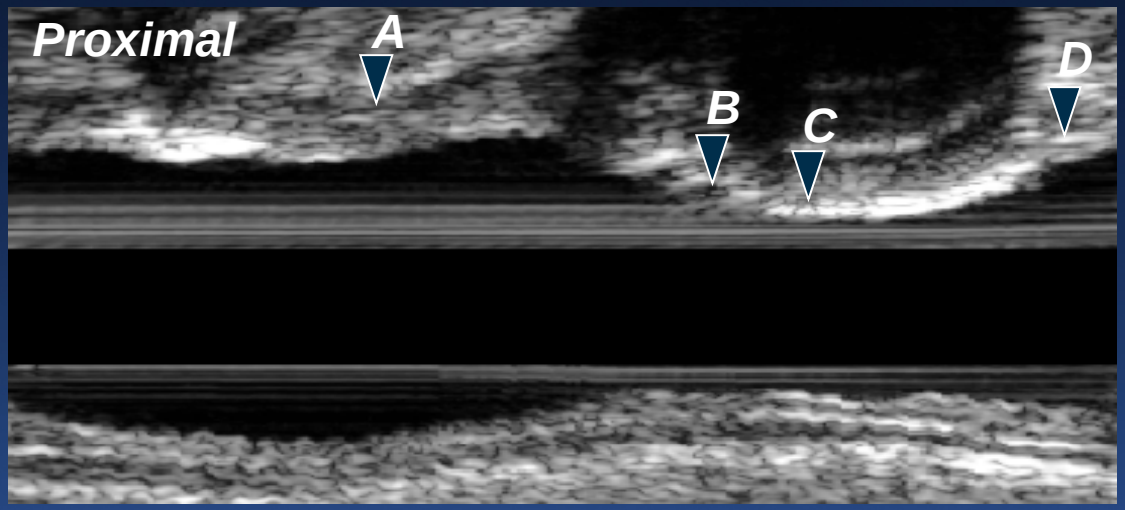

1 mm

Calcium nodule defined by convex shape and irregular and rough contour of the luminal surface or luminal side of calcium

Lee et al. Circulation (in press)

- *The block color of the 17 calcified nodules was orange in 2 (probability of the top 10th percentile containing lipid core plaque of 0.57-0.84) and red in 15 (lowest probability of lipid core plaque).*

- *No significant difference in computed LCBI between calcified nodules vs non-nodular calcium (46 ±70 vs 71 ±129, p=0.42).*

- *Higher LCBI between calcified nodules vs fibroatheromas (46 ±70 vs 215 ±213, p=0.001)*

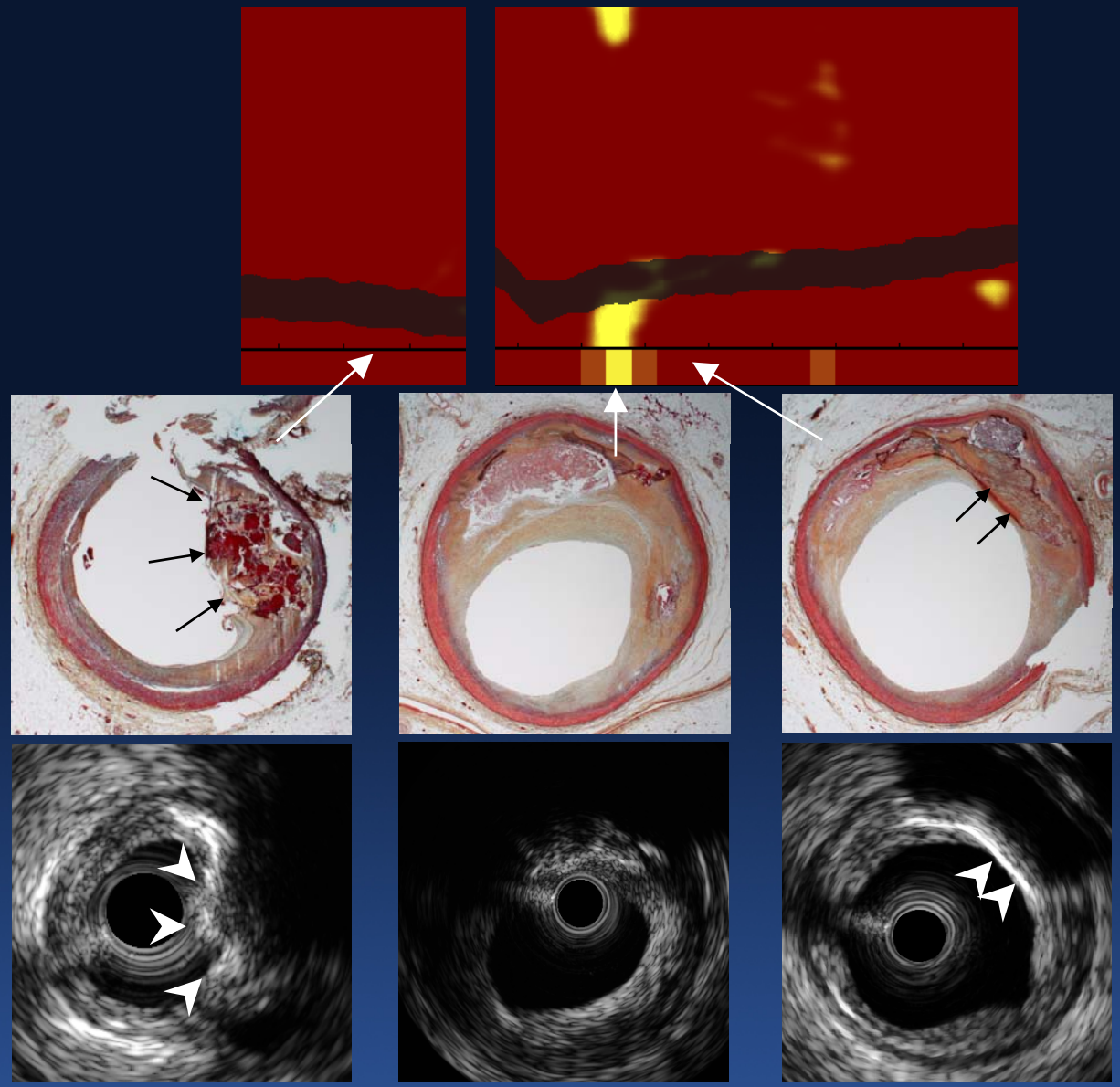

- ***A total of 315 calcified nodules were detected in 251 of 1421 analyzable arteries in 189 of 615 patients in PROSPECT.***

- ***The prevalence of calcified nodules was 18% per artery and 31% per patient.***

- ***Two or more calcified nodules were detected in 48 coronary arteries (3%) and in 74 patients(12%).***

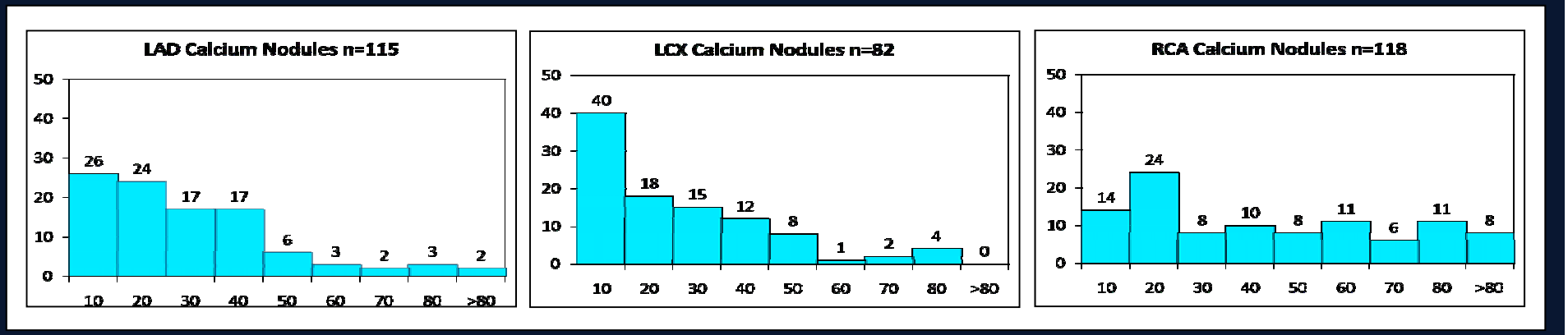

LAD *LCX* *RCA*

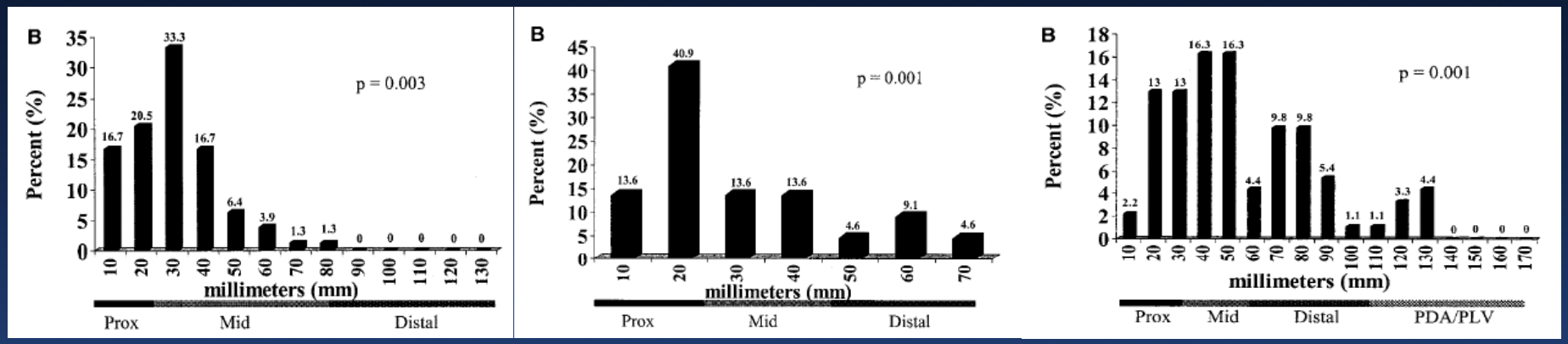

(Wang et al. Circulation 2004;110:278-84)

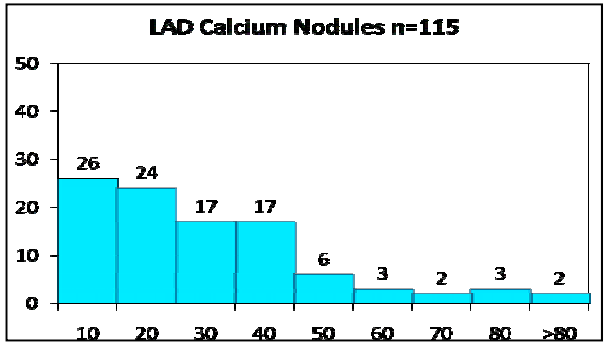

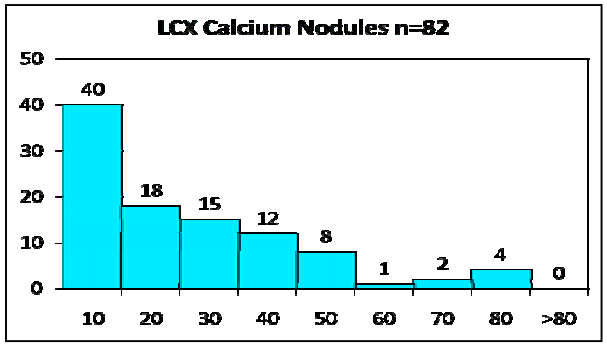

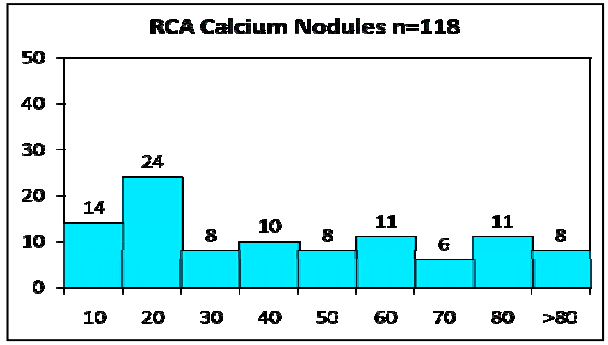

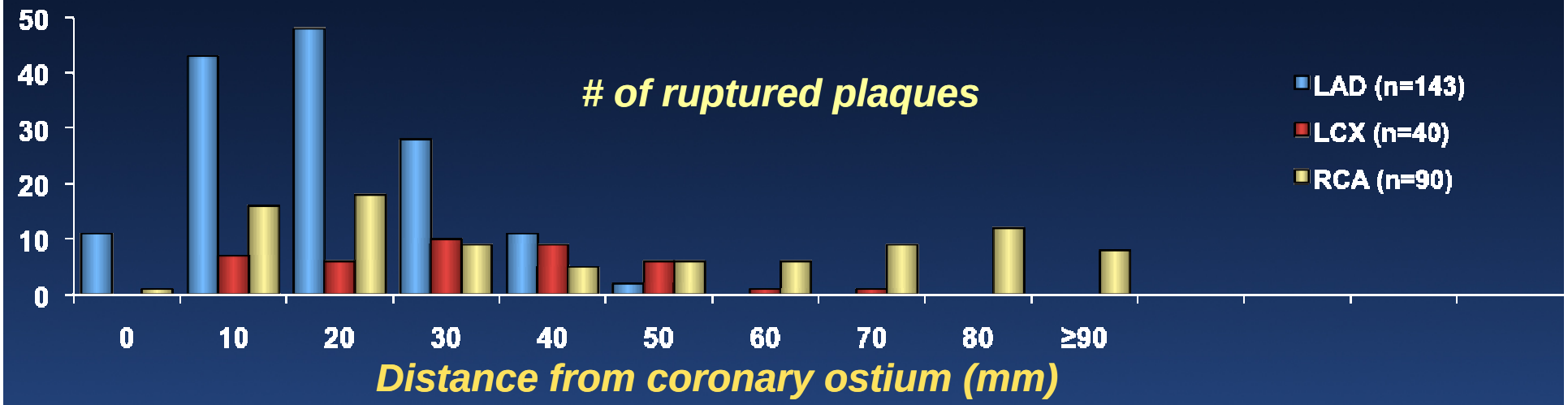

Hong et al J Am Coll Card 2005;46:261-5

Spatial Distribution of Advanced Coronary Lesions

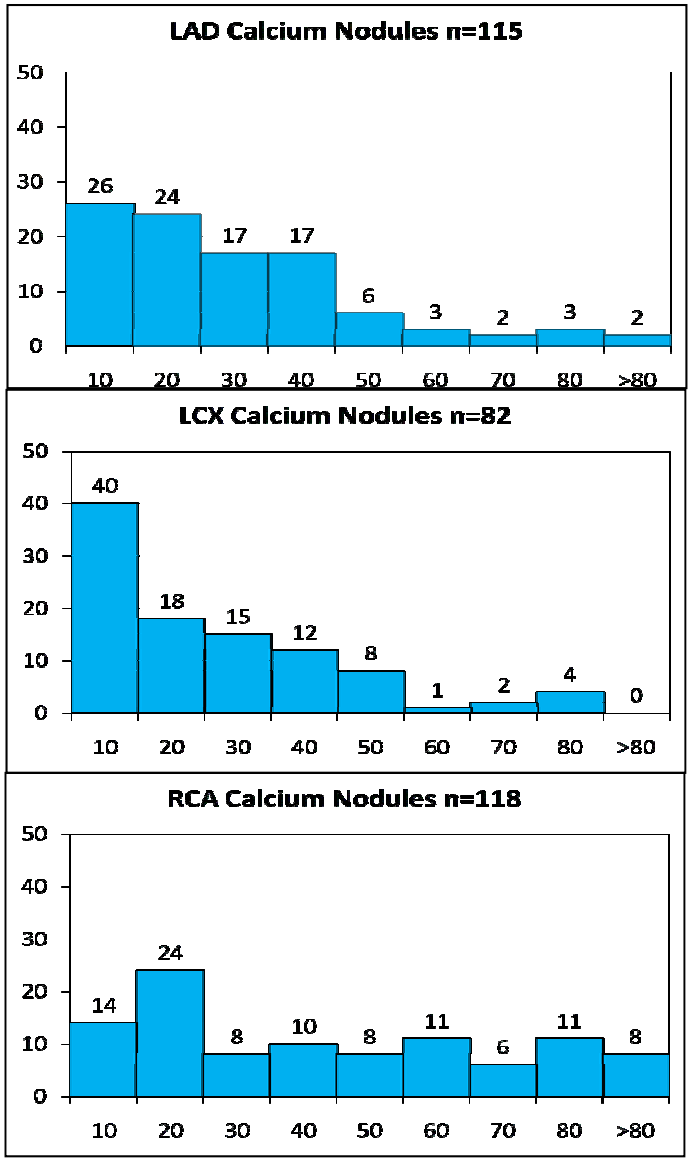

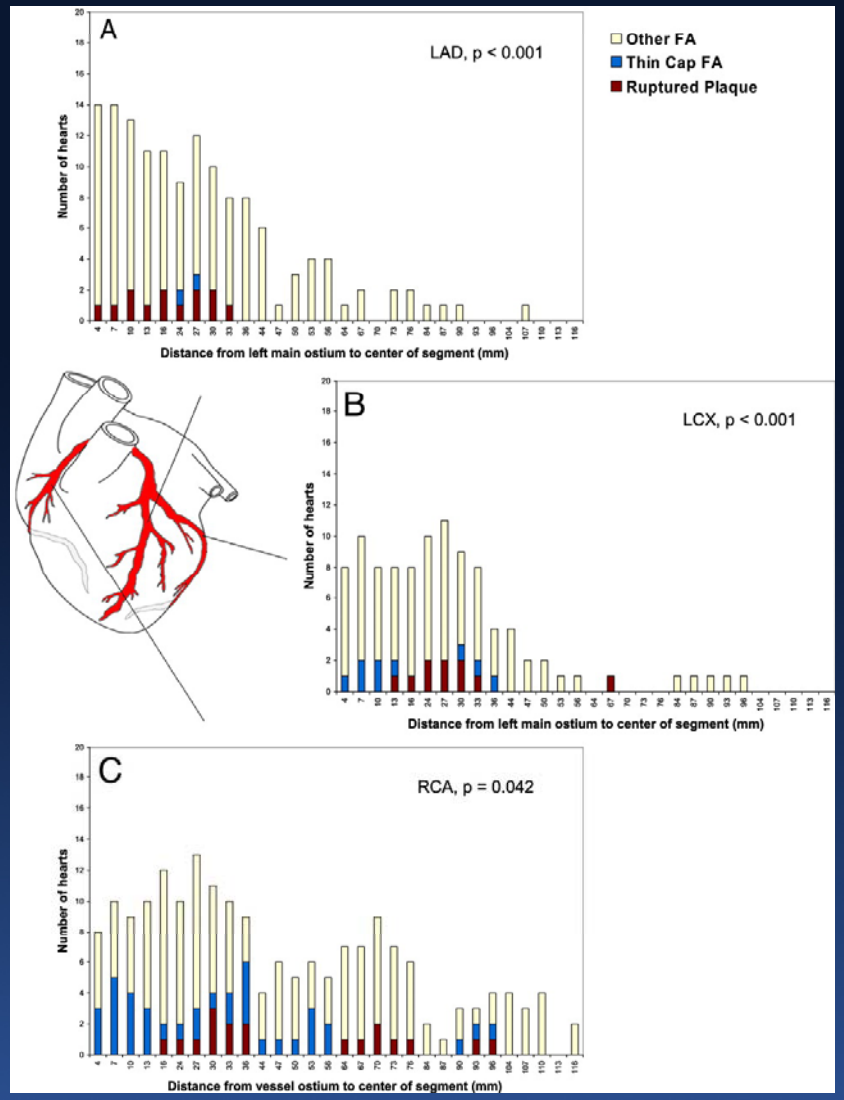

Cheruvu et al. J Am Coll Cardiol 2007;50:940-949

LipiScan-IVUS

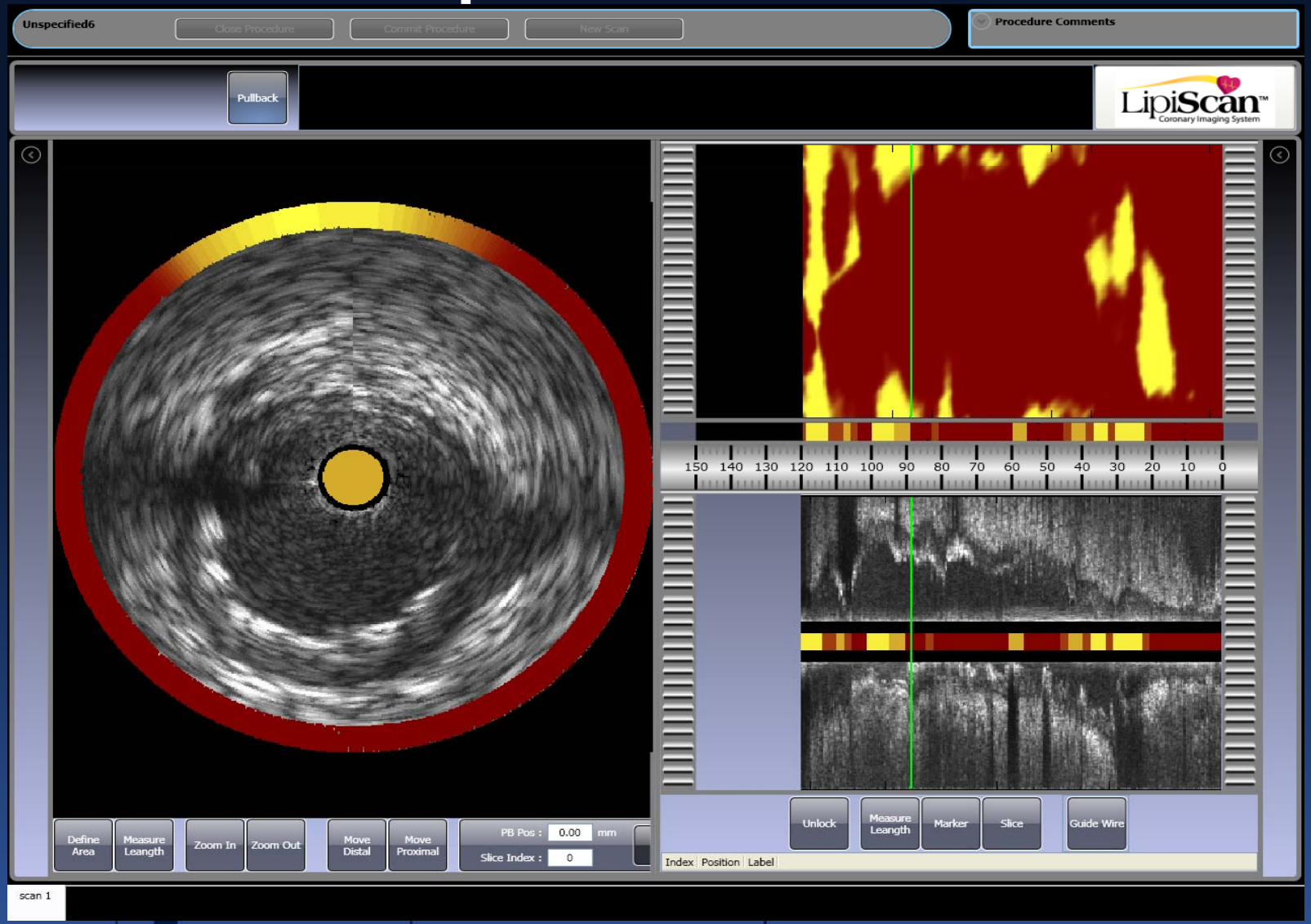

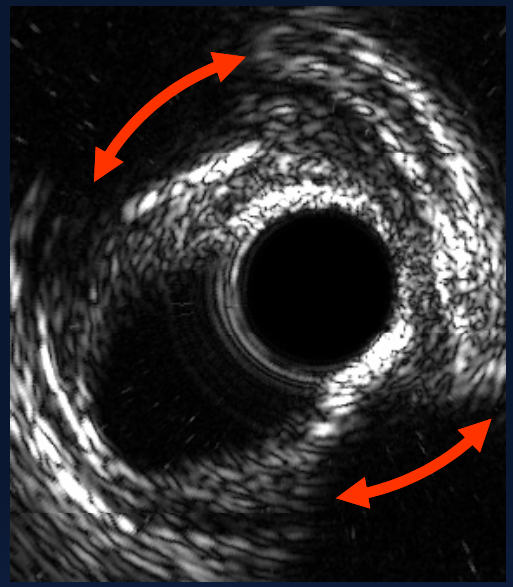

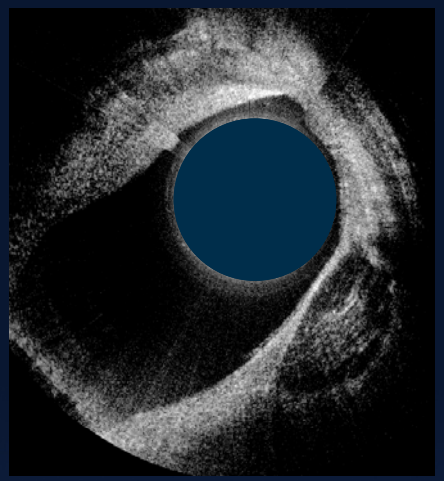

Histology (H&E)

IVUS

OCT

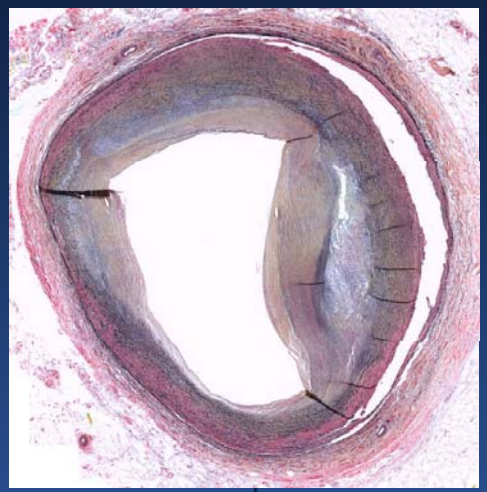

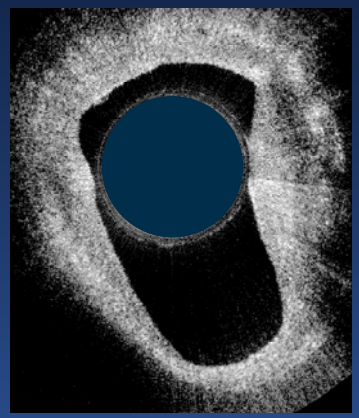

Courtesy of Brian Courtney