"Optical Coherence Tomography"

In ACS vs. Stable Angina

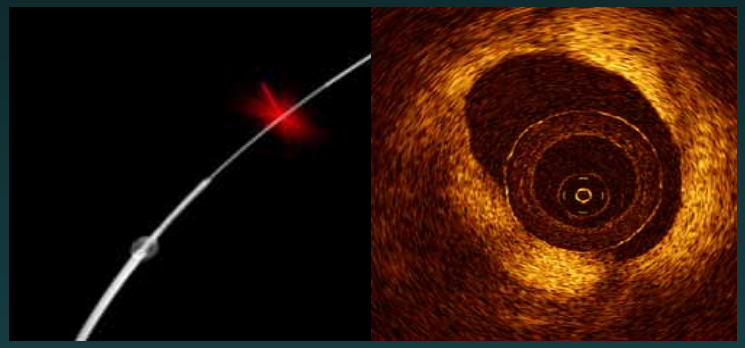

So-Yeon Choi, MD, PhD
Ajou University School of Medicine
Suwon, Korea

Q1. Could OCT provide better information for detecting vulnerable plaque than other modalities?

Pathologic Criteria for Vulnerable Plaque

Based on previously presented autopsy study

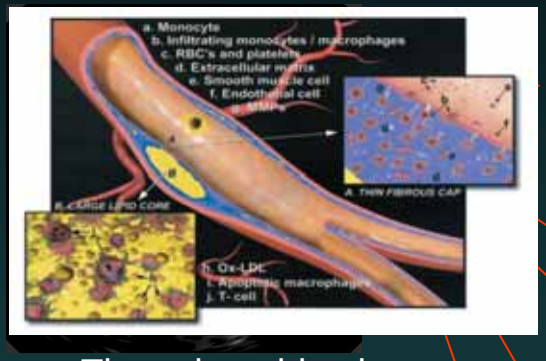

The vulnerable plaque characterized by thin fibrous cap, extensive macrophage infiltration, and large lipid core.

Major

Echolucent plaque

Atteunated plaque

crophage

- **Thin**
- **End**
  pla
- **Fissured pla**
- **Stenosis 90%**

Ruptured plaque c/s thrombus

Minor criteria

- **Superficial calcified nodule**
- **Glistening yellow**
- **Intraplaque hemorrhage**
- **Endoth**
- **C**

Positive Remodeling

Circulation. 2003;108:1664-1672

Pathologic Criteria for Vulnerable Plaque

Based on previously presented autopsy study

Major criteria

- Active inflammation (monocyte/macrophage and T-cell infiltration)
- Thin cap with large lipid core
- Endothelial denudation with superficial platelet aggregation
- Fissured plaque
- Stenosis 90%

Minor criteria

- Superficial calcified nodule
- Glistening yellow
- Intraplaque hemorrhage
- Endothelial dysfunction
- Outward (positive) remodeling

Circulation. 2003;108:1664-1672

Case #1

SJS, 46/M
STEMI, anterior

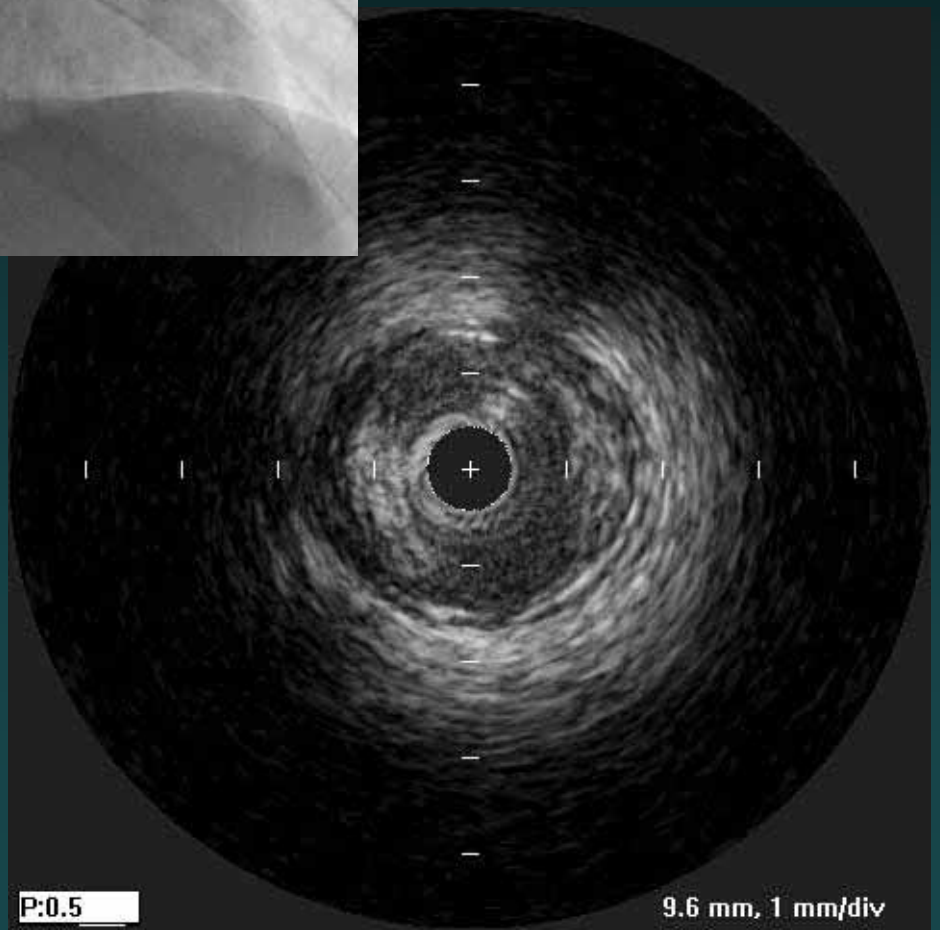

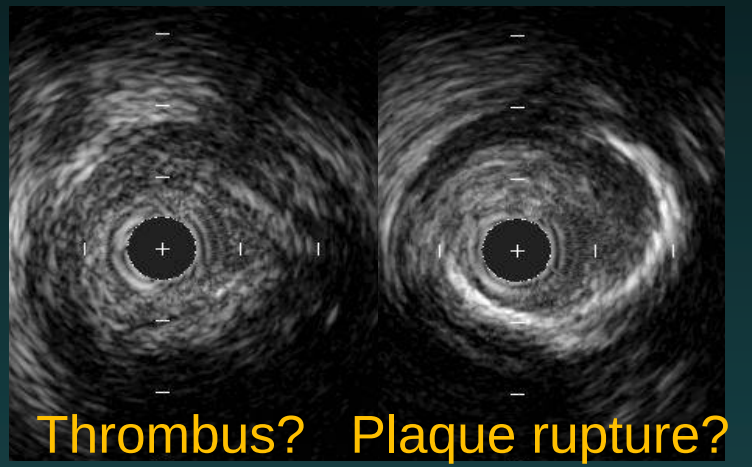

Thrombus? Plaque rupture?

Ruptured Plaque and Lipid Core

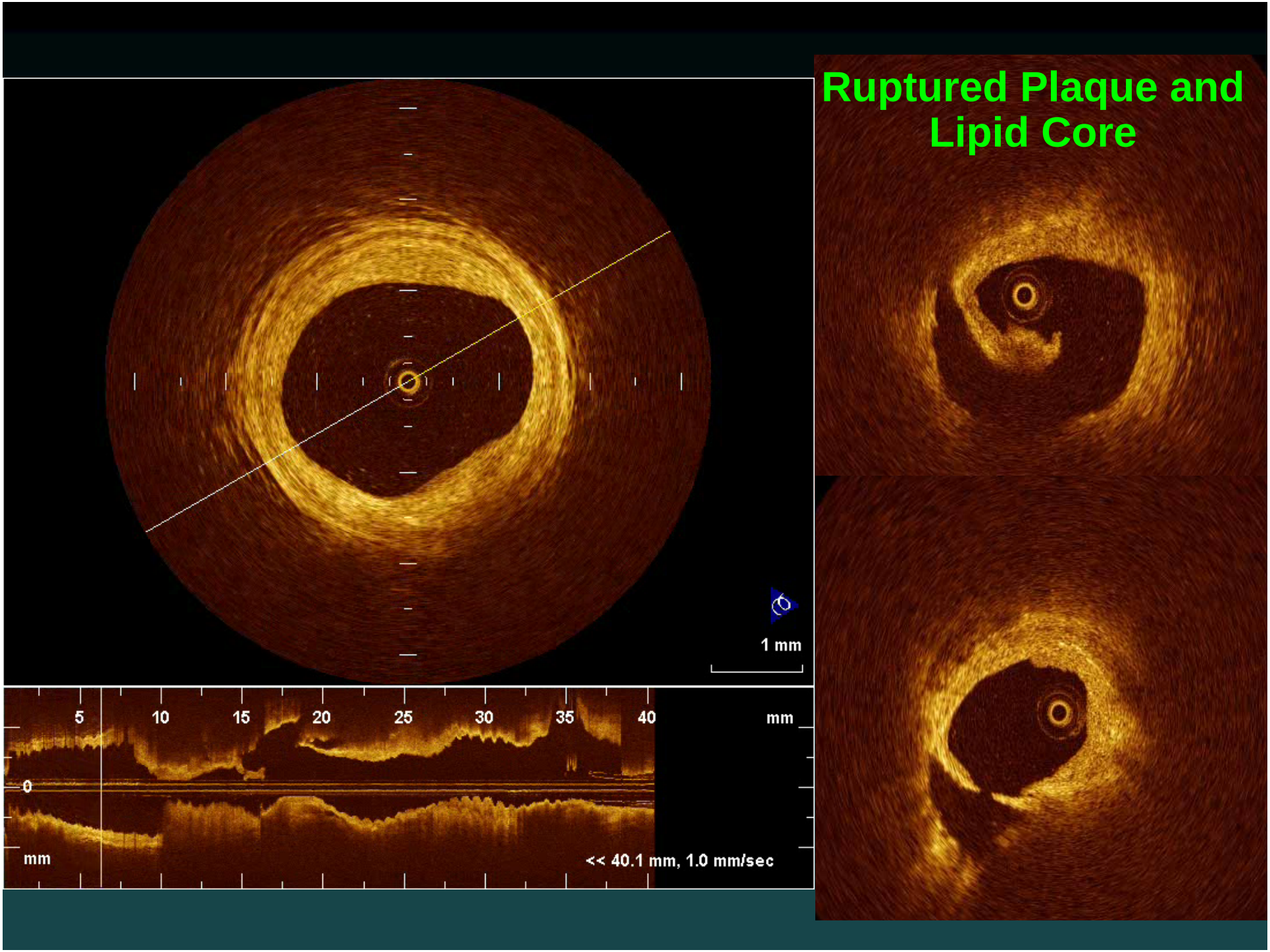

Case #2

PDS, 63/M
STEMI, anterior

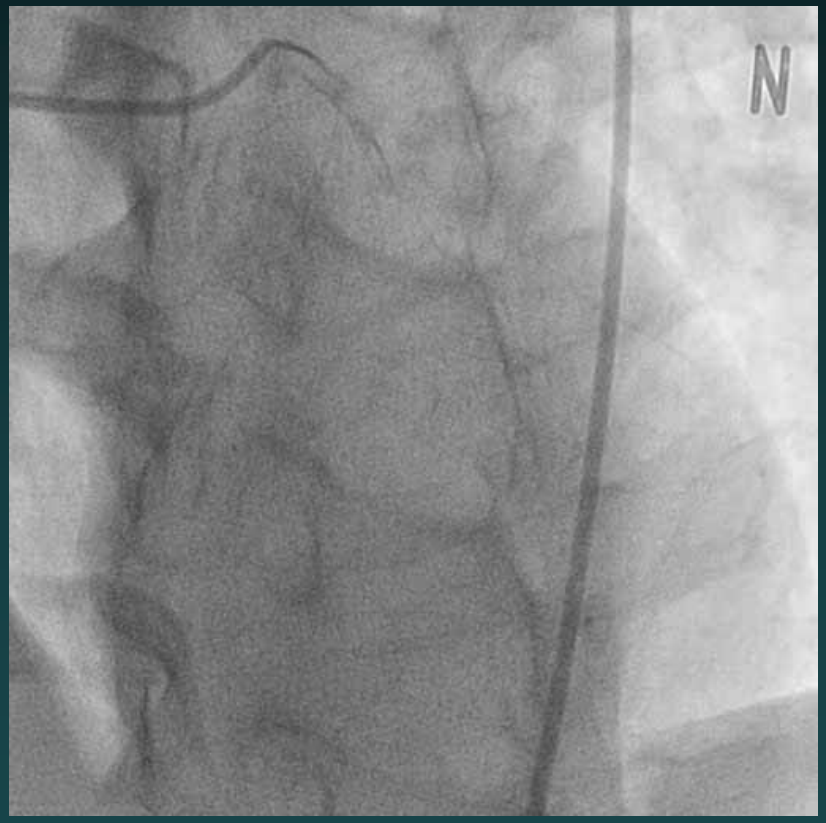

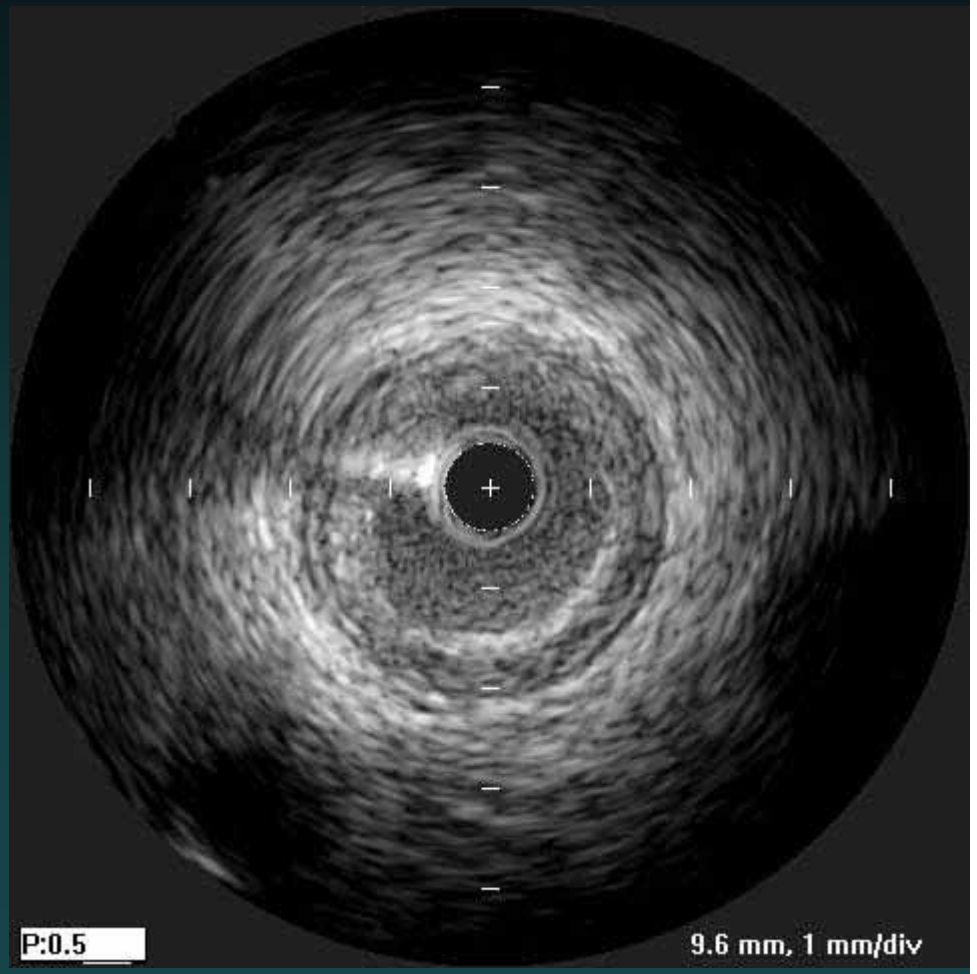

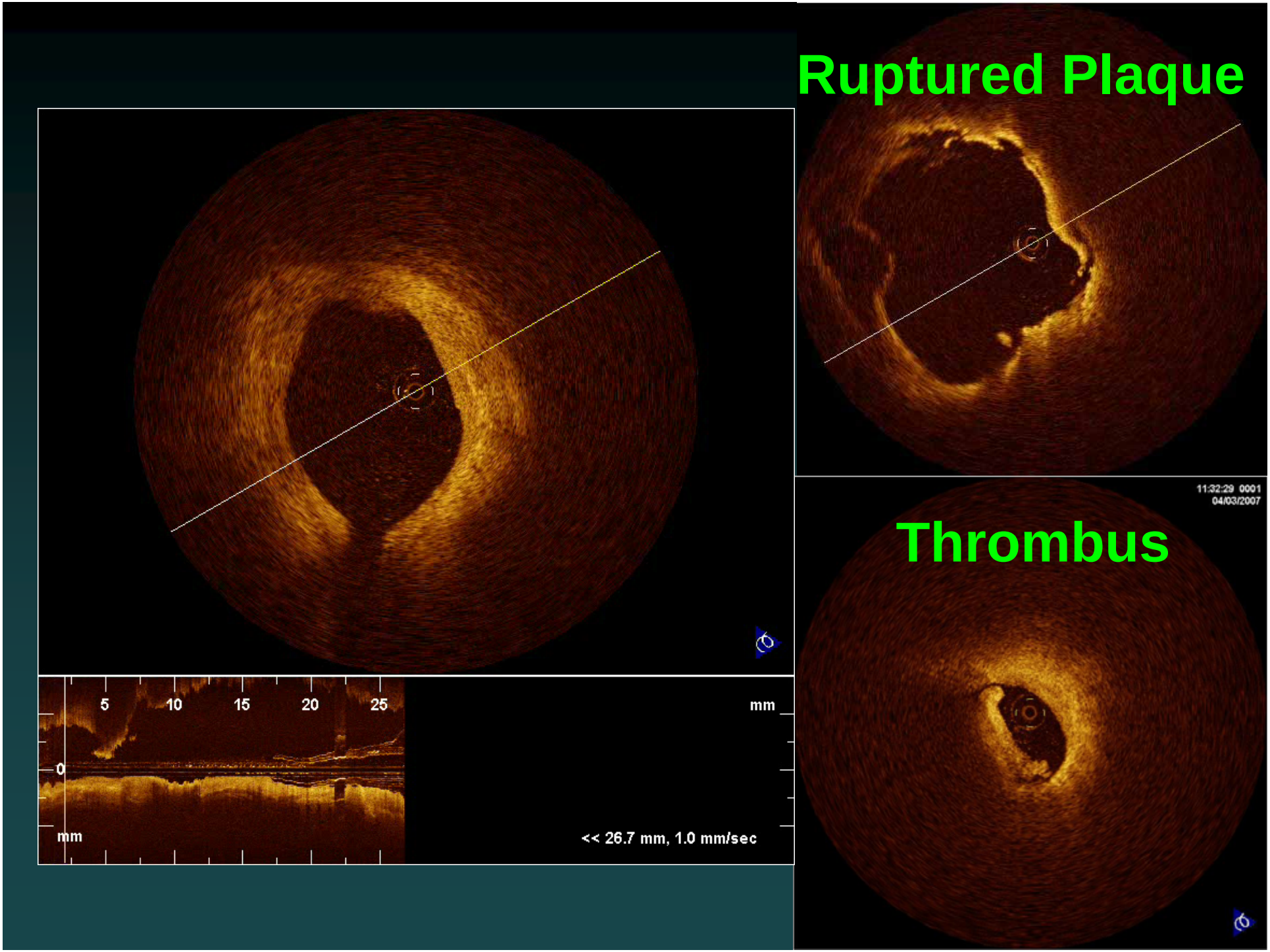
Ruptured Plaque
Thrombus
11:32:29 0001
04/03/2007
5
10
15
20
25
mm
0
mm
<< 26.7 mm, 1.0 mm/sec

Case #3

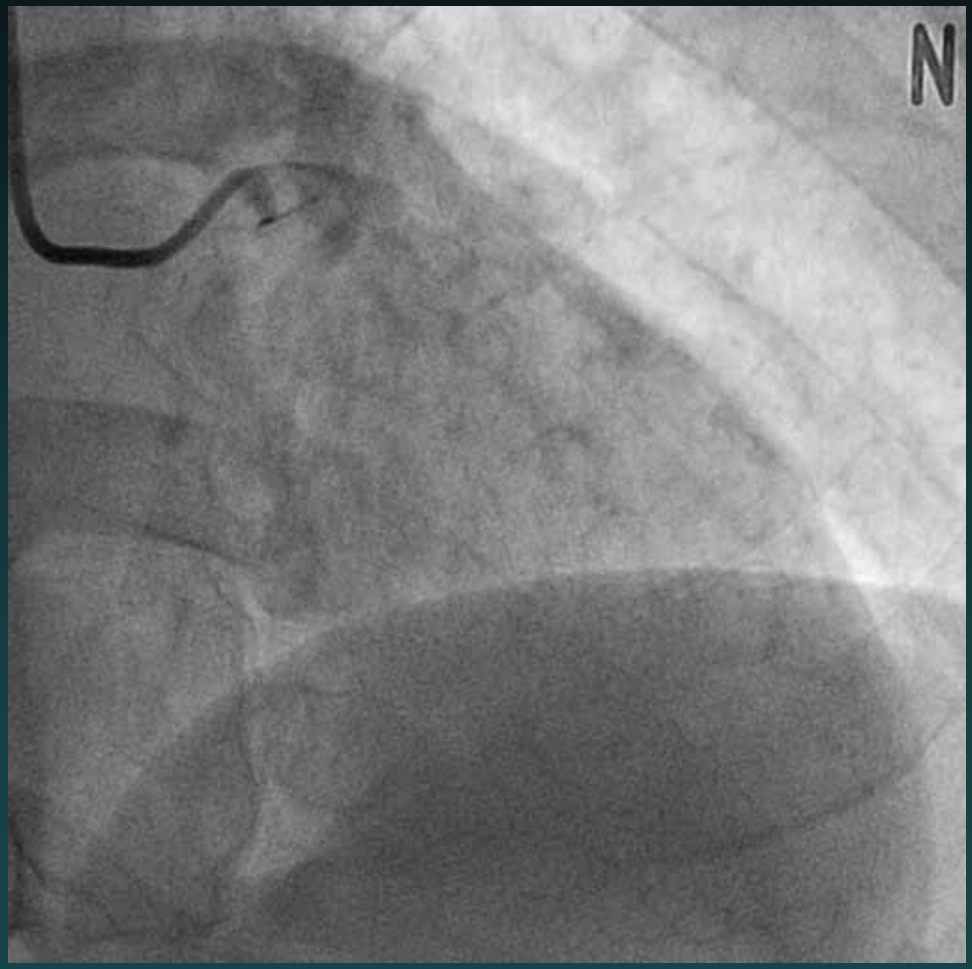

SKK, 65/M
NSTEMI, anterior

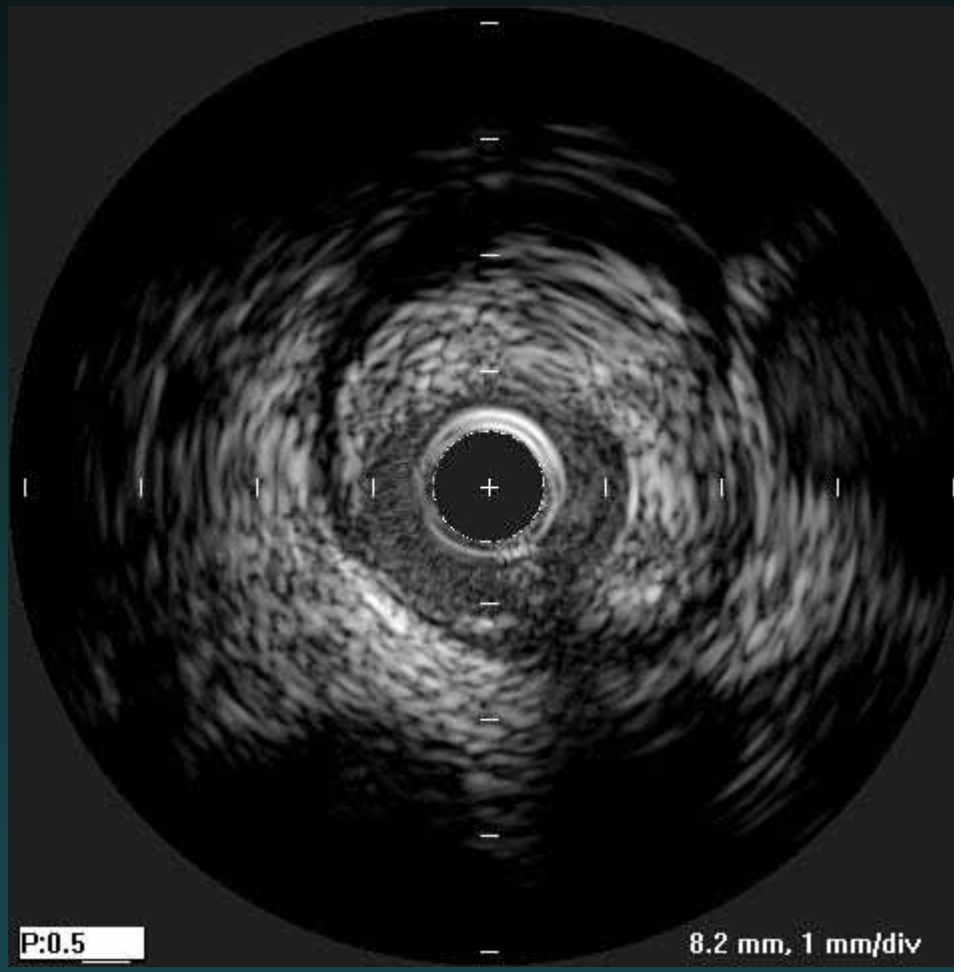
P:0.5
8.2 mm, 1 mm/div

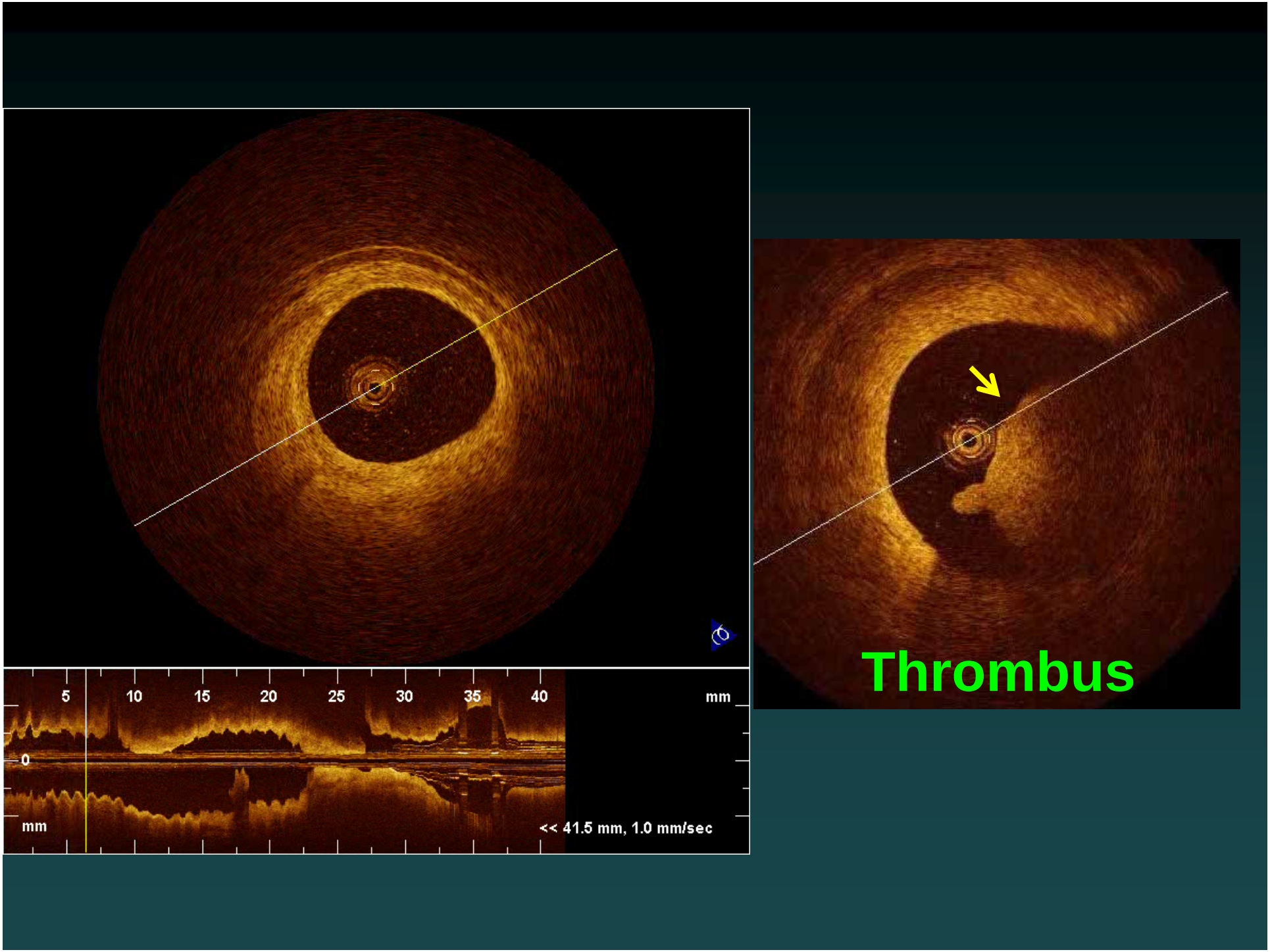
5
10
15
20
25
30
35
40
mm
0
mm
<< 41.5 mm, 1.0 mm/sec
Thrombus

Case #4: which one is red thrombus?

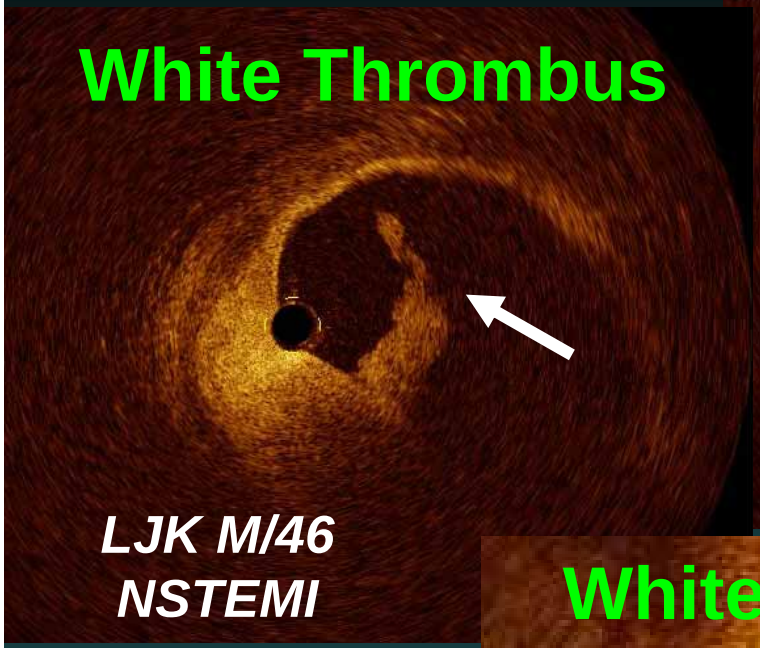

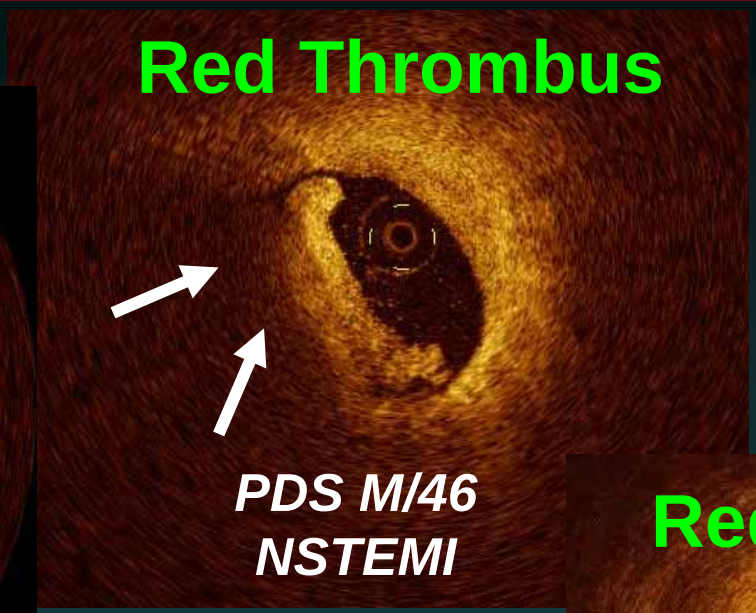

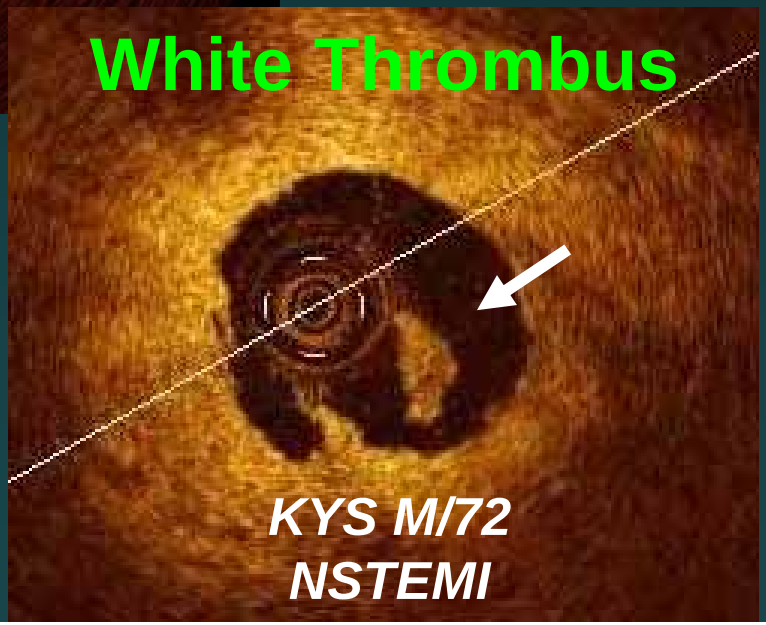

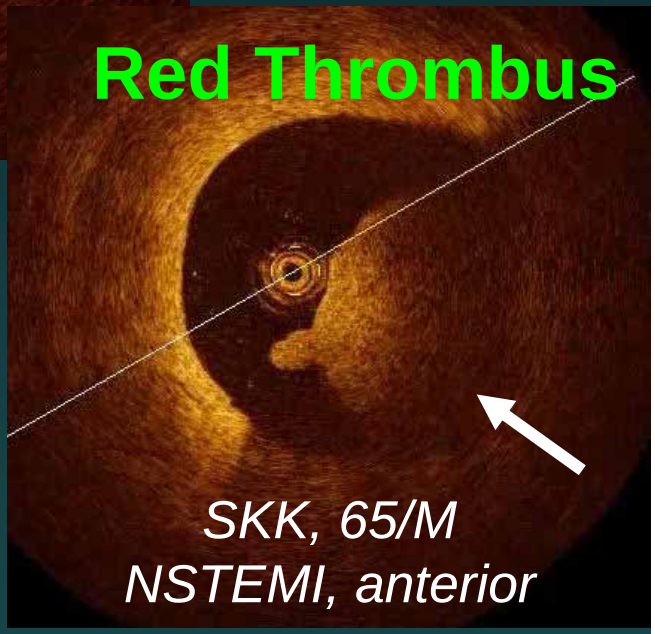

Red Thrombus vs. White Thrombus

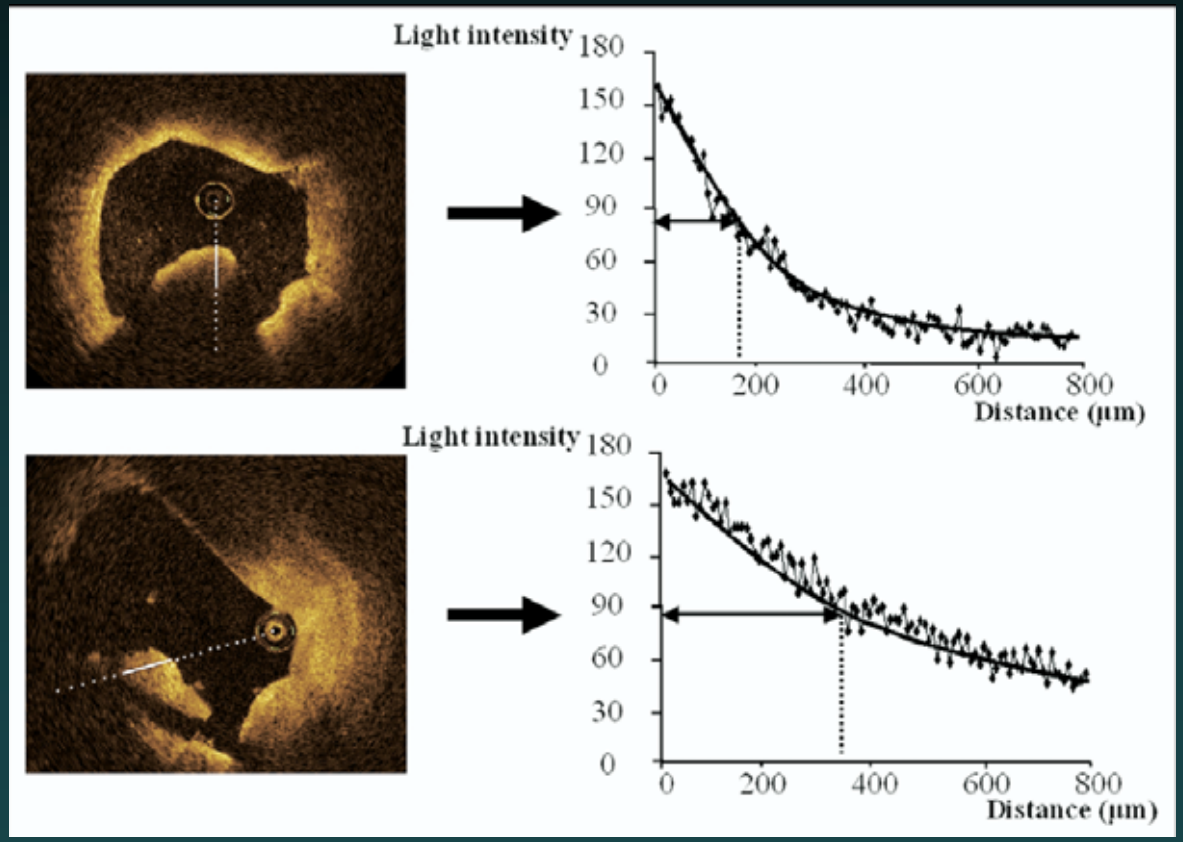

T Kume et al. Am J Cardiol 2006

Case #5

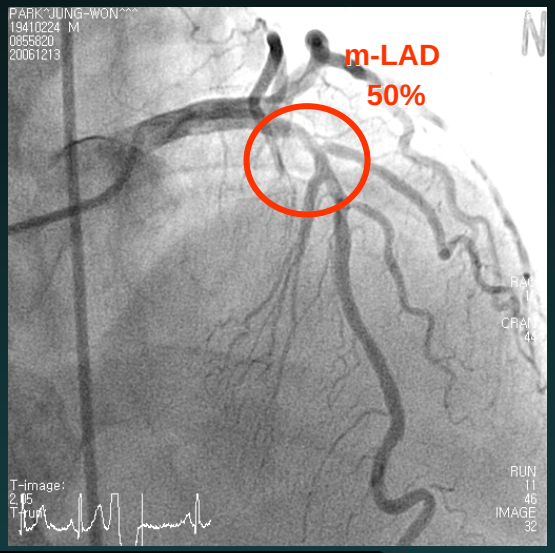

PJW, 65/M
UAIIIB

OCT-TCFA

Lipid rich plaque (≥2 quadrants) with a thin fibrous cap (<65 µm)

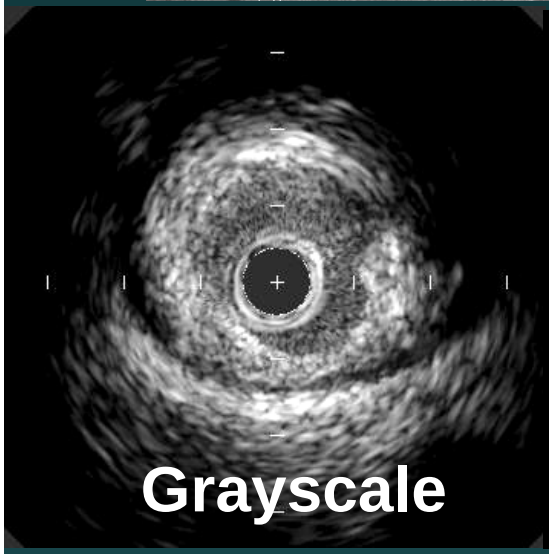

Grayscale

≥10% NC /s evidence overlying fibrous tissue

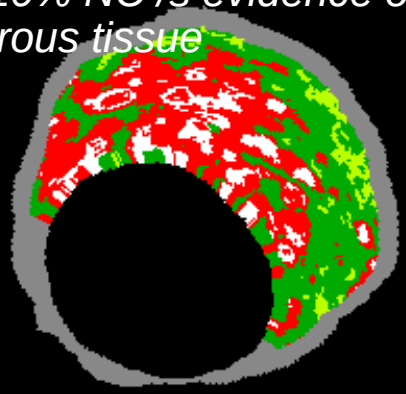

VH -IVUS

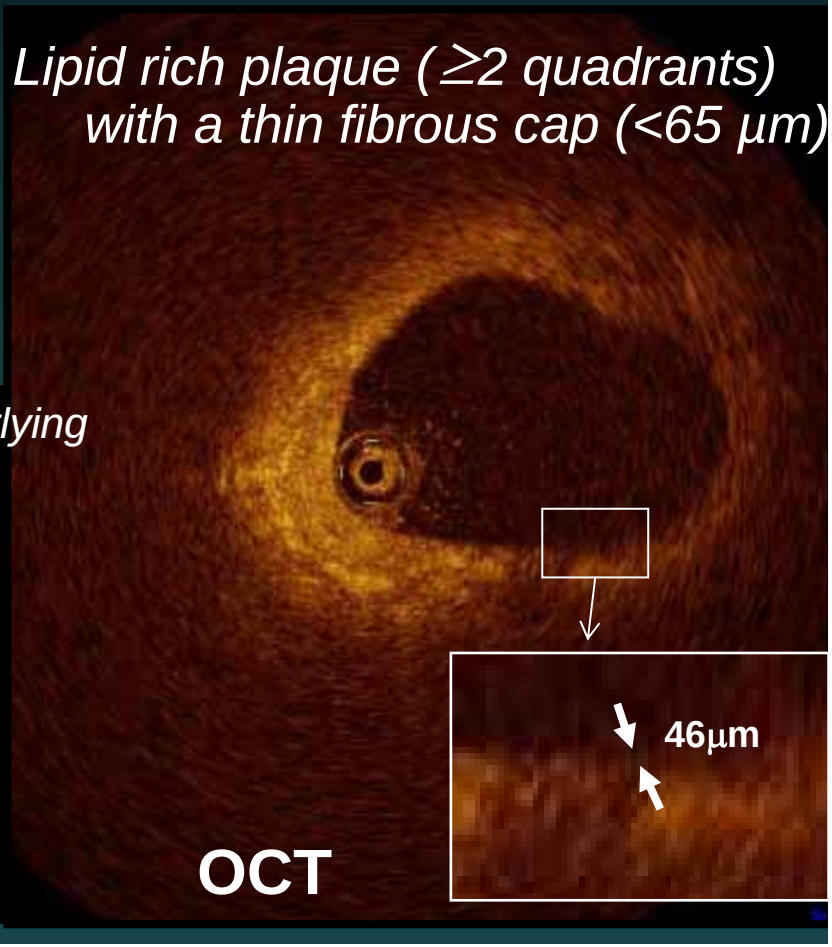

OCT

Case #6

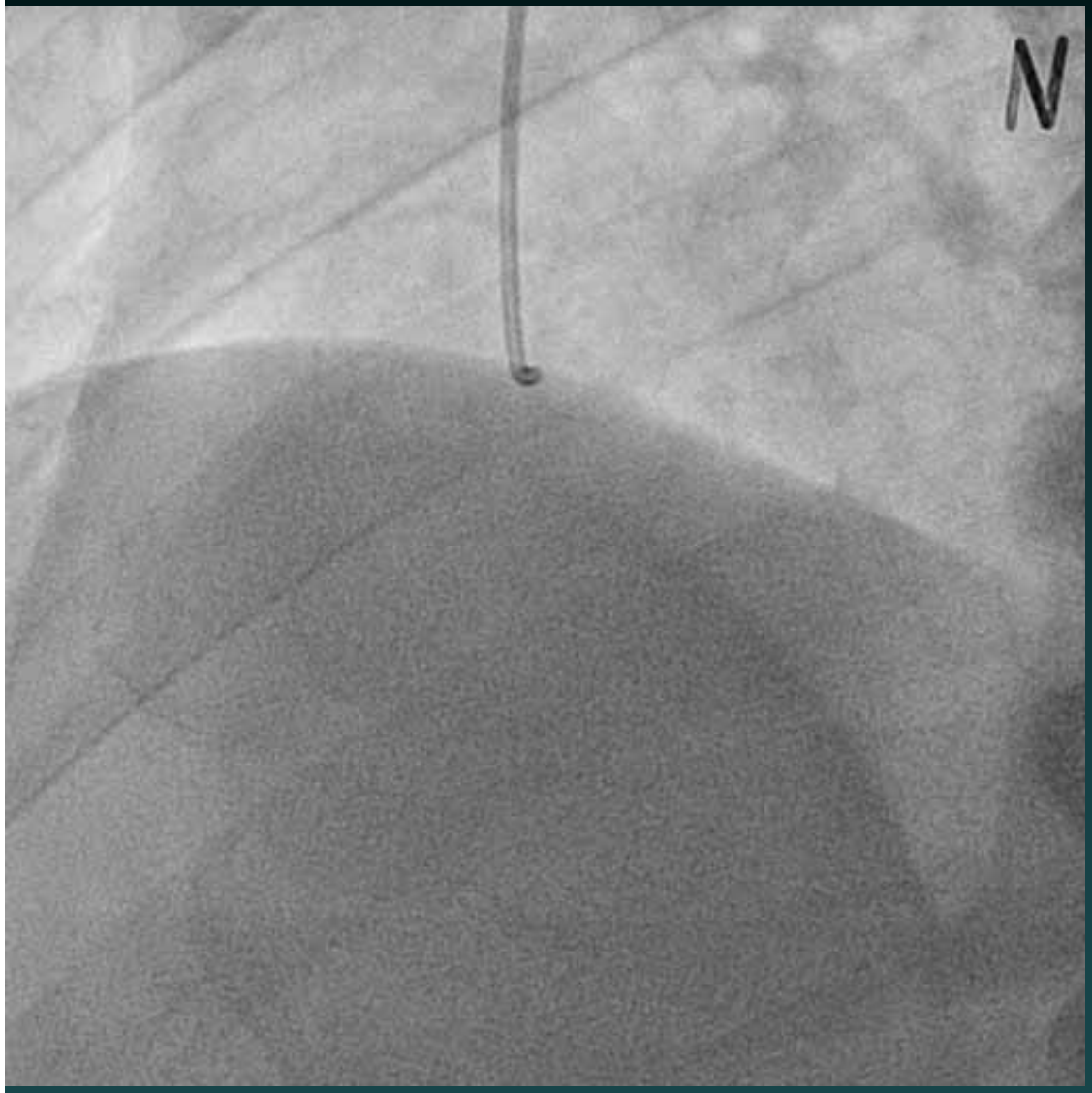

PJW, 65/M
UAIIIB

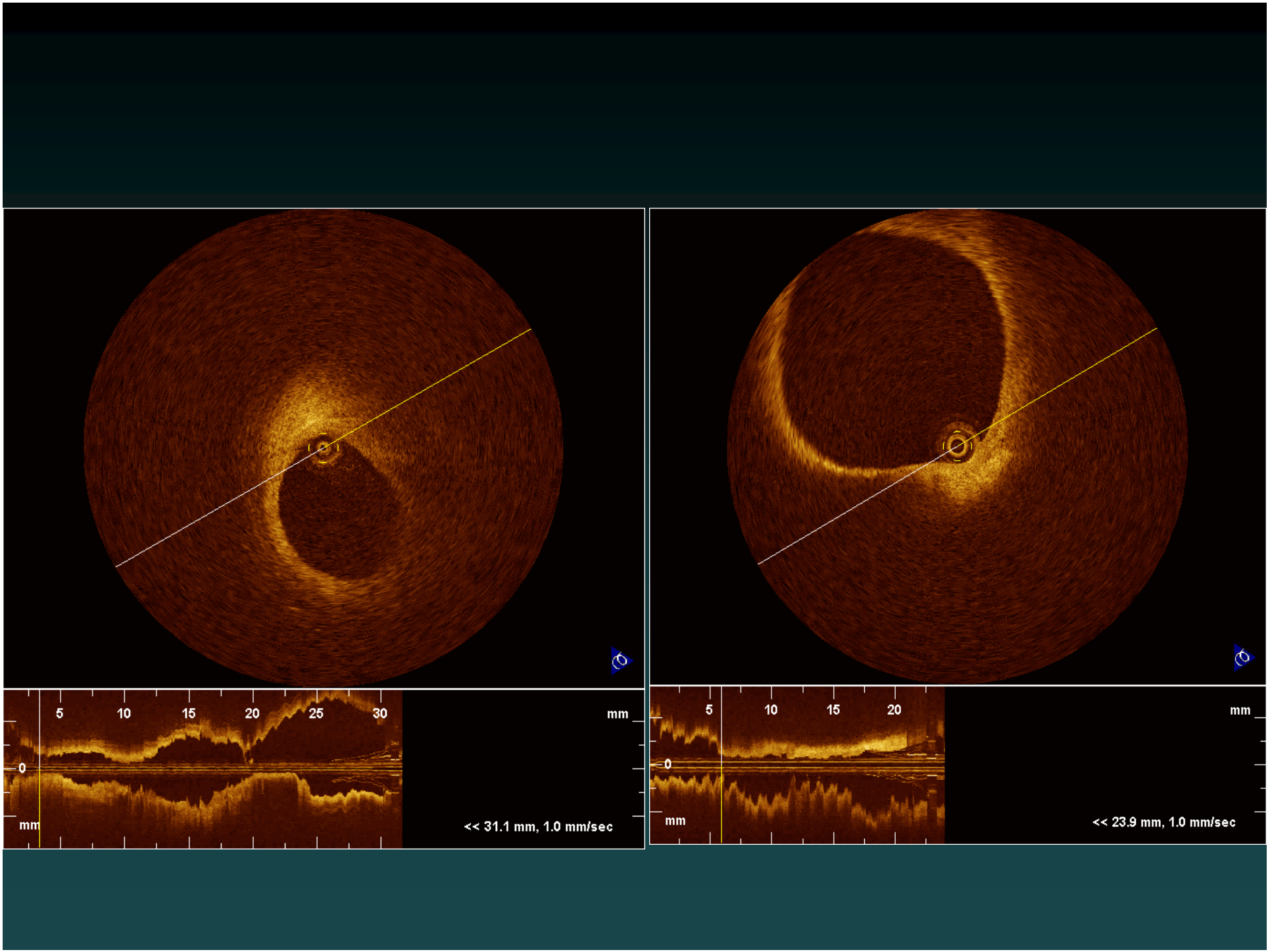
5
10
15
20
25
30
mm
0
mm
<< 31.1 mm, 1.0 mm/sec
5
10
15
20
mm
0
mm
<< 23.9 mm, 1.0 mm/sec

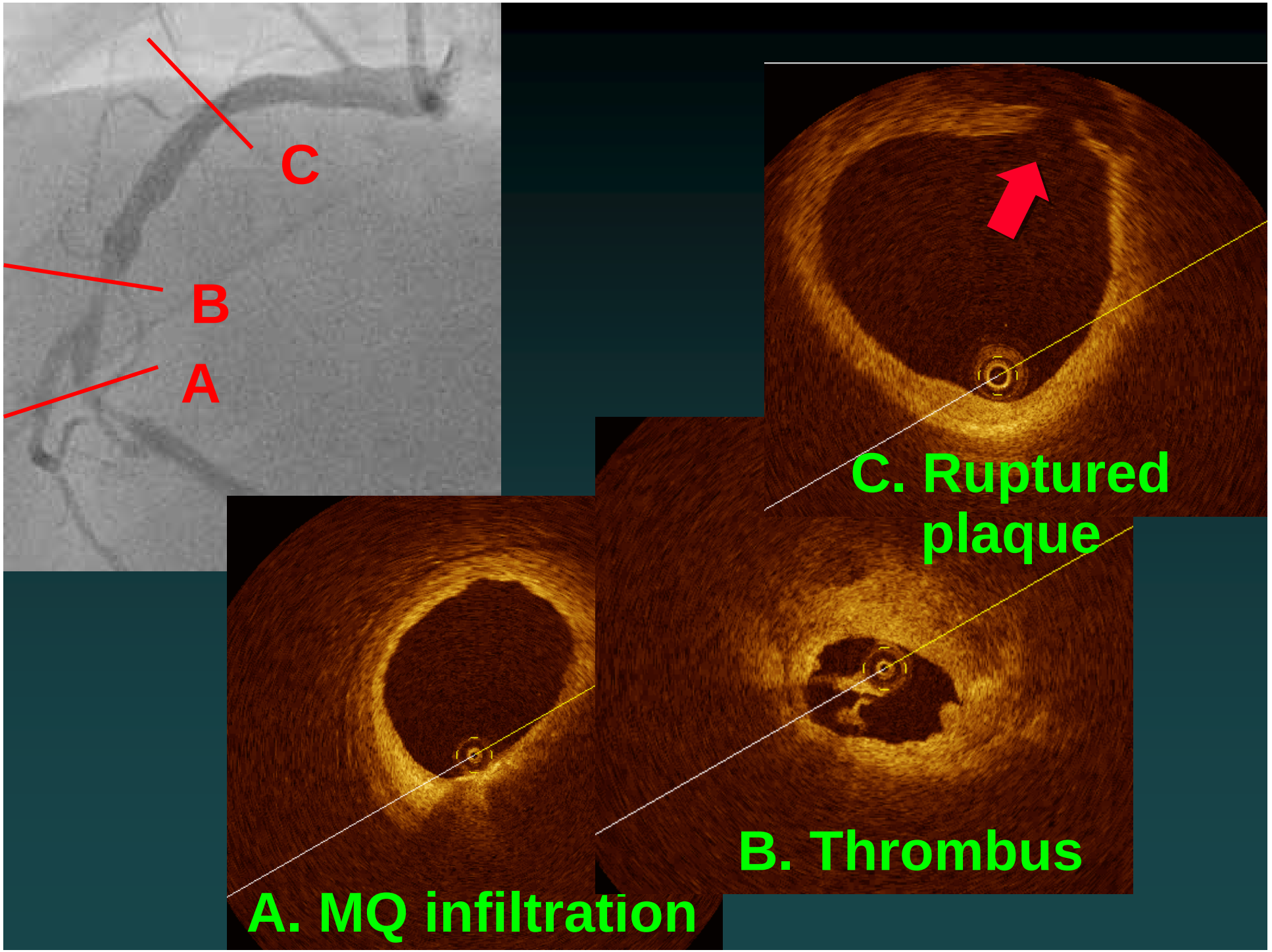
C
B
A
C. Ruptured plaque
B. Thrombus
A. MQ infiltration

Inflammation: Macrophage Cluster

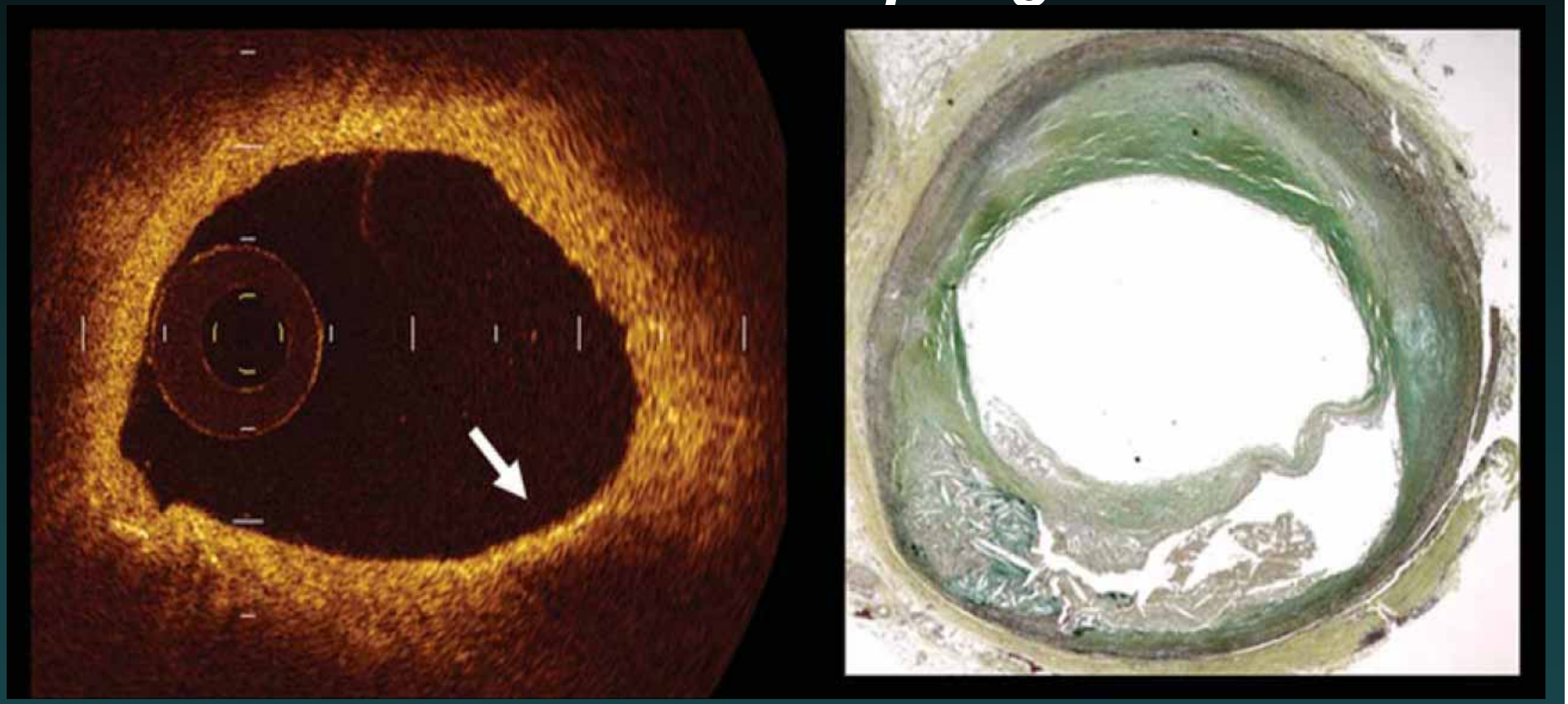

F Prati et al. Eur Heart J, 2010

Q2. Does OCT give us too much information about plaques?

Case #7

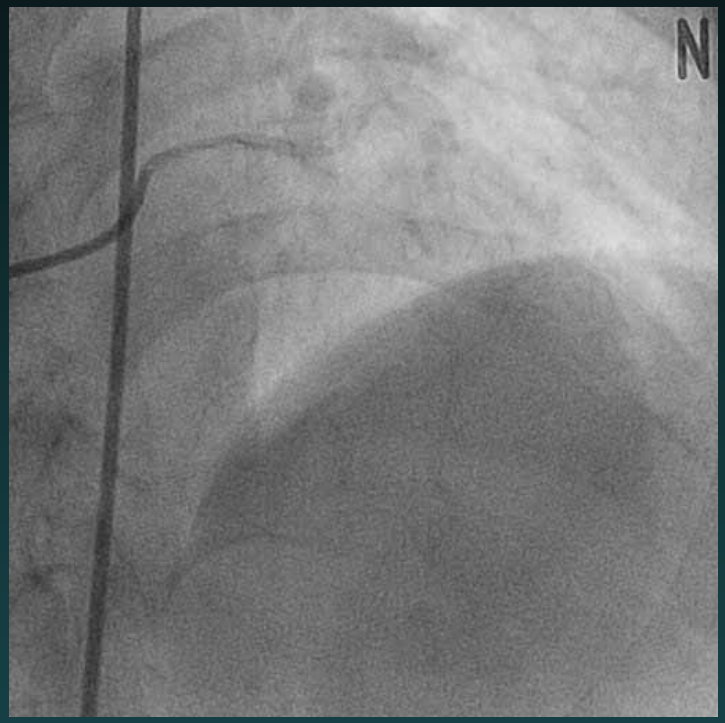

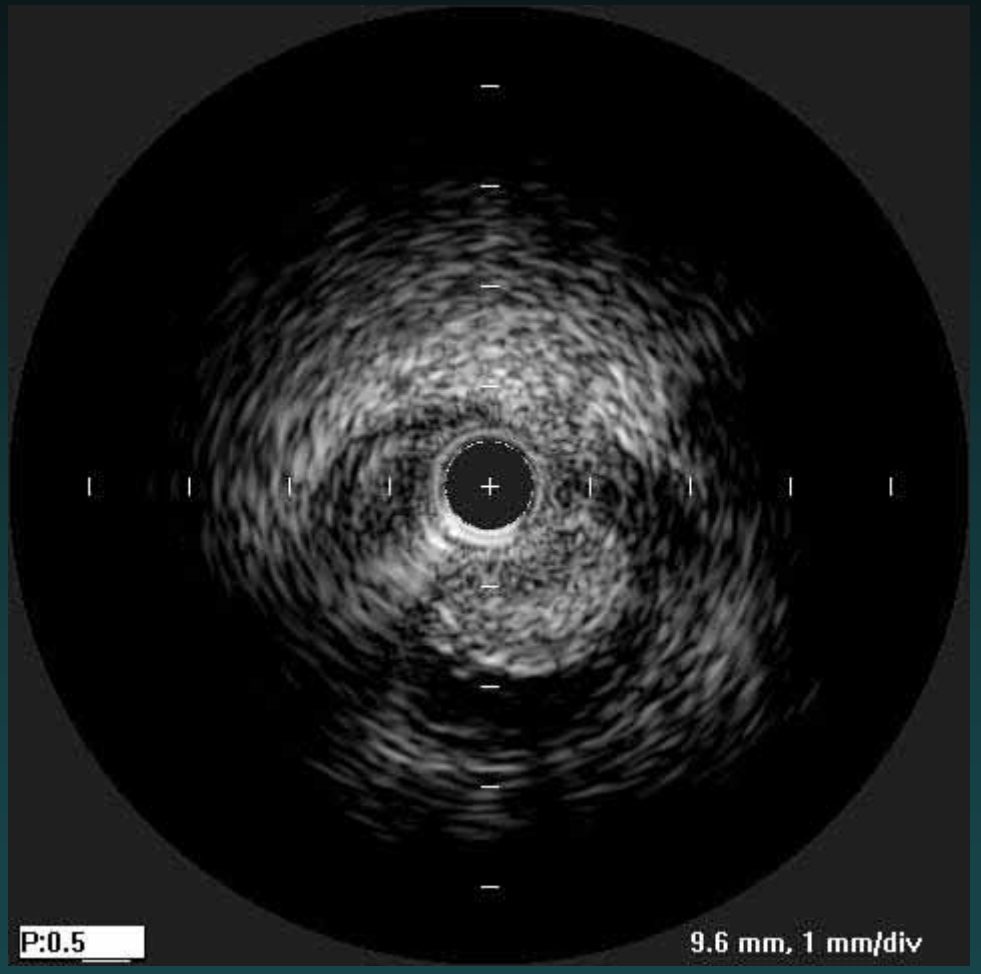

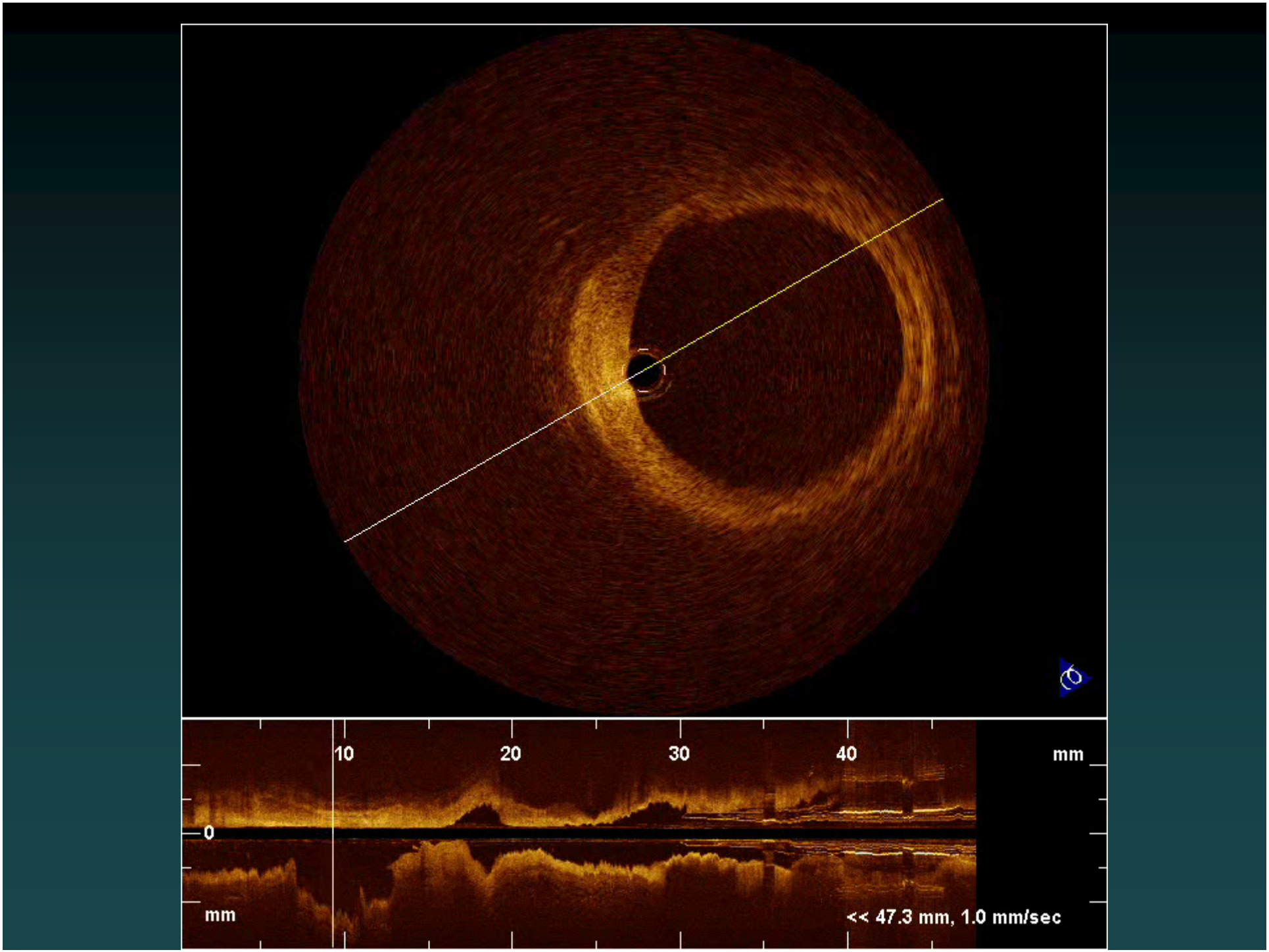
10
20
30
40
mm
0
mm
<< 47.3 mm, 1.0 mm/sec

Stable plaque?
Unstable plaque?

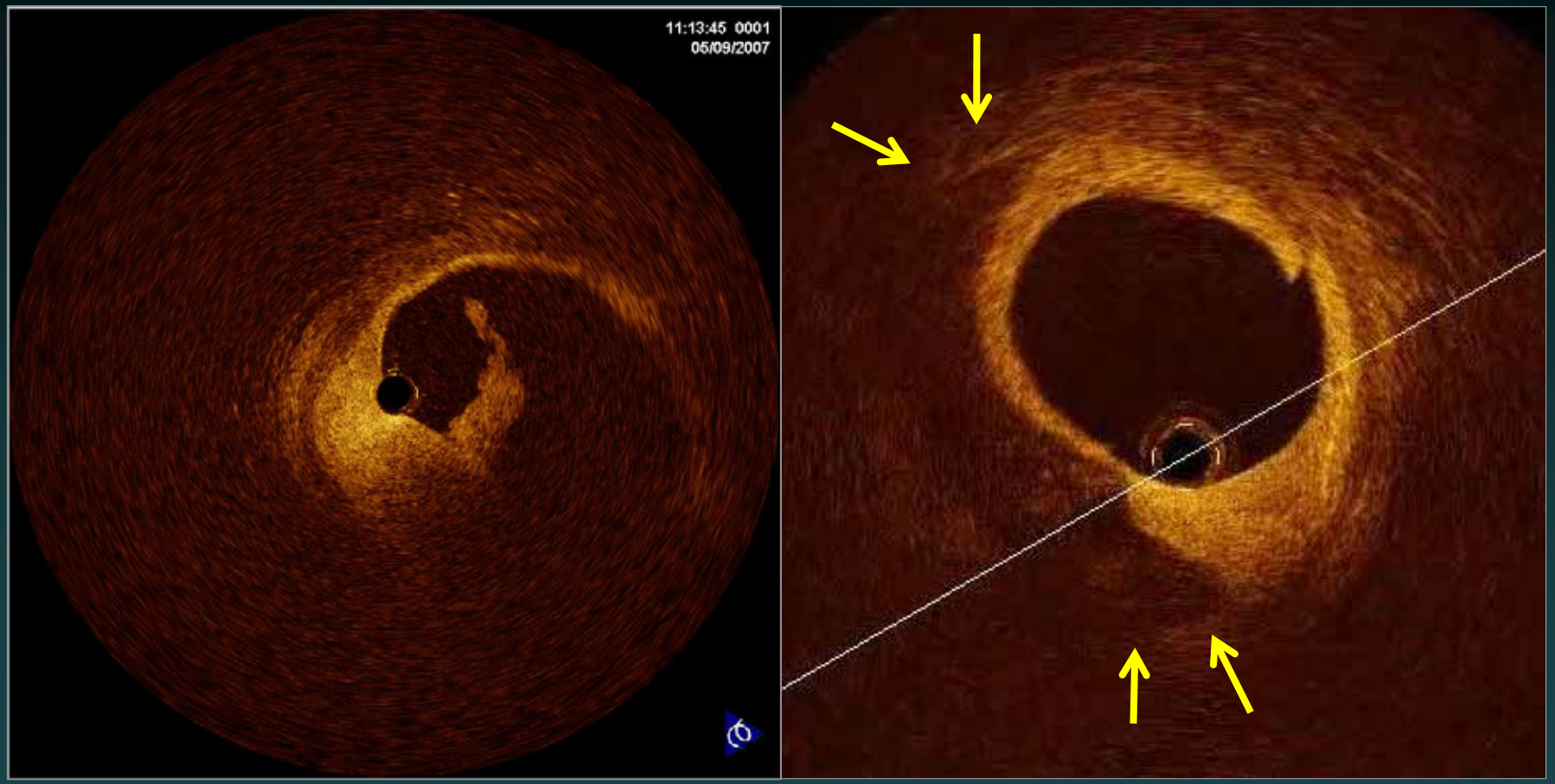
11:13:45 0001
05/09/2007

Case #8

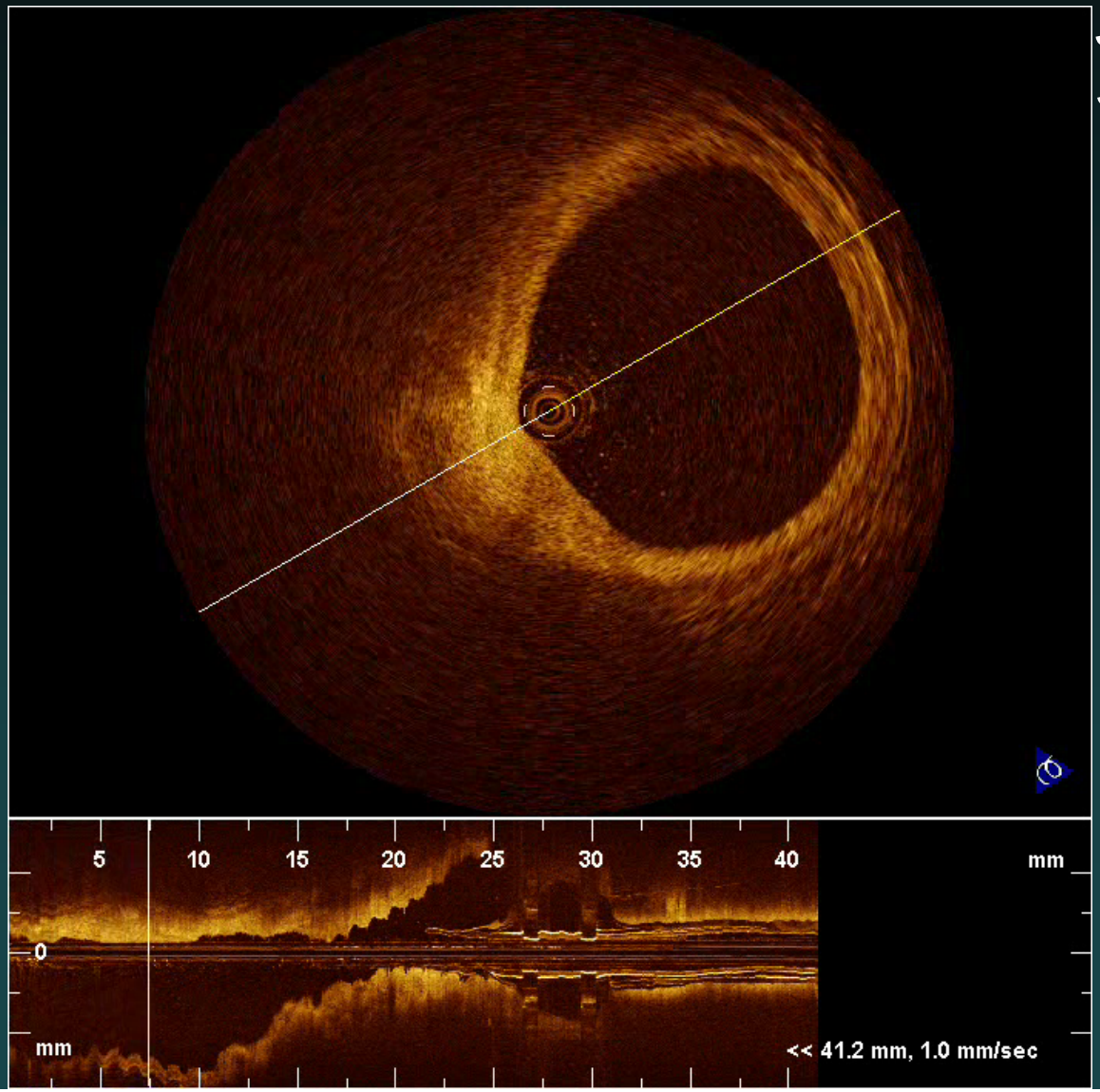

JMA F/55
SA

Take Home Massages

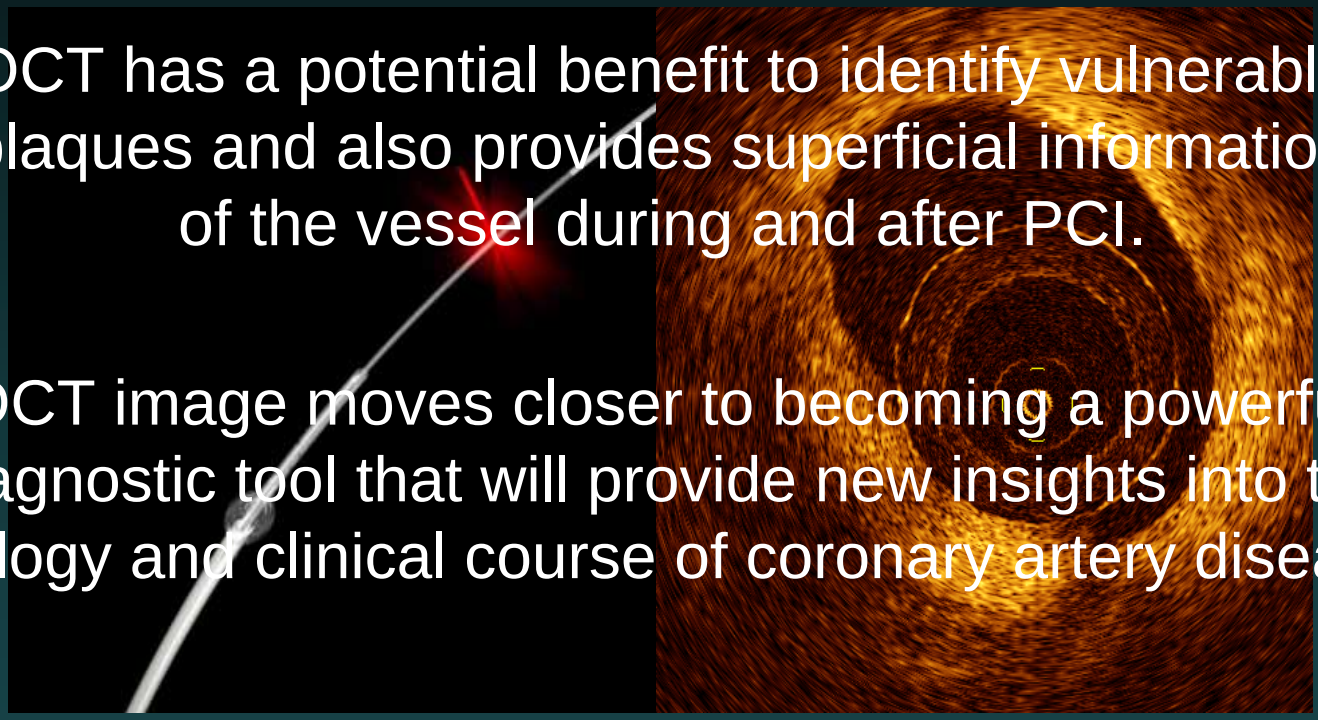

OCT has a potential benefit to identify vulnerable plaques and also provides superficial information of the vessel during and after PCI.

OCT image moves closer to becoming a powerful diagnostic tool that will provide new insights into the etiology and clinical course of coronary artery disease.

Detection of VP in OCT

IVUS vs. VH-IVUS vs. OCT

The Major and Minor Criteria for Vulnerable Plaque

- 48 Patients (48 lesions) were enrolled and categorized according to their clinical presentation into SAP (n=15) and ACS (n=33).

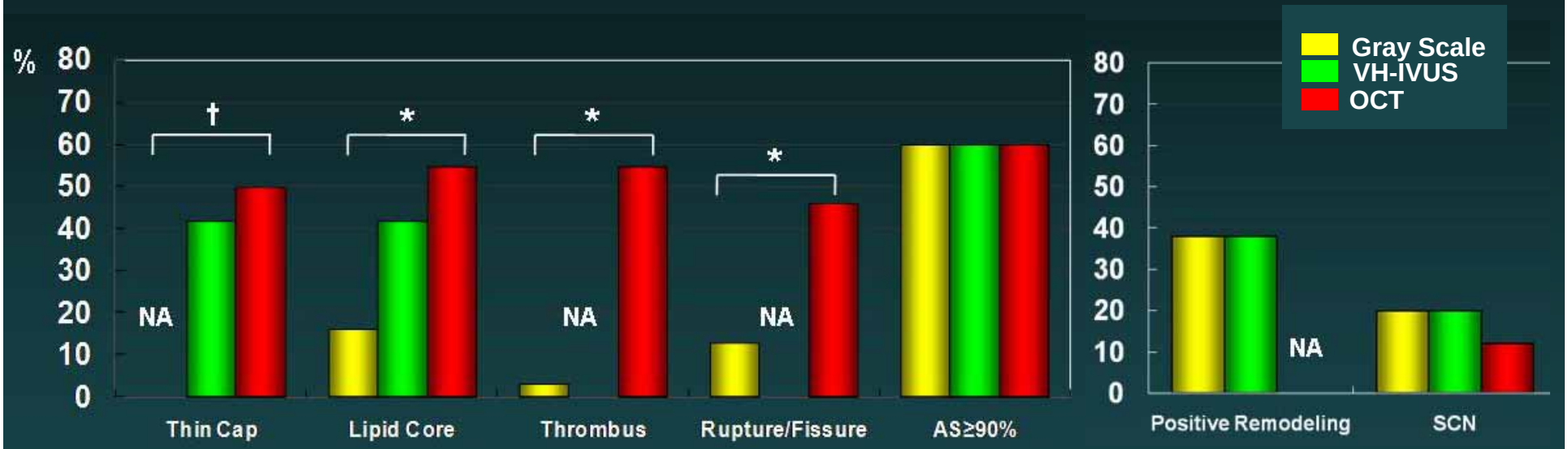

Major Criteria **Minor Criteria**

*p<0.05 among 3 modalities, †p<0.05 between GS vs. OCT, ‡p<0.05 between VH-IVUS vs. OCT

Choi et al, TCT 2008