

FFR Guided Intervention in a Patient with Coronary Artery Ectasia

Seung-Woon Rha, MD, PhD,
FACC, FAHA, FESC, FSCAI

Cardiovascular Center,
Korea University Guro Hospital, Seoul, Korea

Coronary Artery Ectasia with Significant Lesion

1. Significant Lesion?

; Is this really responsible to myocardial ischemia?

2. Onsite Invasive Lesion Assessment

1) IVUS

2) FFR

Management Option of CAE?

1. Medical Therapy; esp. when combined with significant coronary spasm.
2. Surgery
3. PCI
 - 1) Simple POBA
 - 2) 'Parallel Stenting'
 - 3) Large Peripheral Stenting
 - 4) Others; Atheroablation...

KUMC Guro Experience

1. 'Parallel Stenting' using two DESs (Sirolimus-eluting stent; Cypher)
 2. POBA only by using Large 'Coronary Balloon'
 3. Simple Stenting by Large 'Peripheral Stent'
- ** Functional Lesion Assessment by FFR/IVUS

Six-month Follow Up of 'Parallel Stenting' using Two Sirolimus-Eluting Stents in an Ectatic Coronary Artery Stenosis

Seung-Woon Rha, MD, PhD,
FACC, FAHA, FESC, FSCAI

Cardiovascular Center,
Korea University Guro Hospital, Seoul, Korea

Backgrounds

1. Sirolimus-eluting stent (SES; Cypher™, Cordis) has proved effective in reducing restenosis in a variety of coronary lesions.
2. However, one of practical limitation in using SES is limited available stent diameter for a particular subset of lesions which have larger reference vessel diameter than ordinary native coronary artery disease such as degenerated saphenous vein graft or ectatic coronary artery disease.

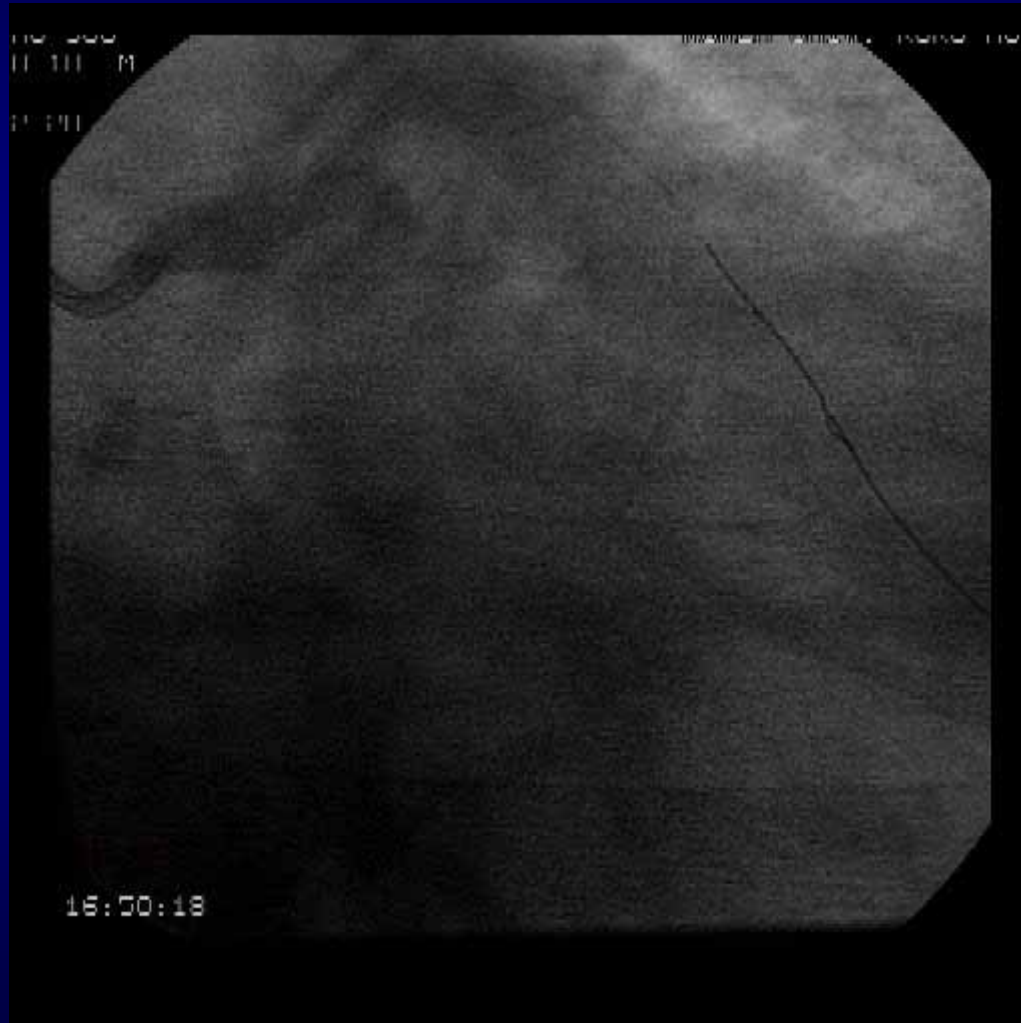Case History

1. Pt's ID; YS Yoo, 57/M
2. C.C: presented with typical sustained chest pain
3. Prior intervention / Medical history
; AMI (Inferior Wall) in 1992 - POBA in mid RCA
4. Risk factors
; Smoking (+), DM(+), Hypertension (-)

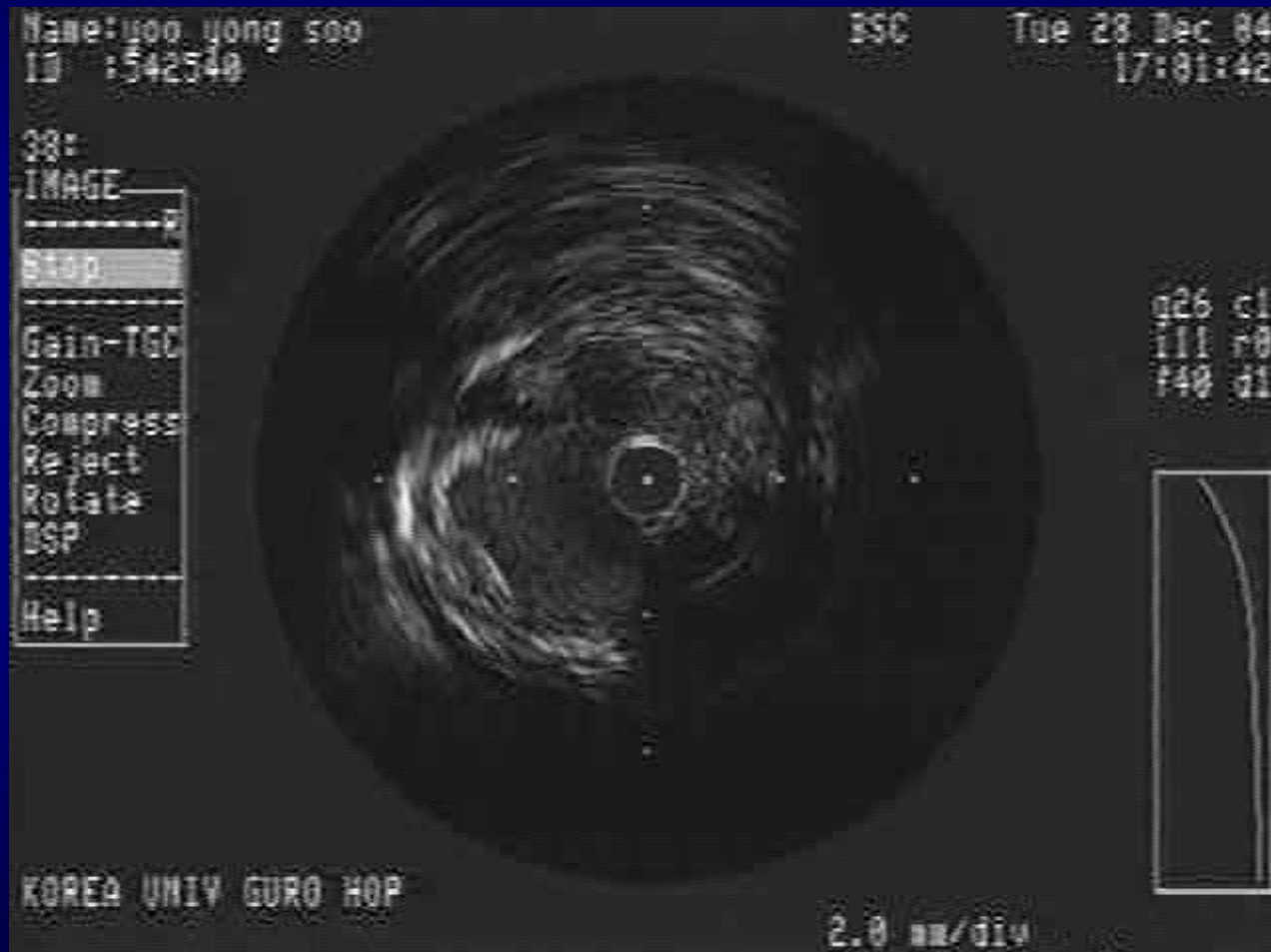
Intended strategy

1. We report a challenging case of 'parallel stenting' using two Cypher stents in an ectatic coronary artery disease.
2. Patient was clinically and angiographically followed up to 6 months.

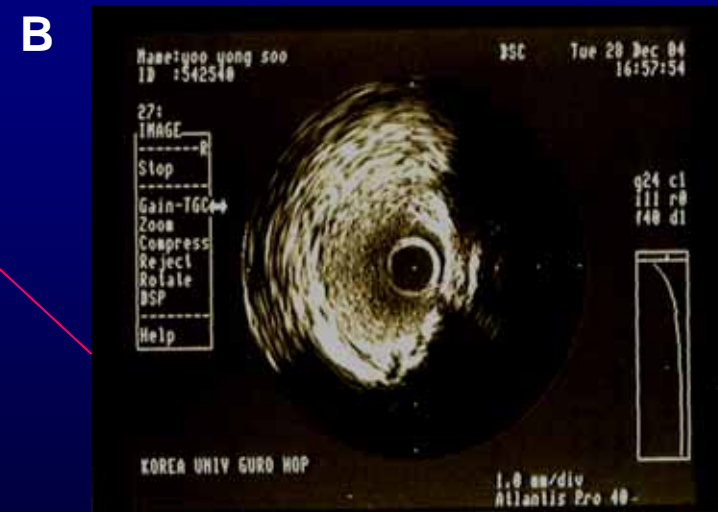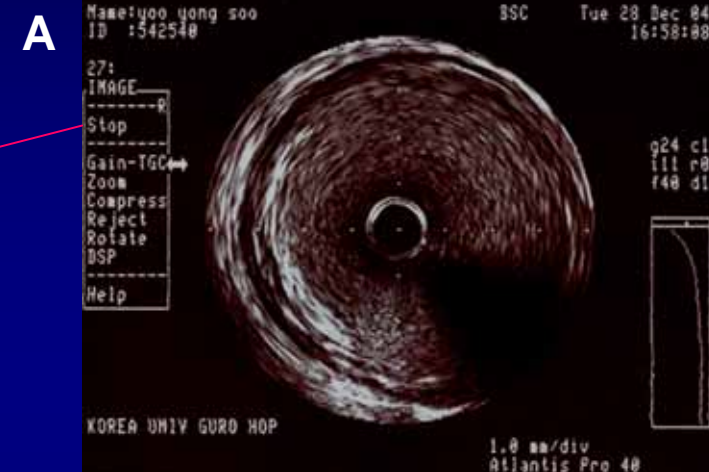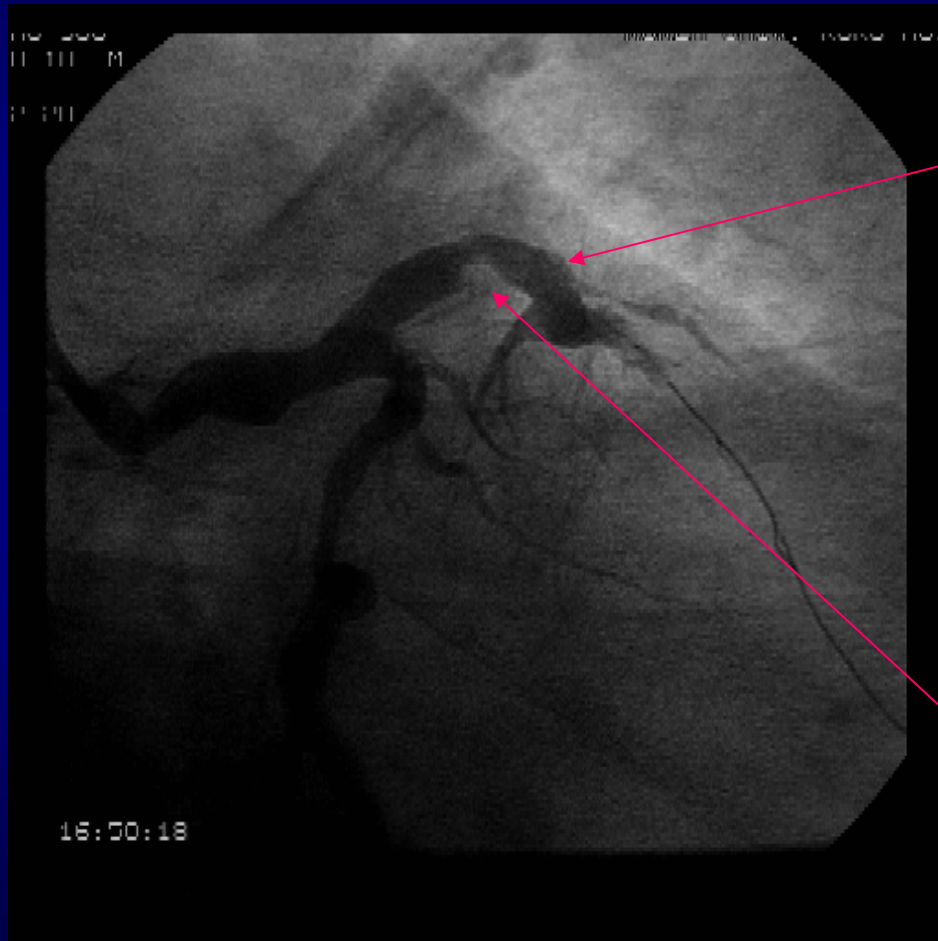
Pre-PCI CAG



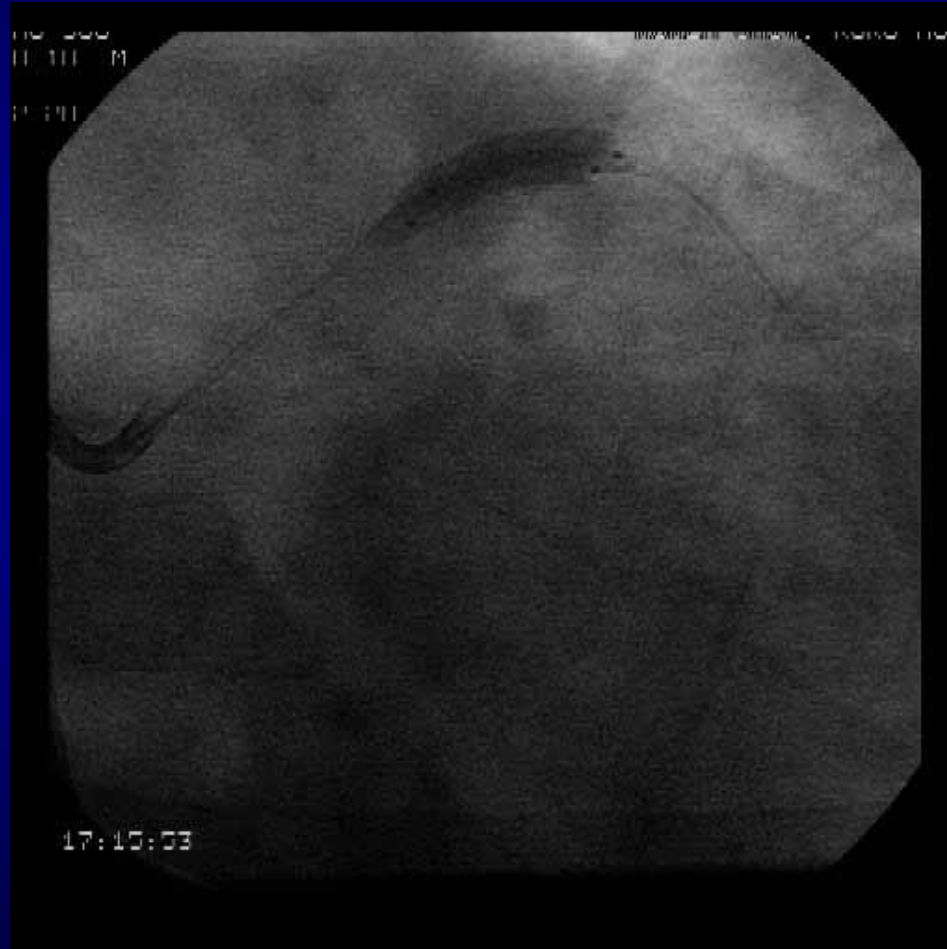Pre-PCI IVUS



Baseline Coronary Angiogram and IVUS Findings (A; distal reference=6.8 mm B; lesion, minimal luminal diameter=2.2 mm)

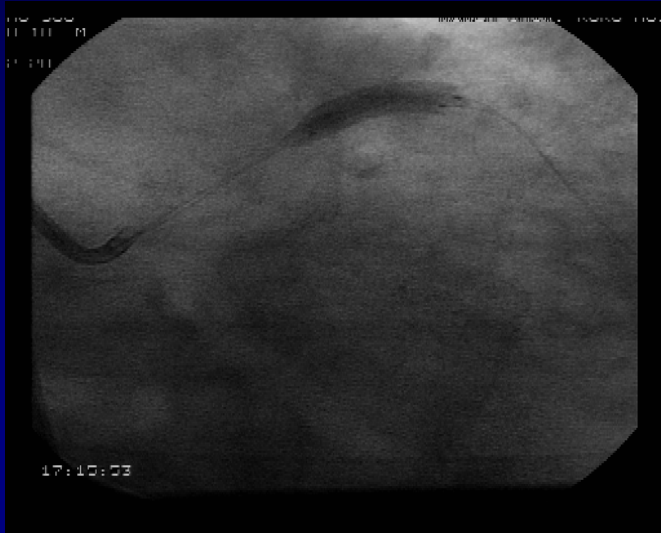


Parallel Stenting



Parallel stenting

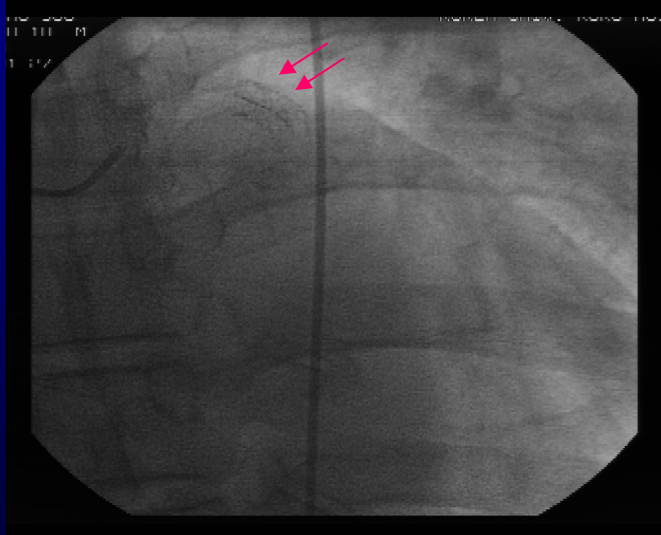A



1. After two wires positioned in proximal LAD lesion, predilation with 4.0 X 20 mm balloon was done (14 atm for 20 seconds).

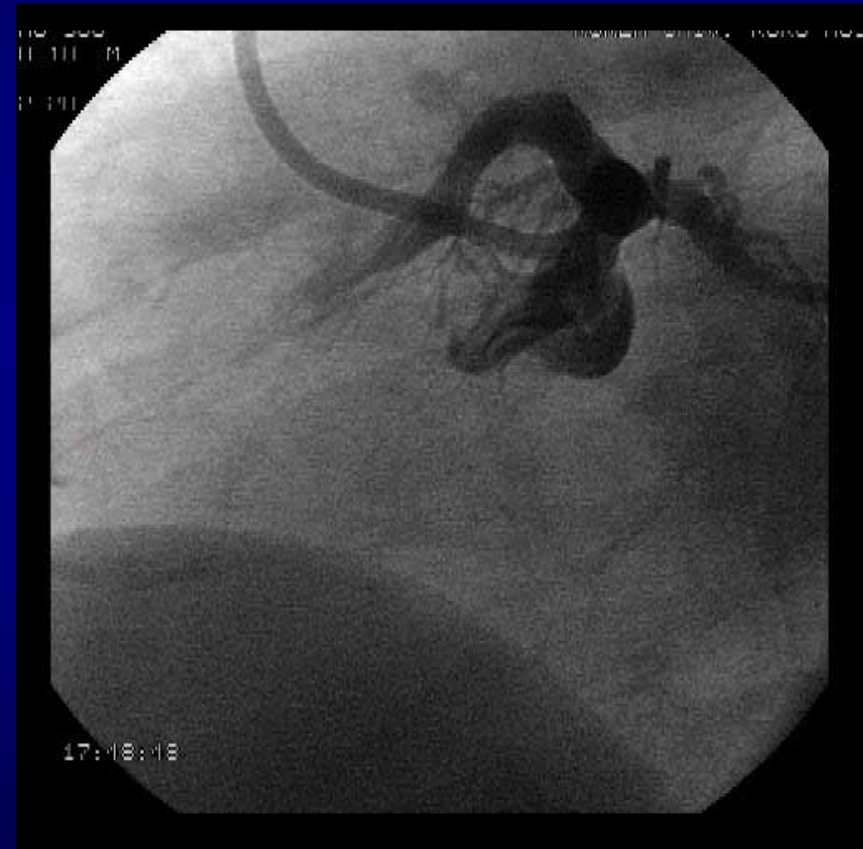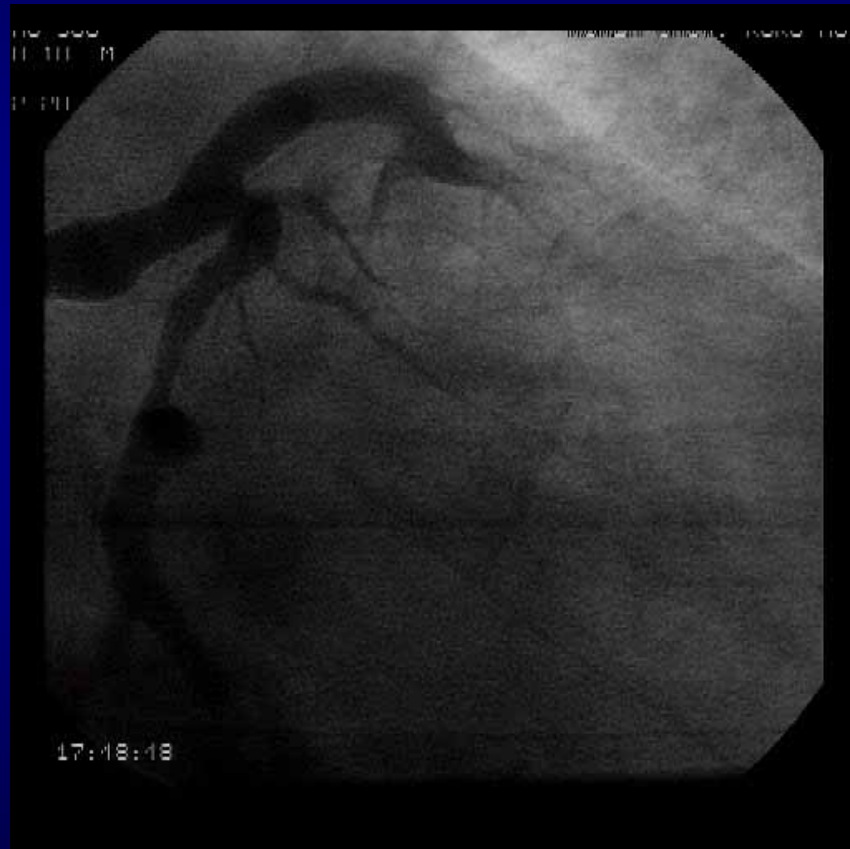
2. Two SESs (3.5 X 18 mm) were simultaneously deployed without immediate complications (Upper & Lower SES; 22 atm each for 10 seconds, A-during parallel stenting, B-post stenting two parallel visible metal stents).

B

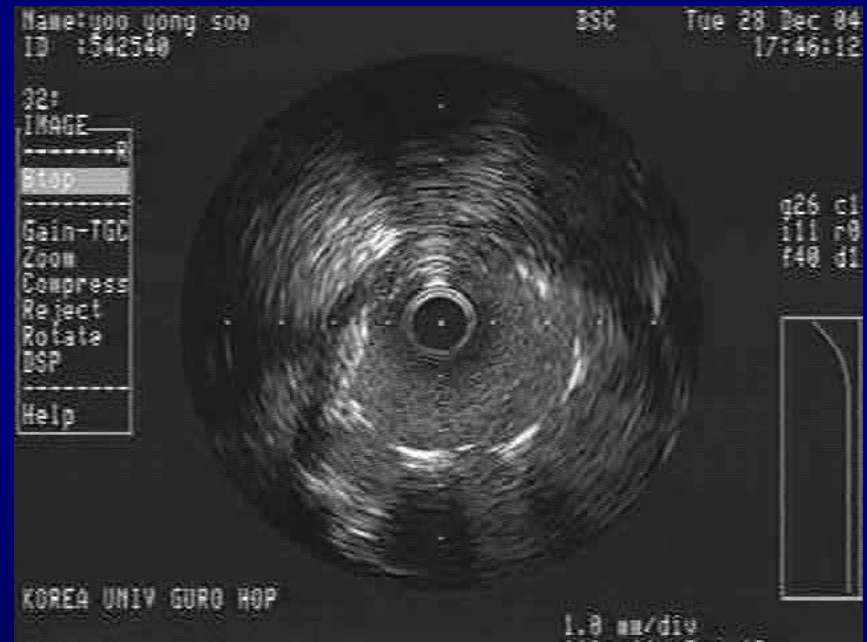
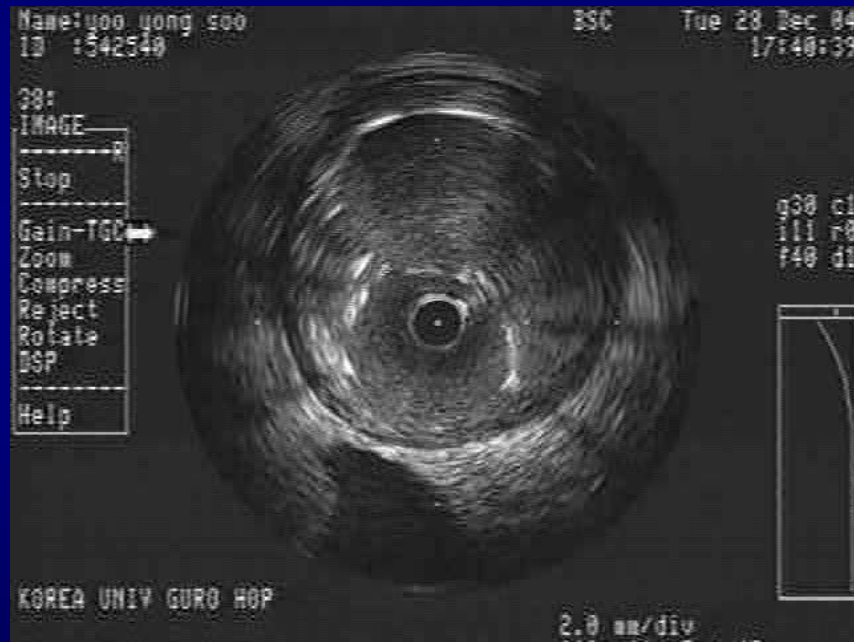
3. The stents were post-dilated using two 4.0 X 20 mm balloons by 'parallel ballooning' technique (14 atm for 20 seconds).

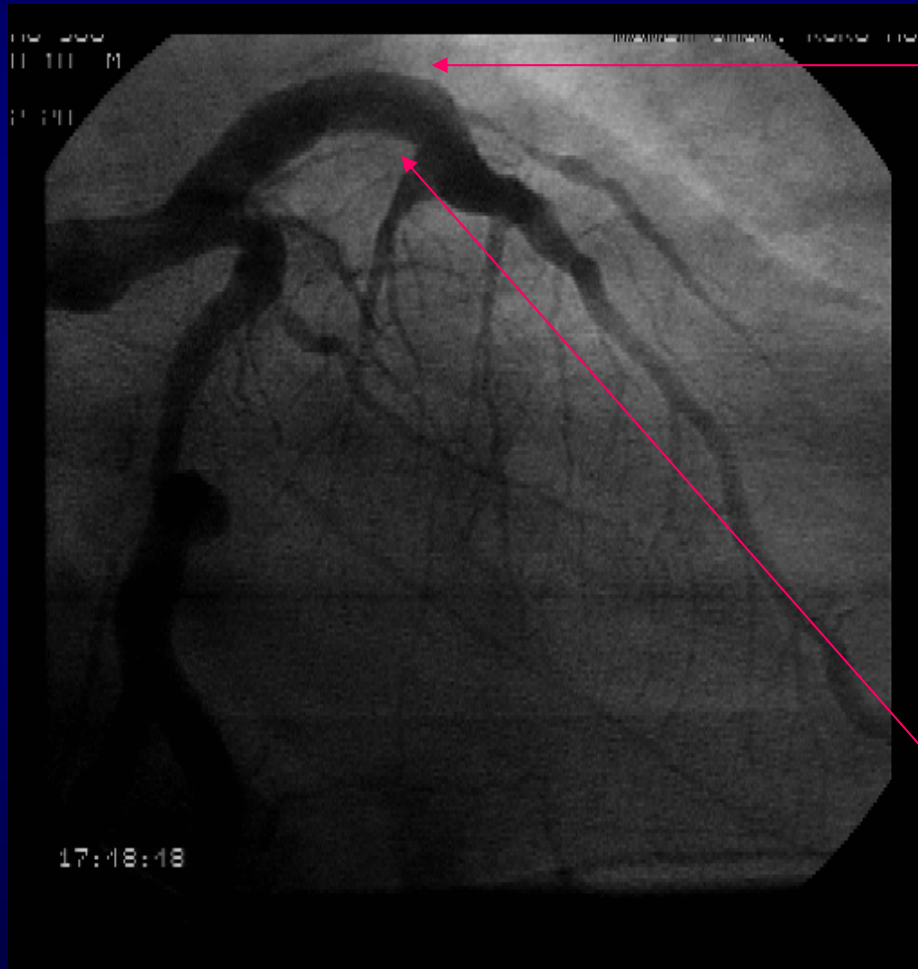
Post-PCI CAG



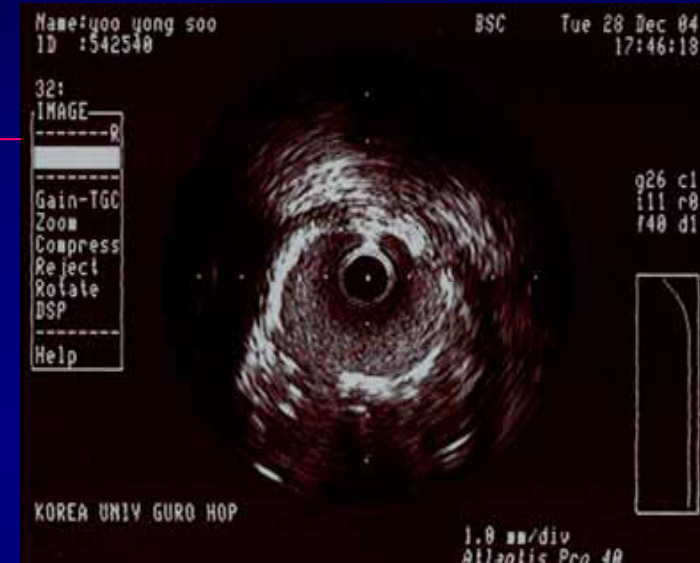Post-PCI IVUS



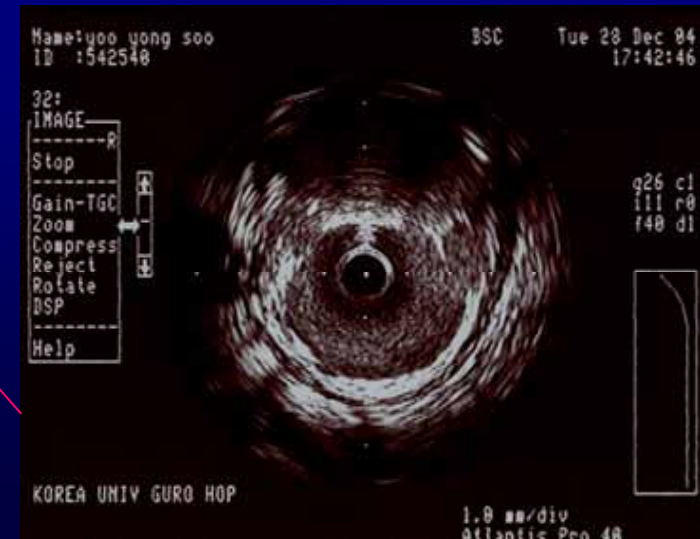Final Angiograms and IVUS Findings (A - at upper SES, B - at lower SES)



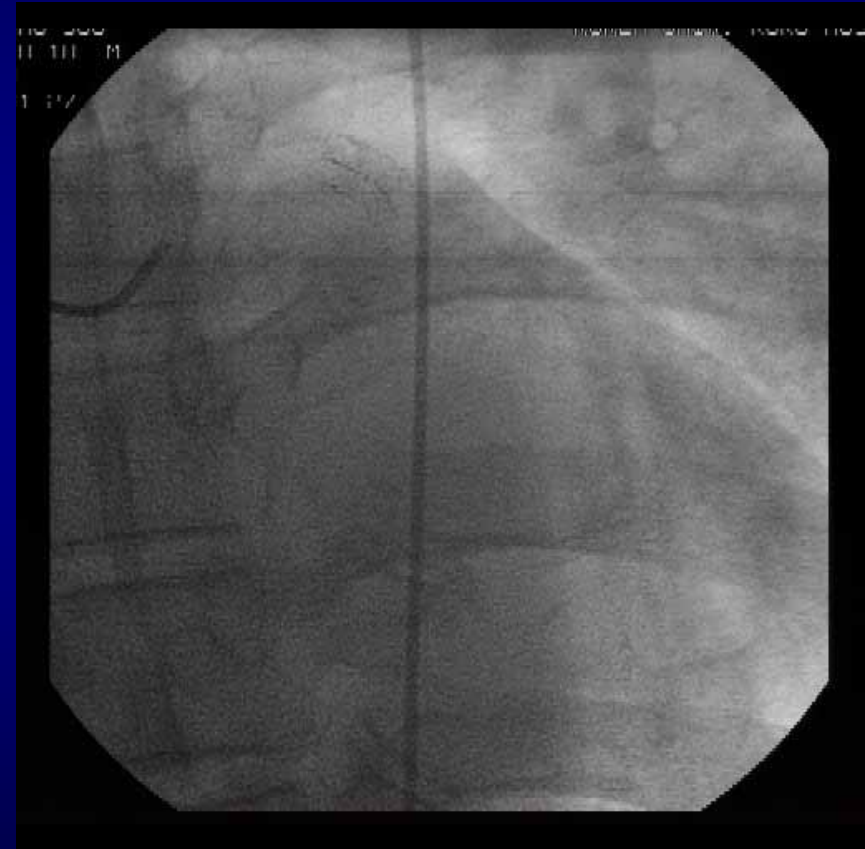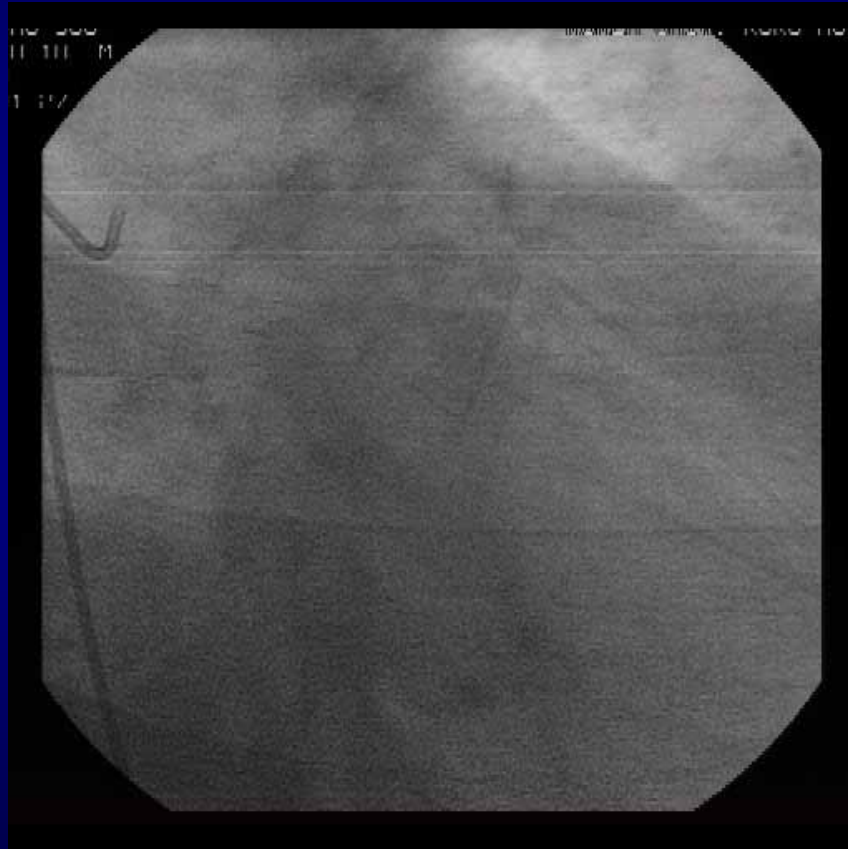A



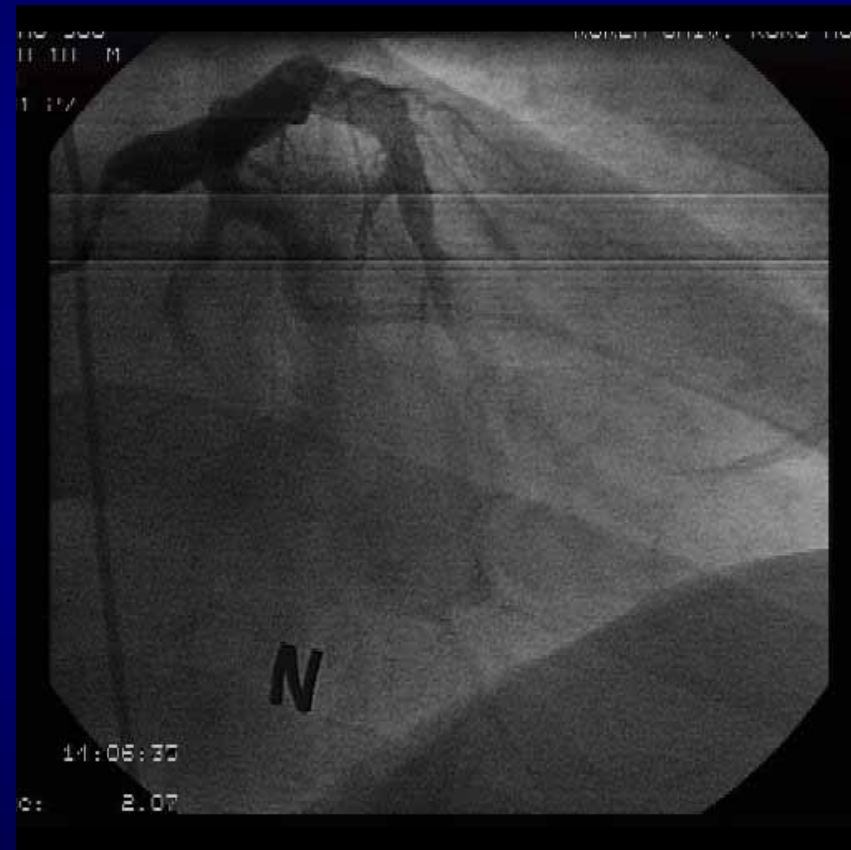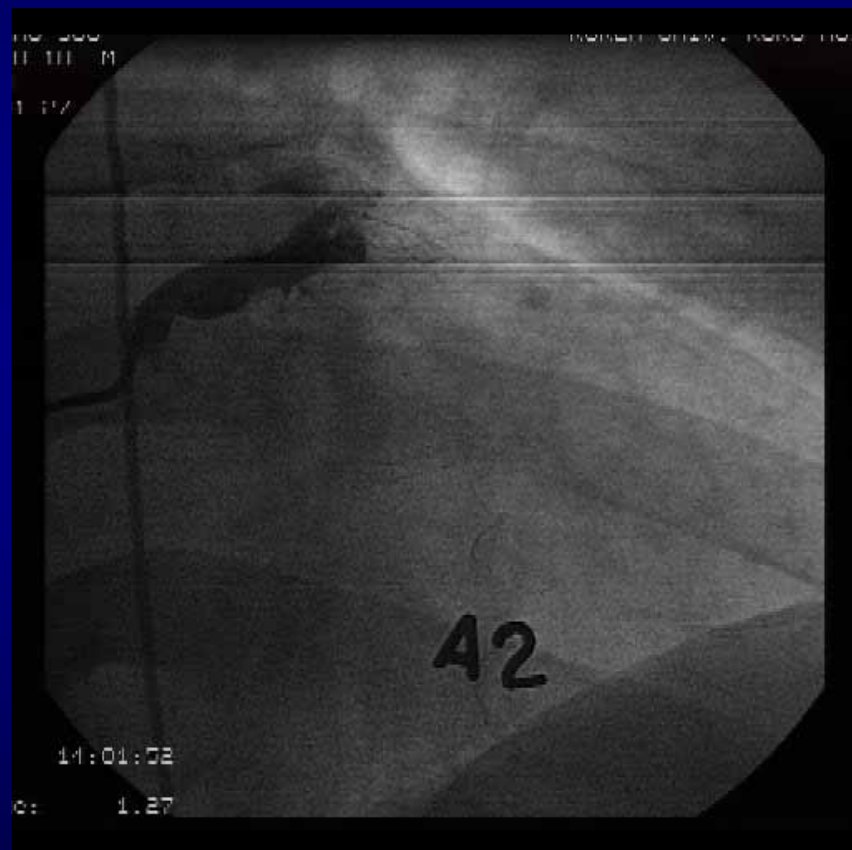B



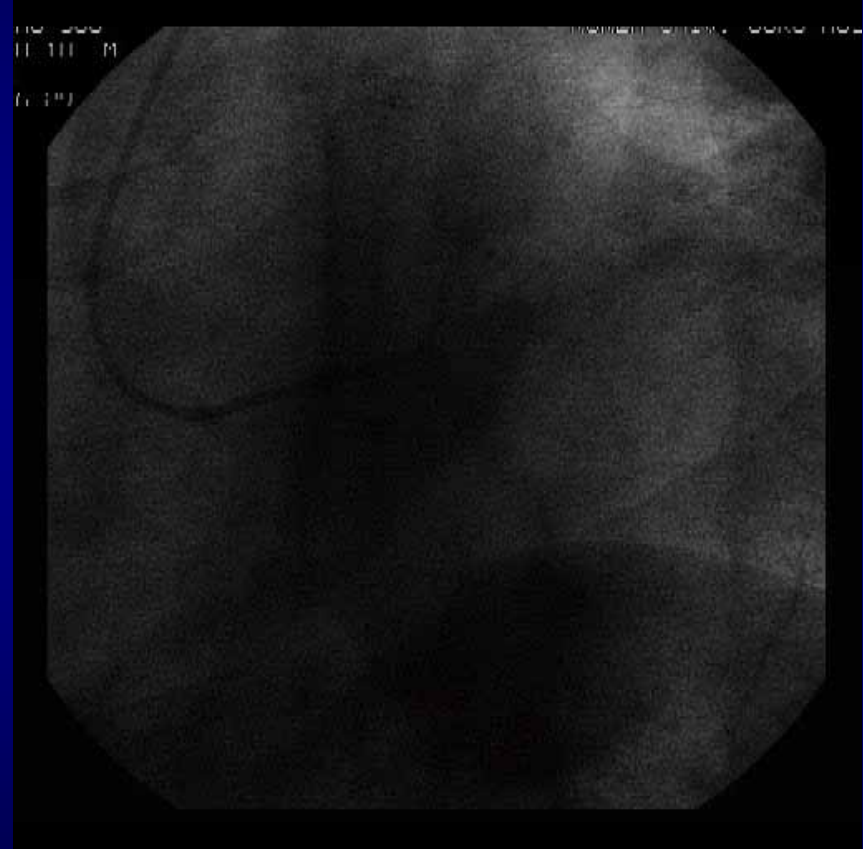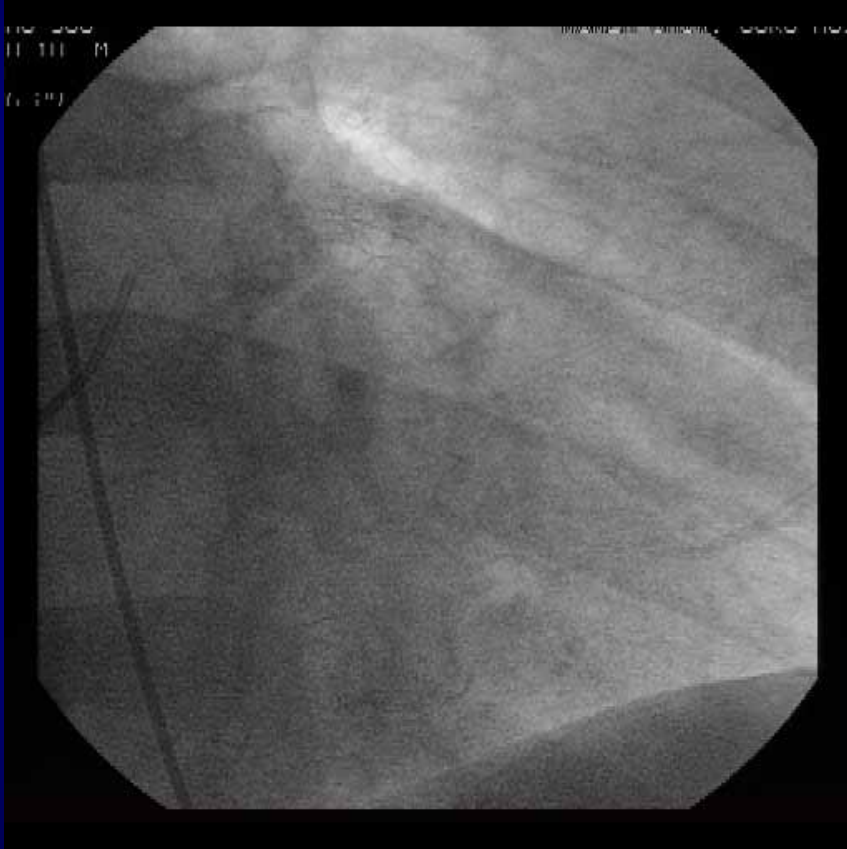CAG at 1 - Month



Ach Provocation Test at 1-month



CAG at 6-Month



* Abnormal opacity (Neomembrane) in new metallic carina of two parallel stents

Summary

1. A 57 year old male with unstable angina was admitted to the emergency room with severe chest pain.
2. Coronary Angiogram and IVUS finding showed a severe discrete eccentric stenosis with unstable plaques at proximal LAD.
3. Simultaneous 'Parallel Stenting' using two SESs (3.5X18 mm) was done without underexpansion or malapposition.
4. At 1-month Coronary Angiogram
; patent and clean previously implanted two parallel stents but Ach-induced spasm was noted.
5. At 6-month Coronary Angiogram
; abnormal radioopacity was observed at the new carina of two parallel stents, suspicious of thin, organized thrombi.
→ IVUS was not done due to risk of stent thrombosis and patient's poor cooperation
→ Seemed not to be associated with clinical events.

Message

1. 'Parallel stenting' for an ectatic coronary artery lesion appears to be clinically safe and feasible technique.
2. Coronary provocation test should be considered when a patient complains chest pain after DES implantation.
3. Six-month CAG follow up showed abnormal opacity at the new carina of parallel stents (Neomembrane similar to LM bifurcation kissing stenting), appears to be safe but needs long-term follow up.

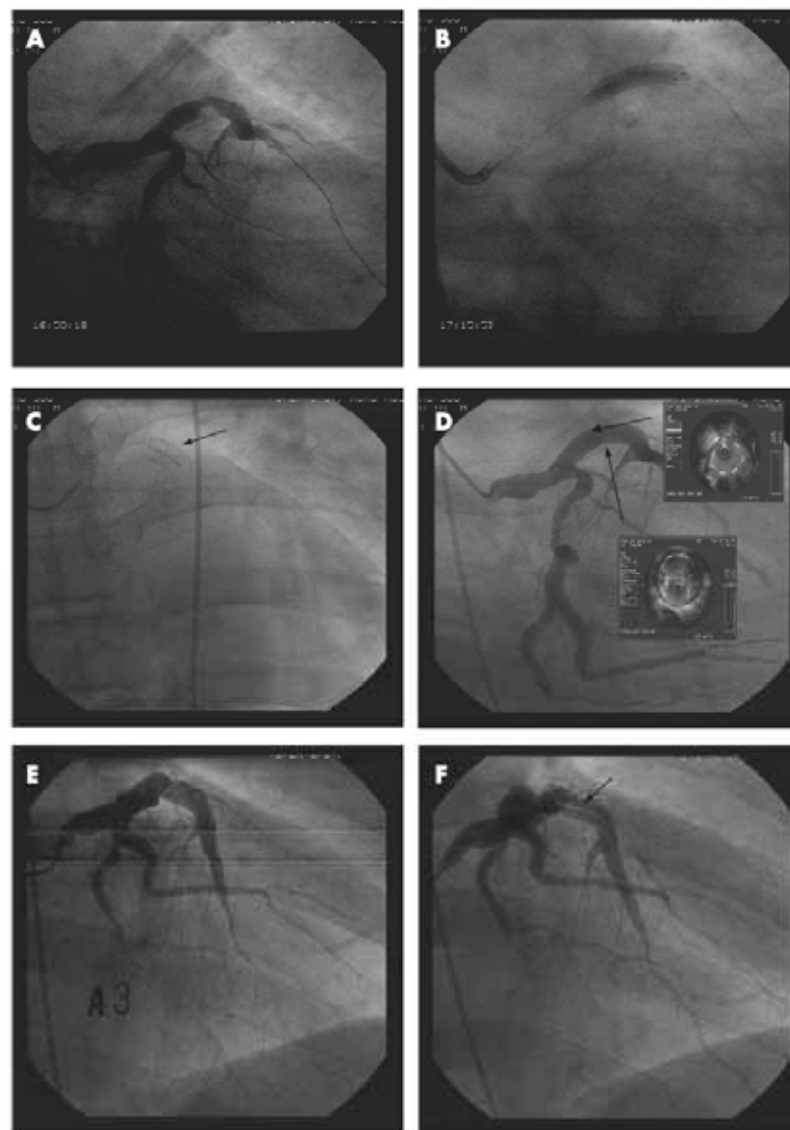
Parallel stenting using two sirolimus-eluting stents in an ectatic coronary artery stenosis

With the introduction of the drug-eluting stent (DES), re-stenosis rates have been reduced. In saphenous vein graft or ectatic coronary artery disease due to large vessel diameter their use is precluded. We report a challenging case of implantation of two sirolimus-eluting stents (SES; Cypher; Cordis) parallel to each other in an ectatic vessel.

A coronary angiogram (CAG) and intravascular ultrasound (IVUS) examination carried out on a 57-year-old man with unstable angina showed severe eccentric stenosis in the ectatic proximal left anterior descending artery (panel A). The lesion was predilated by a "parallel ballooning" technique. Two 3.5 × 18 mm SES were simultaneously deployed (upper and lower SES; 22 atm each; panel B). Final angiography and IVUS showed two widely patent stents without underexpansion or malposition (panel D). At 1 month, the patient presented with rest angina, and subsequent CAG showed patent parallel stents, but the acetylcholine provocation test showed significant diffuse vasospasm distal to the ectatic portion with typical chest pain (panel E); a 200 µg intracoronary nitroglycerine injection reversed the vasospasm and the chest pain. The 6 month routine CAG showed a peculiar membrane in the new stent carina, which is a similar observation to that after the kissing stenting in the left main bifurcation lesion (panel F). This membrane does not seem to be related to clinical events.

In lesions which have a large reference diameter one can consider parallel stenting using DESs as a new intervention strategy. It also depicts the association of vasospastic angina with coronary ectasia.

Seung-Woon Rha, Sunil P Wani, Dong Joo Oh
kuhohdj@yahoo.co.kr



Coronary angiogram showing severe eccentric stenosis in the proximal left anterior descending artery at baseline (panel A), during parallel stenting (panel B). Fluoroscopic visualisation of two implanted parallel SESs (panel C). Post stenting angiogram with intravascular ultrasound delineation of superior and inferior stents (panel D). One month follow-up angiogram showing diffuse severe vasospasm with acetylcholine injection (panel E). Six month follow-up angiogram showing the new membrane between the two stents (arrow, panel F).

Revascularization of an Ectatic Coronary Artery Stenosis by Plain Old Balloon Angioplasty

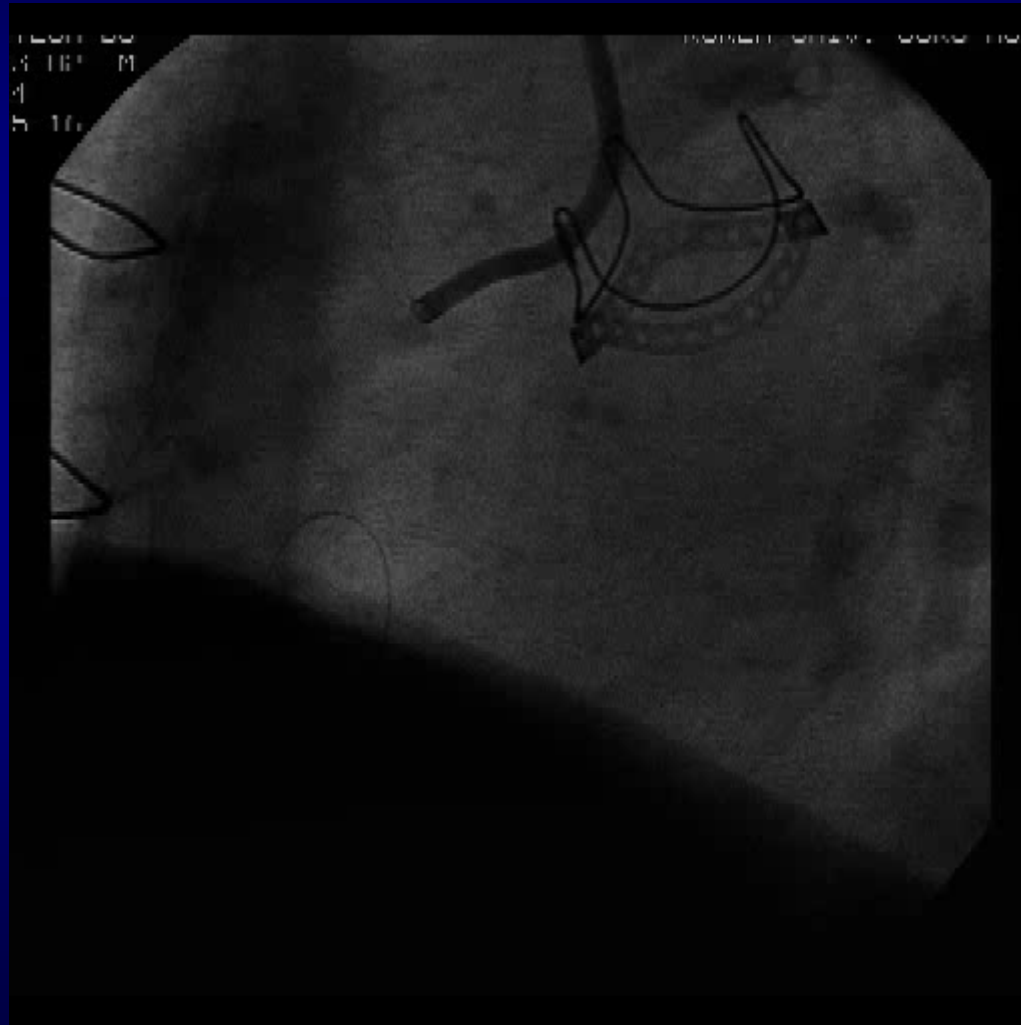Seung-Woon Rha, MD, PhD,
FACC, FAHA, FESC, FSCAI

Cardiovascular Center,
Korea University Guro Hospital, Seoul, Korea

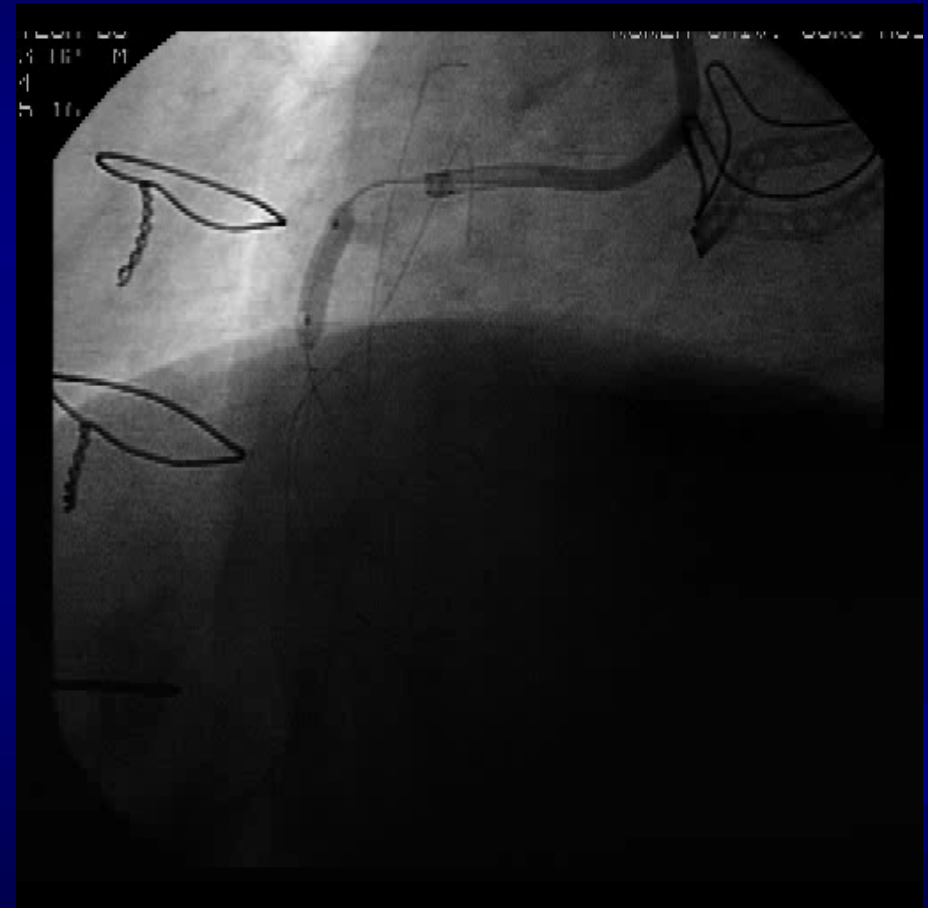
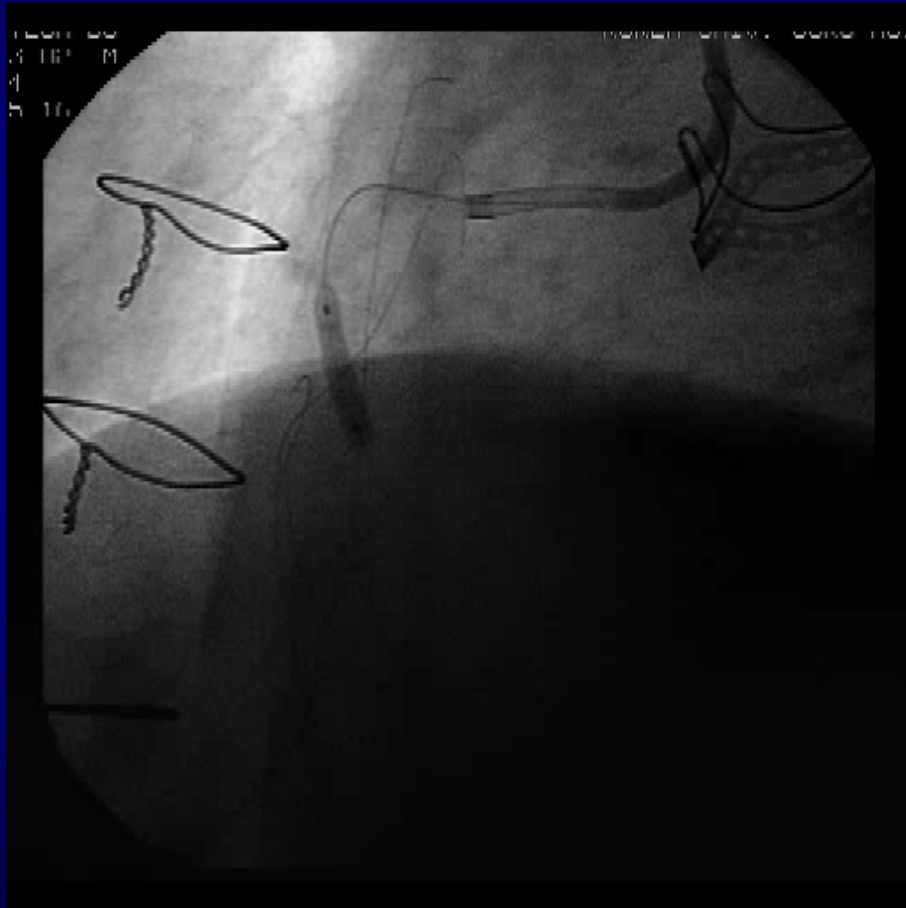
Case History

1. Pt's ID; HD Jang, 57/M
2. C.C: presented with typical sustained chest pain
3. Prior intervention / Medical history
;AVR op (2006.4 CE 21mm), s/p CABG (2006.10.19), AAA
4. Risk factors
; Smoking (+), DM(+, insulin), Hypertension (-)

Baseline Coronary Angiogram

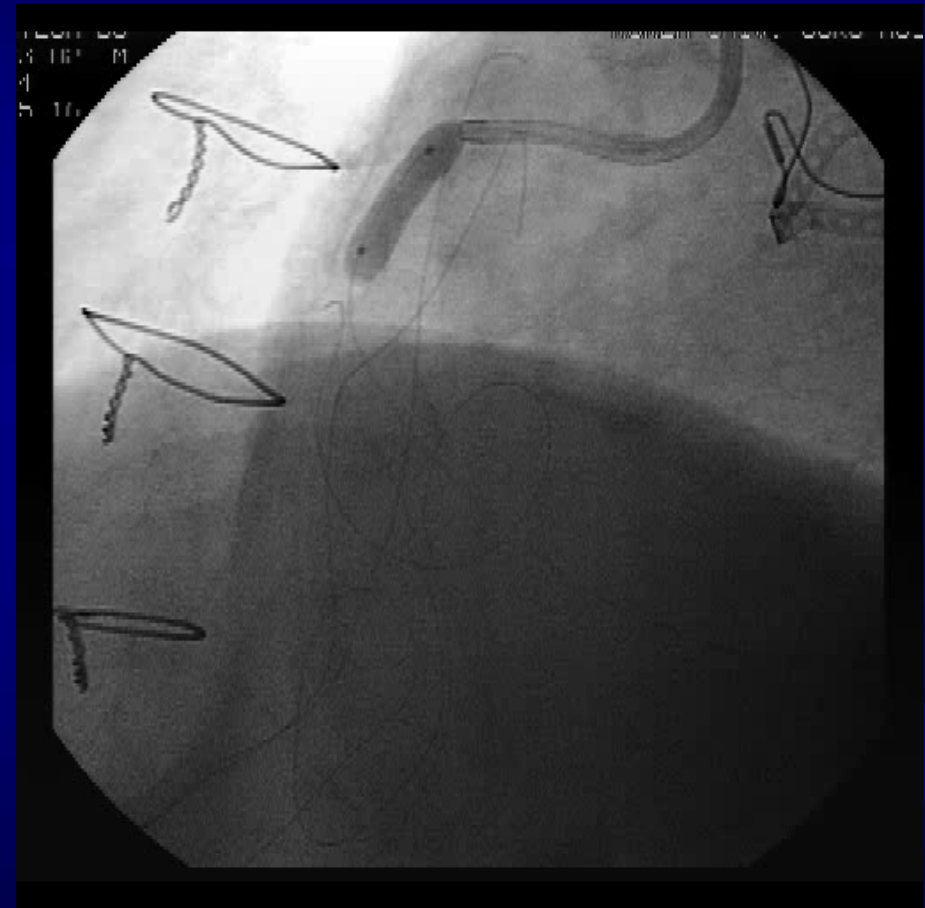
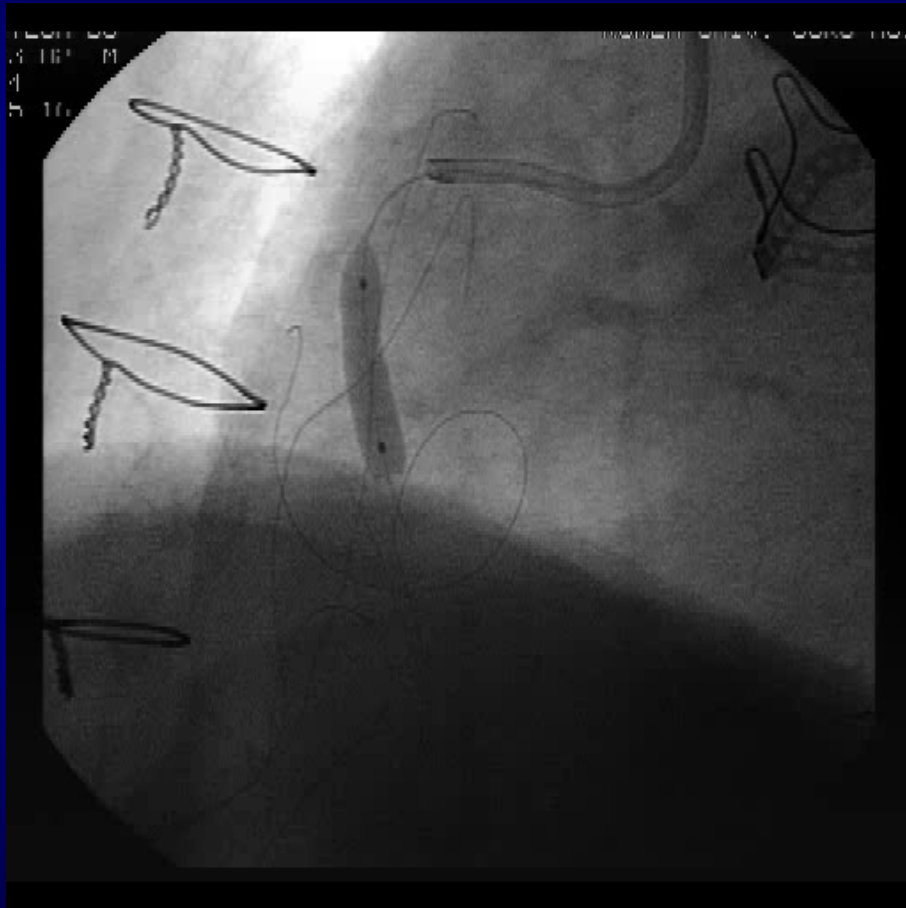


POBA 1



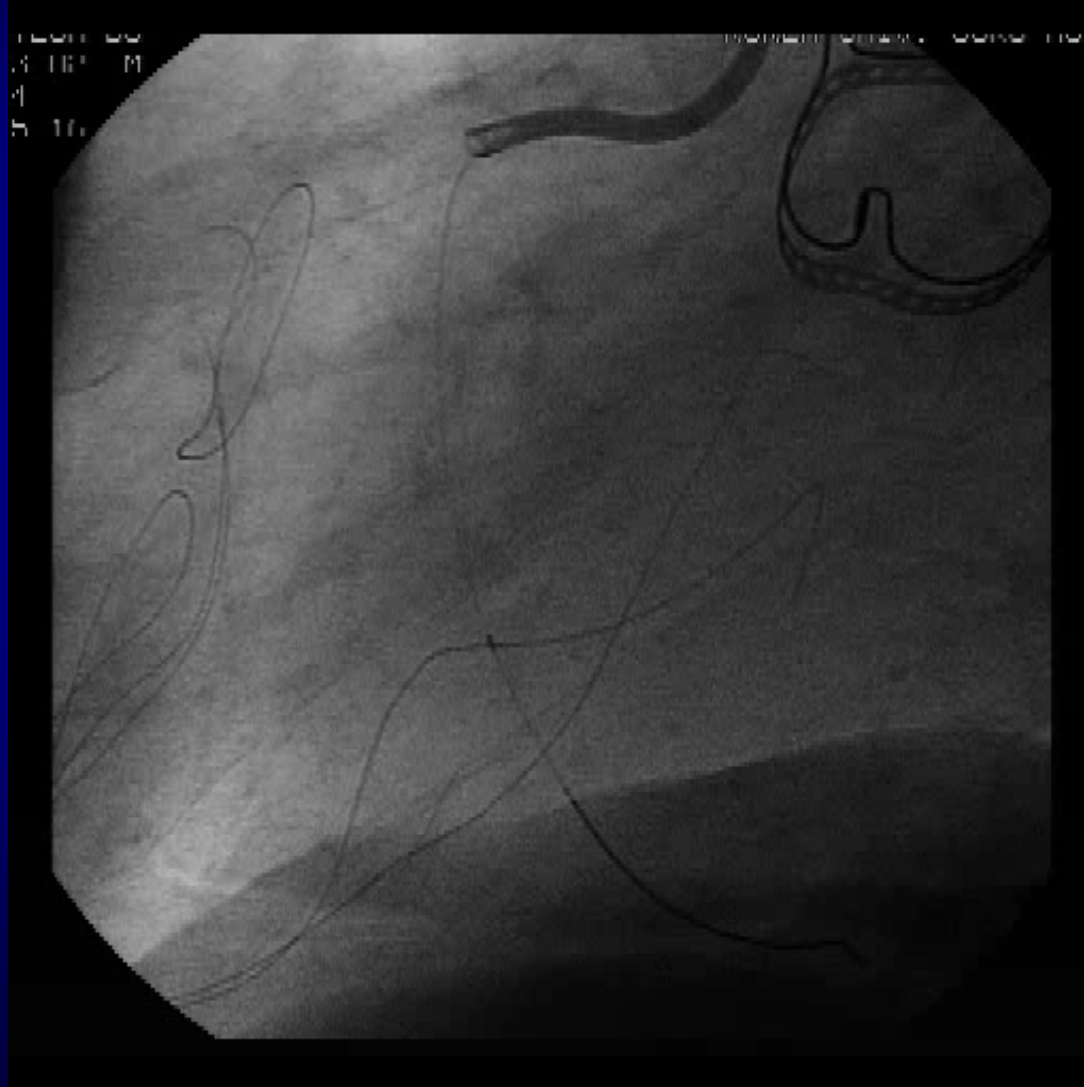
Avita 3.0 X 14 mm

POBA 2

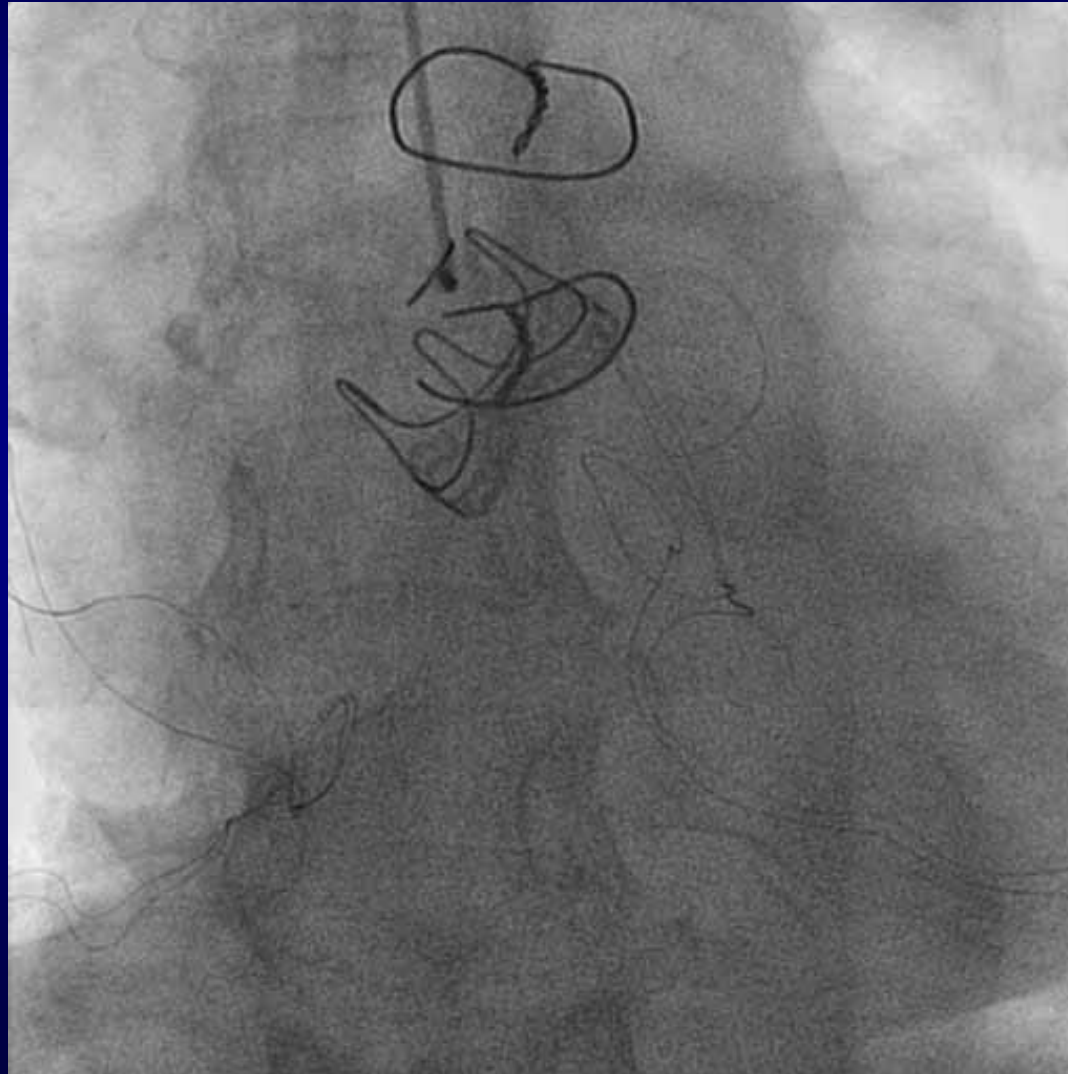


Mercury 4.5 X 20 mm

Final Index Angiogram



Follow Up Angiography at 6 Month



Successful Revascularization using Peripheral Stent in a Patient with Coronary Artery Ectasia

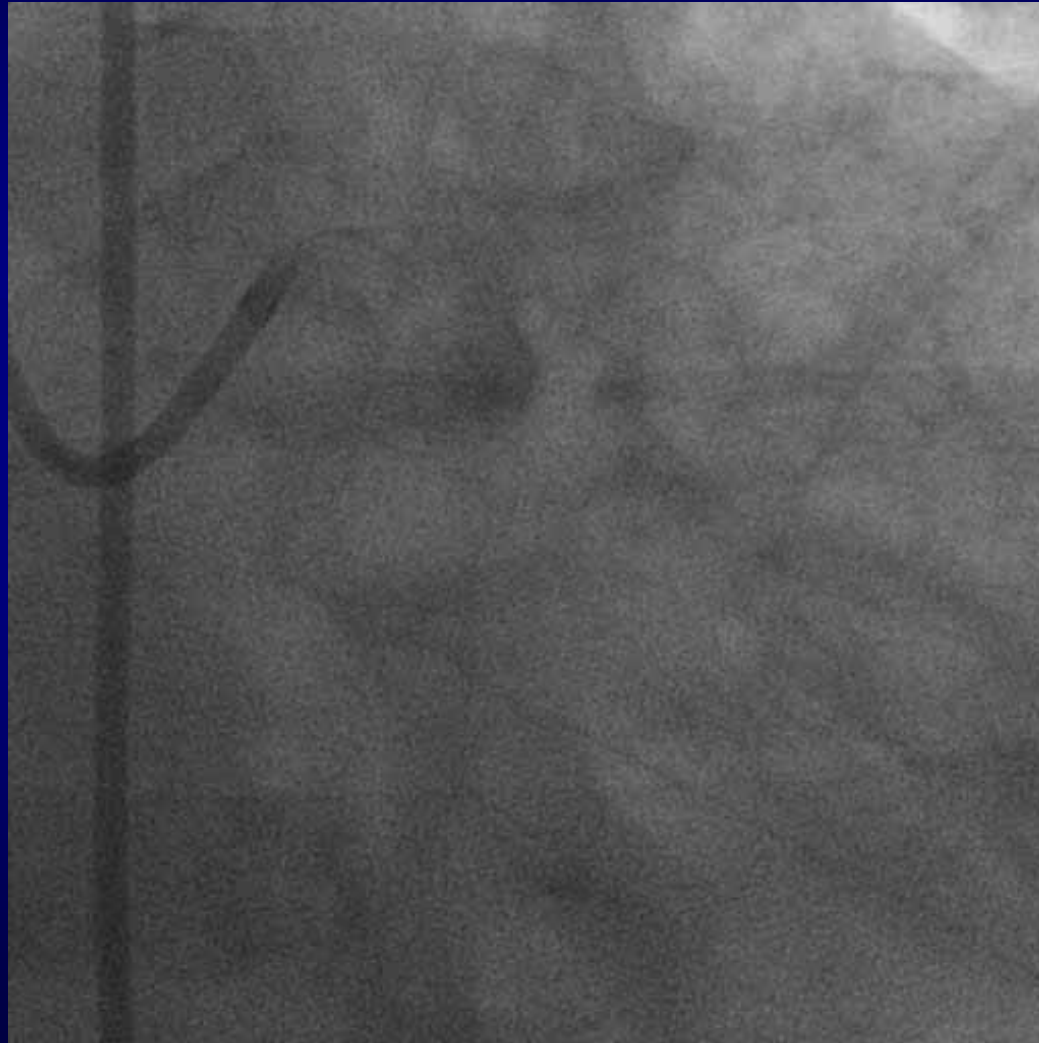
Seung-Woon Rha, MD, PhD,
FACC, FAHA, FESC, FSCAI

Cardiovascular Center,
Korea University Guro Hospital, Seoul, Korea

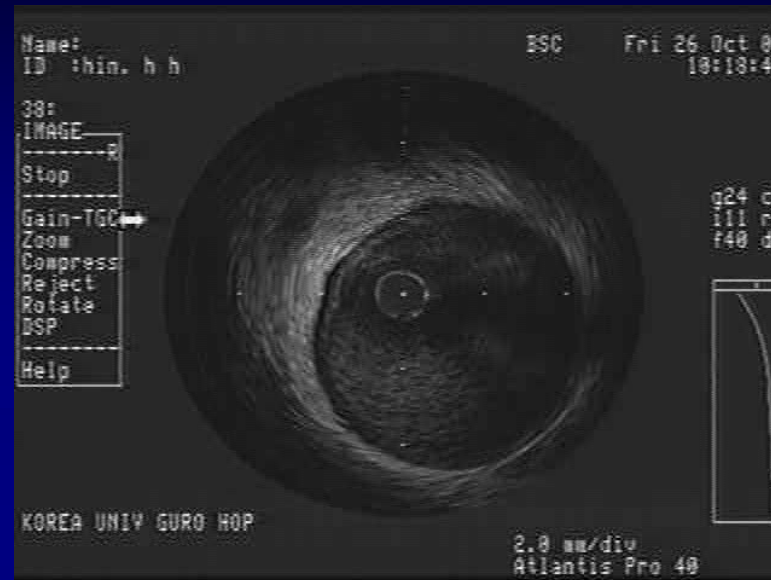Case History

1. Pt's ID; HH Shin, 49/M
2. C.C: presented with typical effort-induced chest pain
3. Risk factors
; Smoking (+, 10 yrs), DM(-), Hypertension (-), Hyperlipidemia (-), Obesity (+)
4. Lab Findings
 - 1) ECG; ST depression in II, III
 - 2) Echo; Normal LV function, No RWMA

Baseline Coronary Angiogram



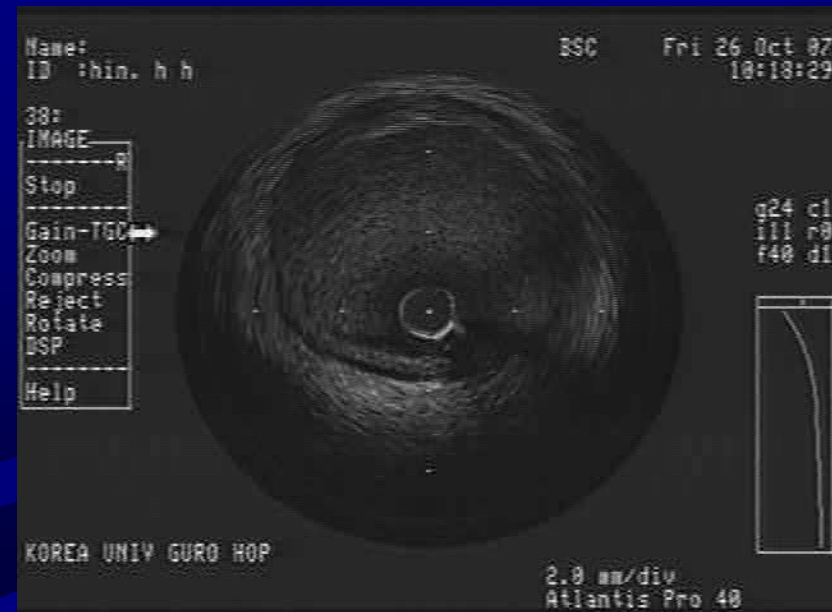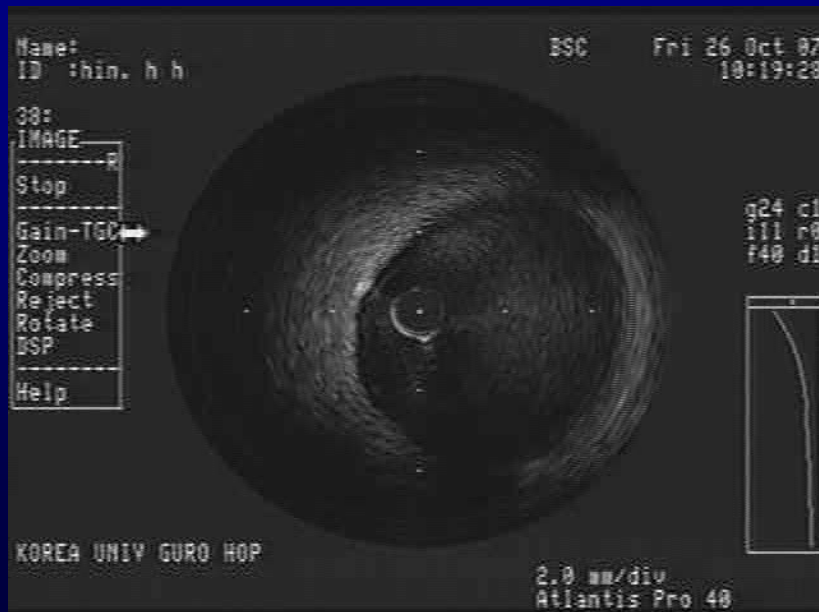Pre PCI IVUS Finding



Lesion

Proximal

Distal

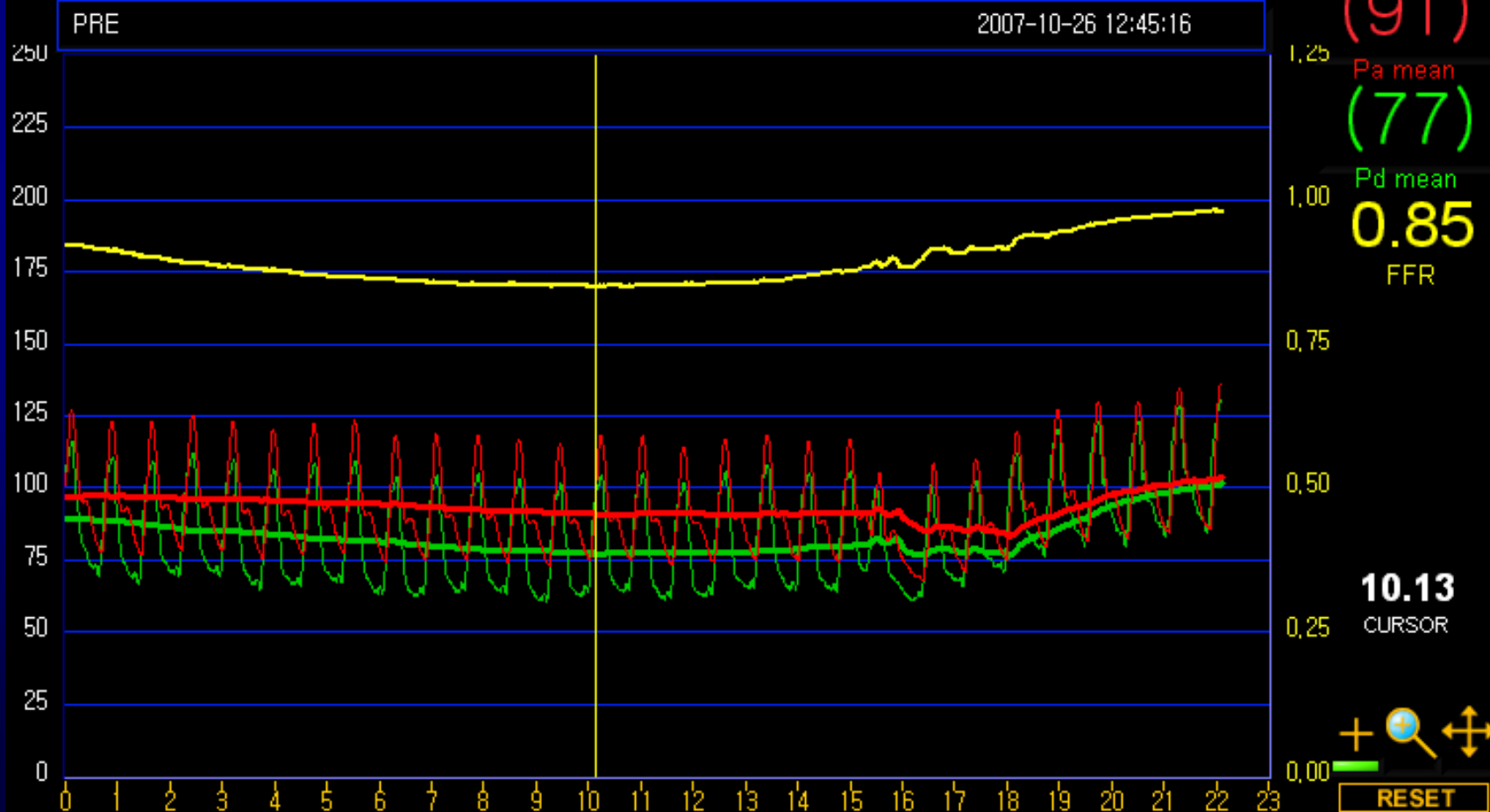


FFR Measurement at LCX

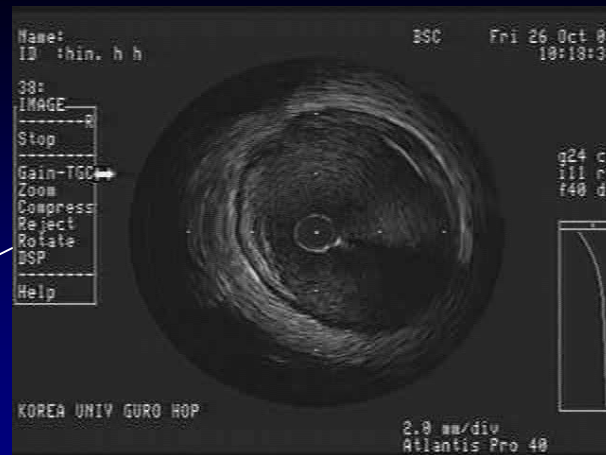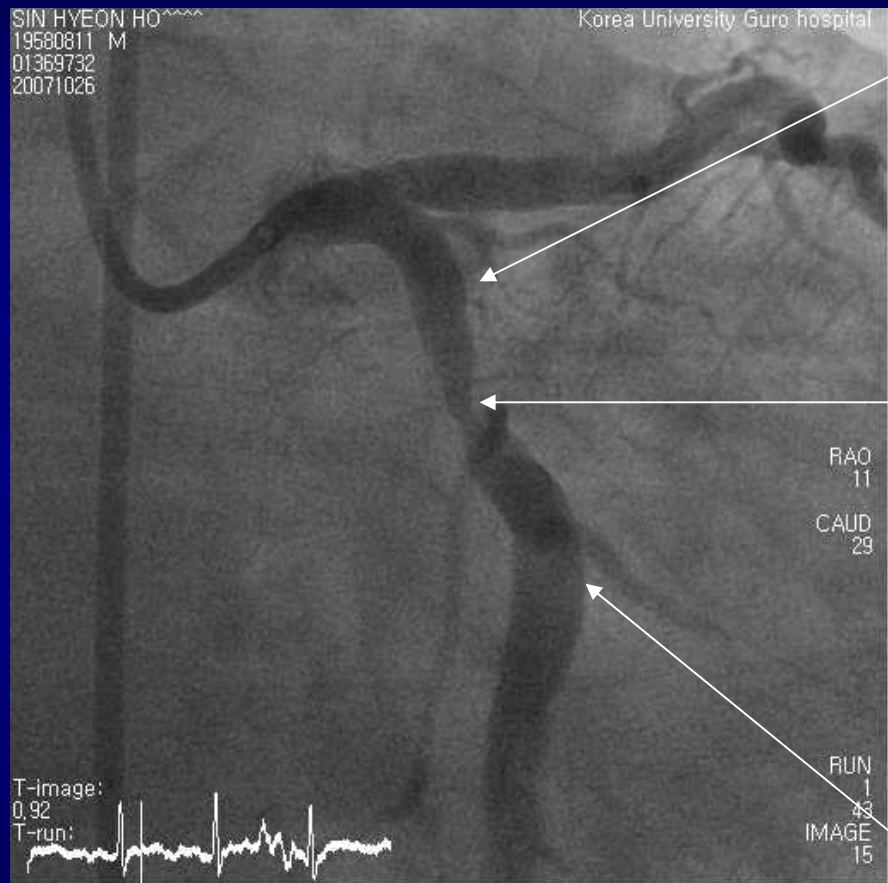ARCHIVE CUSTOM	c:\WRADI\DOWNLOAD\2007-12-05						COM 3
FOLDER	PATIENT ID	DATE	TIME	VESSEL	PROCEDUR	ACTION	TYPI SIZE
2007-12-05	POST	2007-10-26	13:12:53				FFR 18Kb
2007-09-04	PRE	2007-10-26	12:45:16				FFR 22Kb
2007-07-04							
2007-05-17							



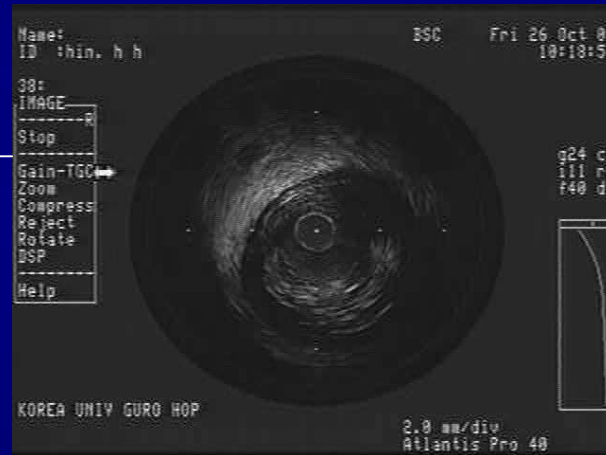PRINT **EDIT** **RENAME** **EXPORT** **ERASE** **SETUP**



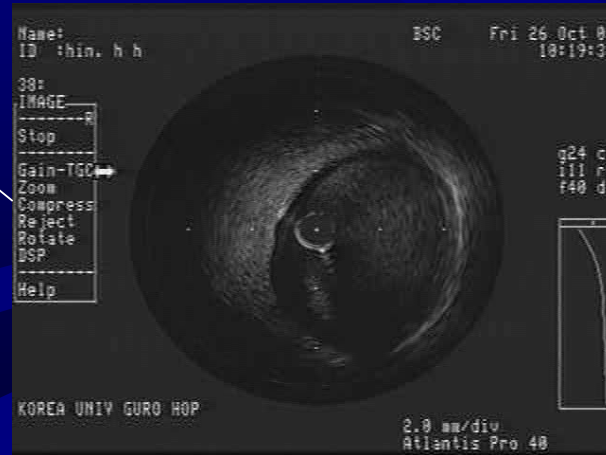Pre - Intervention



Prox Ref = 6.7 mm

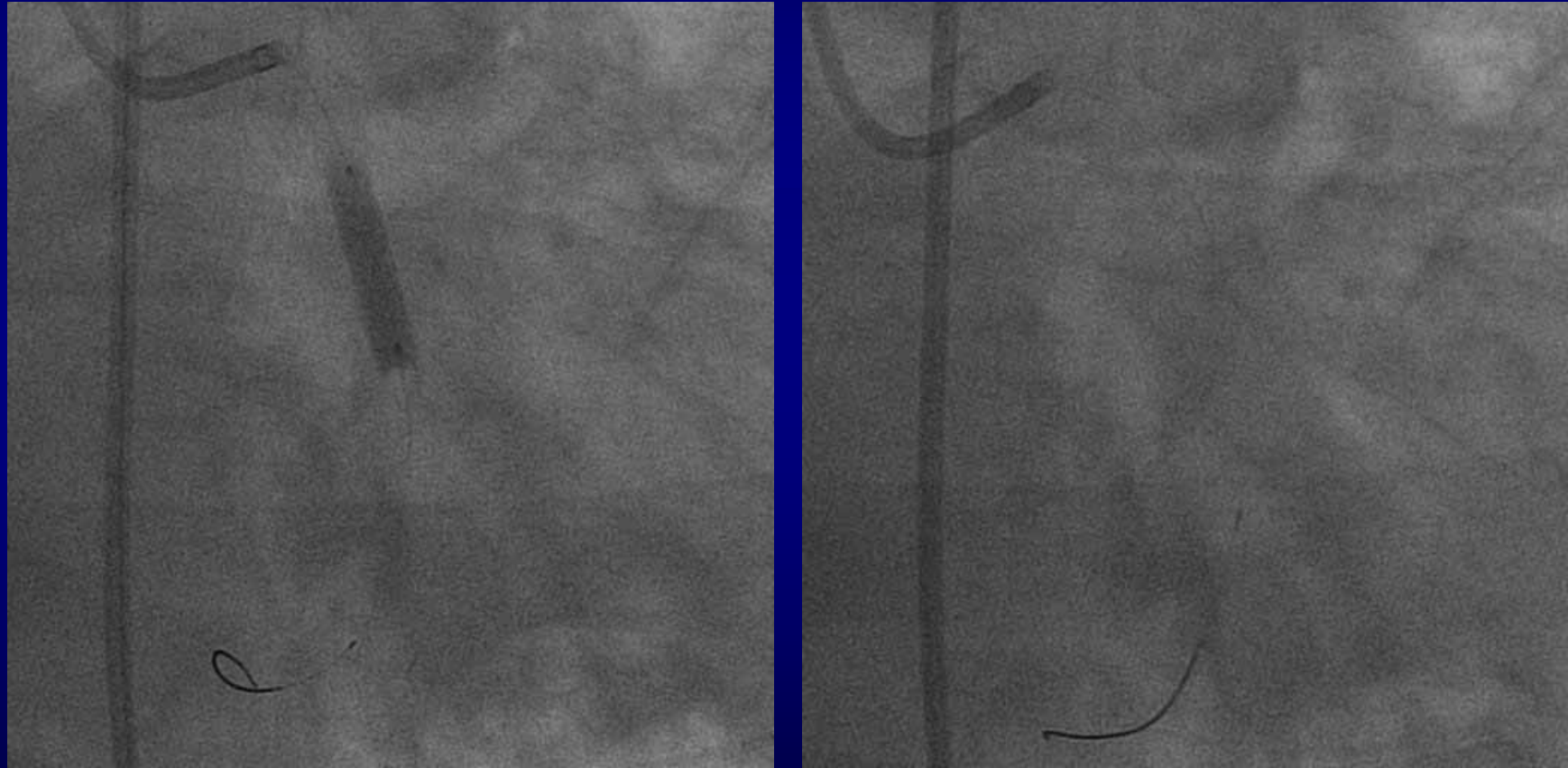


MLD 2.5 mm AS; 82%



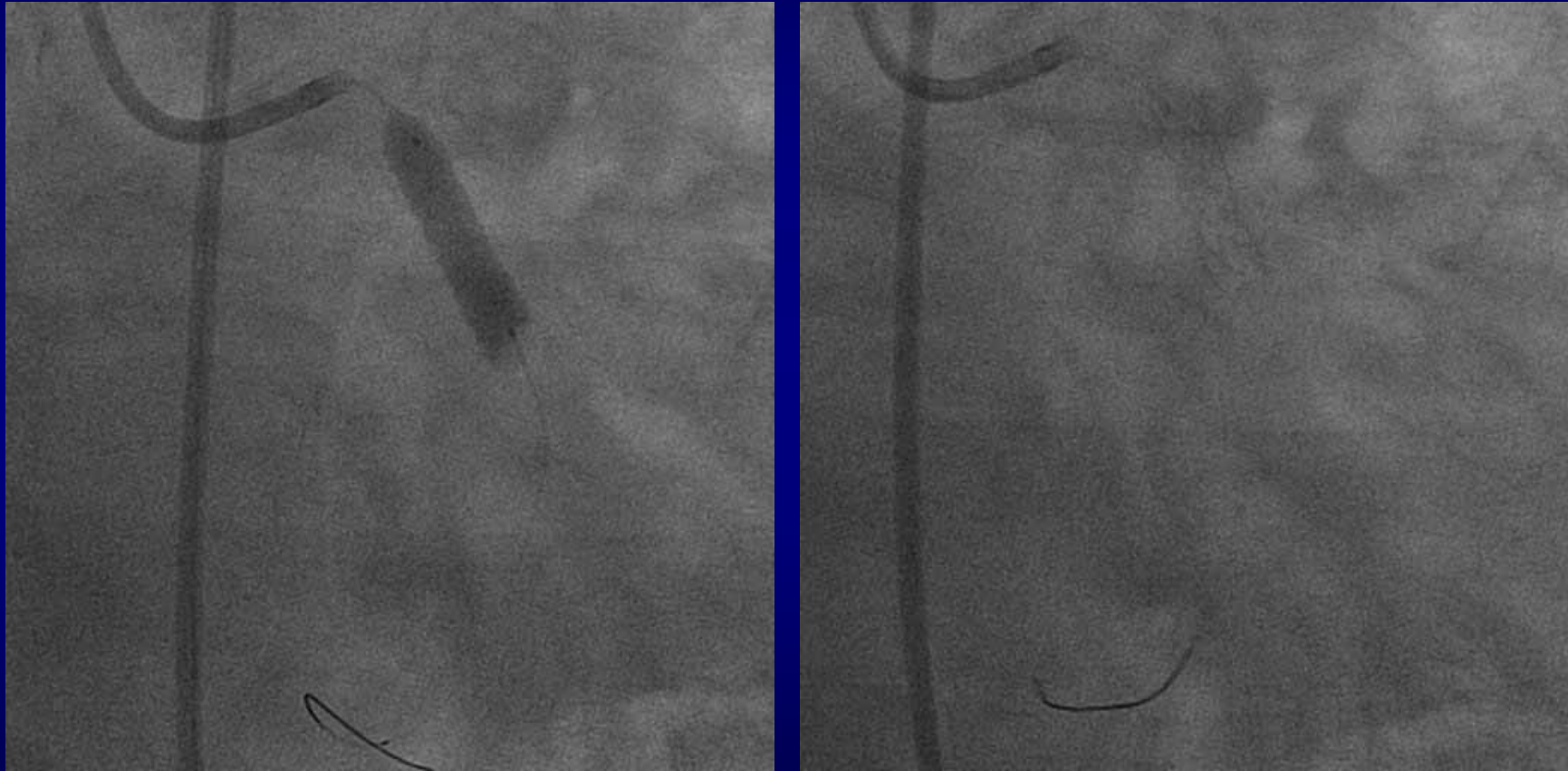
Distal Ref = 6.8 mm

Predilation



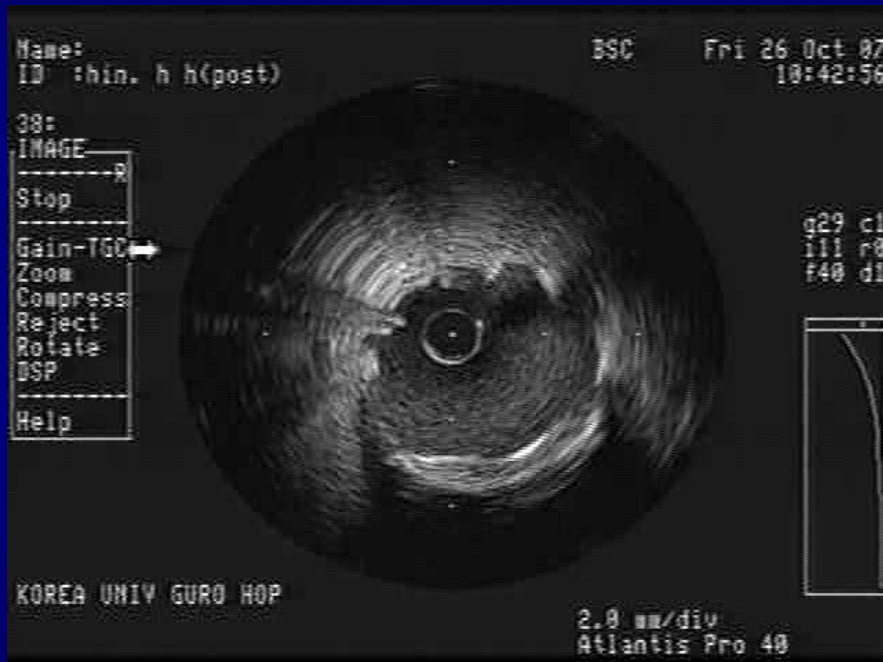Amiia 5.0 X 20 mm

Peripheral Stenting

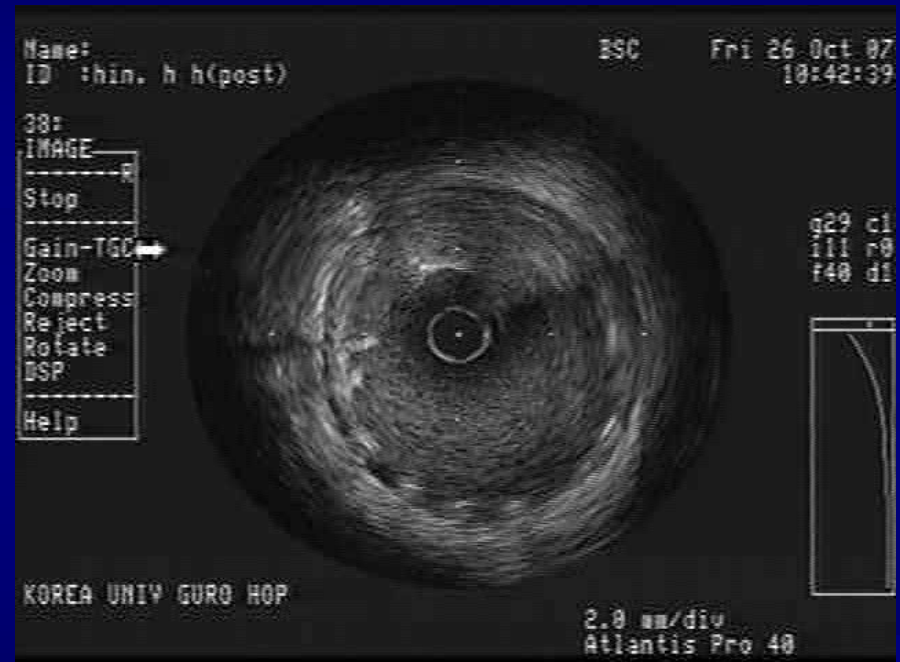

Genesis 6.0 X 24 mm (Cordis)

Post-stenting IVUS Finding

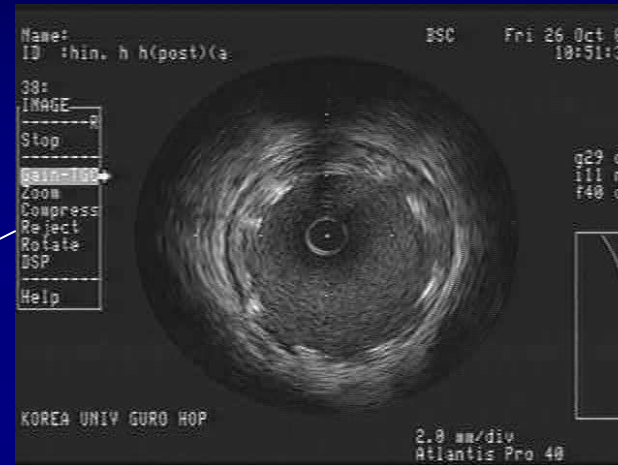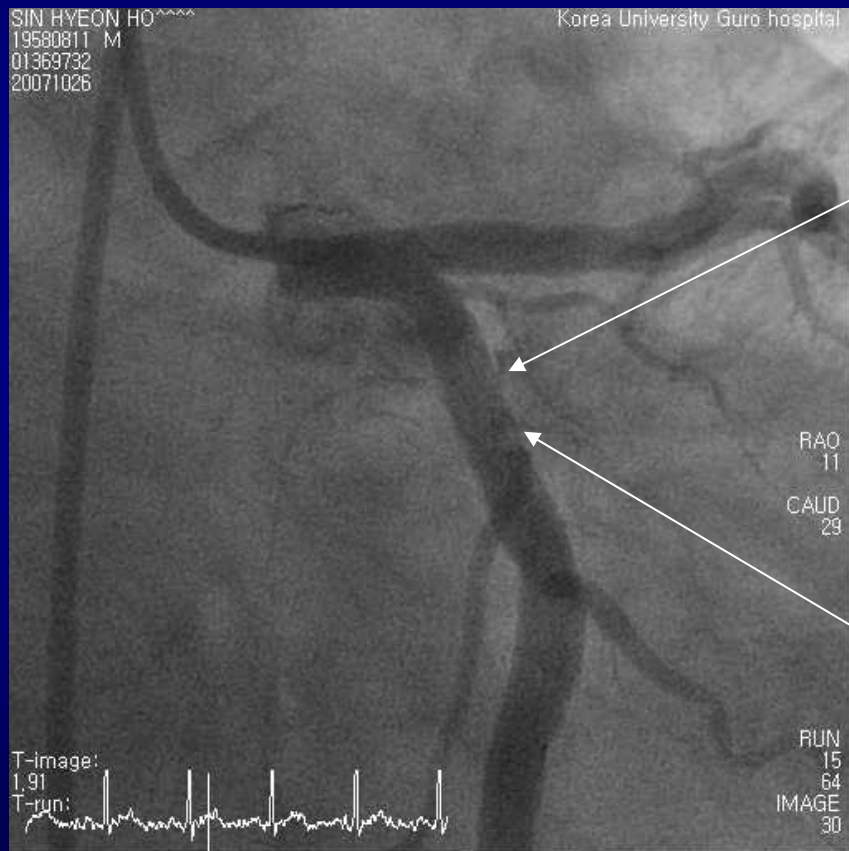


Proximal of the stent

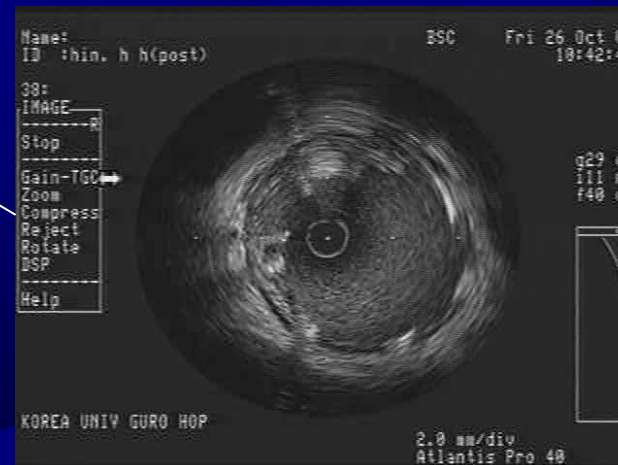

Distal of the stent

Post - Intervention ; before Adjuvant Balloon Postdilation

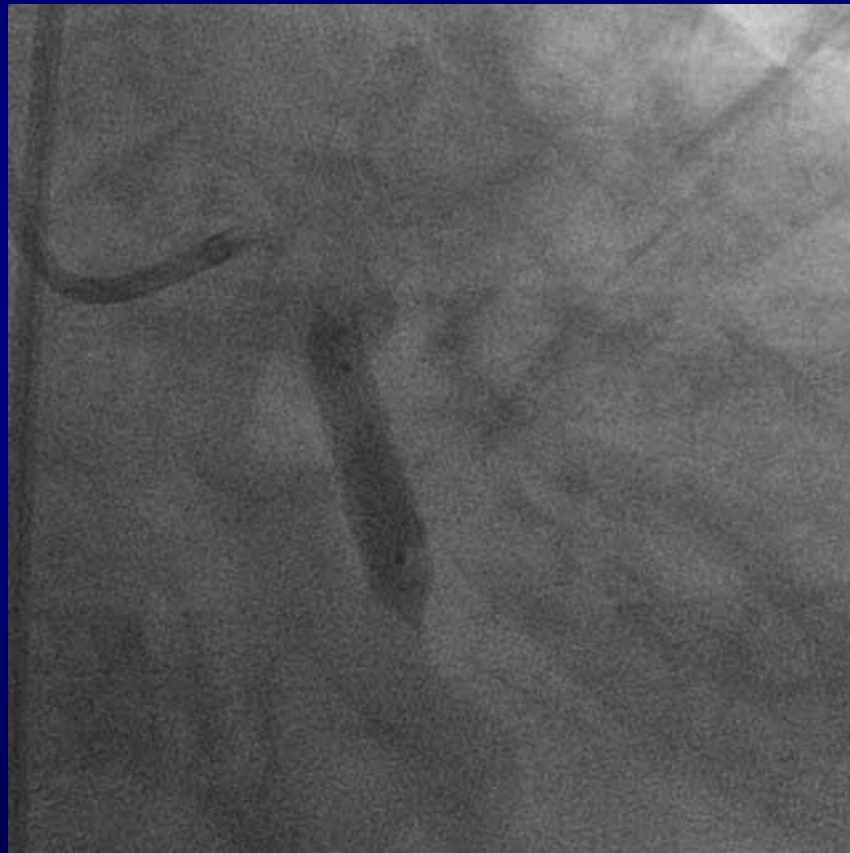

Proximal of
the stent

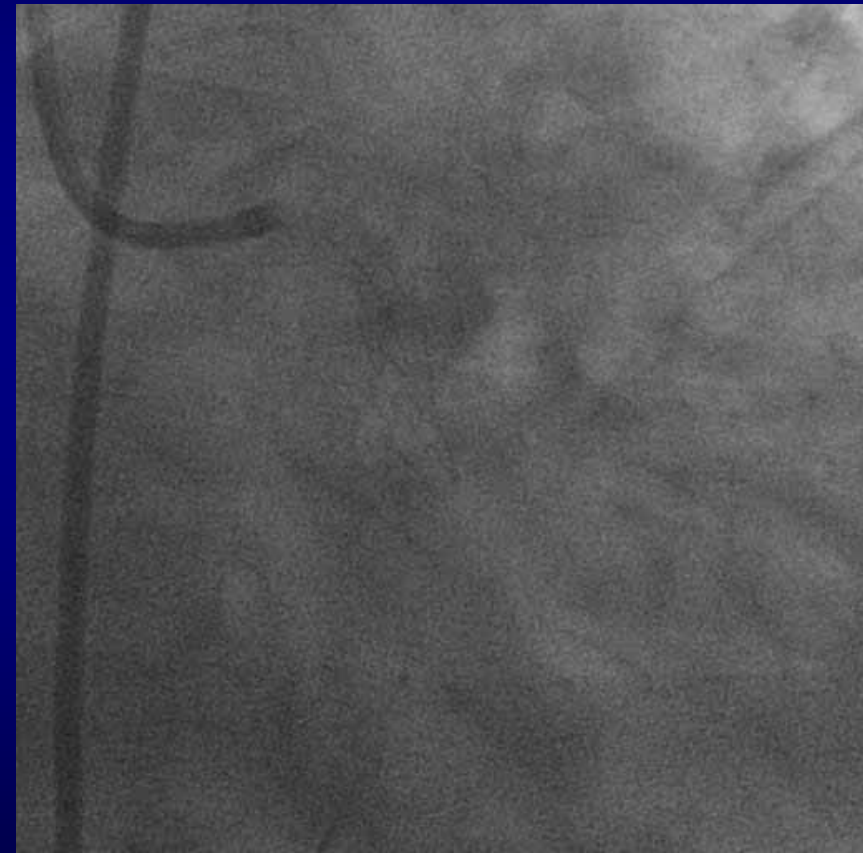

Distal of
the stent

Adjuvant Balloon Postdilation

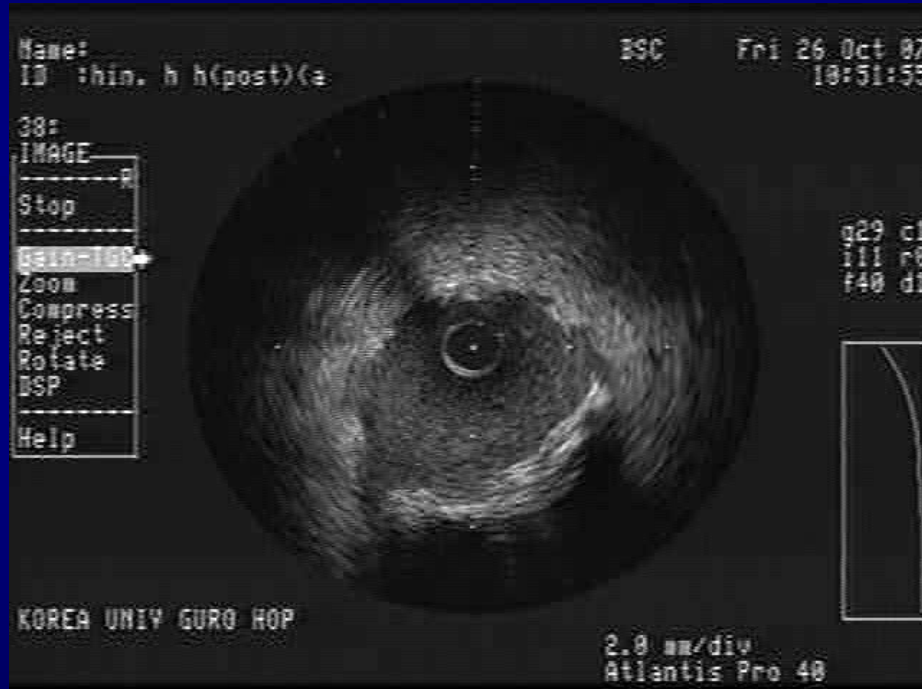

Amiia 7.0 X 20mm

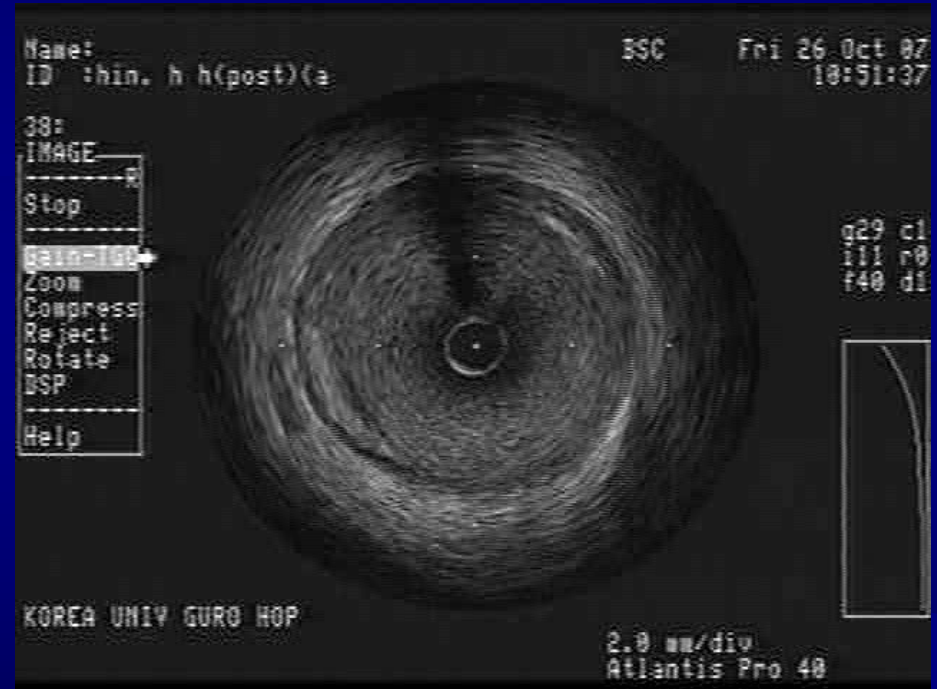


Final Image

Final IVUS Finding



Proximal of the stent

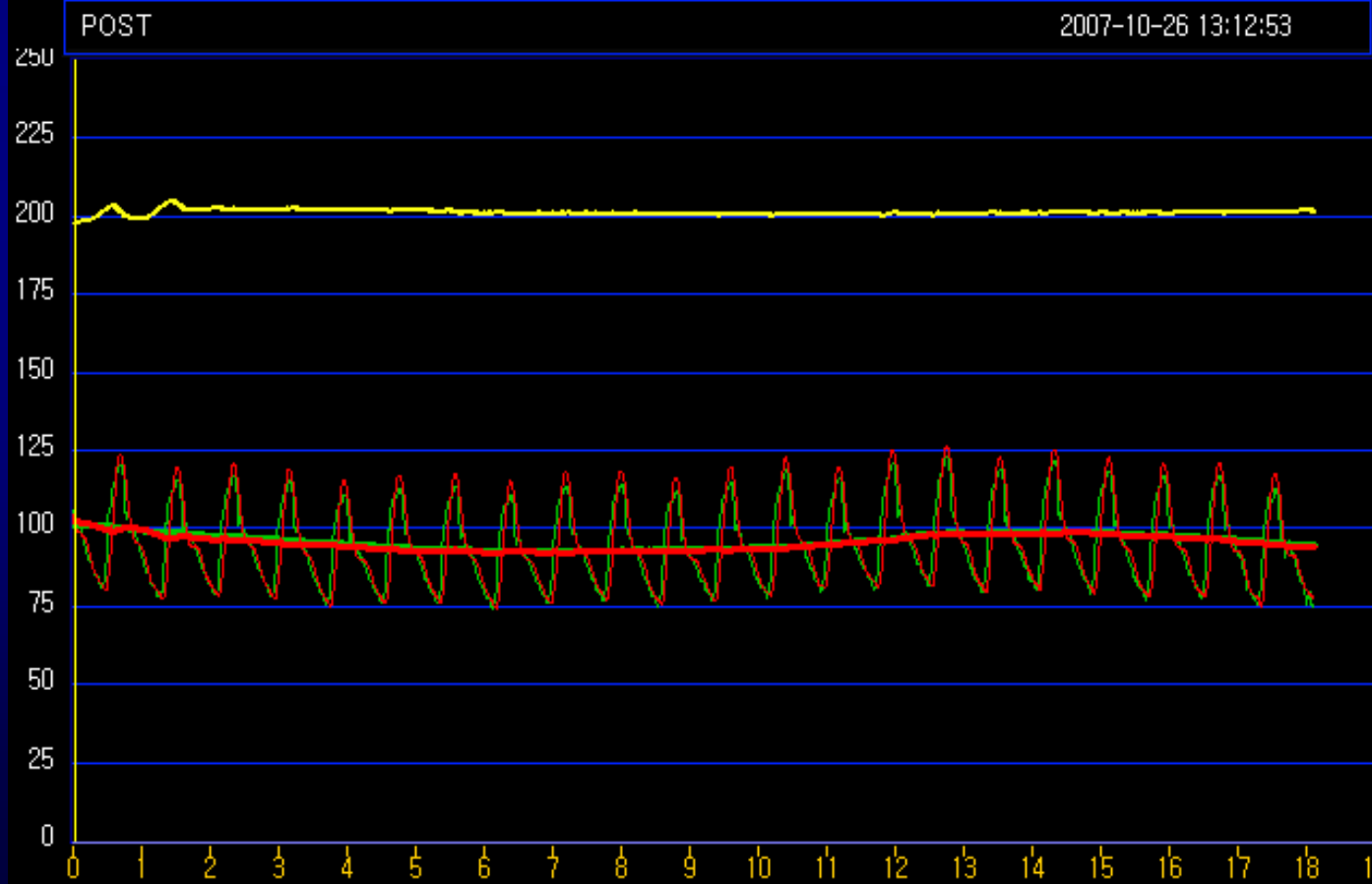


Distal of the stent

Post PCI FFR Measurement

ARCHIVE CUSTOM	c:\WRADI\DOWNLOAD\2007-12-05						COM 3
FOLDER	PATIENT ID	DATE	TIME	VESSEL	PROCEDUR	ACTION	TYPI SIZE
2007-12-05	POST	2007-10-26	13:12:53				FFR 18Kb
2007-09-04	PRE	2007-10-26	12:45:16				FFR 22Kb
2007-07-04							
2007-05-17							

PRINT **EDIT** **RENAME** **EXPORT** **ERASE** **SETUP**



(102) Pa mean
(101) Pd mean
0.99 FFR
0.03 CURSOR
+ [magnifying glass] [crosshair]
RESET

KFC Multicenter Study 2007 -

Center	DEFER DES	Diffuse Long	FILM	LM	ISR	Diff Guiding
()	18	13				
()	100		10		8	20
()	12	4	1	1	4	
()	3					
()	41					
()	24					3
()	32		4			
()	20	75	2		1	
()	76	10	4	4	8	28
	326	102	21	5	21	51

Conclusion

1. Importance of Pre & Post-intervention work up including IVUS and FFR in patient with coronary artery ectasia.
2. Current treatment strategy
; depends on the physician's discretion, case by case...
3. Best mechanical revascularization strategy should be clarified with larger study populations.

Thank You for Your Attention!!

Korea University Guro Hospital

