

NEEDLE IN A HAY STACK

DR BINOY JOHN

MD DM (CARDIOLOGY) FACC FESC FSCAI FAPSIC

CHIEF: DEPARTMENT OF CARDIOLOGY & INTERVENTIONAL
CARDIOLOGY

MIOT INTERNATIONAL
CHENNAI

TCT AP 2015; SEOUL; S KOREA

60 YEAR OLD

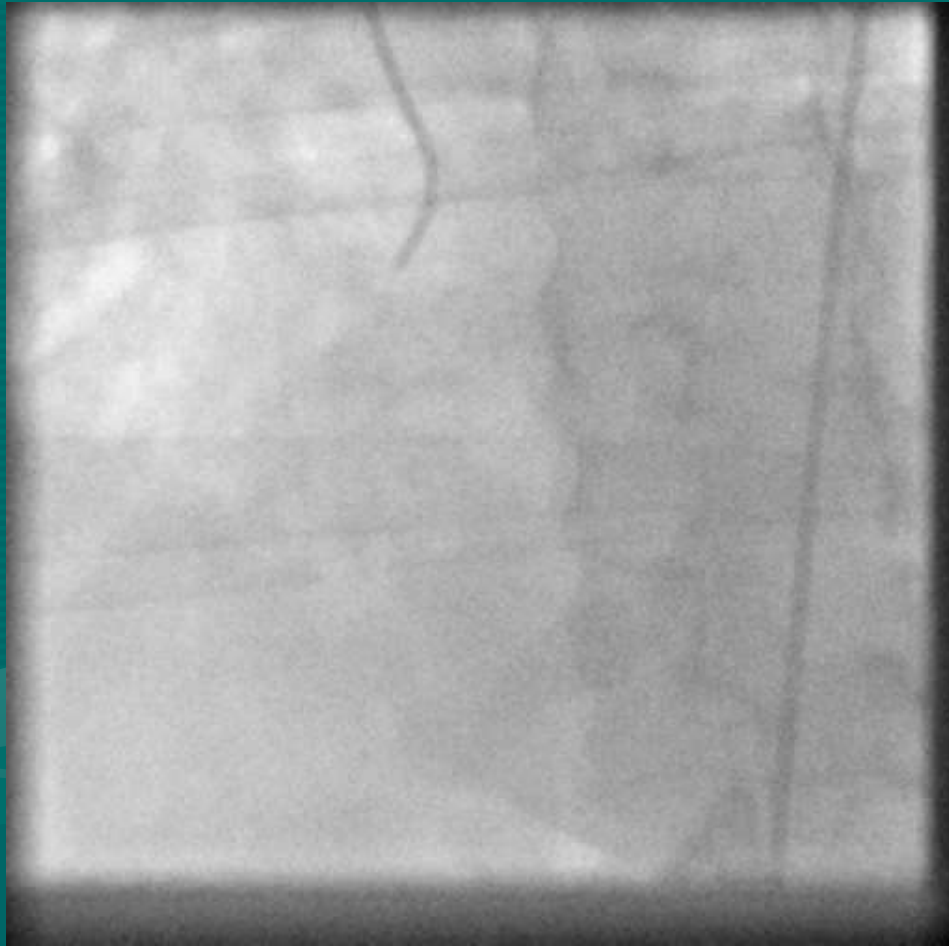DIABETIC (HbA1c 10.8)

CRESCENDO REST ANGINA

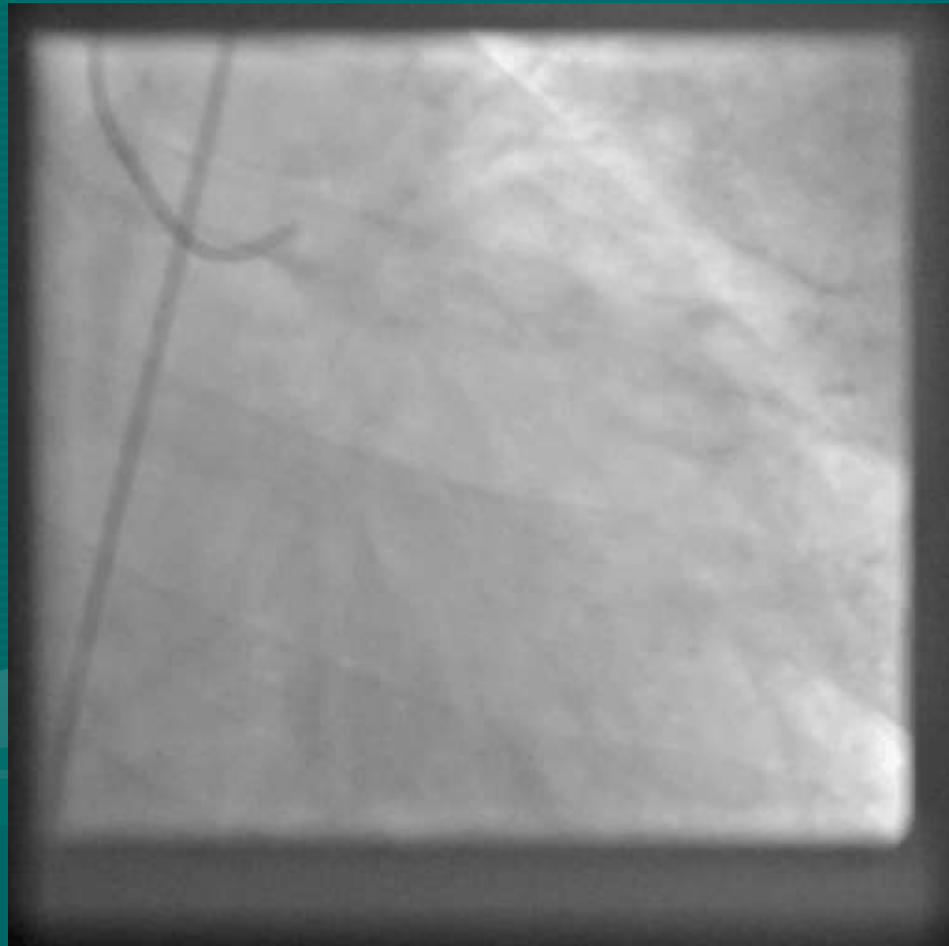
S.Cr 1.8

LV EF: 60%

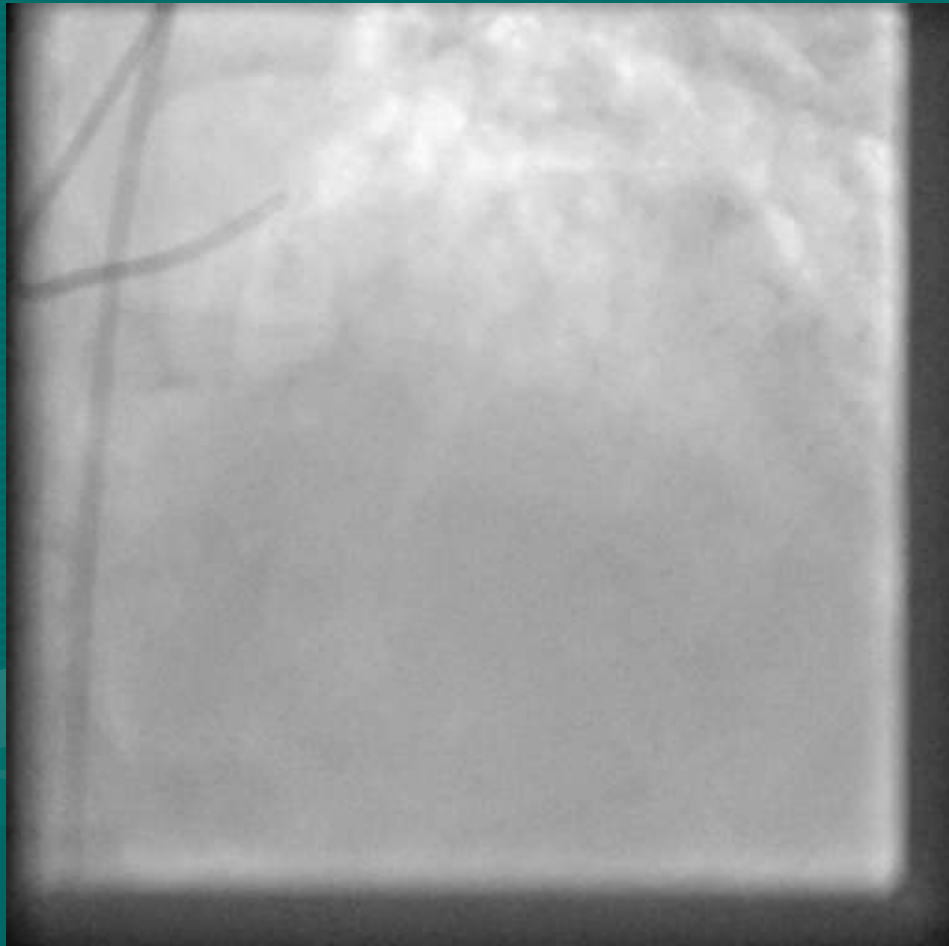
RCA



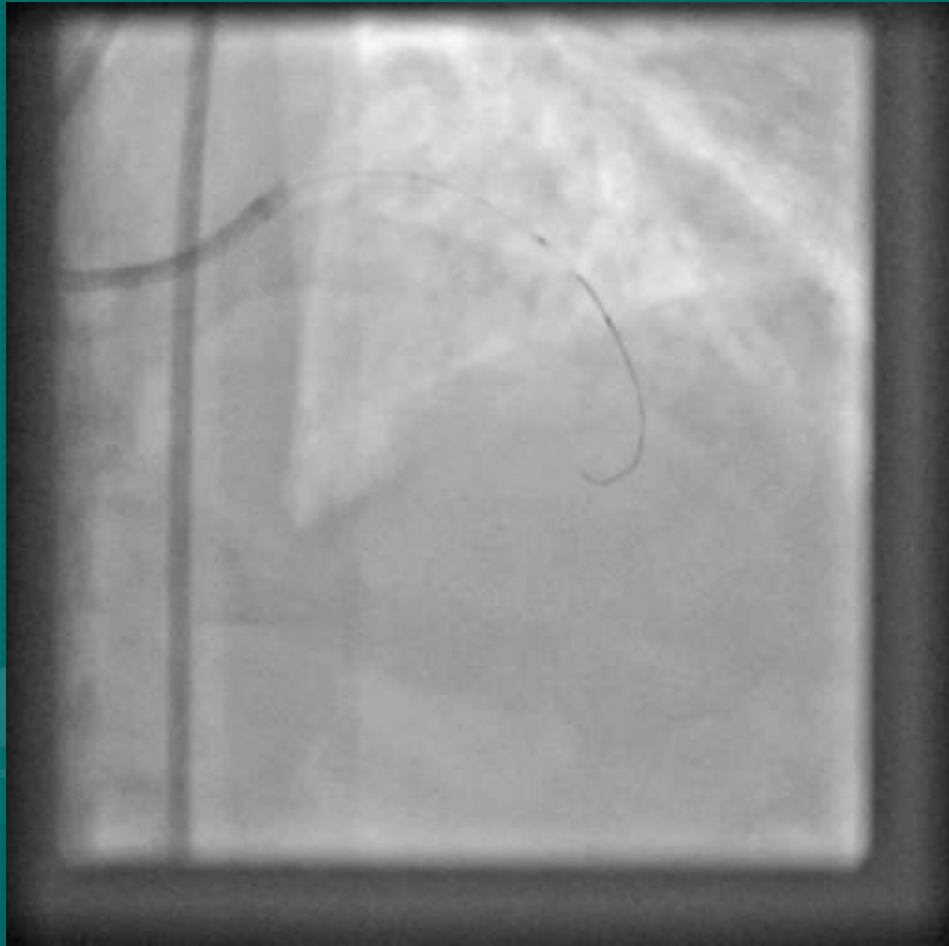
LEFT SYSTEM

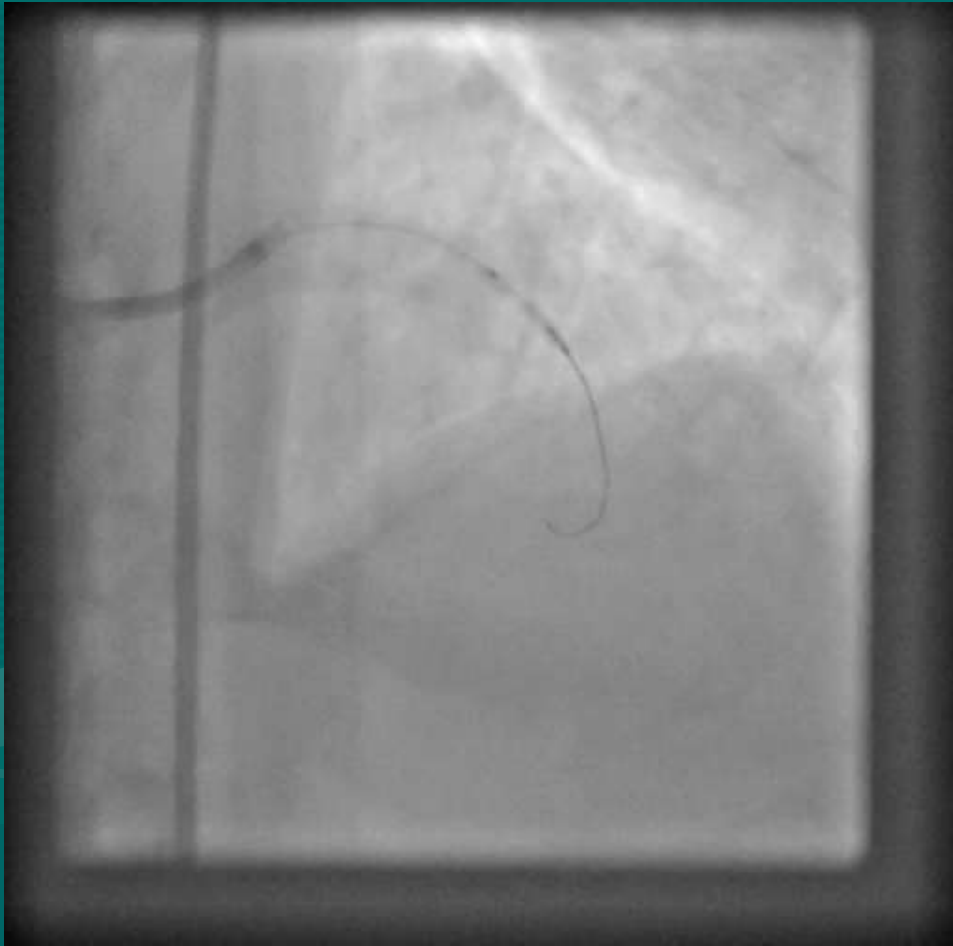


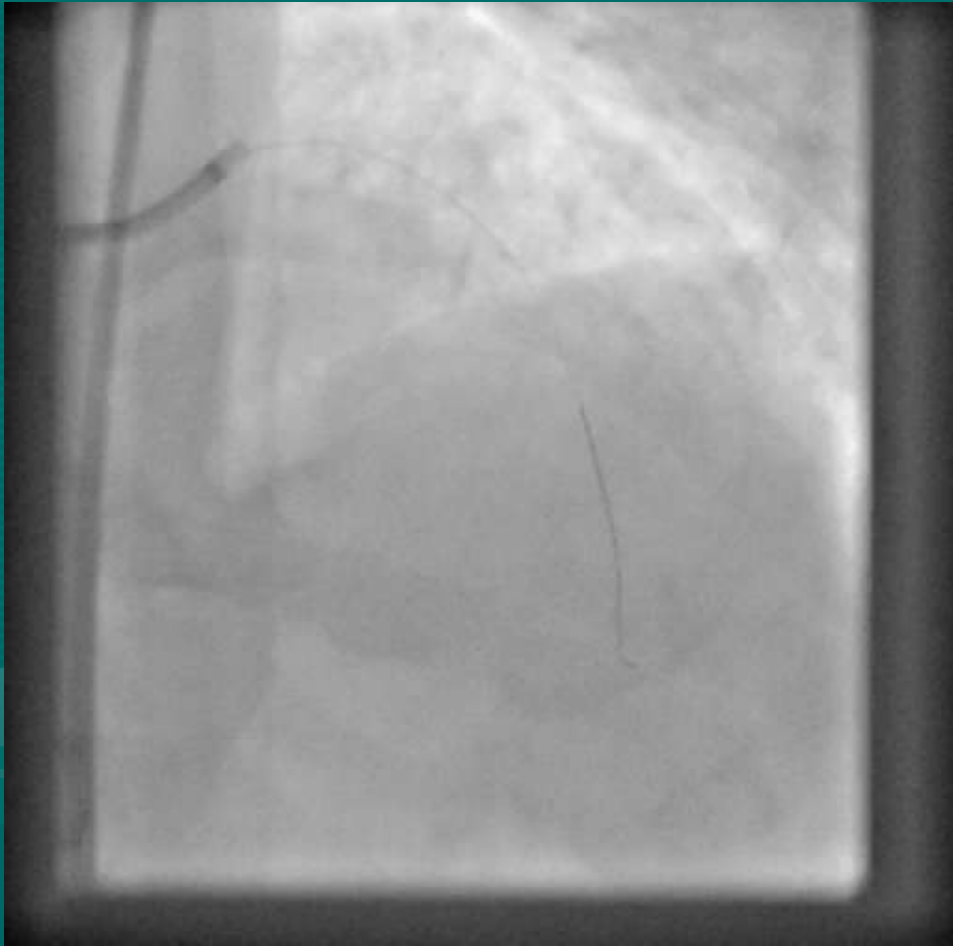
LAD



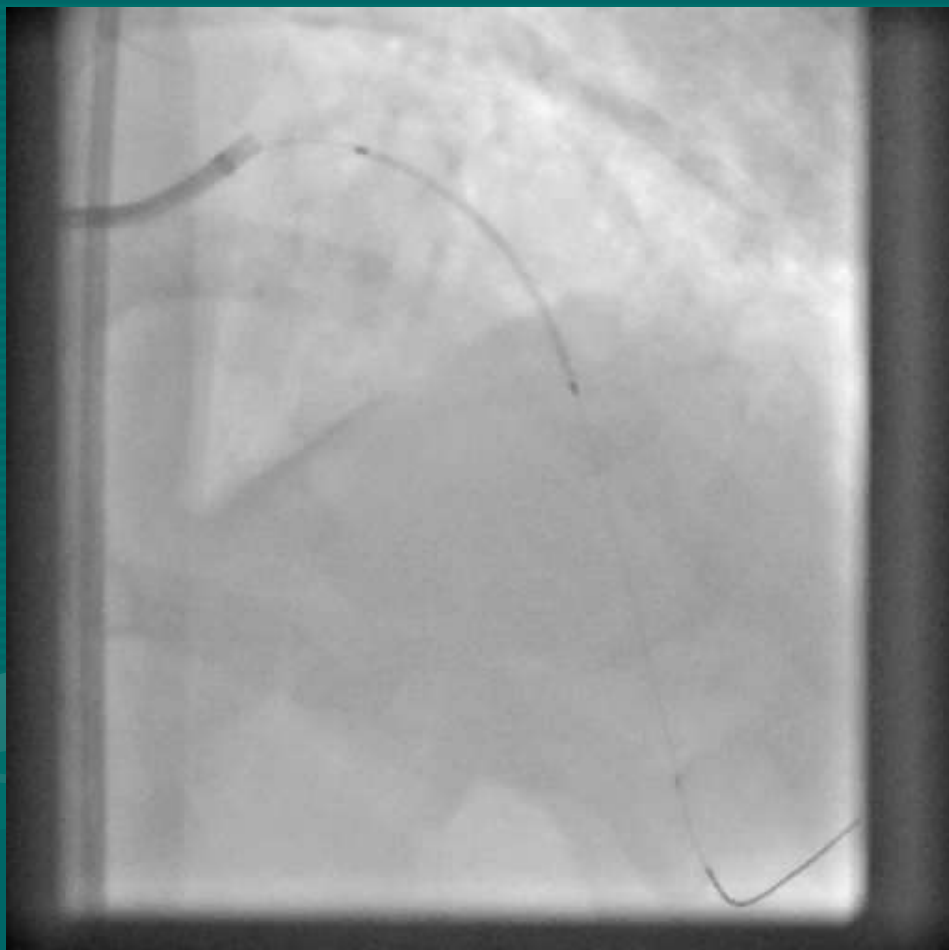
2.0 X 12 TREK BALLOON



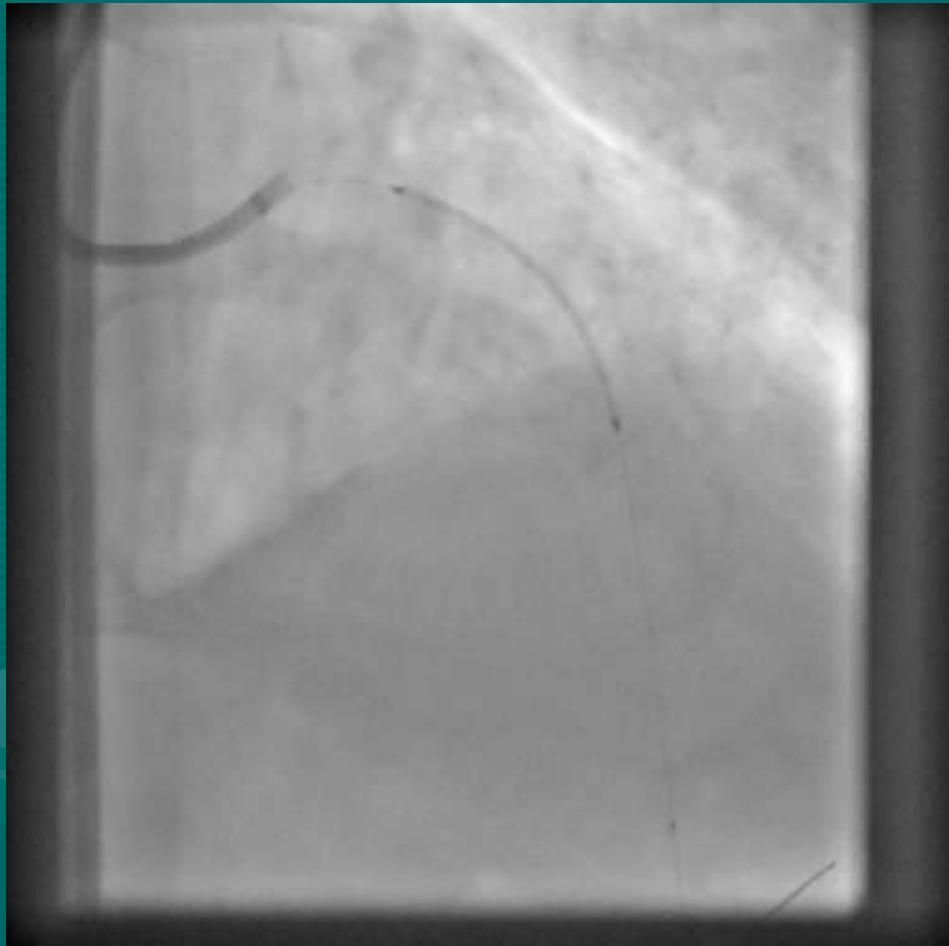


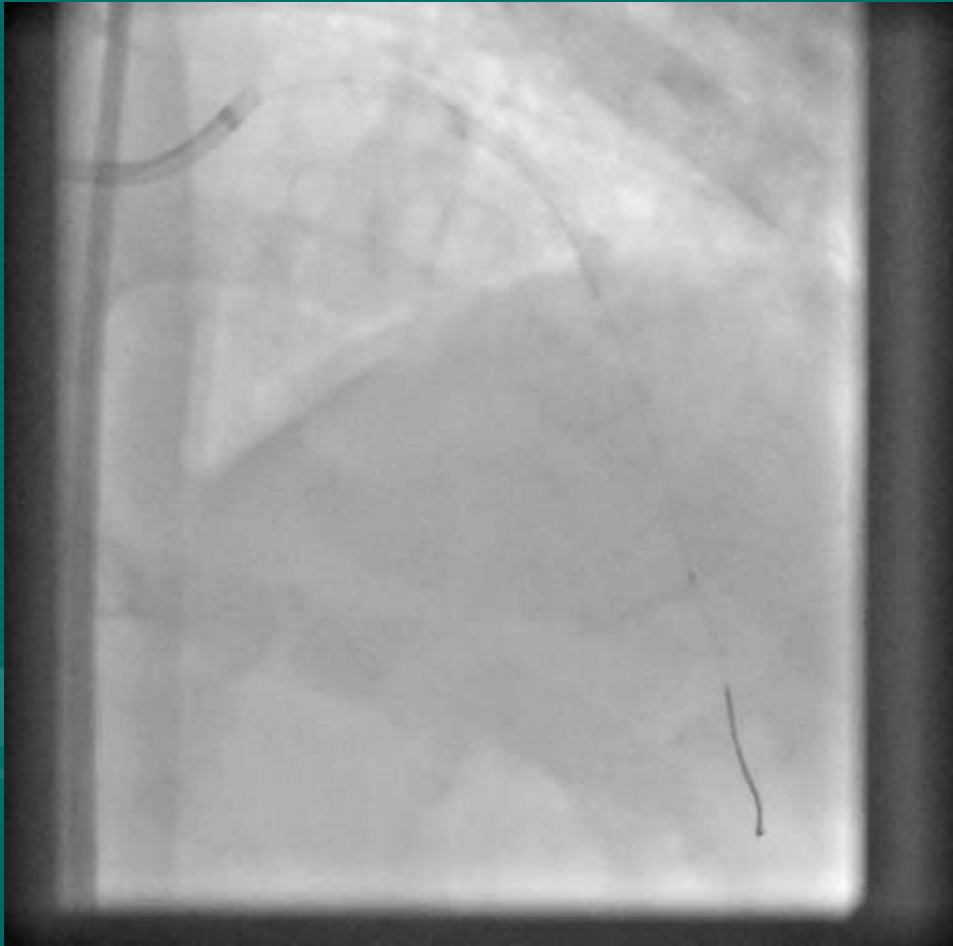


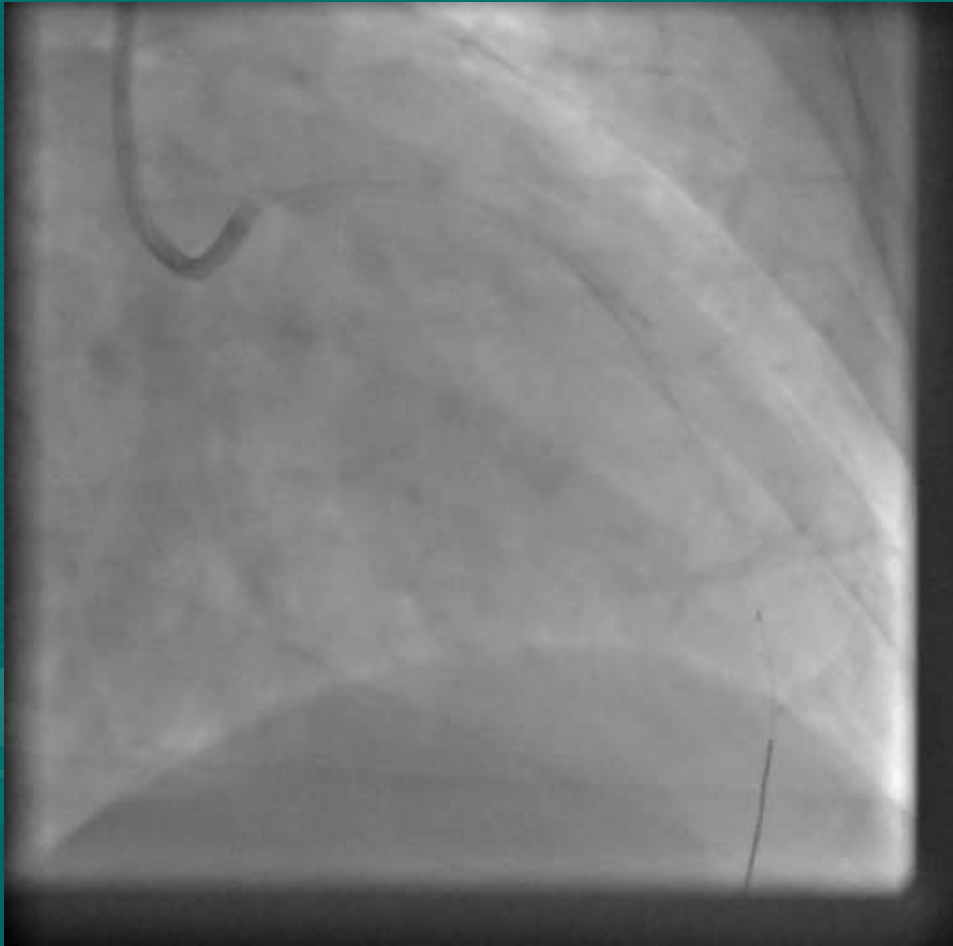
2.50 X 38 XIENCE PRIME



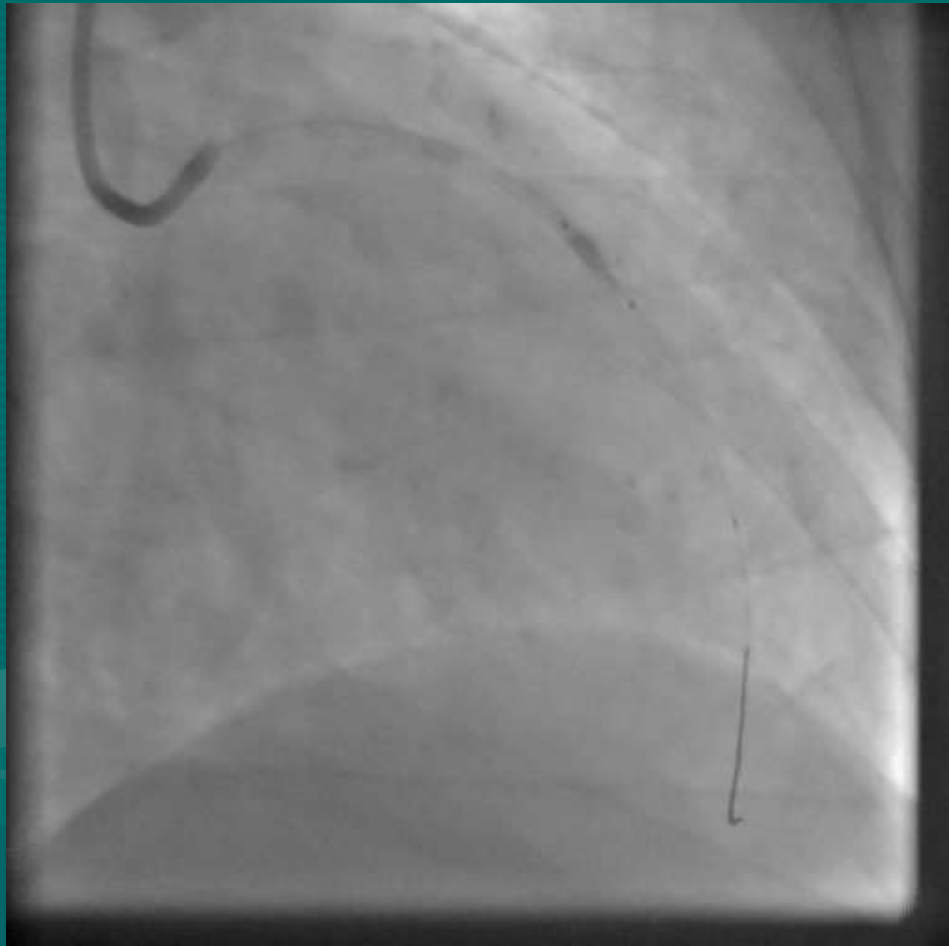
DEPLOYED

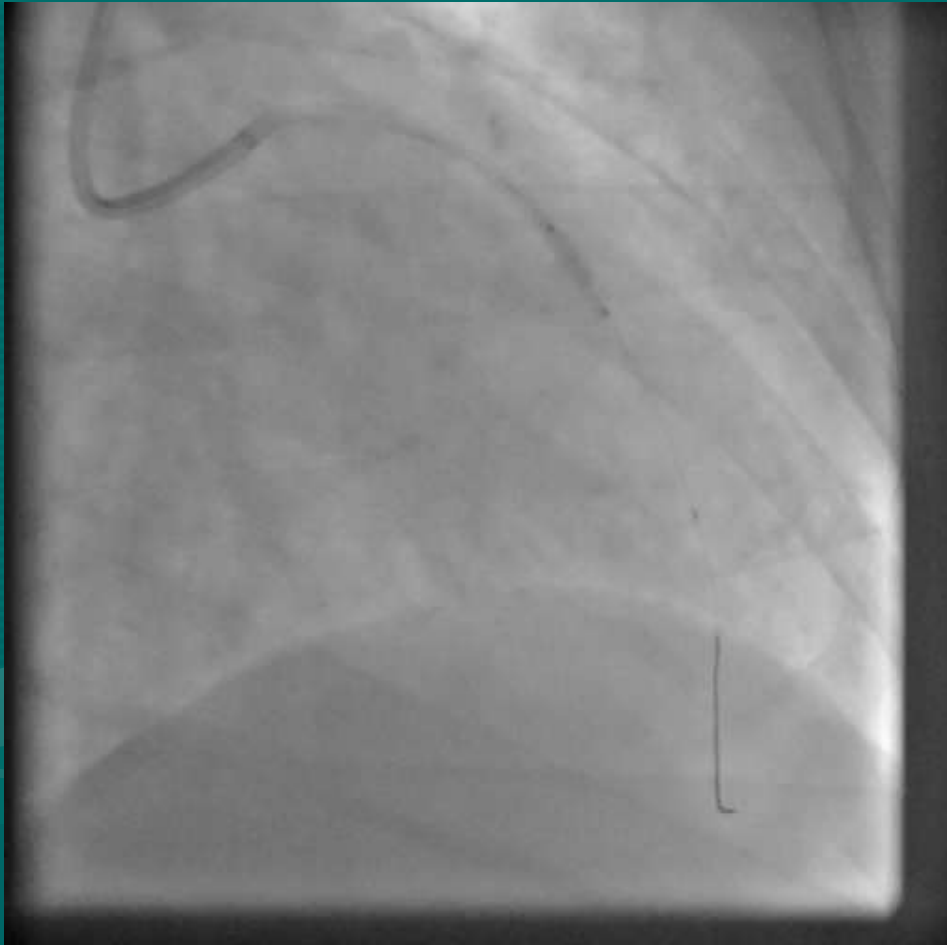


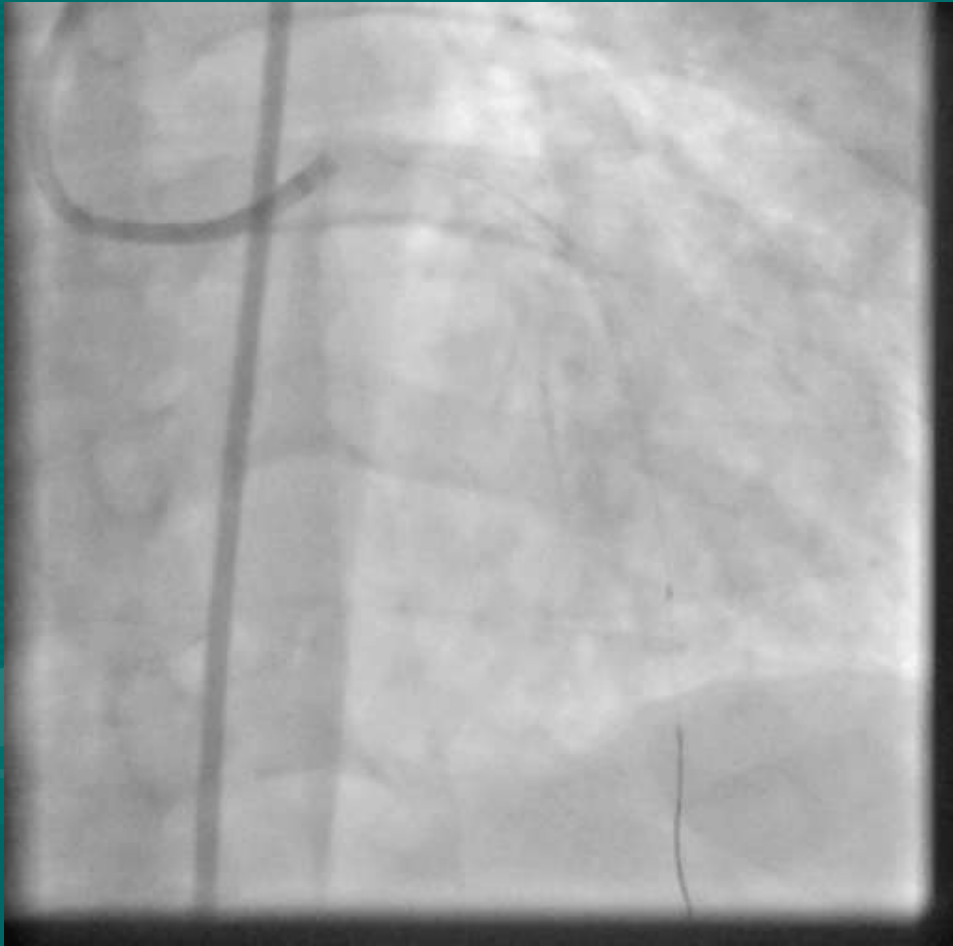




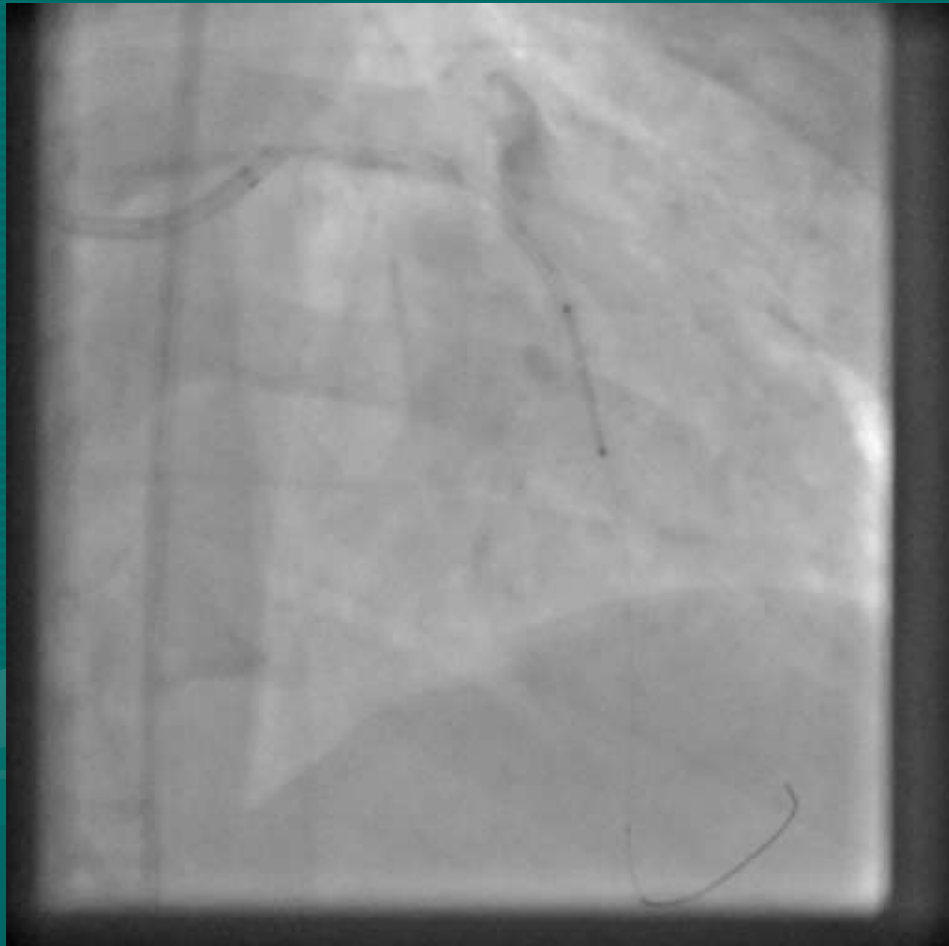
BALLOON INFLATION



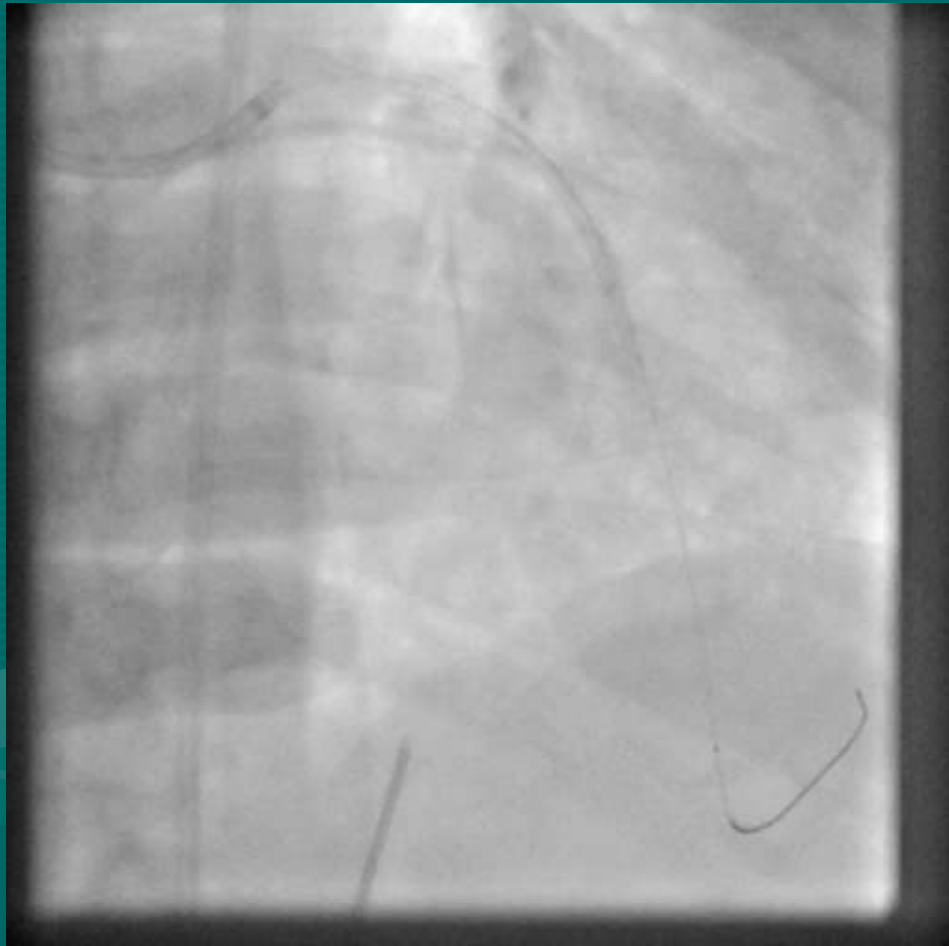


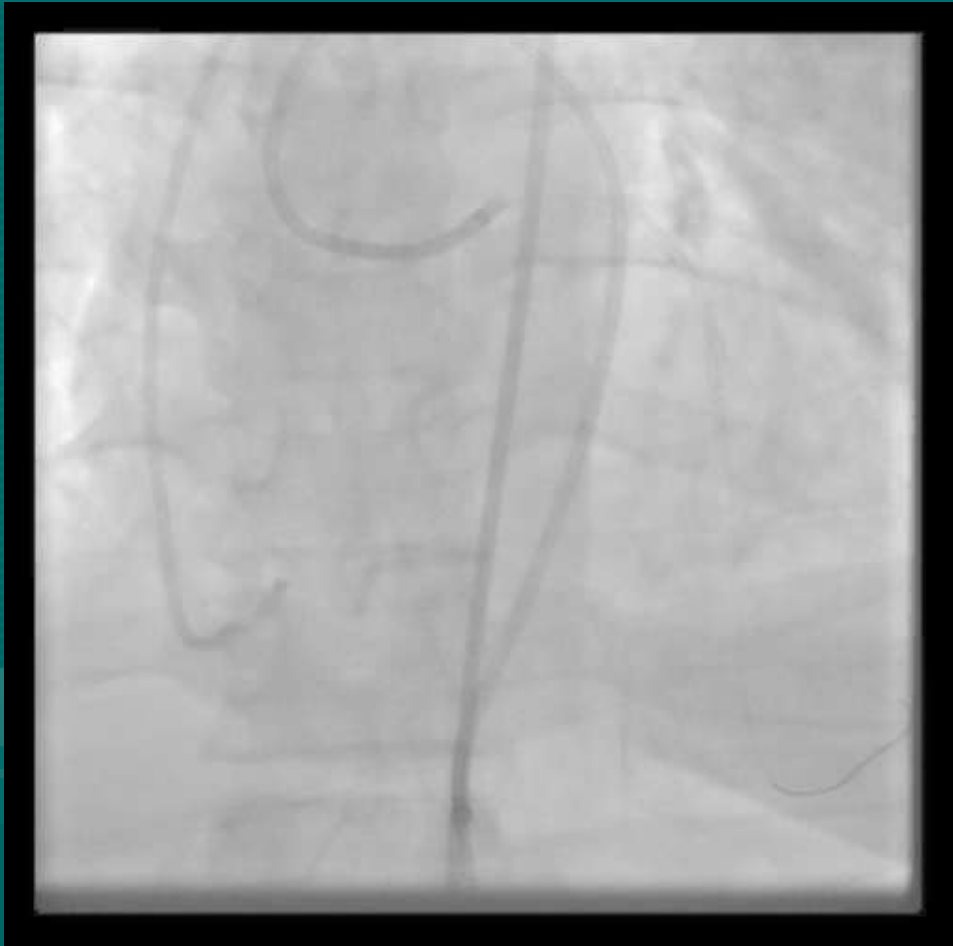

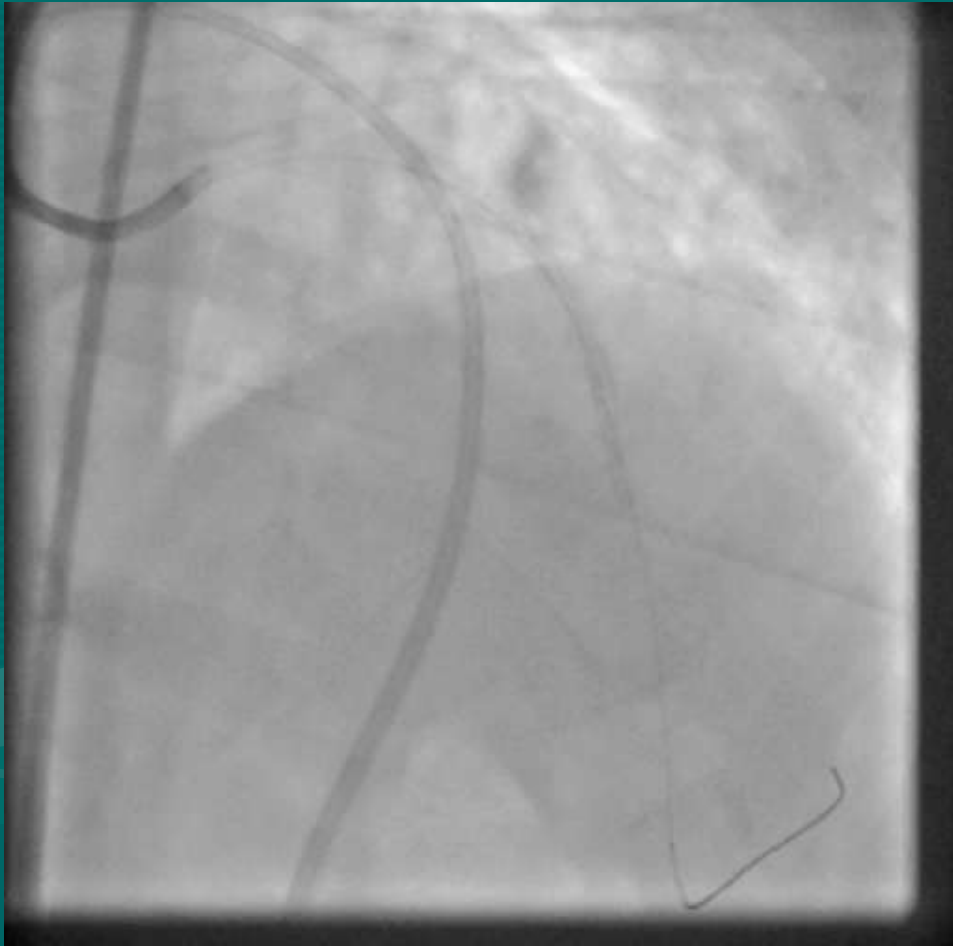
2.5 x 18 XIENCE PRIME

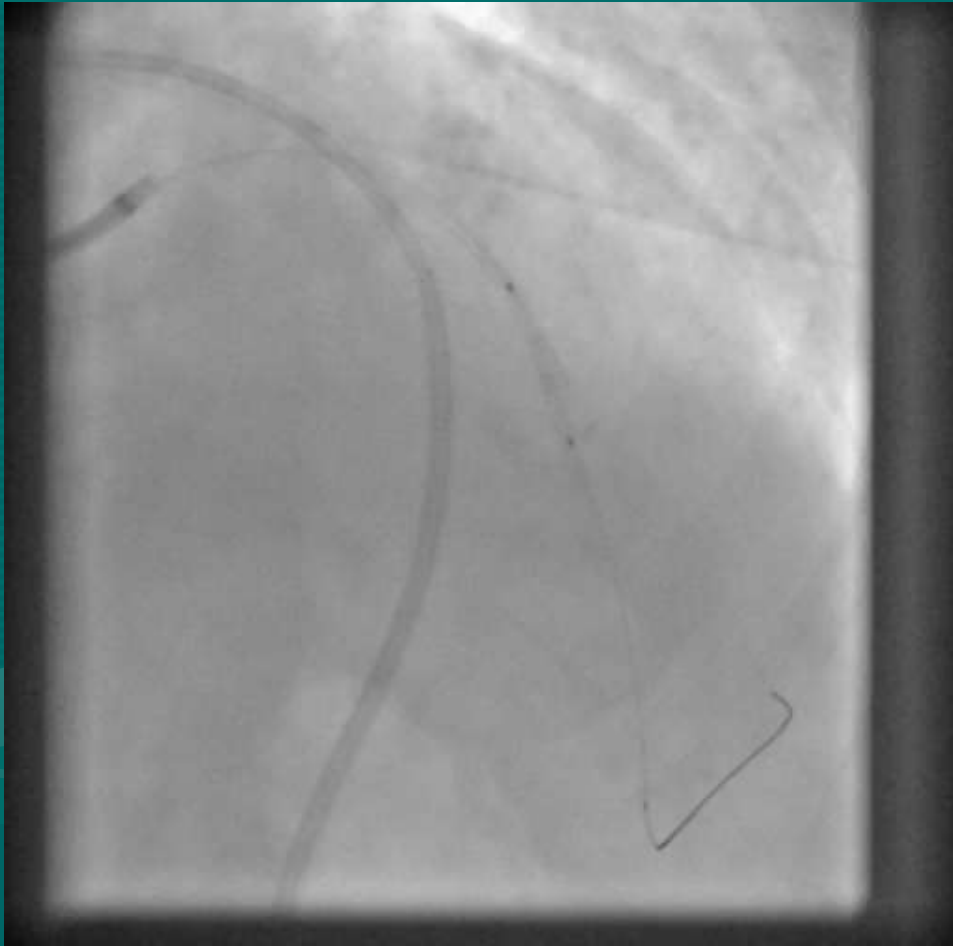


PERICARDIOCENTESIS

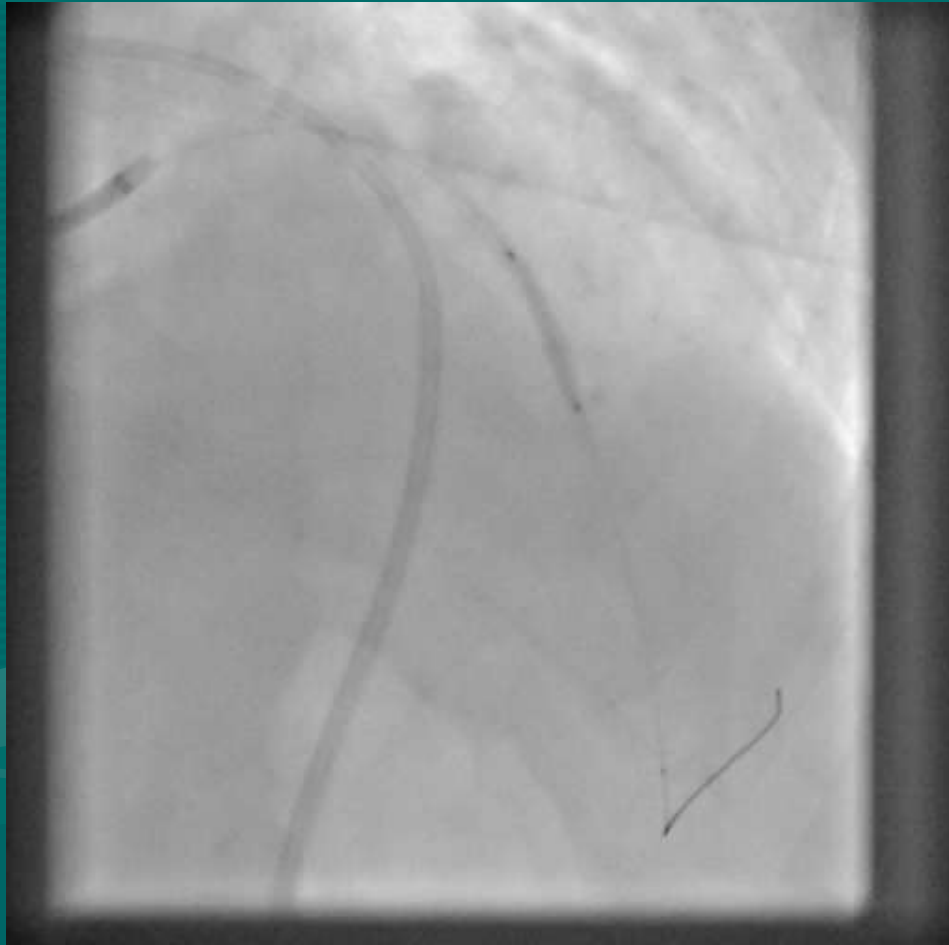




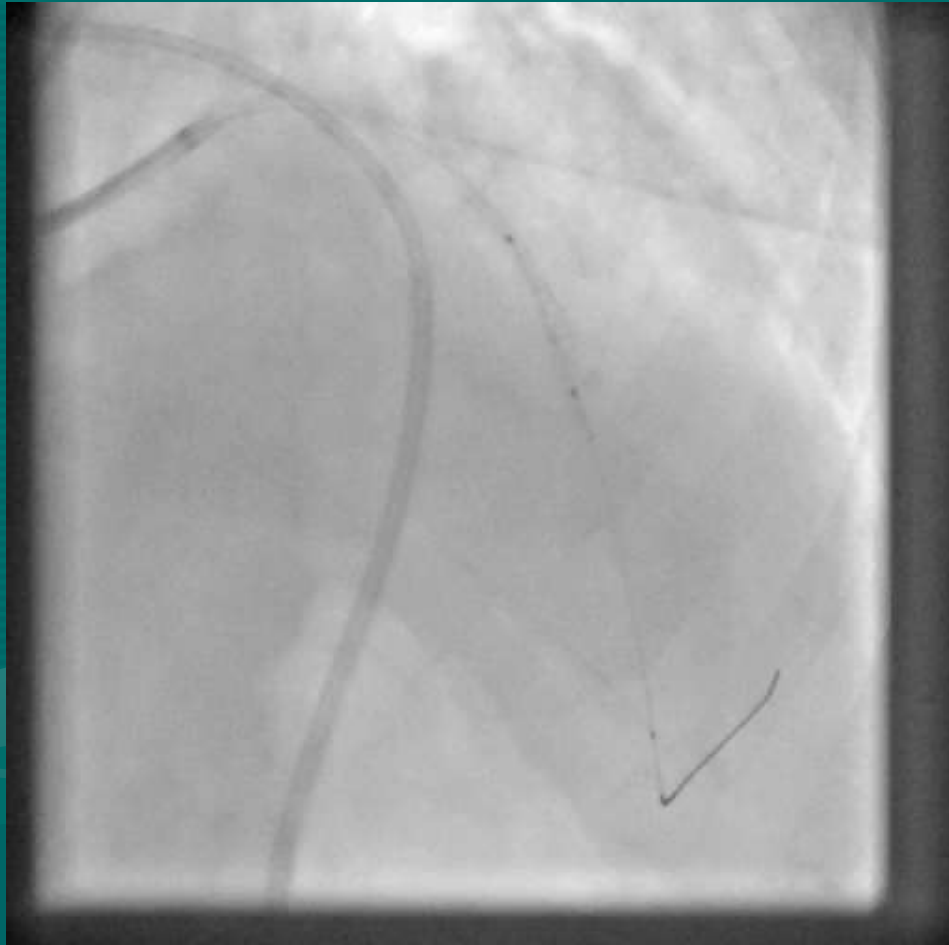




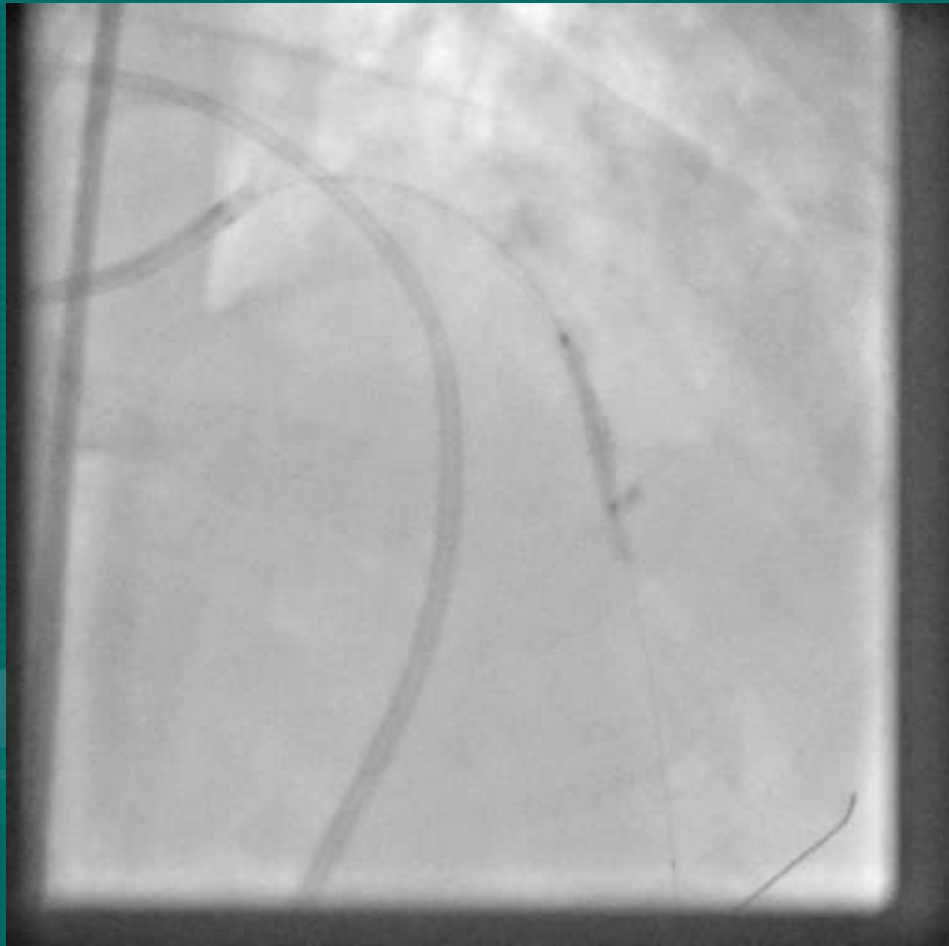
BALLOON INFLATION



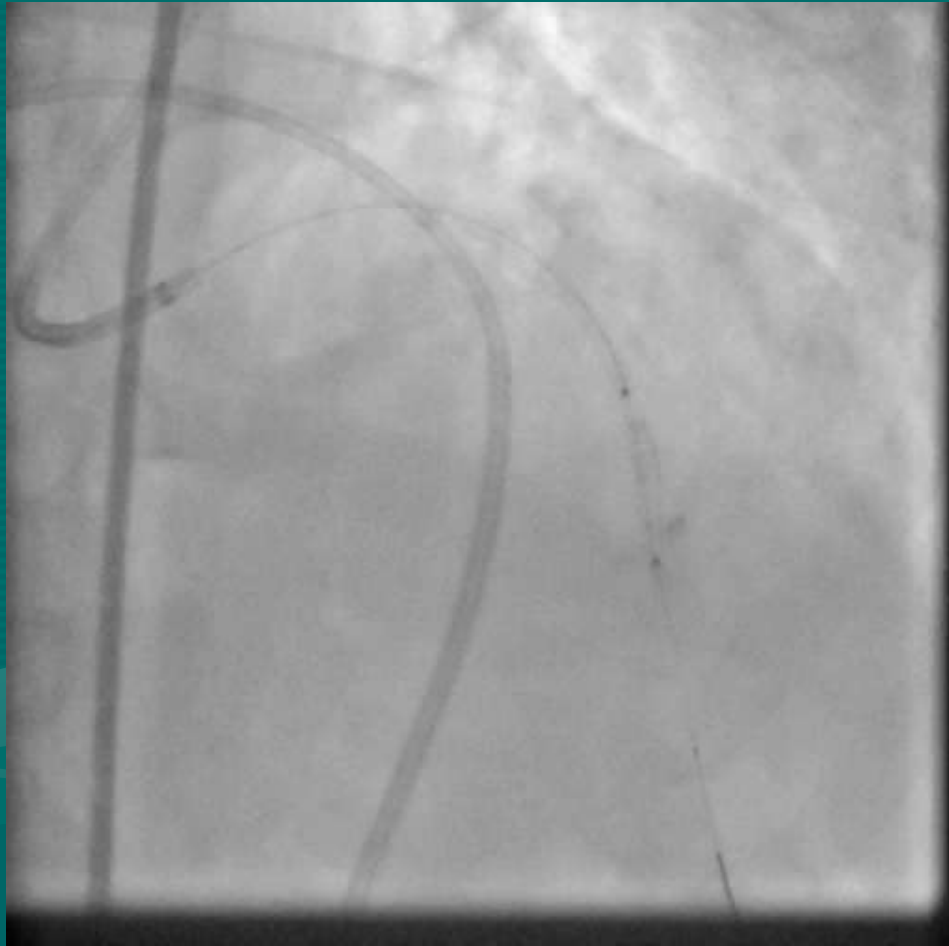WHILE...



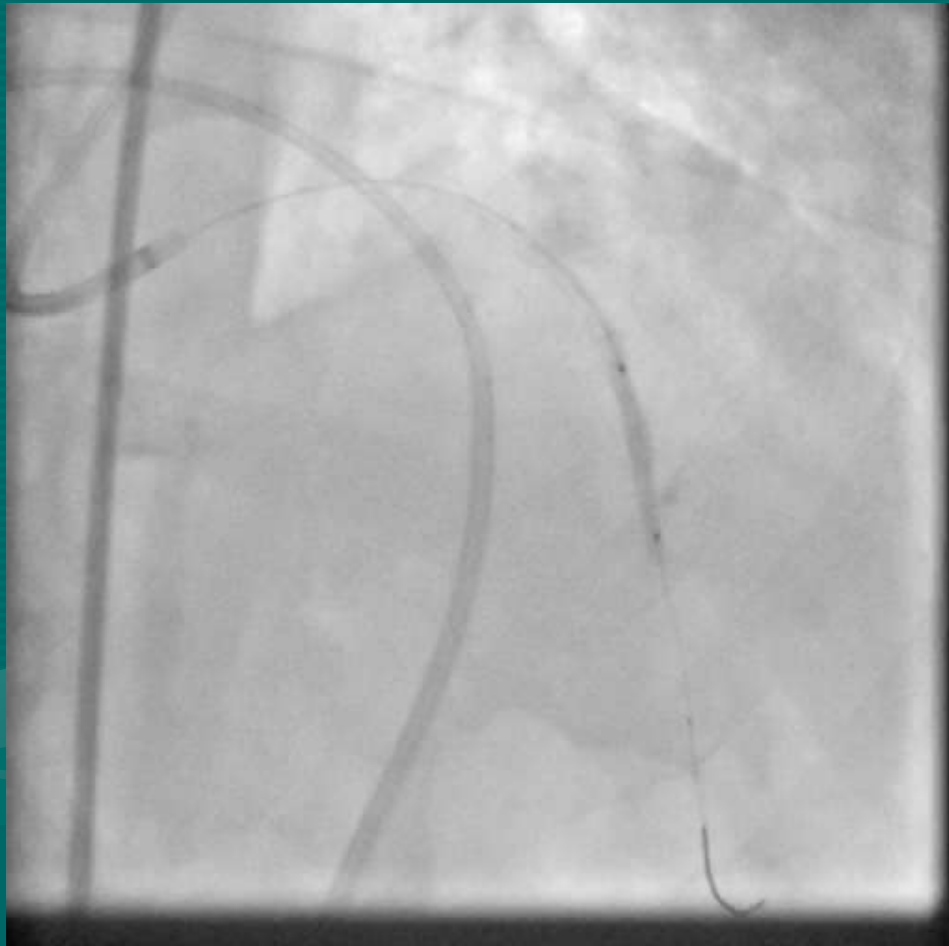
I...



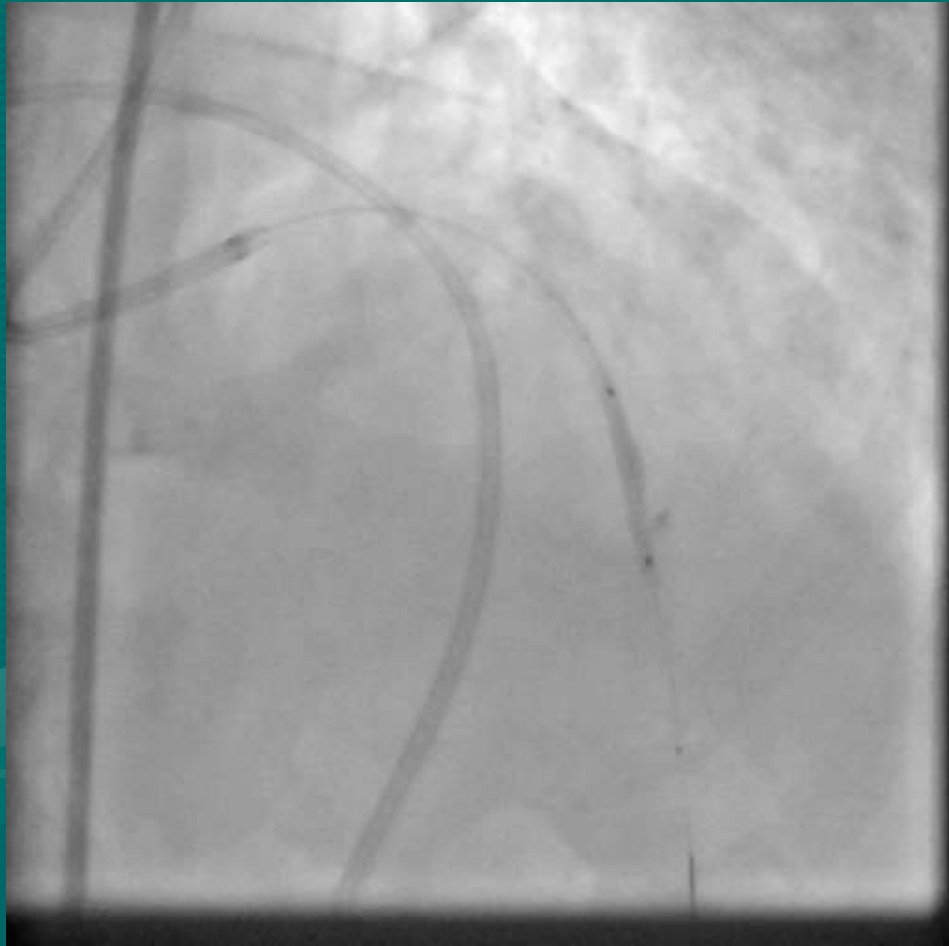WAITED...



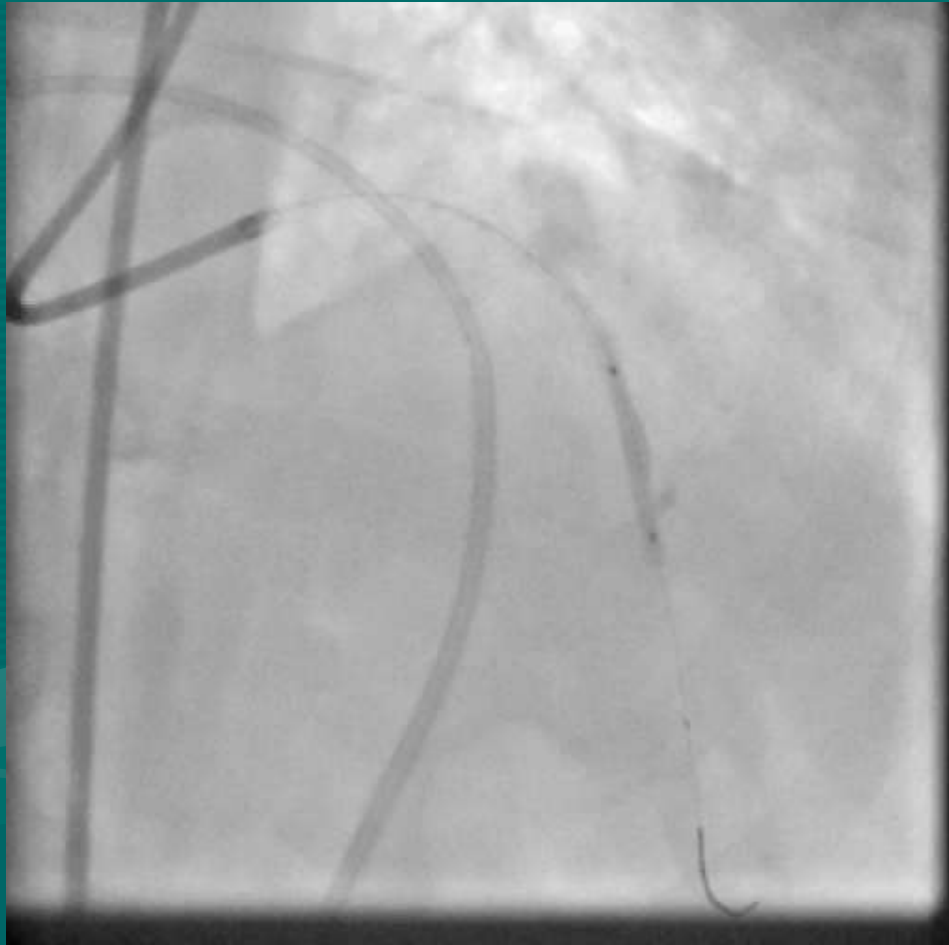
PATIENTLY....



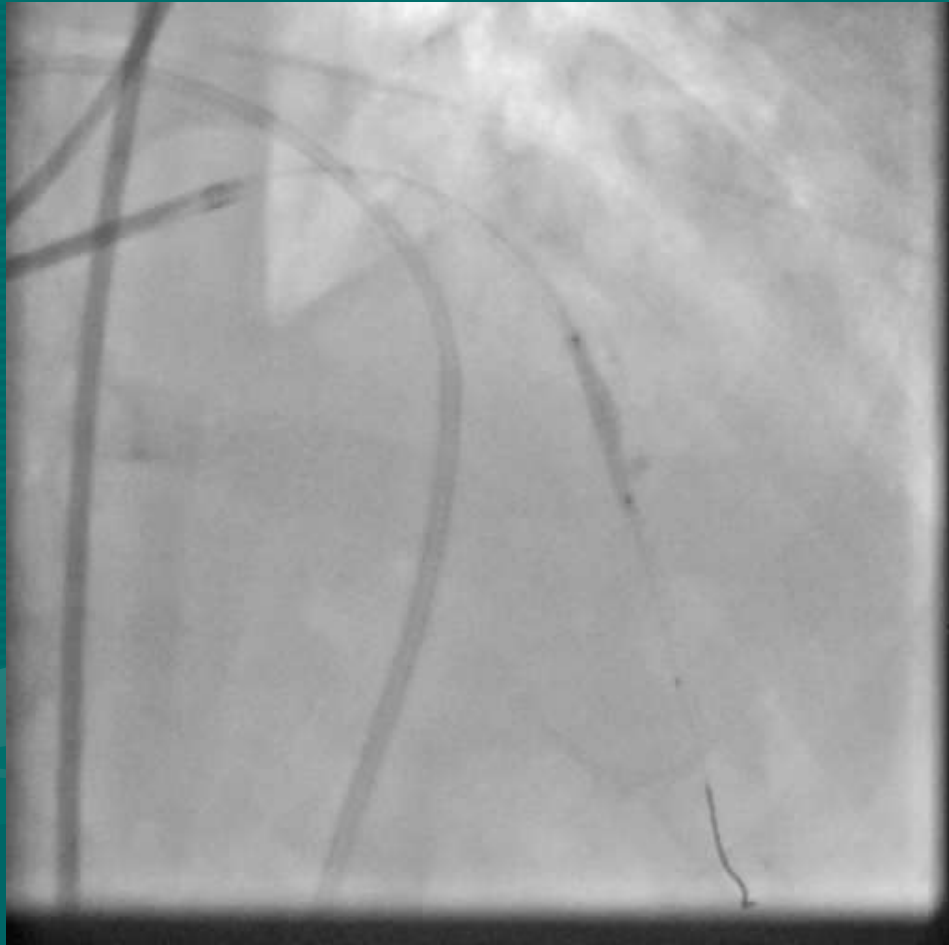
FOR....



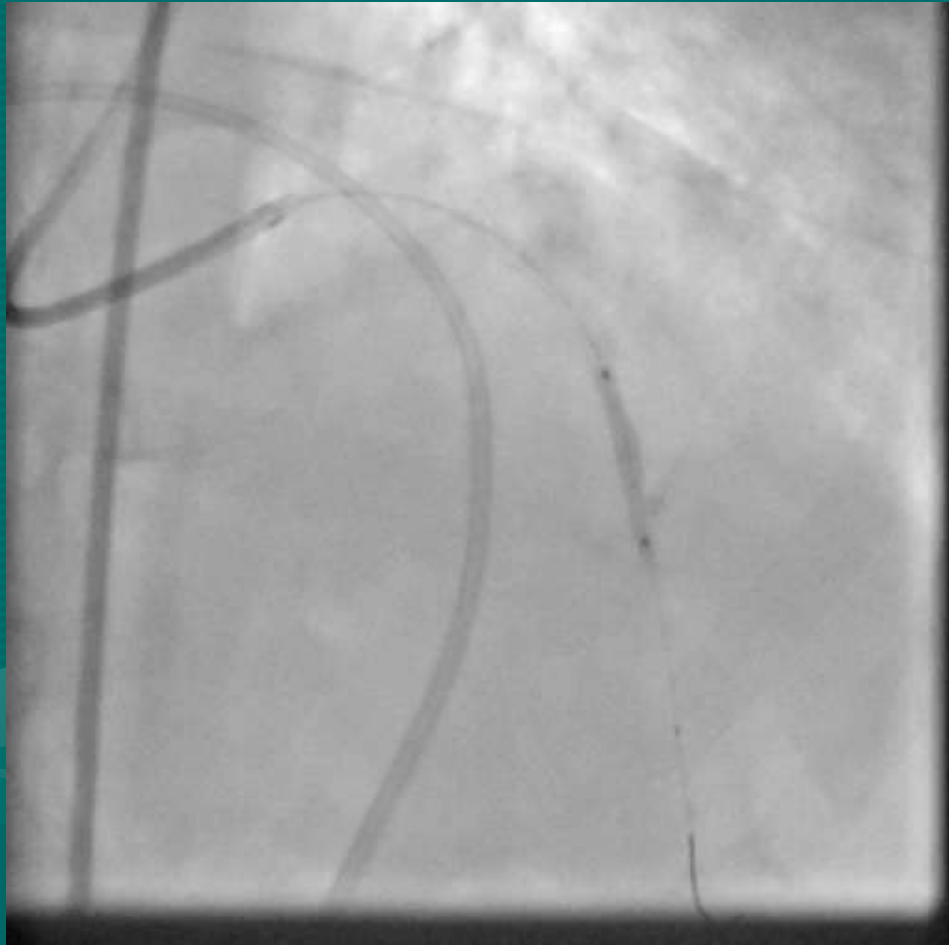
THE...



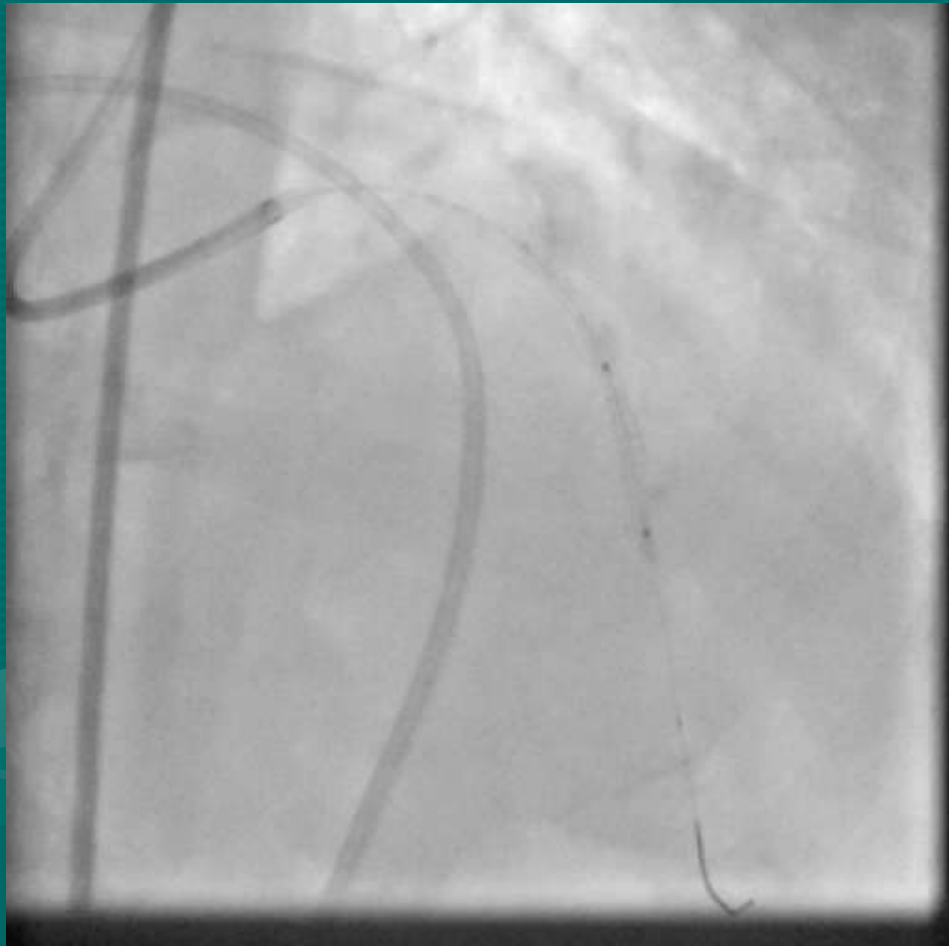
COVERED....



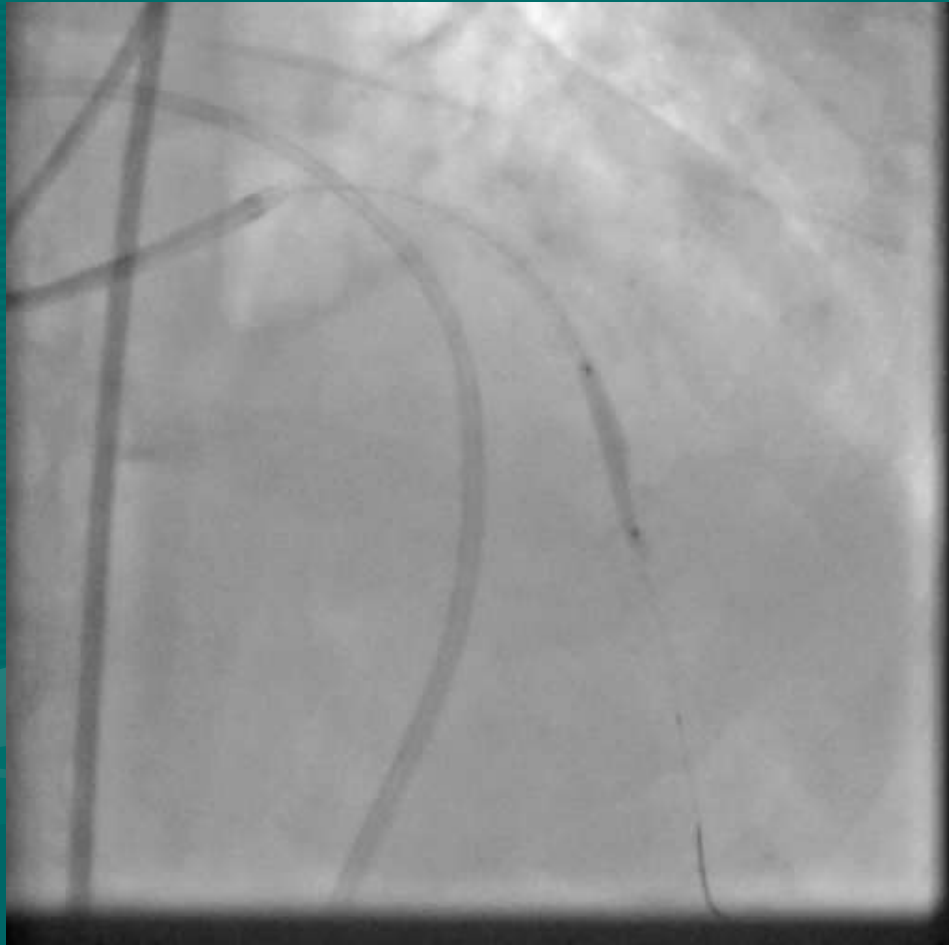
STENT....



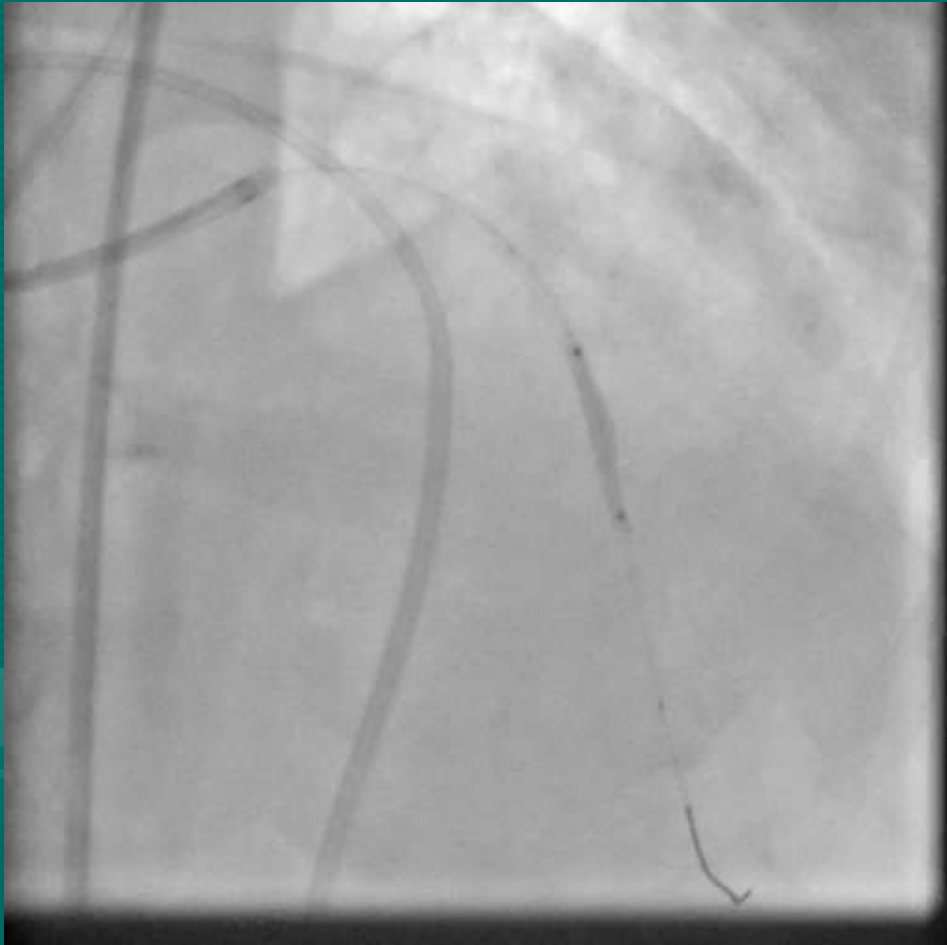TO....



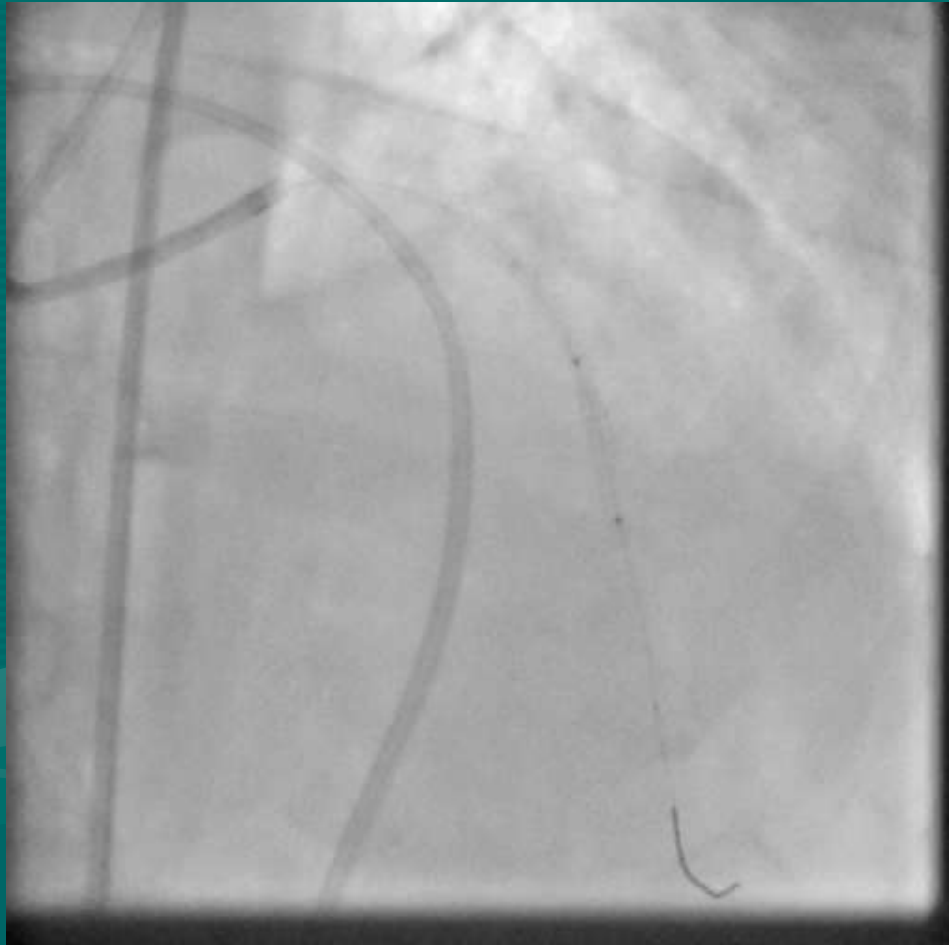
ARRIVE.....



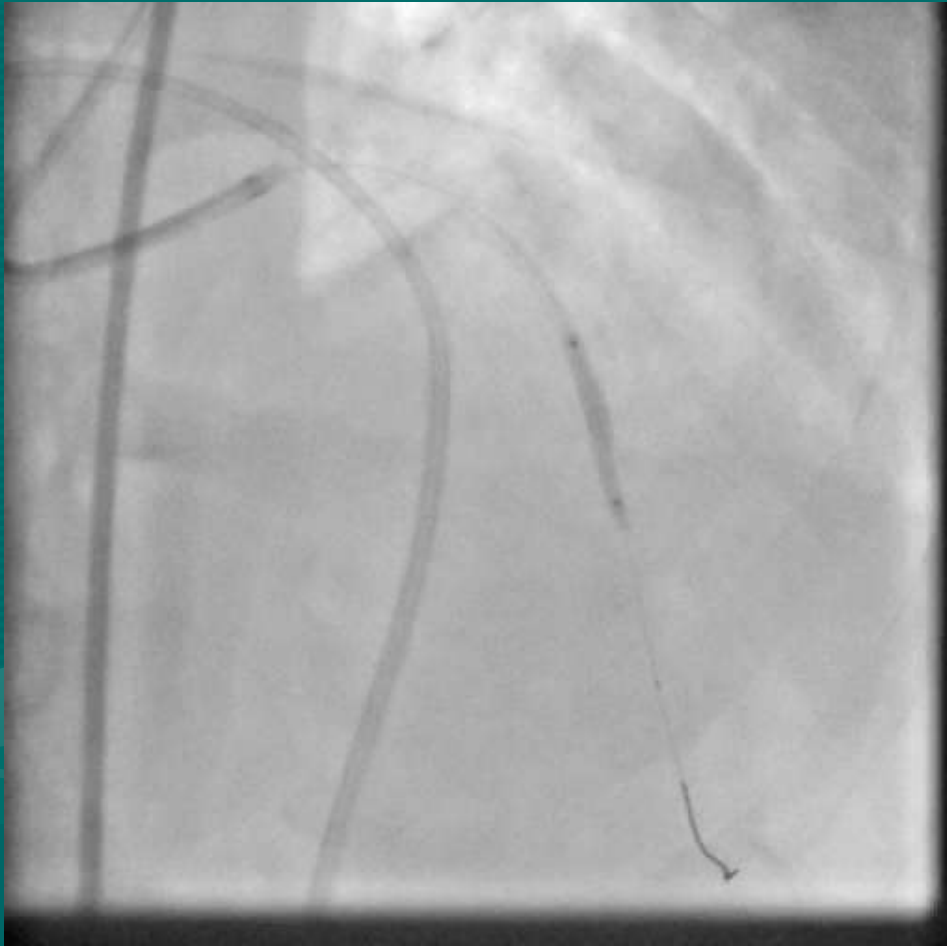FROM.....



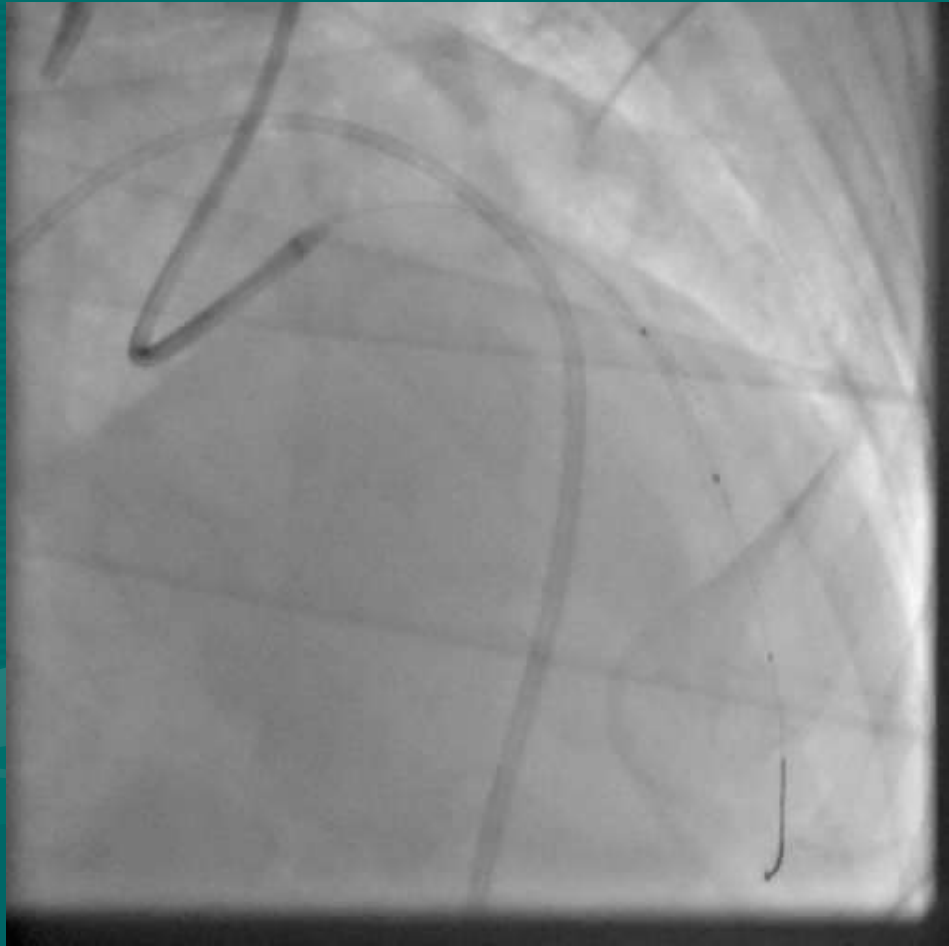
FAR....



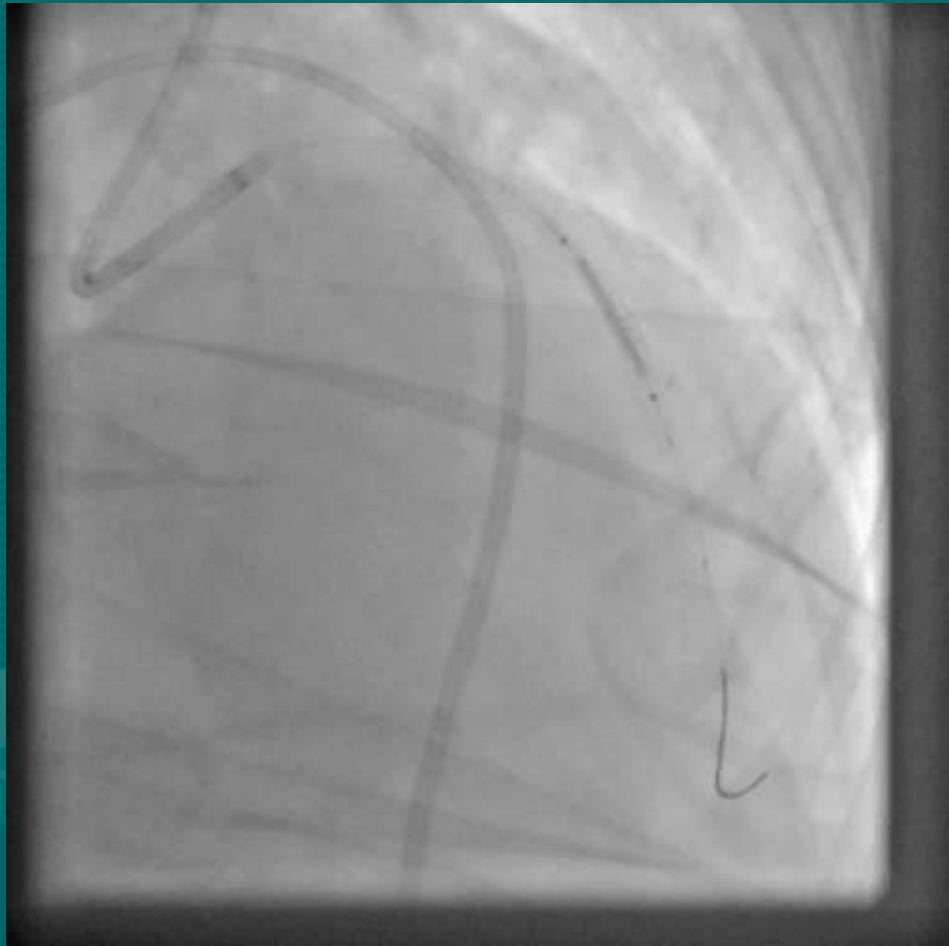
FAR.....

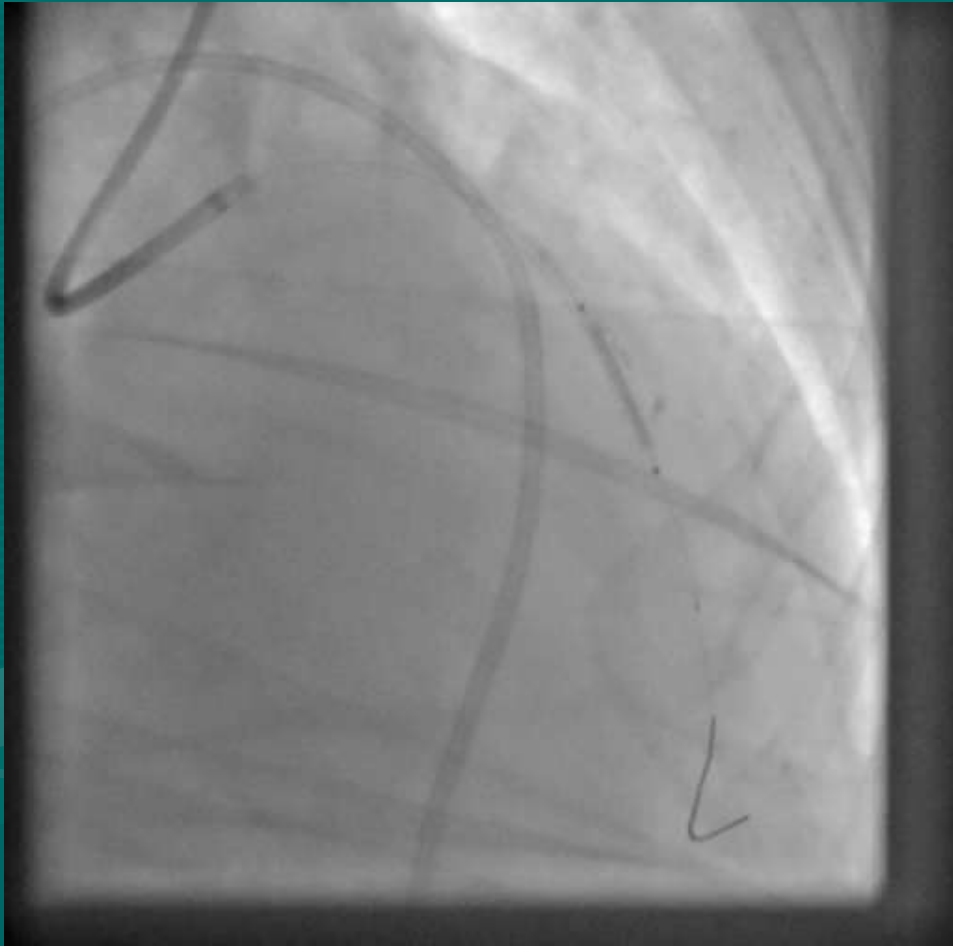


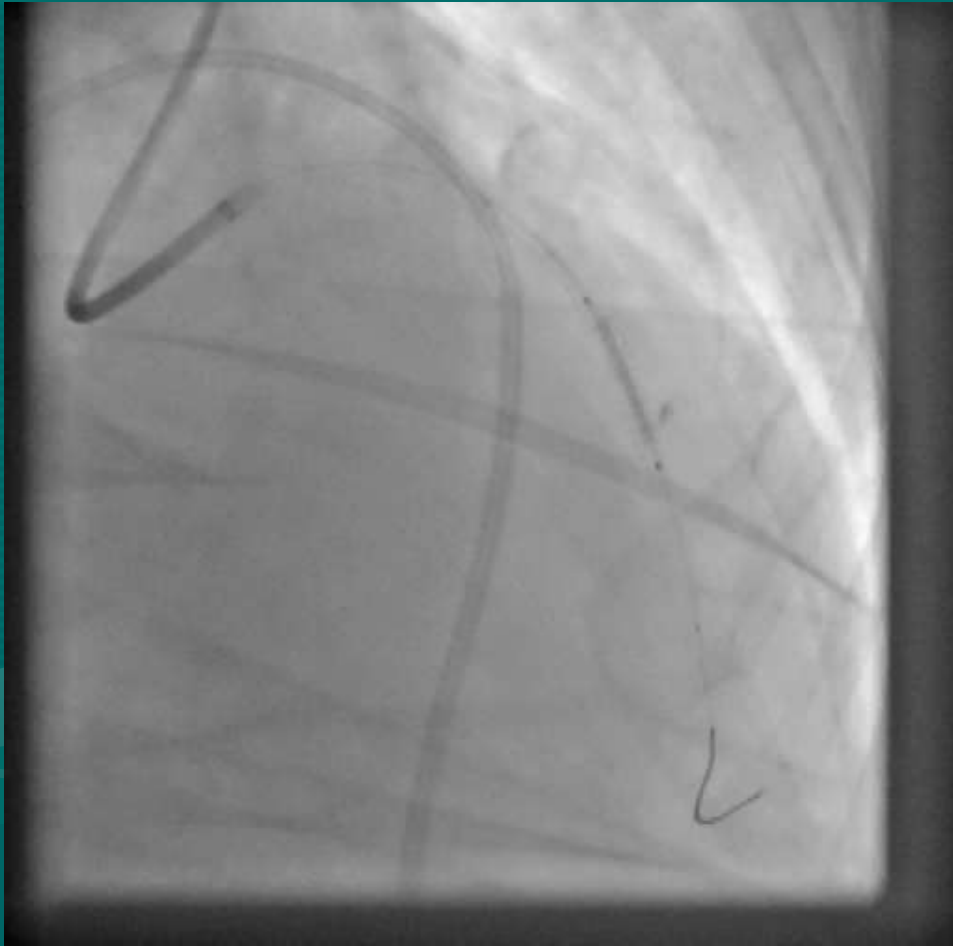FAR AWAY.....

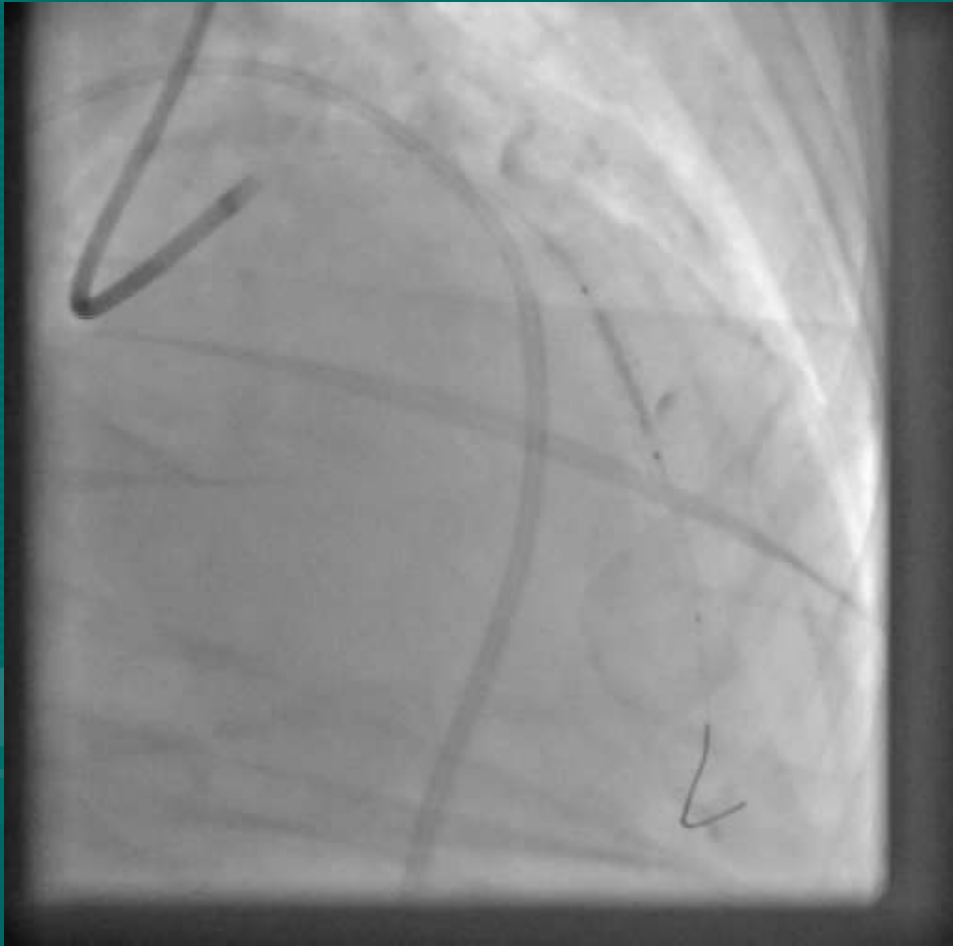


3.0 x 15 COVERED STENT

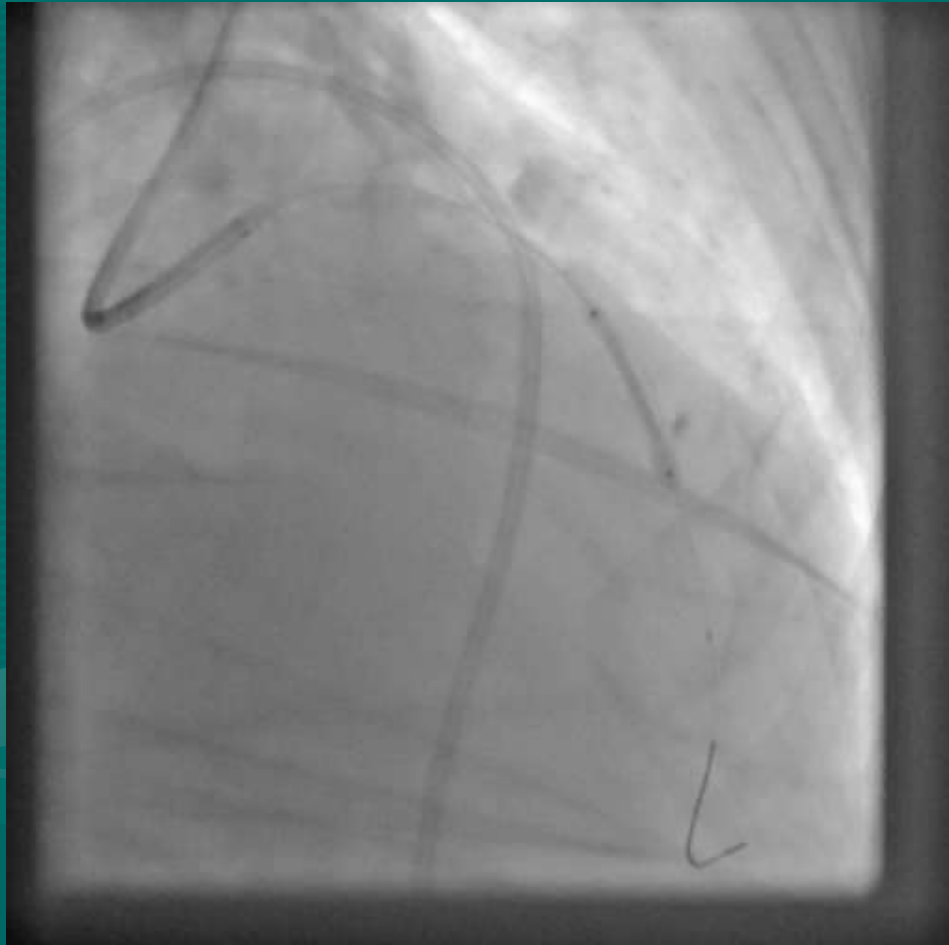




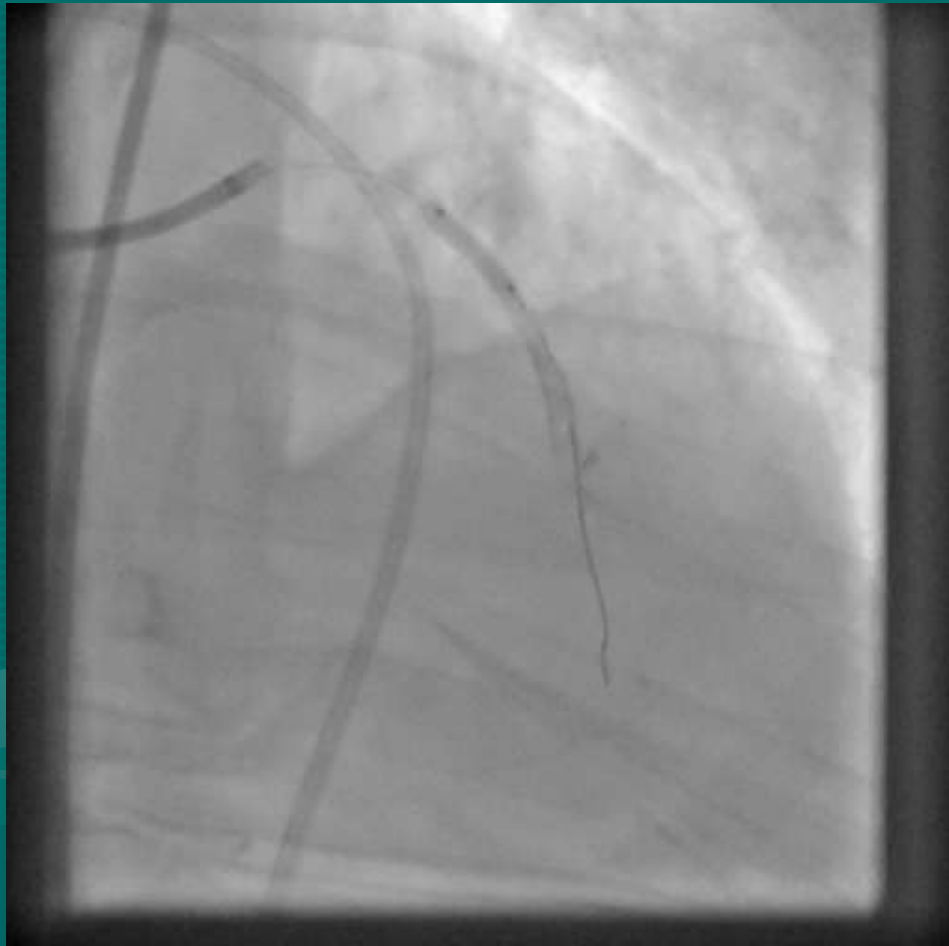



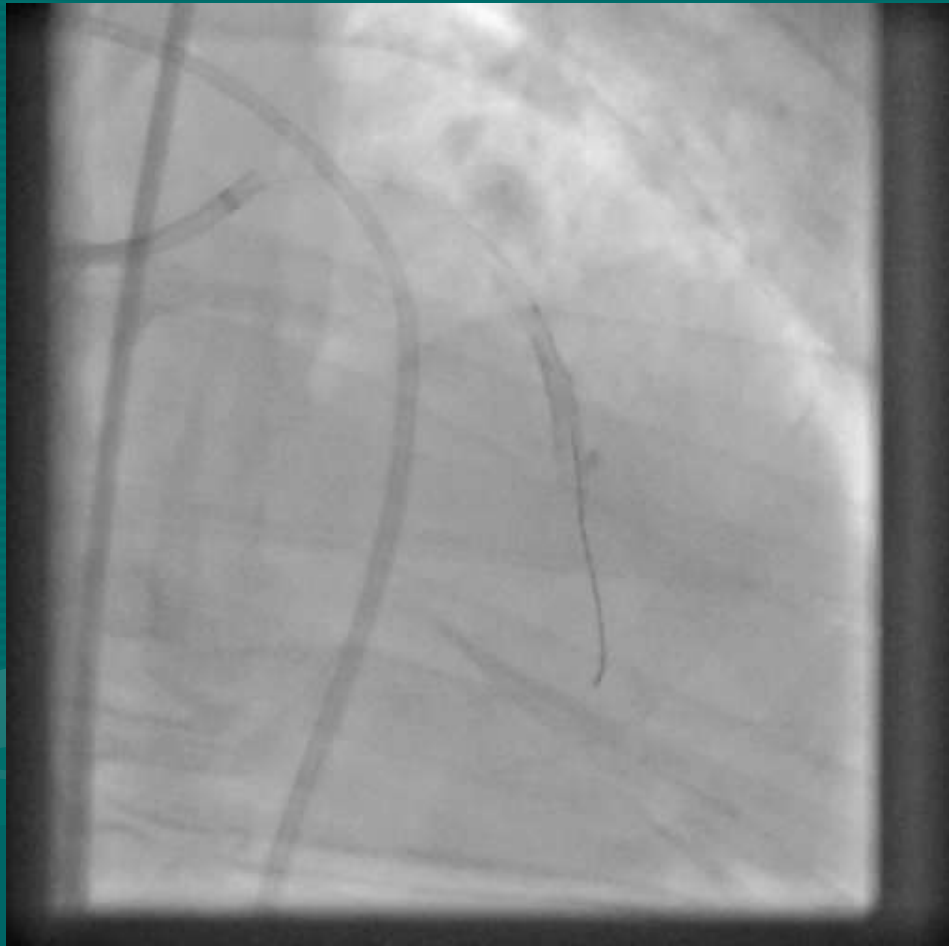
DEPLOYED

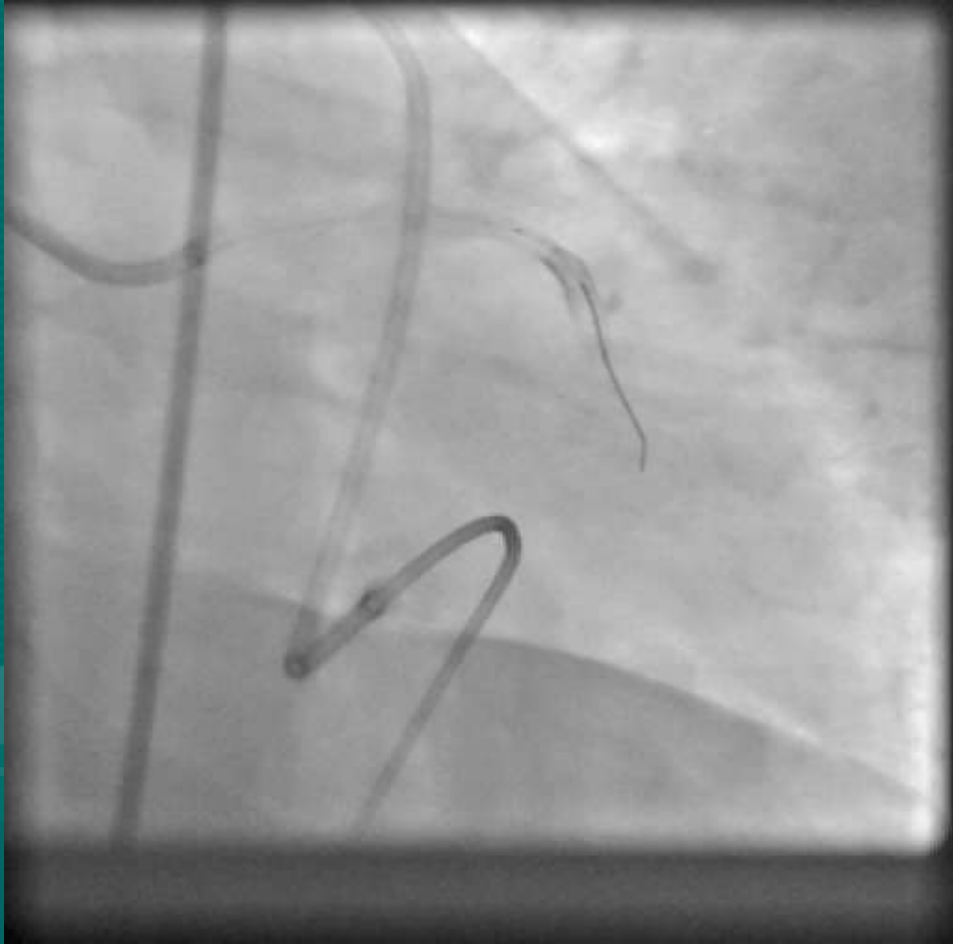

POST DILATED

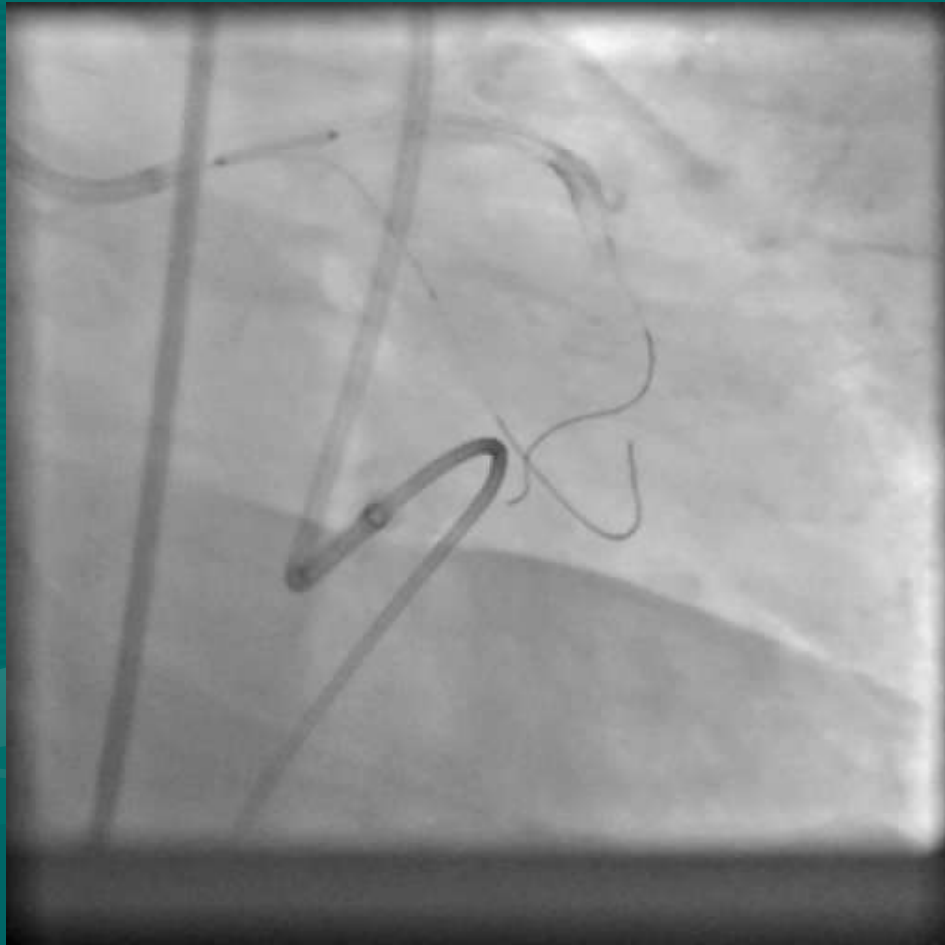


NEW ISSUE

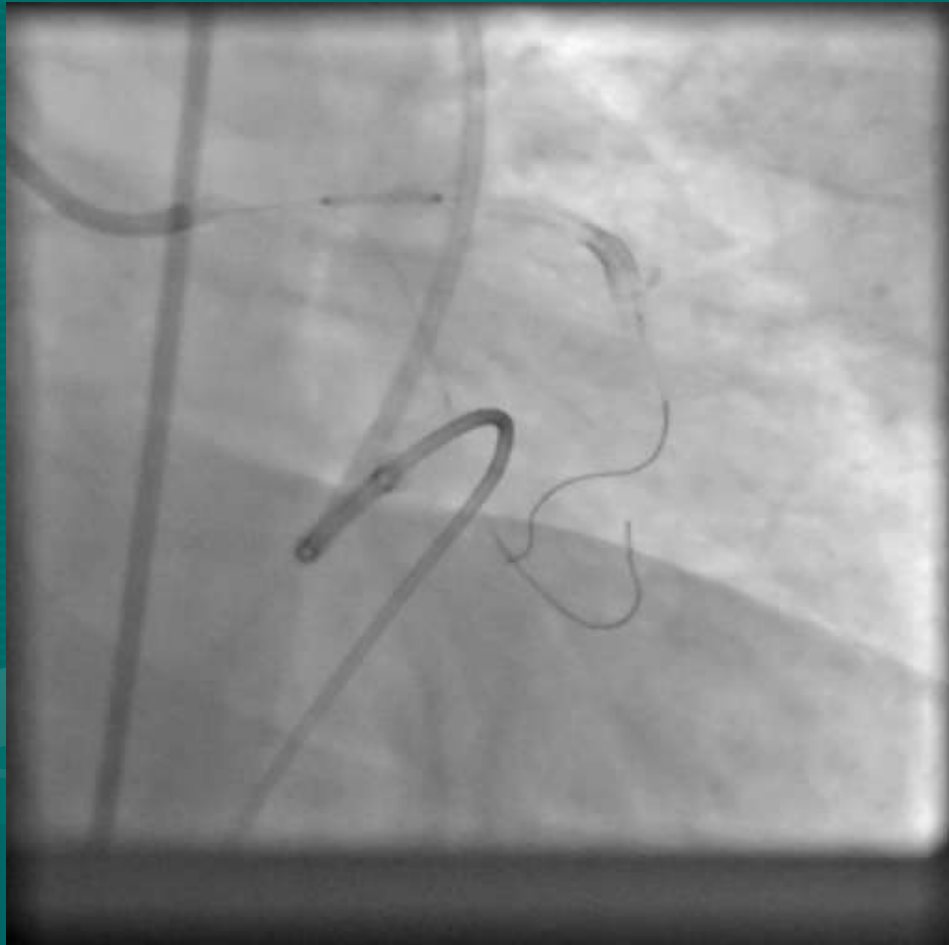




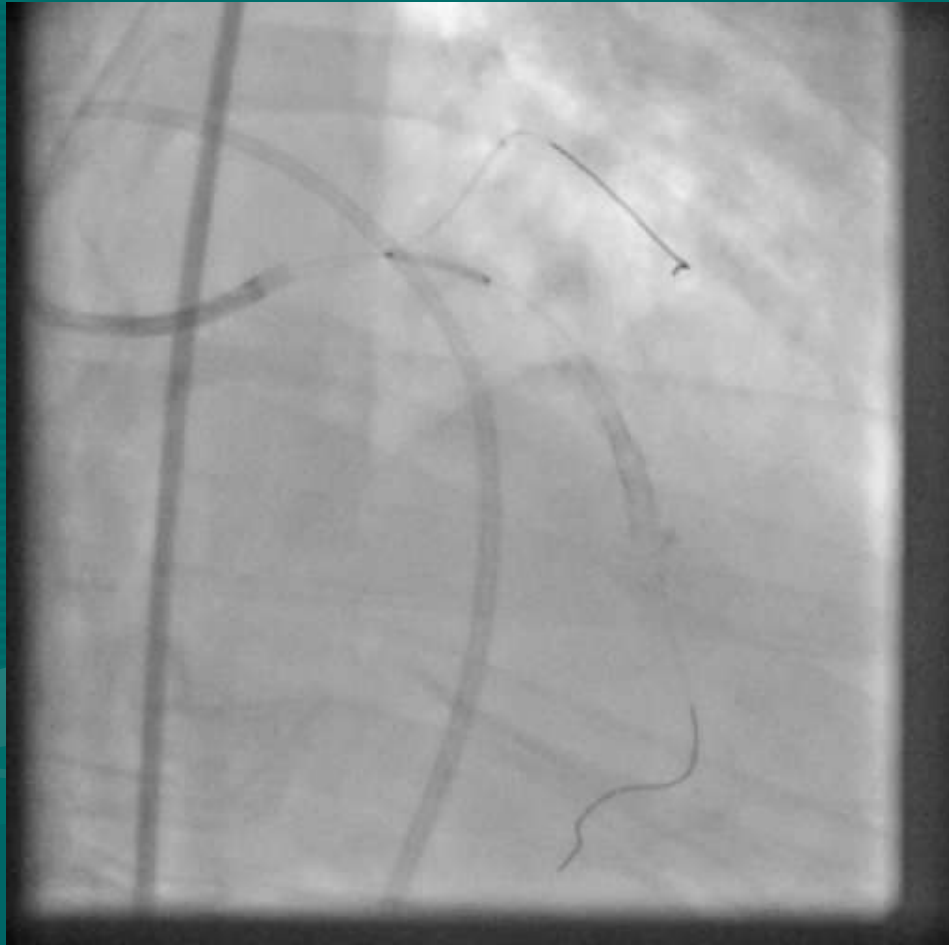
LCX WIRED; 3.5 X 12 XIENCE V



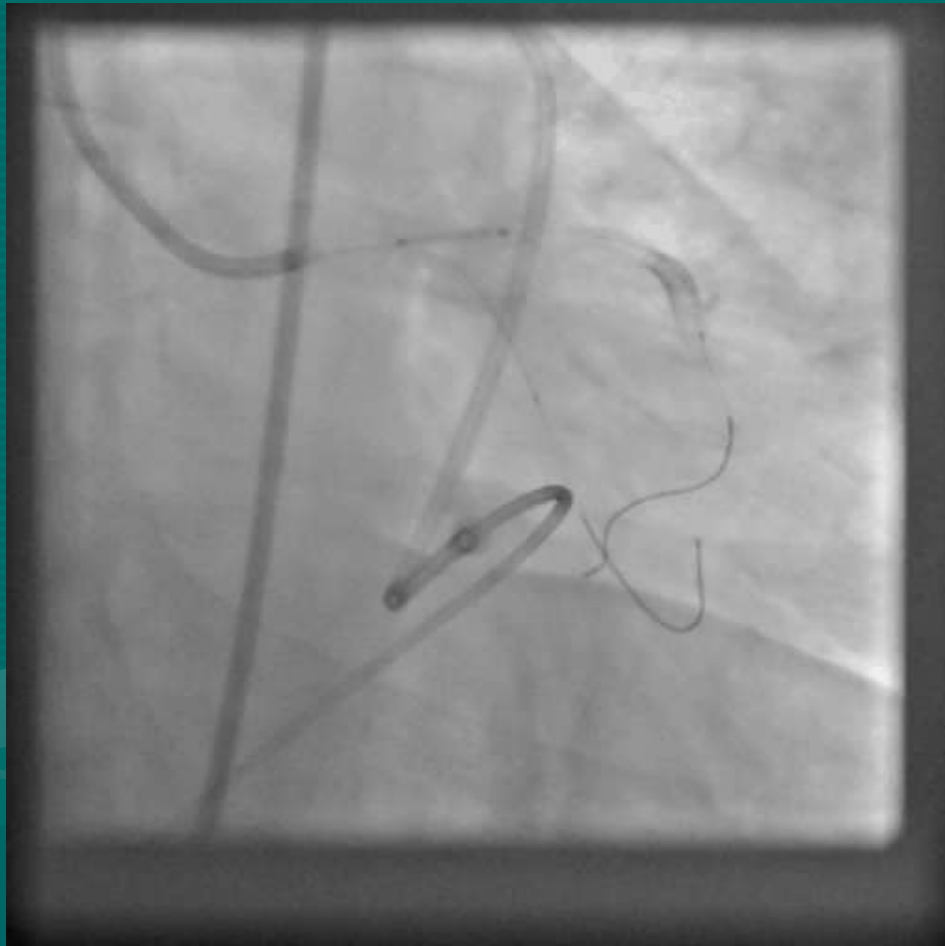
POSITIONED



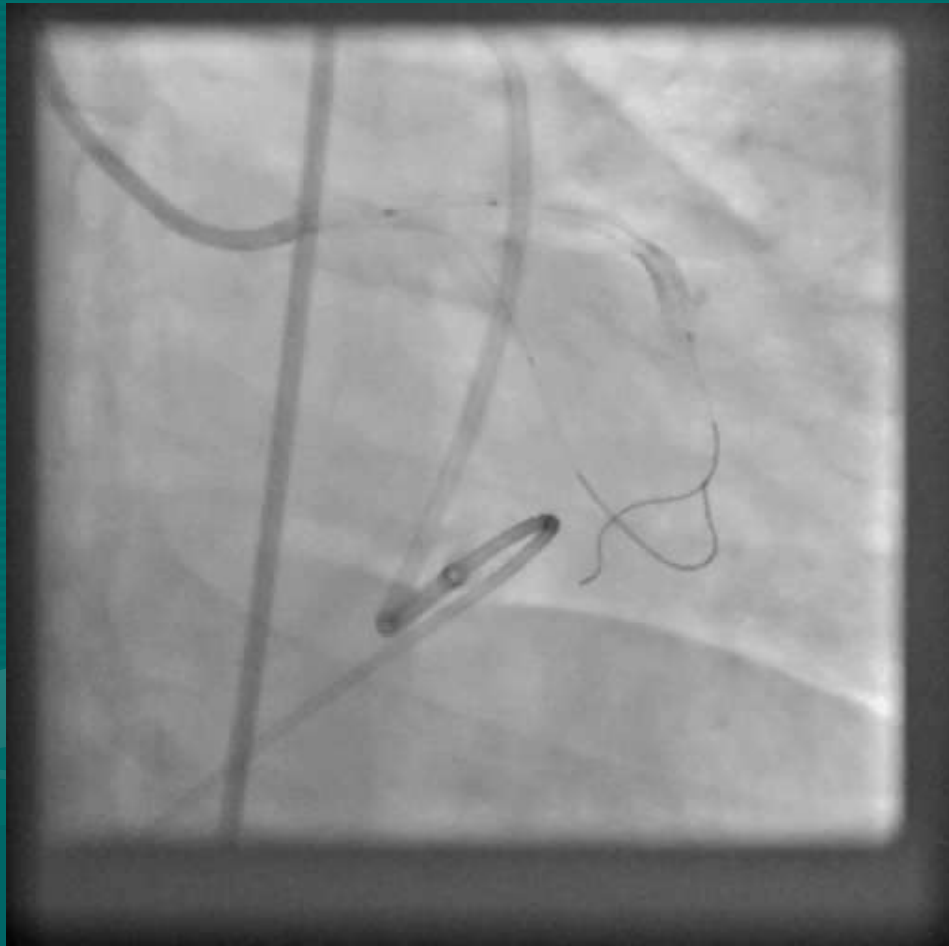
POSITION CONFIRMED



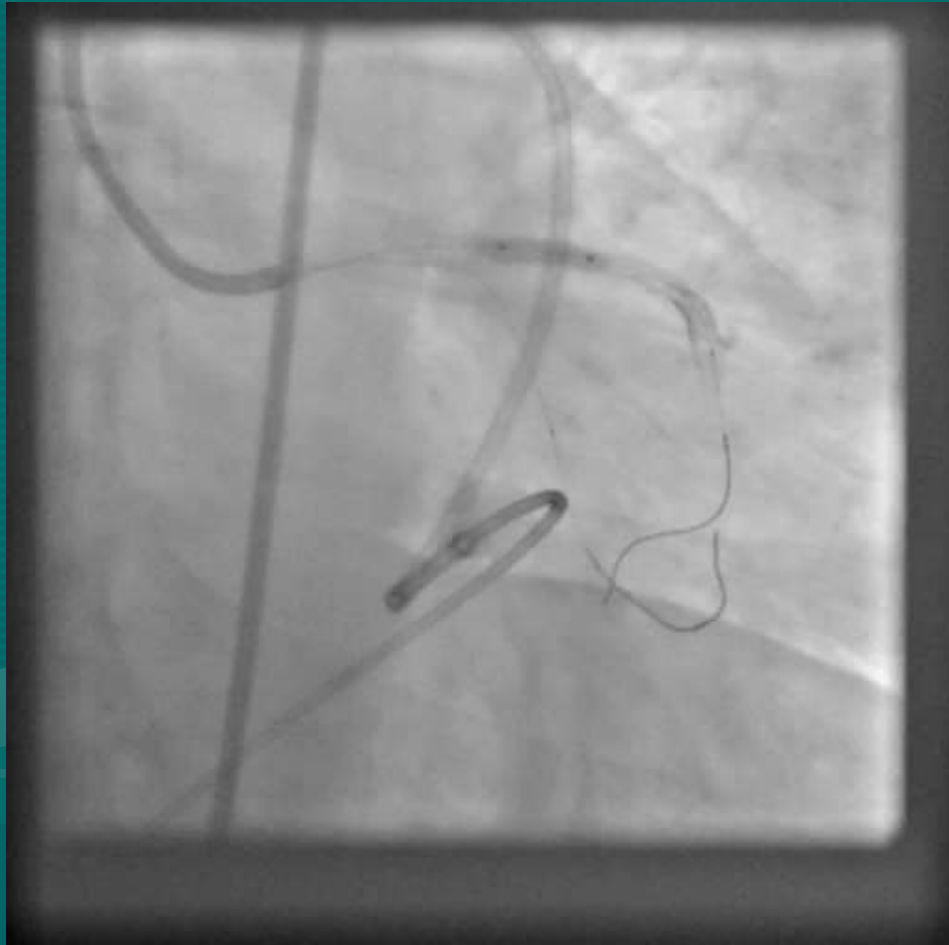
RECHECKED



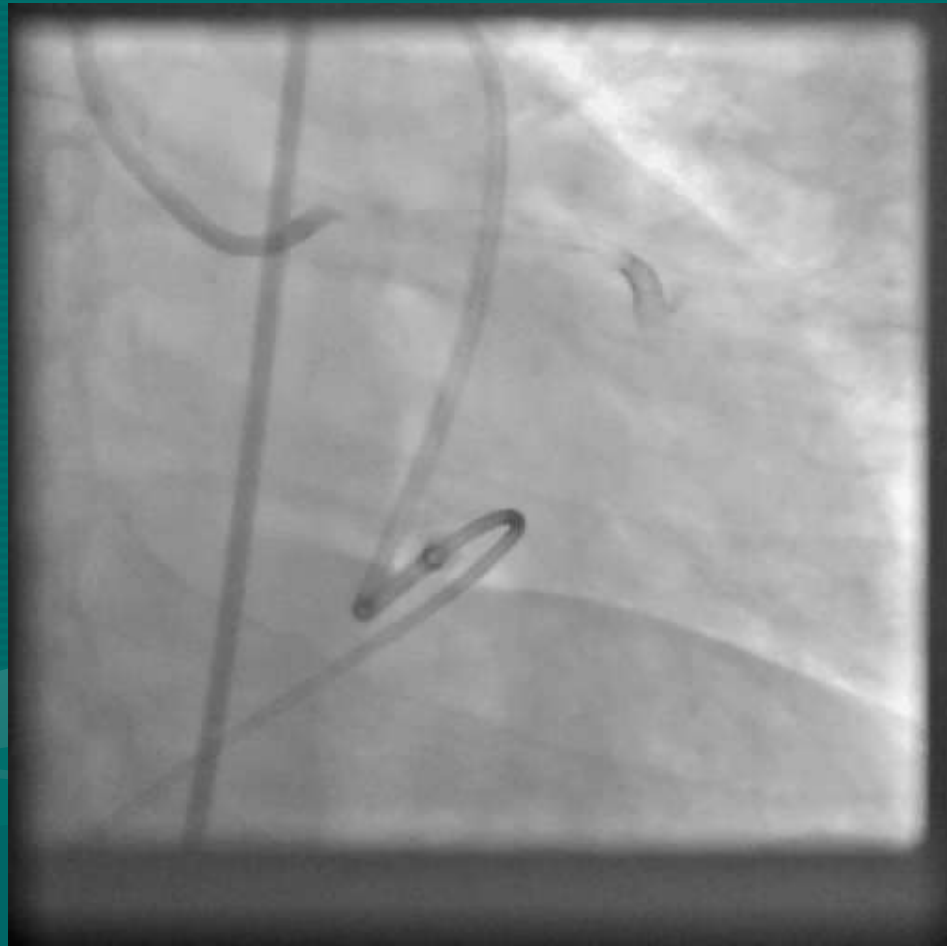
DEPLOYED



POST DILATED

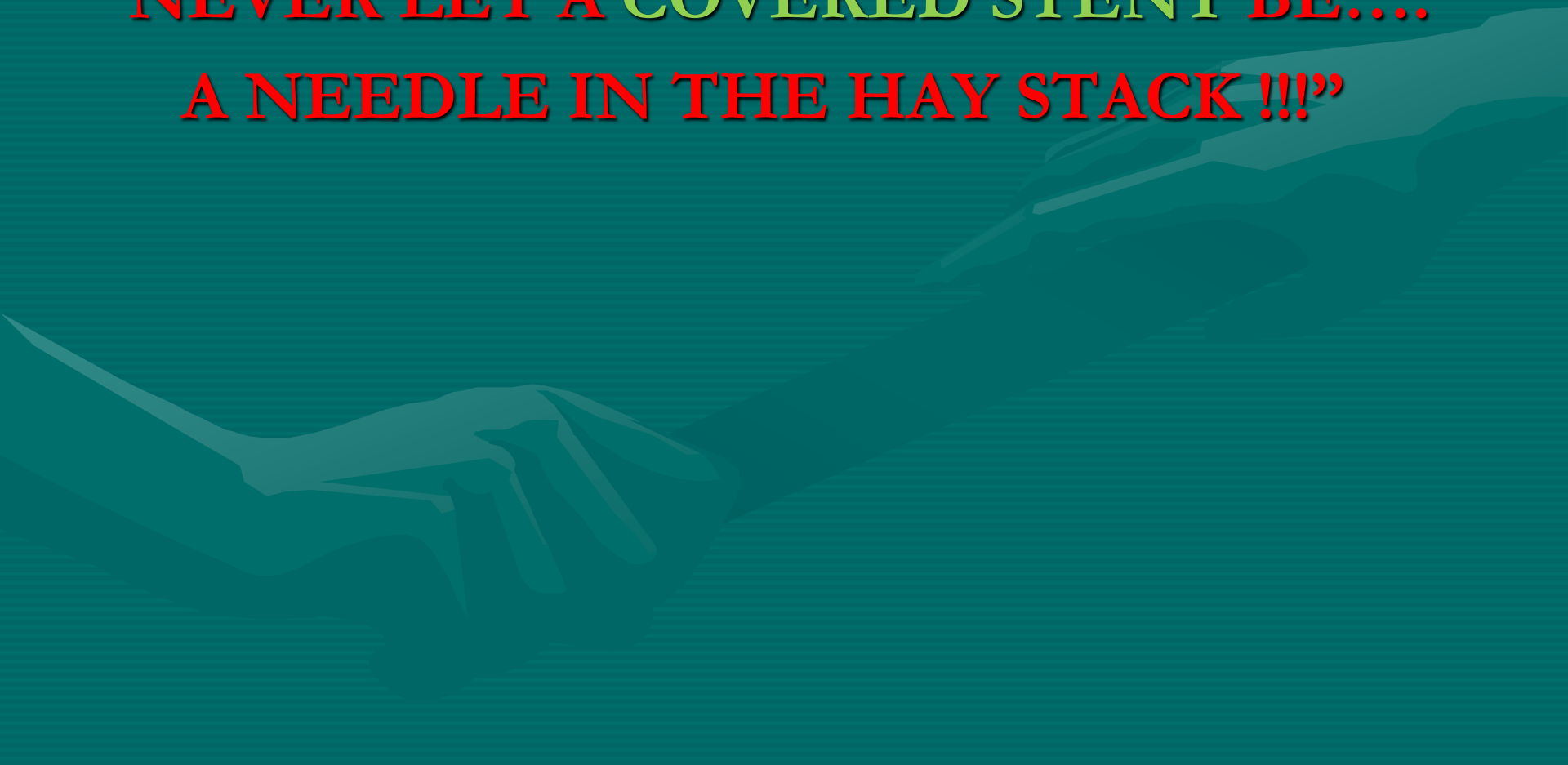


FINAL RESULT



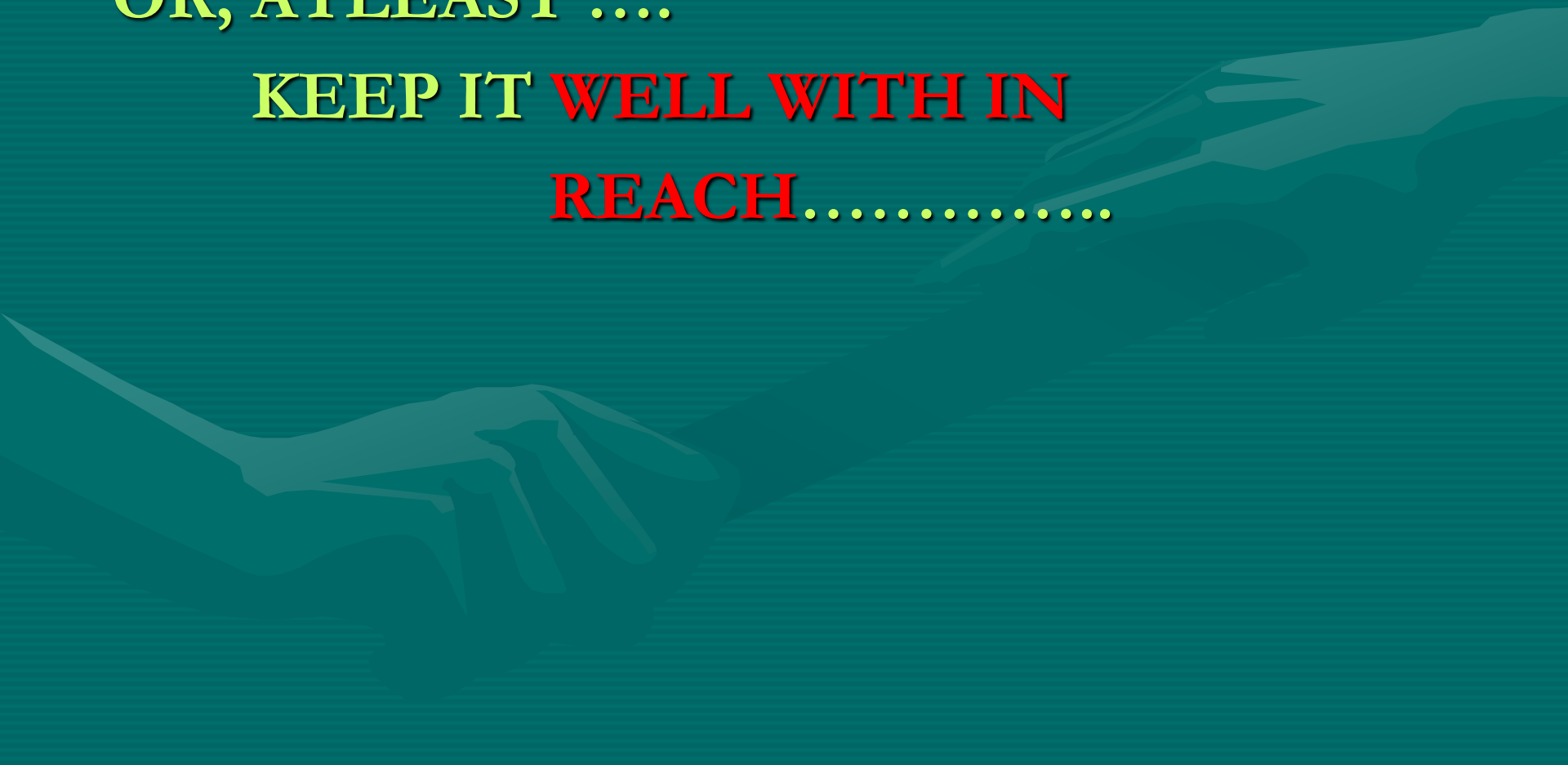MORAL OF THE STORY:

**“NEVER LET A COVERED STENT BE....
A NEEDLE IN THE HAY STACK !!!”**



OR, ATLEAST

KEEP IT **WELL WITH IN**
REACH.....





...AT LEAST IN THY **NEIGHBOUR'S**
CATH LAB....

TQVM

