

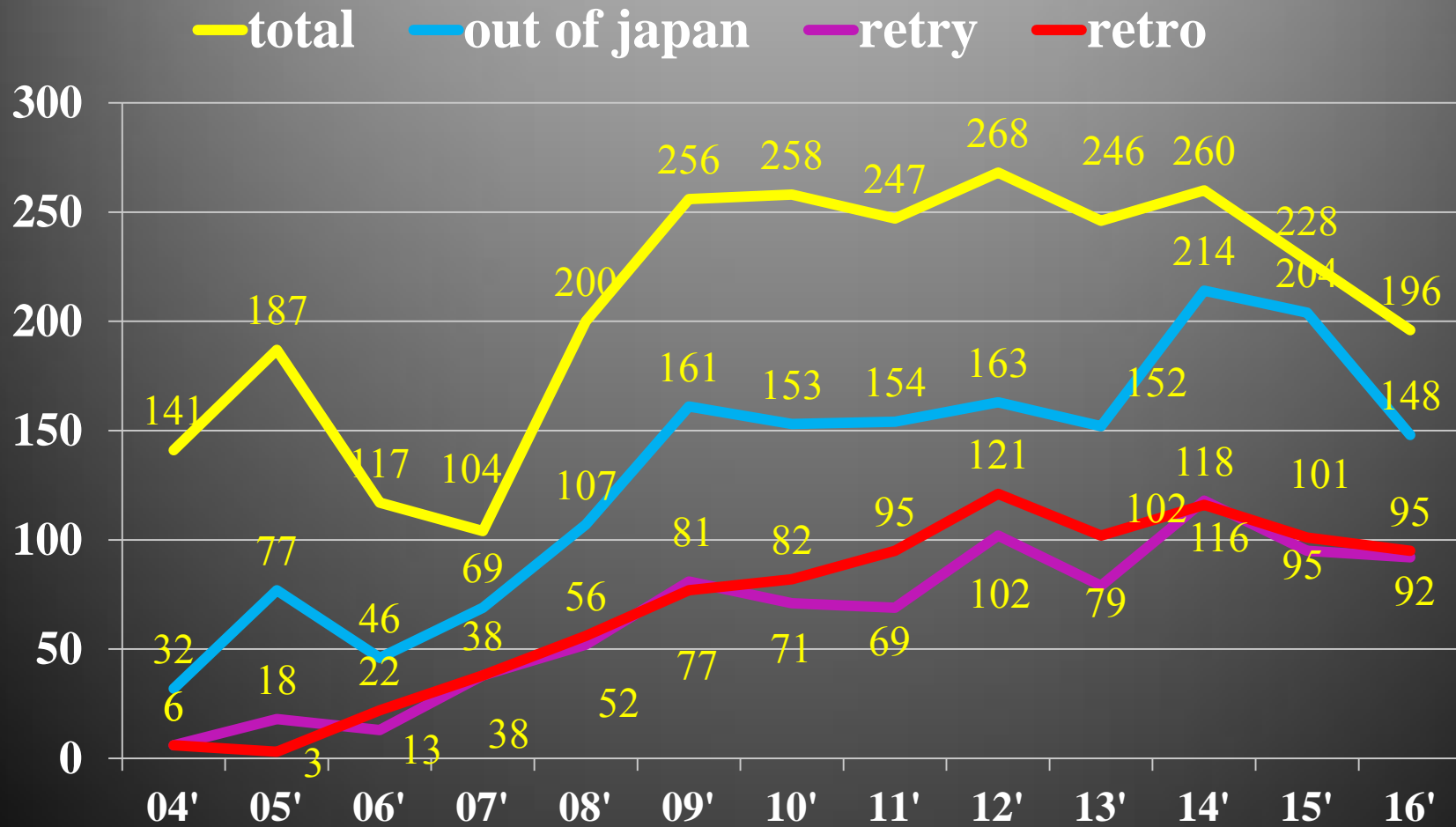
Learning from ACT programs -lesson from the CTO cases-

Toshiya Muramatsu

Tokyo Kamata Hospital

Tokyo General Hospital

Number of CTO lesion

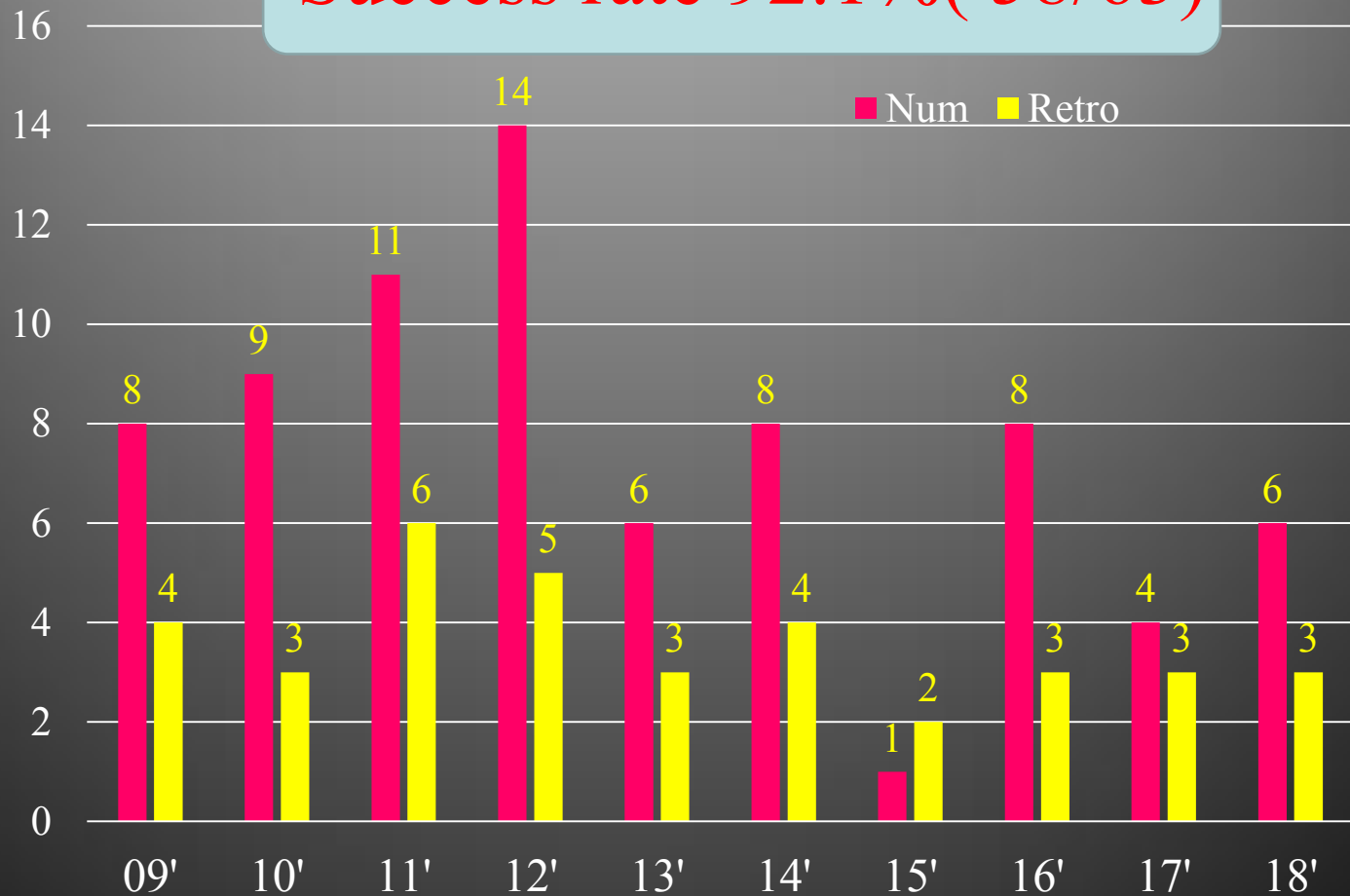


Tokyo General / Kamata Hospital

CTO pts at ACT program

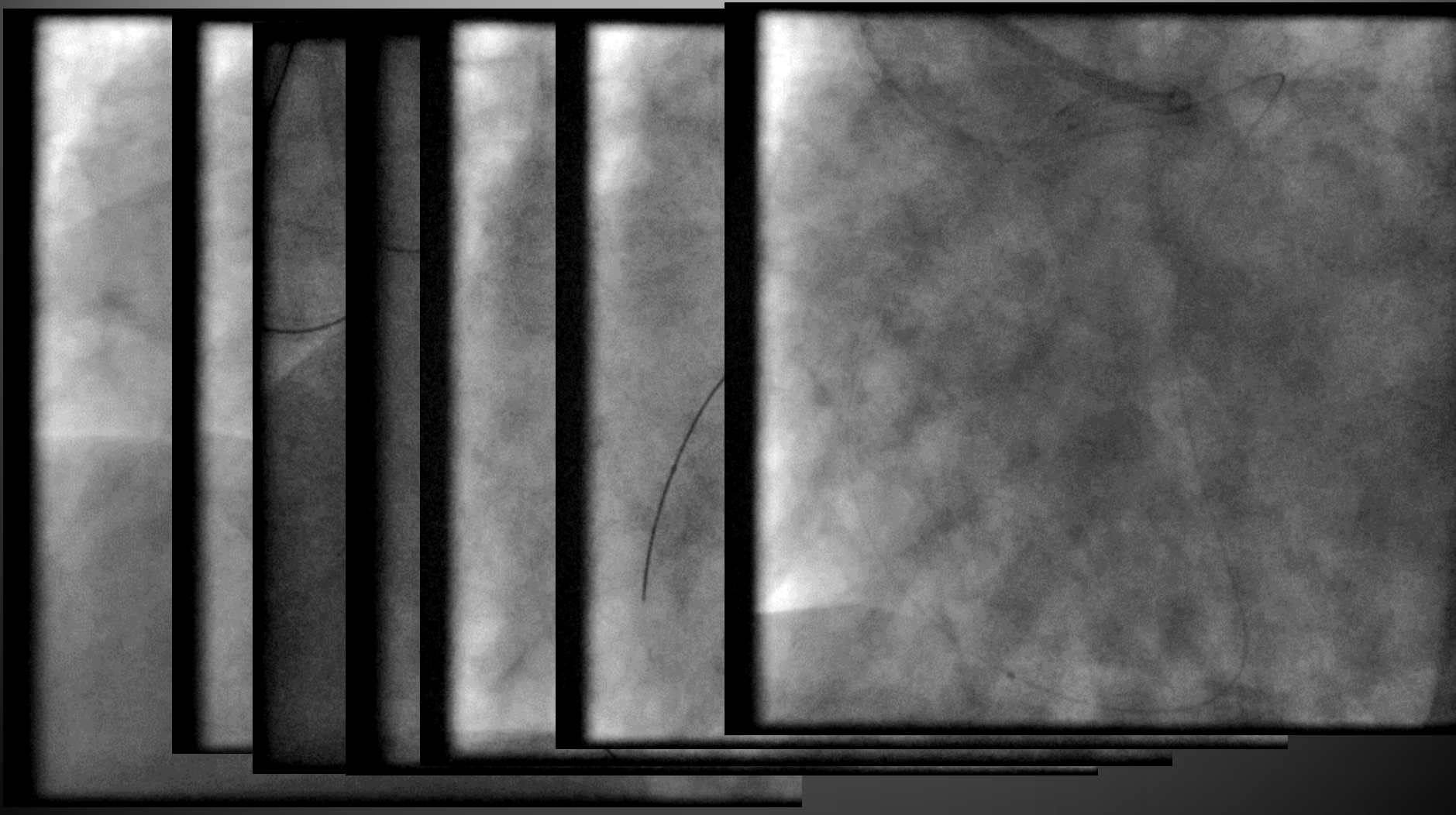n

Success rate 92.1% (58/63)



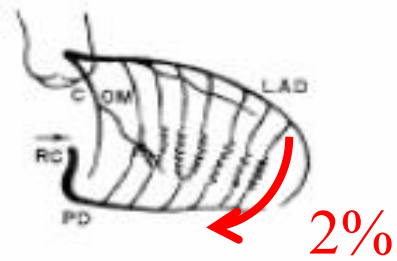
Tokyo General / Kamata Hospital

First Case ACT Program 09'2/25

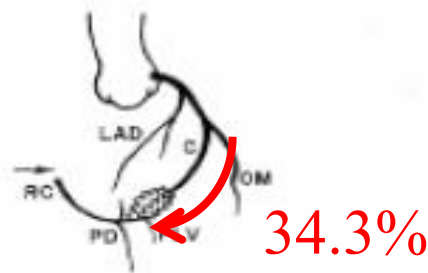


Tokyo General / Kamata Hospital

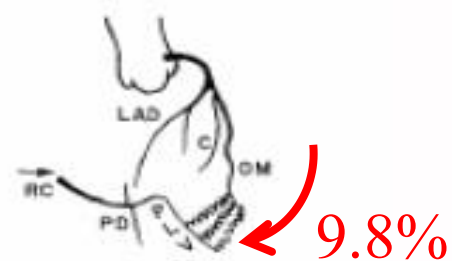
Epicardial Collateral (RCA)



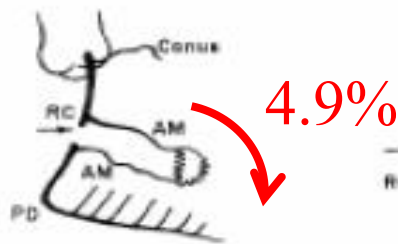
A. RAO-LC Injection (28)



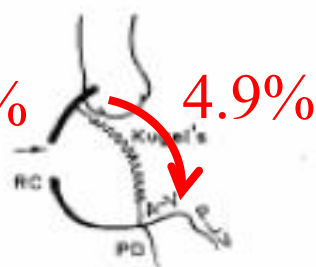
B. LAO-LC Injection (24)



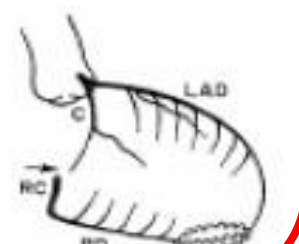
C. LAO-LC Injection (17)



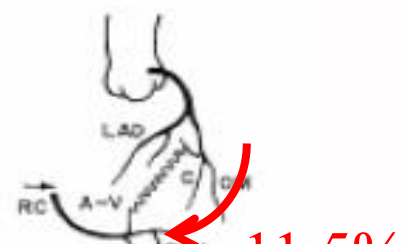D. RAO-RC Injection (9)



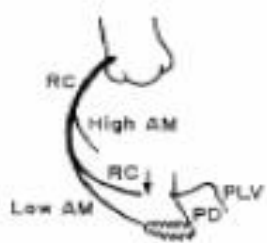
E. LAO-RC Injection (9)



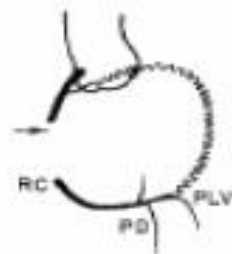
F. RAO-LC Injection (9)



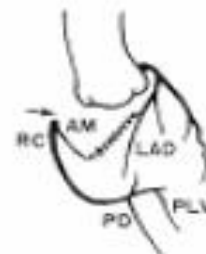G. LAO-LC Injection (6)



H. LAO-RC Injection (6)

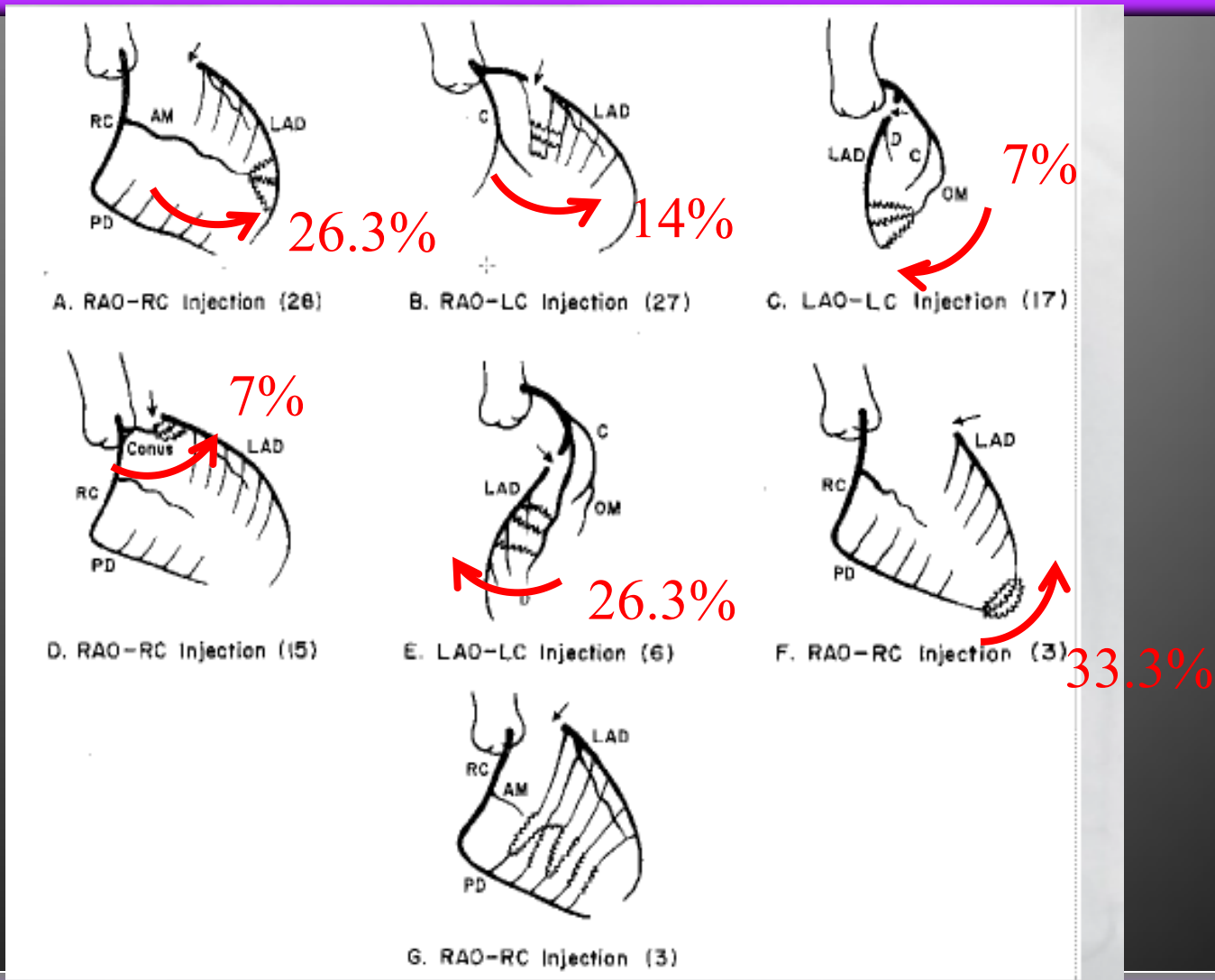


I. LAO-RC Injection (2)

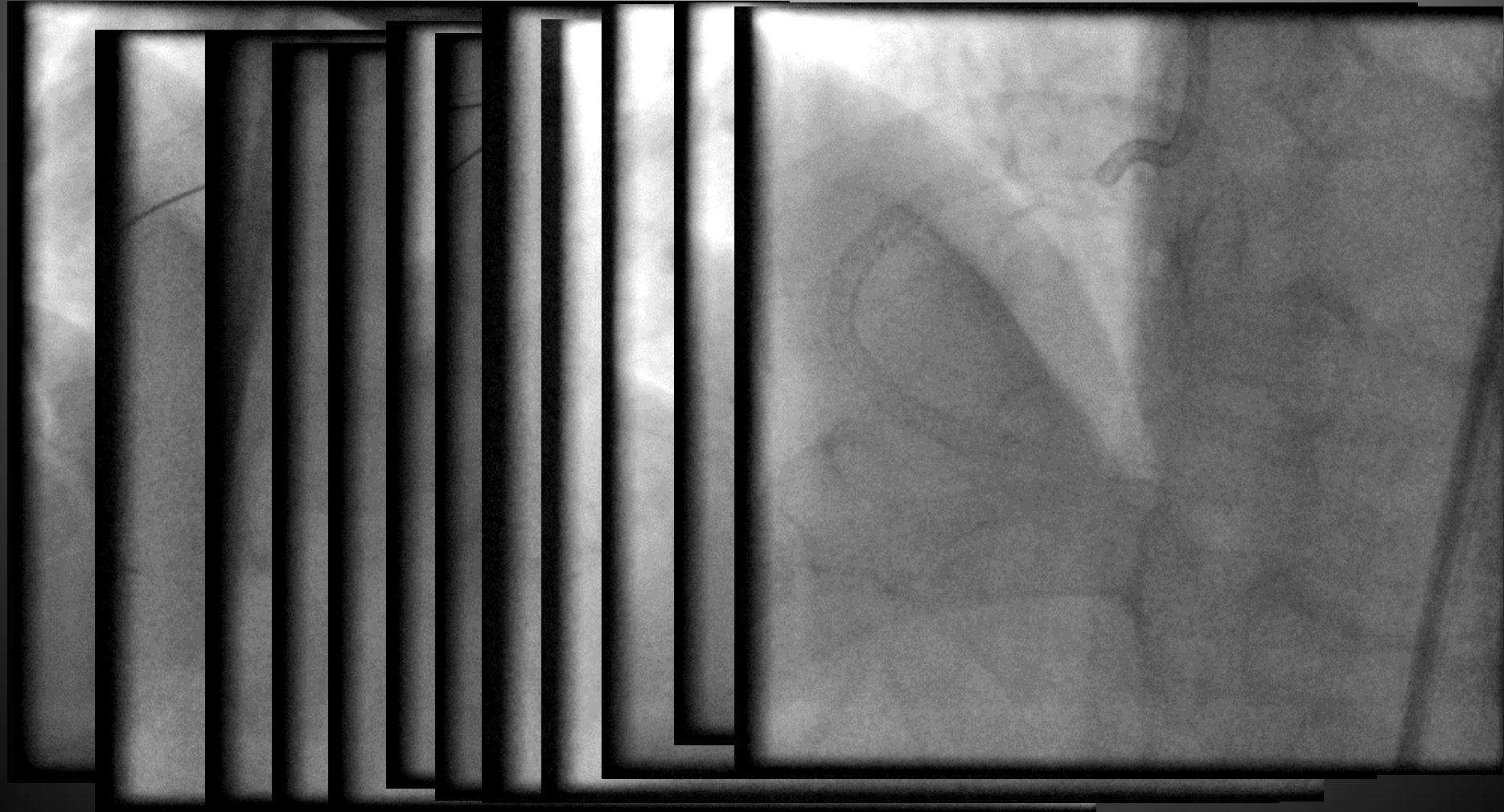


J. LAO-LC Injection (2)

Epicardial Collateral (LAD)

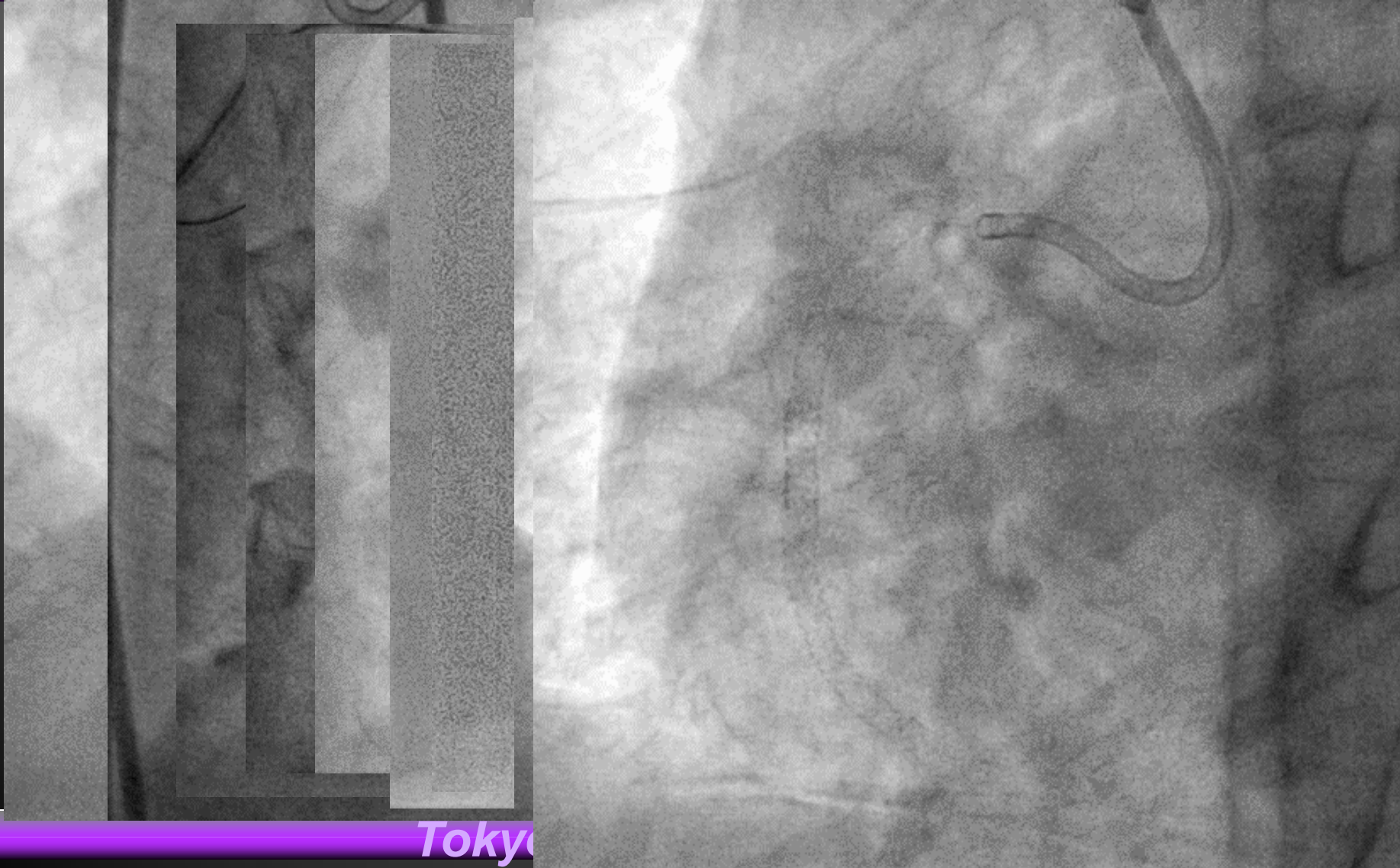

Toutous Apical channel



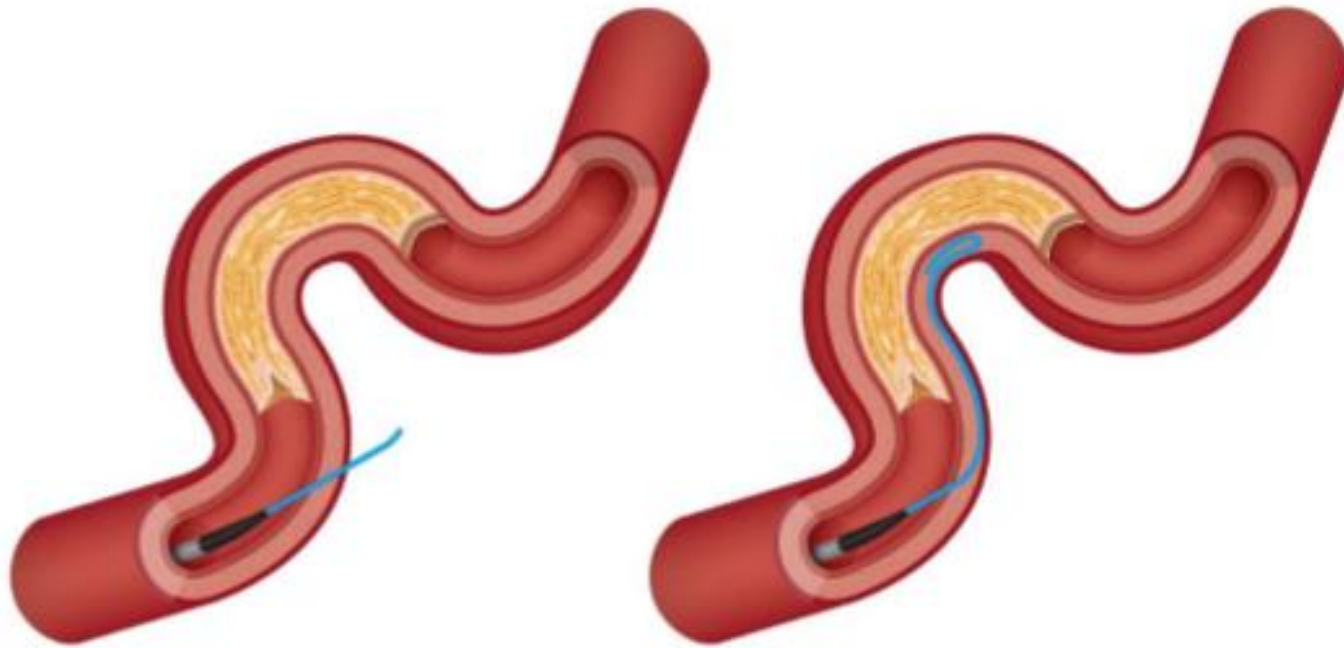
Tokyo General / Kamata Hospital

Toutous Atrial channel



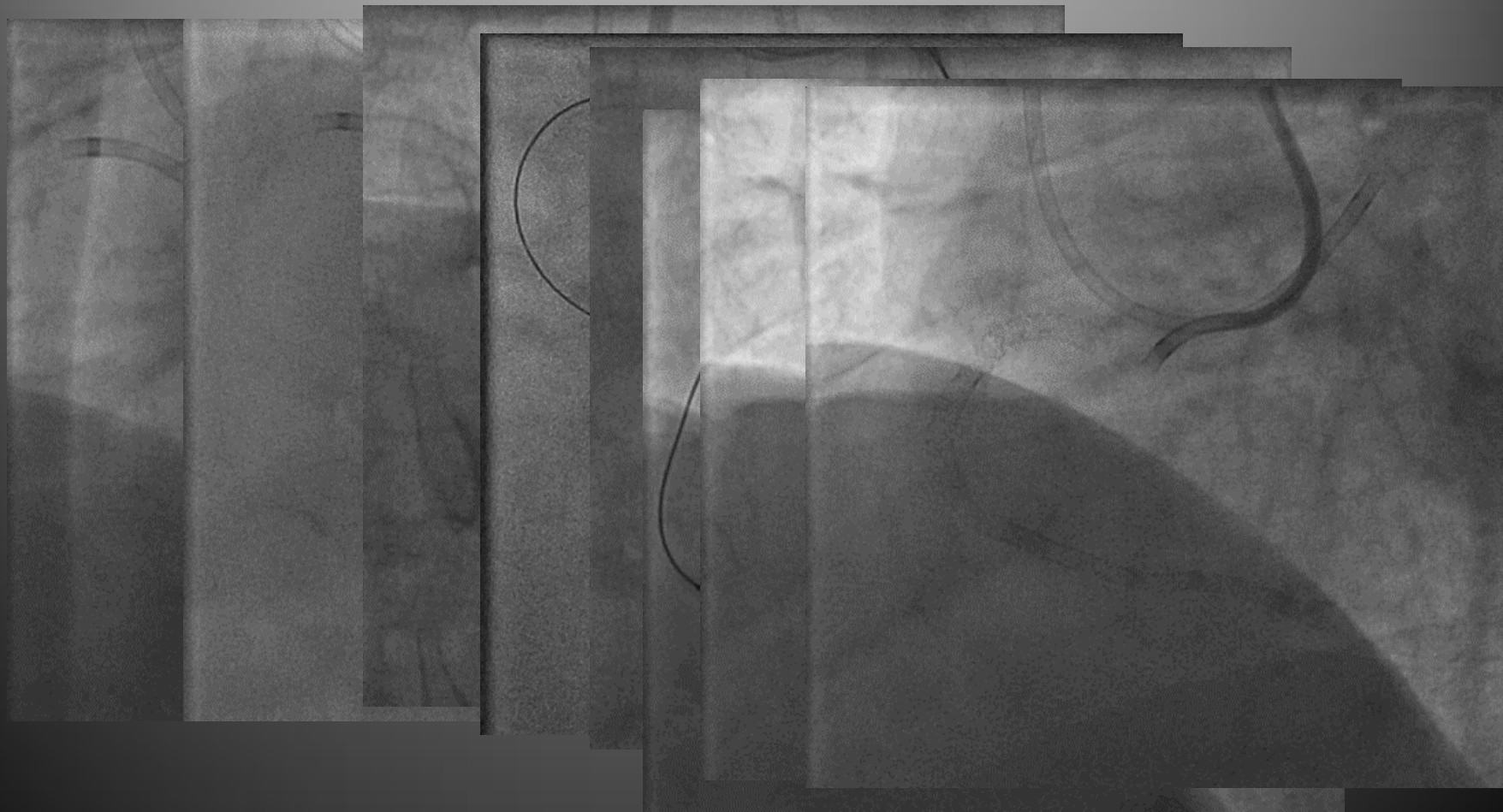
Tokyo

Straight vs. Knuckled wires



Illustrations from 'A Guide to Mastering Retrograde CTO PCI' / www.ctoibooks.com

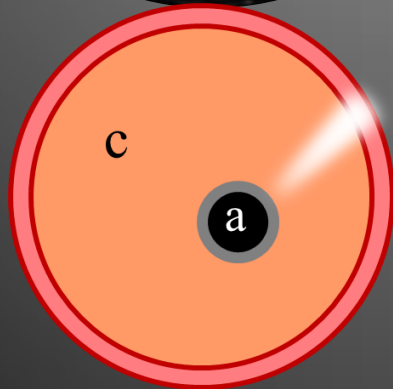
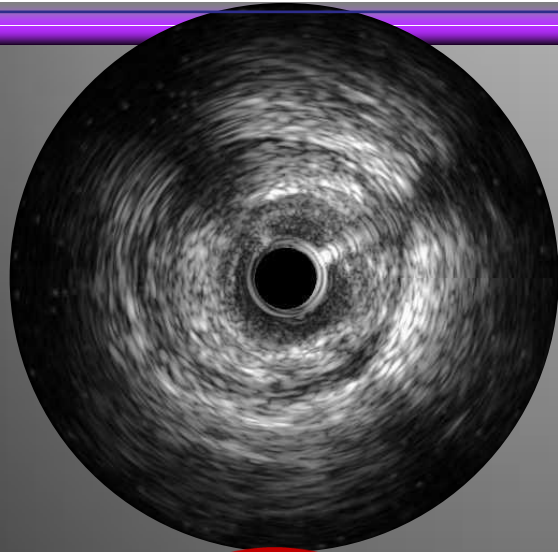
Knuckle plus r-CART for CTO



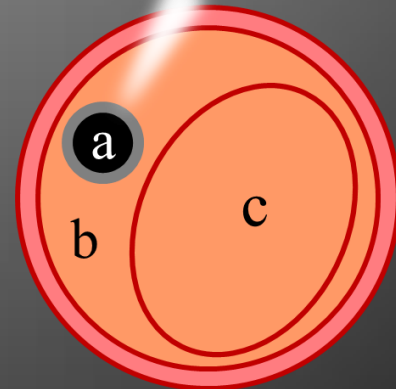
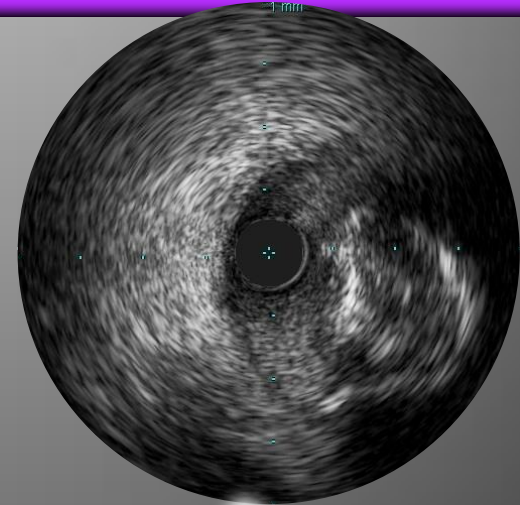
Tokyo General / Kamata Hospital

IVUS Image

Intimal vs. Sub-Intimal Tracking



Intimal Plaque Tracking

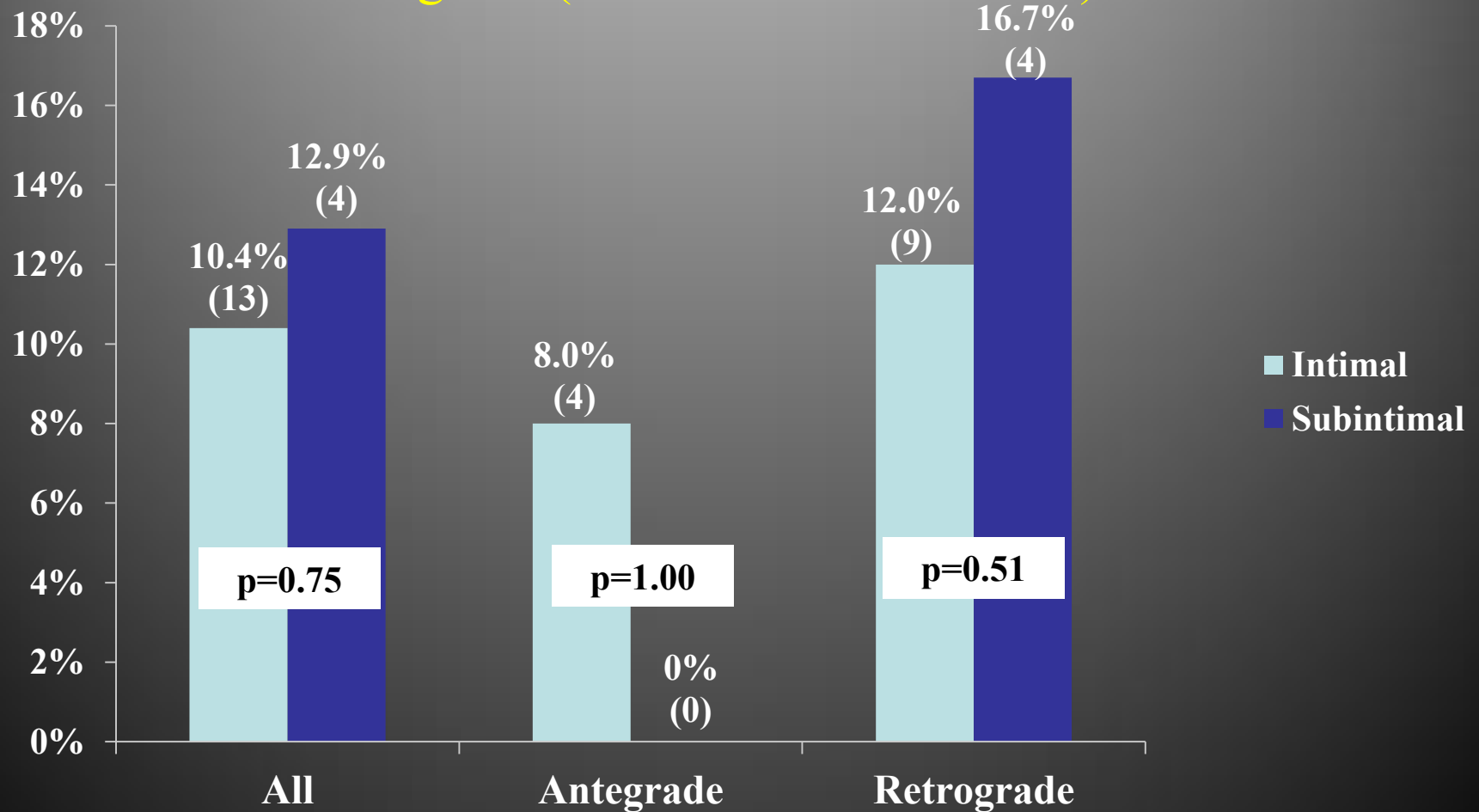


Sub-Intimal Tracking

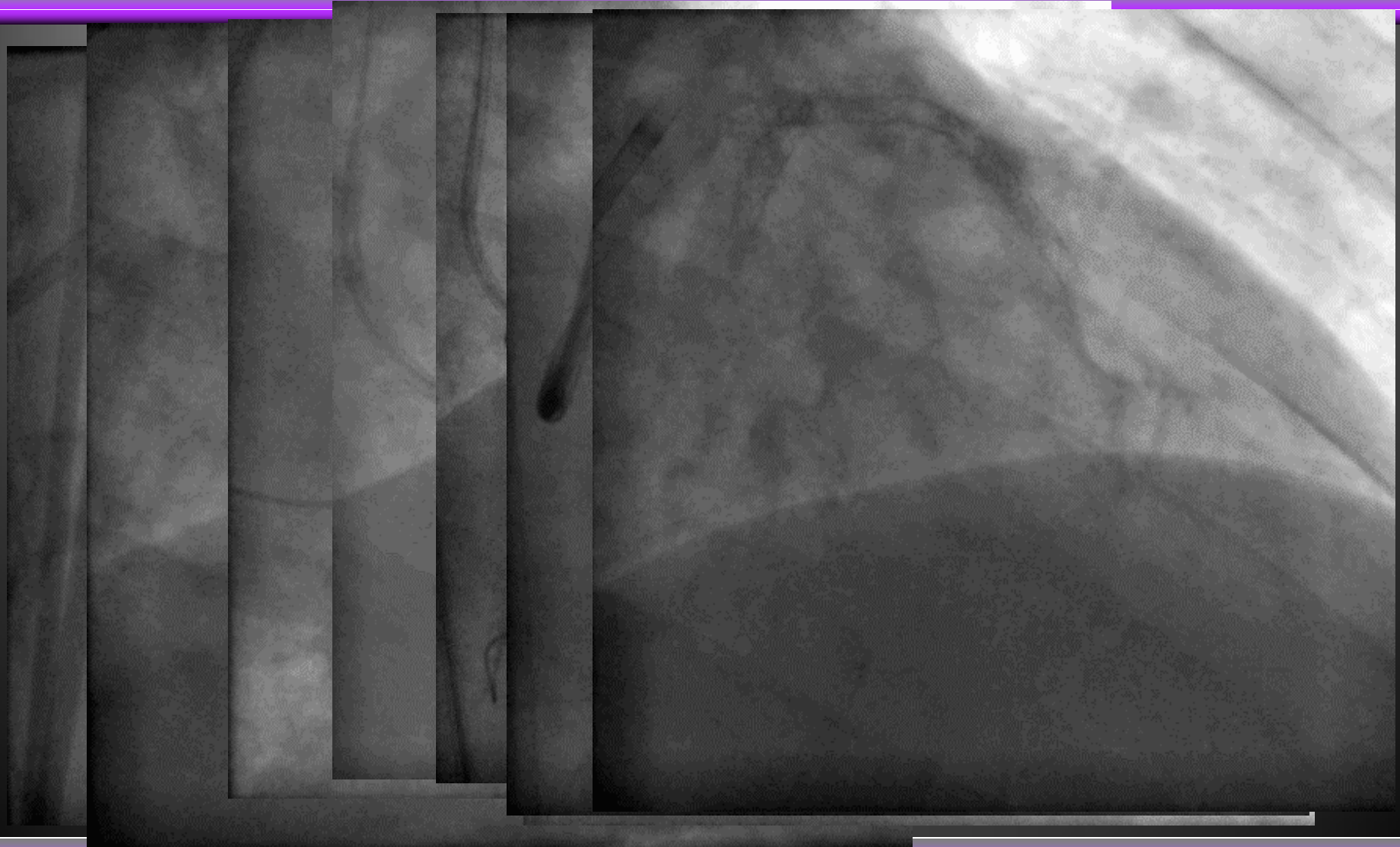a = IVUS catheter , b = Sub-Intimal space, c = the Intimal Plaque

TVR at 12 months

Antegrade (Intimal vs. Sub-intimal)
Retrograde (Intimal vs. Sub-intimal)



Retrograde + Rota Therapy



Tokyo General / Kamata Hospital

Take Home Message

1. I have been performed PCI for CTO during 10 yrs ACT program.

2. **Congratulation !**

3. and educational opportunity for young interventional cardiologist.

4. ACT program gives me many valuable time and fateful encounter.