happinnovation

강북삼성병원

SAMSUNG

강북삼성병원

Basic of Echocardiography

이동오

전체 순서

- 1. 초음파 정의
- 2. heart anatomy
- 3. Echo window
- 4. Axis (Measure,Wall motion)

1. 초음파 정의

SAMSUNG 강북삼성병원

초음파란 무엇인가?

- 인간이 들을 수 있는 소리의 한계를 넘어선 음파
  - ✓ 주파수 **(Frequency) > 20kHz**
  - ✓ 임상 진단 초음파 **2-12 MHz**
- 초음파 검사는 이러한 고주파 초음파를 인체에 쏘아서 되돌아 오는 초음파를 받아 영상을 구성함으로써 내부의 장기를 관찰할 수 있는 검사임.
- 초음파는 공기를 통과하기 어려우므로, 초음파 검사시 탐촉자와 피부의 완벽한 접촉이 요구됨.

심장초음파

- 심장 초음파는 초음파를 이용하여 실시간으로 심장의 움직이는 모습을 관찰할 수 있으며, 심장의 해부학적 구조의 이상, 심장 기능, 심장 내 압력 등을 실시간으로, 비침습적으로 관찰할 수 있는 검사법이다.

- 대부분의 심장 질환에 매우 중요하게 사용되고 있으며, 많은 심장 질환에서 높은 정확도를 가진다.

초음파 I

- 1. 2d
- 2. 3d
- 3. m-mode
- 4. doppler mode

2. Heart anatomy

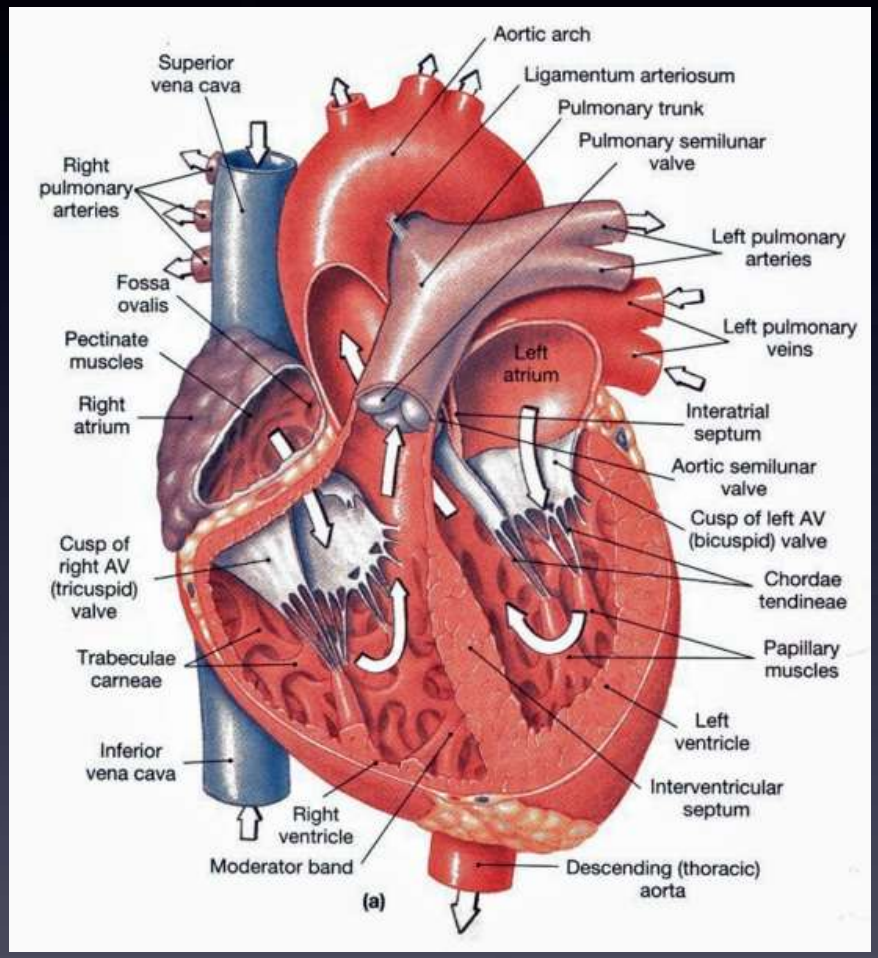

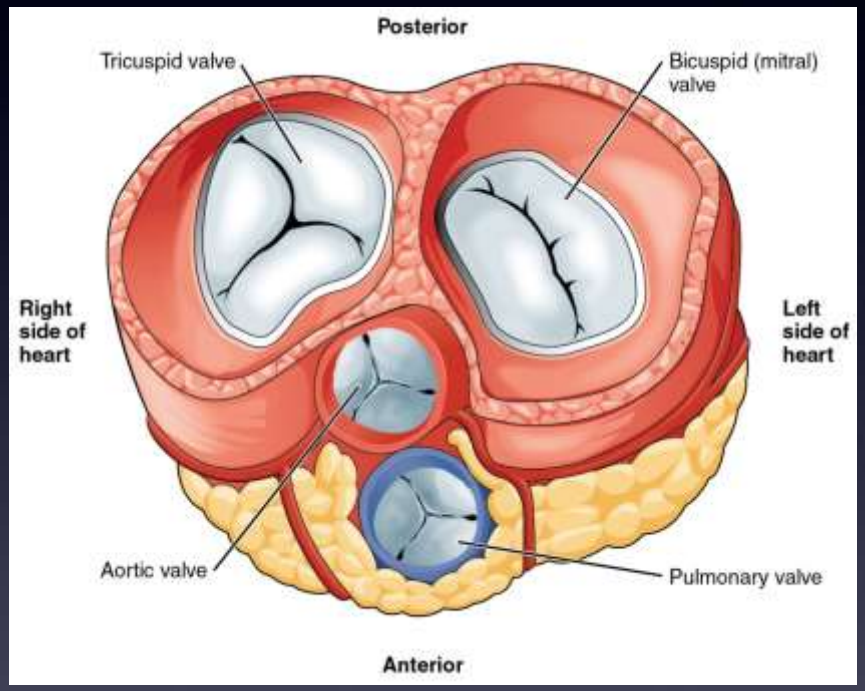

3.Echo window

Echo Window

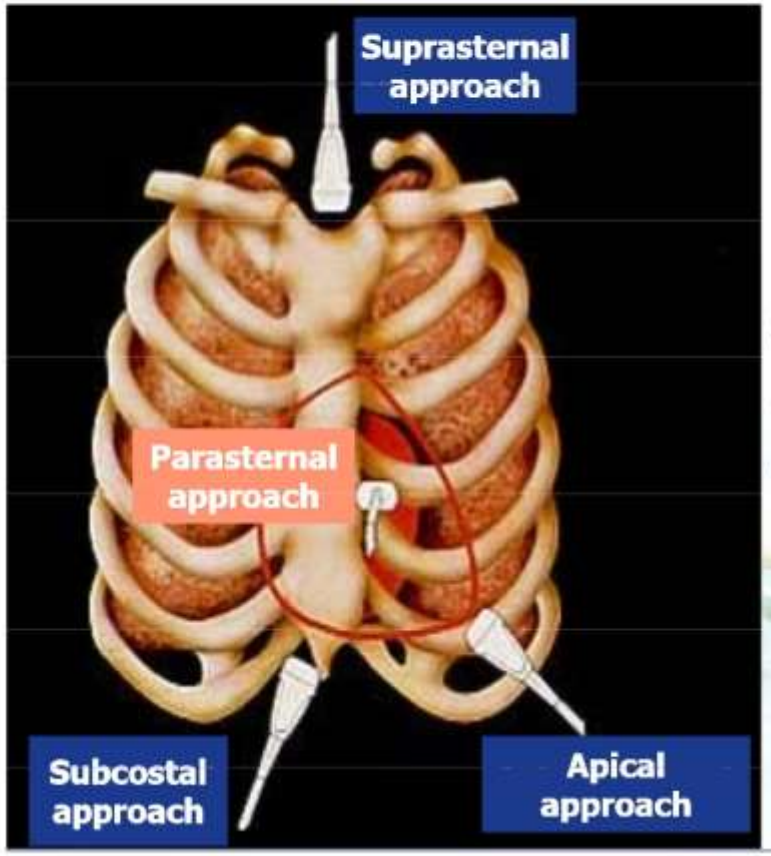

1. Parasternal
2. Apical
3. Subcostal
4. Suprasternal notch

4.Axis

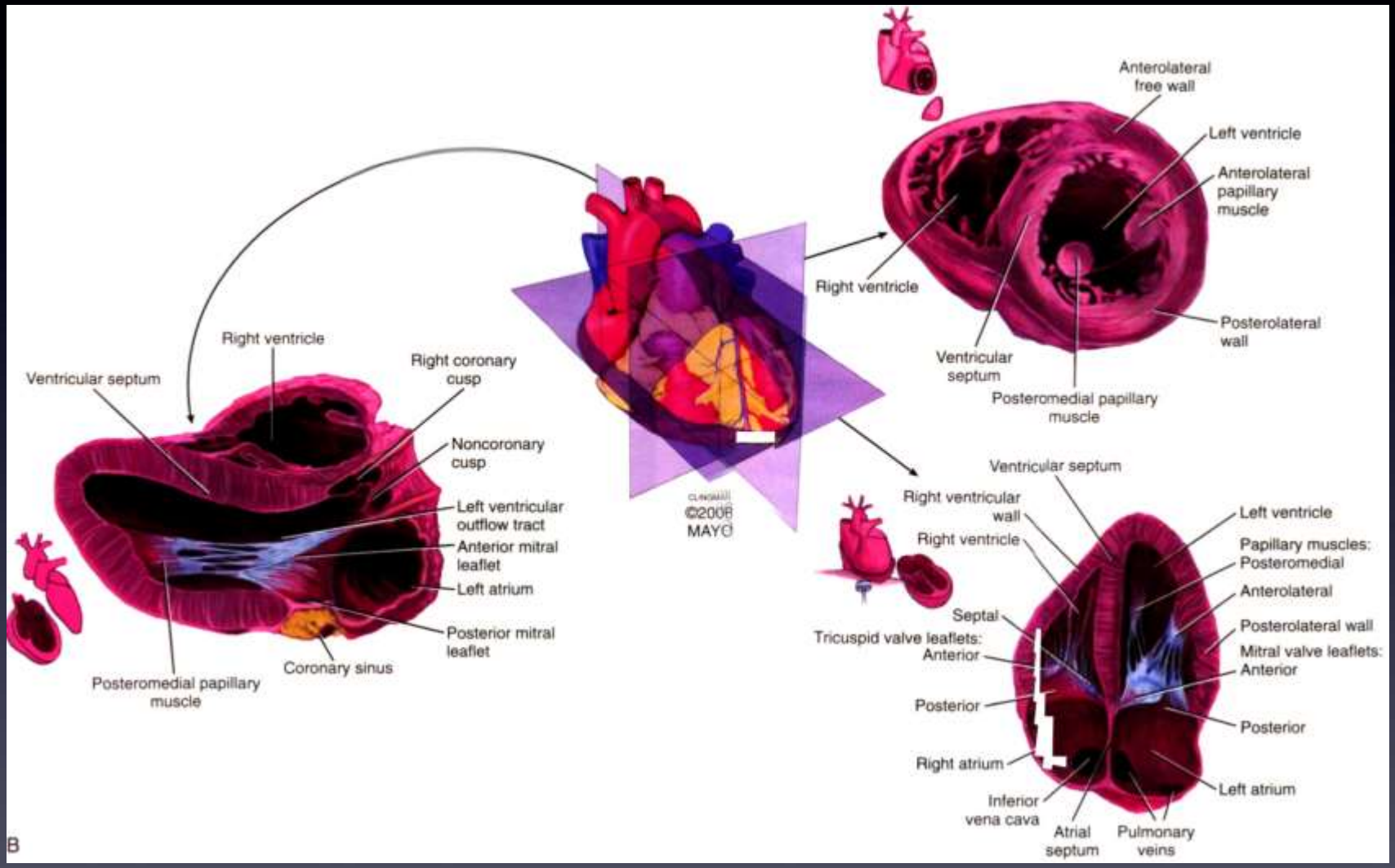
Ventricular septum
Right ventricle
Right coronary cusp
Noncoronary cusp
Left ventricular outflow tract
Anterior mitral leaflet
Left atrium
Posterior mitral leaflet
Coronary sinus
Posteromedial papillary muscle
©2008 MAYO
Anterolateral free wall
Left ventricle
Anterolateral papillary muscle
Right ventricle
Posterolateral wall
Ventricular septum
Posteromedial papillary muscle
Ventricular septum
Right ventricular wall
Right ventricle
Left ventricle
Papillary muscles: Posteromedial
Anterolateral
Posterolateral wall
Mitral valve leaflets: Anterior
Posterior
Septal
Tricuspid valve leaflets: Anterior
Posterior
Right atrium
Left atrium
Inferior vena cava
Atrial septum
Pulmonary veins
B

검사 순서

- 1. parasternal long axis (measure)
- 2. parasternal short axis (measure)
- 3. apical 4chamber (measure)
- 4. apical 5chamber (measure)
- 5. apical 2chamber (measure)
- 6. wall motion
- 7. subcostal view

1. Parastrenal long axis

SAMSUNG 강북삼성병원

Parasternal long axis view

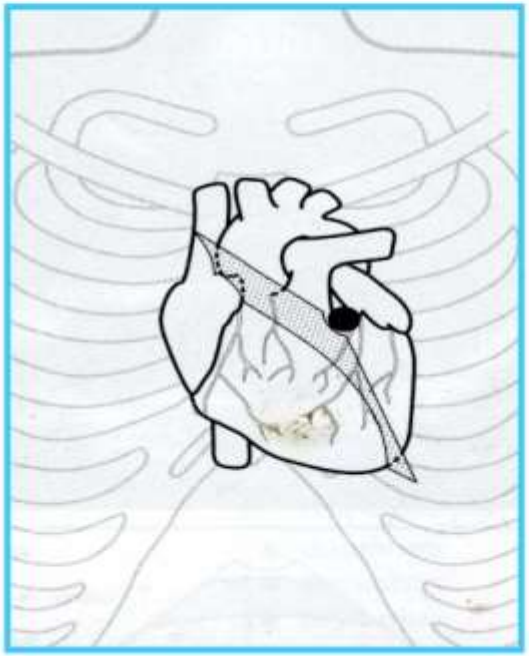

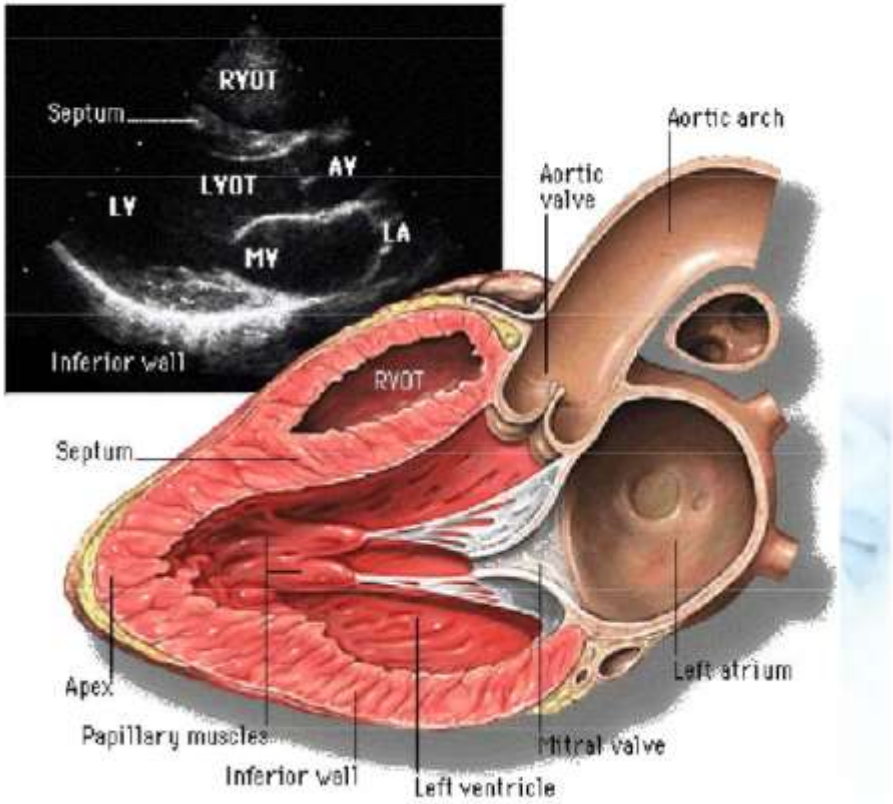

Long axis

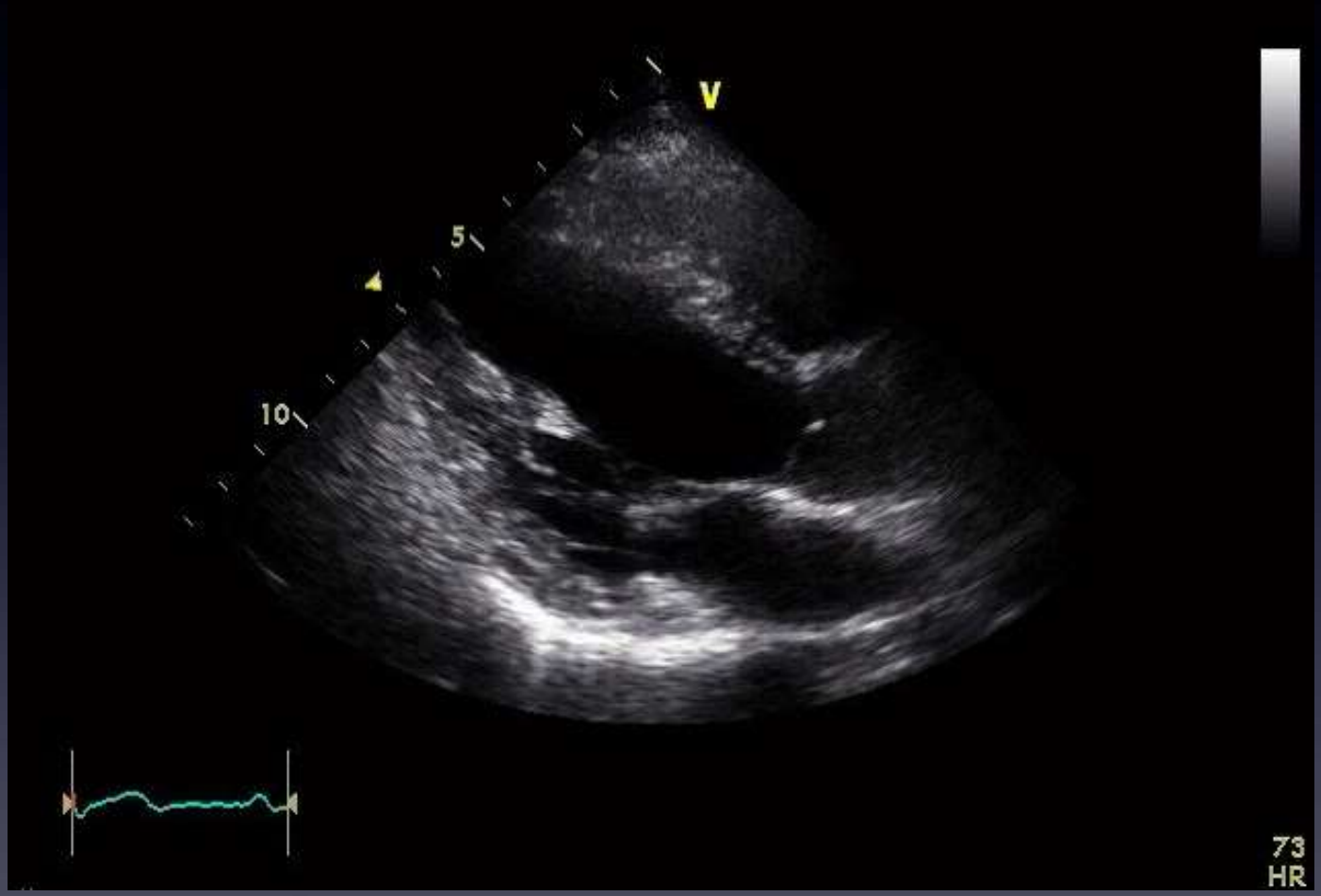

Long axis doppler

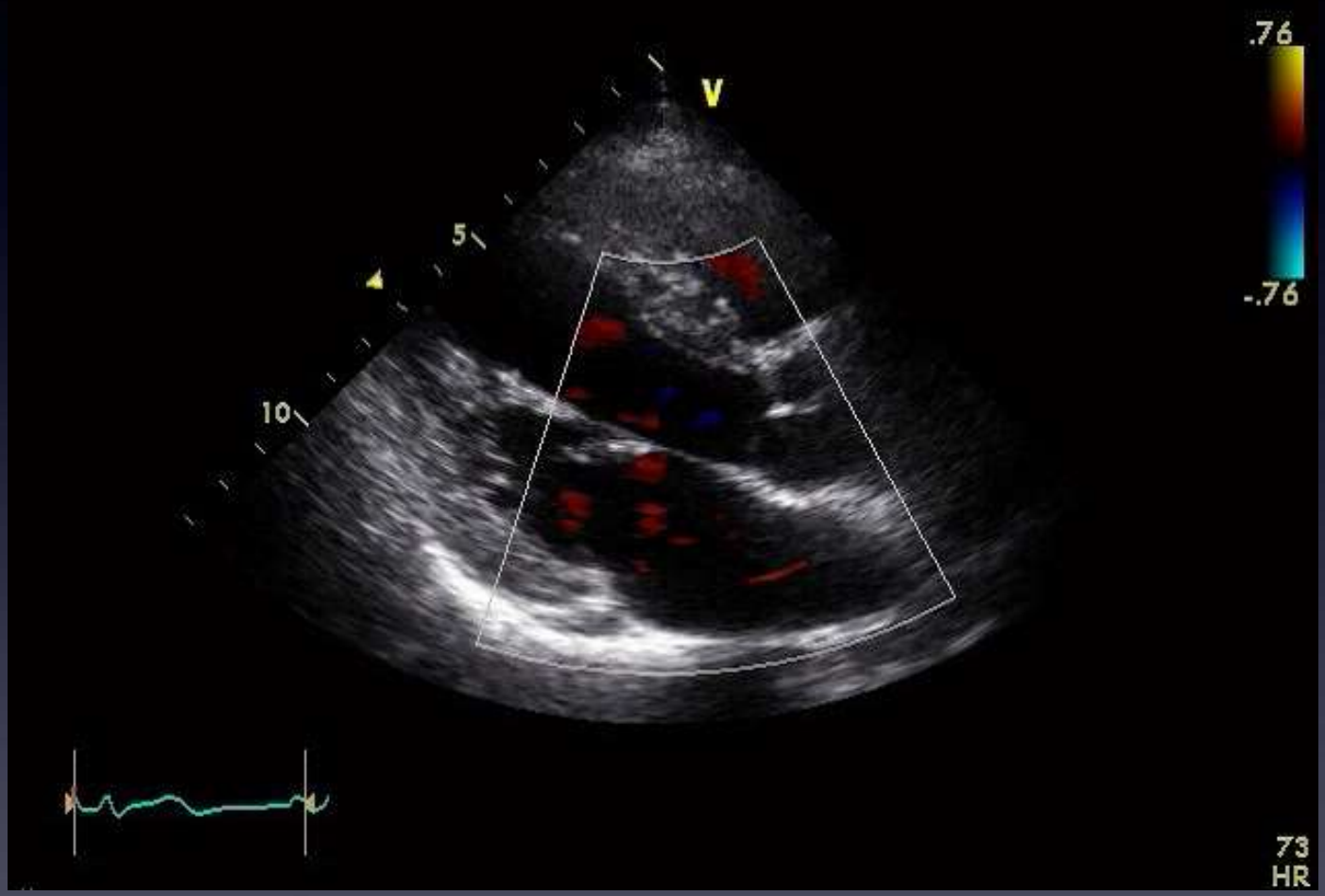

Long axis 확대

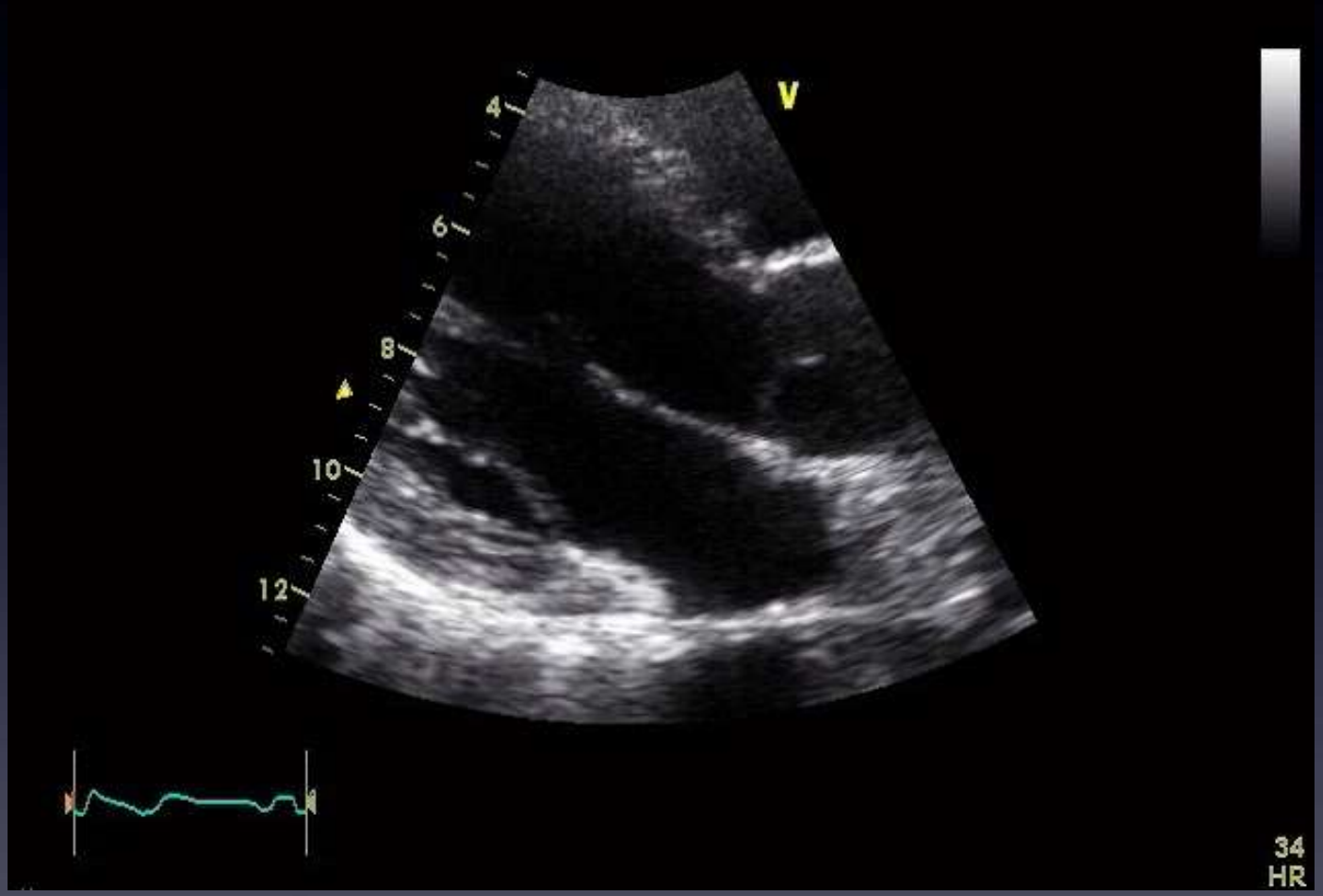

Long axis 확대 doppler

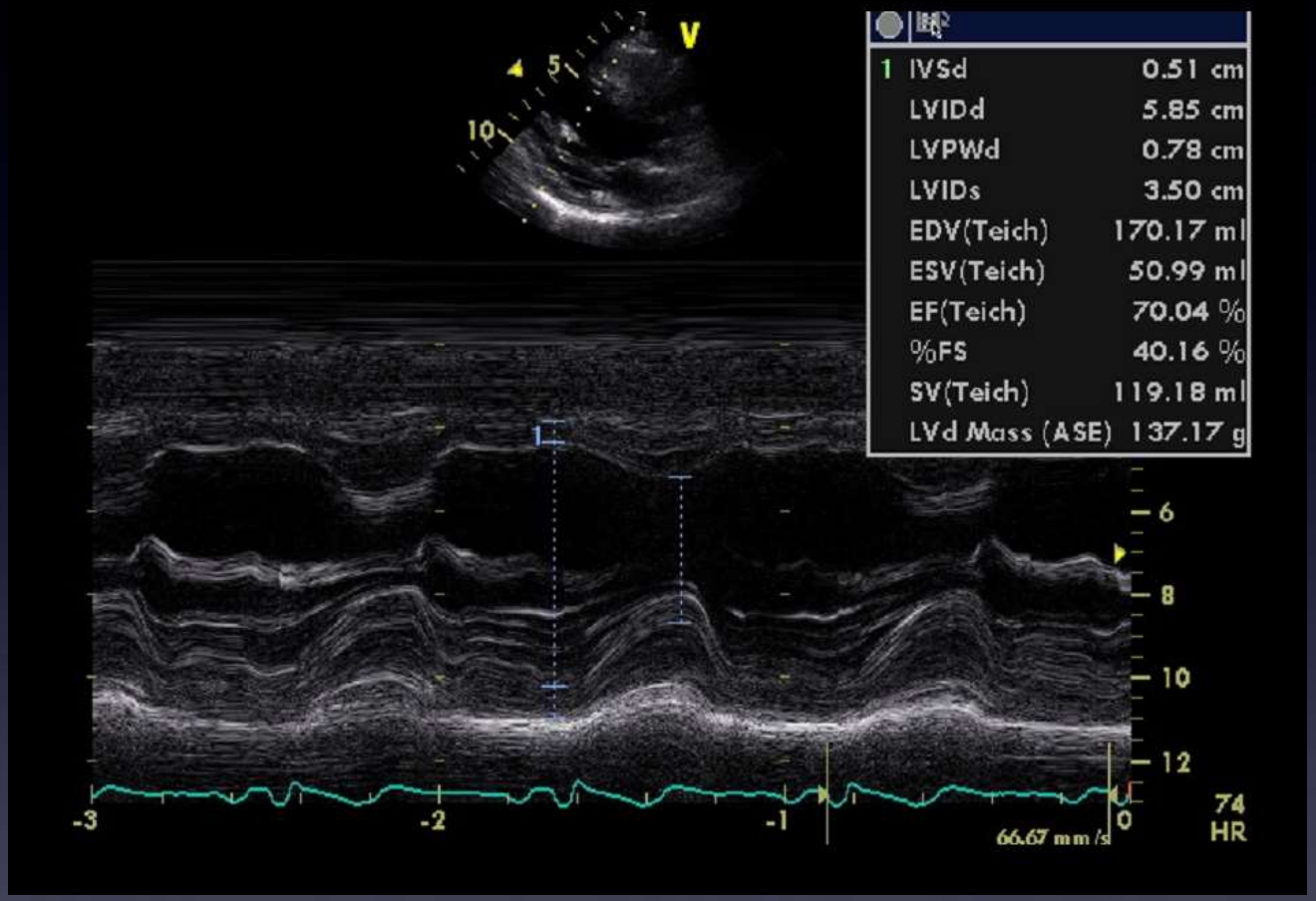

LVSd – left ventricular septum, diastolic
-– 1cm 이하

LVIDd – left ventricular internal dimension, diastolic
-- 5.7cm 이하

LVPWd - left ventricular posterior wall, diastolic
-- 1cm 이하

LVIDs - left ventricular internal dimension , systolic

EDV – end diastolic volume

ESV – end systolic volume

EF – ejection fraction

Ejection fraction

Hyperdynamic	> 70%
Normal	69- 55%
Borderline	54- 50%
Mildly reduced	50- 45%
Mild to moderately reduced	44- 40%
Moderately reduced	39- 35%
Moderate to severely reduced	34- 30%
Severely reduced	< 30%

Ao diam
4cm 이하

LA diam
4cm 이하

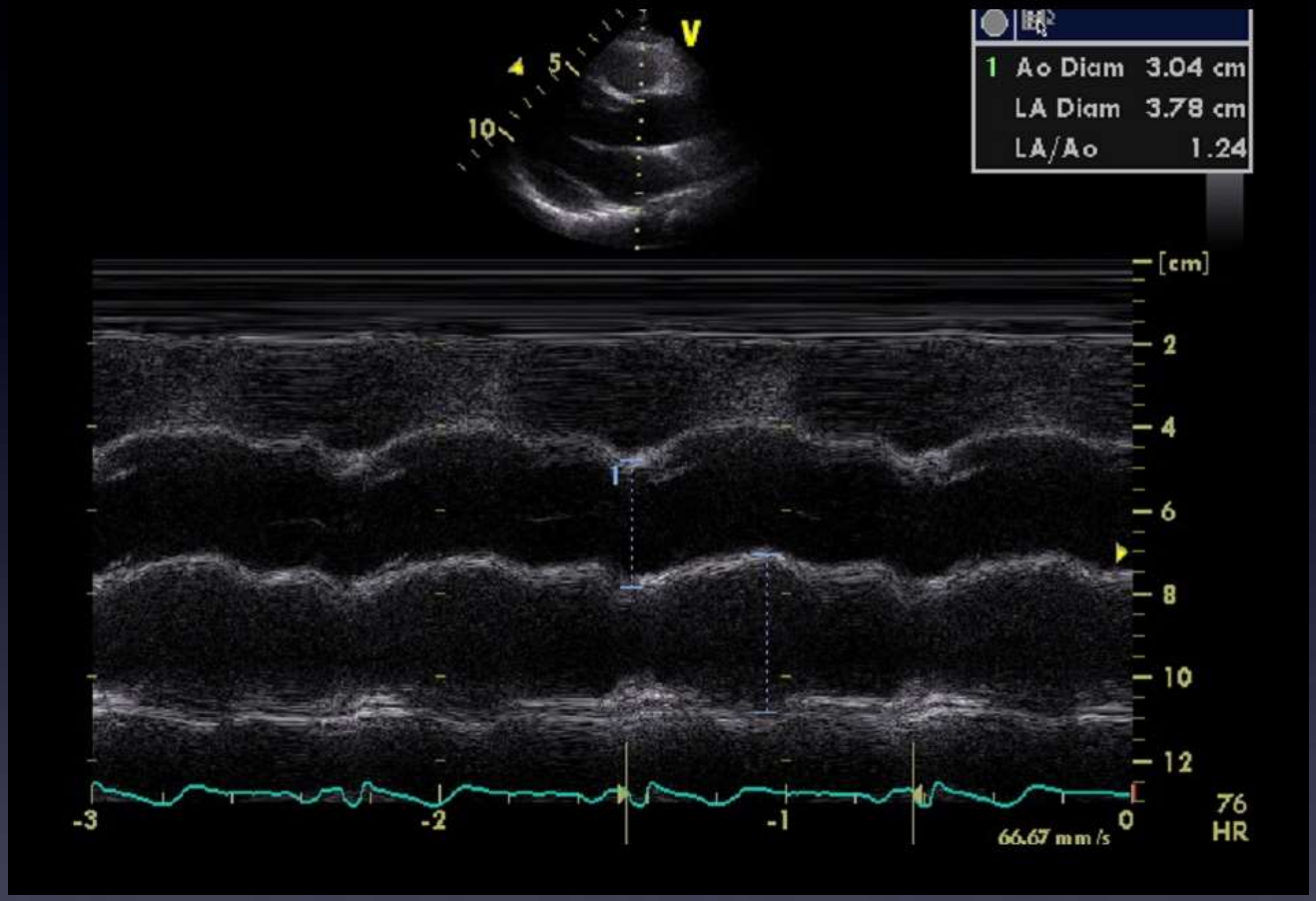

2. Parasternal short axis

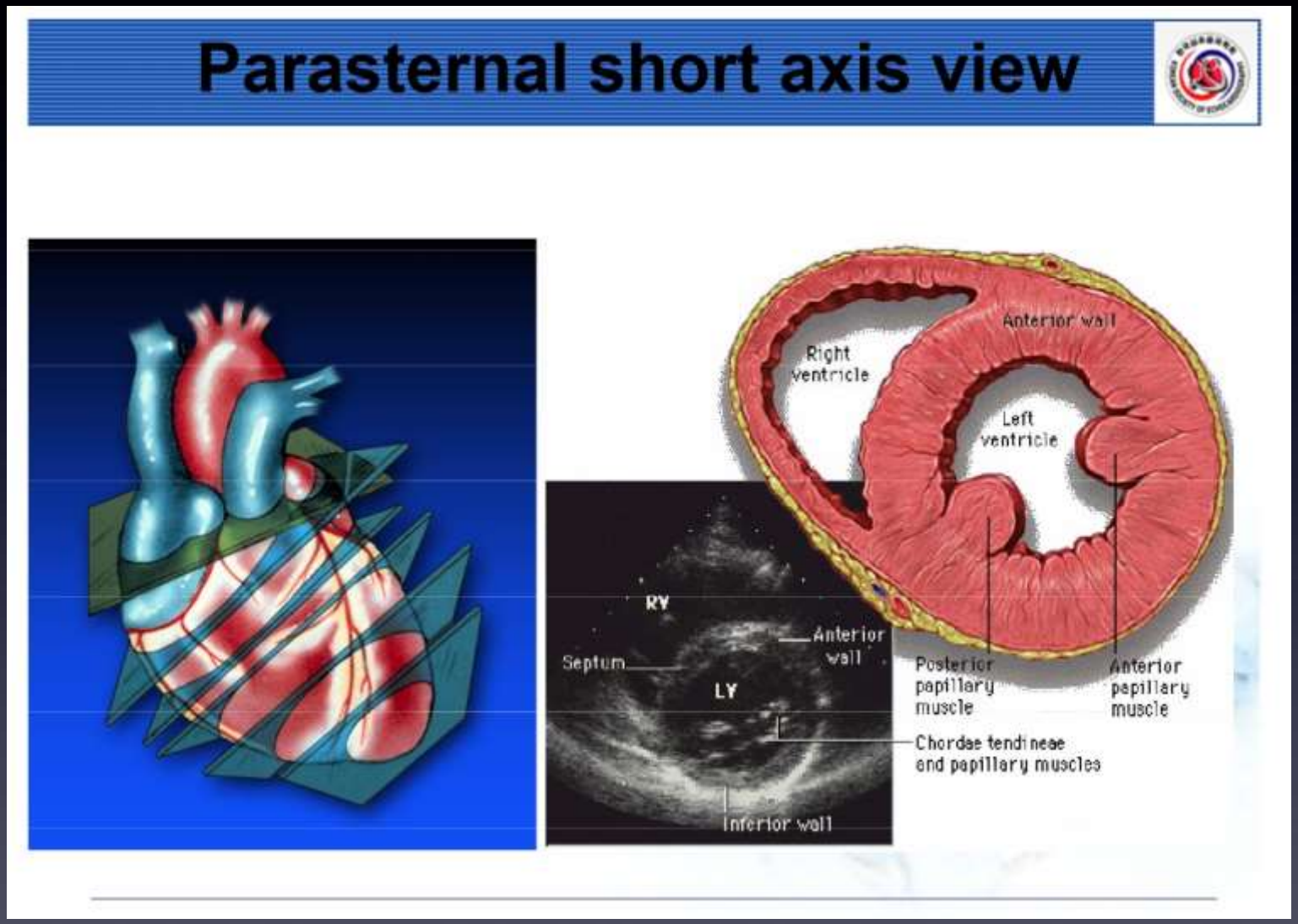

Parasternal Short Axis view

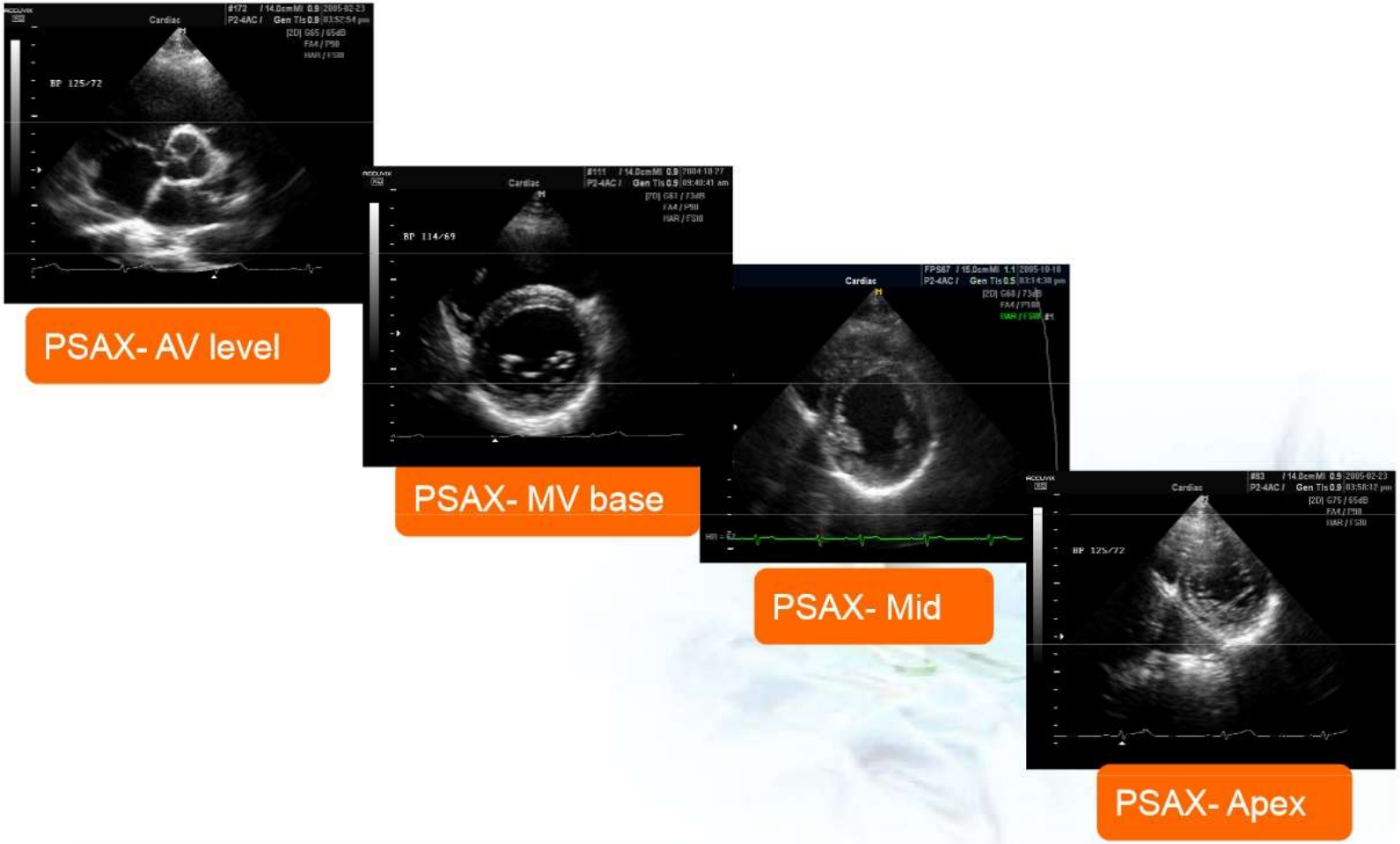

Short axis view of aorta

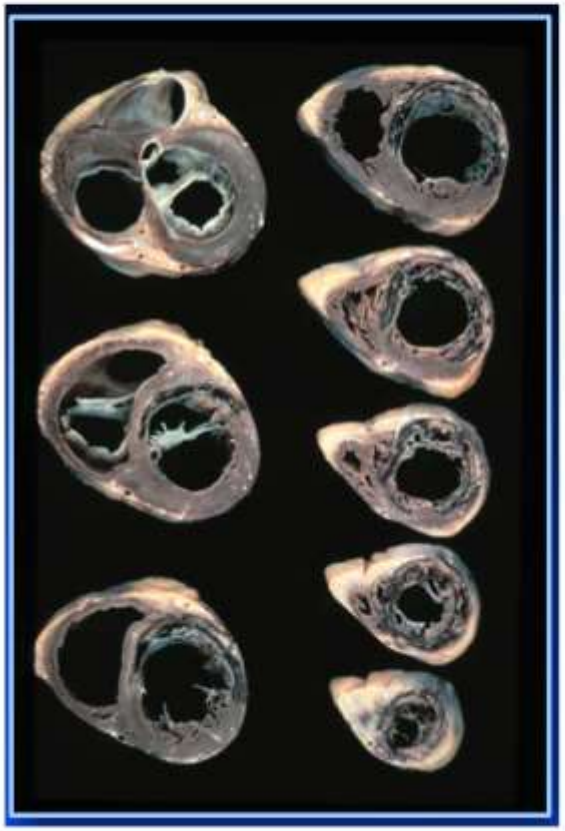

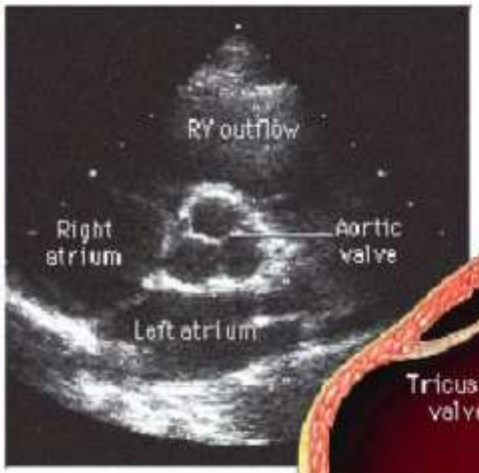

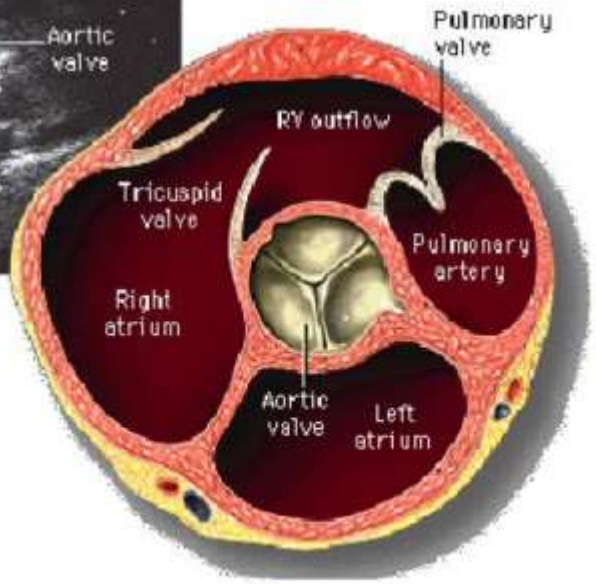

Aorta valve short axis

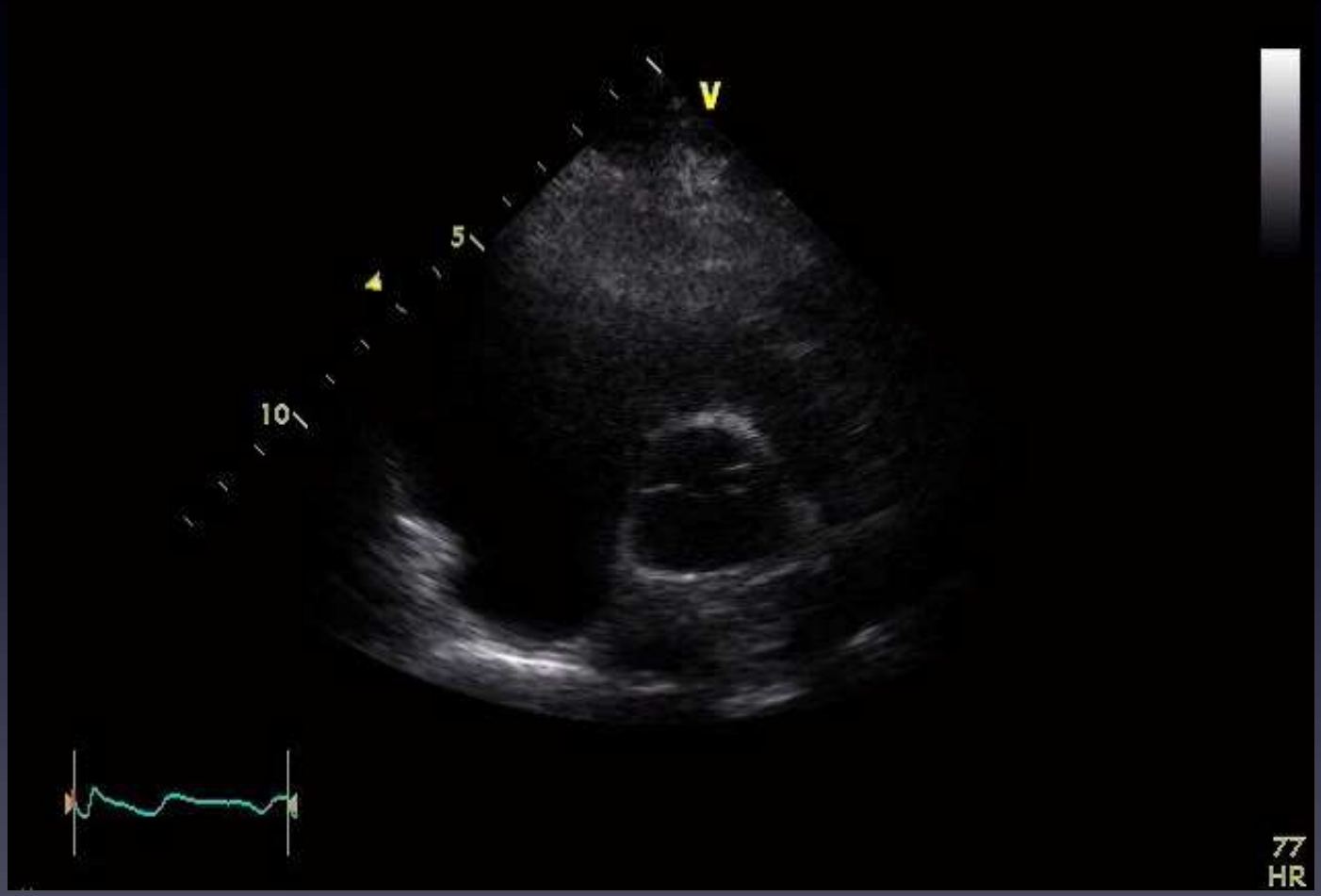

Aorta valve doppler

Pulmonary artery doppler

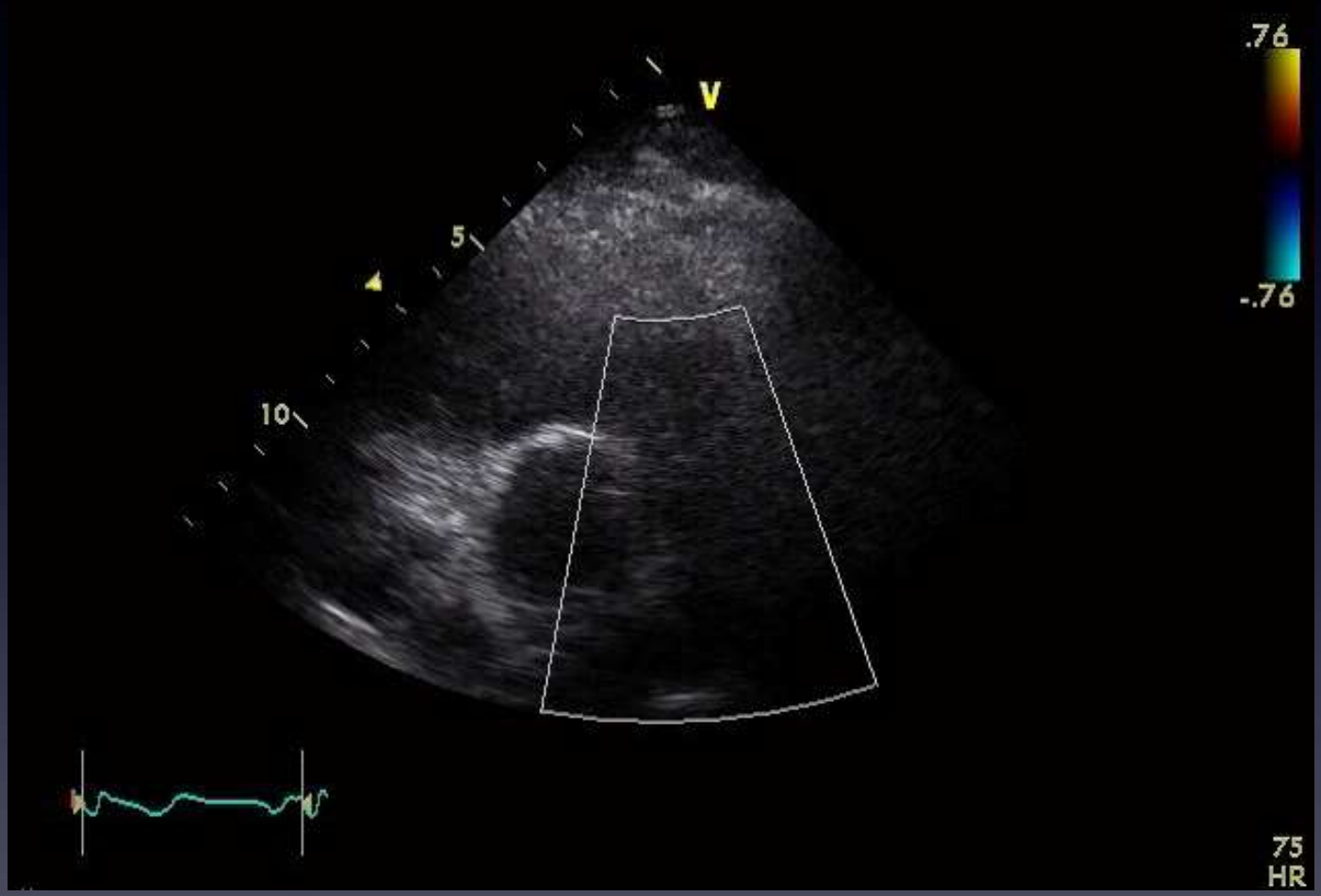

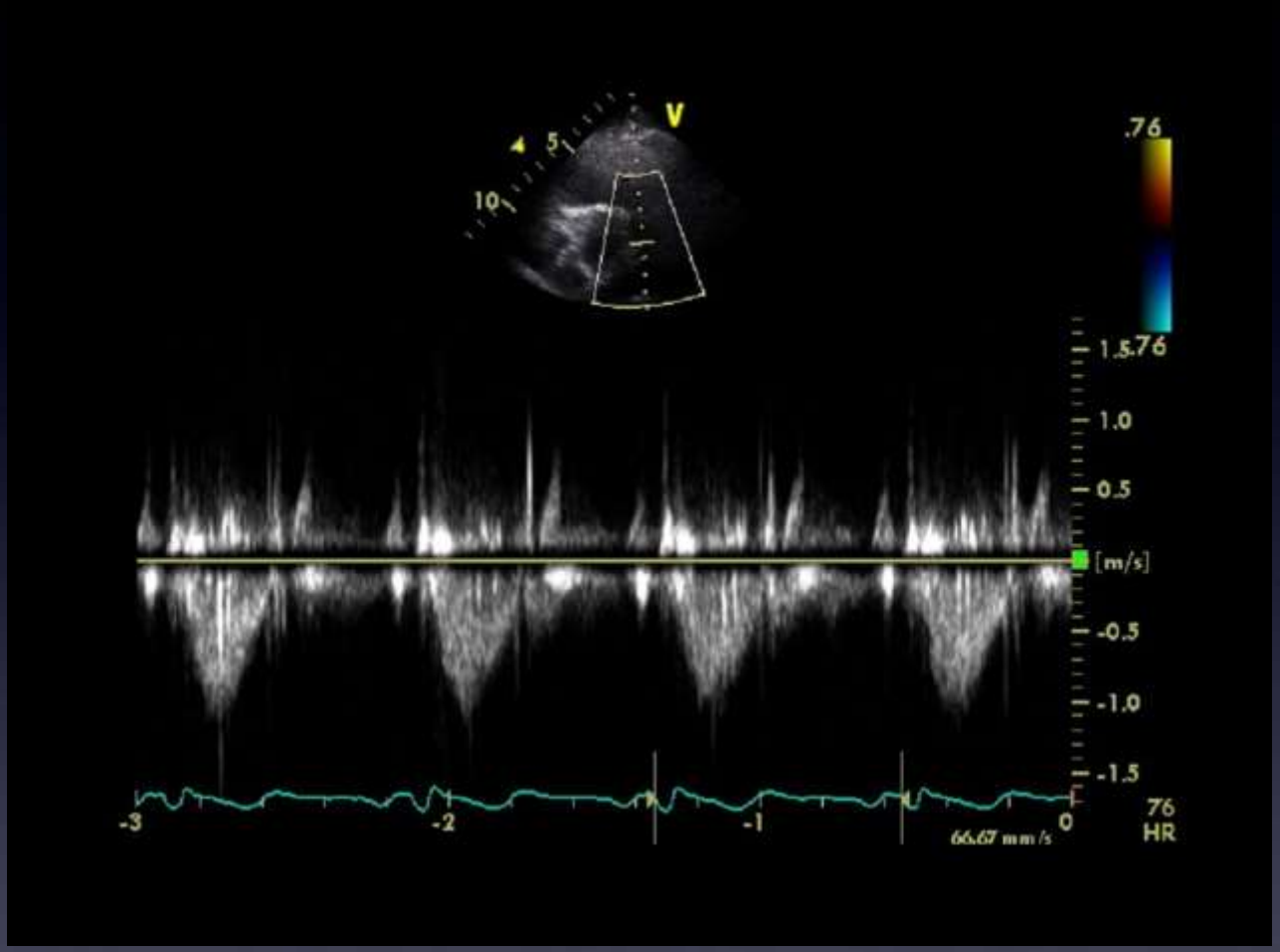

Velocity –
2m/s 이하

Mitral valve site

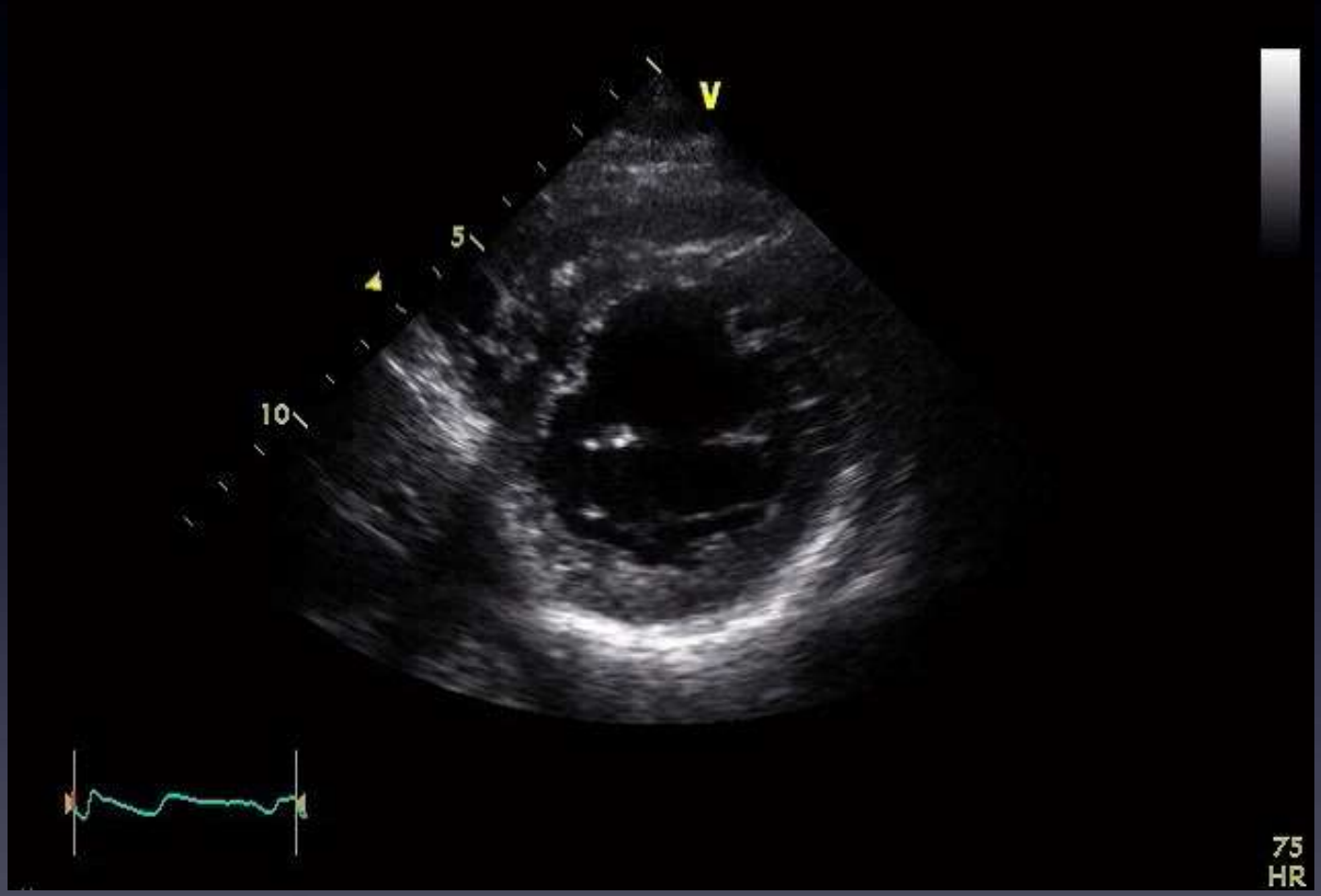

Mid

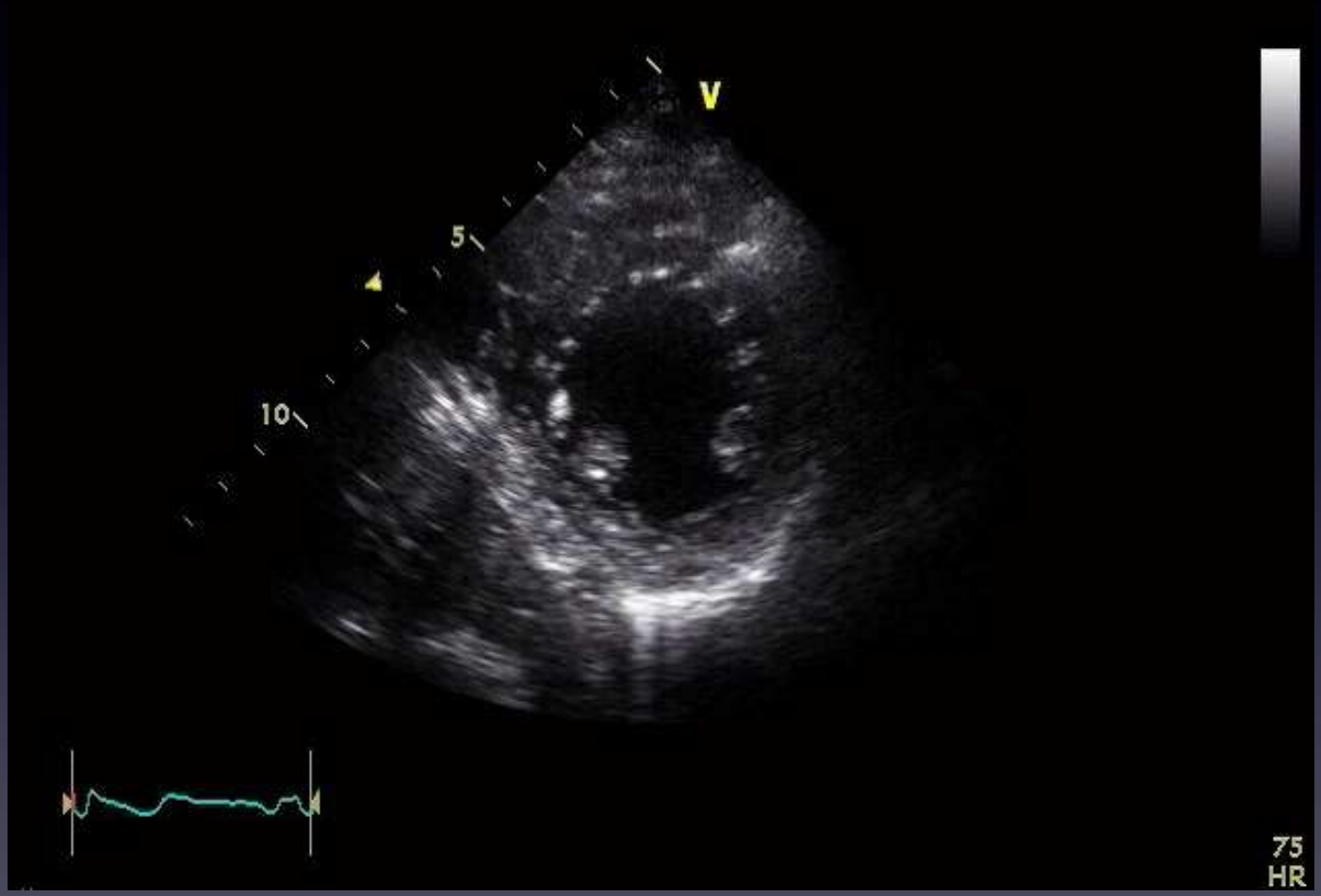

Apex

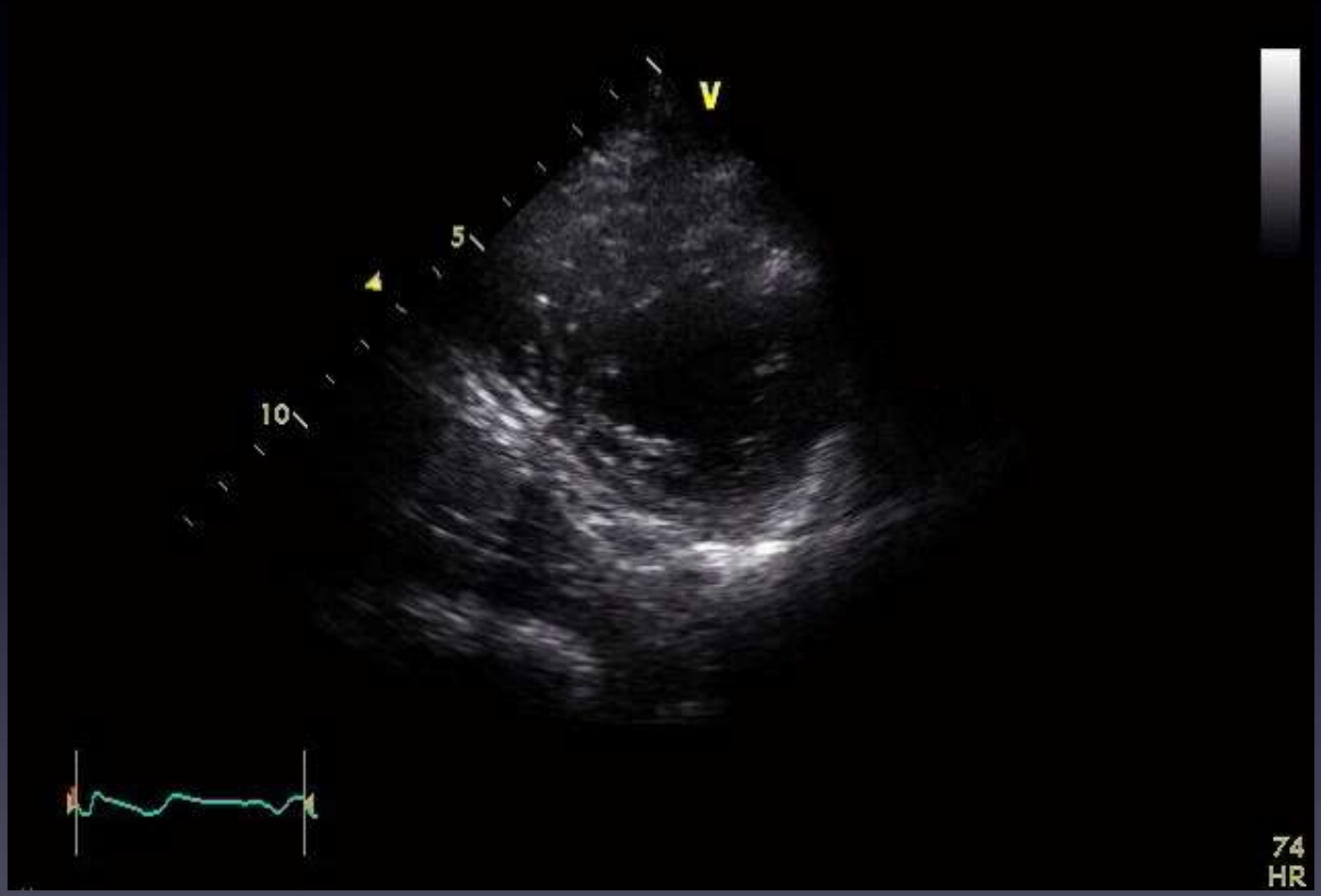

3. Apical 4 chamber

Apical 4 chamber view

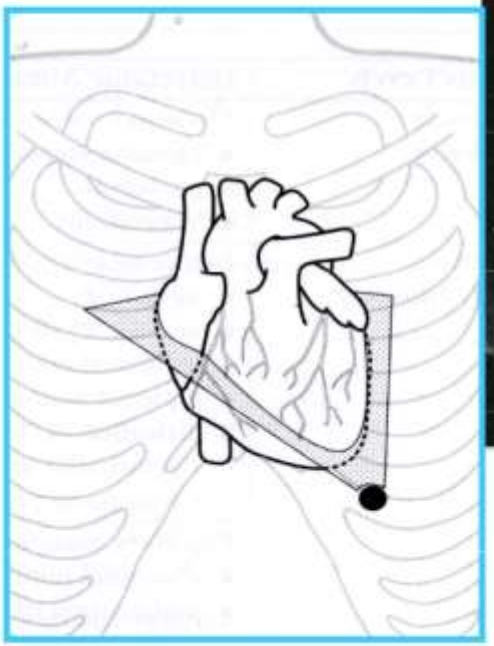

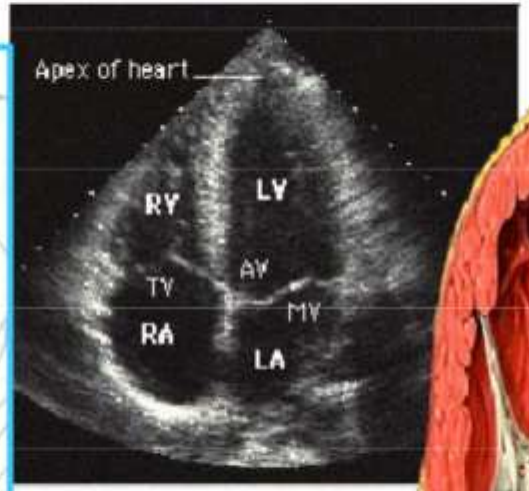

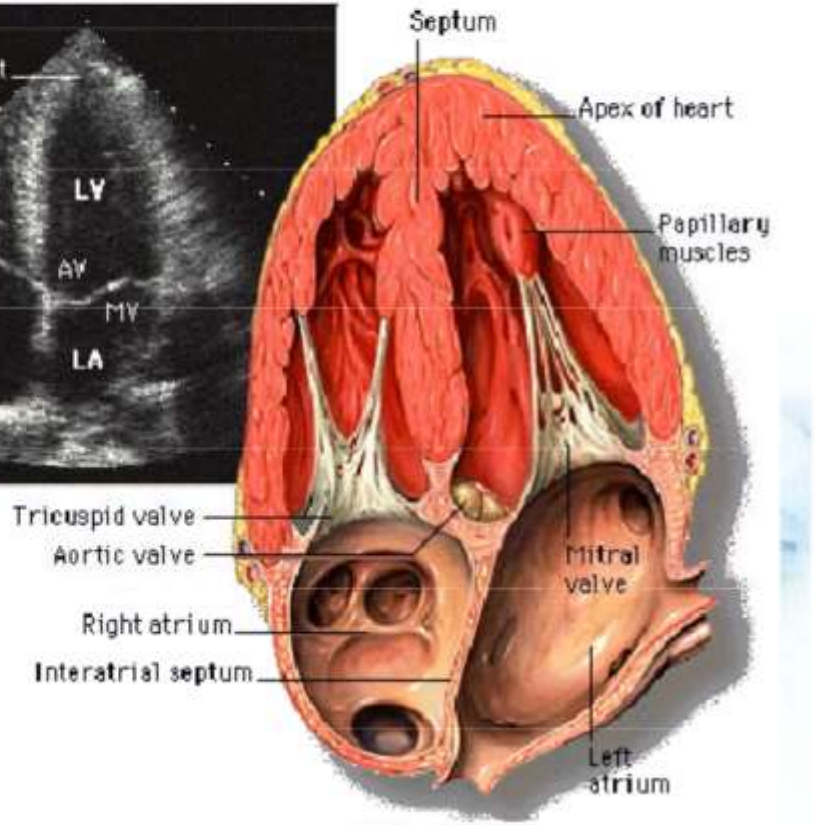

4chamber view

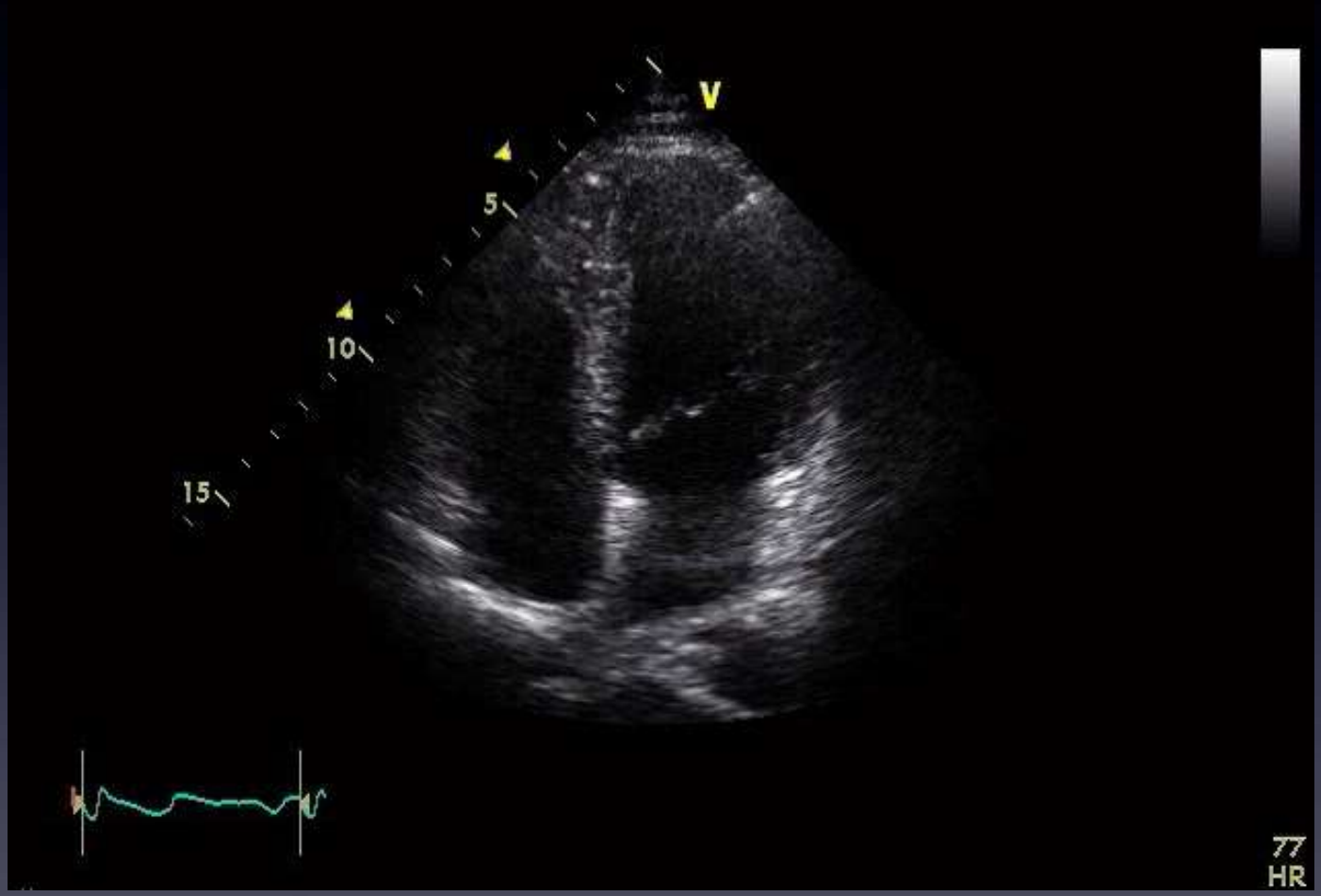

4chamber doppler

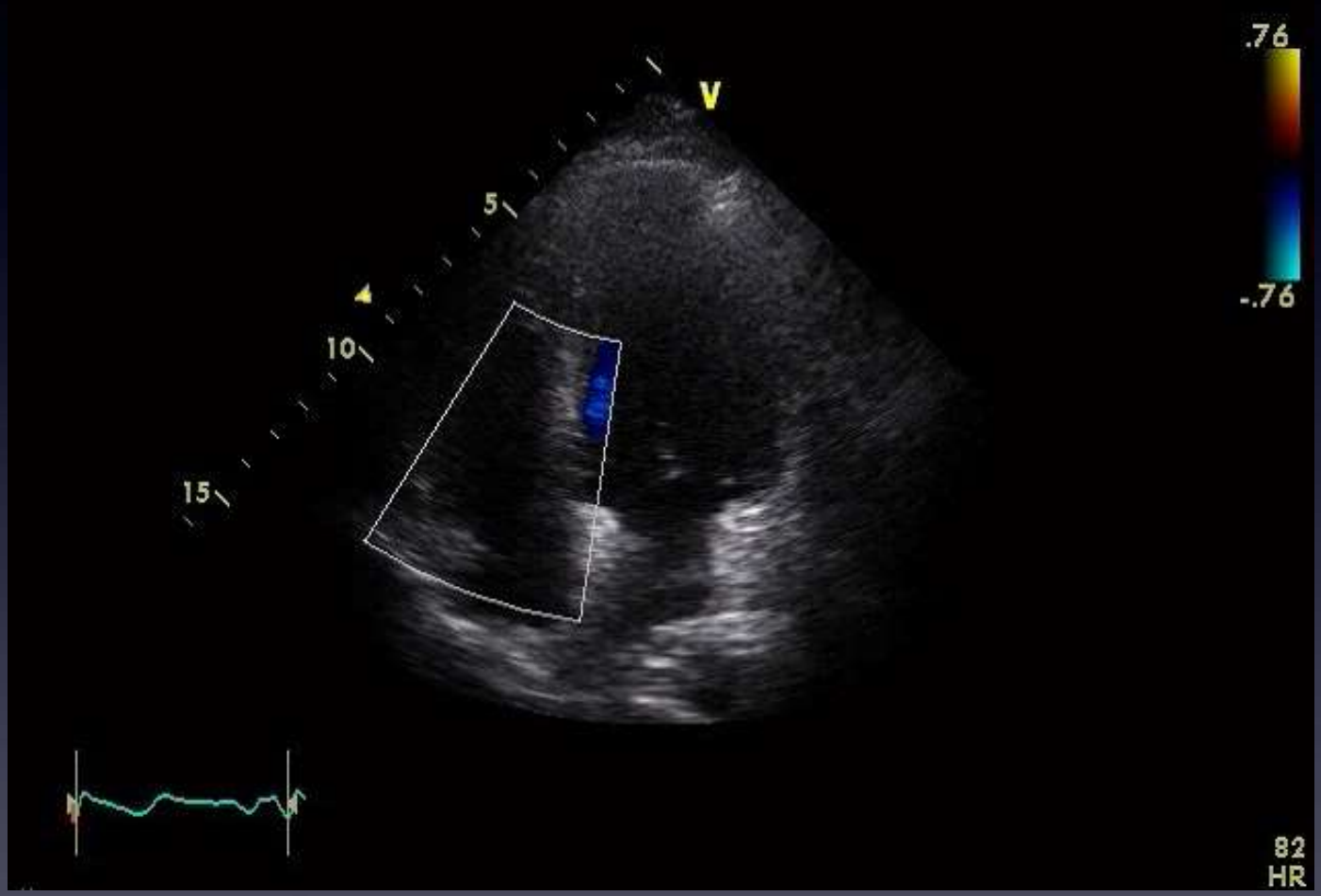

4chamber doppler

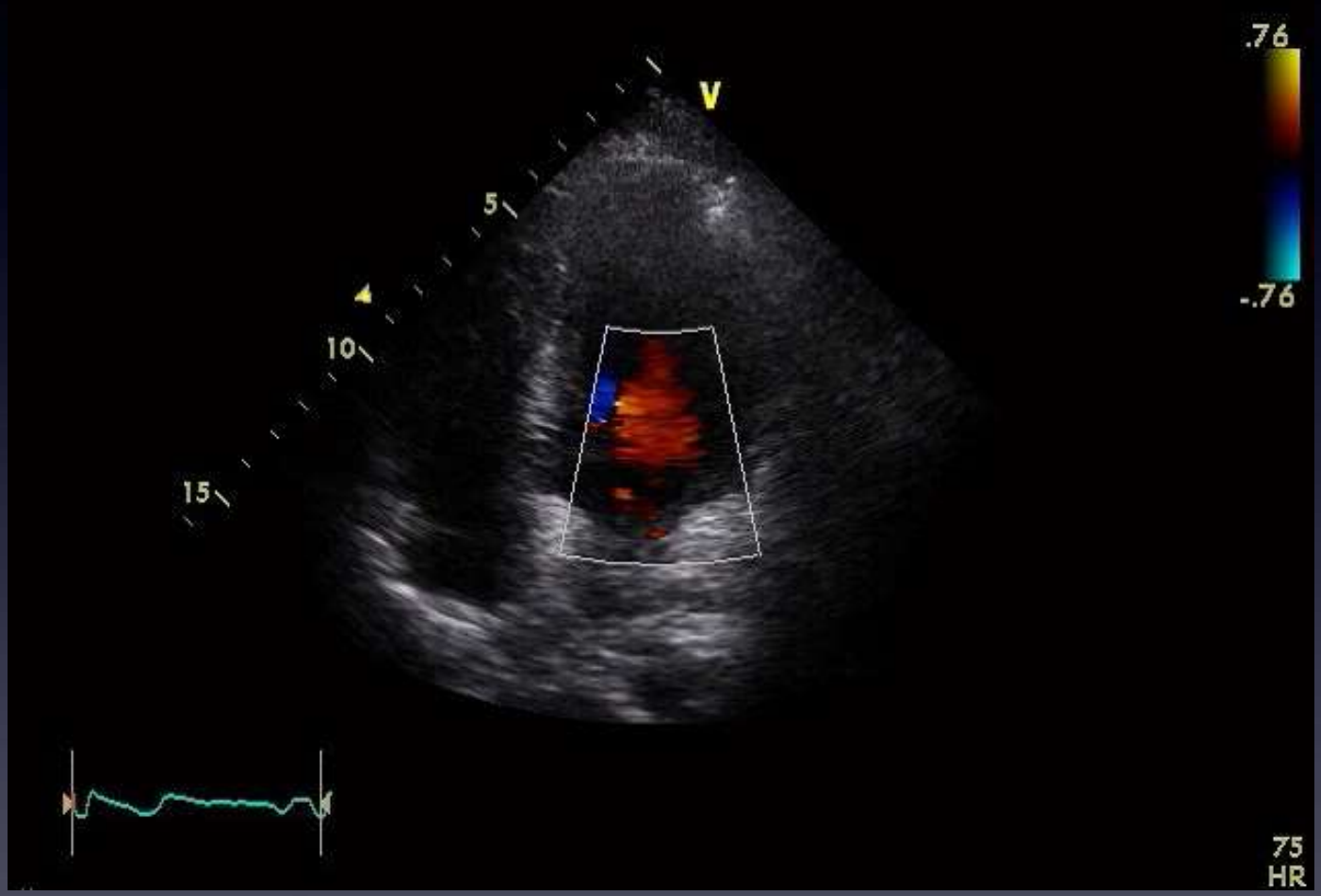

Ischemic cascade

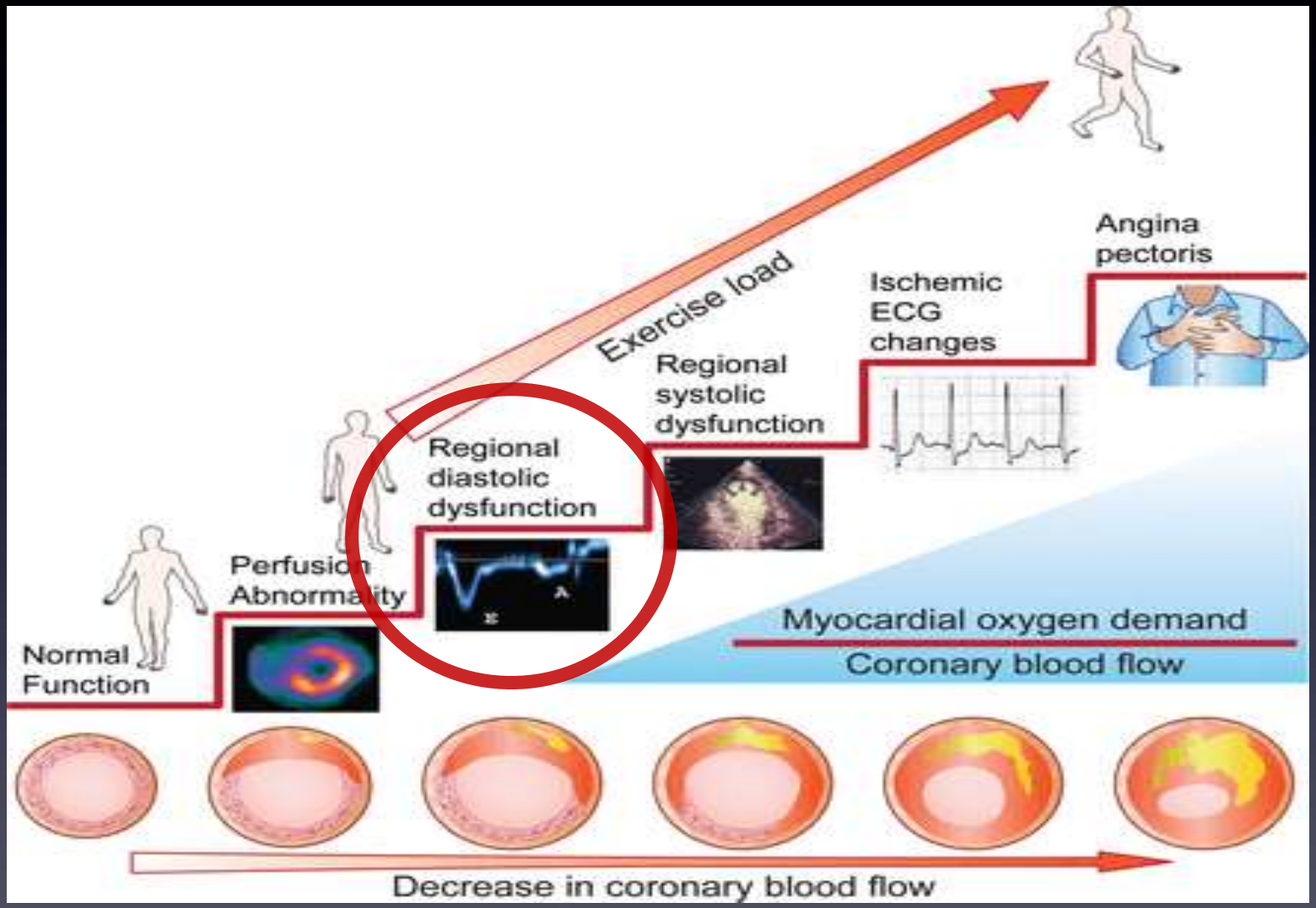

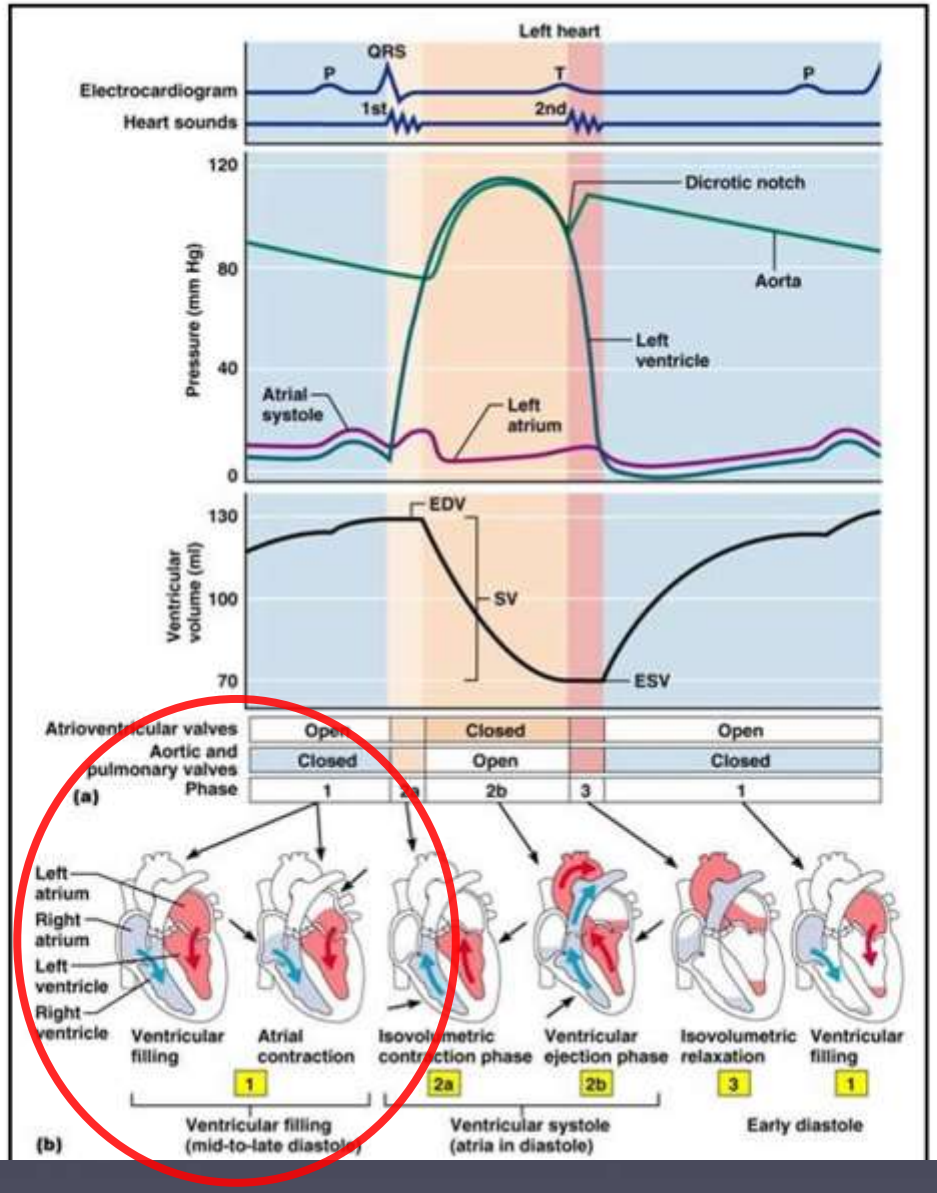

Diastolic function test

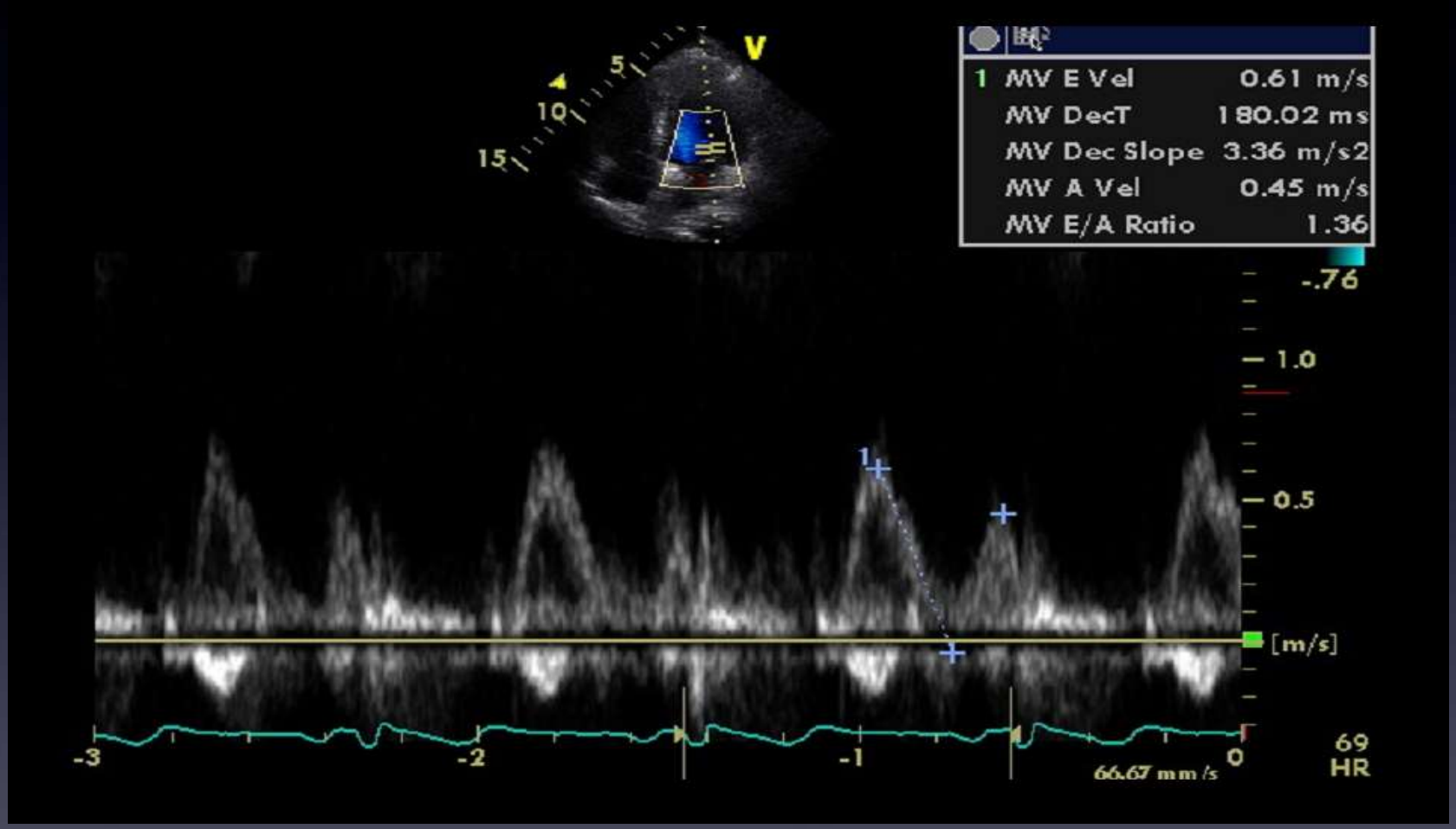

Diastolic function test

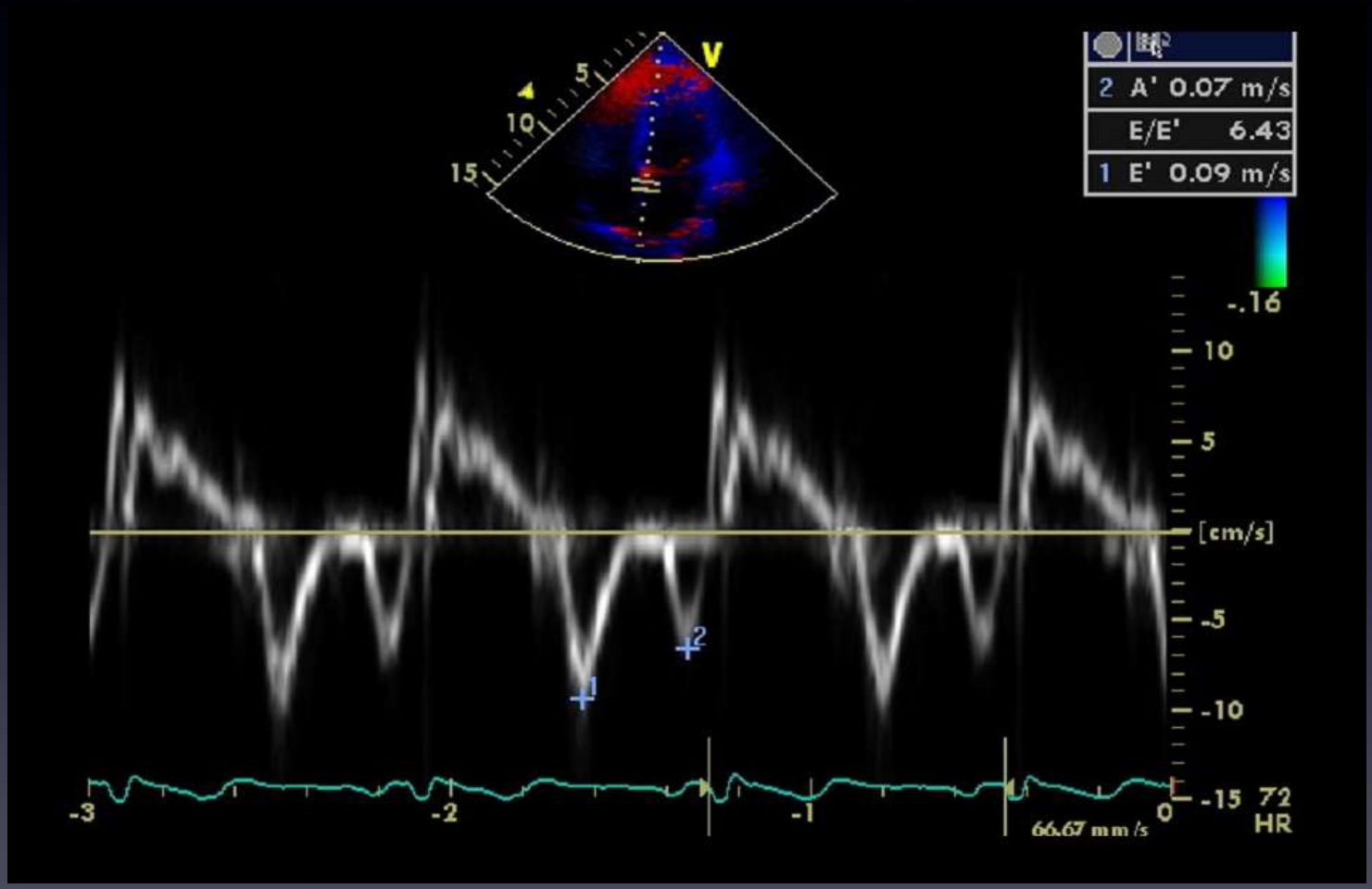

	normal	Relax abnormality	Pseudo normal	Restrictive relaxation
E/A	1~2	<1	1~1.5	>2
E’	>0.10m/s	<0.08m/s	<0.08m/s	<0.08m/s
E/E’	<8	<8	>15	>15

From: Assessment of Mitral Annulus Velocity by Doppler Tissue Imaging in the Evaluation of Left Ventricular Diastolic Function

J Am Coll Cardiol. 1997;30(2):474-480. doi:10.1016/S0735-1097(97)88335-0

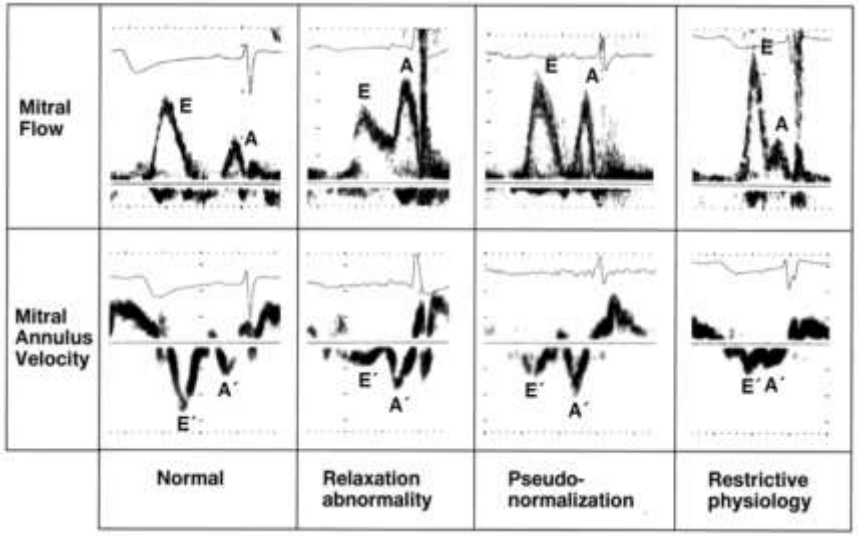

Figure Legend:

Patterns of mitral inflow and mitral annulus velocity from normal to restrictive physiology. Pseudonormalization is easily differentiated.

4. 5chamber view

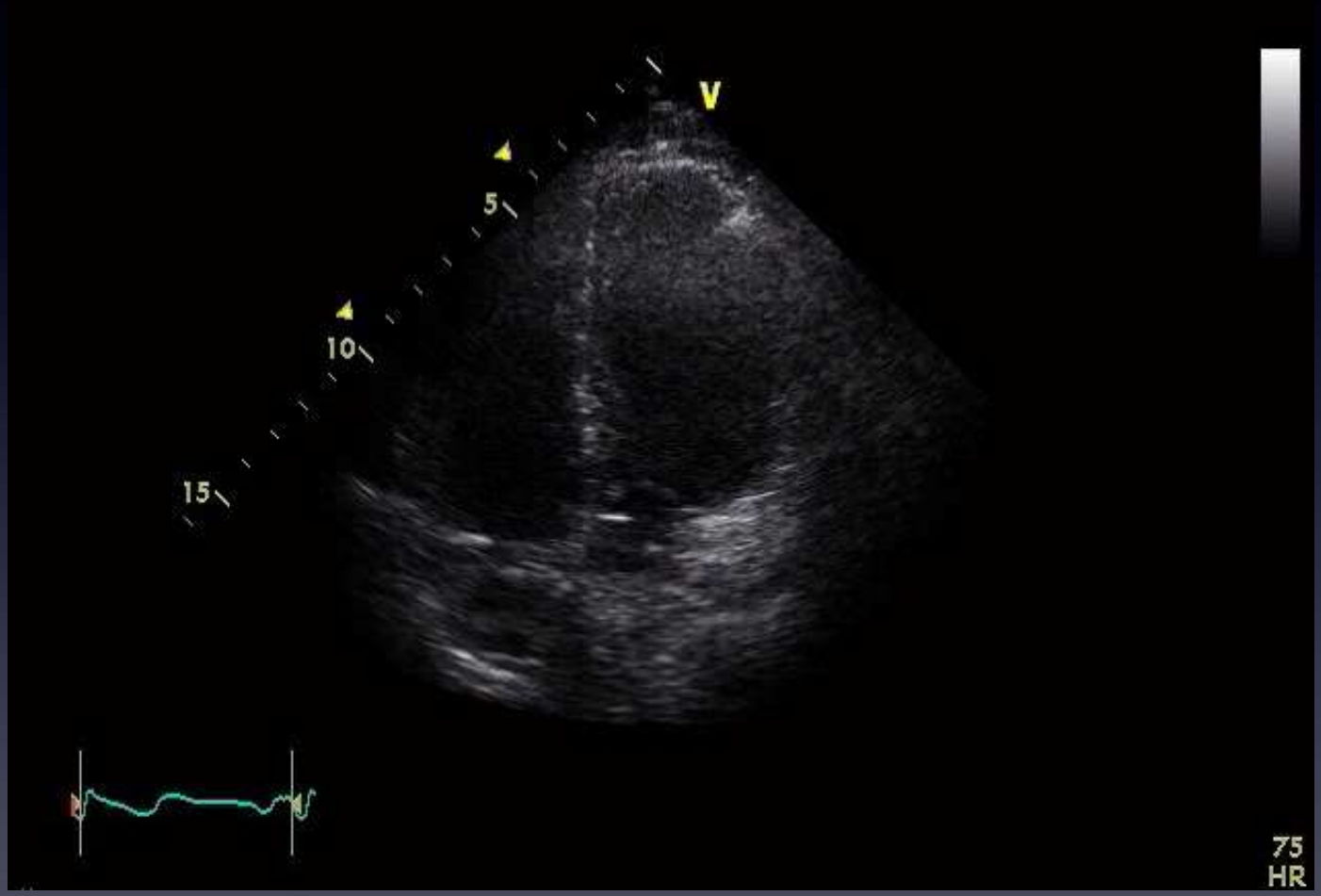

Aorta valve doppler

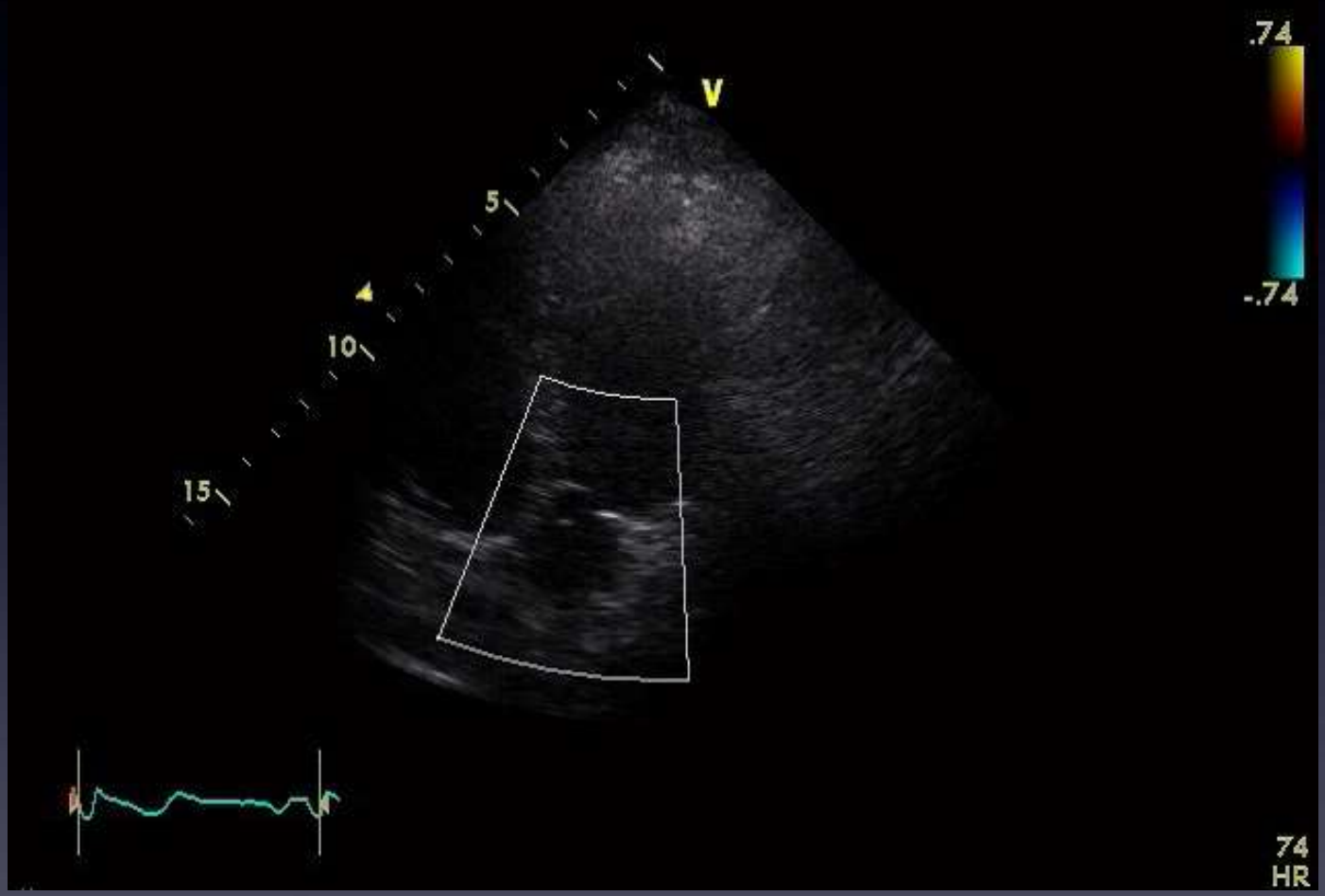

Aorta pressure test

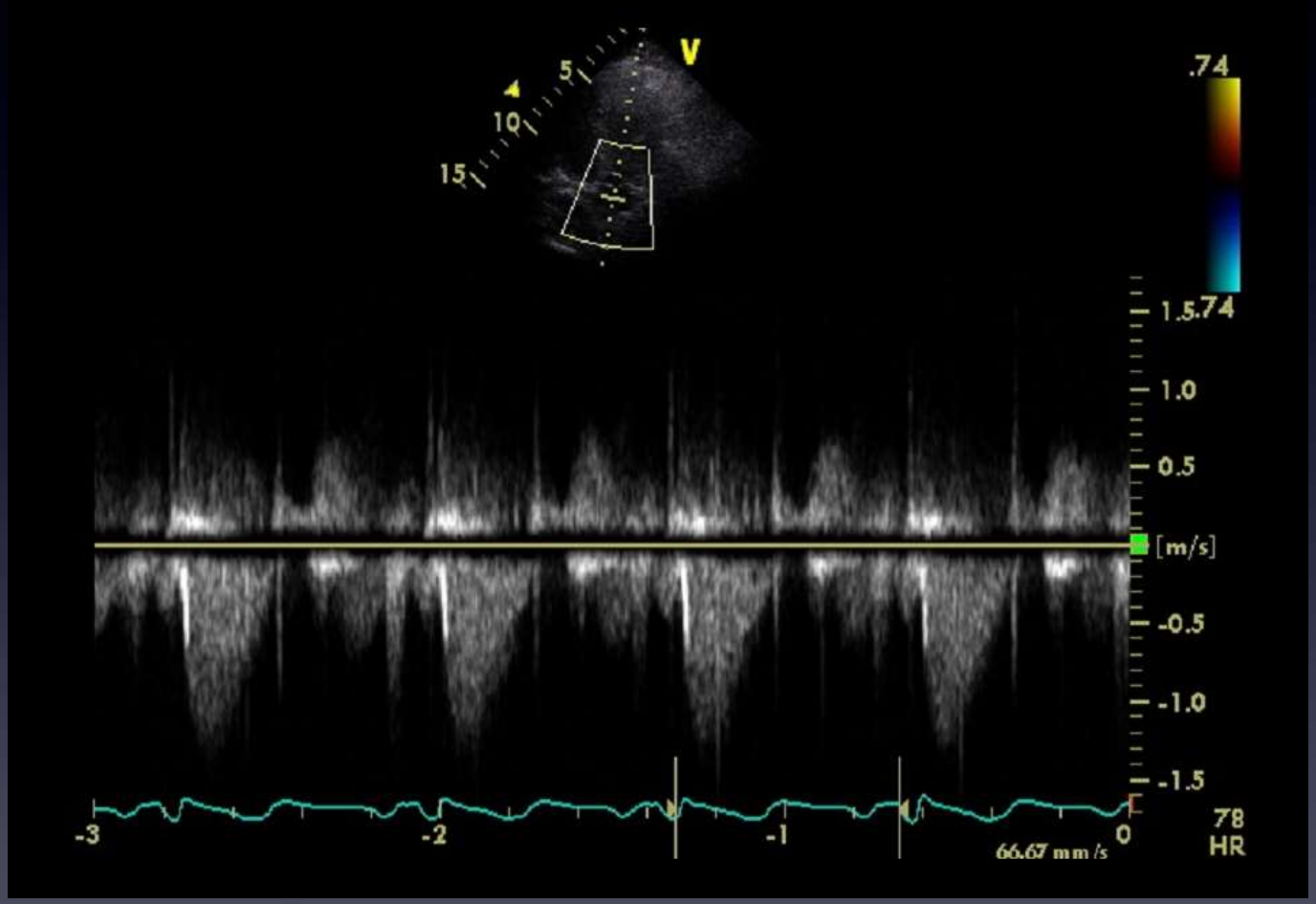

5. Apical 2chamber

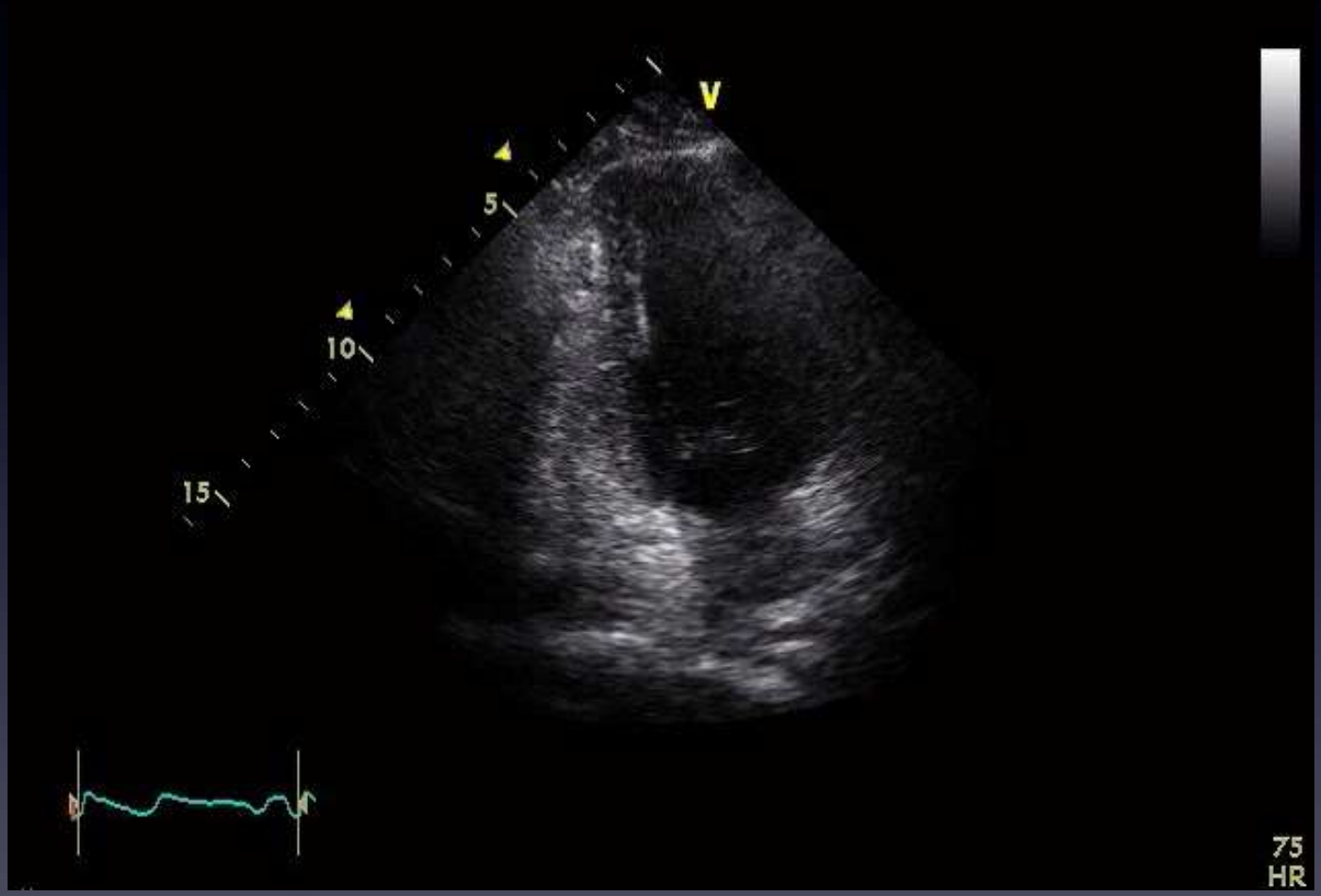

6. Wall motion

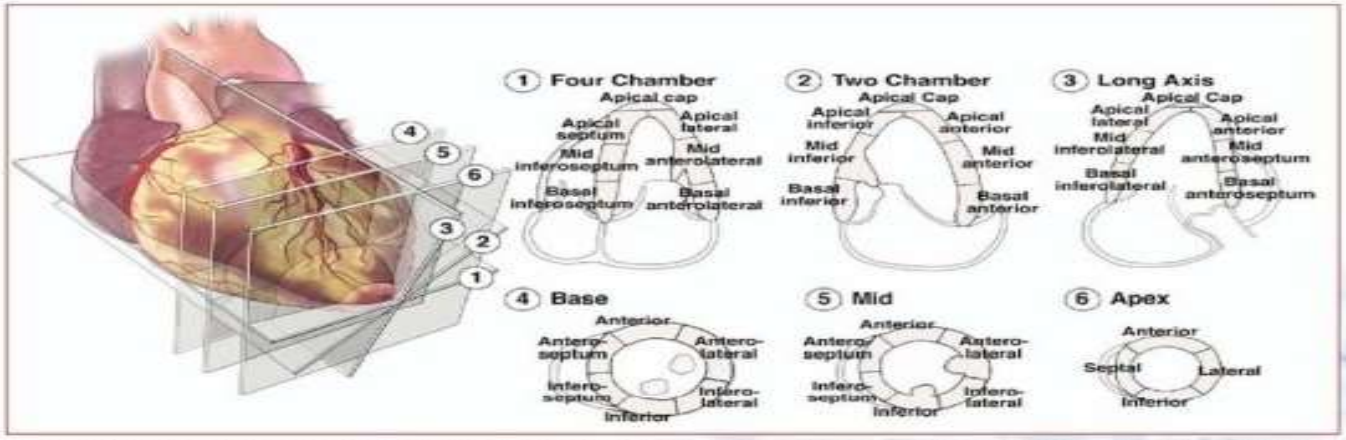

Segmental analysis of LV walls in a parasternal short-and long-axis views at 3 different levels.

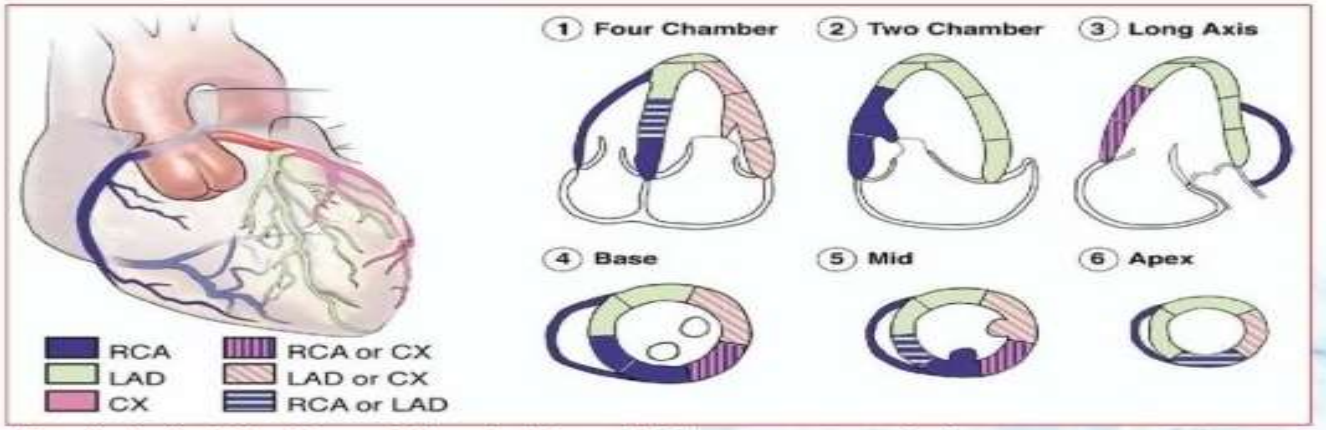

Typical distribution of the right and left coronary arteries.

LAD : anterior, anterior septum, septum
RCA: inferior --> RV 경색 확인(RVE와 RWMA, mod.이상의 TR 소견)
LCX: anterior lat, posterior, infero-lat

Regional Wall Motion Abnormalities

Segmental motion	LV wall thickening	Score
Normokinesia	> 35-40% wall thickening in systole	1
Hypokinesia	10-30% wall thickening in systole	2
Akinesia	< 10% wall thickening in systole or no inward movement	3
Dyskinesia	Moving outward in systole	4
Aneurysm	Bulging outward in systole & diastole	5

벽운동 지수 (Wall Motion Score Index)

$$\text{벽운동 지수 (WMSI)} = \frac{\text{각분절의 벽운동 점수의 합}}{\text{관찰한 심실 분절 개수의 합}}$$

Wall motion(mitral valve)

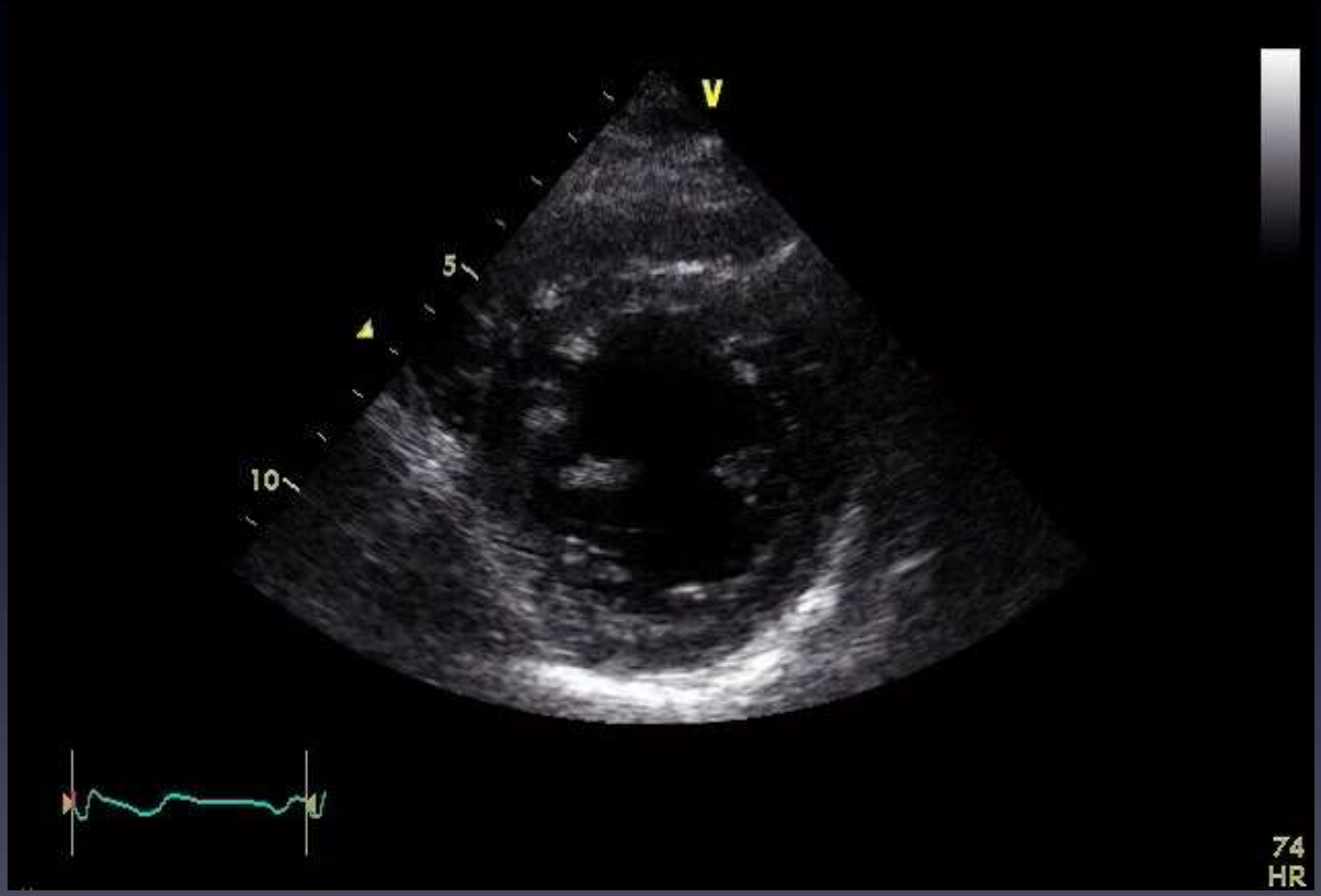

Wall motion(papillarry muscle)

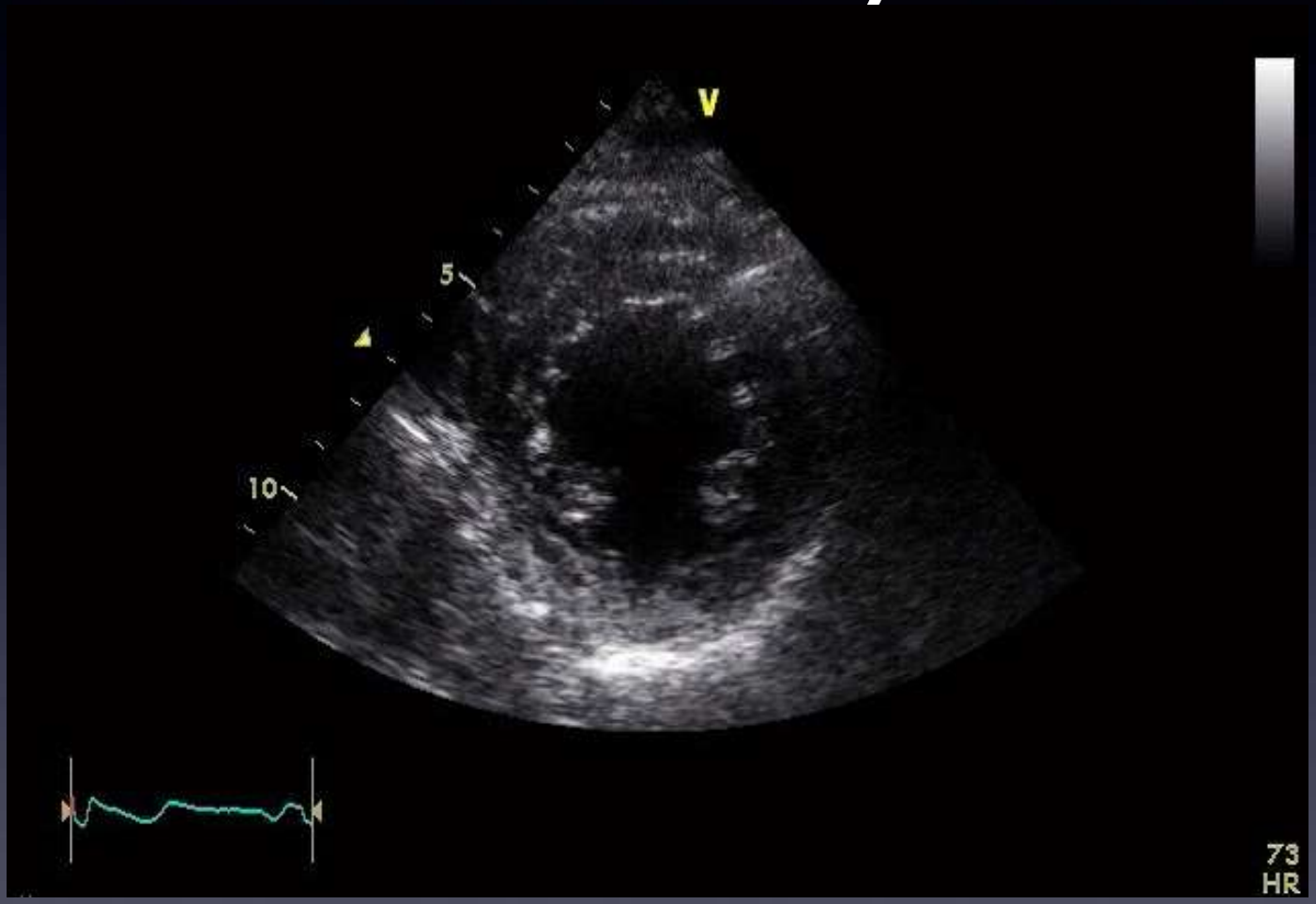

Wall motion(apex)

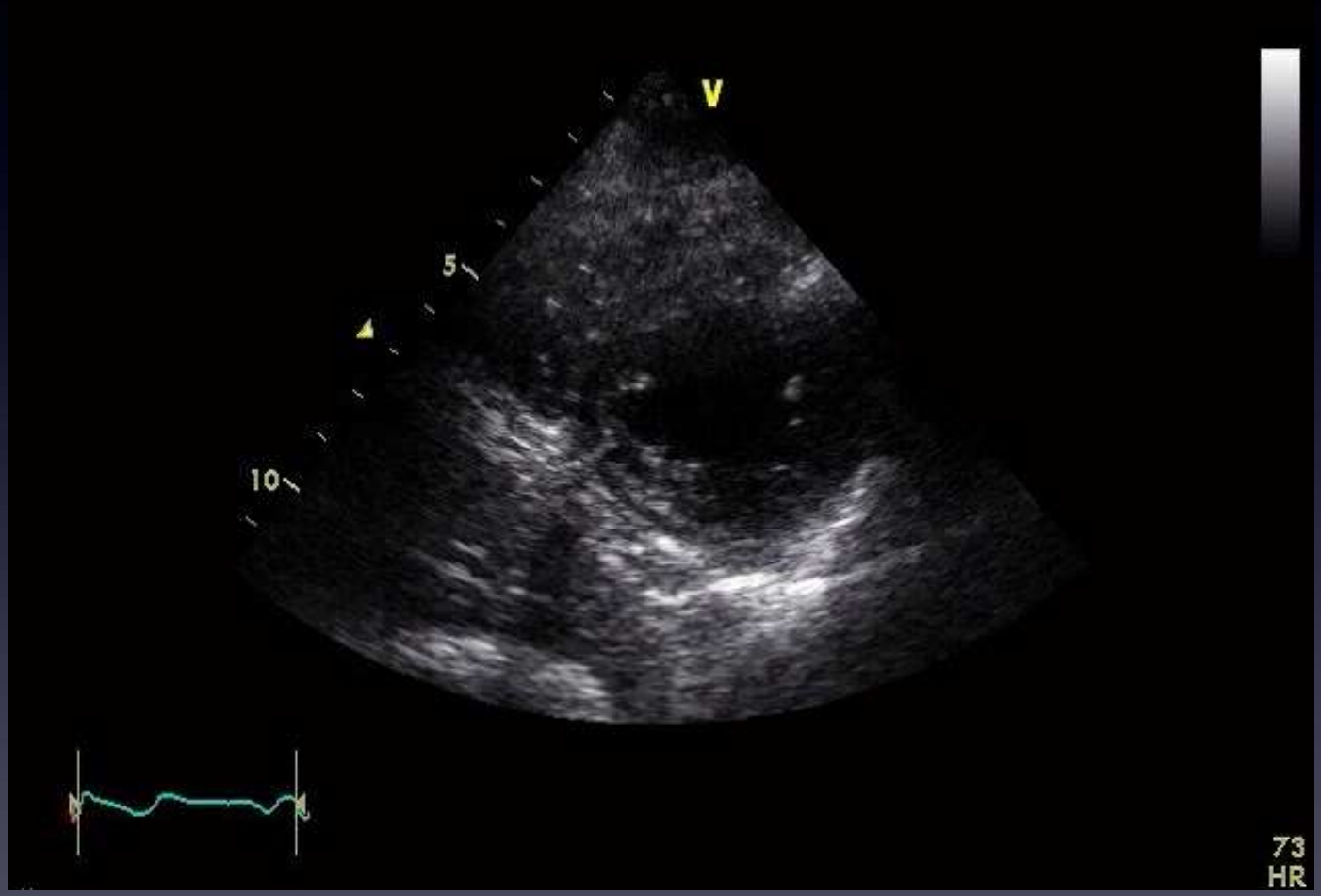

RCA total occlusion

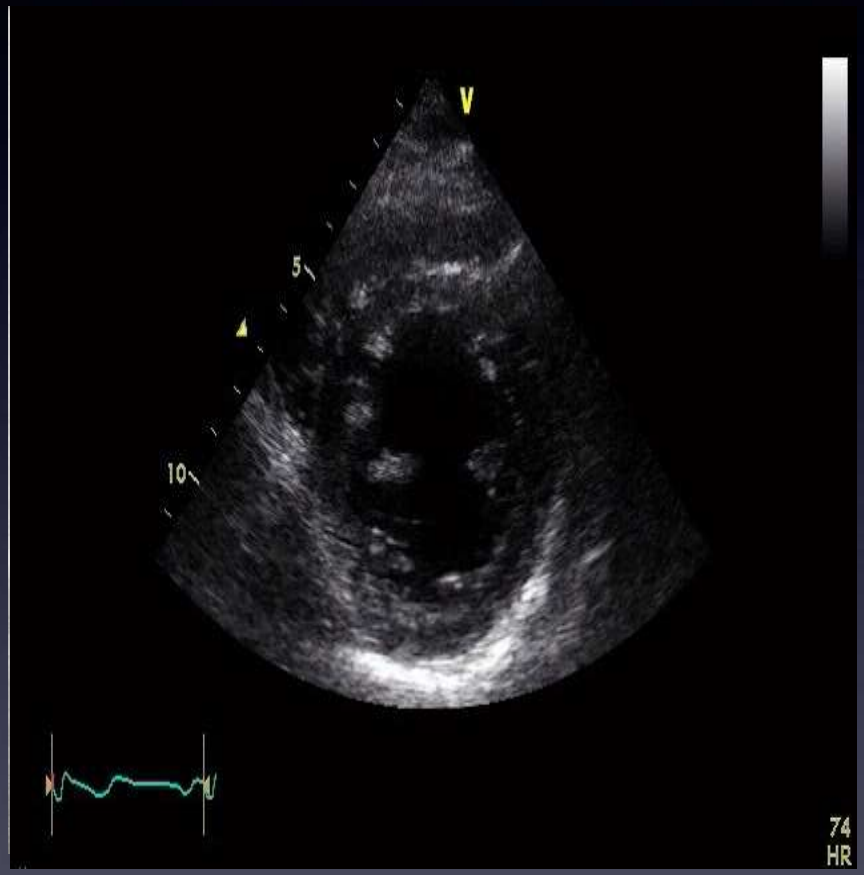

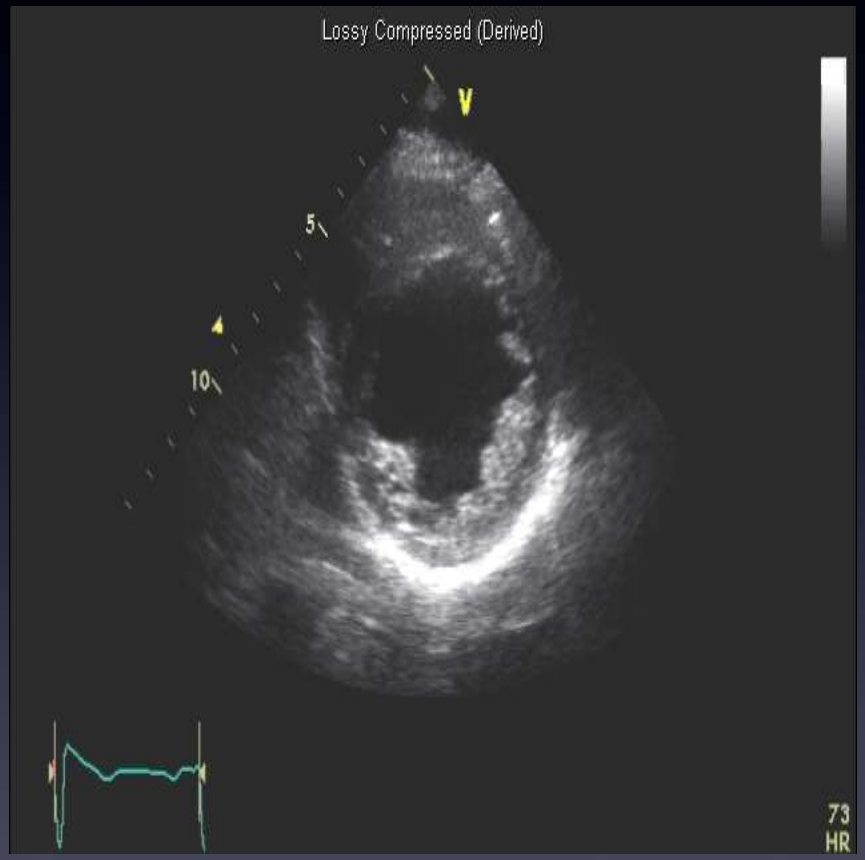

LAD total occlusion

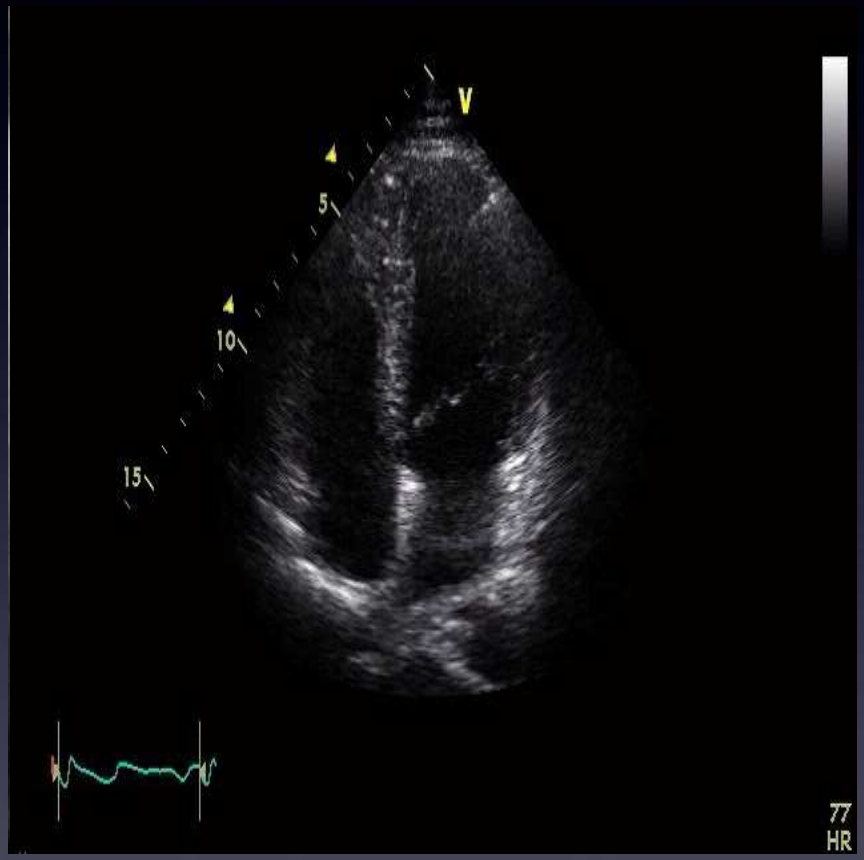

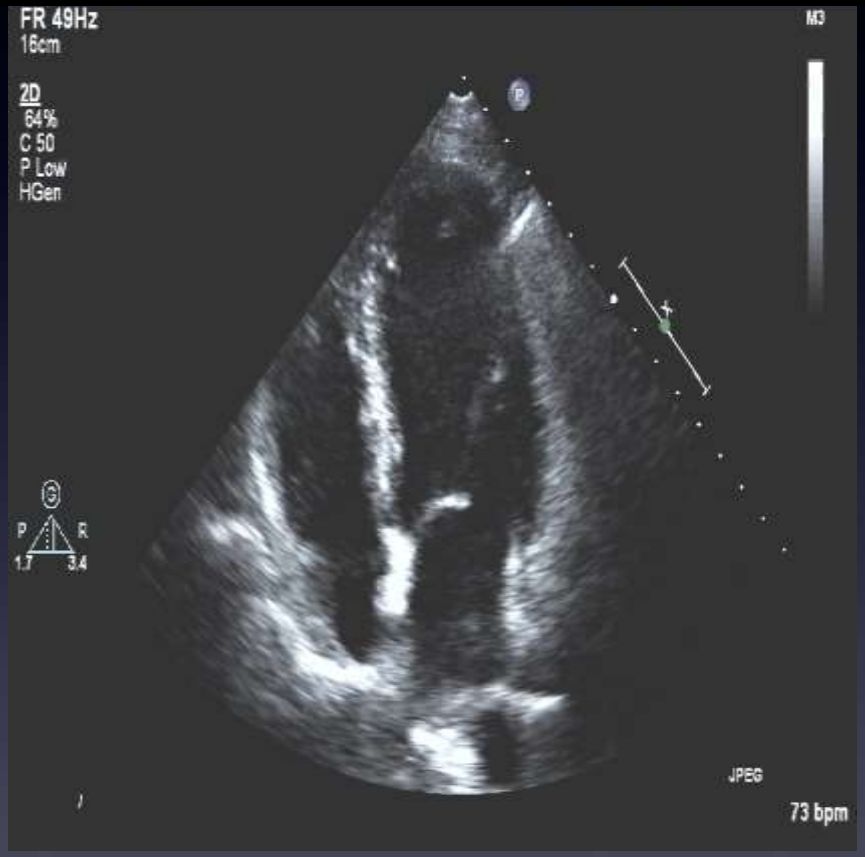

LCX total occlusion

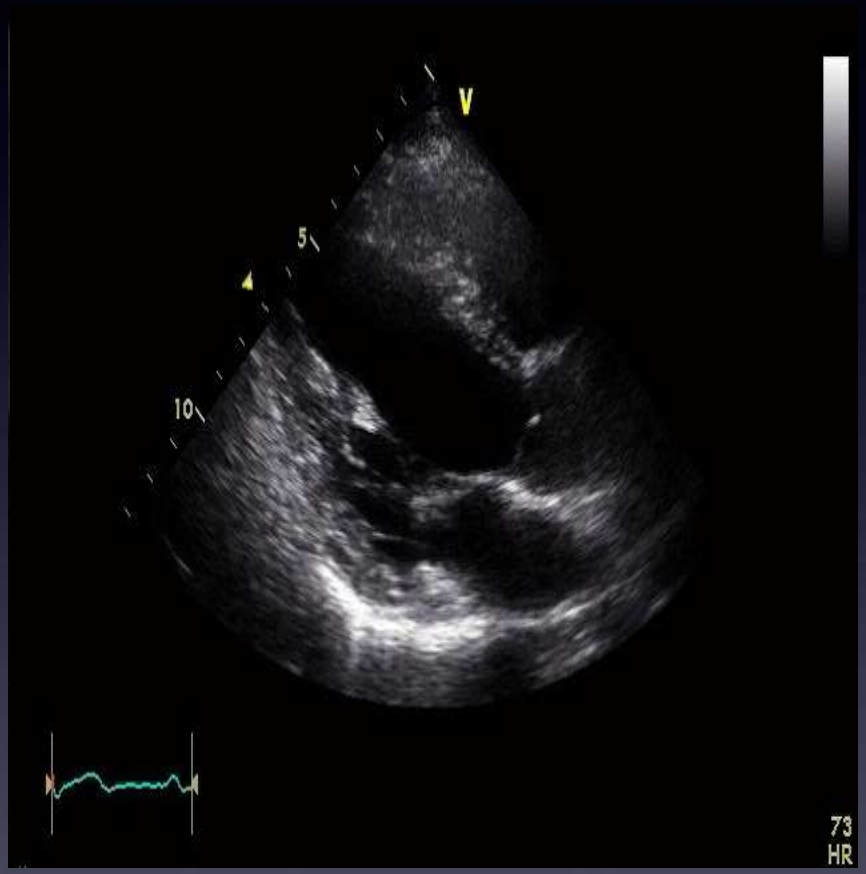

RCA total occlusion
NO rwma

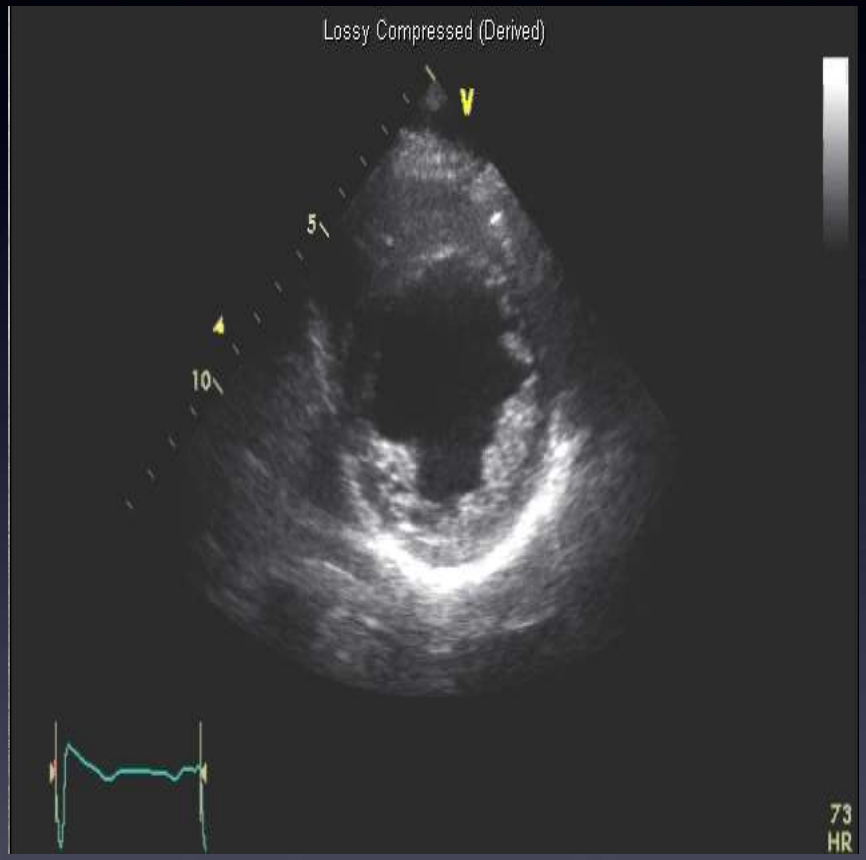

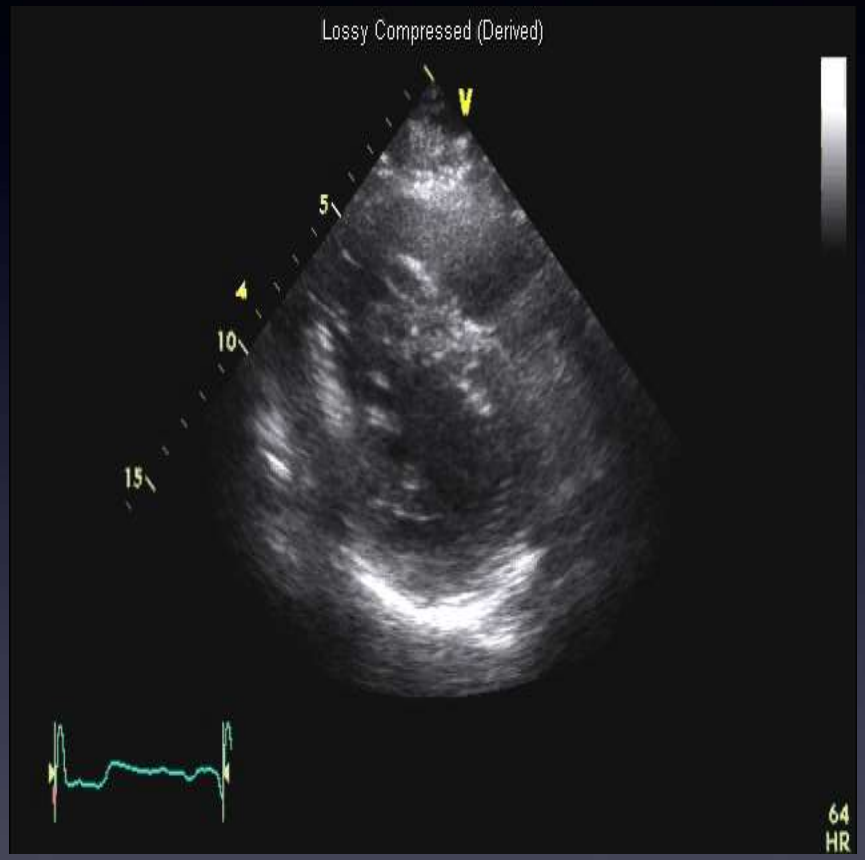

7. Subcostal view

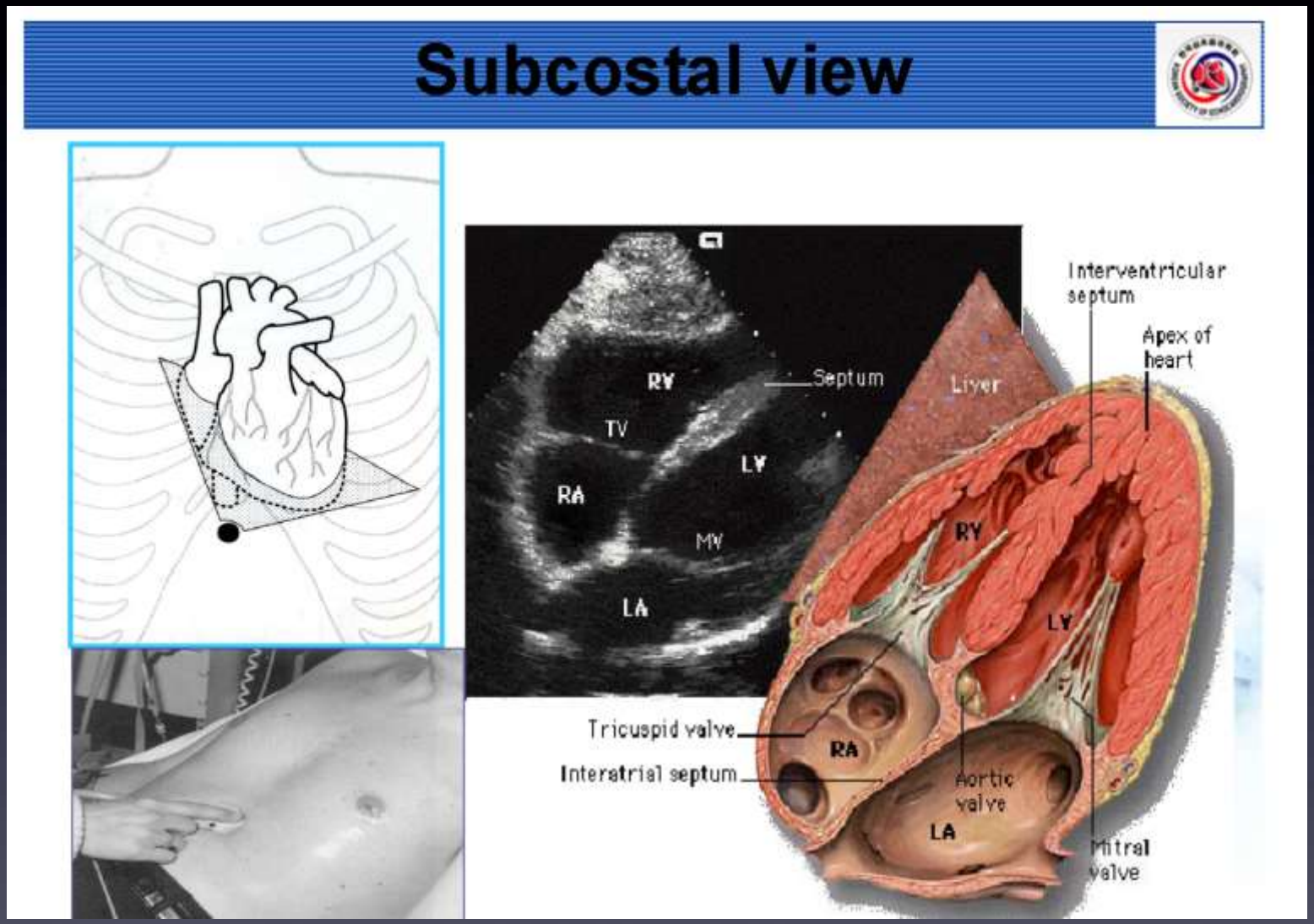

Subcostal view

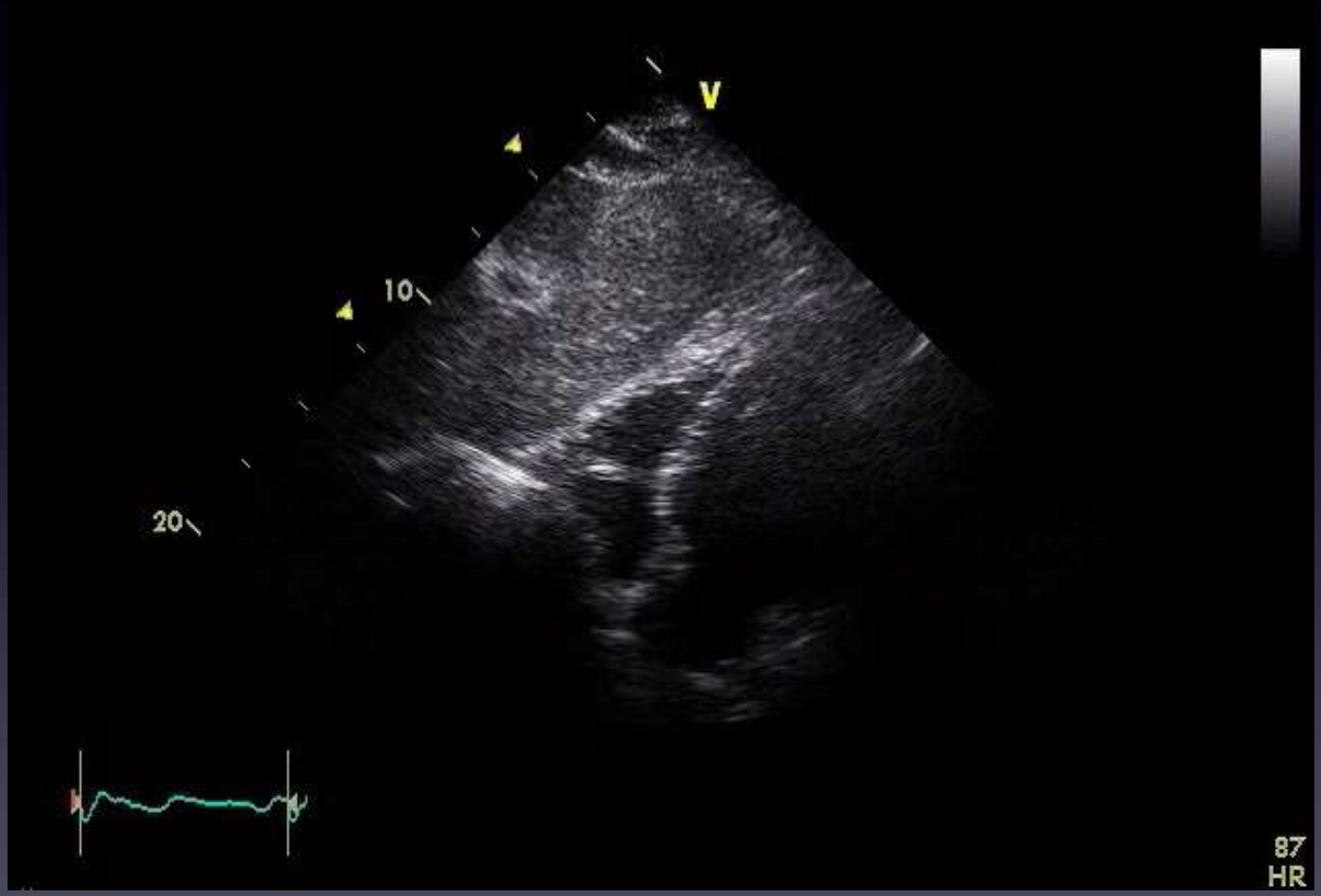

Subcostal view(doppler)

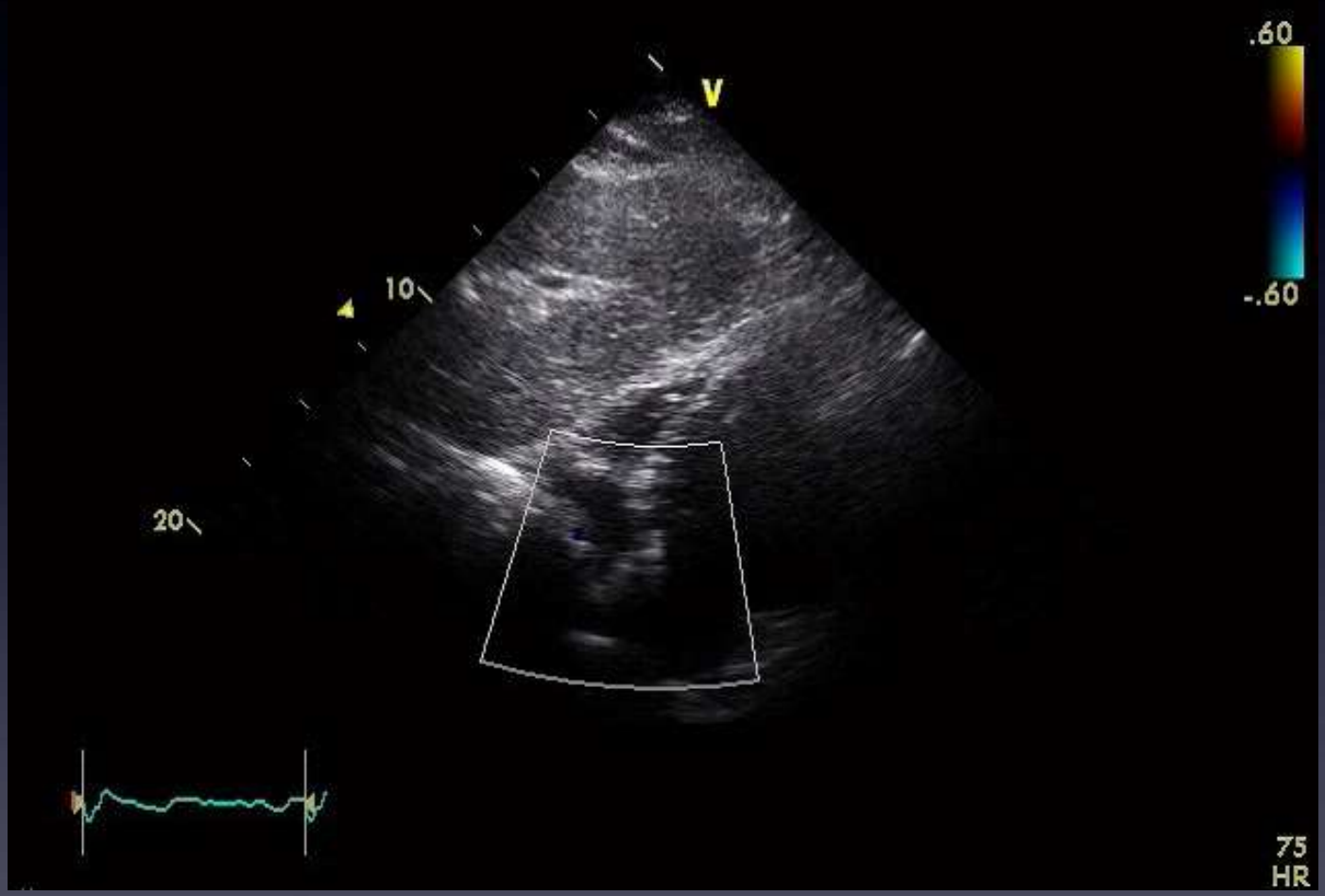

Subcostal view(IVC)

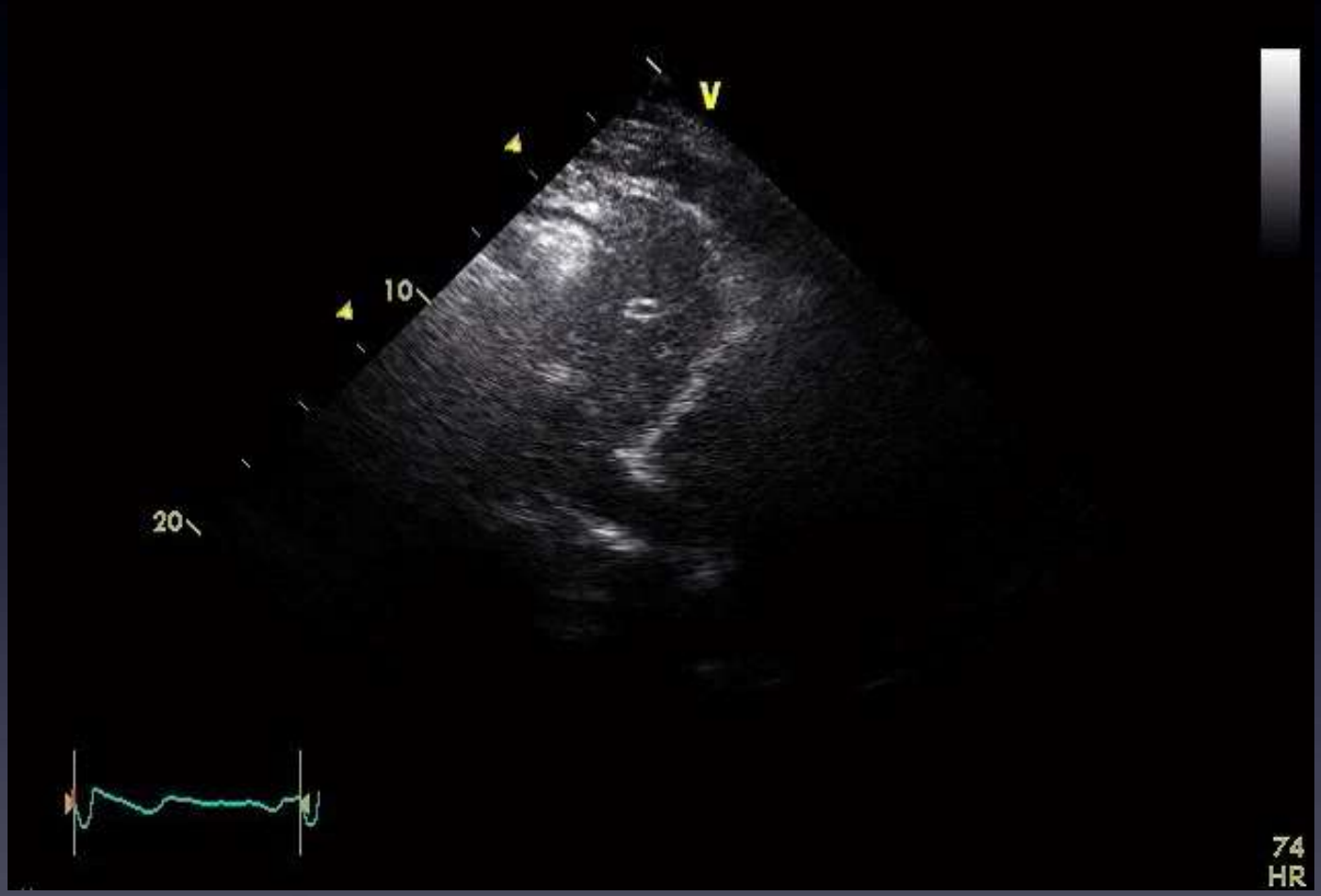

Take home massage

SAMSUNG 강북삼성병원

Google

심초음파 ppt

웹문서 이미지 동영상 뉴스 지도 도서

검색결과 약 352,000개

모든 언어
한국어 웹

모든 날짜
지난 1시간
지난 1일
지난 1주
지난 1개월
지난 1년

모든 결과
완전일치

[PDF] 경흉부 심초음파도
www.ksecho.org/infomation/contents/notice126/3.pdf
학습 목표. 경흉부 **심초음파**의 기본 View 를 안다. 1. 좌심실 내경 및 용적 측정법을 안다. 2. 좌심방 크기 및 용적 측정법을 안다. 3. Company Logo ...

[PDF] 심초음파의 물리 및 기계조작
www.ksecho.org/infomation/contents/notice126/2_1.pdf
목차. I. **심초음파**의 물리. • 초음파의 물리학적 원칙. • 초음파 음속. • 소리 저항과 반사. • 해상력. • 침투력. II. 탐촉자. III. **심초음파** 검사의 표시 방식. IV. **심초음파** 기계 ...

[PDF] 심장 해부학 및 생리학
www.ksecho.org/infomation/contents/notice126/1.pdf
심초음파 인증의 연수교육. 심장 해부학 및 생리학. 학습목표. 1. 심실 및 심방, 대 혈관, 관상동맥 혈관의 해부학적 위치를 설명할 수. 있어야 한다. 2. 판막의 해부학적 ...