

Acute LM occlusion

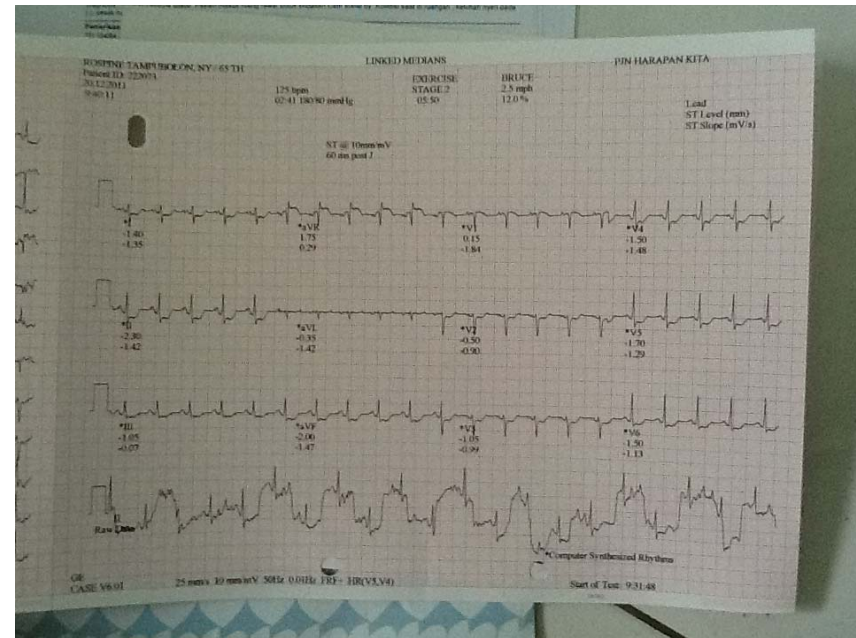
Dr. Retna Dewayani

Dr. Doni Firman

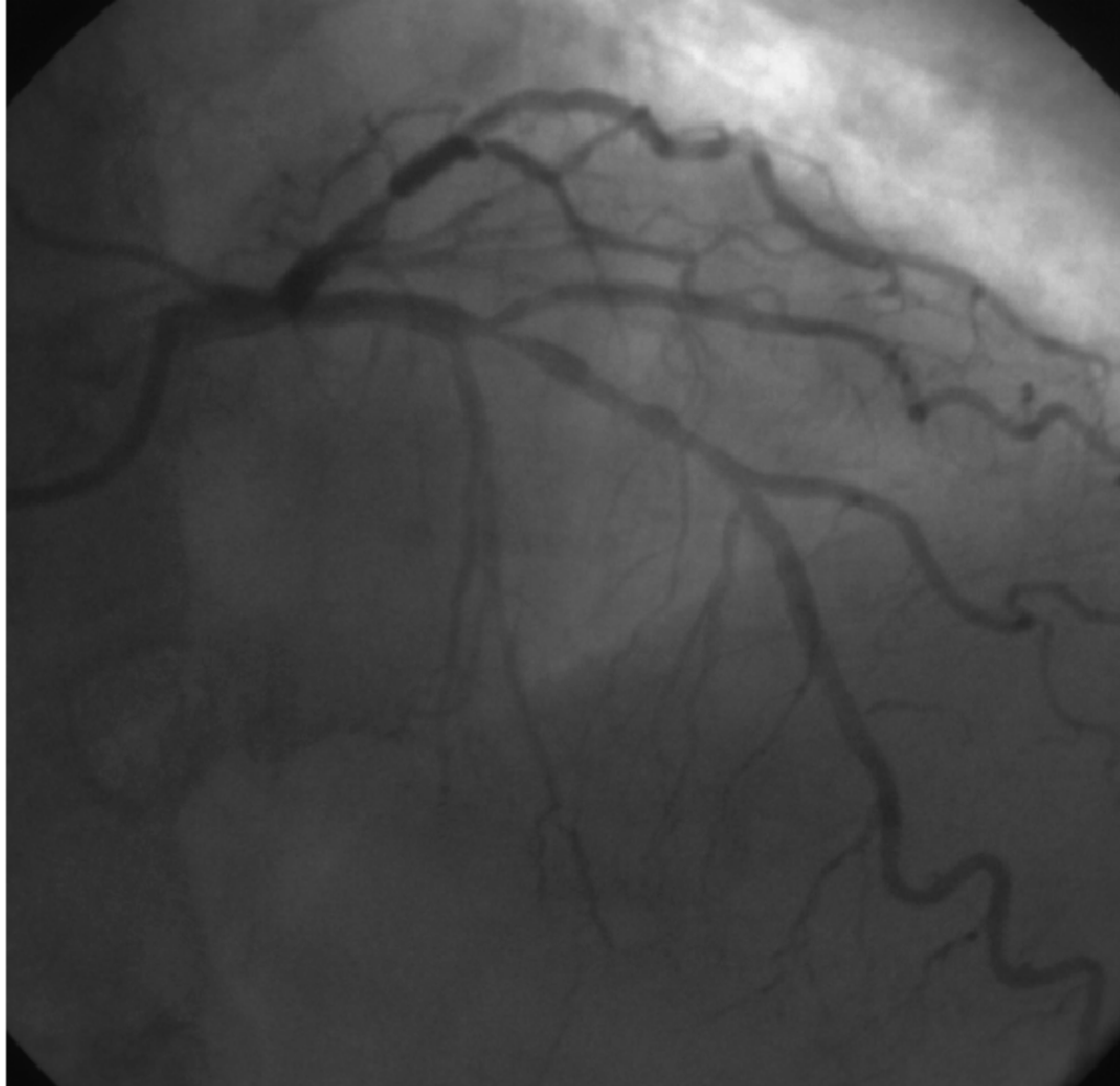
National Cardiac Center Harapan Kita

Clinical Presentation

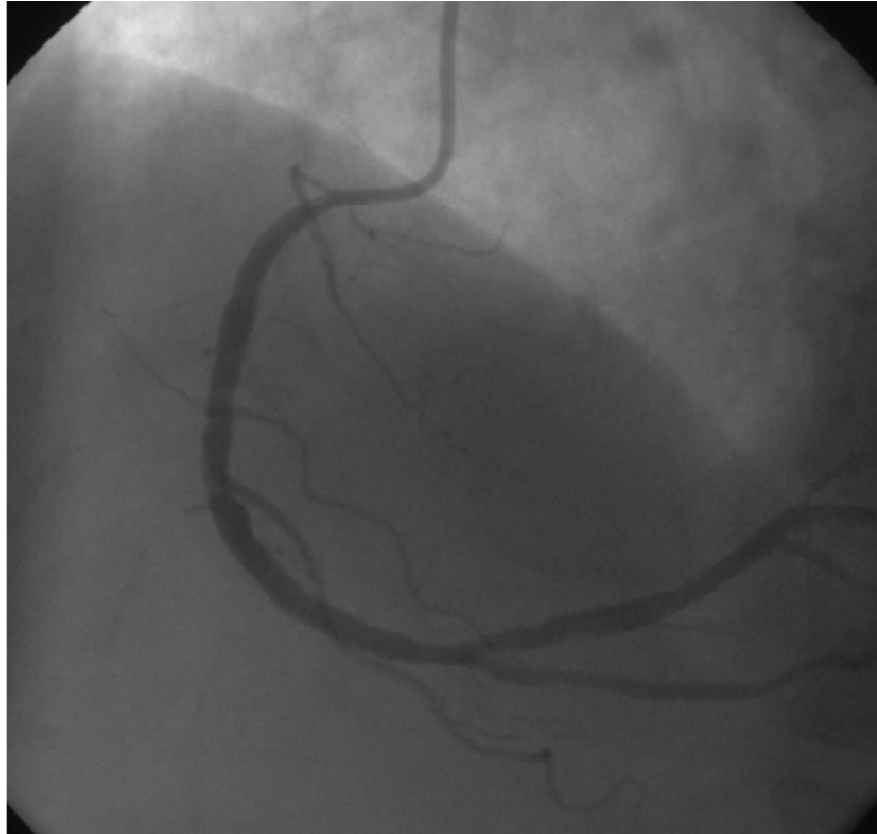
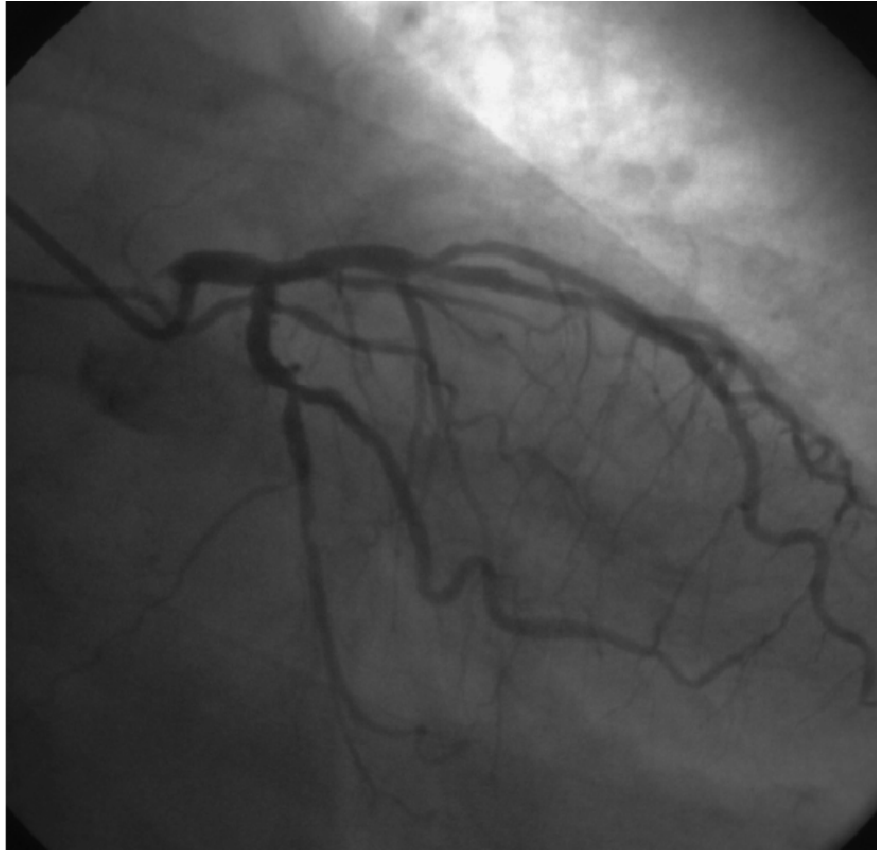- A 65 year-old lady
- Stable angina
- TMT: +ve at st 2
- Risk Factors : DM + HTN
- LVEF 70%
- Creatinin level 0.8 mg/dL



Baseline coronary angiogram



Bifurcation
MEDINA 1.1.0



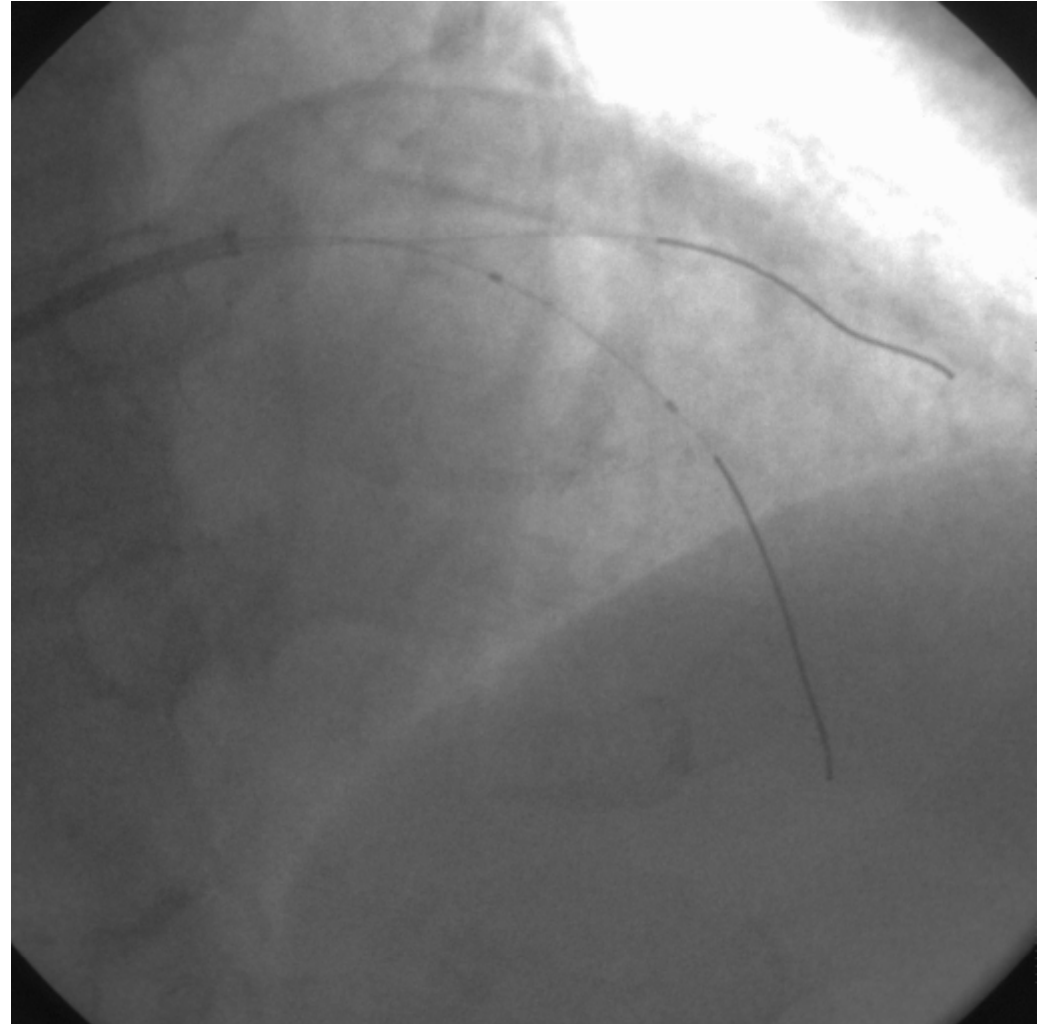
Proceed..

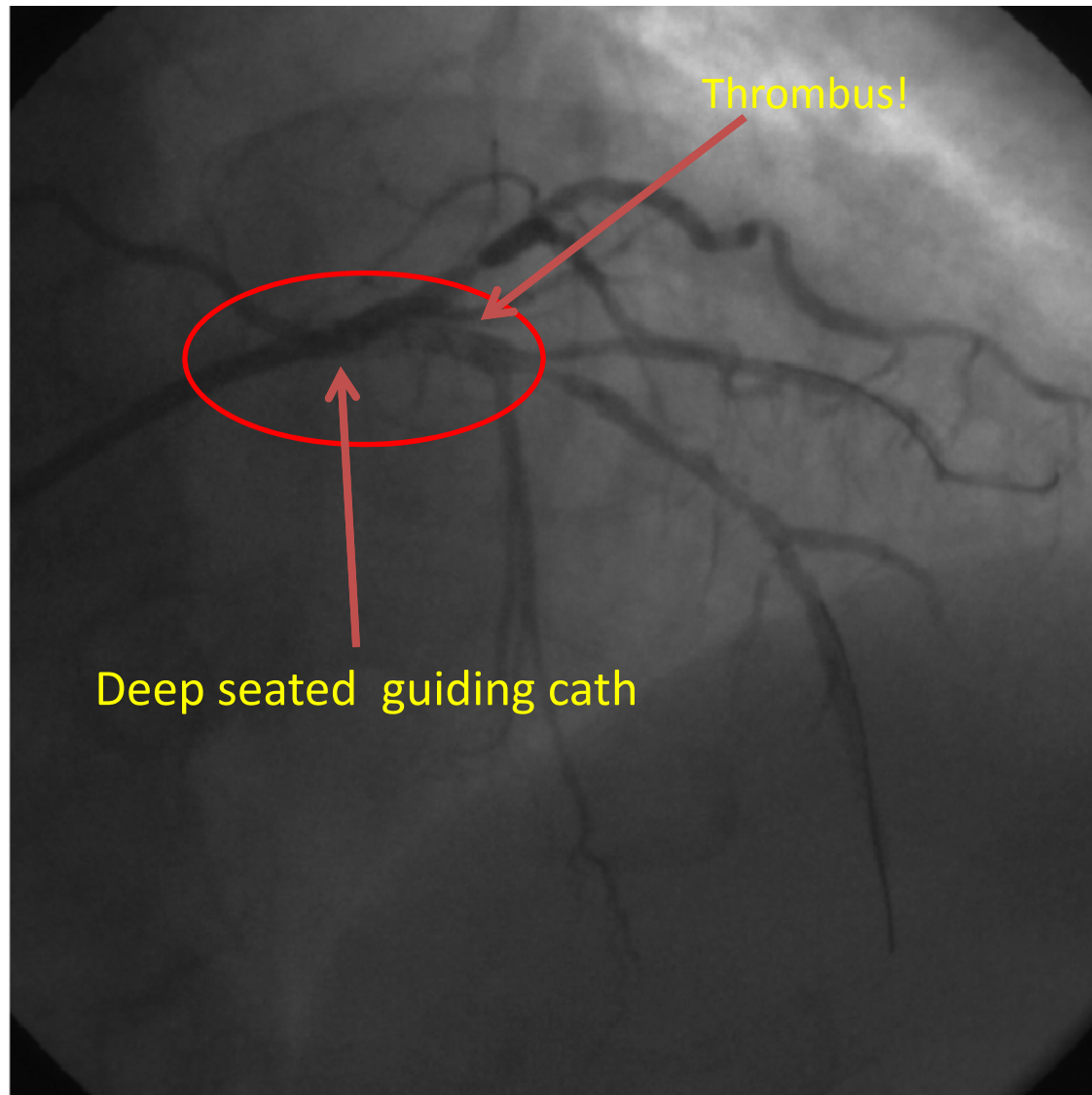
Strategy:

1 stent strategy

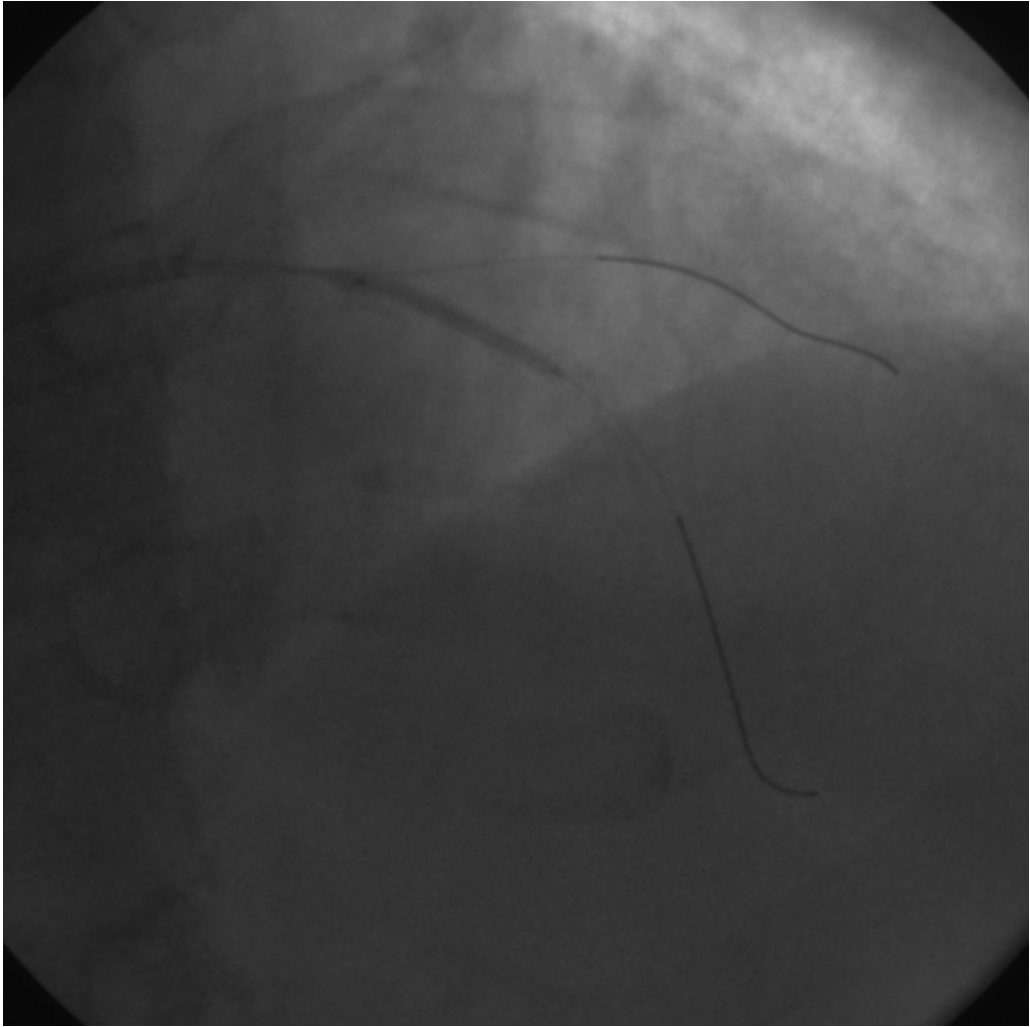
Protect side branch

- Right radial artery,
- Guiding cath: XB3.5/6fr
- Runthrough floppy to LAD
- Runthrough floppy to D1
- Mini trek 2.0/20

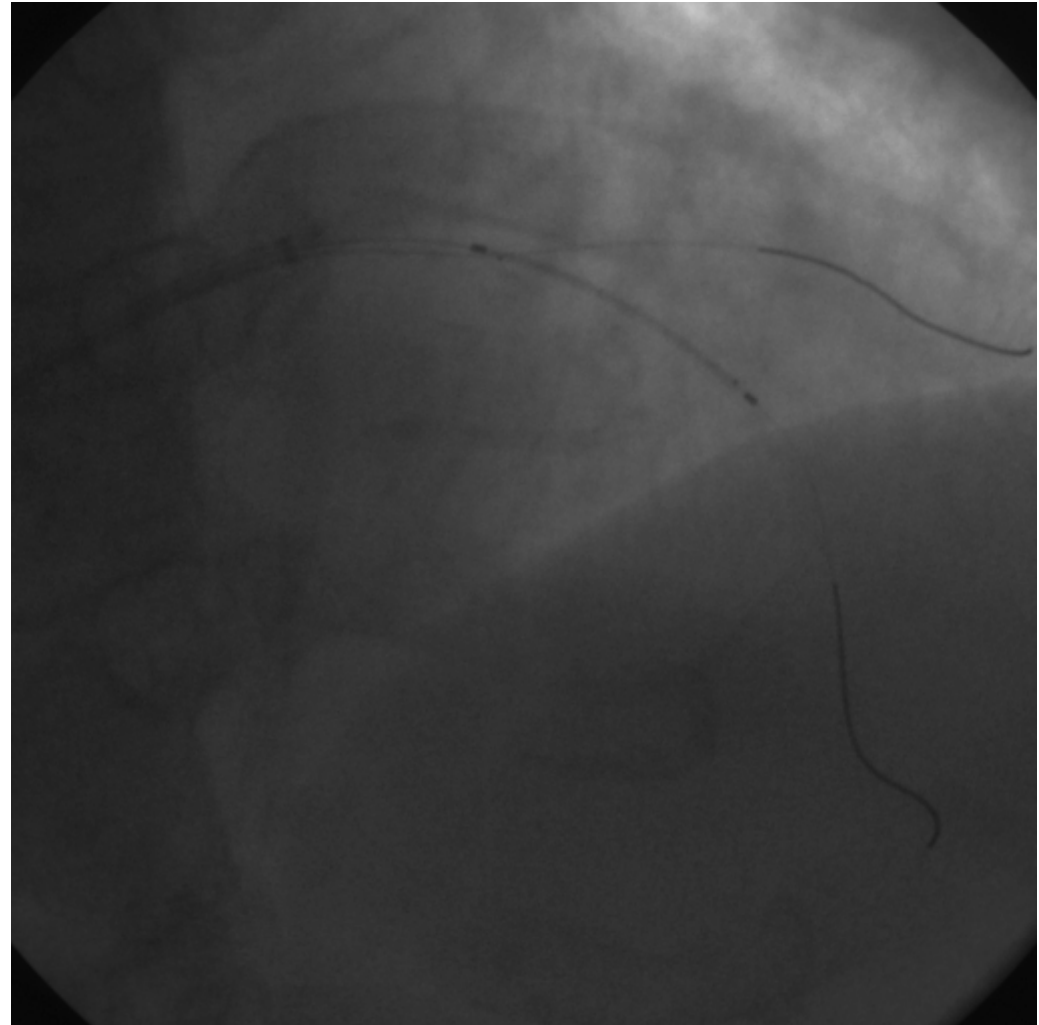




Minitrek 2.0/20

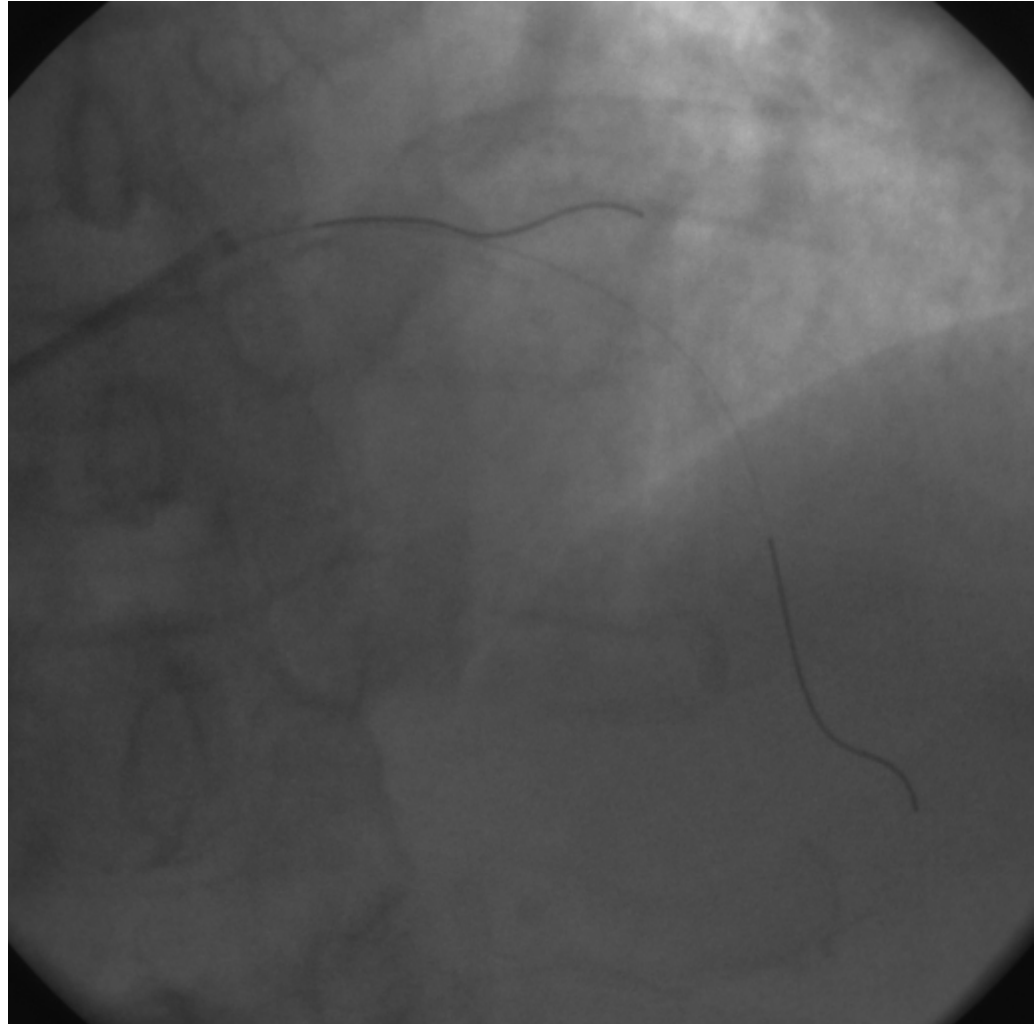


Tsunami stent 3.0/25
TIMI 1 flow
Trombus in LM and
Prox LAD

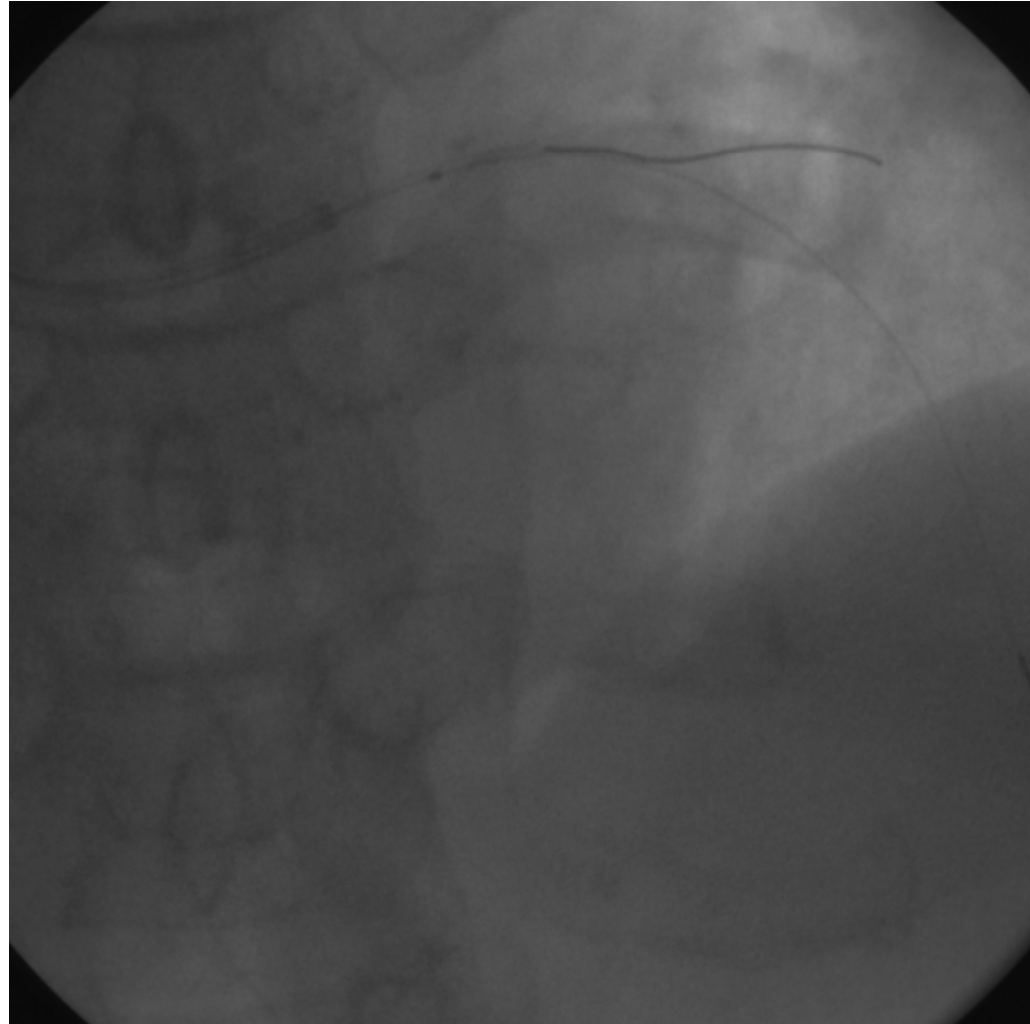


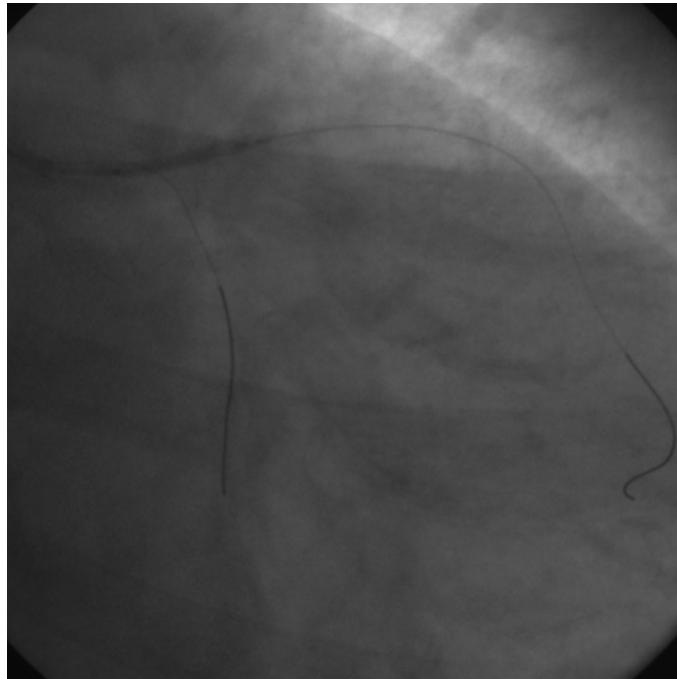
NO FLOW
ST elevation
Chest pain

BAILOUT strategy?

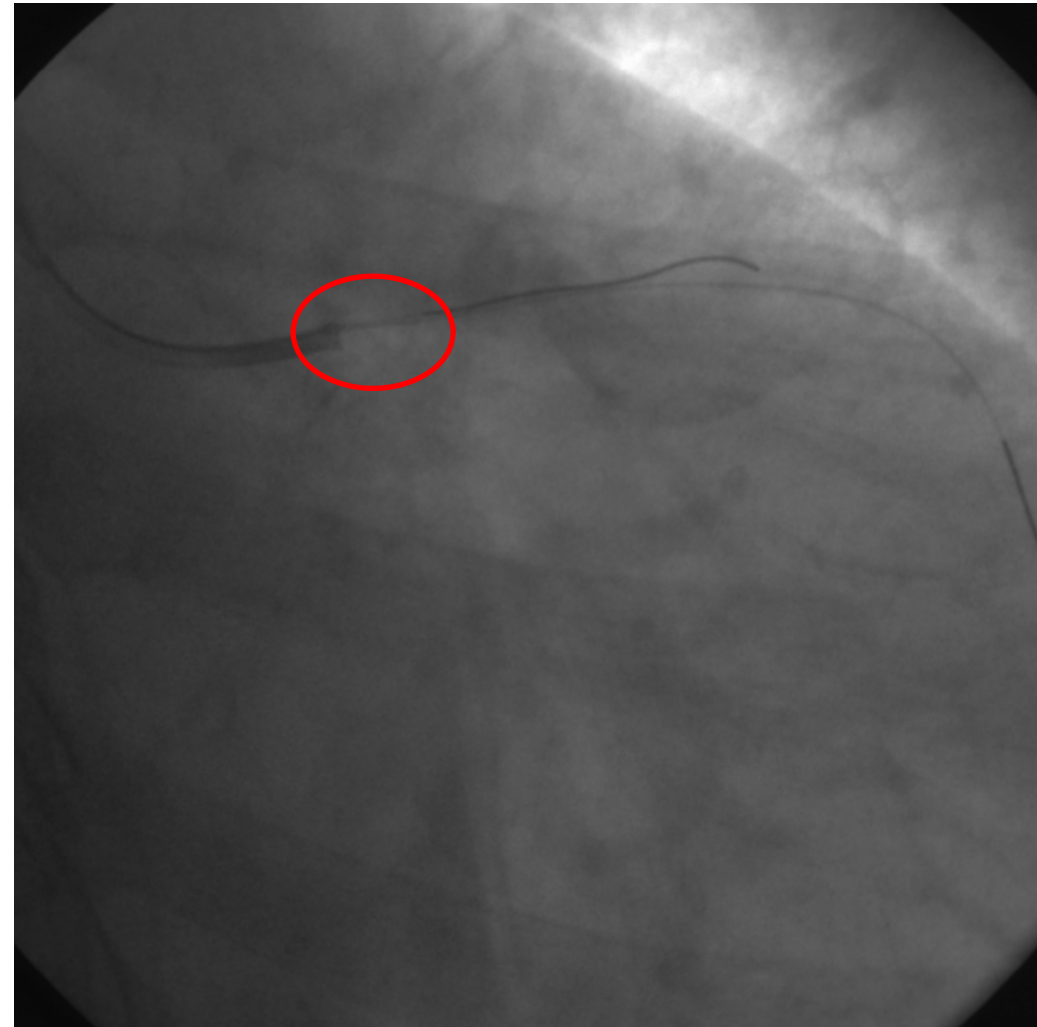


O2,
Intracoronary NTG +
INTERGRILIN
Aspiration
(thrombuster II 6fr)



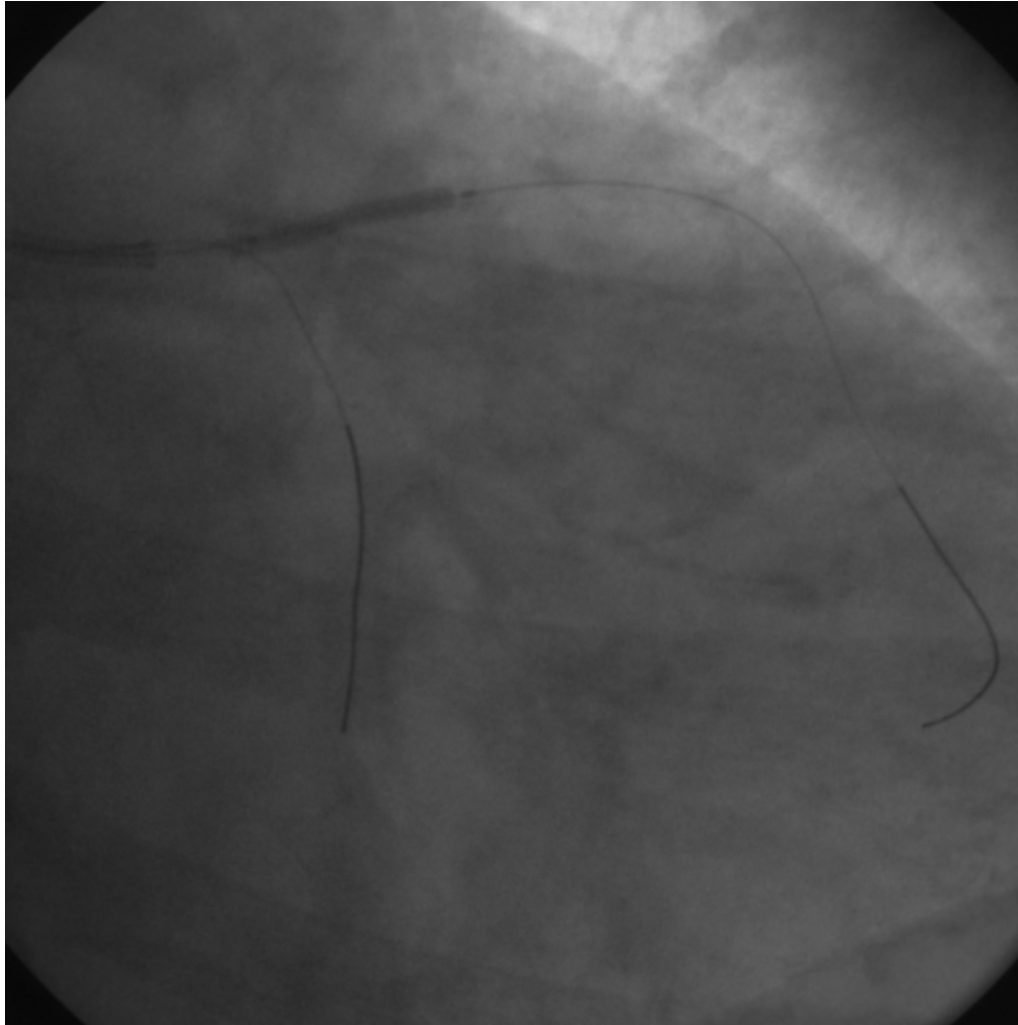


After Those ATTEMPTS,
Timi 0
Large thrombus
Burden
Dissected LM
What shld we do



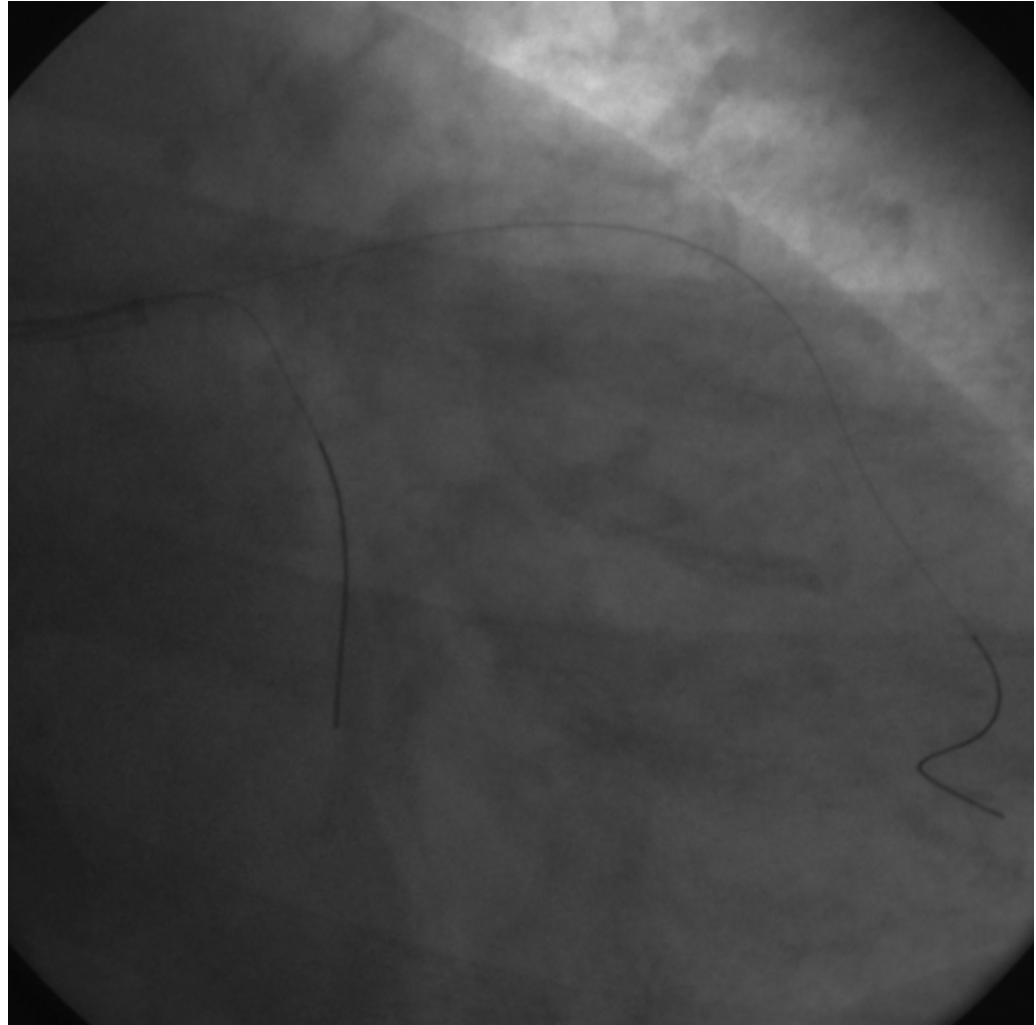
LESSON LEARNED:
BE CAREFUL WITH XB in short LM

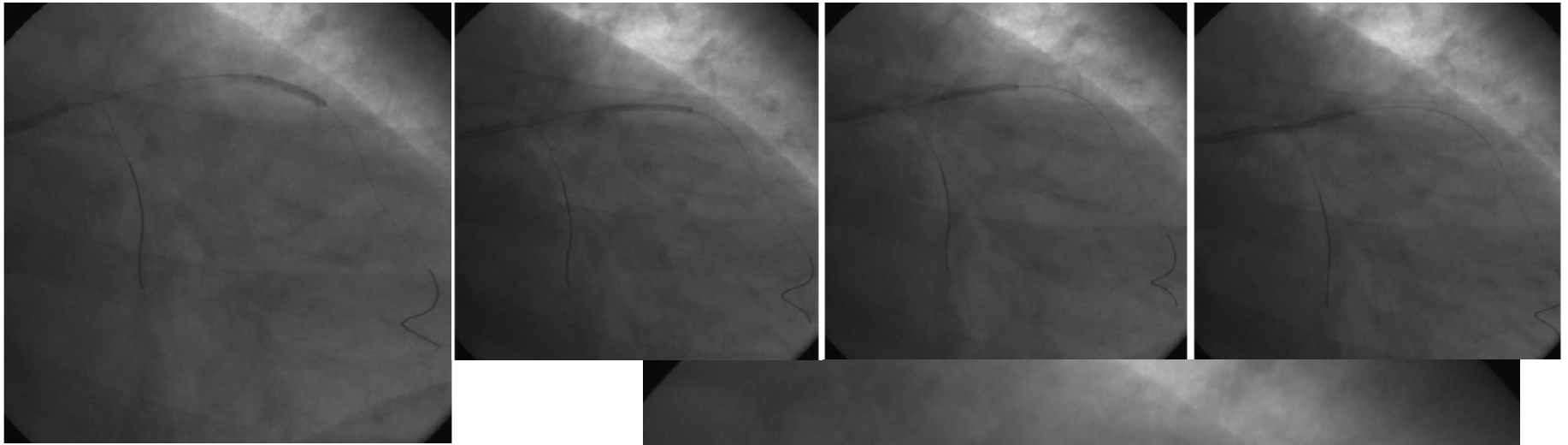
Minitrek 2.0/20



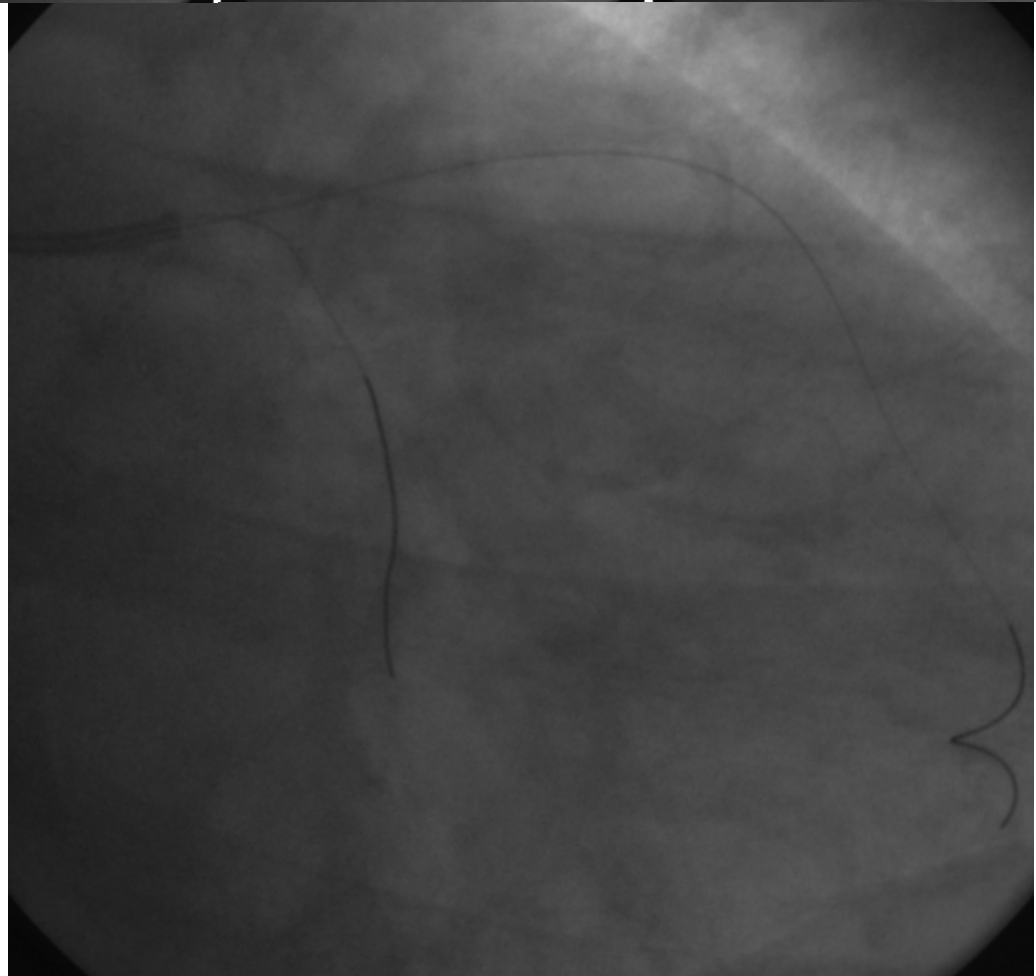
DON'T LOSE YOUR WIRES!!

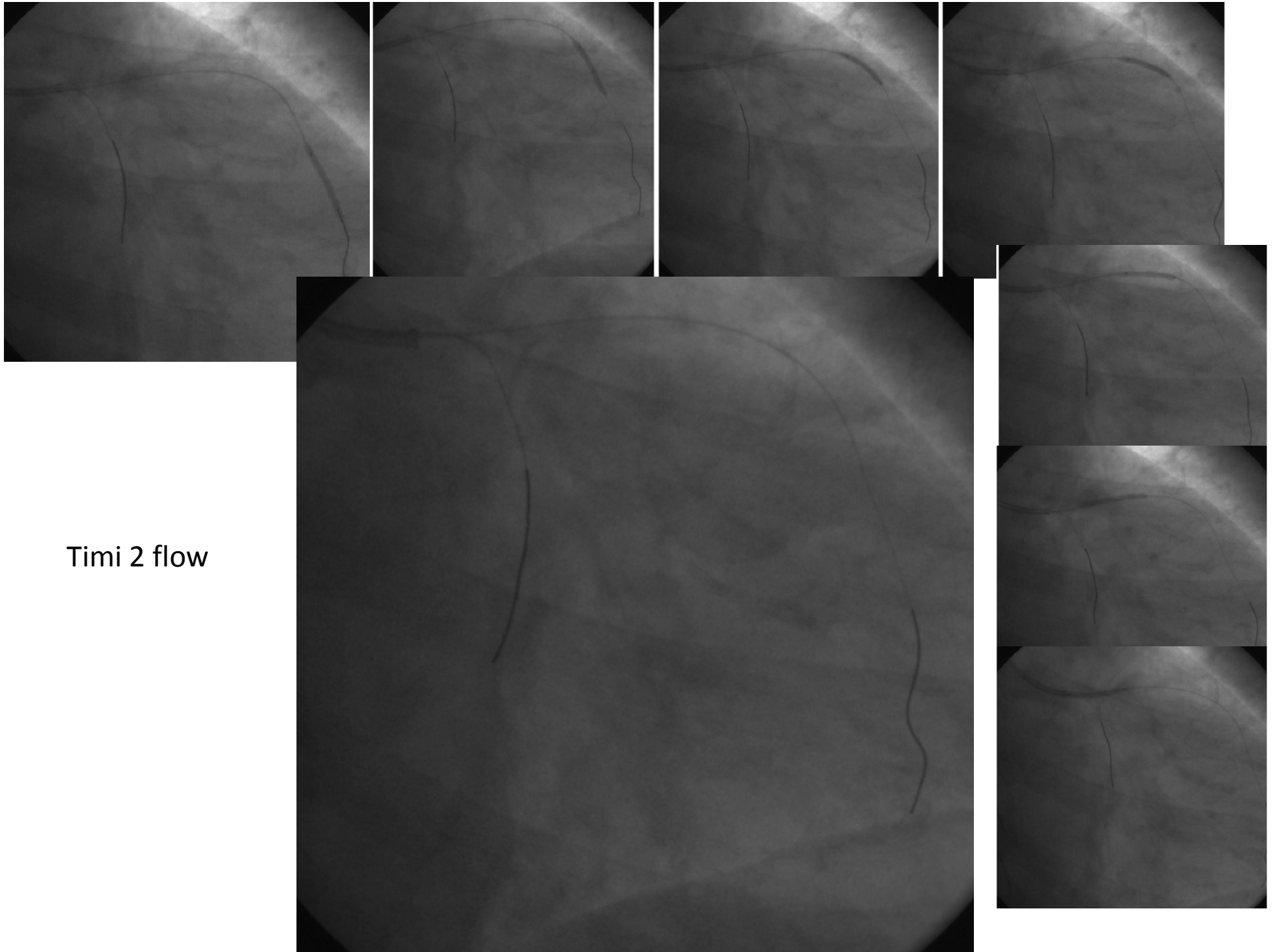
See light at the end
of the tunnel



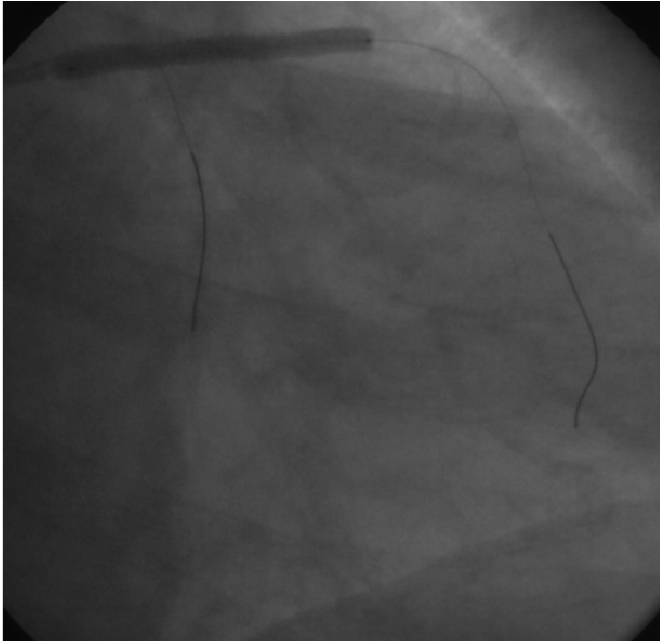


Naughty thrombus





Timi 2 flow

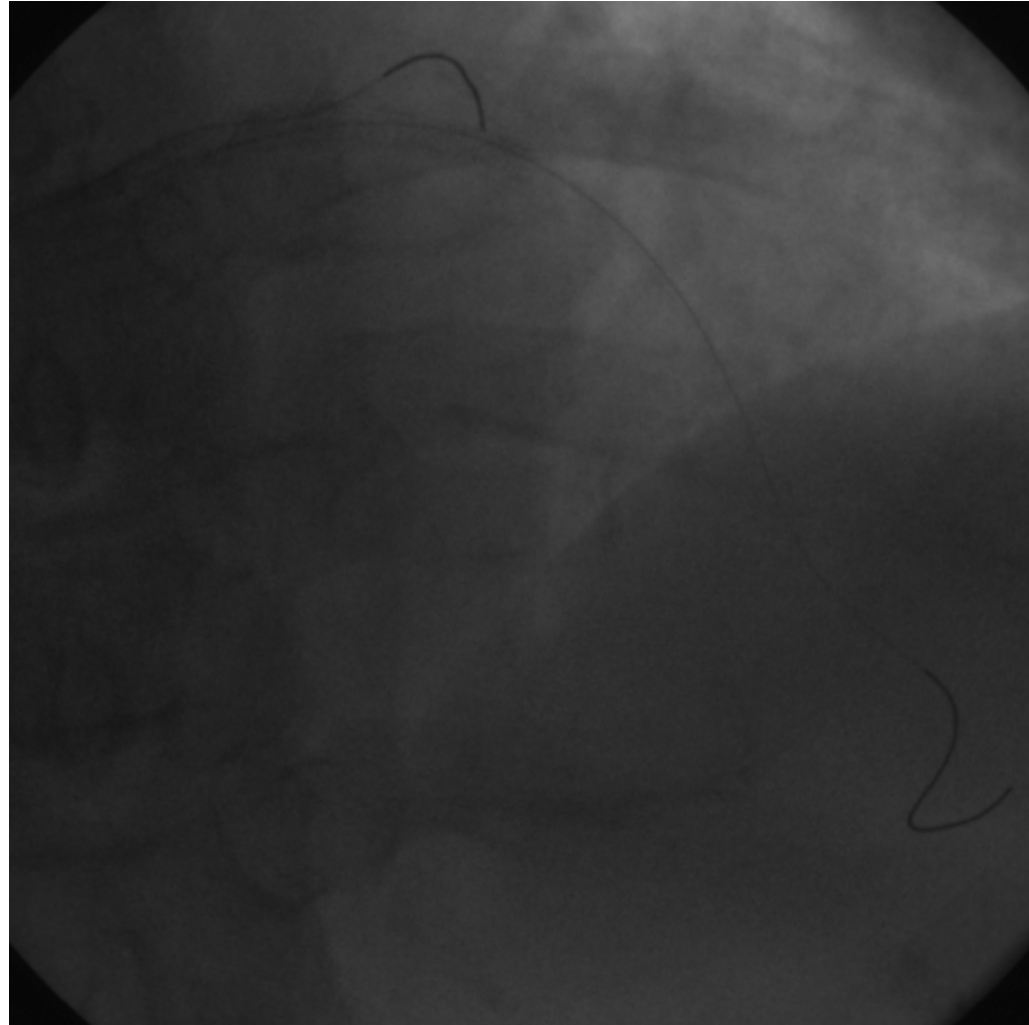


Amazonia croco

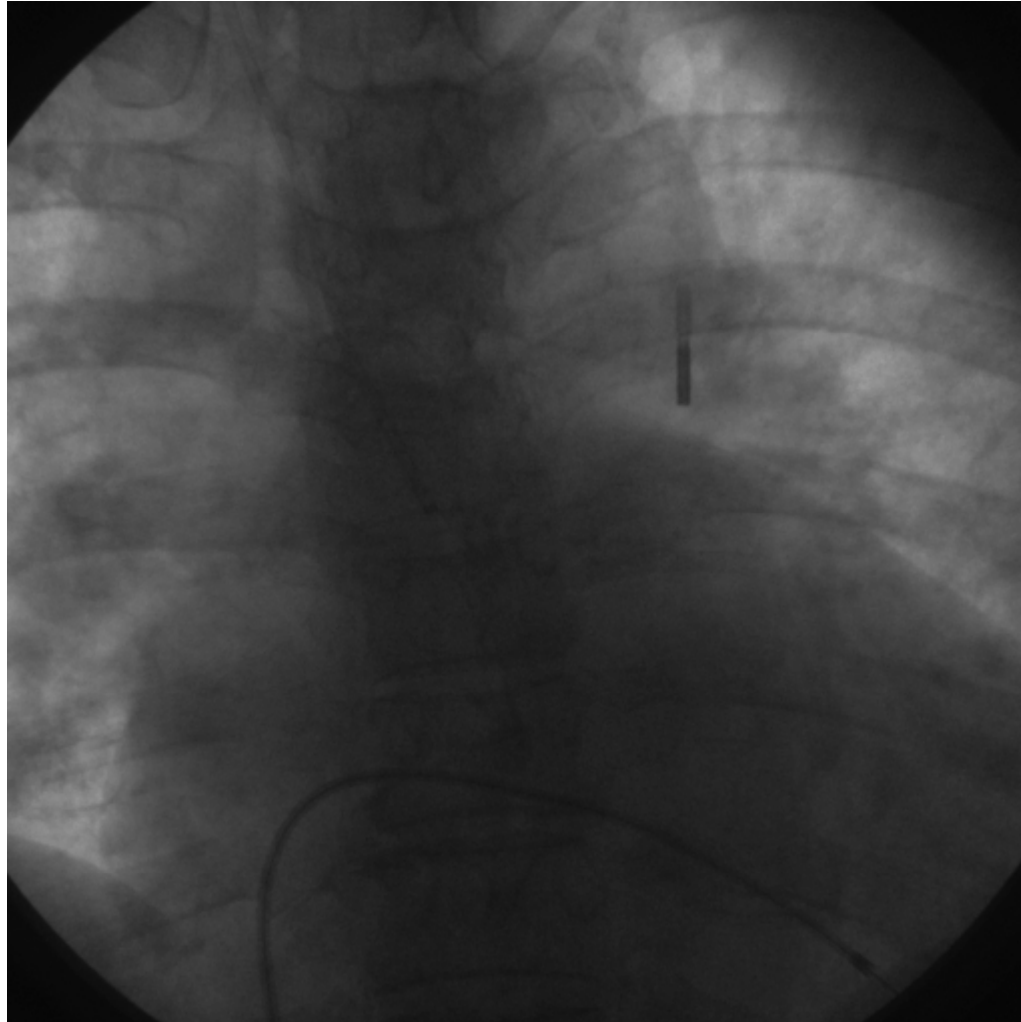
3.5/40

TIMI 3 FLOW, TMP2 BLUSH

Wheres LCX?



Temporary
wire
IABP inserted
Intracoronary
nitrates given

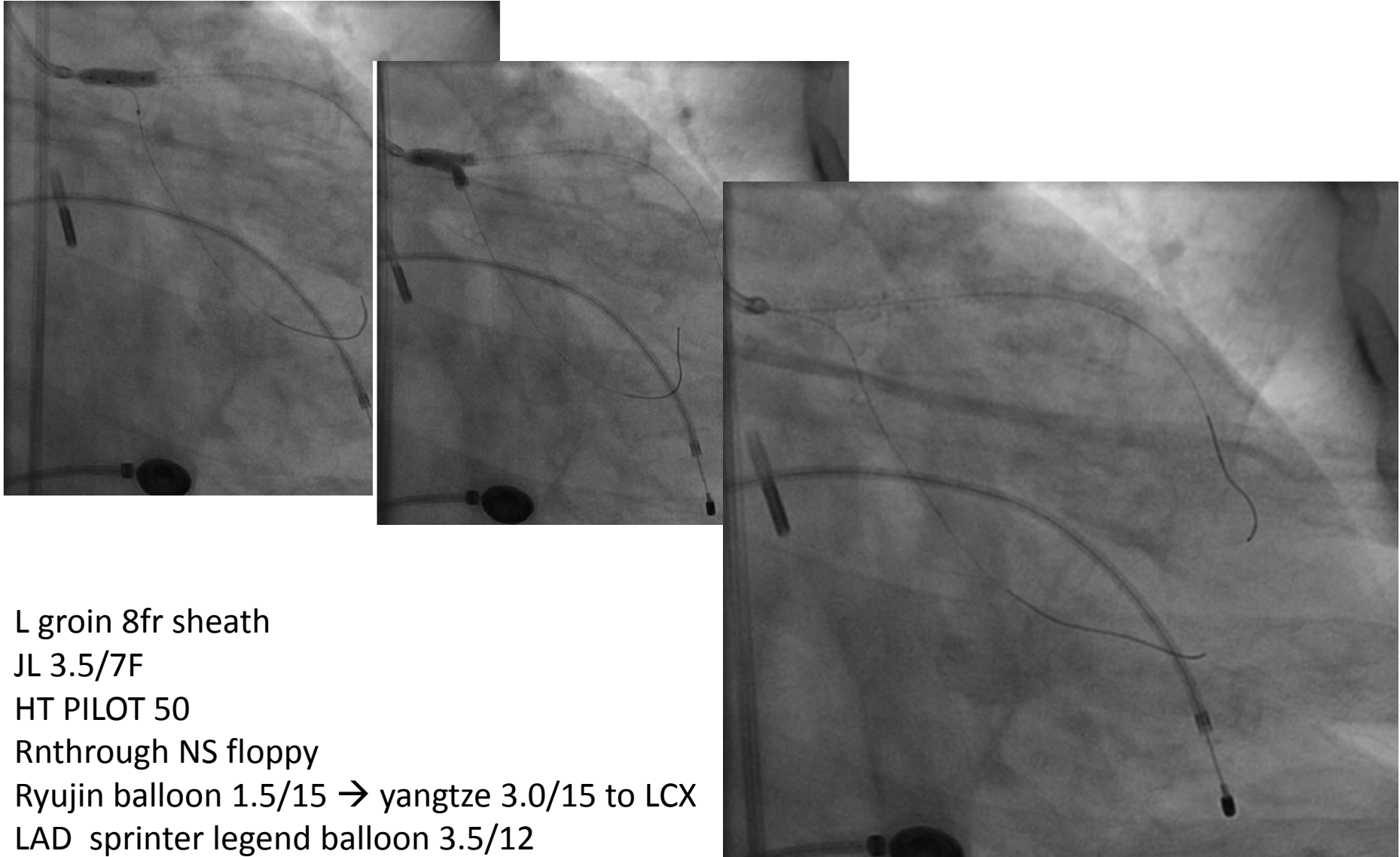


ICCU

Uneventful

Wean and off inotropes in day 2

2 days later, PCI LCX



L groin 8fr sheath

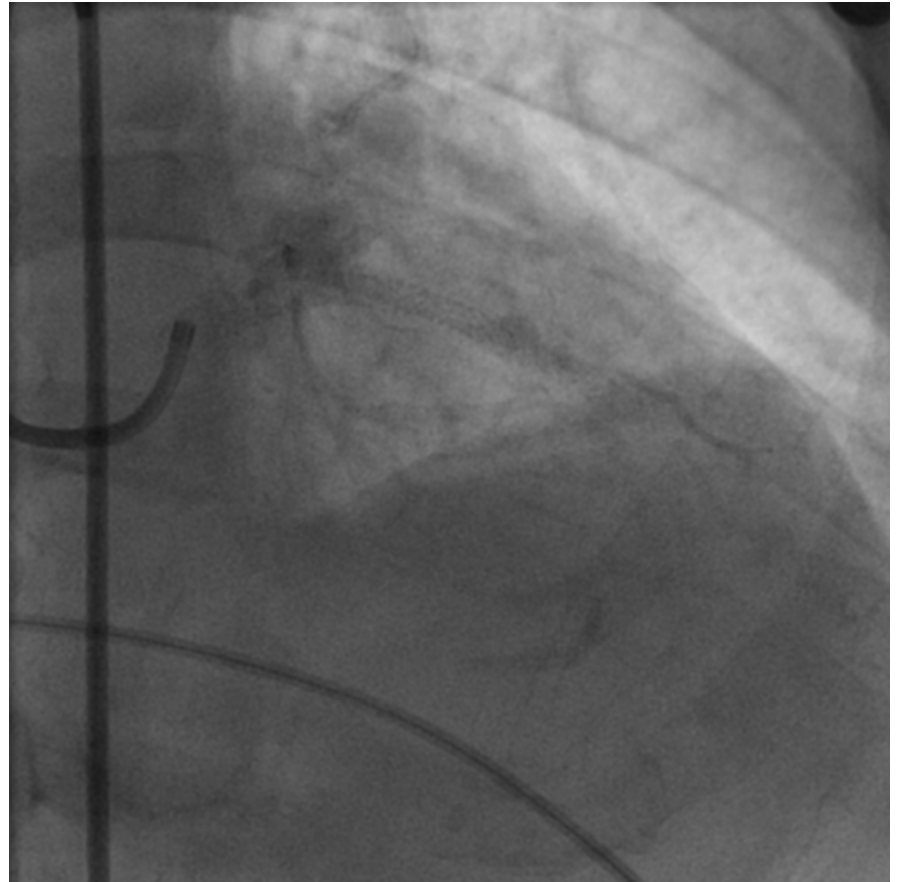
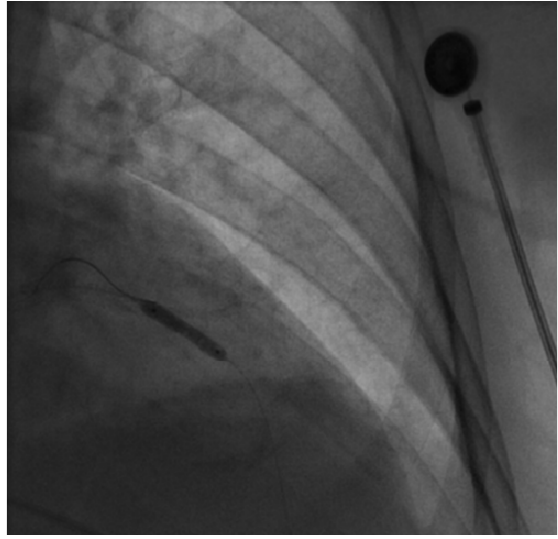
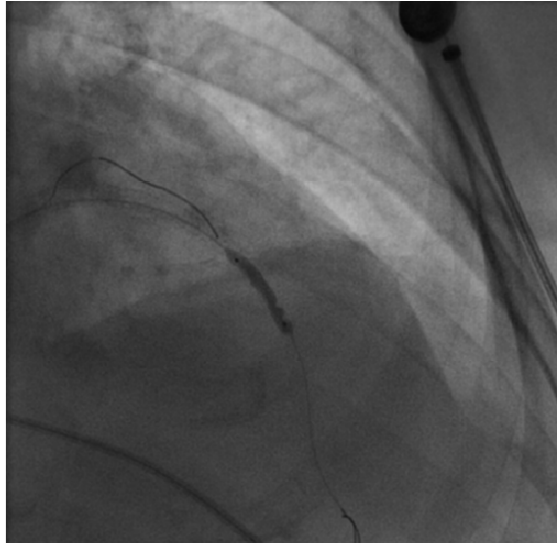
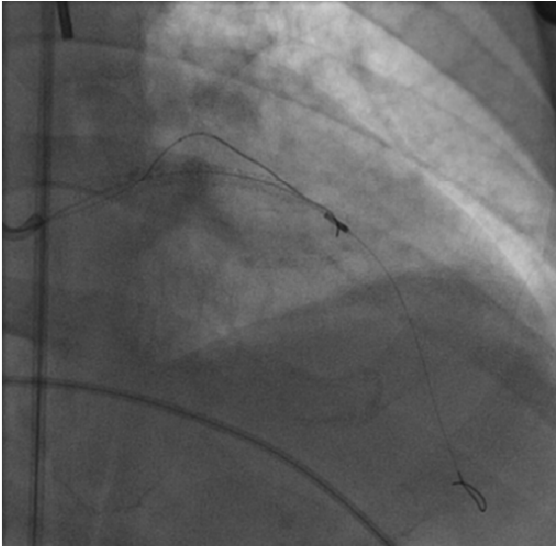
JL 3.5/7F

HT PILOT 50

Rnthrough NS floppy

Ryujin balloon 1.5/15 → yangtze 3.0/15 to LCX

LAD sprinter legend balloon 3.5/12



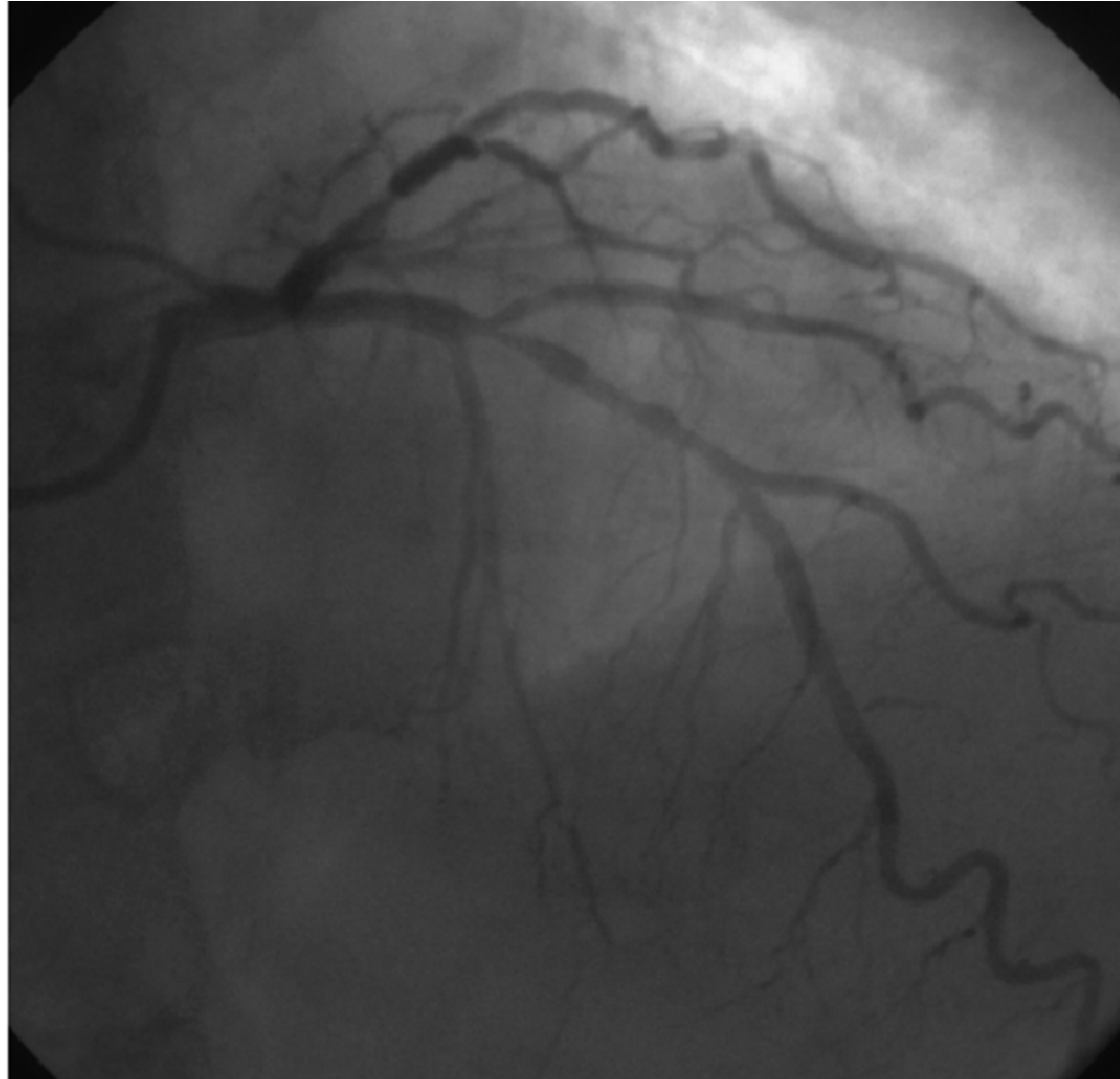
- Discharged at day 7th.

Take home message

- Be careful of using XB guiding for short LM
- Pay attention to your GUIDE. Dont be too focused on THE LESION!
- Do not LOSE your WIRES.
- Be careful when you retrieve balloon, the GUIDE can be SLIDED IN and causing injury and DISSECTION.

Be careful of using XB/EBU guiding for short LM

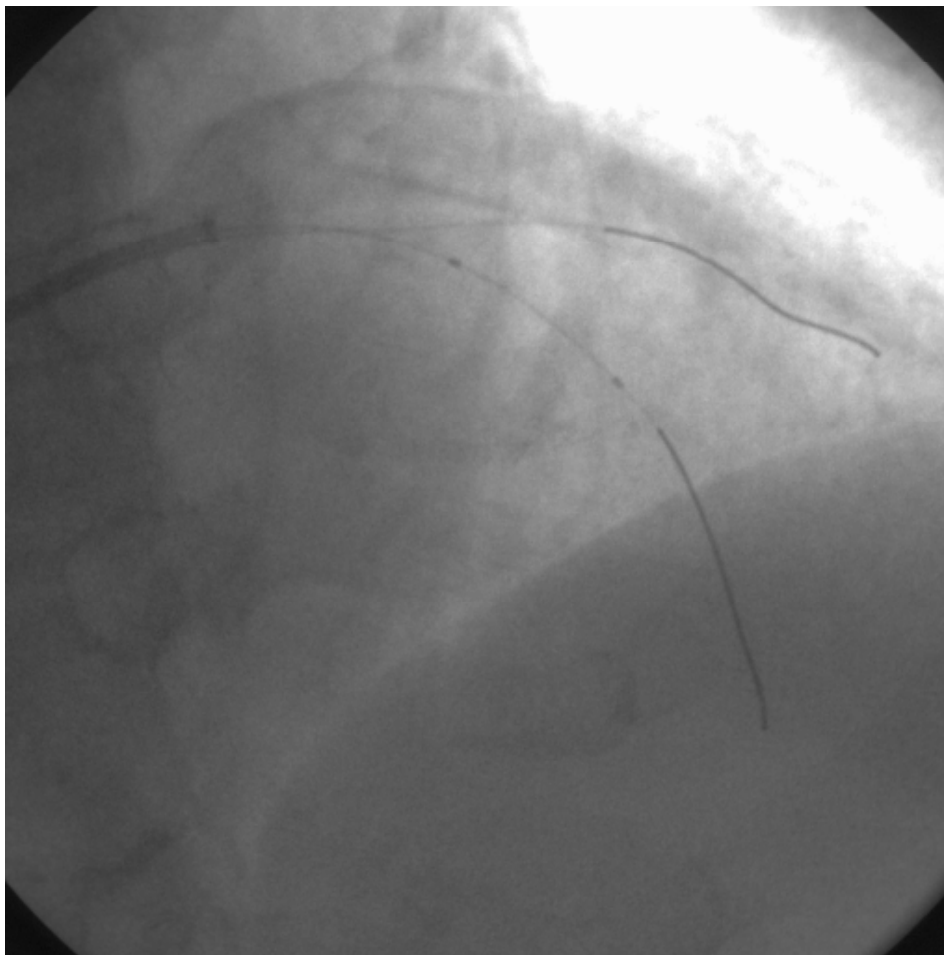
Non calcified
Non tortous



Take home message

- Be careful of using XB guiding for short LM
- Pay attention to your GUIDE. Dont be too focused on THE LESION!
- Do not LOSE your WIRES.
- Be careful when you retrieve balloon, the GUIDE can be SLIDED IN and causing injury and DISSECTION.

Pay attention to your GUIDE. Dont be too focused on THE LESION!



Take home message

- Be careful of using XB guiding for short LM
- Pay attention to your GUIDE. Dont be too focused on THE LESION!
- **Do not LOSE your WIRES.**
- Be careful when you retrieve balloon, the GUIDE can be SLIDED IN and causing injury and DISSECTION.

Take home message

- Be careful of using XB guiding for short LM
- Pay attention to your GUIDE. Dont be too focused on THE LESION!
- Do not LOSE your WIRES.
- Be careful when you retrieve balloon, the GUIDE can be SLIDED IN and causing injury and DISSECTION.

- Be careful when you retrieve balloon, the GUIDE can be SLIDED IN and causing injury and DISSECTION
Always retrieve balloon under fluoroscopy

