

Percutaneous Intervention of Unprotected Left Main Ostial and Shaft Disease

Technical feasibility and Clinical outcomes

Seung-Jung Park, MD, PhD, FACC

**Professor of Internal Medicine
Asan Medical Center, *Seoul, Korea***

Subject 268 Patients
(M/F=188/80, Age: 55years)

- Elective Stenting in Patients with Normal LV function 216
- Follow-up angiogram at 6 month 157/184 (85%)

2002 AMC

Inclusion Criteria

- Good Candidate for Surgery
(Diameter stenosis $\geq 50\%$ involving both a LMCA and/or the ostium of LAD or LCX with Objective Ischemia)
- Normal LV function

Unprotected Left Main Stenting

How do we do ?

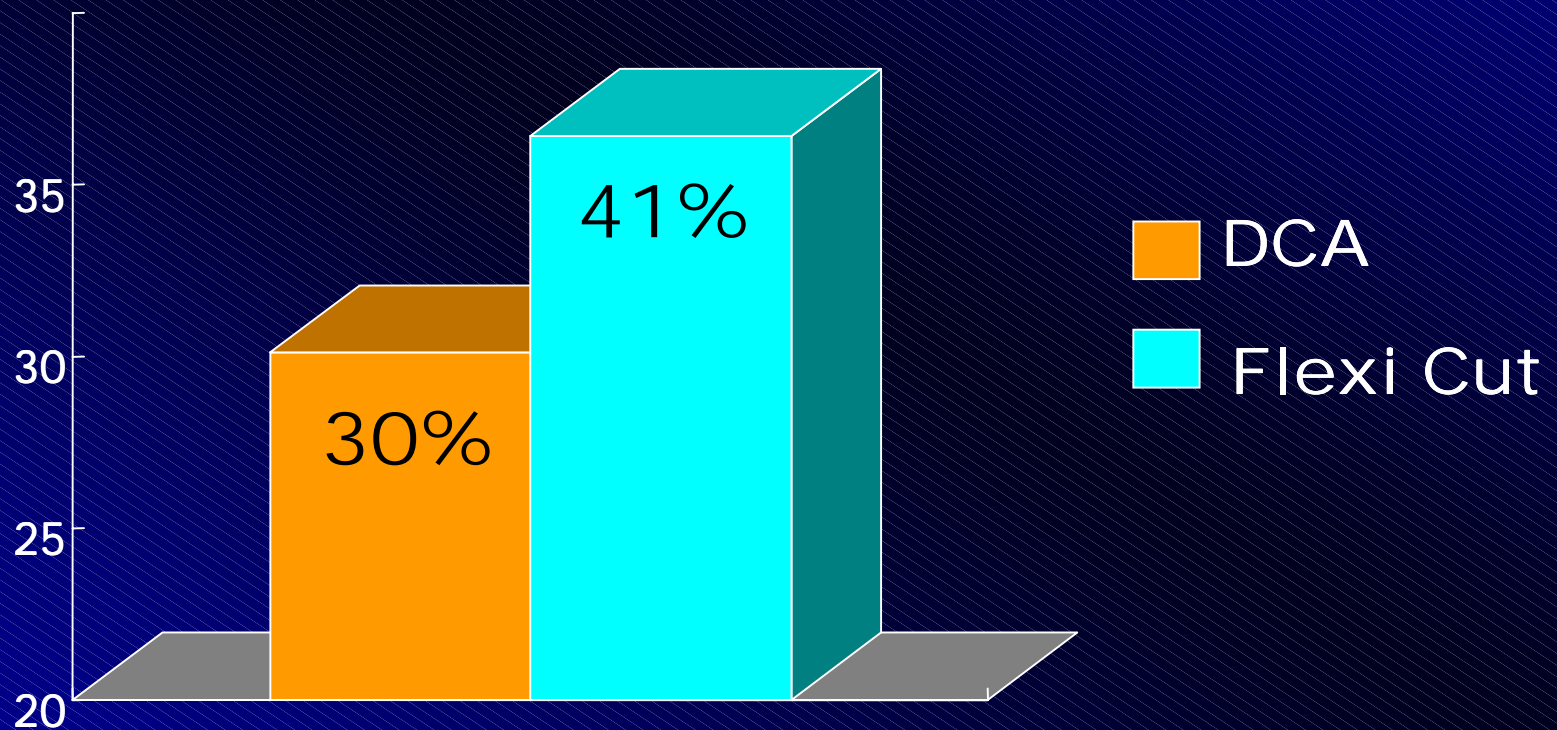
- Ostial lesion

- 1. We should consider IVUS first before the procedure**
- 2. Negative remodeling is common finding in ostial lesion (65%)**
- 3. About 20% of cases should be needed second high pressure optimization**

Unprotected Left Main Stenting

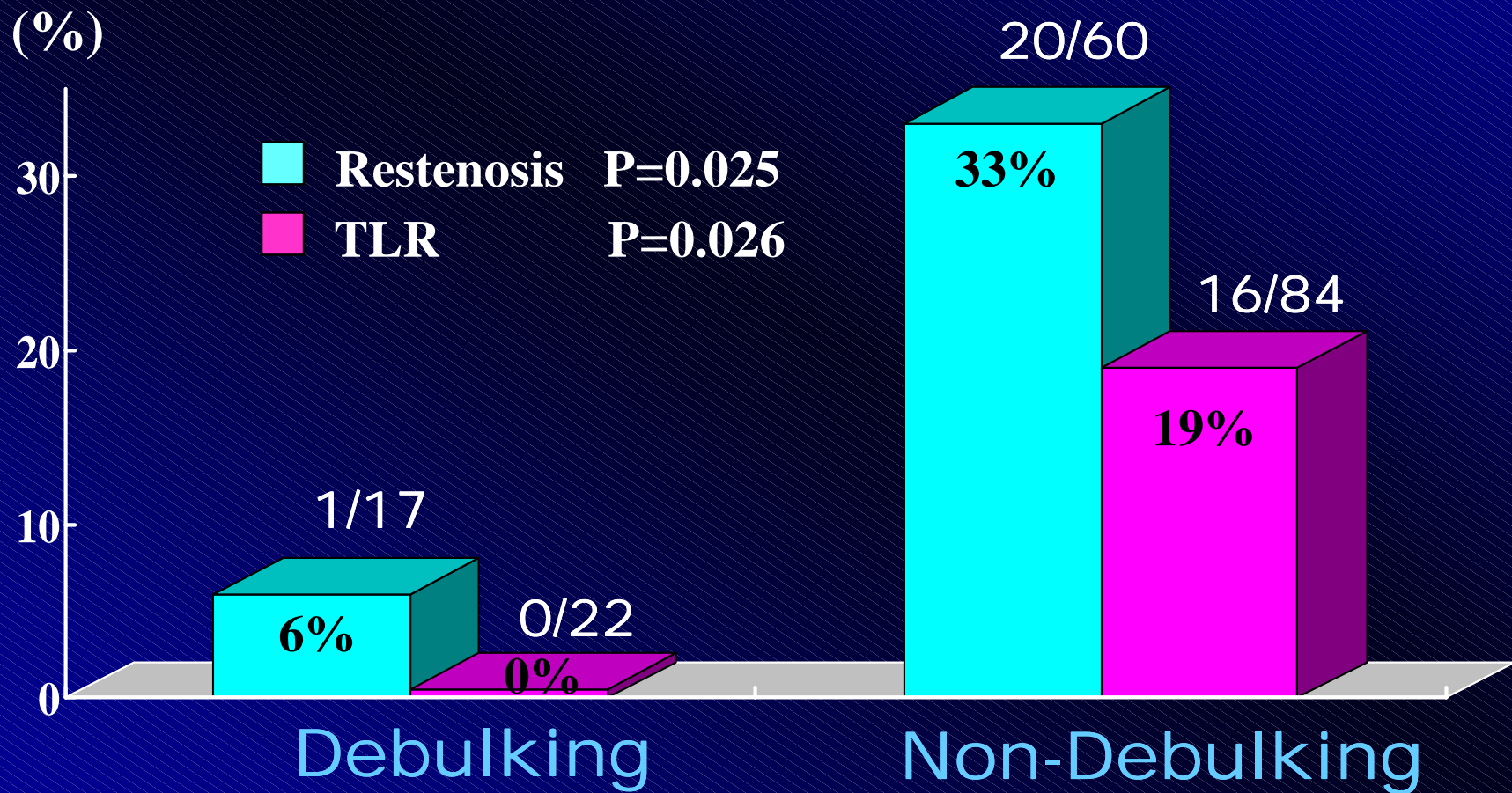
4. We prefer DCA as a debulking...

Reduction of Plaque Burden



Unprotected Left Main Stenting

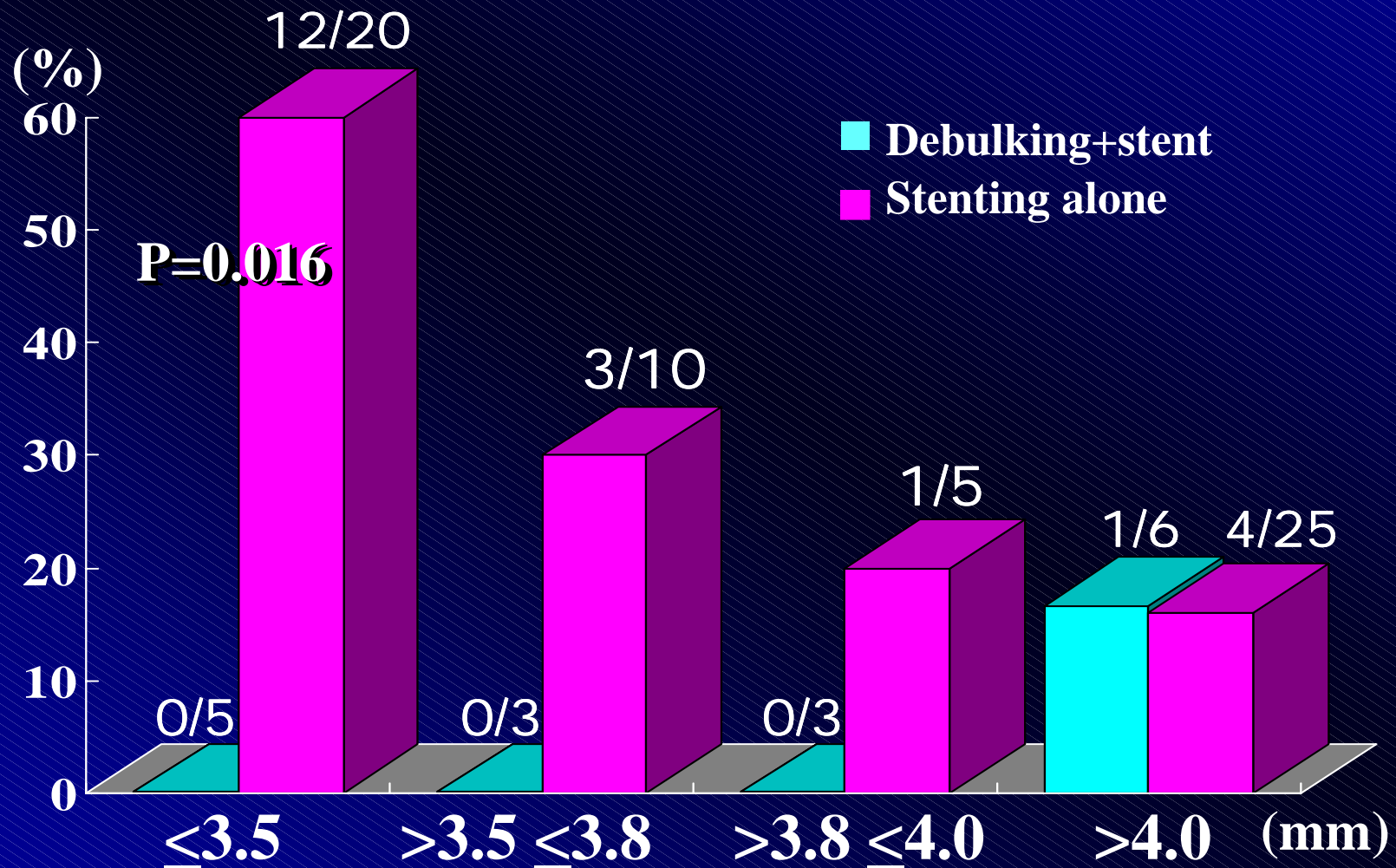
Restenosis Rate & TLR at Ostial lesion



Restenosis Rate

according to reference vessel size

Ostial lesion



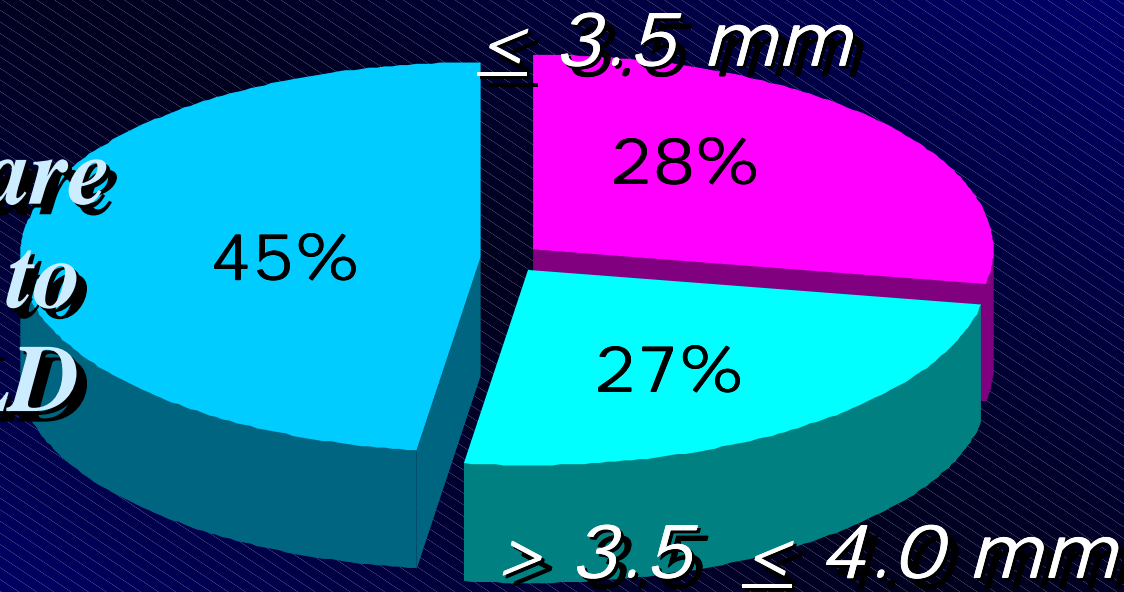
Based on the data

Debulking is....

Definitely beneficial


> 4.0 mm

• *Large vessels are usually enough to obtain a big MLD using stenting alone without debulking*

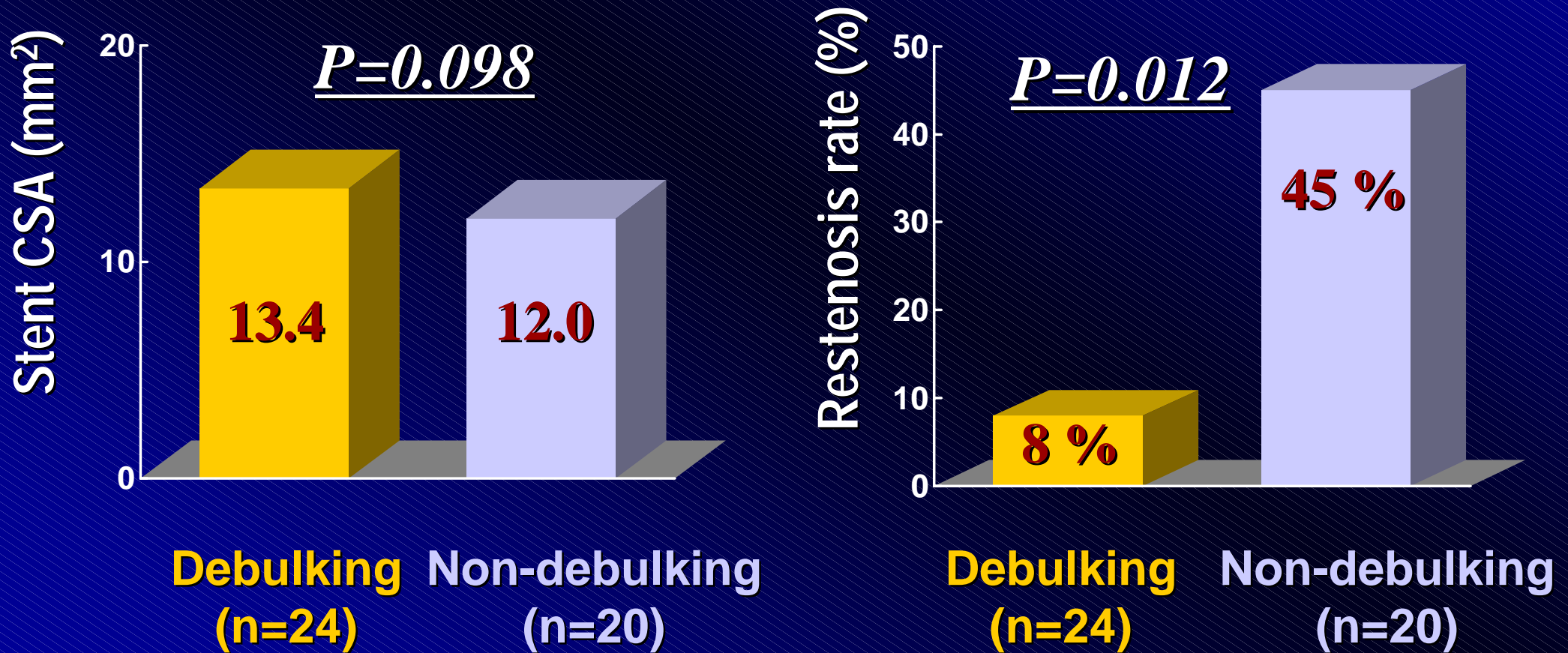


Seems to be beneficial

The effect of debulking in negative remodeling group



The effect of debulking in non-negative remodeling group



Unprotected Left Main Stenting

How do we do ?

- Shaft lesion

Unprotected Left Main Stenting

Restenosis Rate & TLR at overall

