

# *Recurrent cardiac chloroma presenting as acute chest pain*

Seoul St. Mary's Hospital

Mineok Chang



# Case

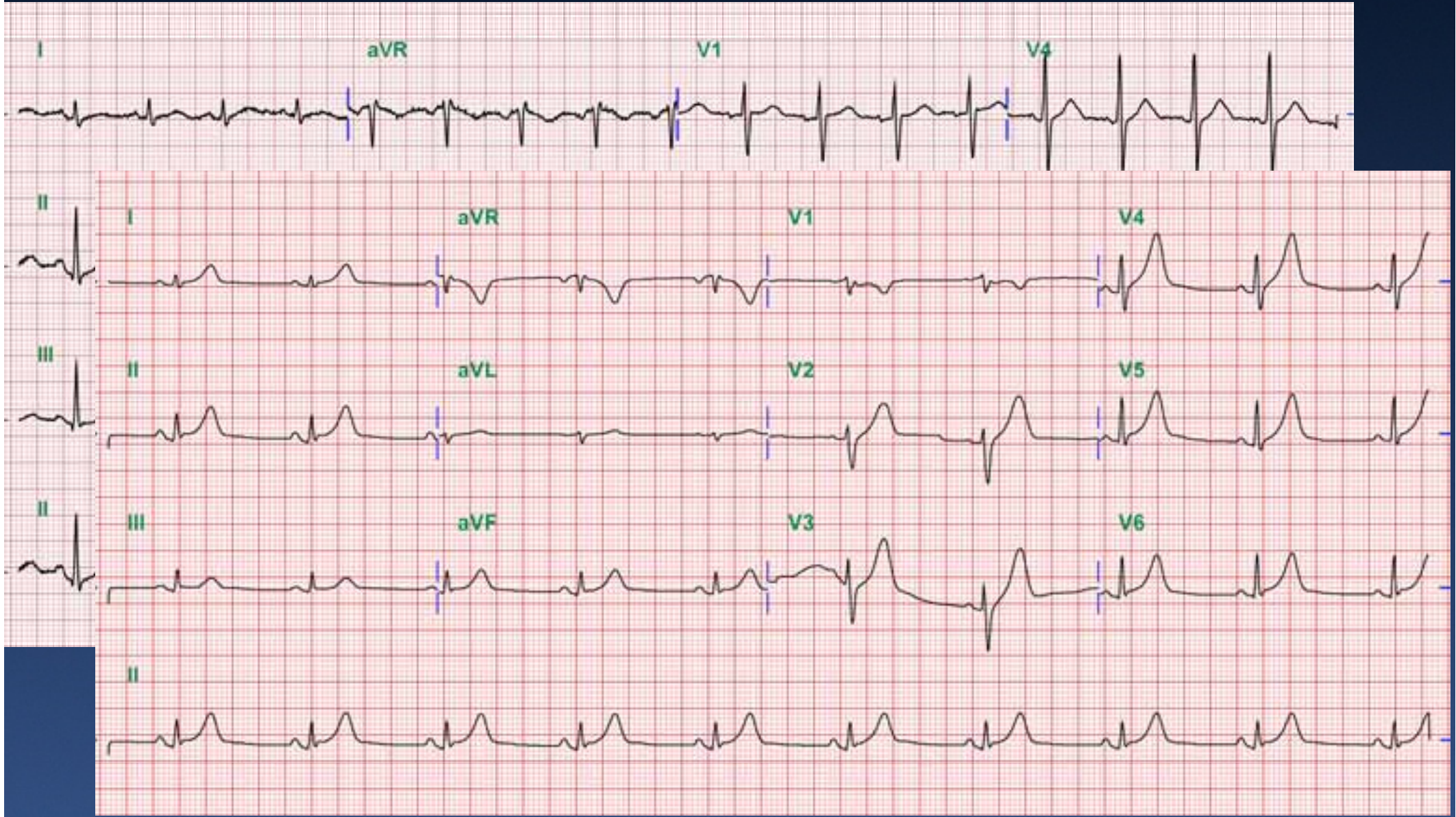
- 41/M
- C/C : Chest tightness during sleeping for 3 hours
- P/Hx : DM/HTN/TBc/Hepatitis (-/-/-/-)

Imatinib, Dasatinib

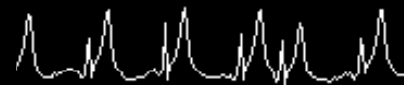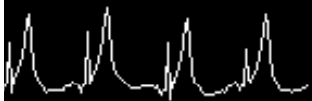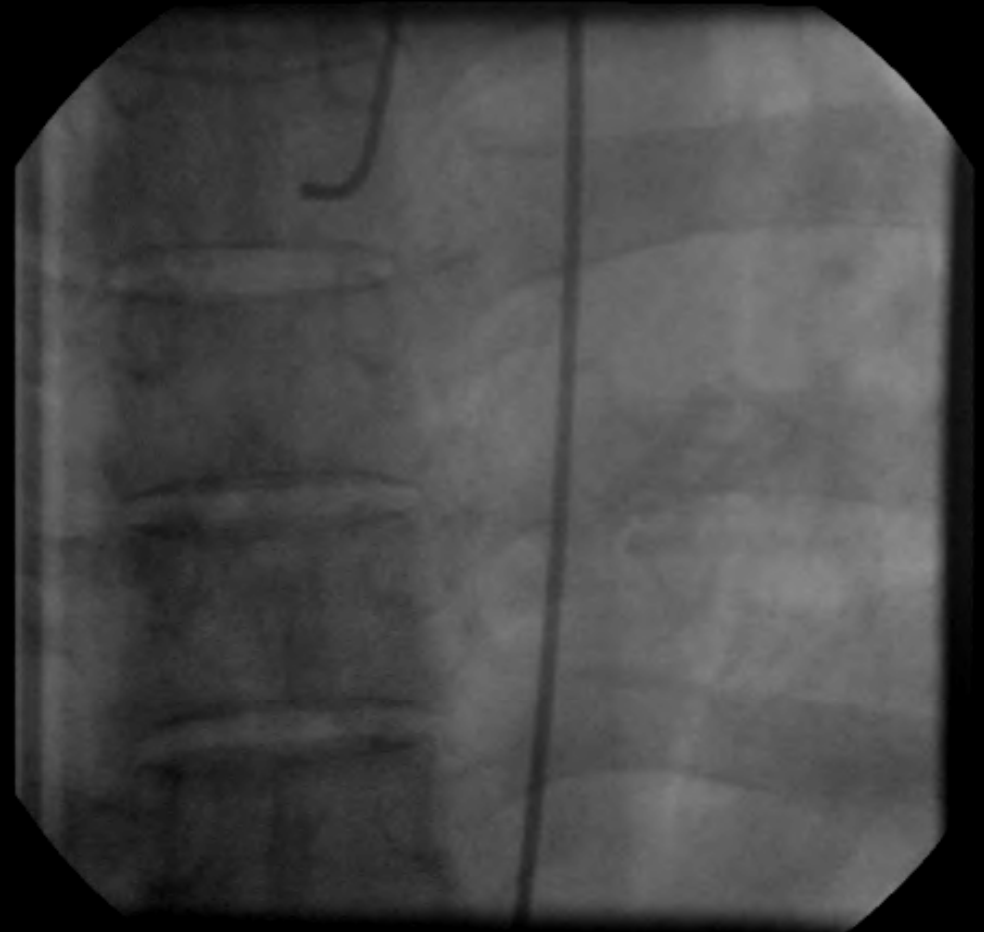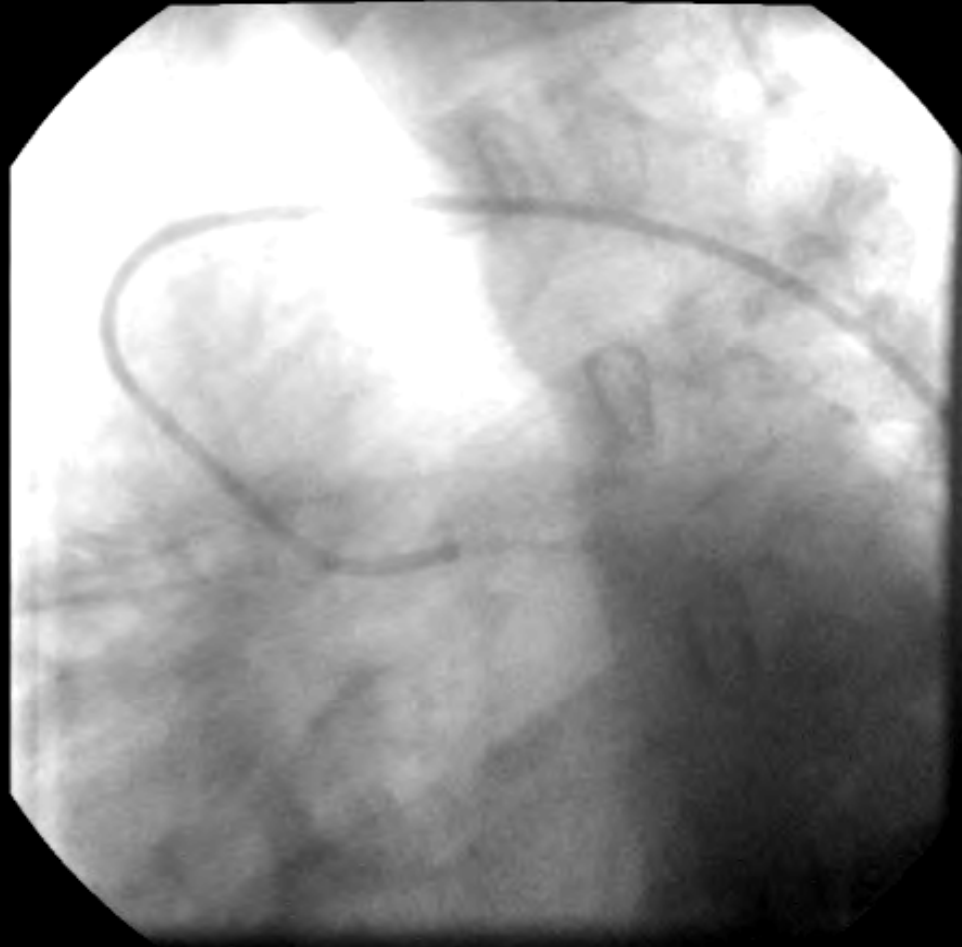s/p alloPBSCT d/t CML



# Electrocardiography



# *Coronary Angiography*





# Echocardiography (Initial)

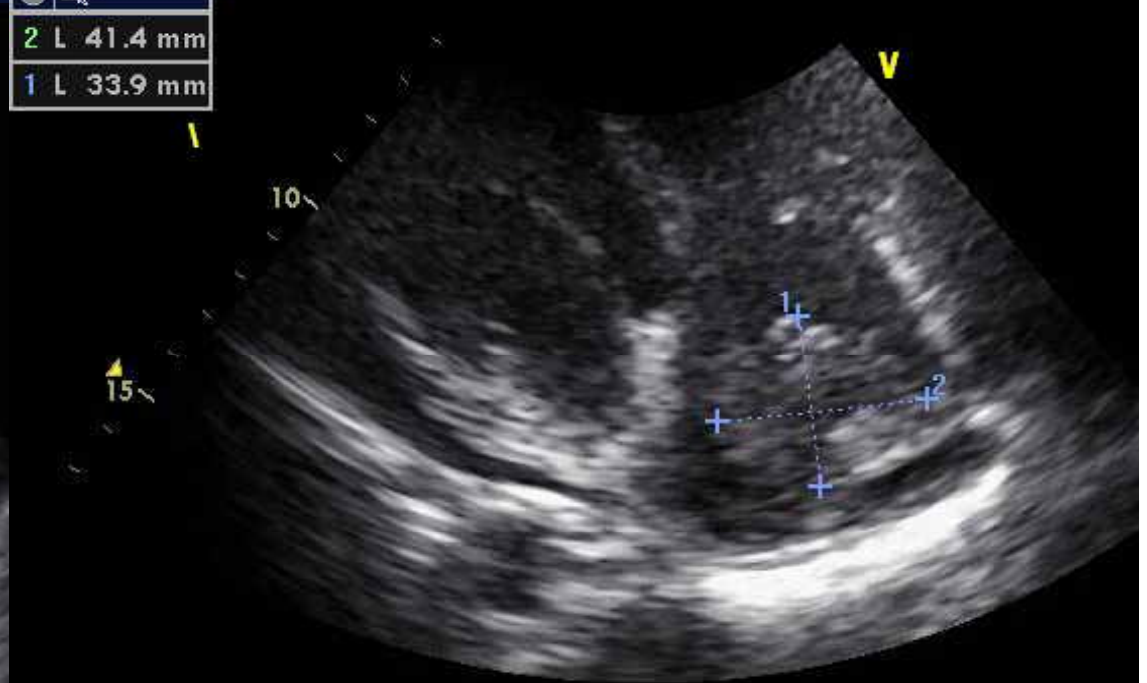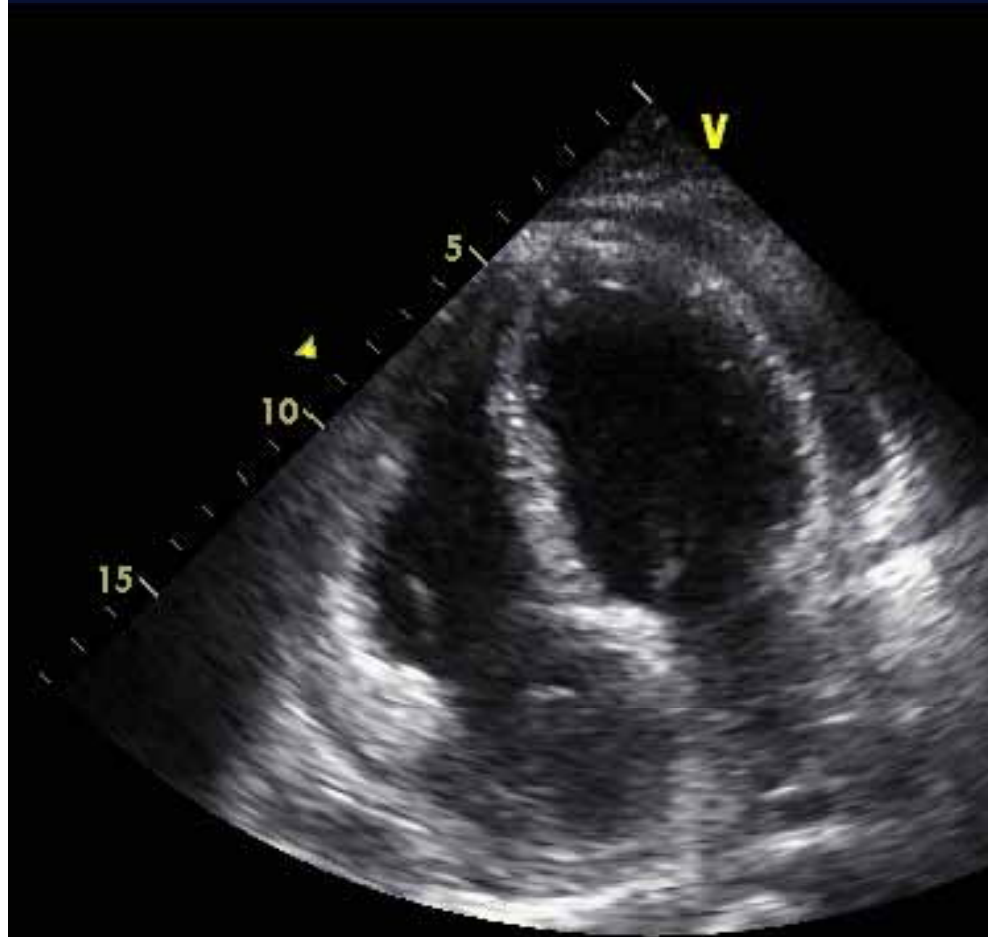PARK JEONG HO  
19728674, 24/09/1970

Seoul St. Mary's Hos  
06/02/2012 10:30:41

PARK JEONG HO  
19728674, 24/09/1970

Seoul St. Mary's Hosp. M4S  
06/02/2012 10:51:44 ADM Cardiac

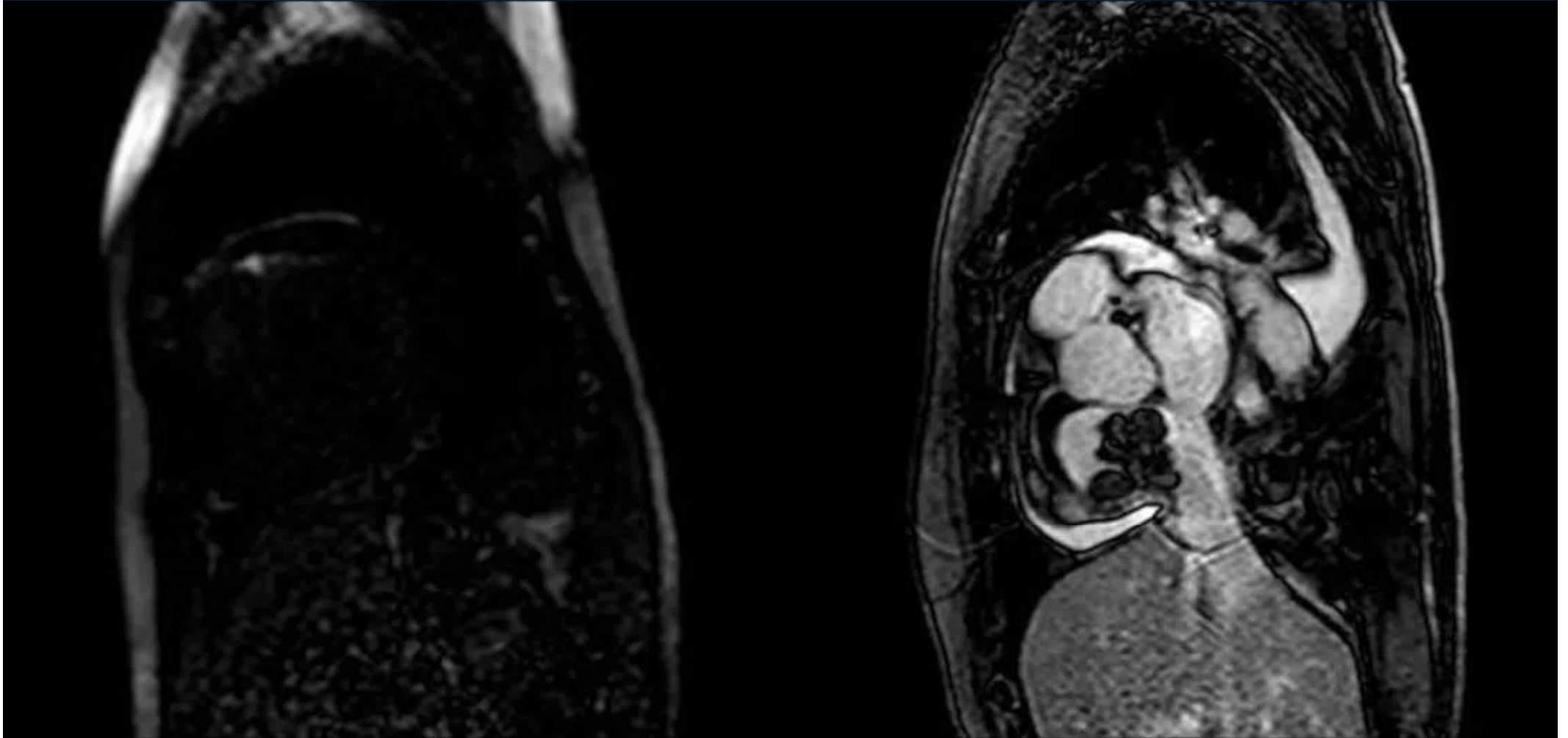
●	■
2 L	41.4 mm
1 L	33.9 mm



53  
HR



# *Cardiac Magnetic Resonance*

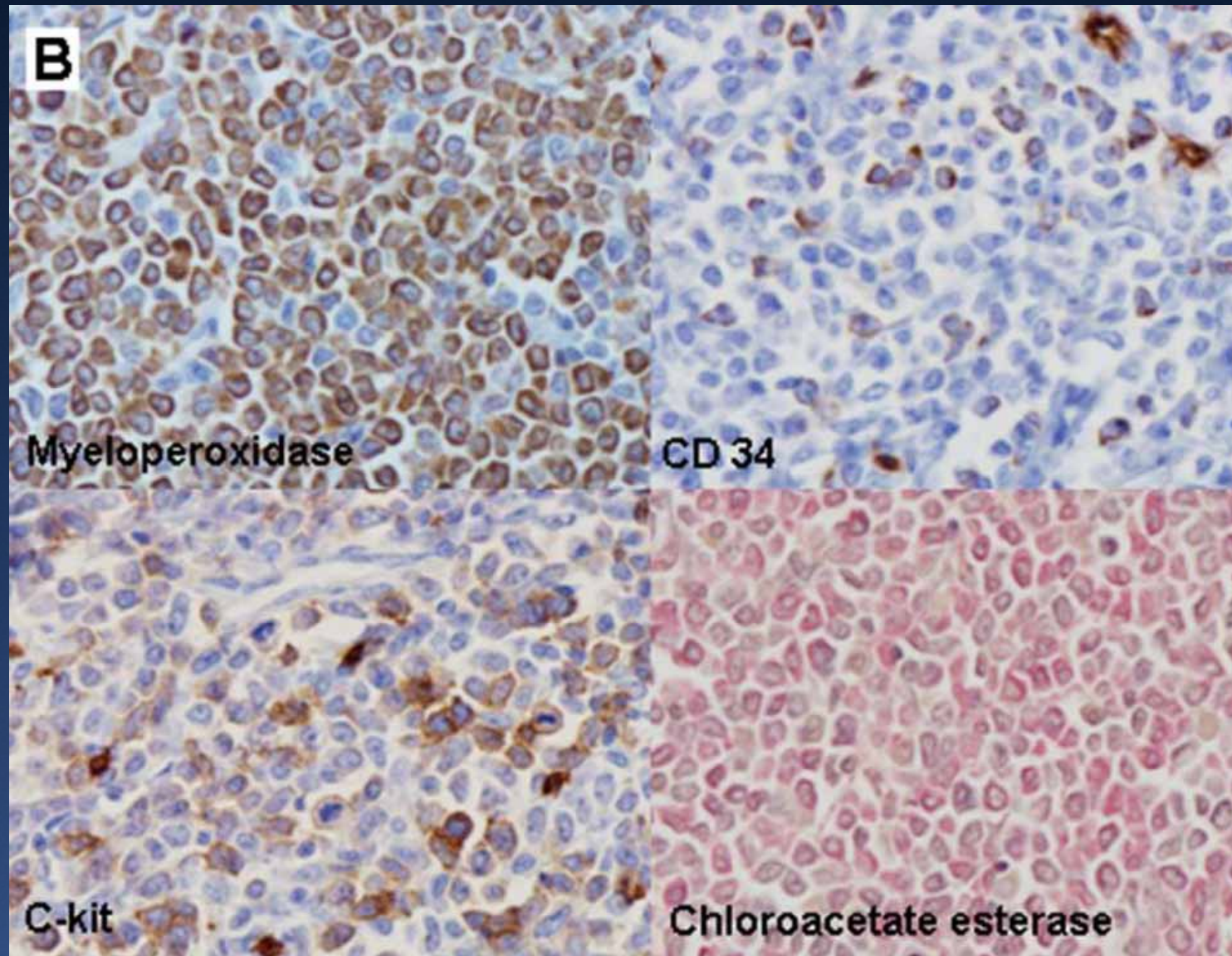


Perfusion

LGE



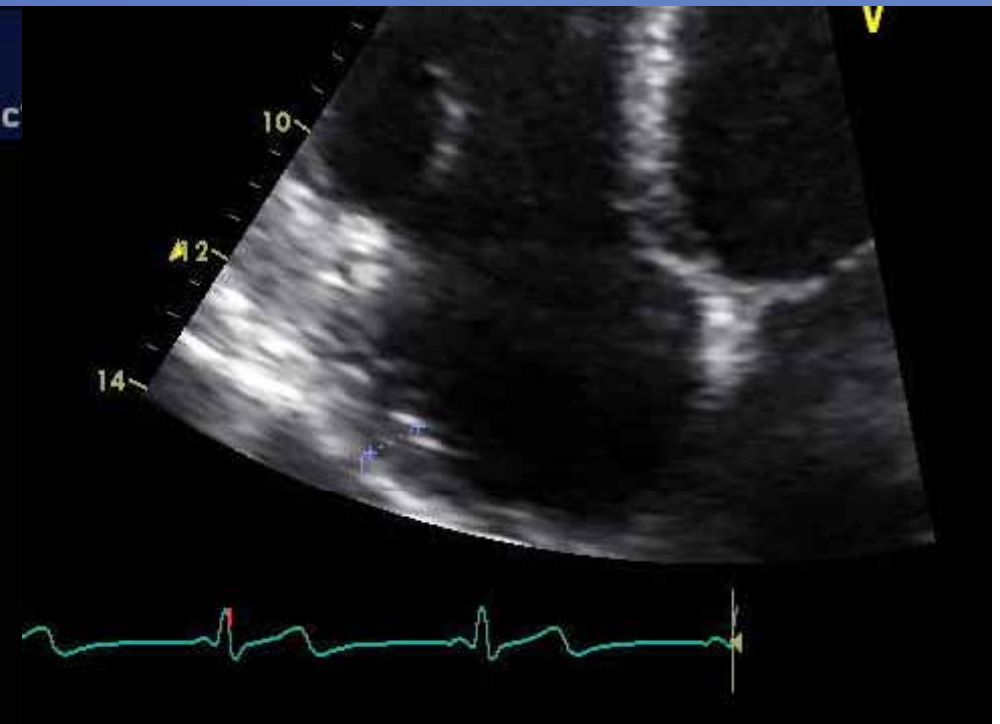
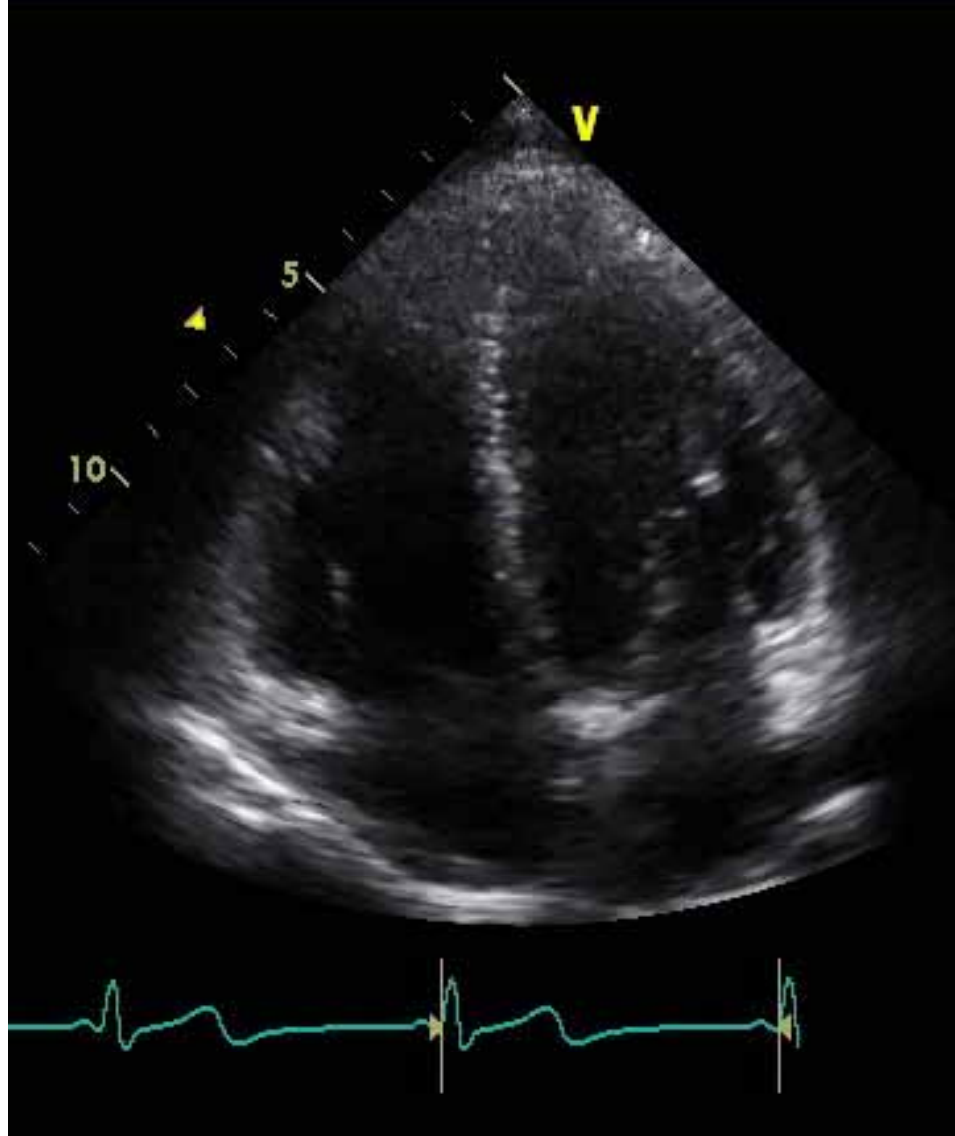
# Pathology



# Echocardiography (Post op. 1m)

ONG HO  
24/09/1970

Seoul St. Mary's Hosp. M4S  
14/02/2013 13:43:16 ADM Cardiac



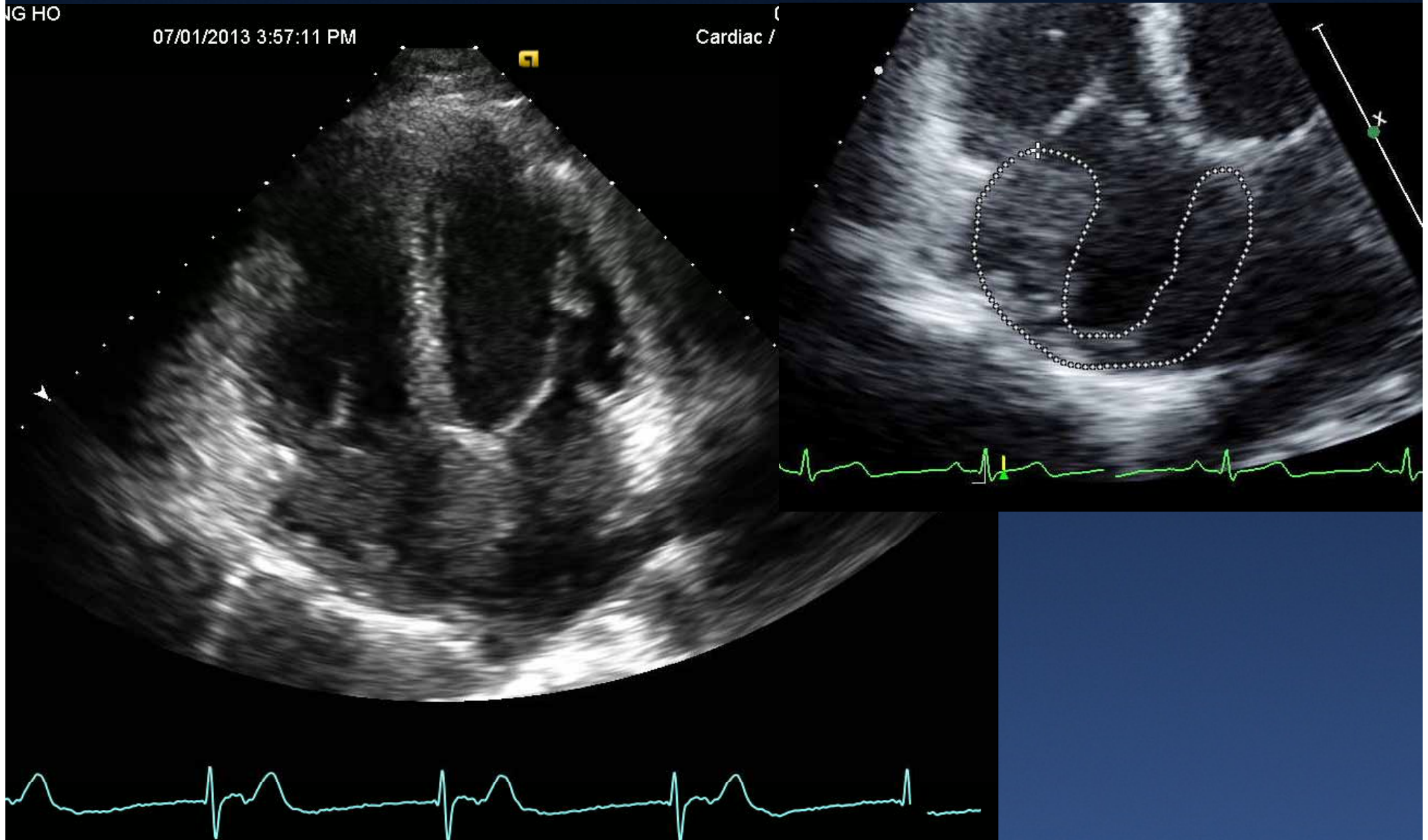


# Echocardiography (Post op. 17m )

IG HO

07/01/2013 3:57:11 PM

Cardiac /



# *Discussion point*

- Hematology's decision
  - Increased dose of Dasatinib
  - Echocardiography f/u
  
- Cardiology's recommendation
  - Stress CMR
  - Coronary angiography f/u, check CFR
  - Coiling of feeding vessel



# Echocardiography (Post op. 21m)

PARK JEONG HO  
19728674

2013/11/13 05:42:12PM TIS0.9  
S5-1/ECHO

