

Renal Artery Stenosis and Abdominal Aortic Aneurysm

DR. Rabin Chakraborty

MD, DNB, FRCP(London), FRCP(Glasgow), FICC, FISE, FCSI, DM
(Cardiology)

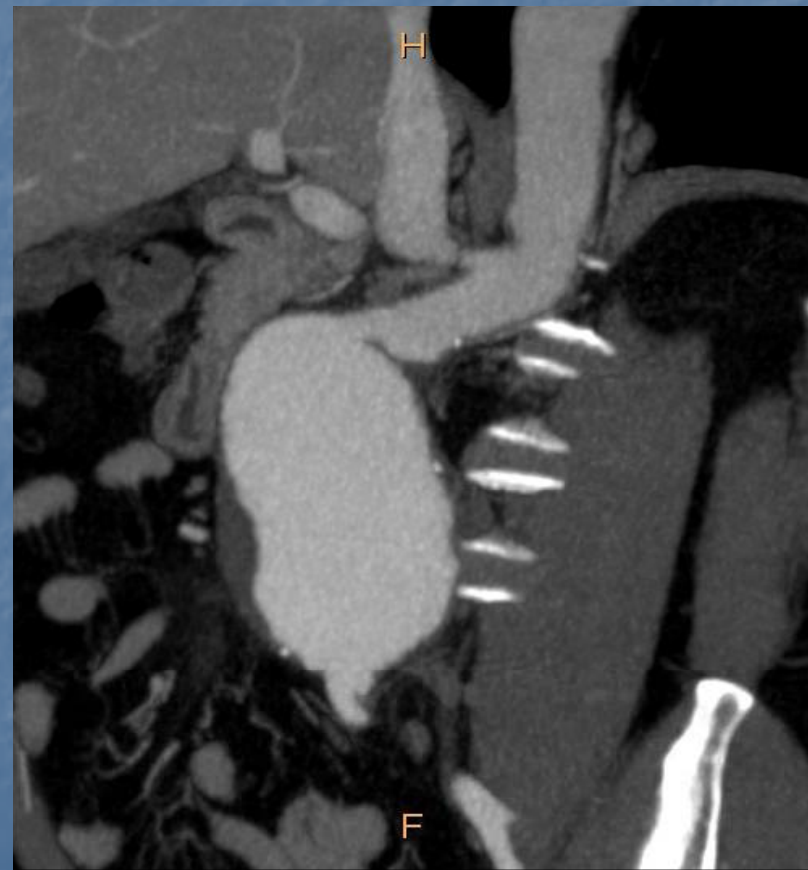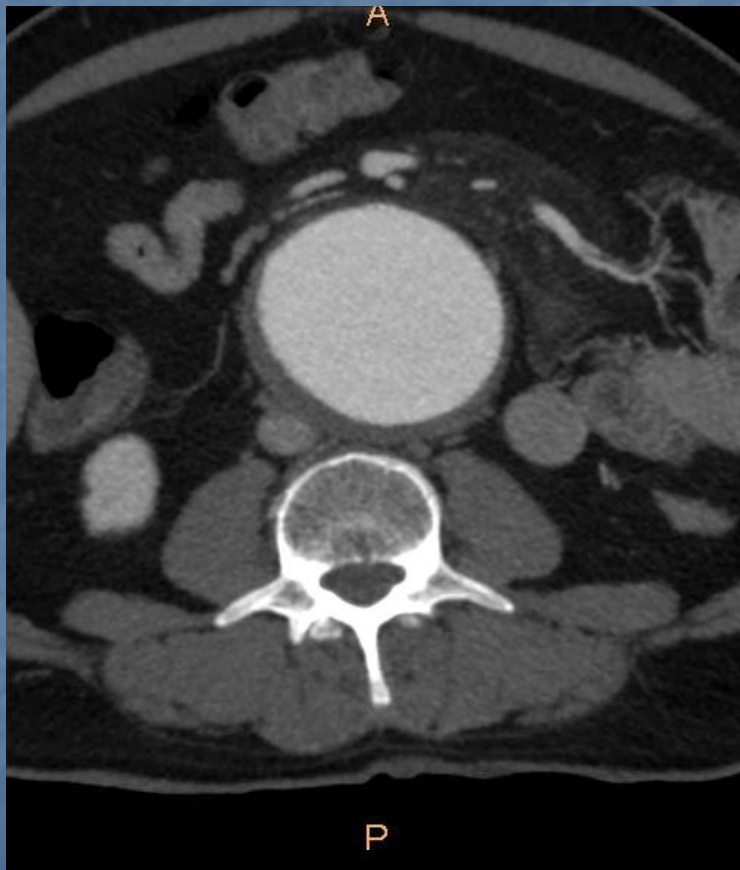
Director and Head , Senior Consultant Interventional cardiologist
Apollo Gleneagles Heart Institutes, Kolkata, INDIA

- DKS 62 yrs / Male
- Hypertension, Euglycemic, Heavy smoker
- C/C: Abdominal pain (dull aching) for last 2-3 months.

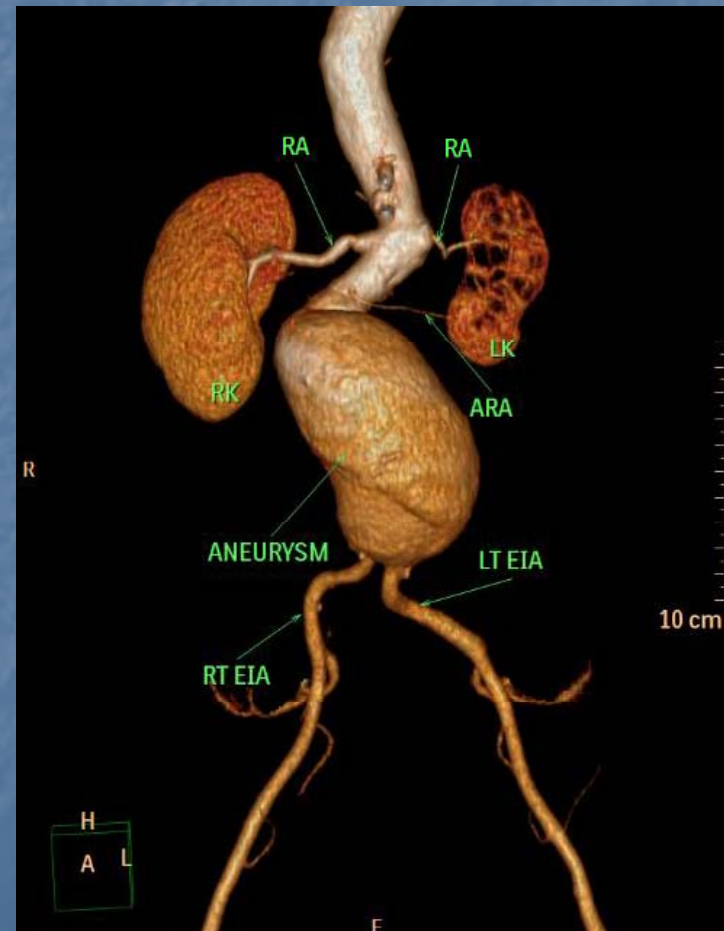
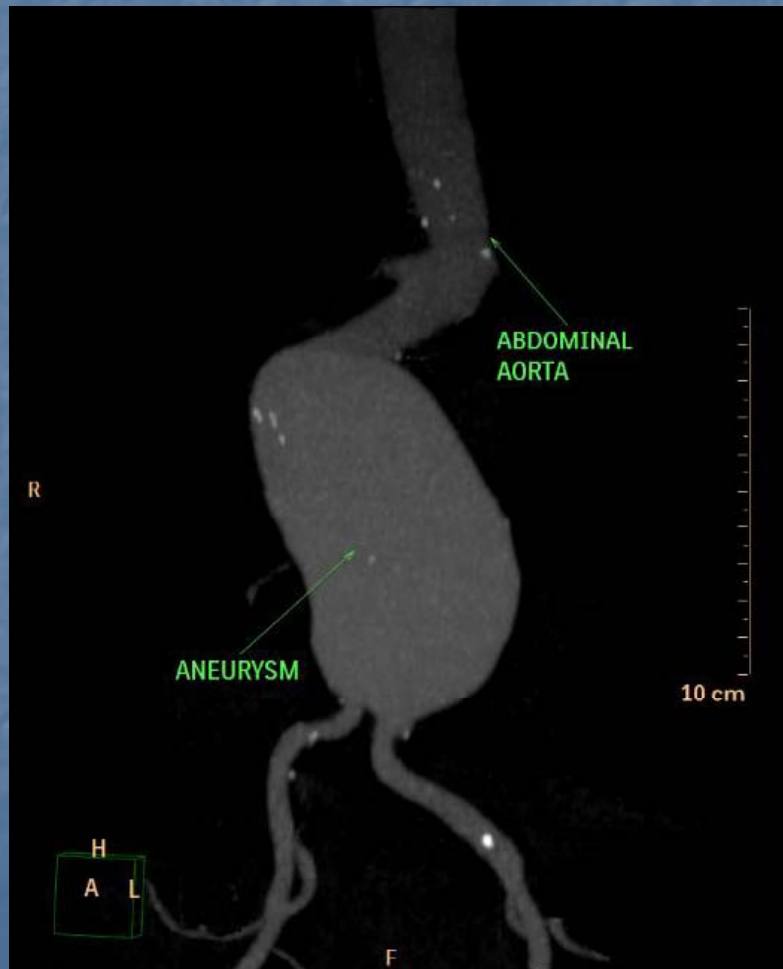Prominent pulsation in lower abdomen for same duration.

- Clinical examination revealed large pulsatile mass in left lower abdomen.
- No Hx of Angina

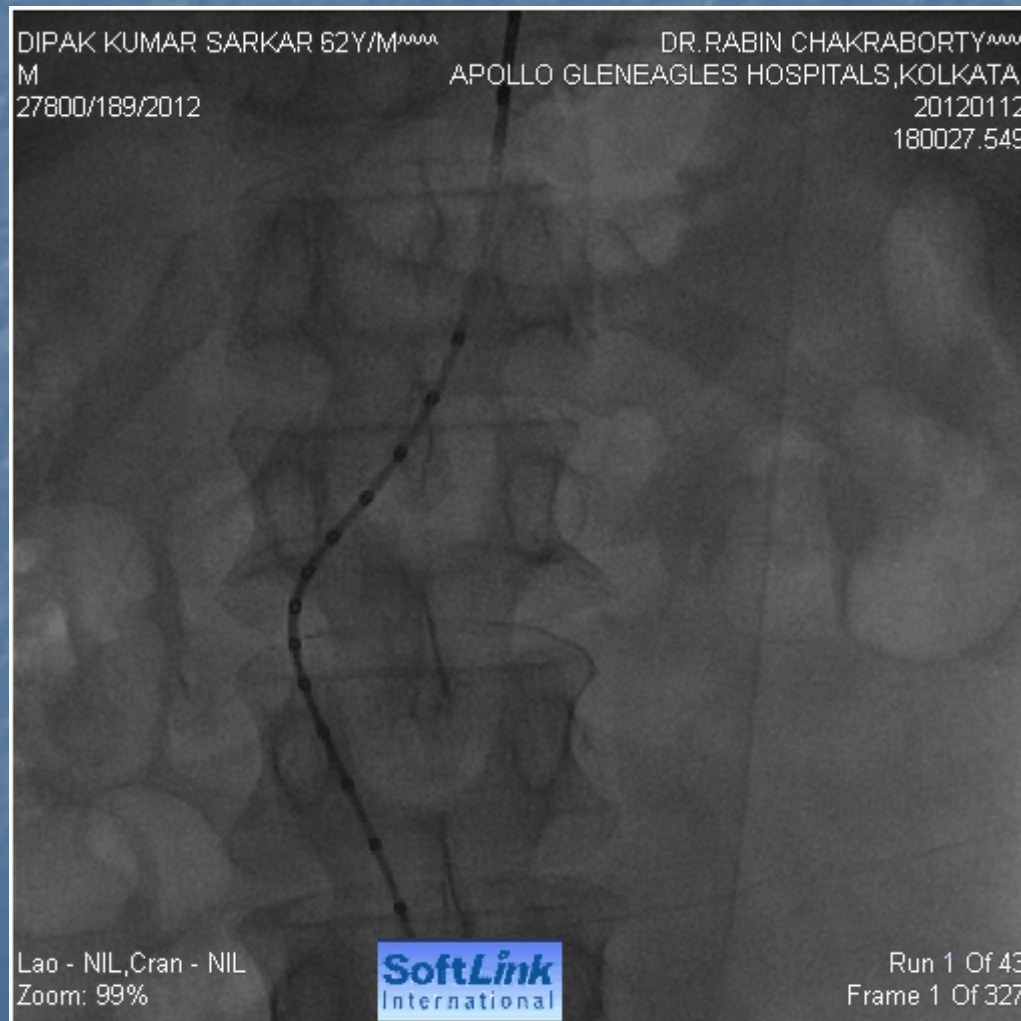
Contrast enhanced CT scan shows large (10.5×6.5 cm) infrarenal aortic aneurysm



Contrast enhanced CT scan shows large (10.5×6.5 cm) infrarenal aortic aneurysm



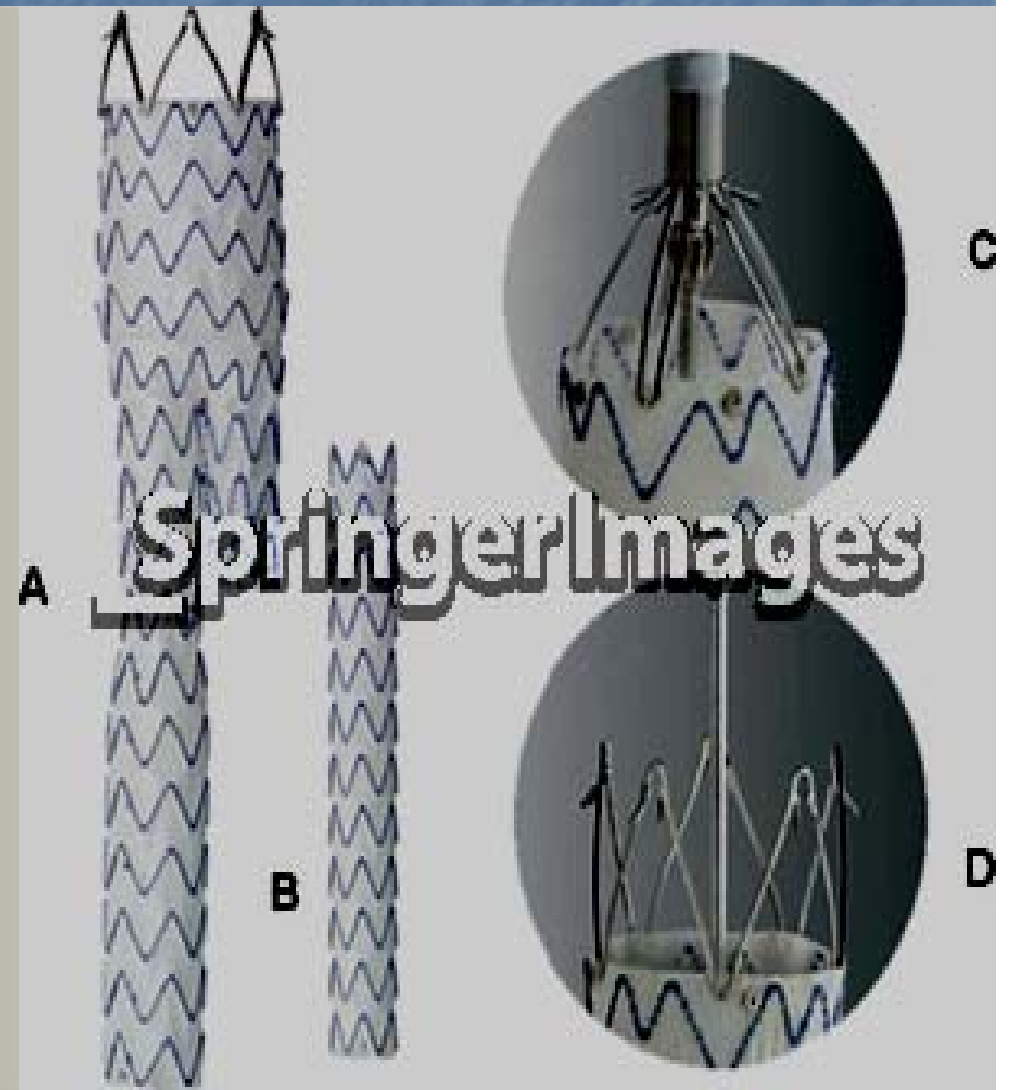
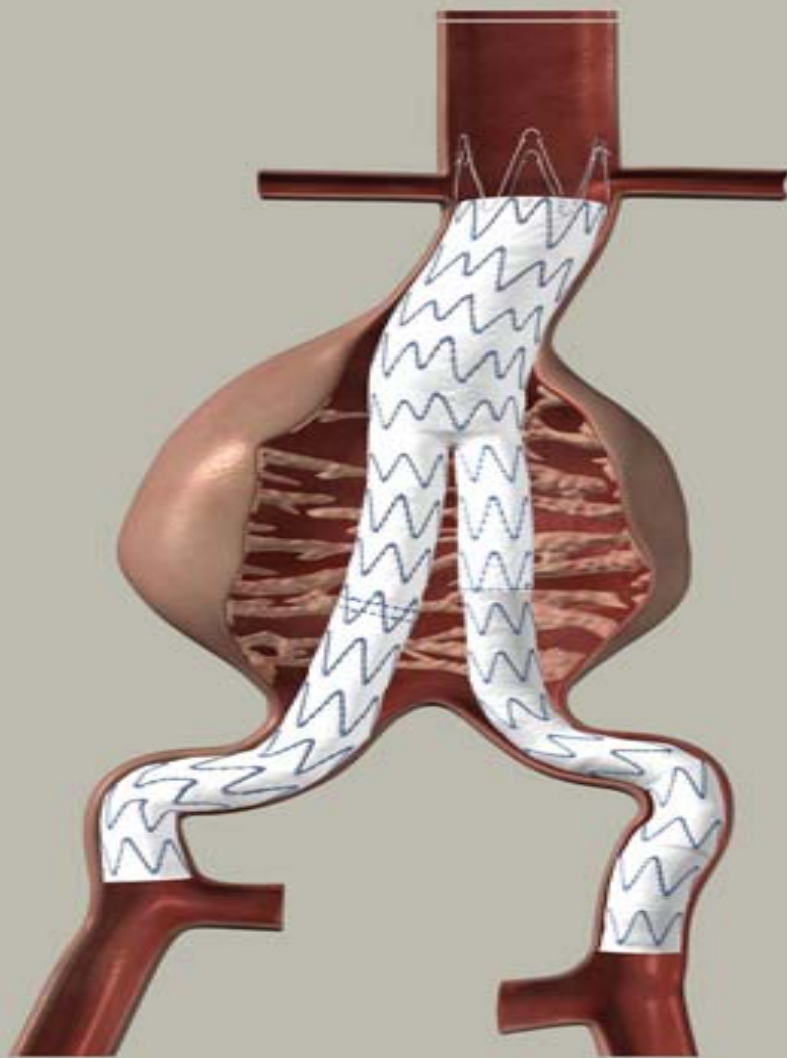
Abdominal aortogram shows large infrarenal aneurysm with right renal artery stenosis



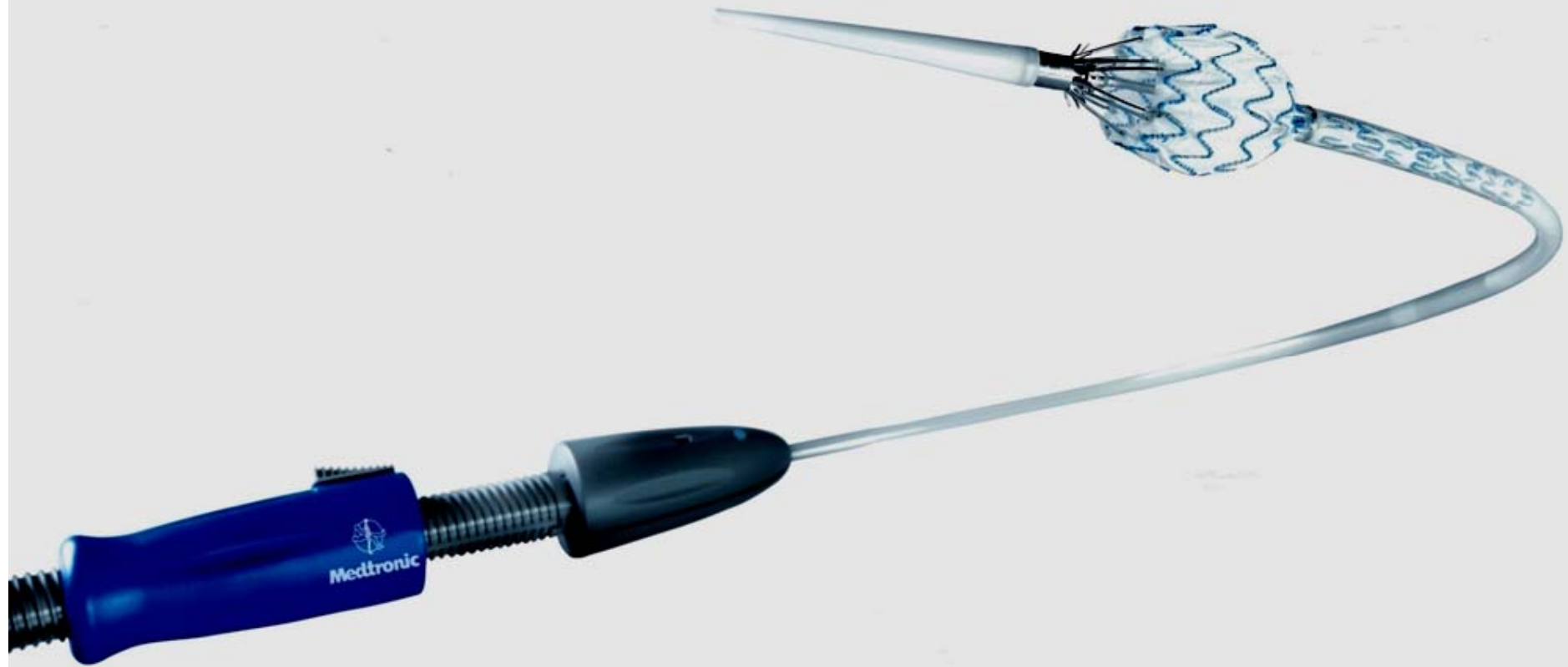
PLAN

- Right renal angioplasty
- Main body of the abdominal aortic bifurcated stent graft from left femoral artery
- Contra-lateral limb from right femoral artery
- We selected AAA stent graft from Medtronic (Endurant stent graft)

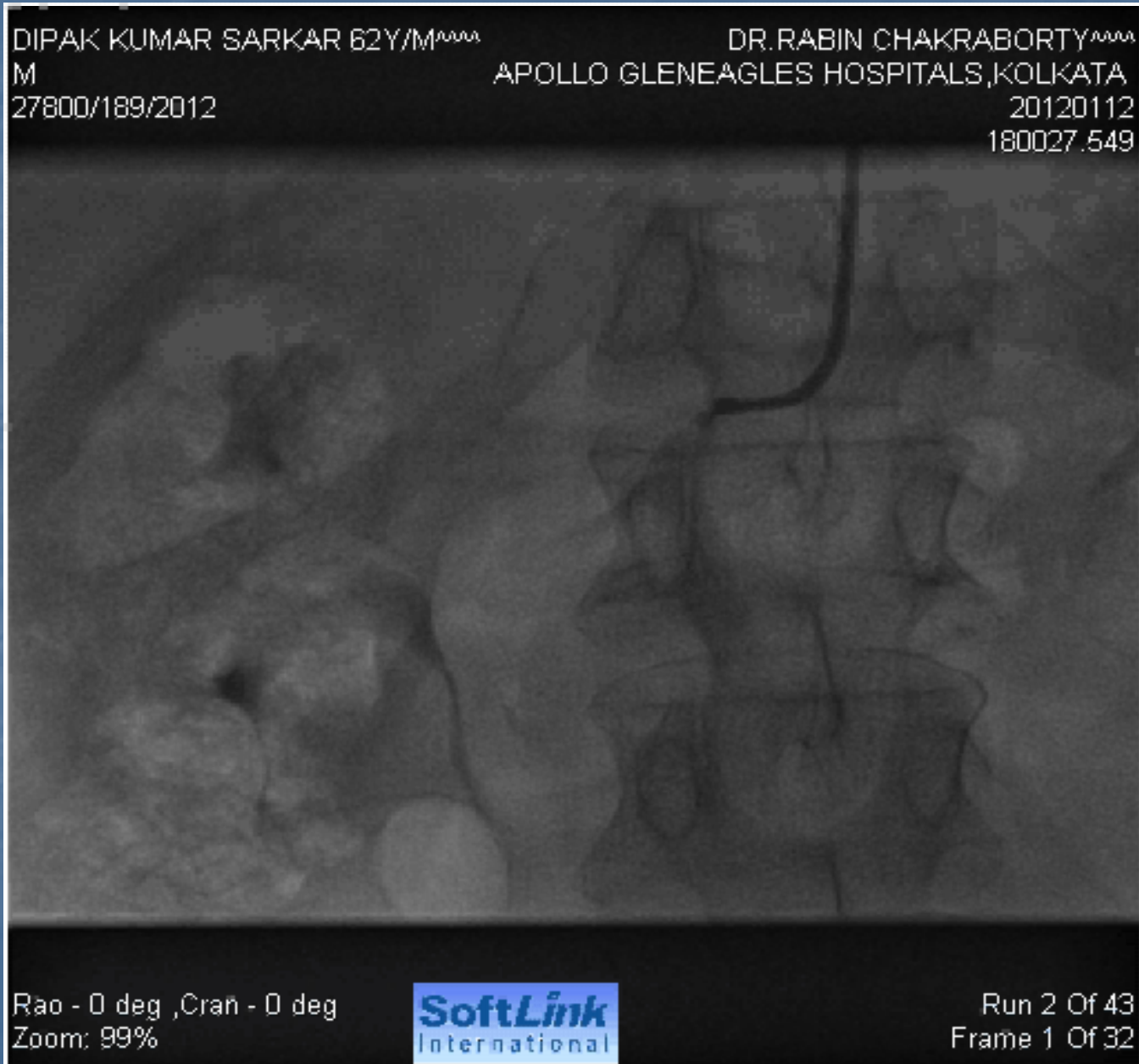Endurant bifurcated stent graft



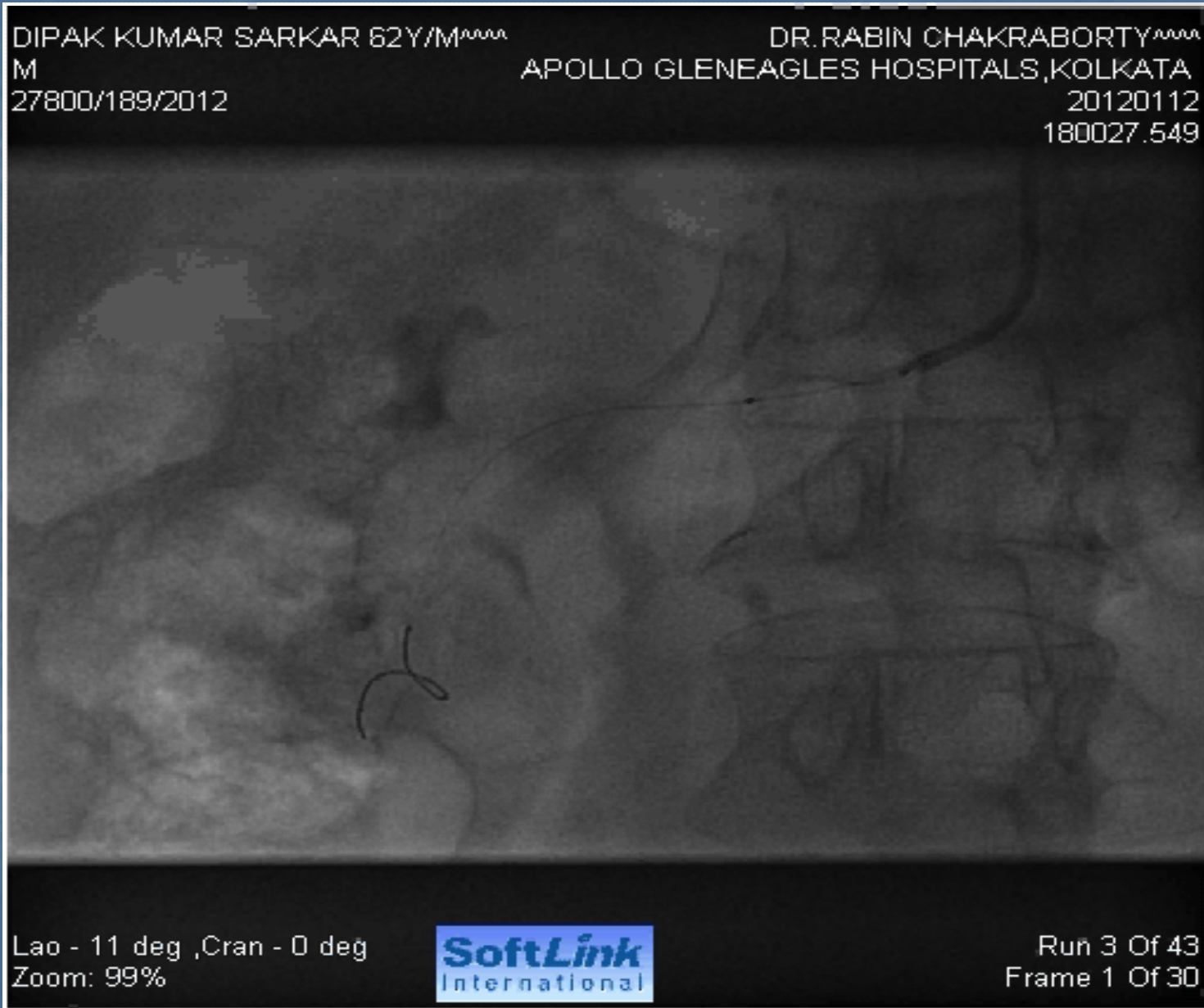Endurant stent graft



Left radial approach, 6F JR3.5, BMW wire, balloon 4.0 × 15 mm



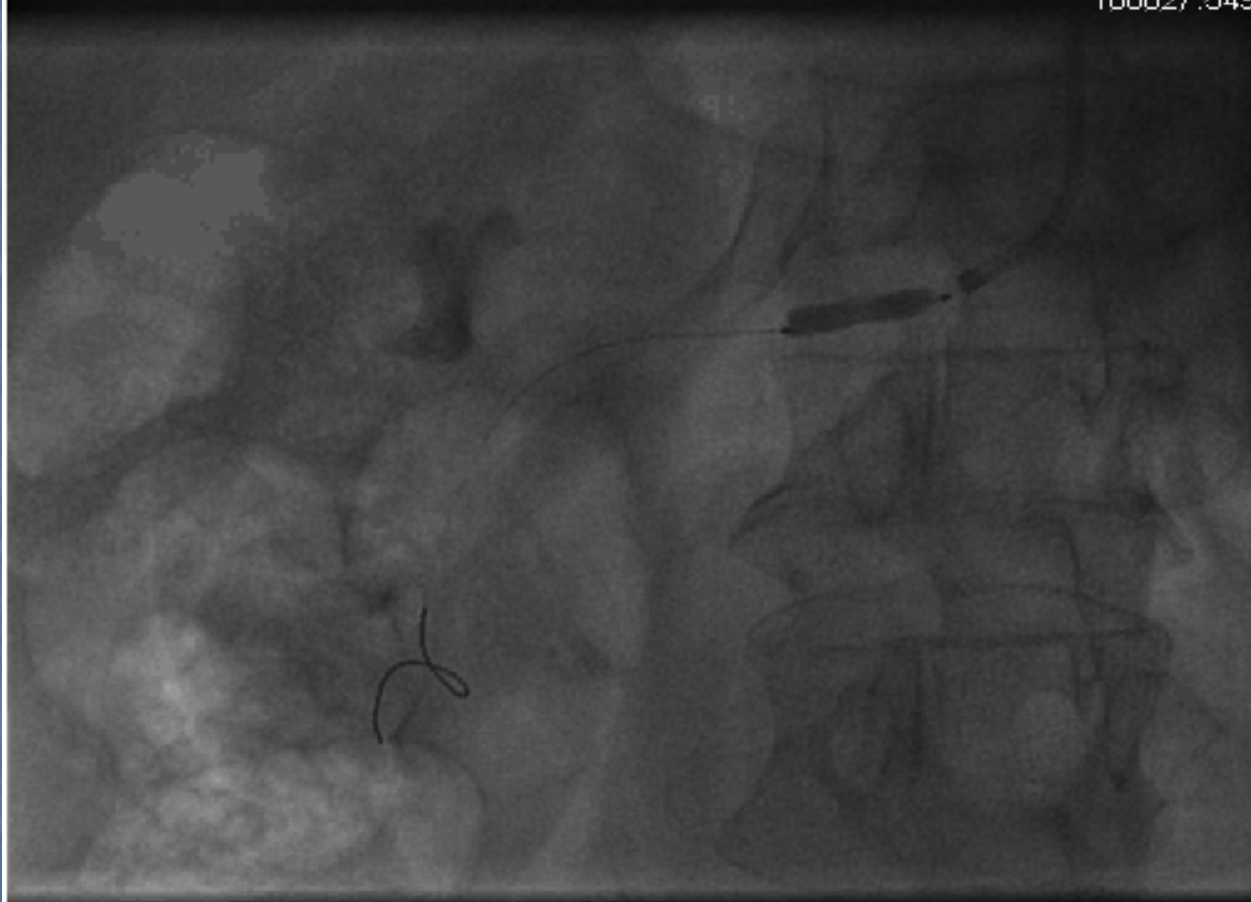Right Renal Angioplasty from Left Radial Artery



Balloon Dilatation

DIPAK KUMAR SARKAR 62Y/M
M
27800/189/2012

DR. RABIN CHAKRABORTY
APOLLO GLENEAGLES HOSPITALS, KOLKATA
20120112
180027.549



Lao - 11 deg ,Cran - 0 deg
Zoom: 99%

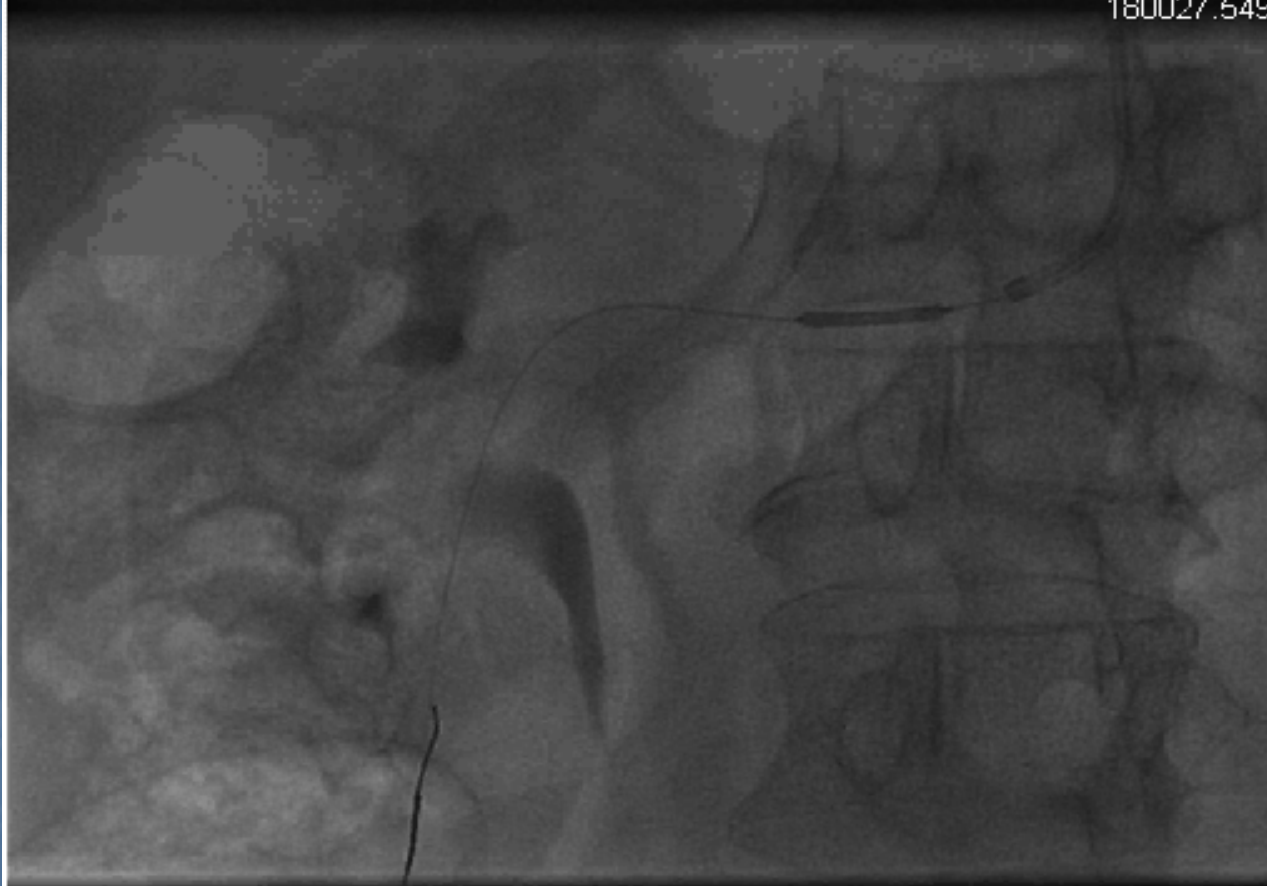
SoftLink
International

Run 4 Of 43
Frame 1 Of 33

Hippocampus 7.0×15 mm

DIPAK KUMAR SARKAR 62Y/M
M
27800/189/2012

DR. RABIN CHAKRABORTY
APOLLO GLENEAGLES HOSPITALS, KOLKATA
20120112
180027.549



Lao - 11 deg ,Crân - 0 deg
Zoom: 99%

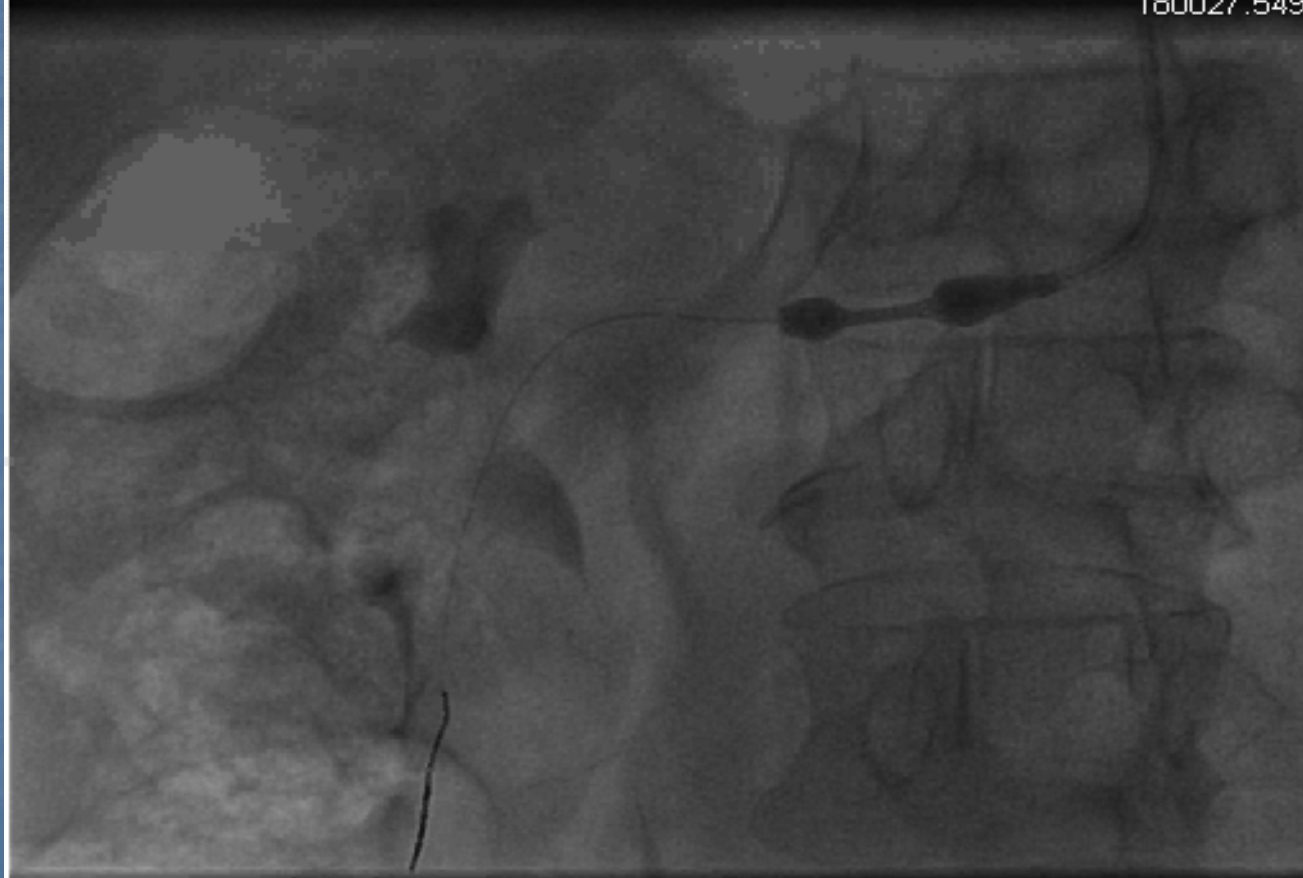SoftLink
International

Run 7 Of 43
Frame 1 Of 47

Hippocampus 7.0×15 mm

DIPAK KUMAR SARKAR 62Y/M
M
27800/189/2012

DR. RABIN CHAKRABORTY
APOLLO GLENEAGLES HOSPITALS, KOLKATA
20120112
180027.549



Lão - 11 deg ,Cran - 0 deg
Zoom: 99%

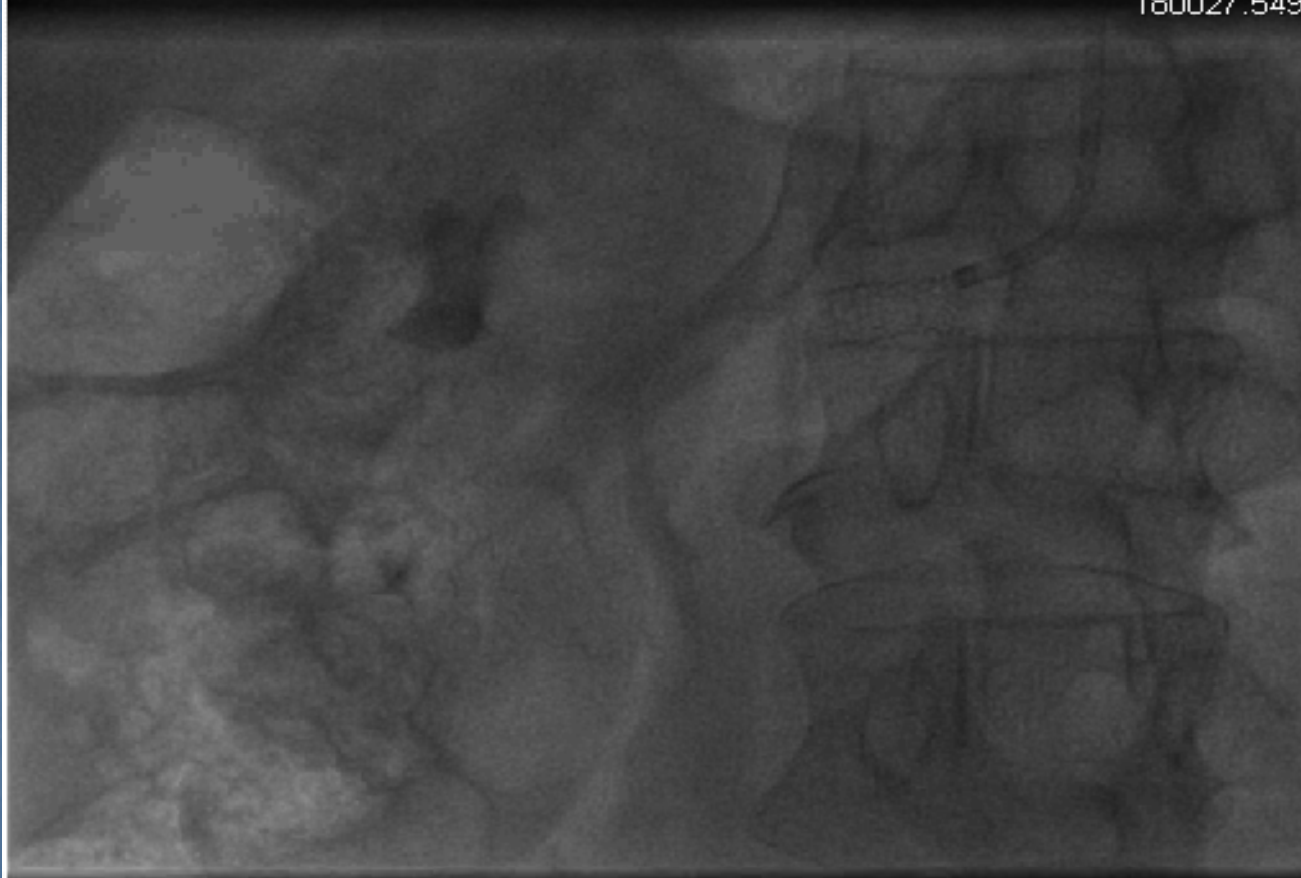
SoftLink
International

Run 8 Of 43
Frame 1 Of 168

Hippocampus 7.0×15 mm

DIPAK KUMAR SARKAR 62Y/M
M
27800/189/2012

DR. RABIN CHAKRABORTY
APOLLO GLENEAGLES HOSPITALS, KOLKATA
20120112
180027.549

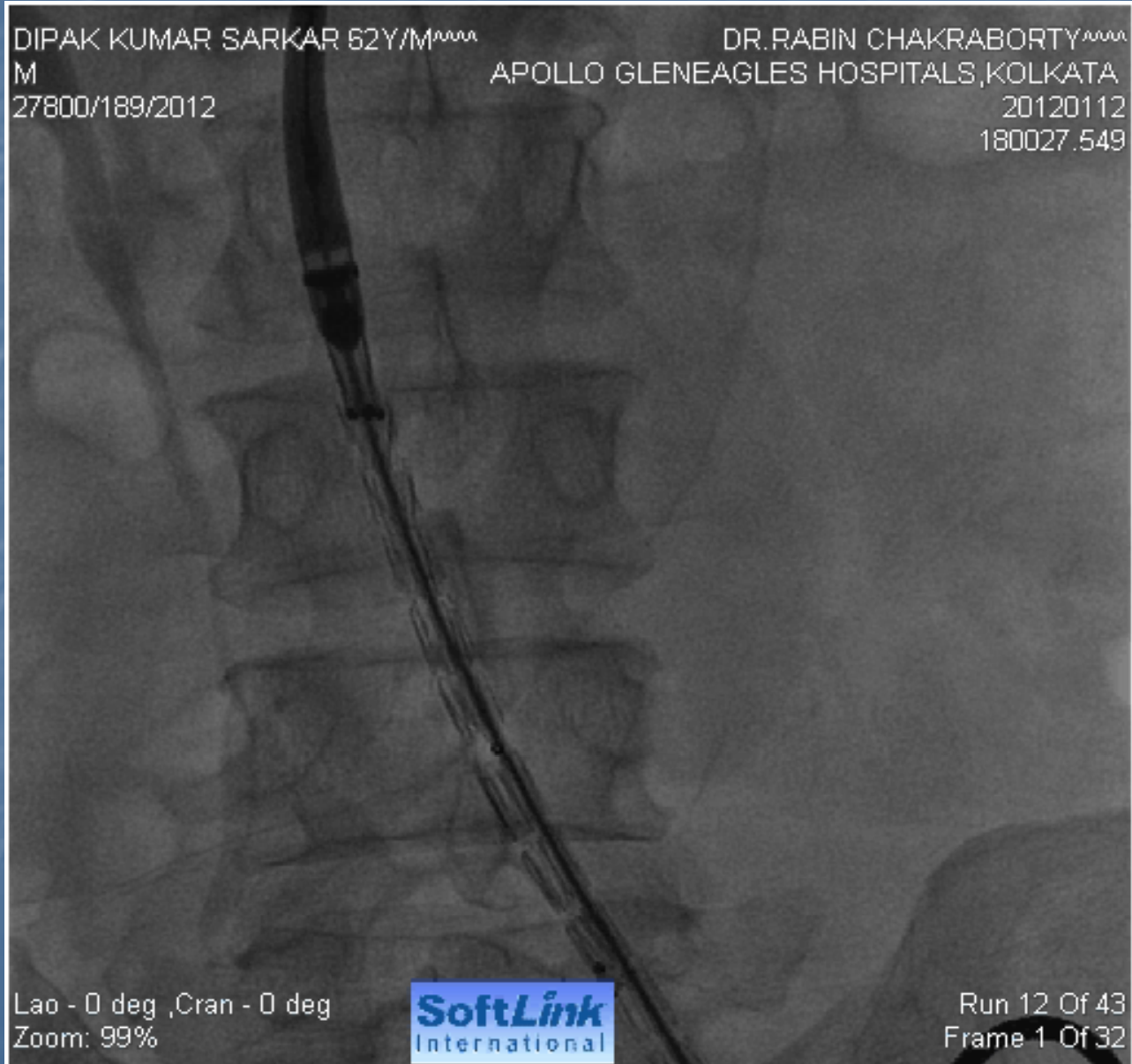


Lao - 11 deg ,Cran - 0 deg
Zoom: 99%

SoftLink
International

Run 10 Of 43
Frame 1 Of 29

Main body: Endurant 32×160 mm



DIPAK KUMAR SARKAR 62Y/M
M
27800/189/2012

DR. RABIN CHAKRABORTY
APOLLO GLENEAGLES HOSPITALS, KOLKATA
20120112
180027.549

Lao - 0 deg ,Cran - 0 deg
Zoom: 99%

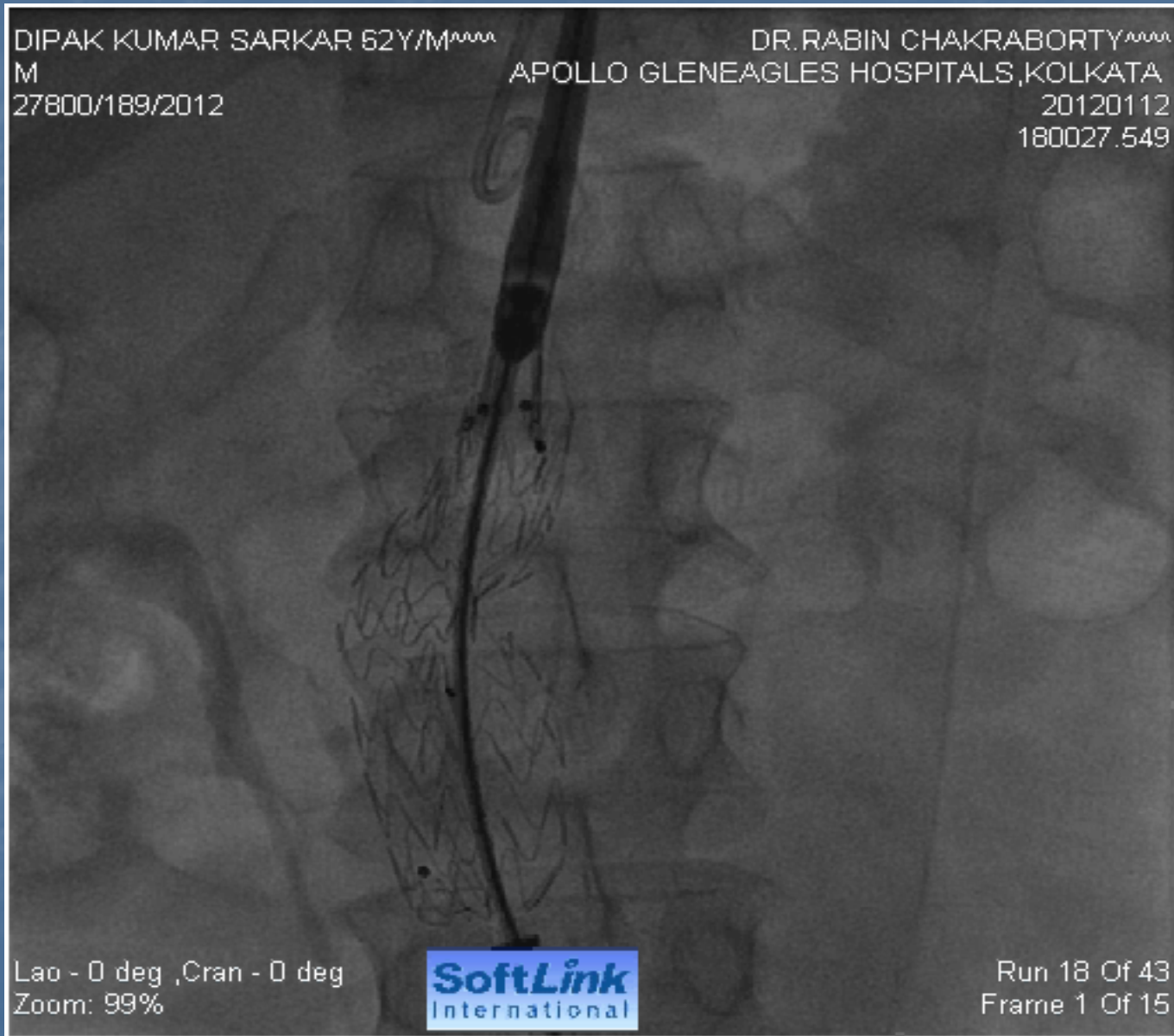
SoftLink
International

Run 17 Of 43
Frame 1 Of 221

Not yet deployed fully

DIPAK KUMAR SARKAR 52Y/M
M
27800/189/2012

DR. RABIN CHAKRABORTY
APOLLO GLENEAGLES HOSPITALS, KOLKATA
20120112
180027.549



Lao - 0 deg ,Cran - 0 deg
Zoom: 99%

SoftLink
International

Run 18 Of 43
Frame 1 Of 15

Proximal Fixation

DIPAK KUMAR SARKAR 62Y/M
M
27800/189/2012

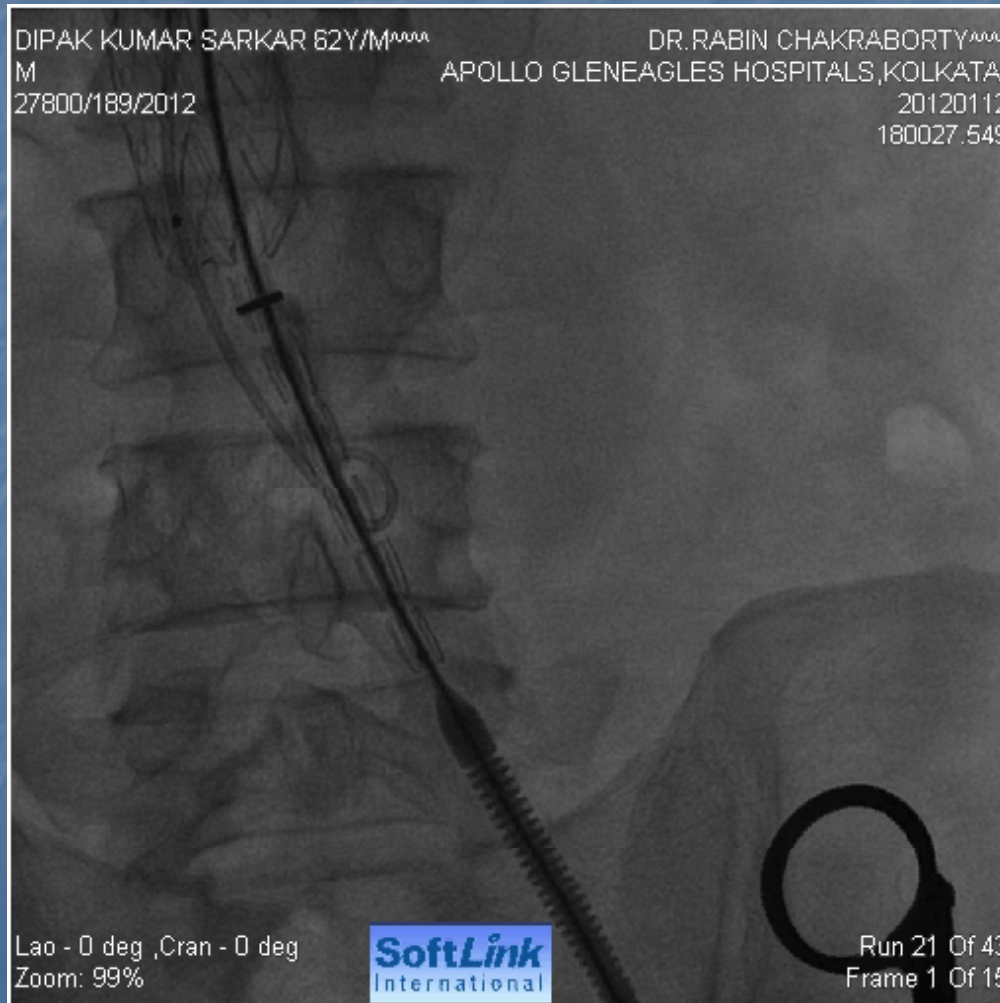DR. RABIN CHAKRABORTY
APOLLO GLENEAGLES HOSPITALS, KOLKATA
20120112
180027.549

Lao - 0 deg ,Cran - 0 deg
Zoom: 99%

SoftLink
International

Run 19 Of 43
Frame 1 Of 155

6F Pigtail through the stent across the opening for contra-lateral limb from left radial



Snaring of the retrograde wire

DIPAK KUMAR SARKAR 62Y/M
M
27800/189/2012

DR. RABIN CHAKRABORTY
APOLLO GLENEAGLES HOSPITALS, KOLKATA
20120112
180027.549

Lao - 0 deg ,Cran - 0 deg
Zoom: 99%

SoftLink
International

Run 23 Of 43
Frame 1 Of 226

DIPAK KUMAR SARKAR 52Y/M
M
27800/189/2012

DR. RABIN CHAKRABORTY
APOLLO GLENEAGLES HOSPITALS, KOLKATA
20120112
180027.549

Lao - 0 deg ,Cran - 0 deg
Zoom: 99%

SoftLink
International

Run 24 Of 43
Frame 1 Of 220

Contra-lateral limb Endurant 10×124 mm

DIPAK KUMAR SARKAR 62Y/M
M
27800/189/2012

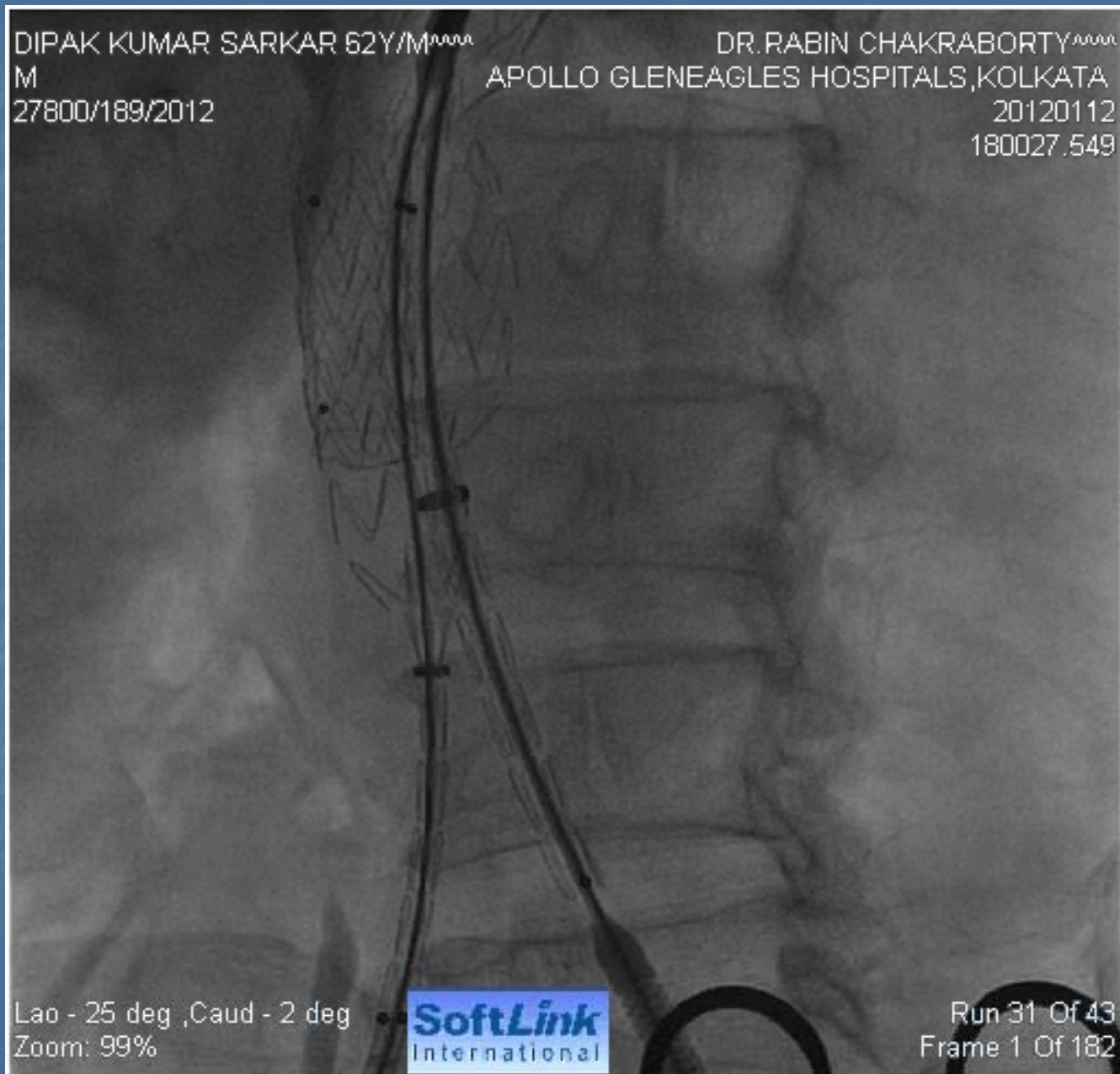
DR. RABIN CHAKRABORTY
APOLLO GLENEAGLES HOSPITALS, KOLKATA
20120112
180027.549

Rao - 1 deg ,Caud - 2 deg
Zoom: 99%

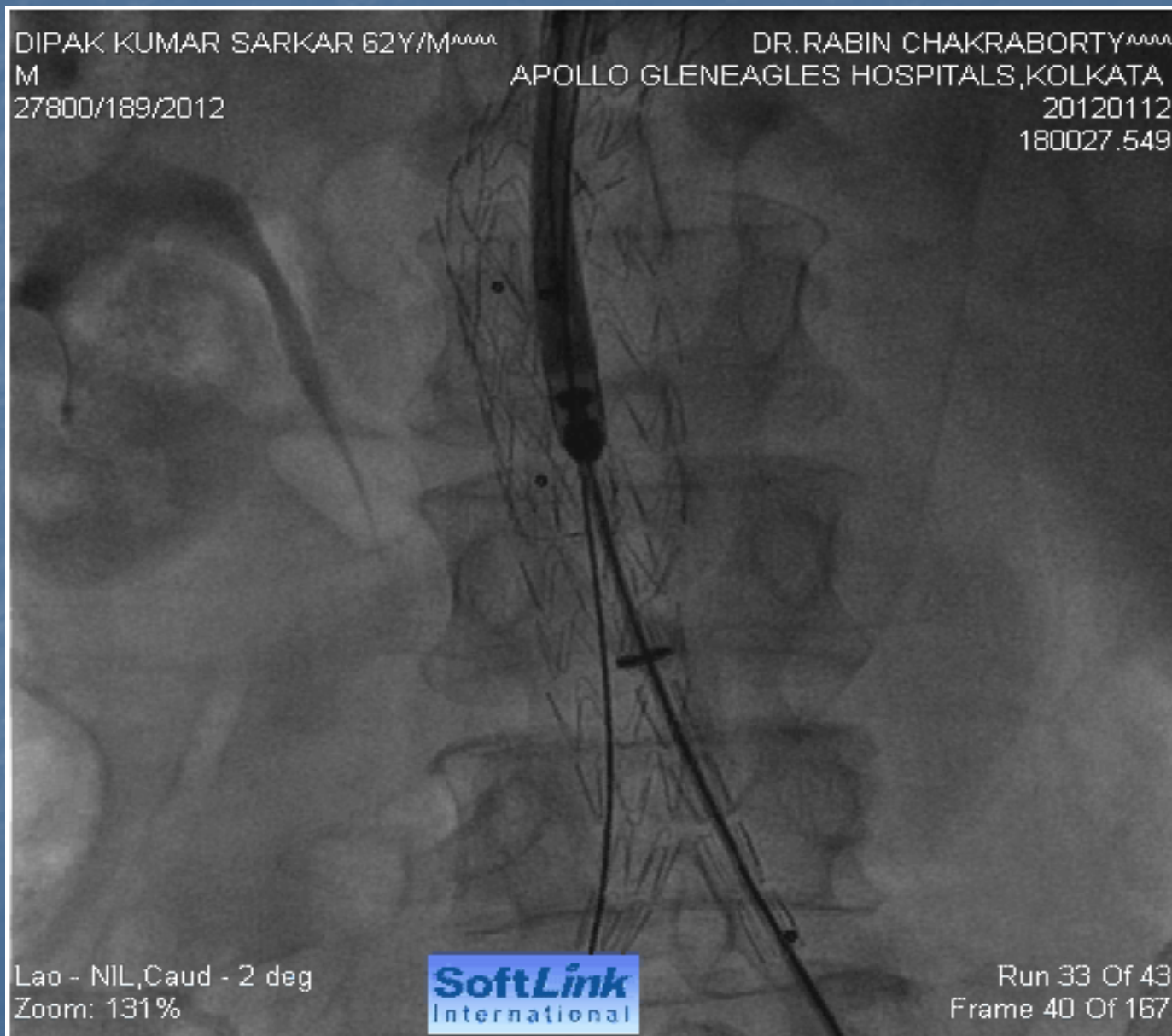
SoftLink
International

Run 26 Of 43
Frame 1 Of 129

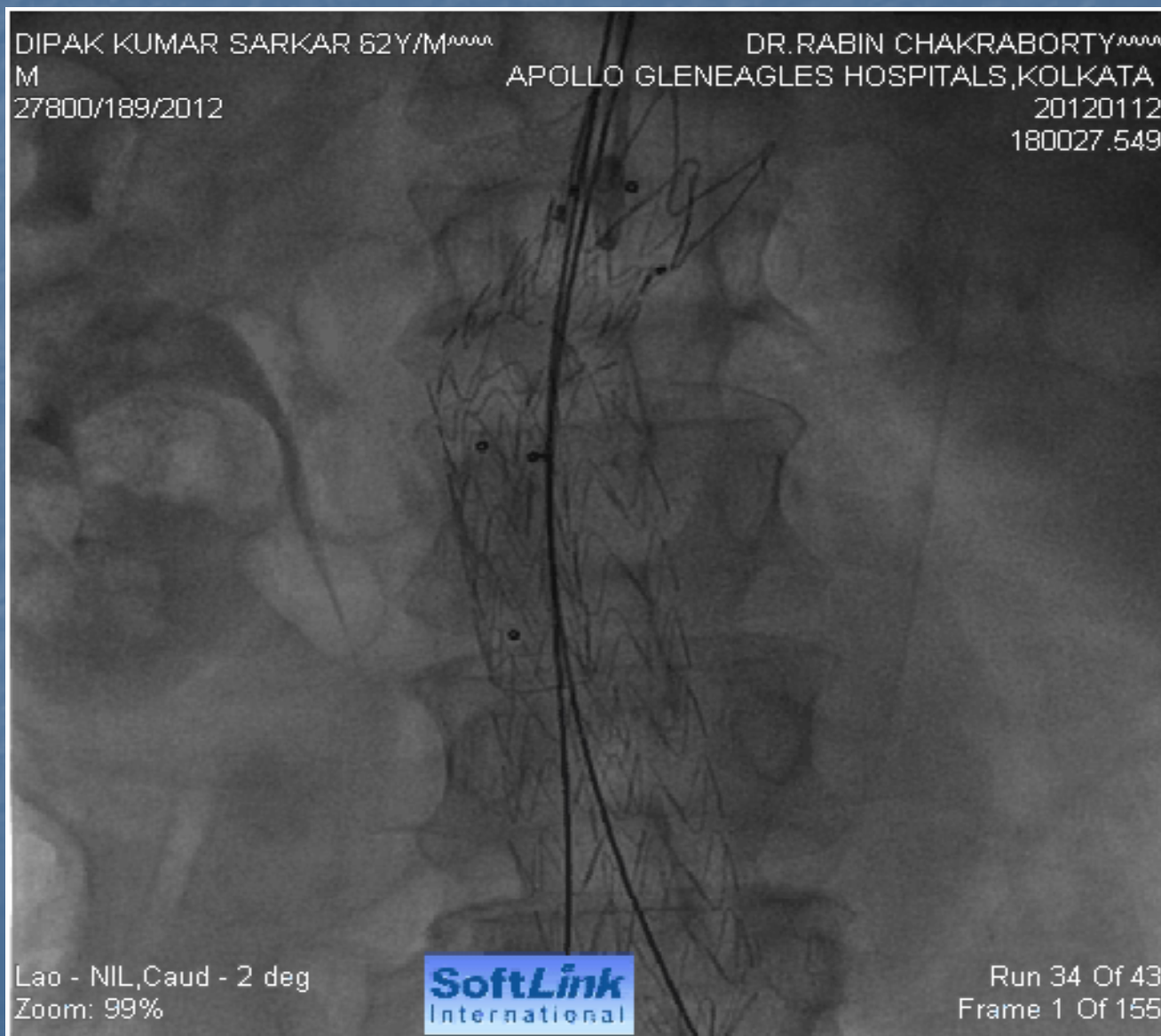
Contra-lateral limb Endurant 10×124 mm



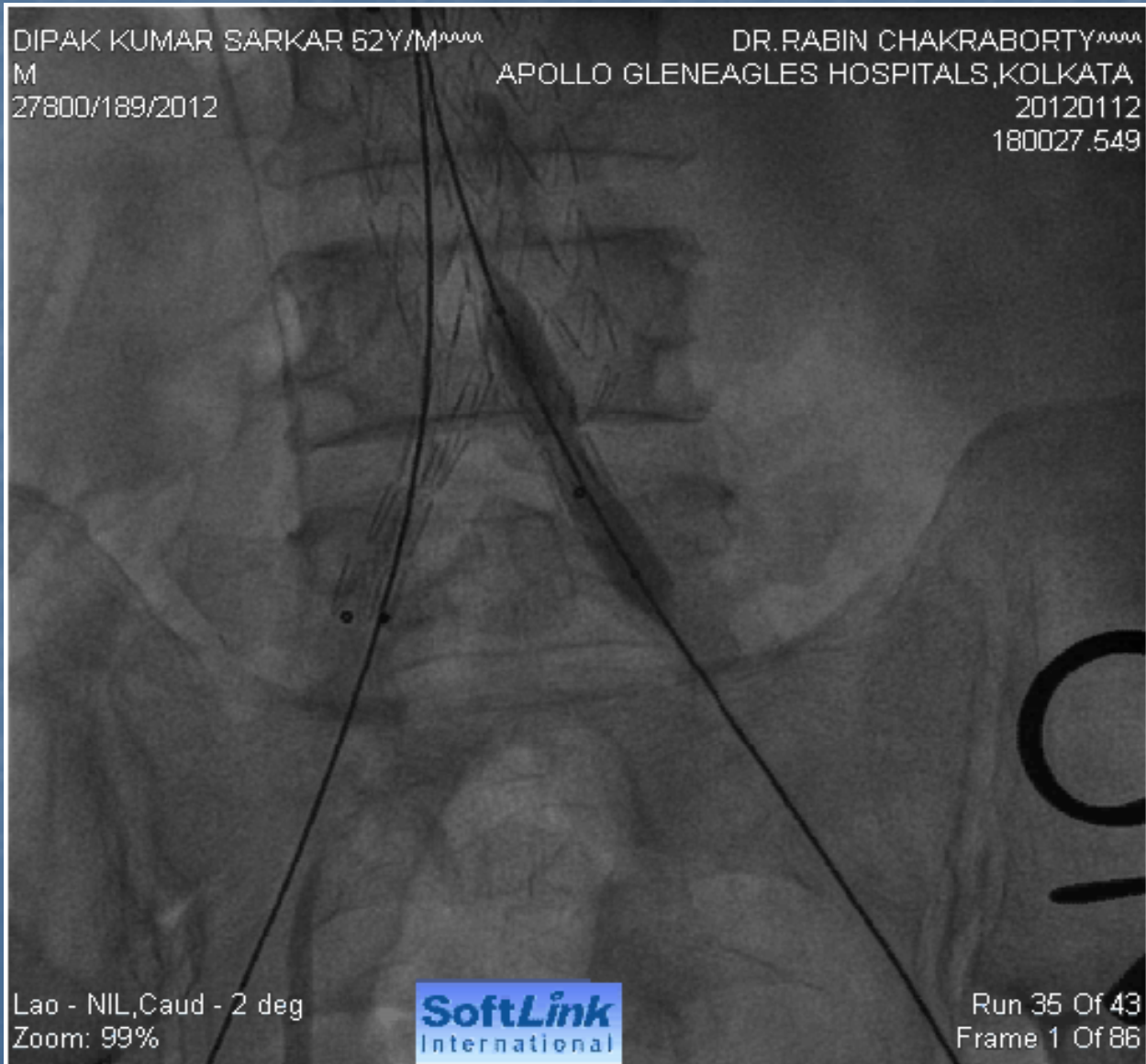
Final deployment of the main body



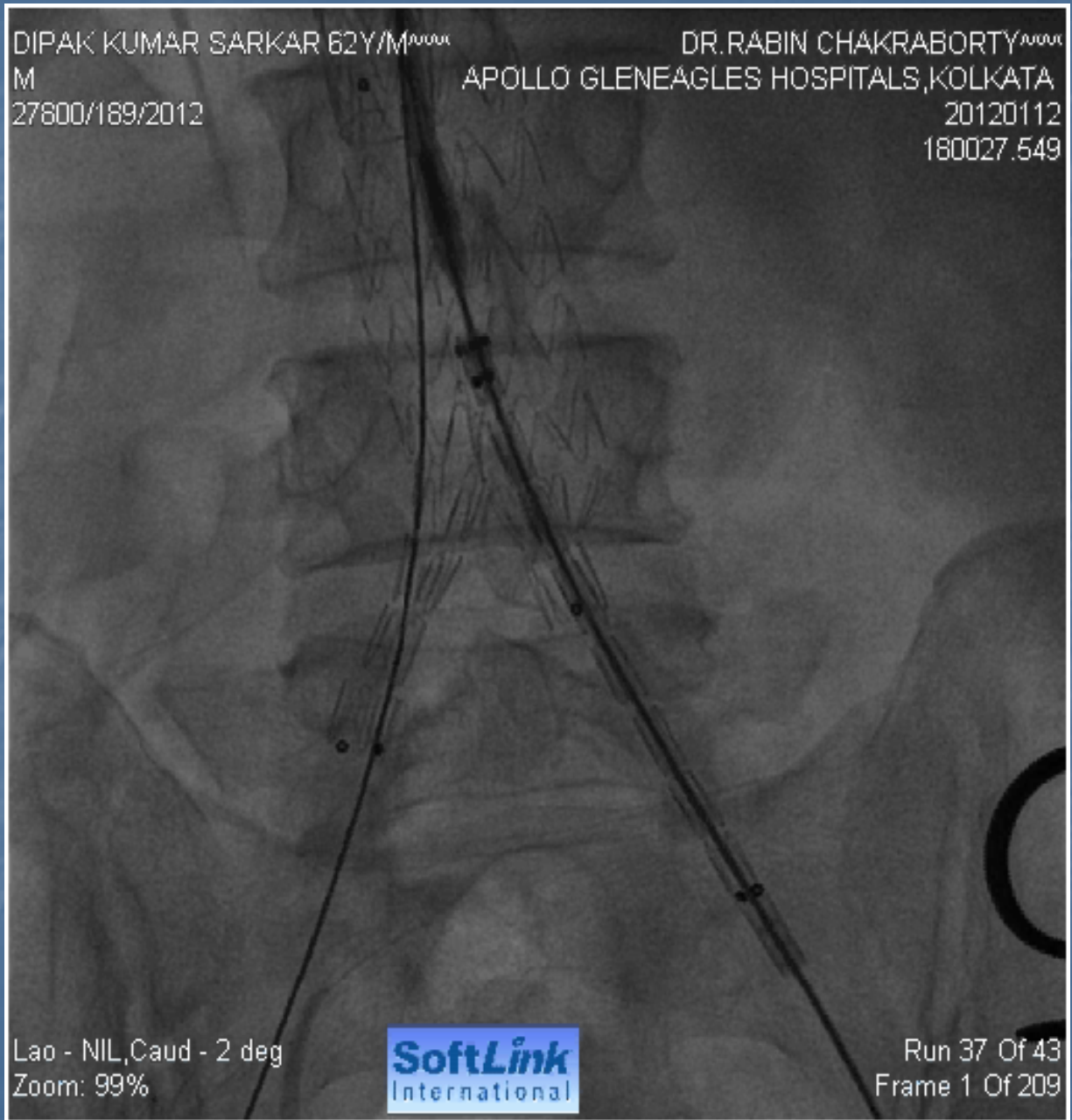
Post Deployment Injection : Diseased left common iliac artery distal to the stent



Low pressure dilatation of ipsilateral limb 10×40 mm balloon



Extension of ipsilateral limb with Endurant 10×82 mm



Low pressure dilatation of whole stent including overlapping areas with a compliant Reliant stent graft balloon.

DIPAK KUMAR SARKAR 52Y/M
M
27800/189/2012

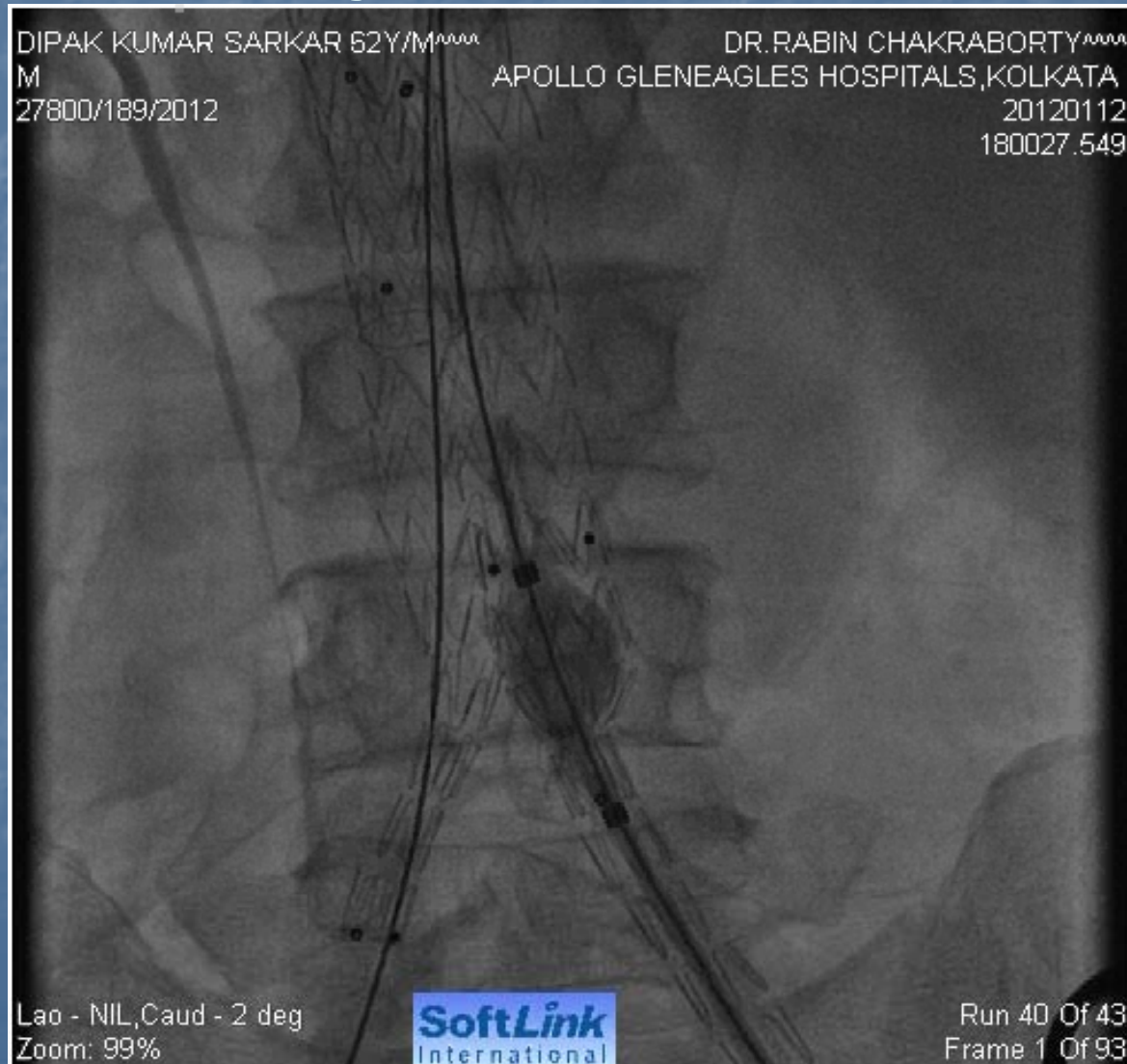
DR. RABIN CHAKRABORTY
APOLLO GLENEAGLES HOSPITALS, KOLKATA
20120112
180027.549

Lao - MIL, Caud - 2 deg
Zoom: 99%

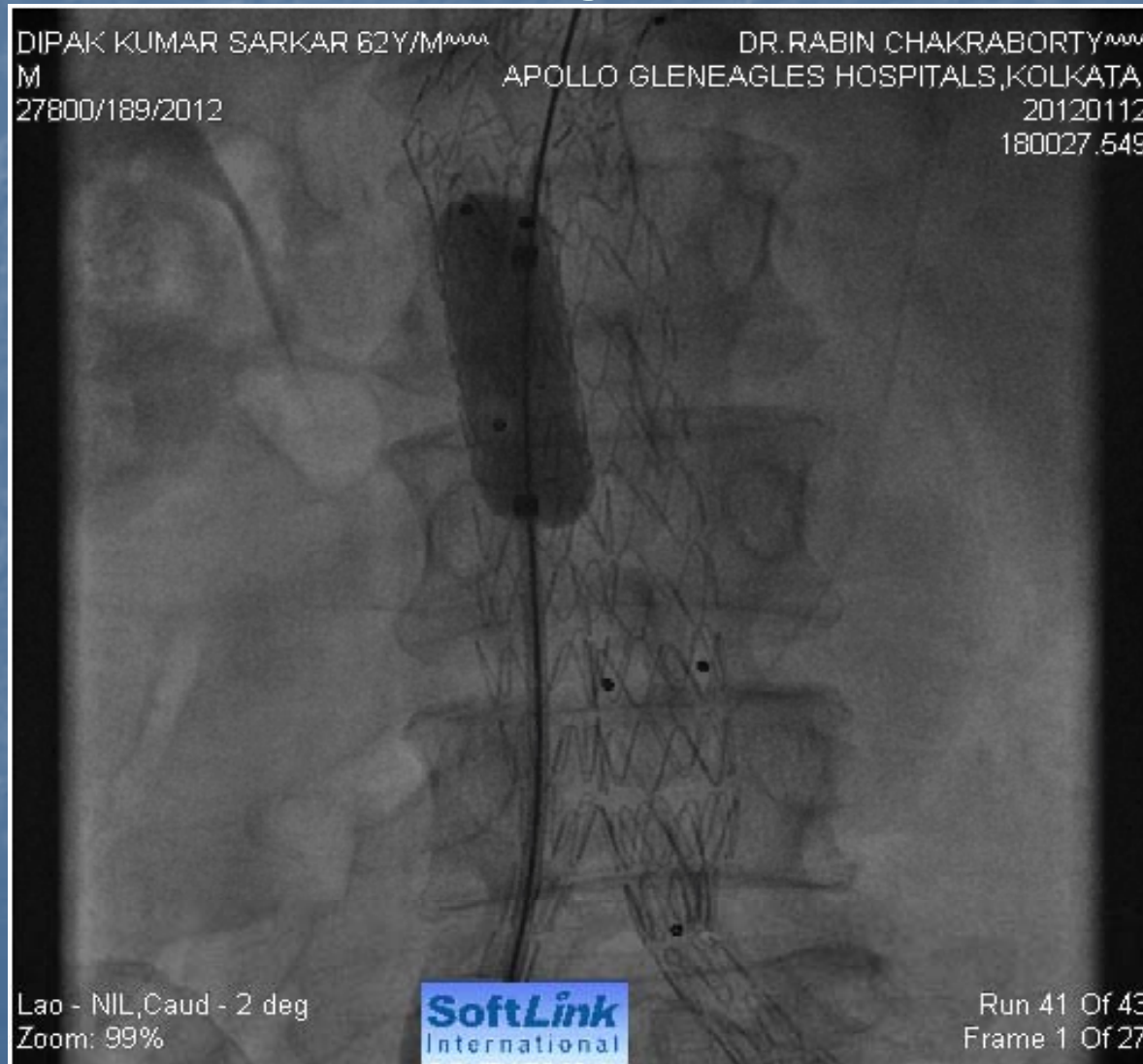SoftLink
International

Run 39 Of 43
Frame 1 Of 113

Low pressure dilatation of whole stent including overlapping areas with a compliant Reliant stent graft balloon



Low pressure dilatation of whole stent including overlapping areas with a compliant Reliant stent graft balloon.



Final result

DIPAK KUMAR SARKAR 62Y/M
M
27800/189/2012

DR. RABIN CHAKRABORTY
APOLLO GLENEAGLES HOSPITALS, KOLKATA
20120112
180027.549

Lao - NIL, Caud - 2 deg
Zoom: 99%

SoftLink
International

Run 43 Of 43
Frame 1 Of 169

Procedure summary

- Procedure date 12.01.2012.
- Under GA (Hybrid with CTU Surgeon)
- Surgical exposure & closure of both femoral arteries
- Total procedure time 95 mins.
- Total UFH 9,000 IU.
- Total contrast used 400 ml Omnipaque.
- Extubated after 1 hr post procedure.
- No blood transfusion required.
- Planning follow up imaging by contrast CT after 6 m

DIPAK KR SARKAR 62Y/M

2SPG 17983/B.NO 235 M/62Y

8 ARTERIAL

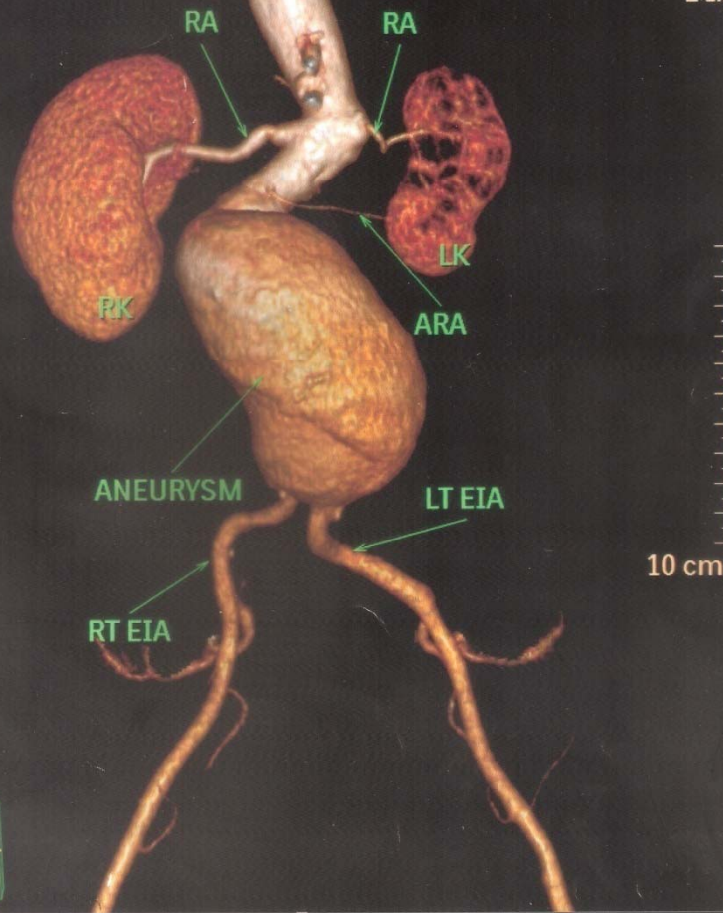
C

Apollo Gleneagles

Philips, Brilliance Big Bore

5 Jan, 2012 10:28:28.00

Z 1.05



DIPAK KUMAR SARKAR 62Y/M
M
27800/189/2012

DR. RABIN CHAKRABORTY
APOLLO GLENEAGLES HOSPITALS, KOLKATA
20120112
180027.549

Lao - NIL, Caud - 2 deg
Zoom: 99%

SoftLink
International

Run 43 Of 43
Frame 1 Of 169

Thank You