

Incomplete release of anchor in CoreValve prosthesis during TAVI

Myeong-Ki Hong, M.D. Ph D

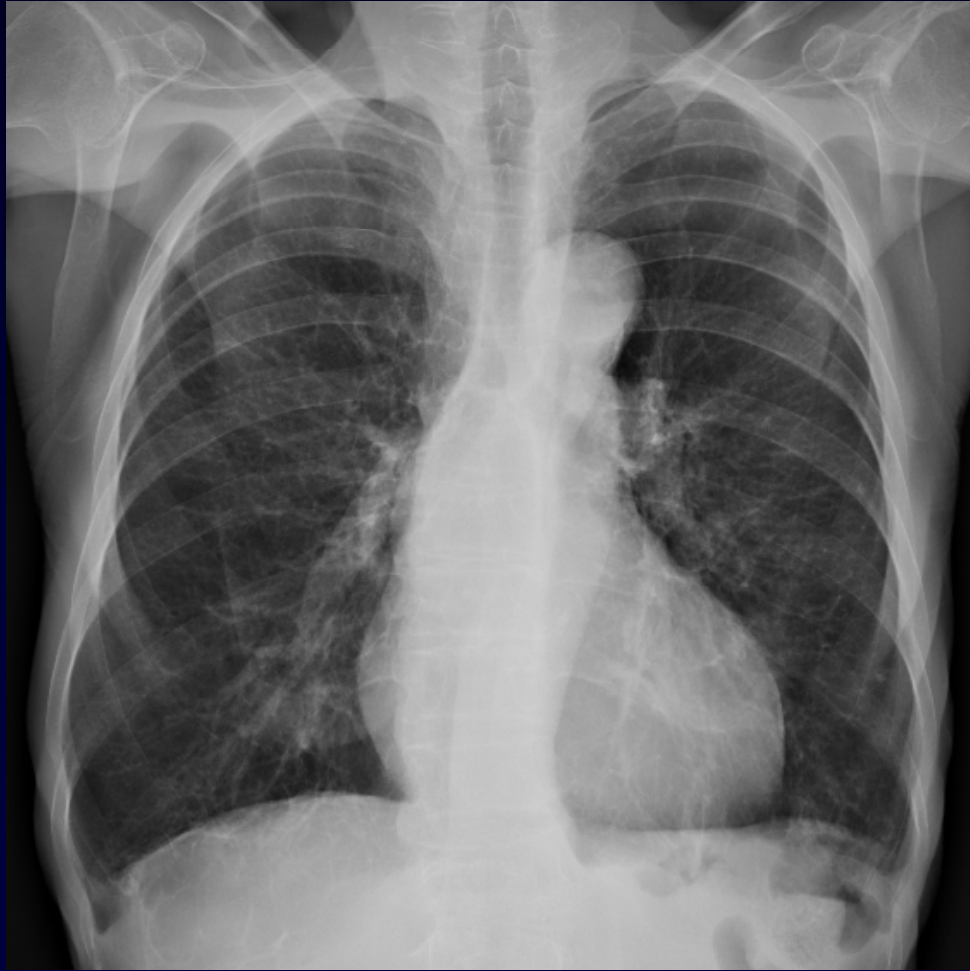Professor of Medicine

Division of Cardiology, Severance Cardiovascular Hospital
Yonsei University College of Medicine, Seoul, Korea

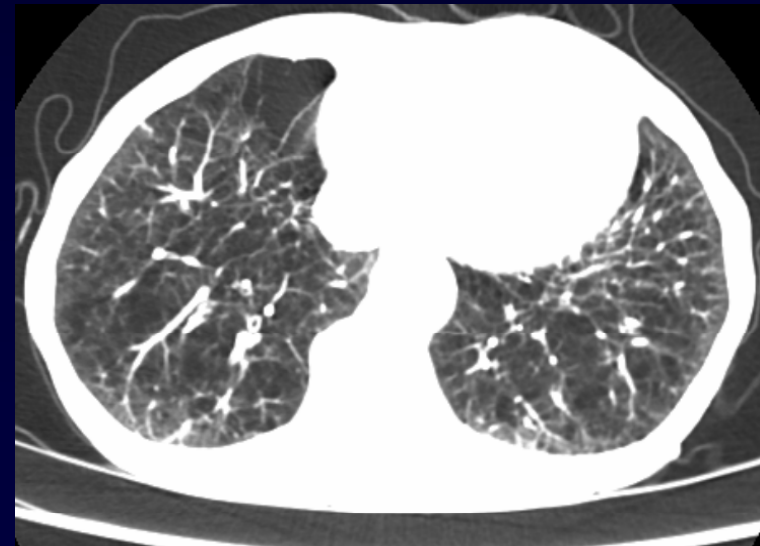
Patient history

- Female / 79 year-old
- C.C: Dyspnea
- PHx: Severe COPD on medication
- Functional class: NYHA II
- Euroscore: 20.3%

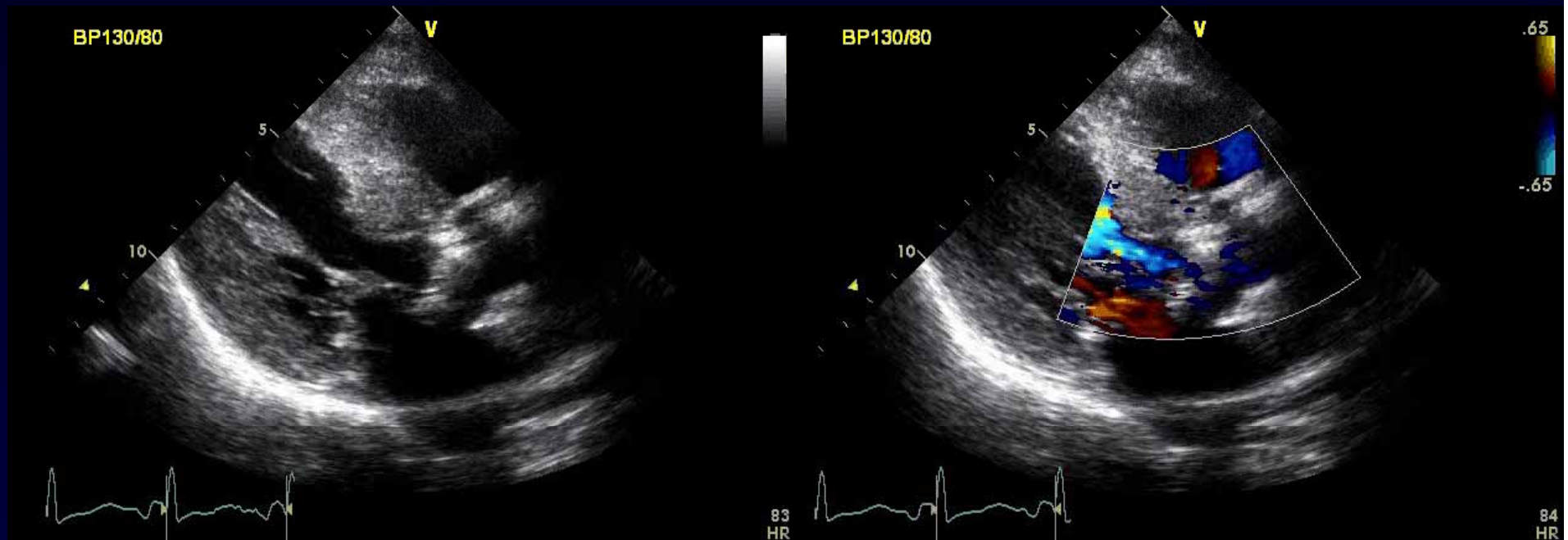
Chest PA



Spirometry	Ref	Pre	%Ref
FVC	2.04	1.85	91
FEV1	1.34	0.66	49
FEV1/FVC	70	36	

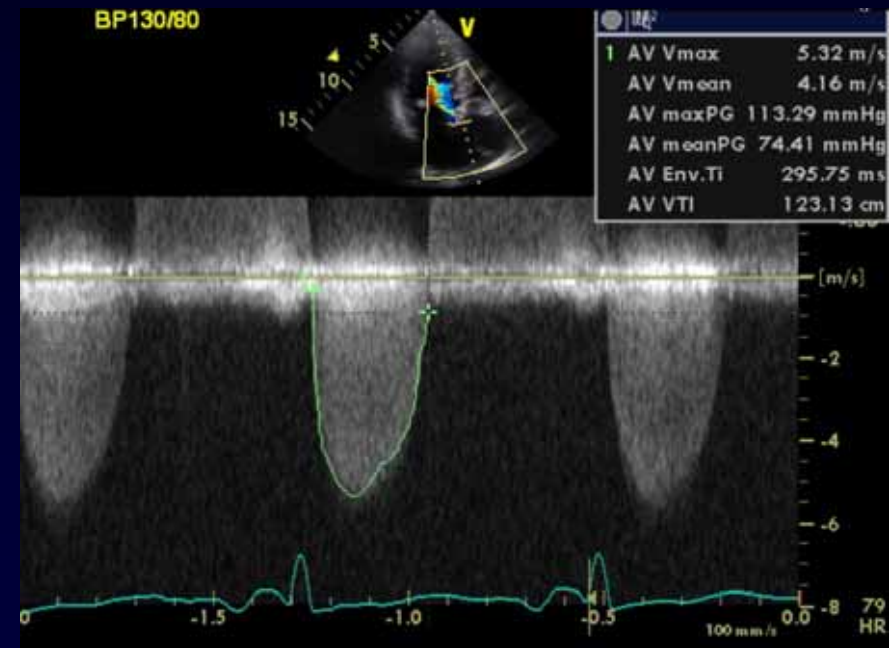
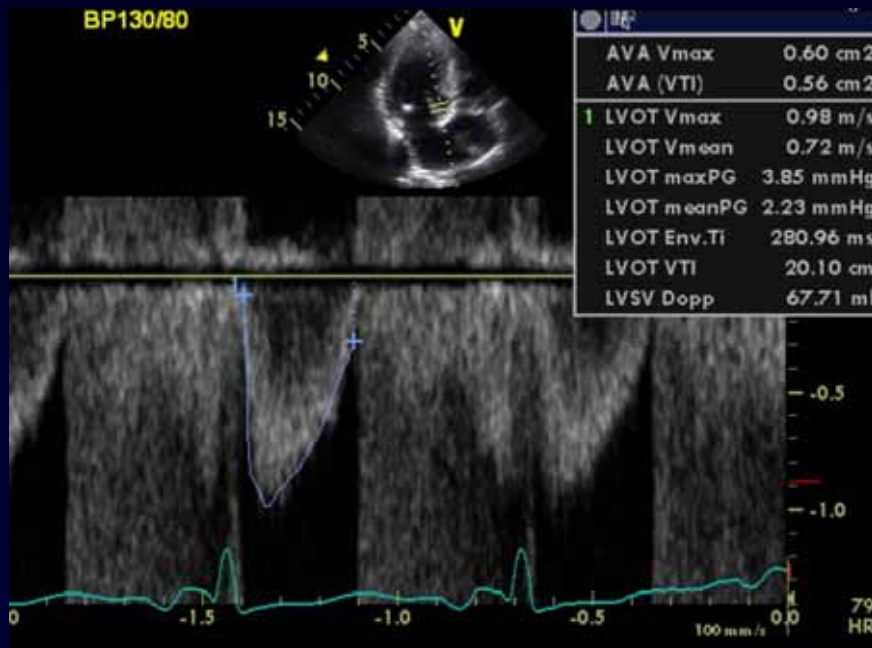


TTE



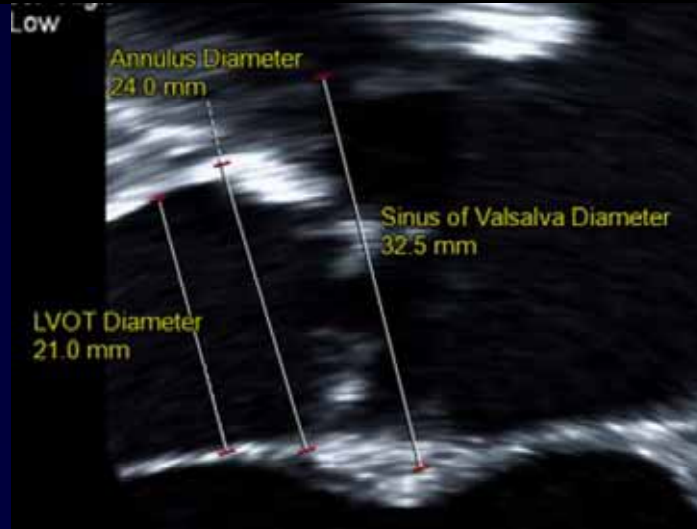
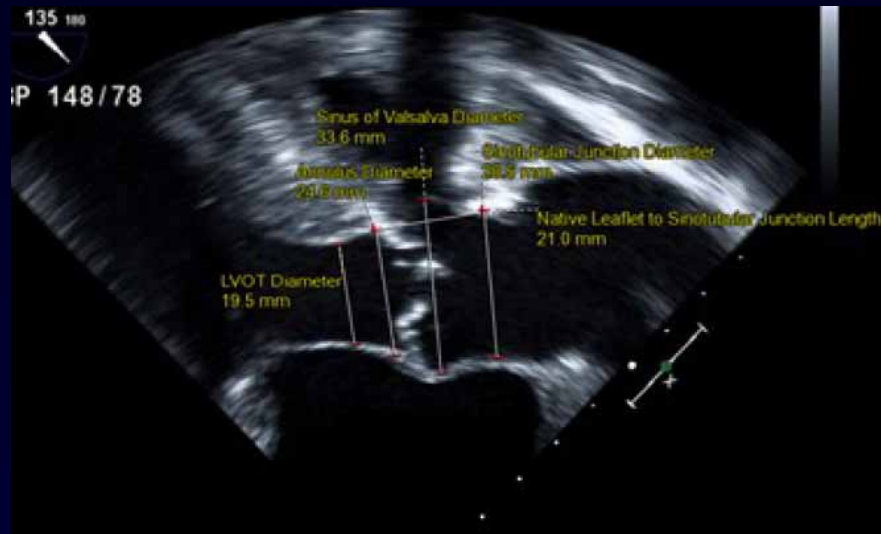
EF: 72%, No RWMA, AR(GII), MR(t), TR(GII), RVSP: 53mmHg

TTE



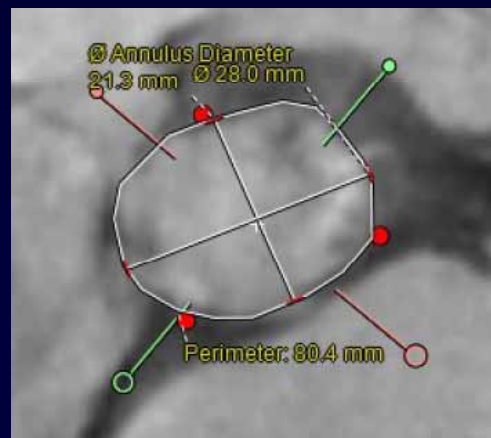
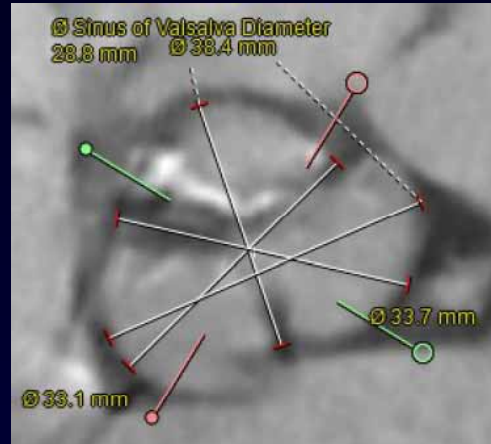
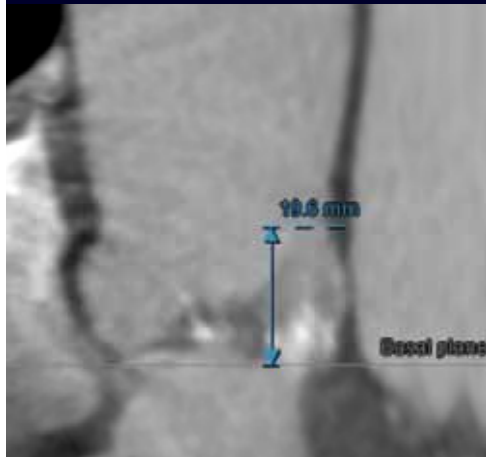
Peak/mean pressure gradient: 113/74 mmHg
AVA with C.E : 0.56 cm²

2D measurement (TEE)



Site	Diameter
LVOT	19.5-21 mm
Annulus	24.5 mm
Sinus of Valsalva	32.5 mm
ST junction	28.5 mm
Ascending aorta	
Native Leaflet to ST junction	21 mm

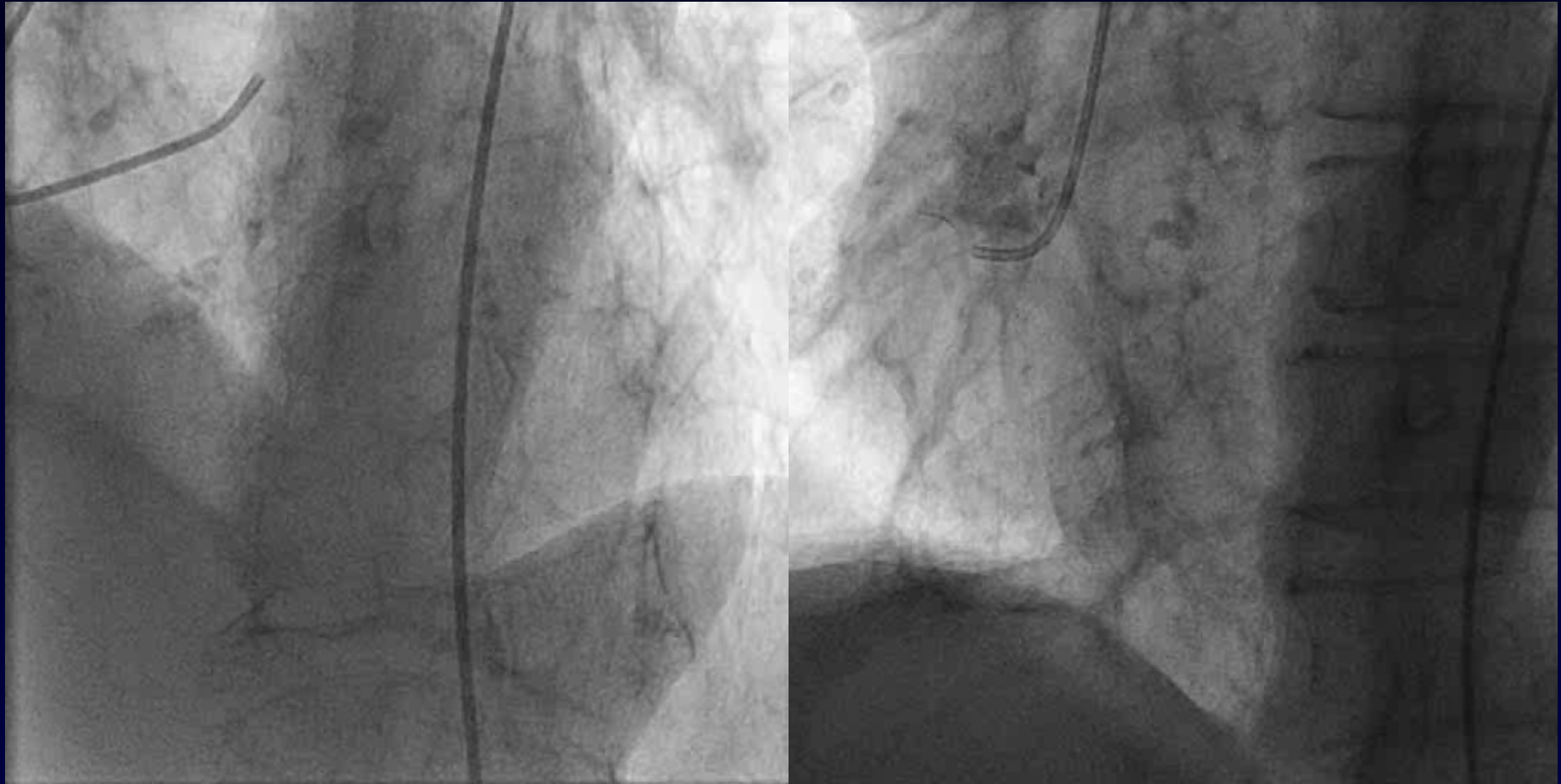
CT measurement



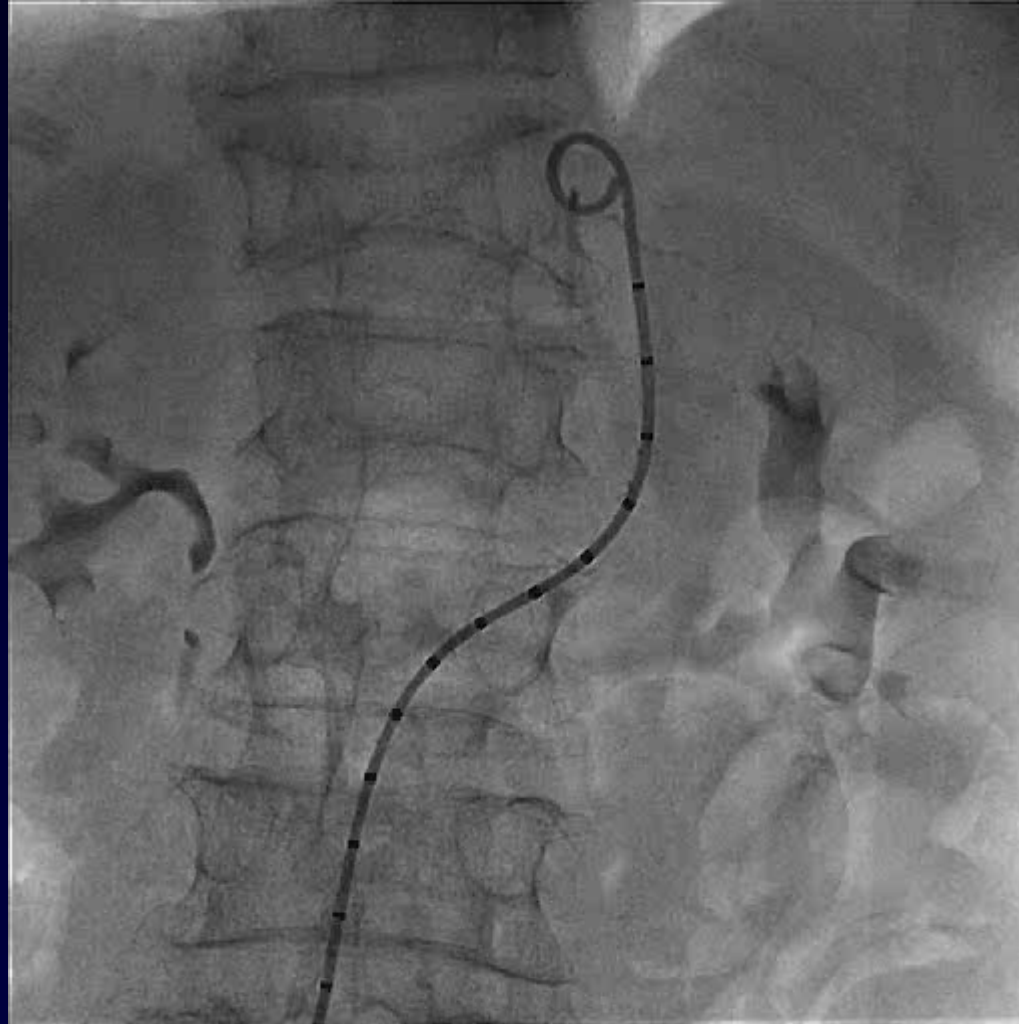
Perimeter: 80.4 mm

Site	Diameter
LVOT	22 mm
Annulus	21.5 x 28 mm
Sinus of Valsalva	29 x 38.5 mm
ST junction	31.5 x 35 mm
Ascending aorta	38 x 39 mm
Native Leaflet to ST junction	19.5 – 26 mm

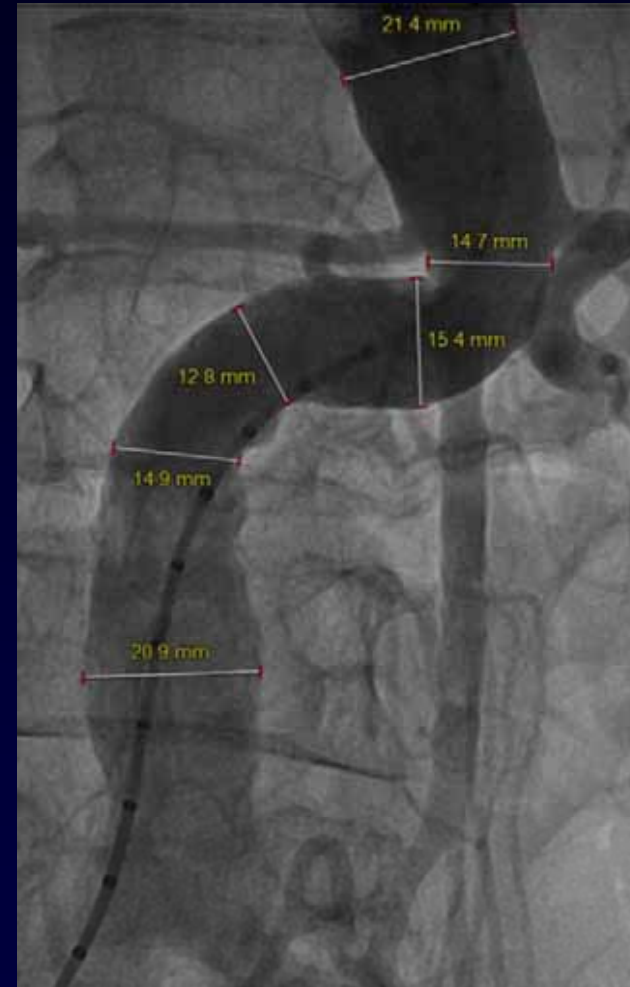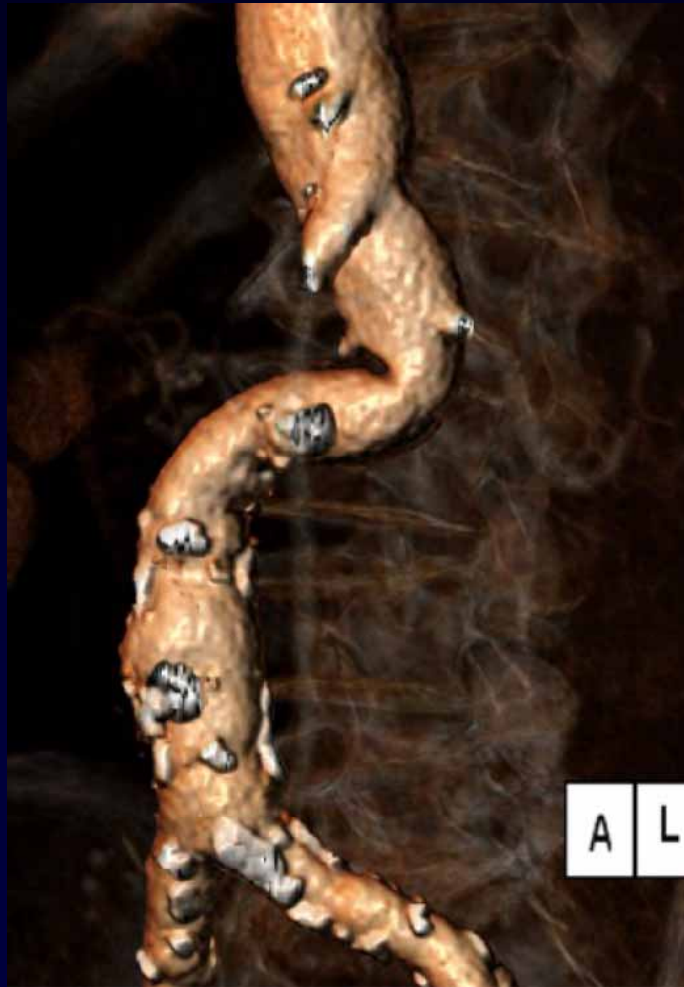Coronary Angiography



Peripheral angiography

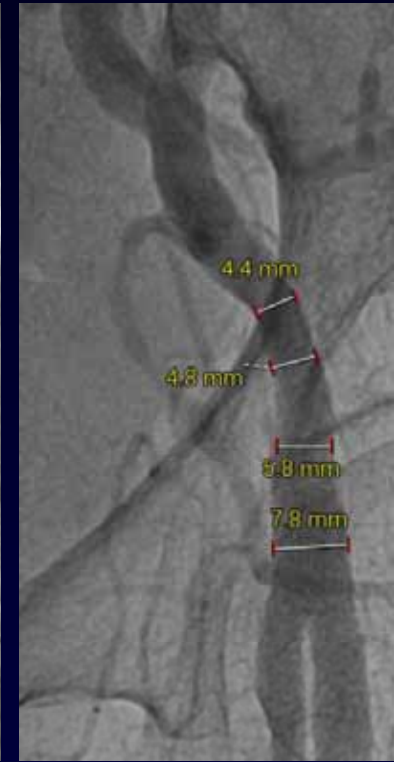
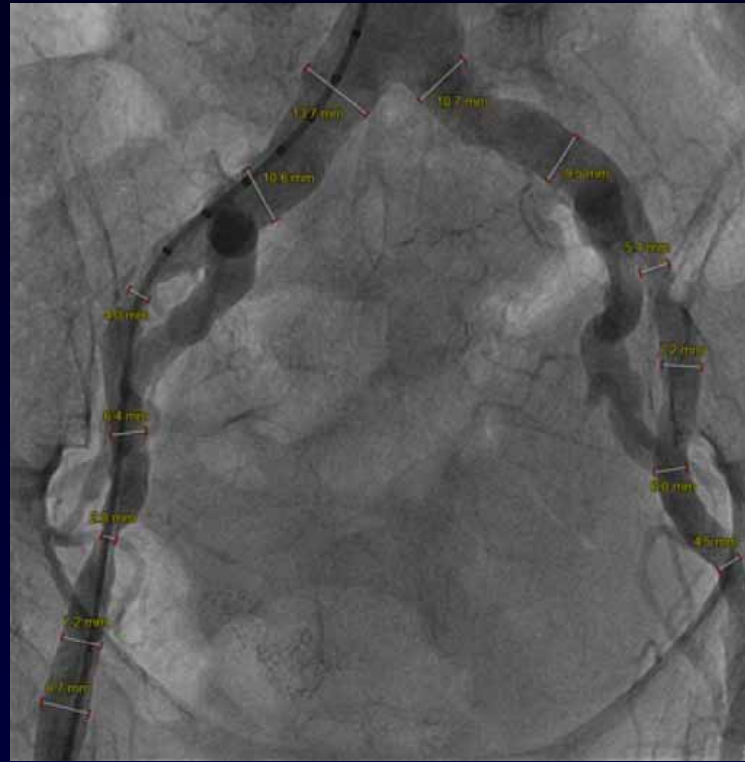
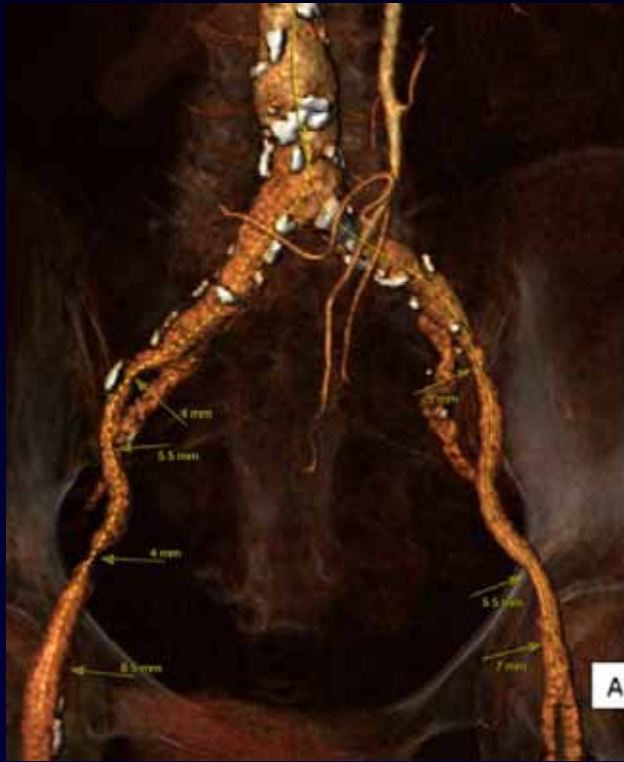Aorta CT



Kinked abdominal aorta

Extremities CT and Angio



	Right	Left	Right	Left
Iliac	4-11.5 mm	5-10.5 mm	3-13.5 mm	4.5-11 mm
Femoral	8.5 mm	7 mm	7-8.5 mm	6 mm
Subclavian		5.5 mm		

Consensus documents from 2 different cardiac surgeons

협진진료의뢰서-의뢰.회신 공통 [2012-05-22]

진단명
진단명
Aortic stenosis (severe)
Asthma
Cataract, unspecified, Right
Osteoporosis, other
Rectal cancer, S/P

의뢰사유 본 79세 여 환자는 [Asthma, Cataract, unspecified, Right, Rectal cancer, S/P, Osteoporosis, other, Aortic stenosis (severe)] 치료 중인 환자로 하기 분야에 관한 선생님의 고진선처를 부탁드립니다.

For: severe AS에 대한 TAM or MVR

5/24일 본과적으로 TAM 시행 위해 입원하였습니다. 귀 과적 판단 위한 협진 의뢰 드립니다. 감사합니다.

R2 김태훈 72110 배상

의뢰일시 2012-05-22 16:17

의뢰과 심장내과

의뢰의 고영국

회신내용 TAM 진행하시기 바랍니다. 감사합니다.

Pf. 장병철 / R3 유우식 72581

회신일시 2012-05-23 16:41

회신과 심장혈관외과

협진주치의 장병철 / 유우식

협진진료의뢰서-의뢰.회신 공통 [2012-05-02]

진단명
진단명
Aortic stenosis (severe)

의뢰사유 본 79세 여 환자는 [Aortic stenosis (severe)] 치료 중인 환자로 하기 분야에 관한 선생님의 고진선처를 부탁드립니다.

For: TAM or AVR

상기 환자 severe AS로 TAM or AVR 시행 고려중인 분입니다. 귀과적 고견을 위한 협진의뢰 드립니다. (TTE, TEE는 5/3(목) 시행 예정입니다.)

심장내과 고영국 / R2 문일주 배상 # 72698

의뢰일시 2012-05-02 10:44

의뢰과 심장내과

의뢰의 고영국

회신내용 Staff notify 하였습니다.

고령, poor lung function, general condition 고려하여 TAM 고려 하시기 바랍니다. 감사합니다.

Pf. 이삭 / R3 유우식 72581

회신일시 2012-05-03 19:08

회신과 심장혈관외과

협진주치의 이삭 / 유우식

TAVI screen meeting documents

[2nd] TAVI 환자 Review meeting 회의록

- 일시: 2011년 8월 29일, 목요일 5시-5시 30분
- 장소: 심장혈관 병원 3층 PCI staff lounge
- 참석자: 홍명기, 고영국, 심재광, 이삭, 심지영, 신상훈, 이수연, 송인선, 김덕희, 김찬

↓ Cardiac imaging cardiologist

↓ Cardiac surgeon

↓ Cardiac anesthesiologist

↓ Endovascular cardiac interventionist

1. 보고사항

- Case review

2. 논의 및 결정사항

- TAVI consult는 최용선 교수에서 심재광 교수로 내도록 결정됨
- 9월 5-6일 양일에 걸쳐 총 4명 환자 시술할 예정임

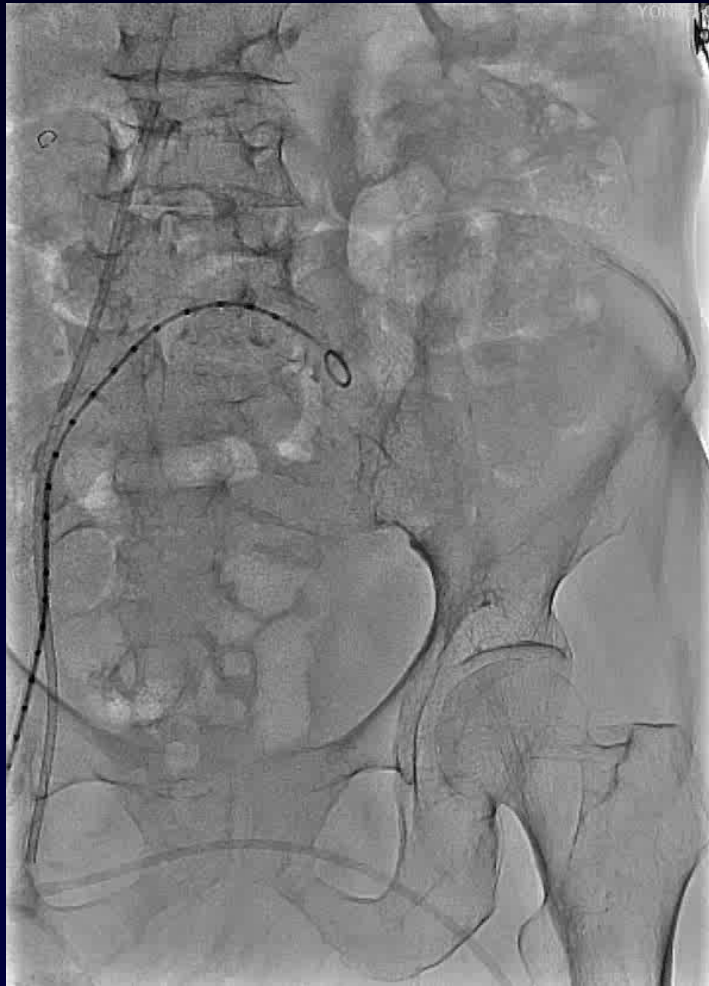1. [redacted] (F/82, 5998917): 9월 4일 14:00 입원 예정, 주치의 홍명기 교수님

2. [redacted] (F/83, 7355602): 9월 4일 14:00 입원 예정, 주치의 홍명기 교수님

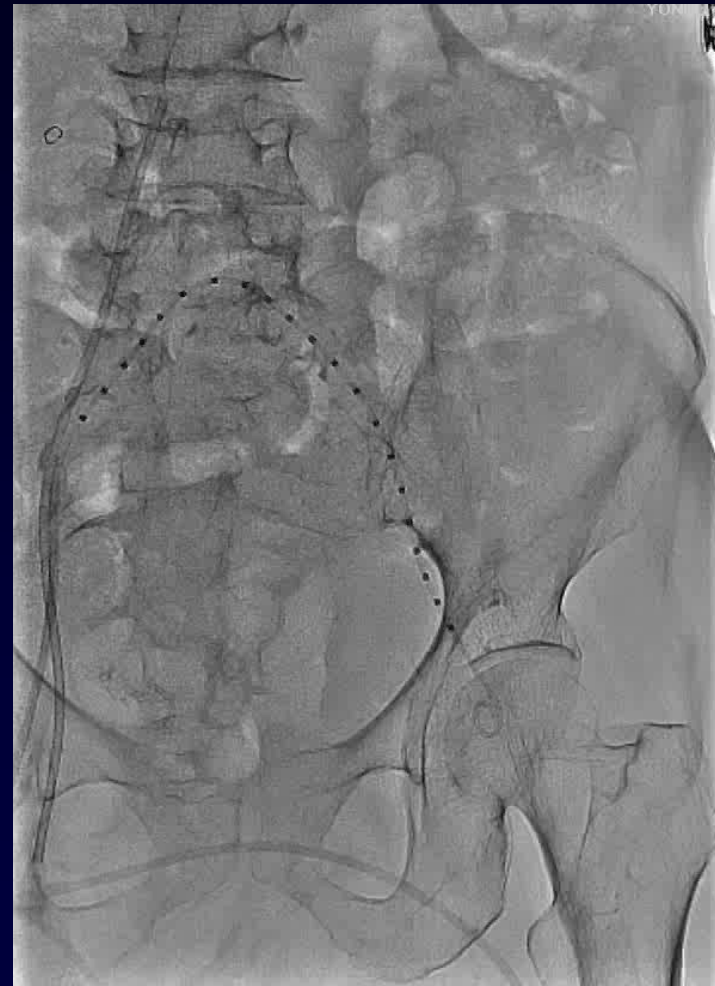3. [redacted] (F/85, 7353071): 현재 89W 입원 중, 주치의 정남식 교수님

4. [redacted] (M/82, 5211985): 9월 4일 14:00 입원 예정, 주치의 최동훈 교수님

Procedure

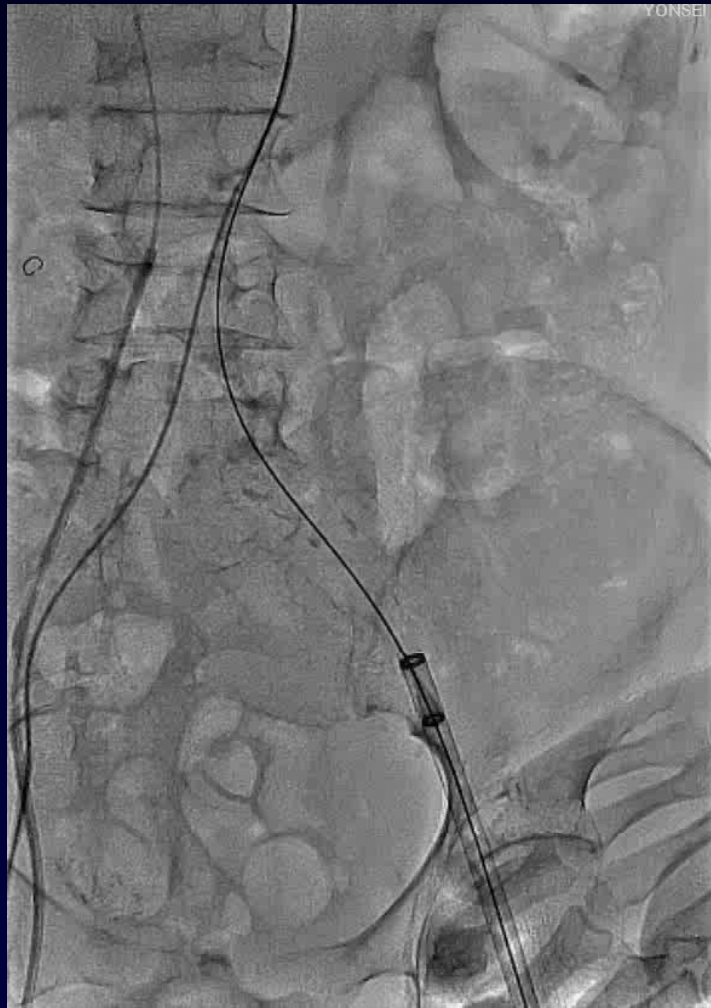

Stenosis at left external iliac artery

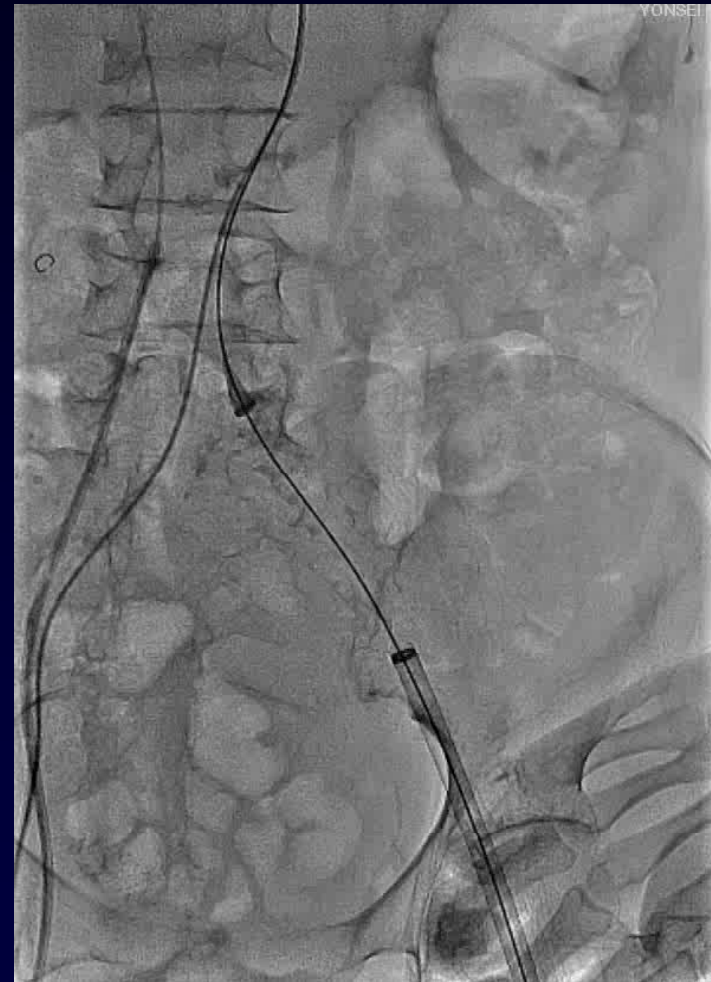

Pigtail guided puncture

Procedure

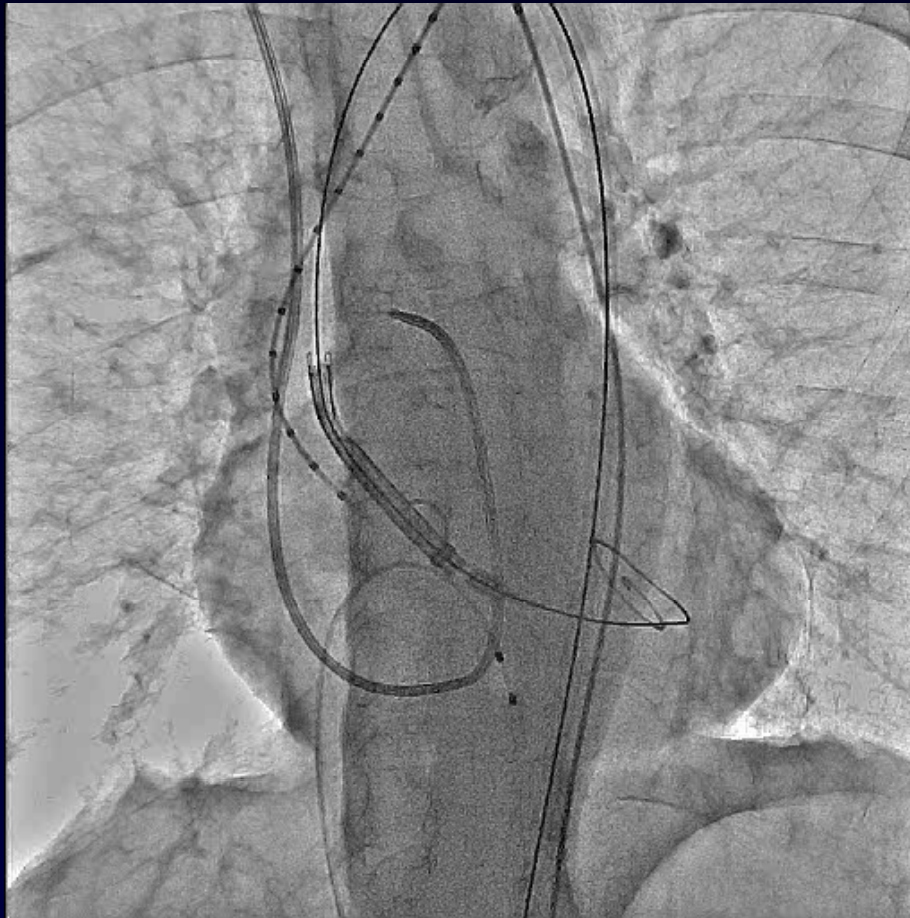

18Fr sheath placed only at EIA

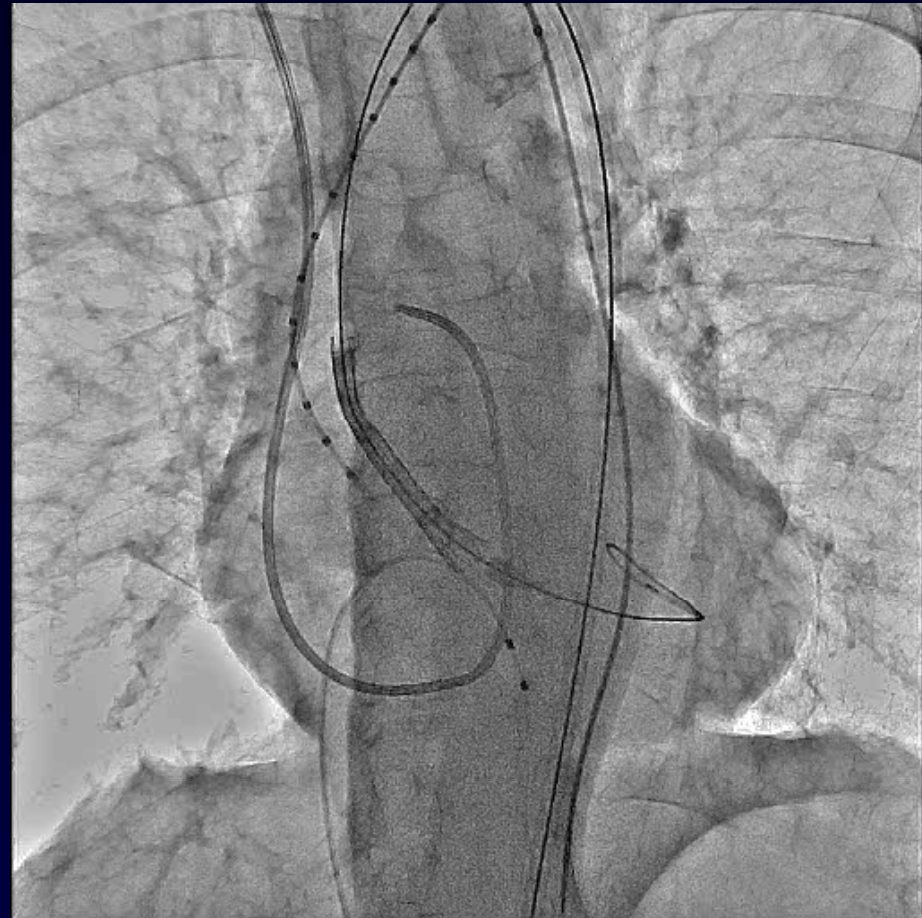

Test passage with unmounted CoreValve delivery system

TAVI procedure

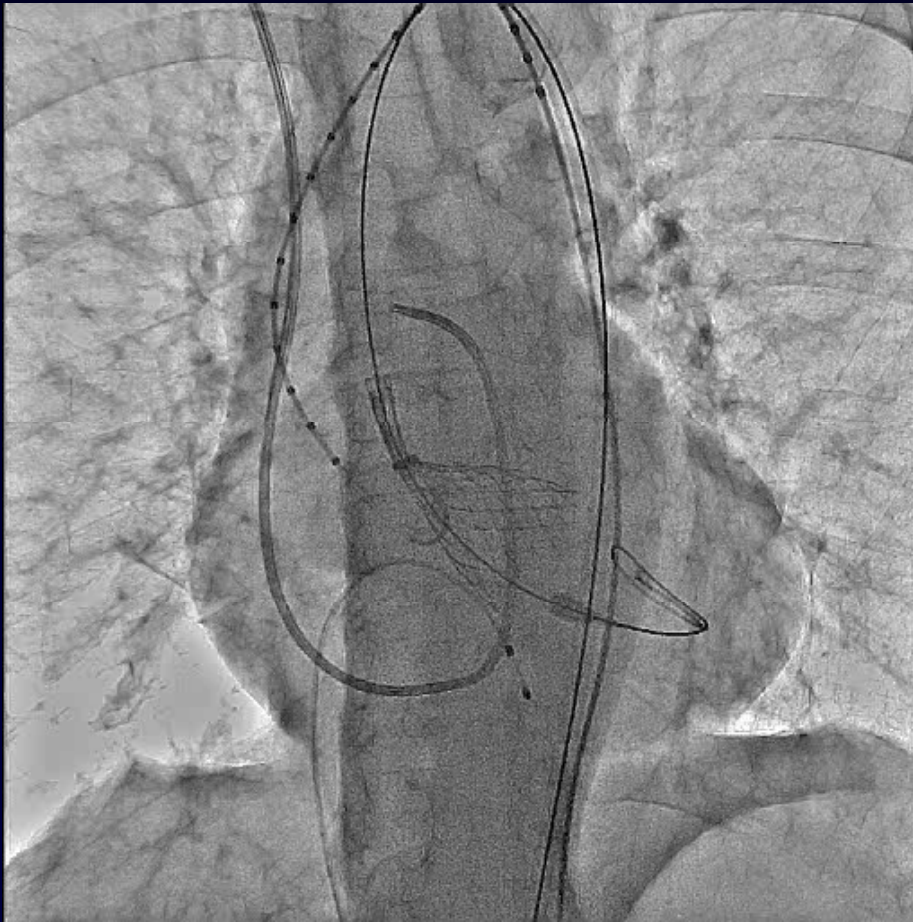

Valve deployed without rapid pacing
or predilation

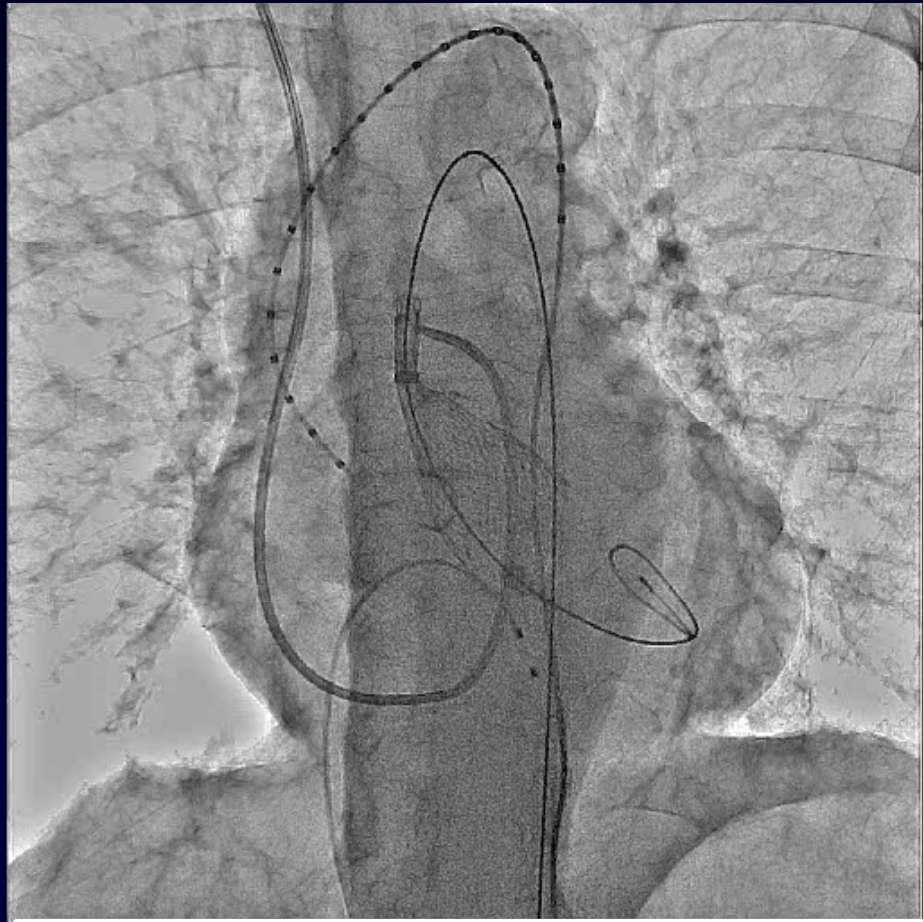

CoreValve 29mm

TAVI procedure

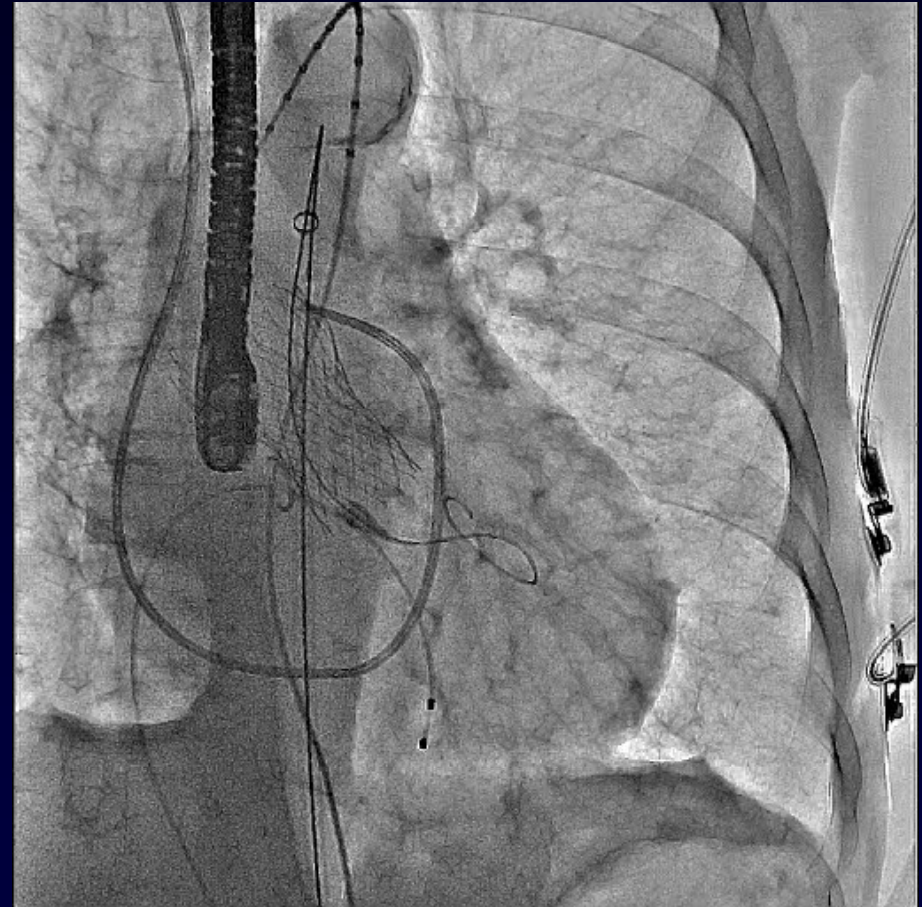
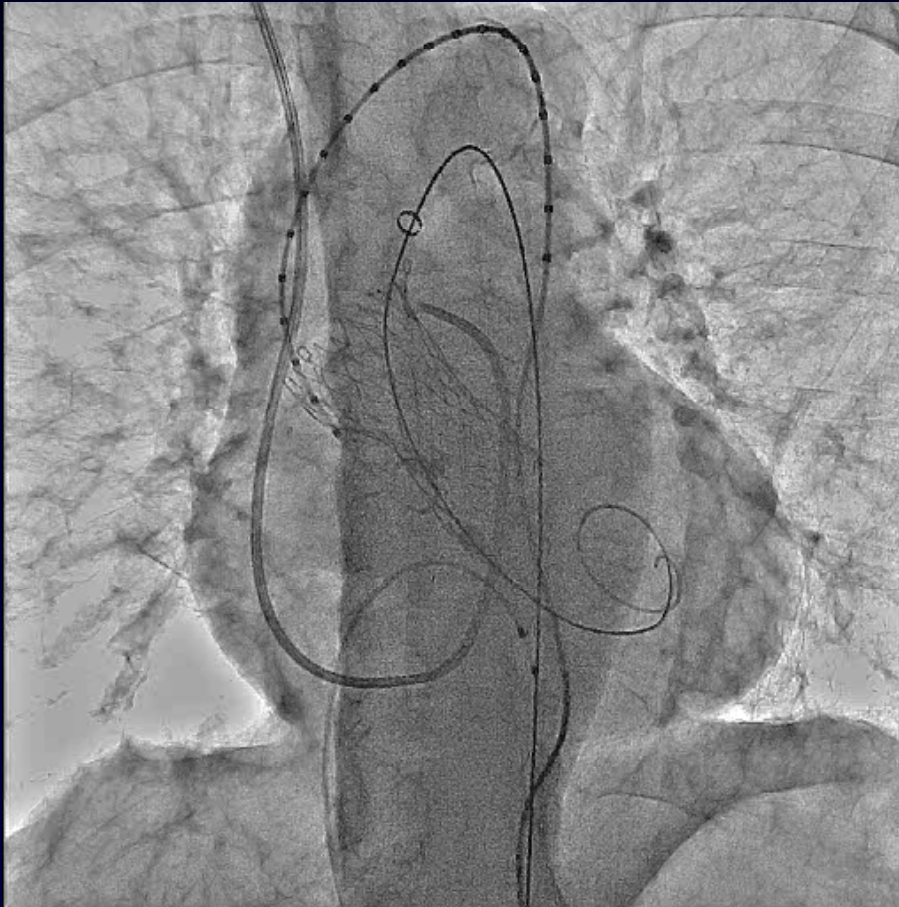

Deeply located valve



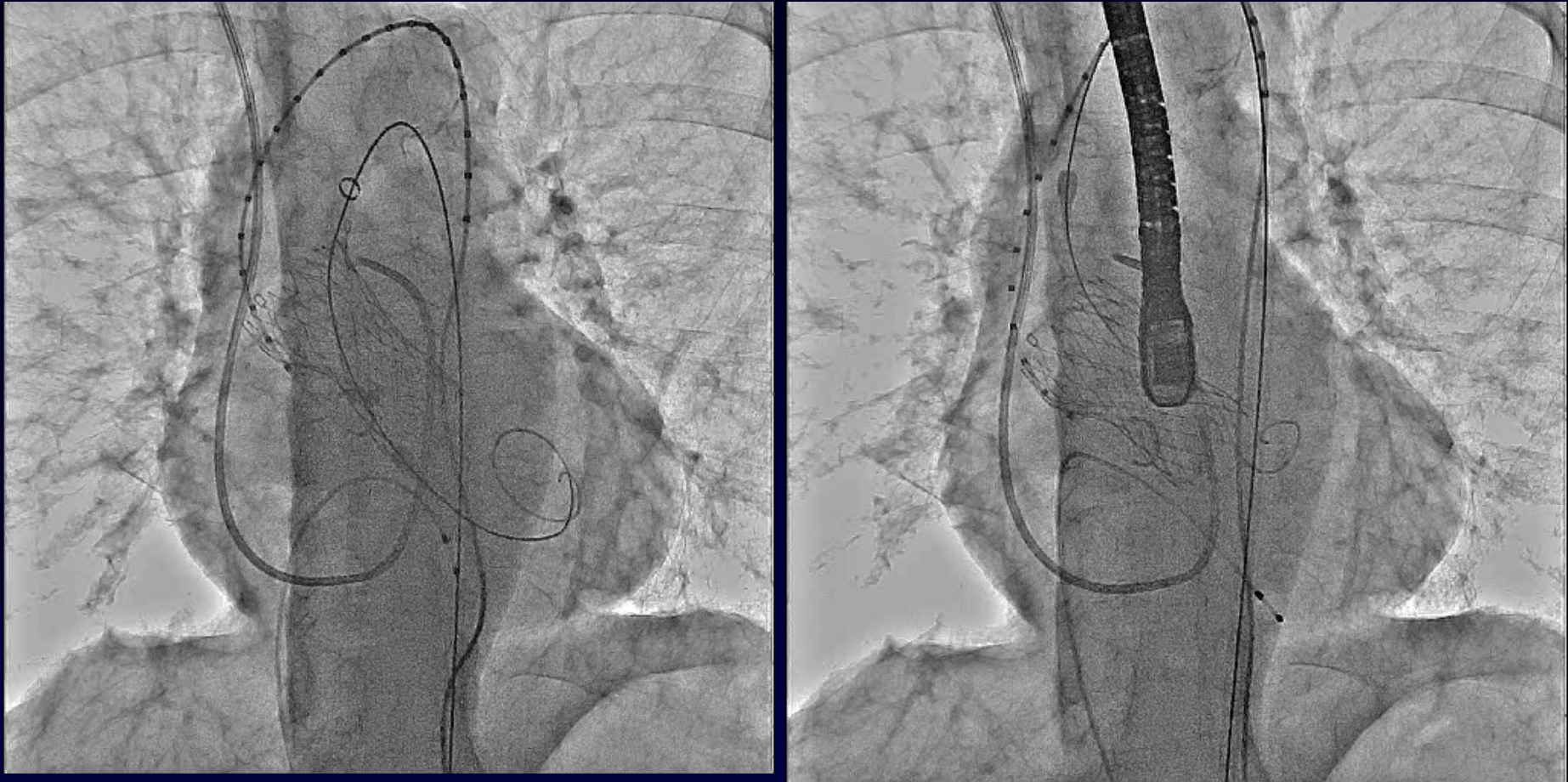
Pull the valve back with delivery system

TAVI procedure



Anchors are not fully released!!

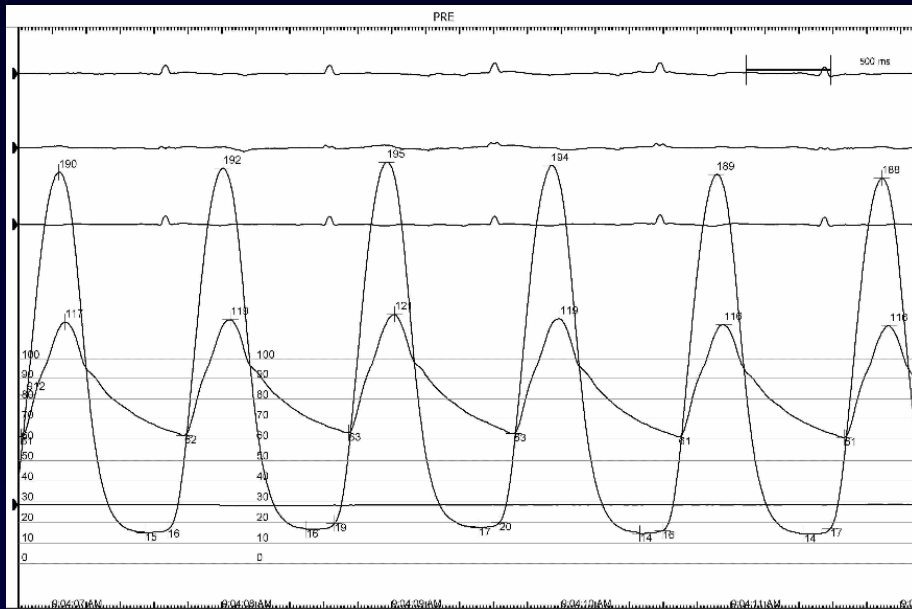
TAVI procedure



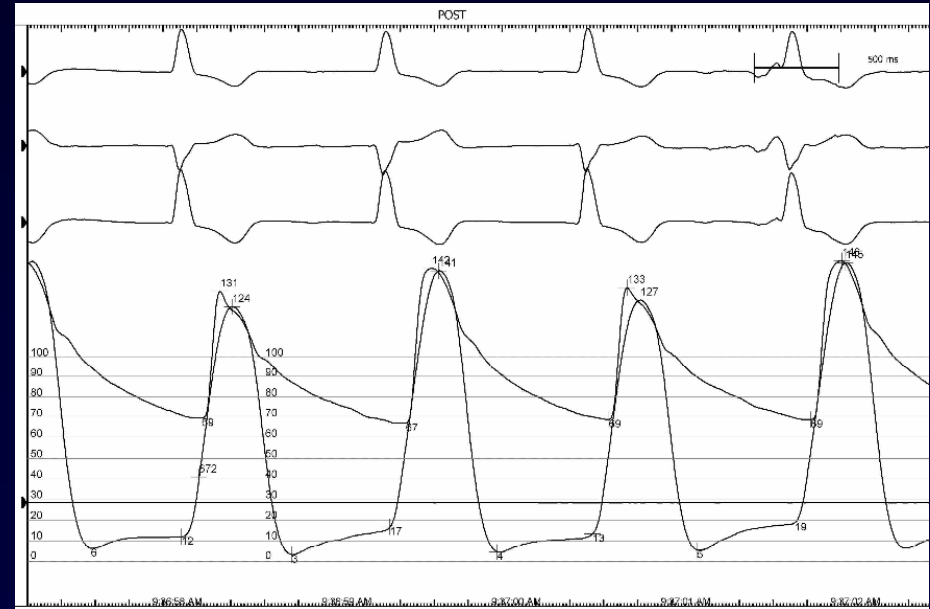
Now, Anchors are fully released!!

Cardiac catheterization

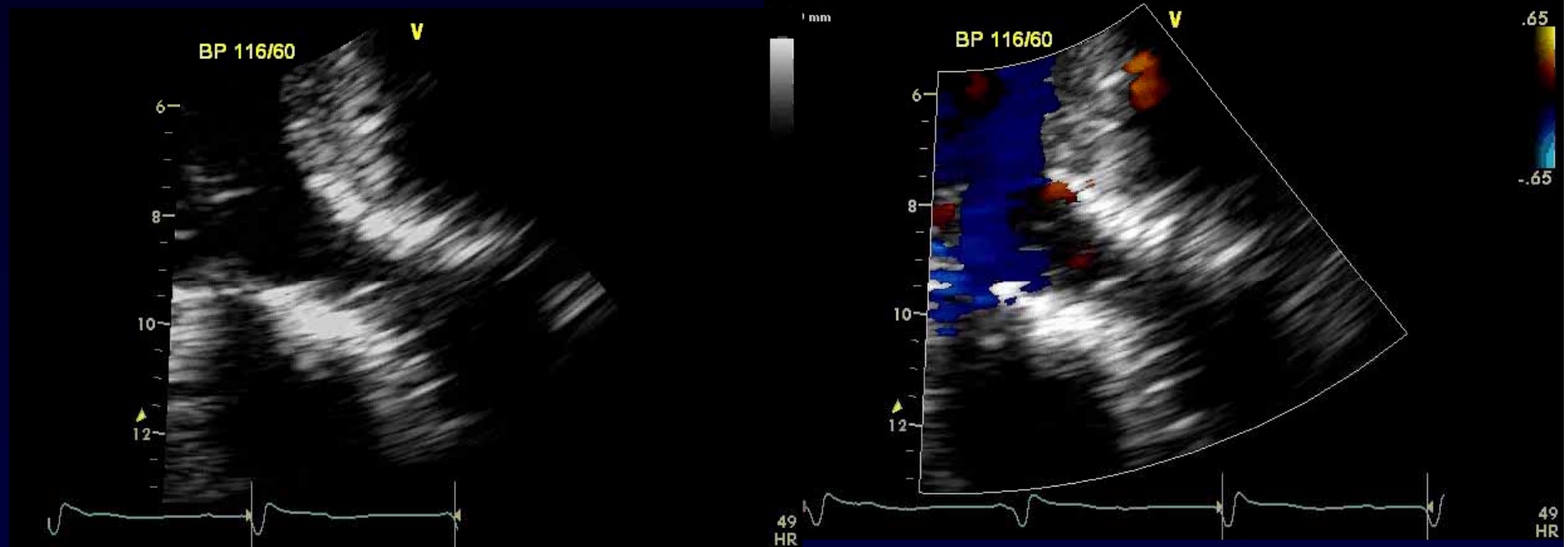
Pre



Post

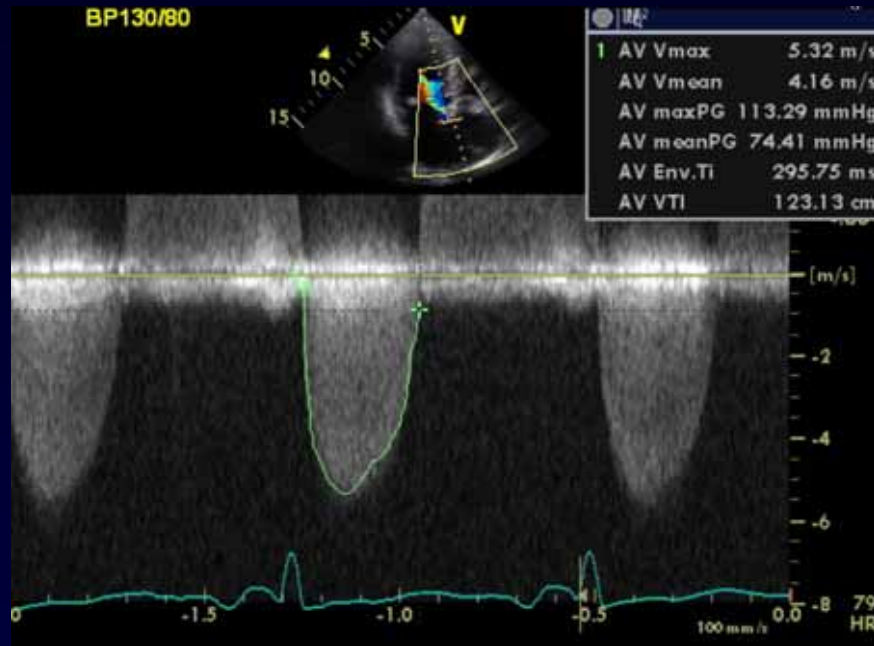


TTE (Post)

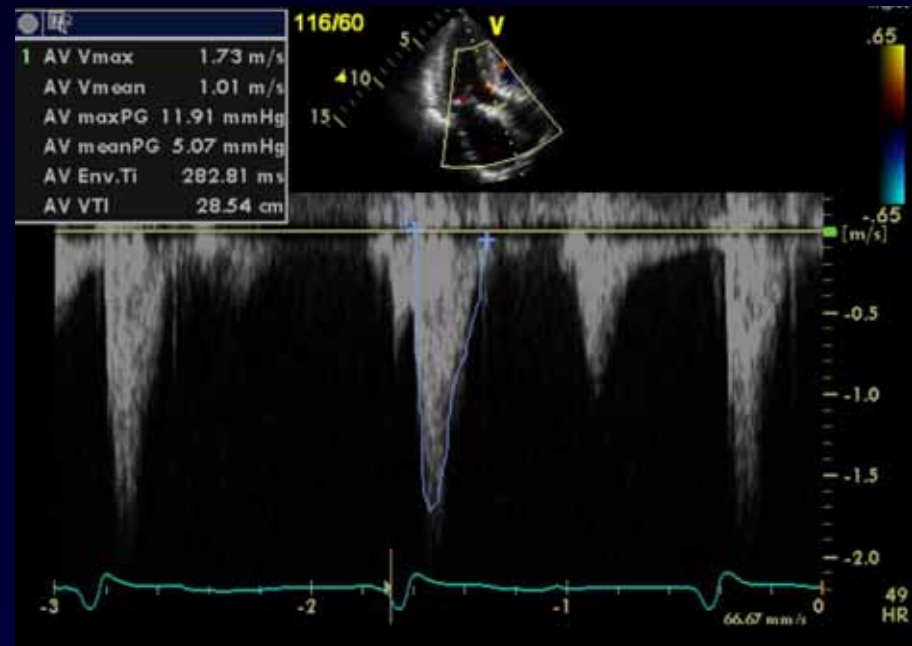


Change of pressure gradient

Pre



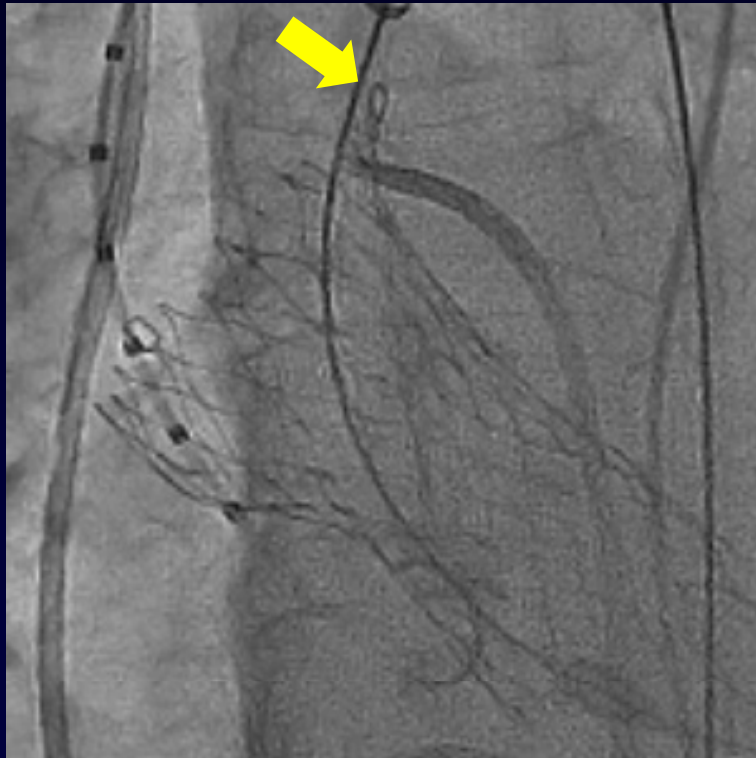Post



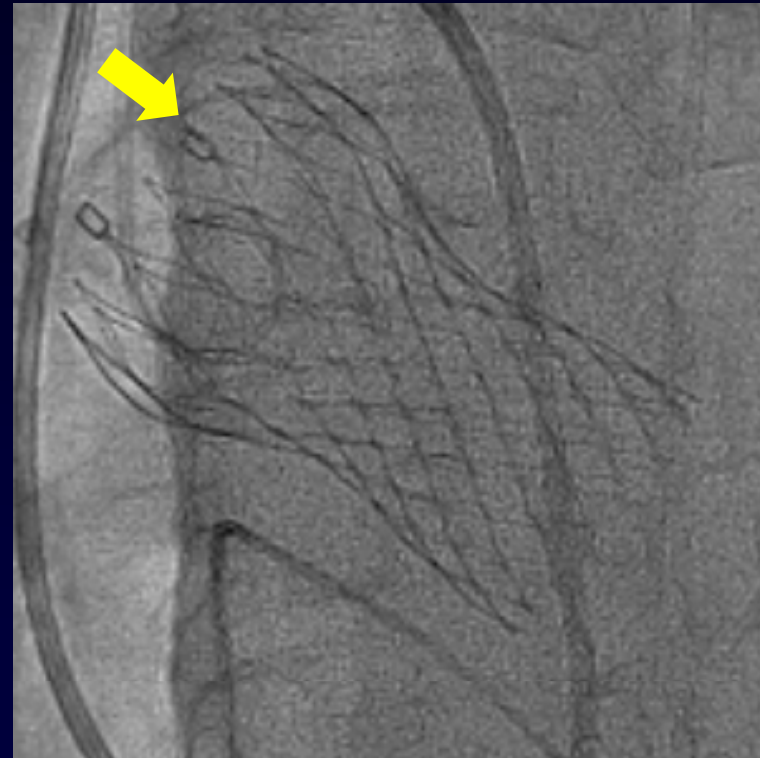Peak/mean pressure gradient: 113/74mmHg ->12/5 mmHg

Conclusion

Anchor, not released



Anchor, released



Look carefully!!