

Role of IVUS and OCT in Left Main PCI

Akiko Maehara, MD

Columbia University Medical Center
Cardiovascular Research Foundation
New York City, NY

Disclosure Statement of Financial Interest

Within the past 12 months, I or my spouse/partner have had a financial interest/arrangement or affiliation with the organization(s) listed below.

Affiliation/Financial Relationship

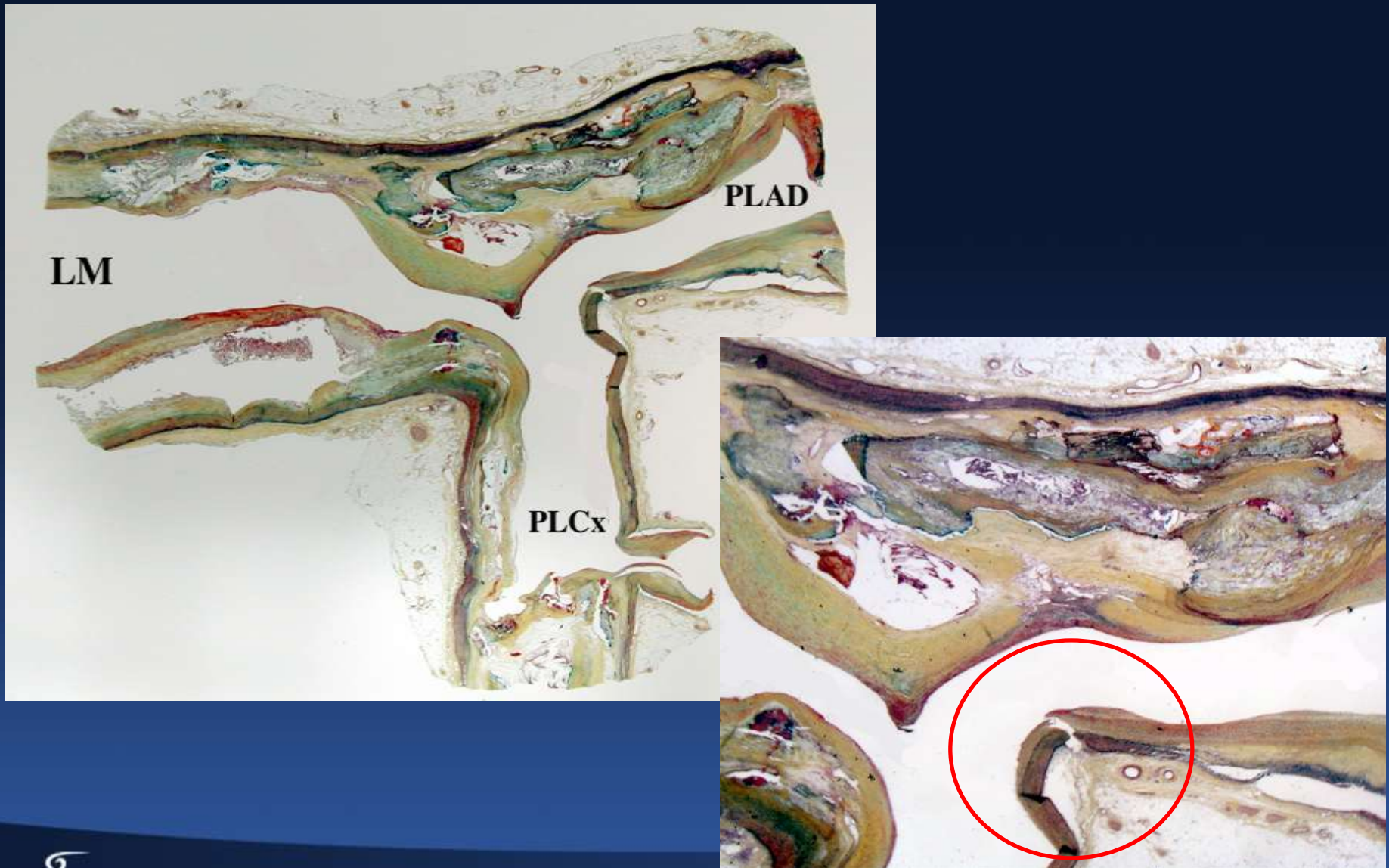
- Grant/Research Support
- Consulting Fees/Honoraria
- Speaker Fee

Company

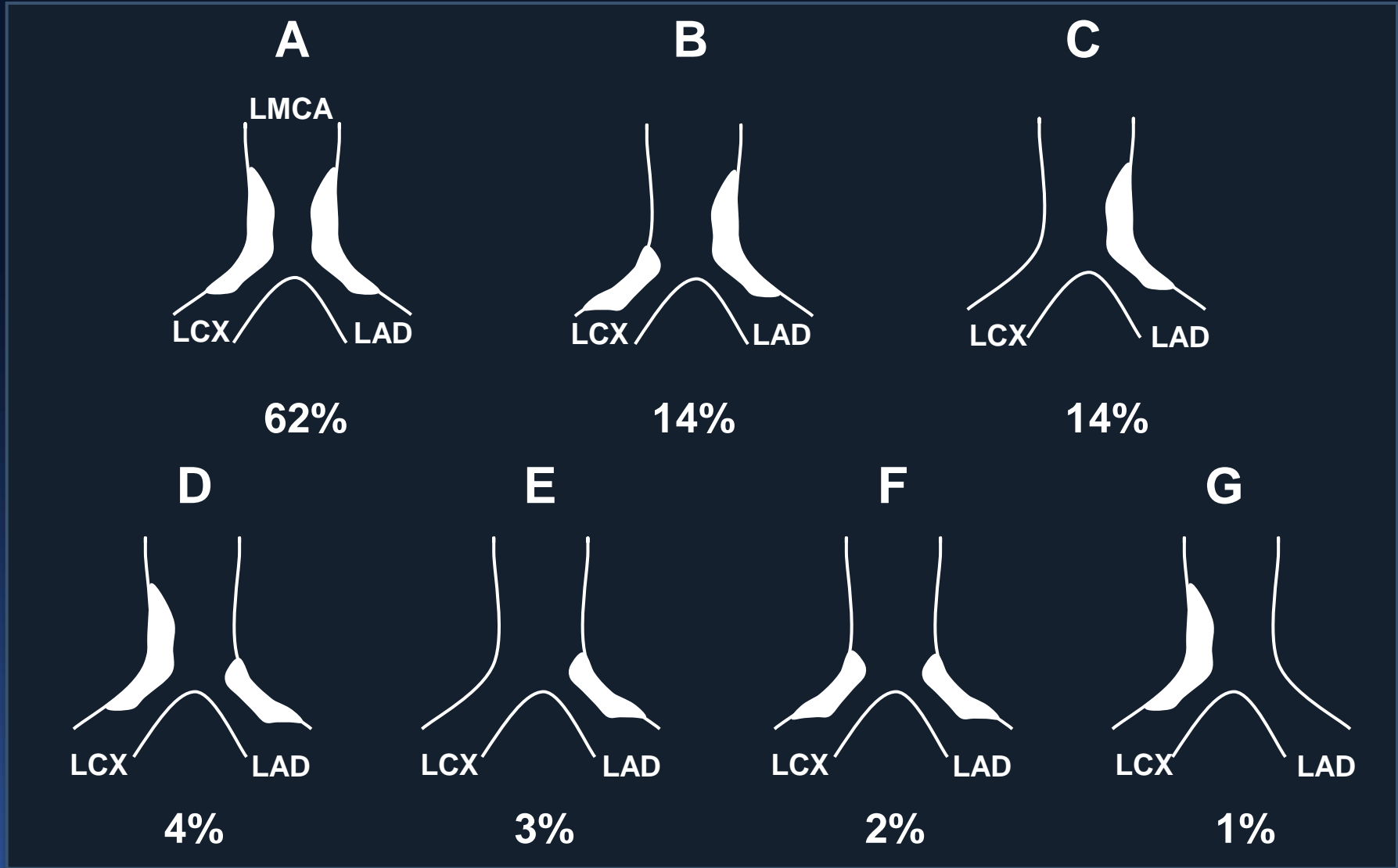
- Boston Scientific Corporation
- Boston Scientific Corporation, ACIST
- Volcano Corporation, St Jude Medical

Nature of Left Main Disease and Diagnosis

Plaque Formation in Left Main

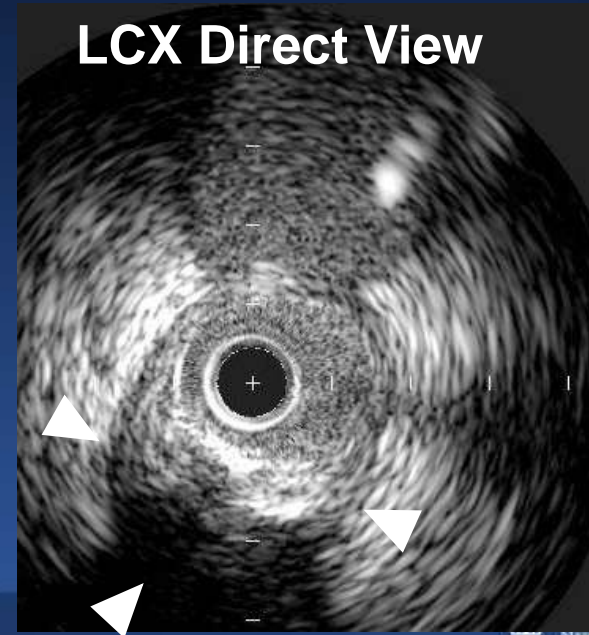
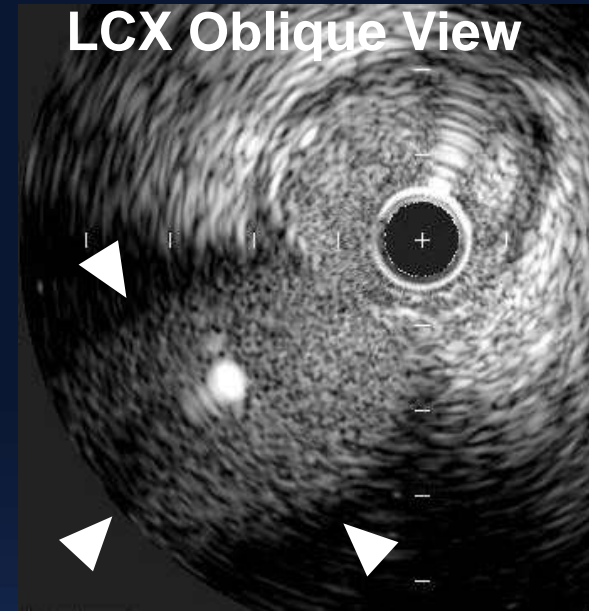
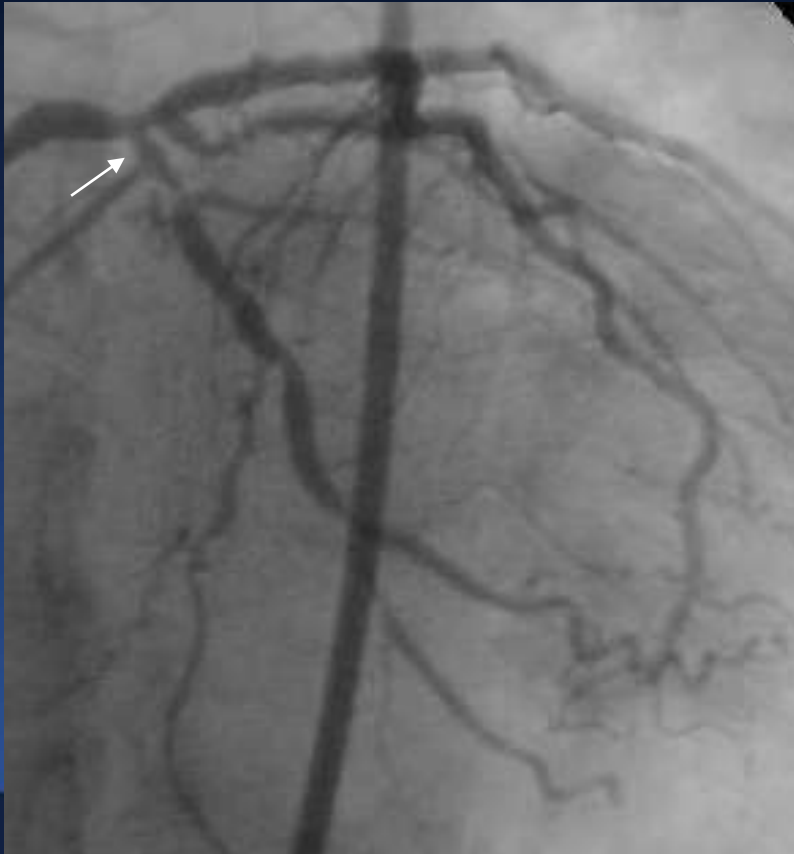

Plaque Distribution by IVUS (n=140)



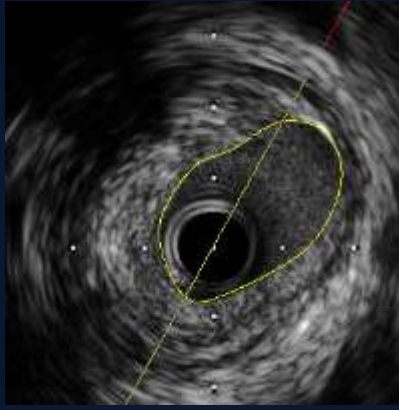
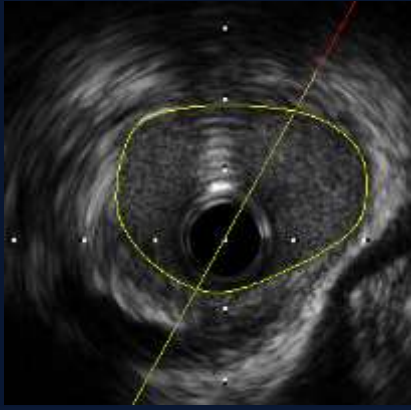
90% of lesions distribute from LMCA-LAD

- Though you don't see anything, this is not true.
- If you see something, this may be true.



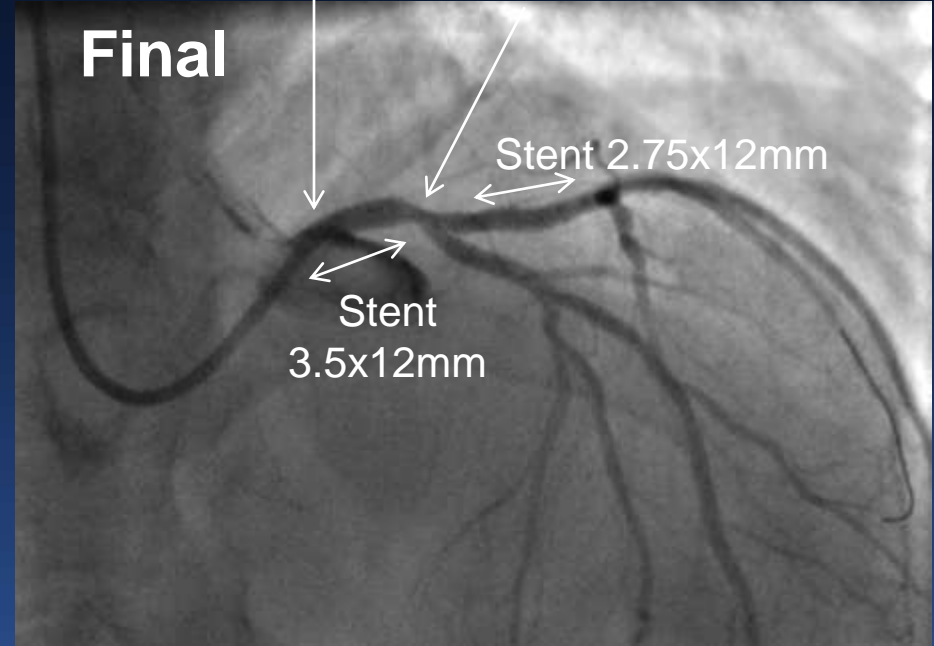
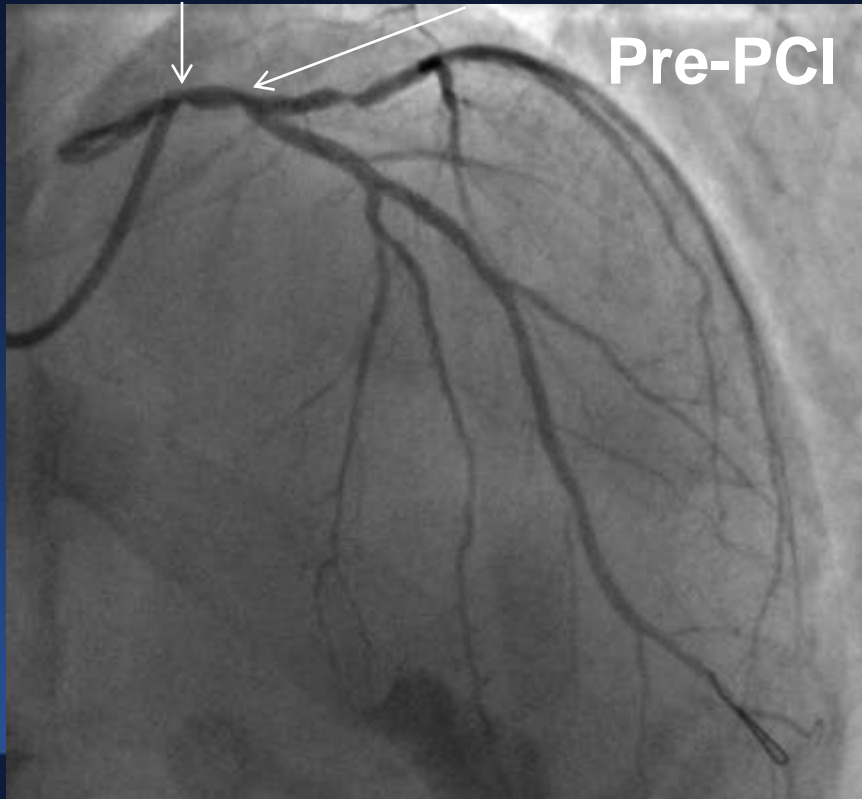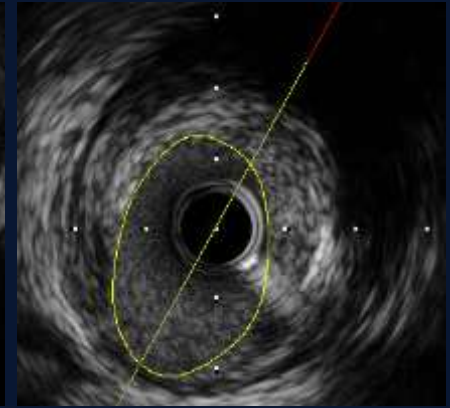
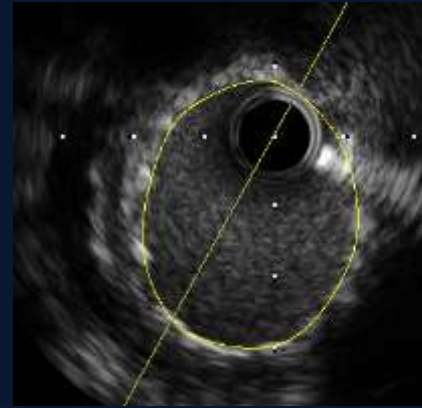
Ostium: 7.2mm²

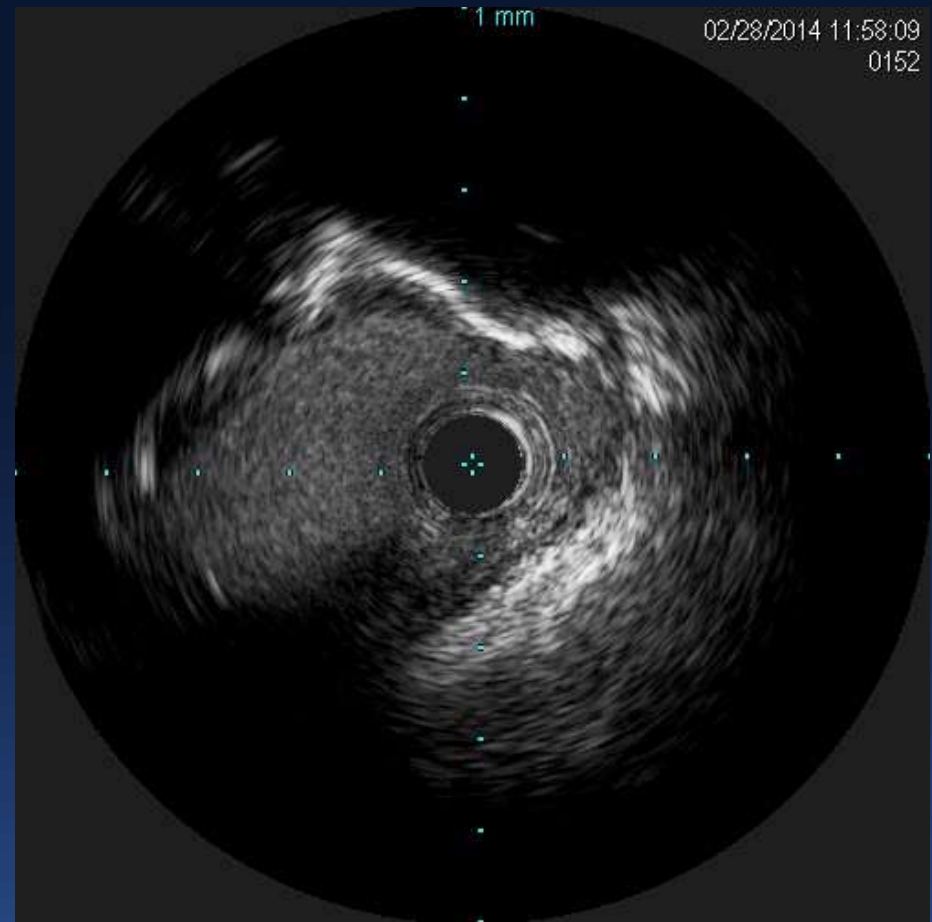
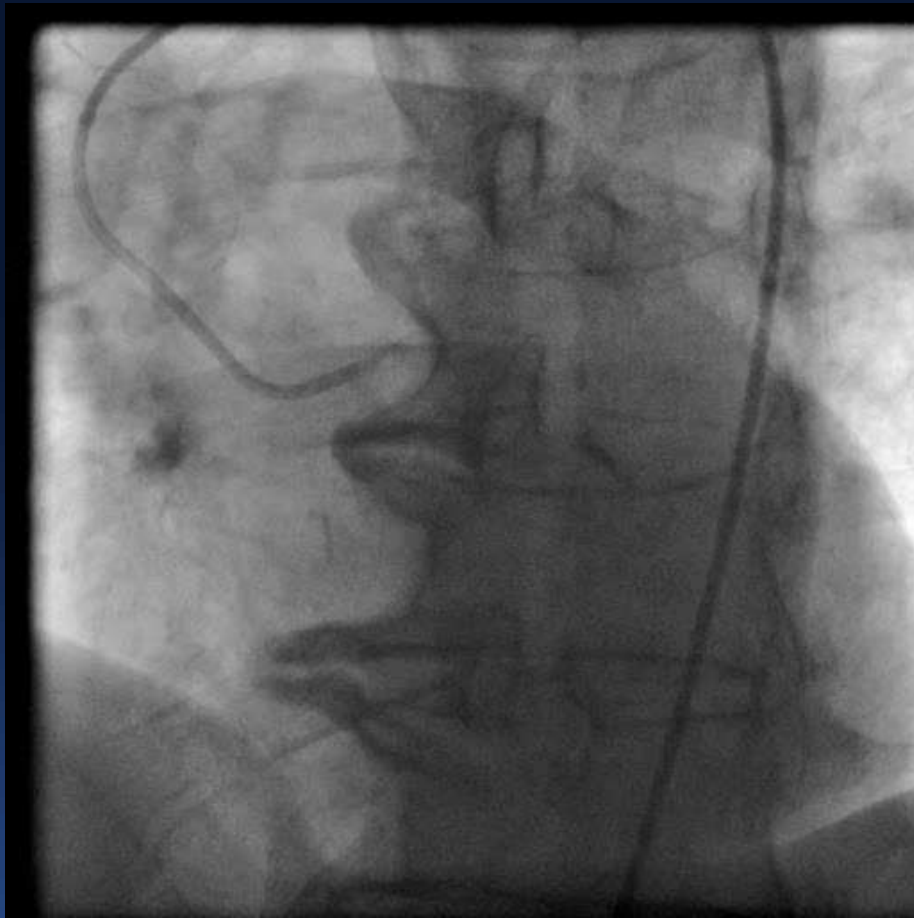
Distal LM: 4.3mm²



Ostium: 8.8mm²

Distal LM: 5.7mm²

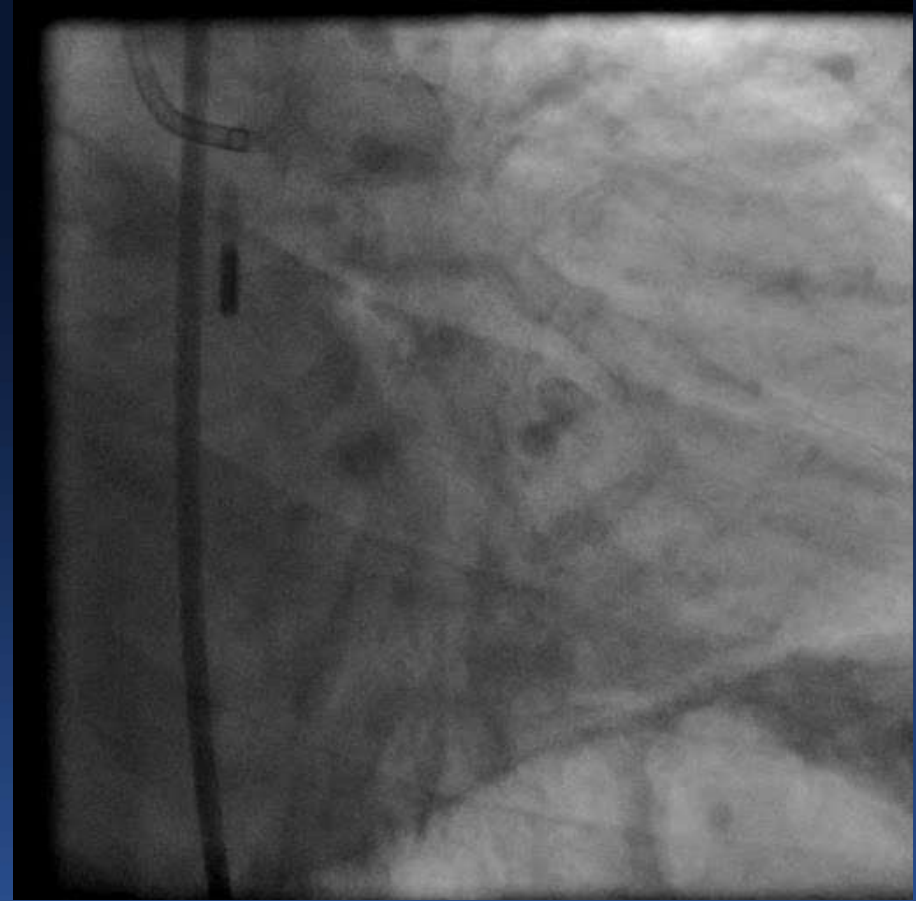
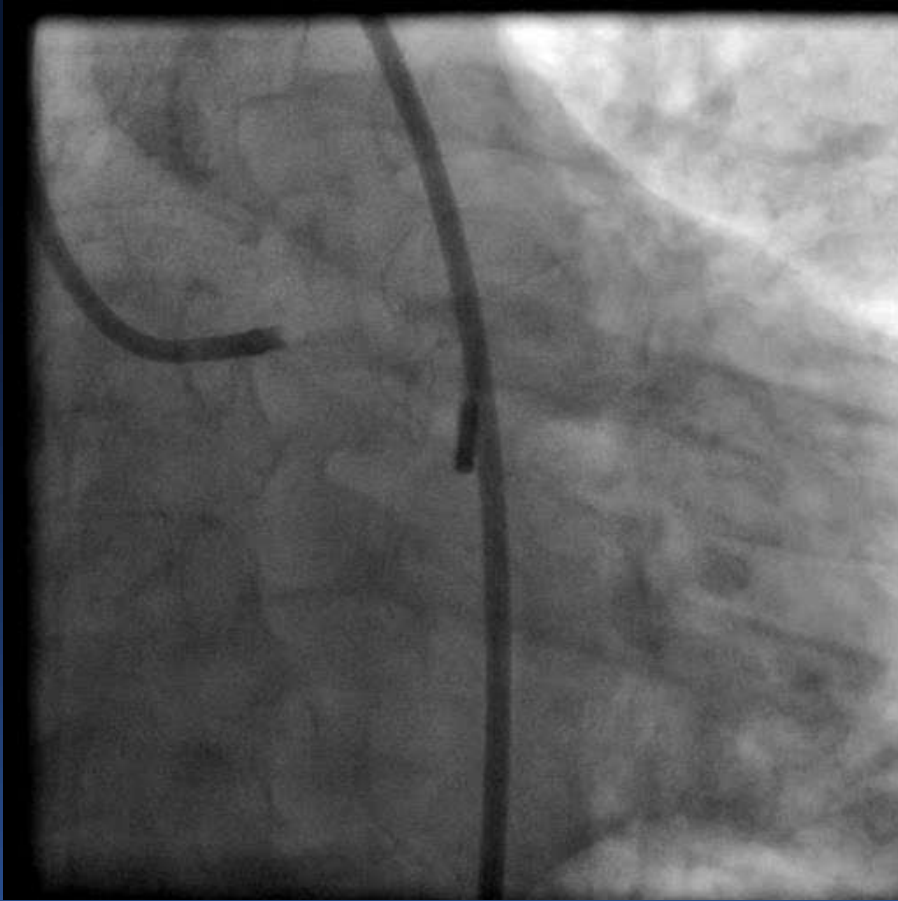


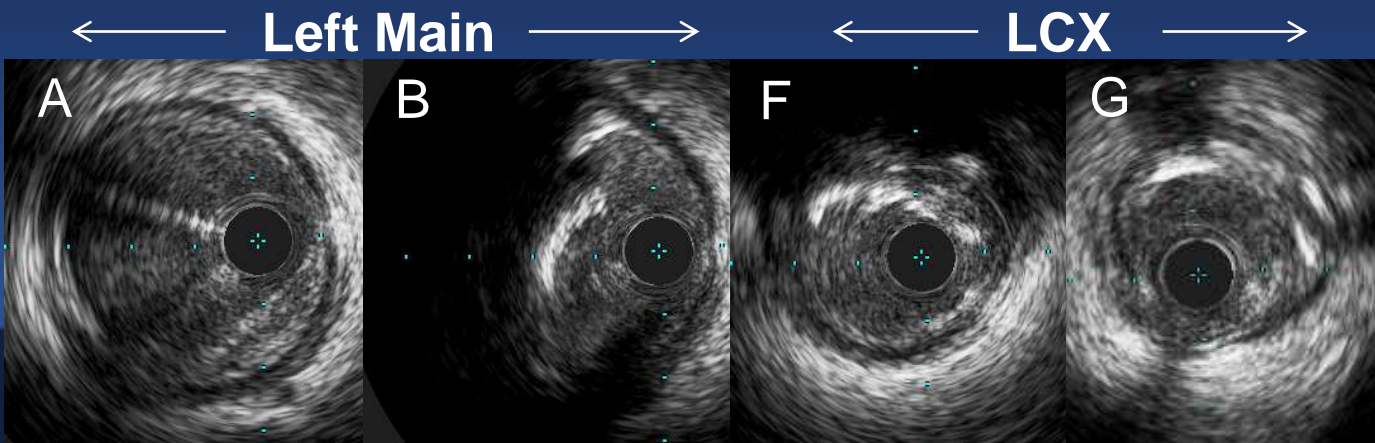
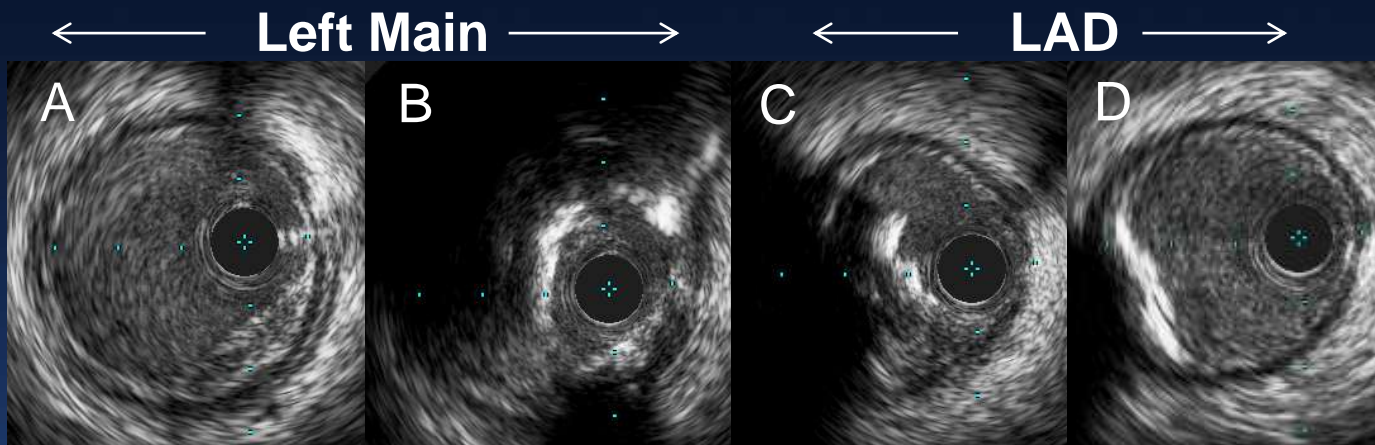
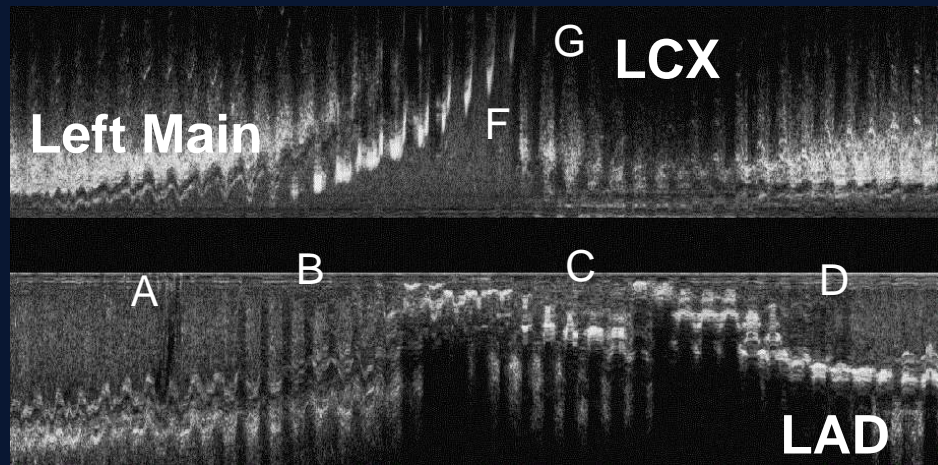
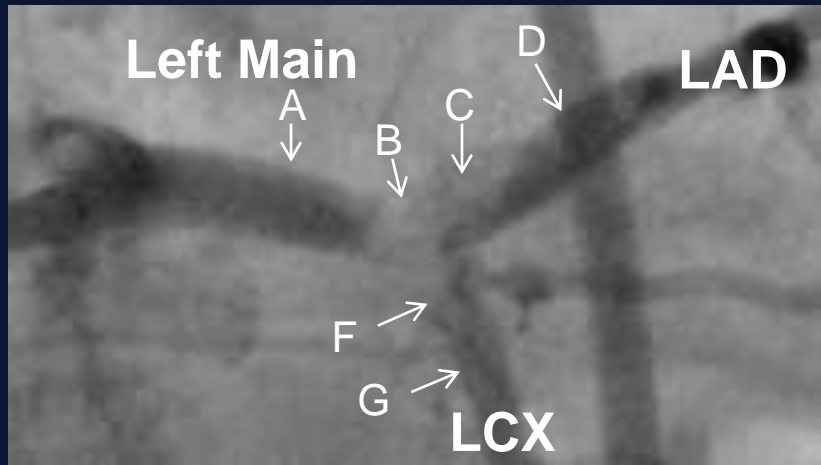


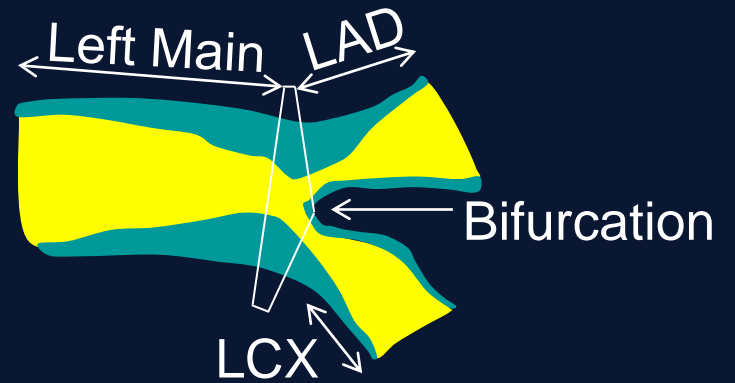
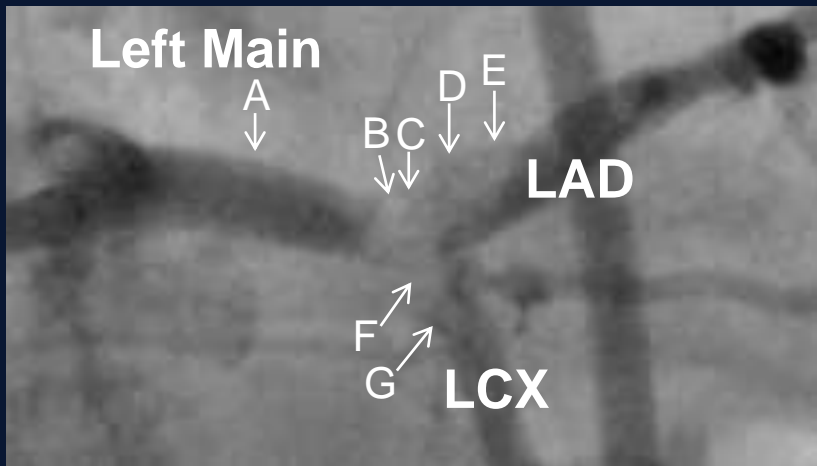
Minimum Lumen Area=4.3mm²

Optimal Left Main Stenting

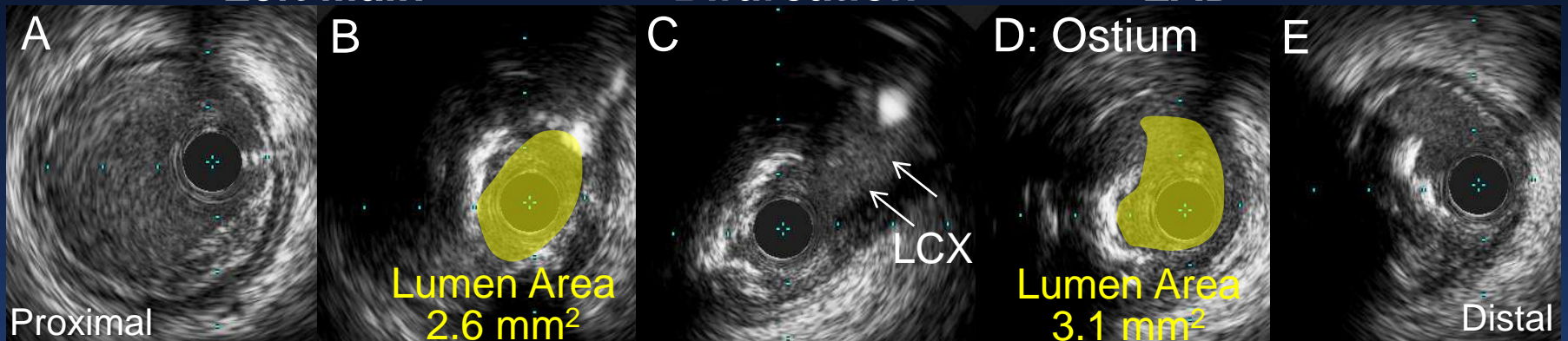
Optimal Stent Expansion



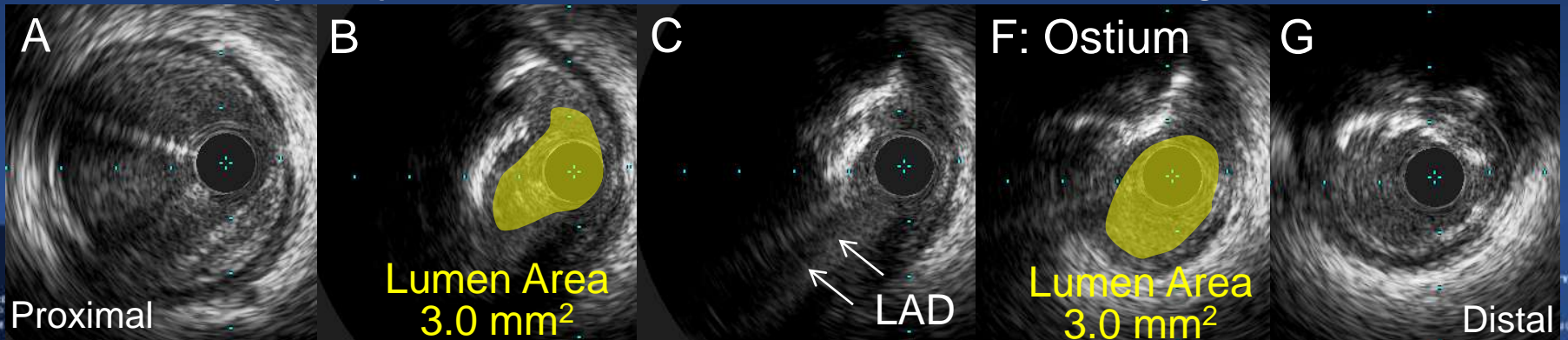


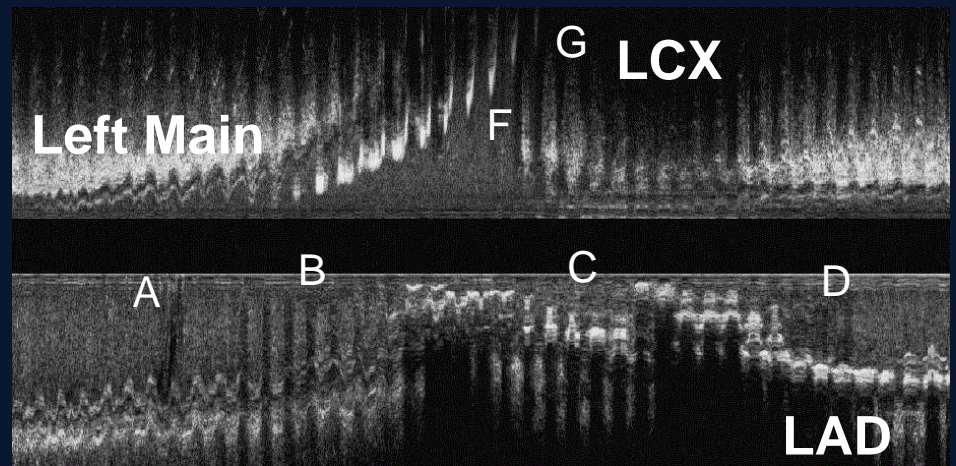
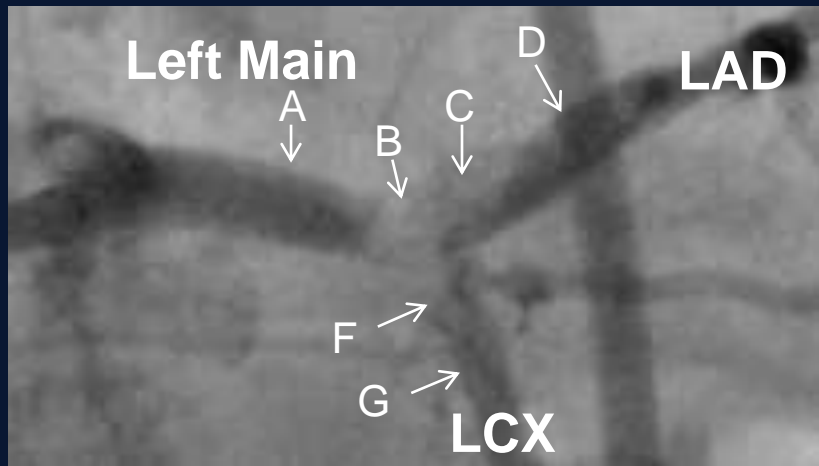


← Left Main → ← Bifurcation → ← LAD →



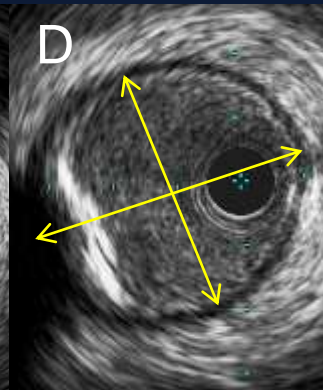
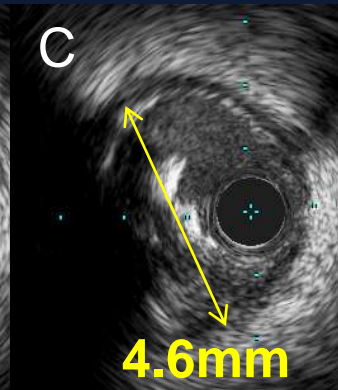
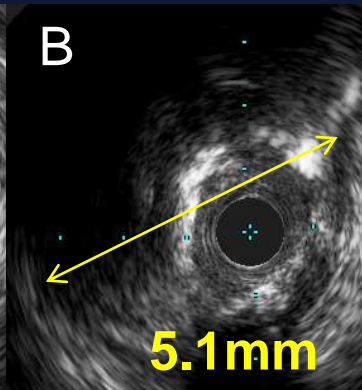
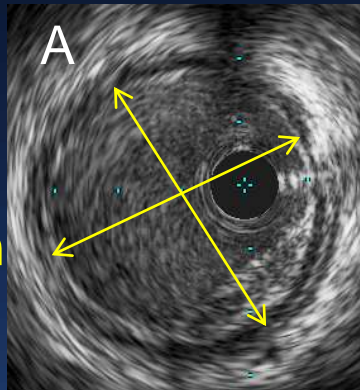
← Left Main → ← Bifurcation → ← LCX →





← Left Main →

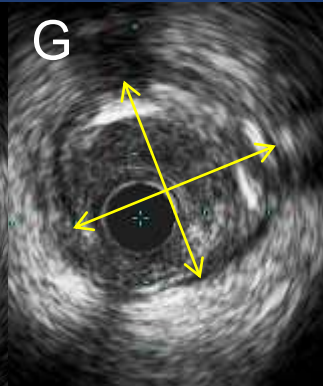
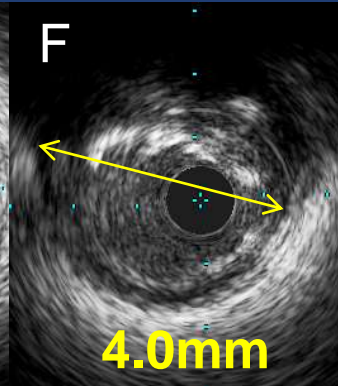
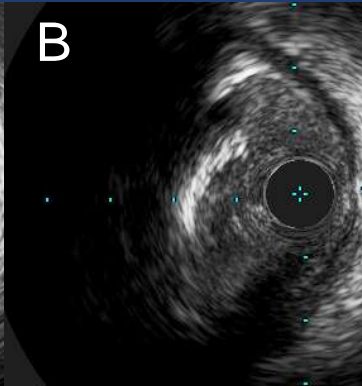
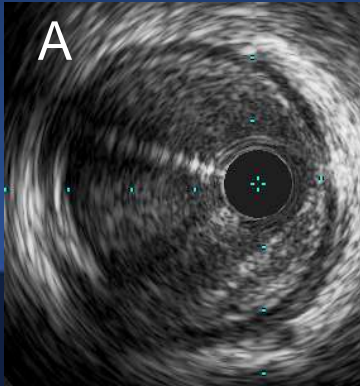
← LAD →



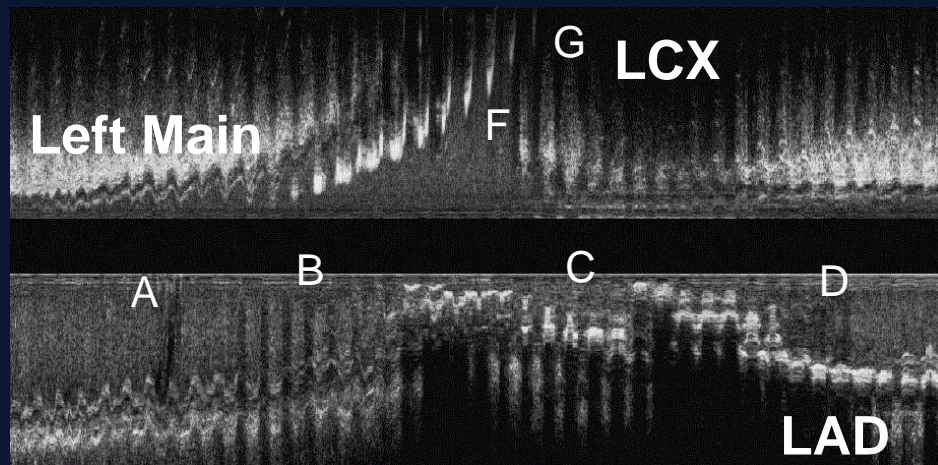
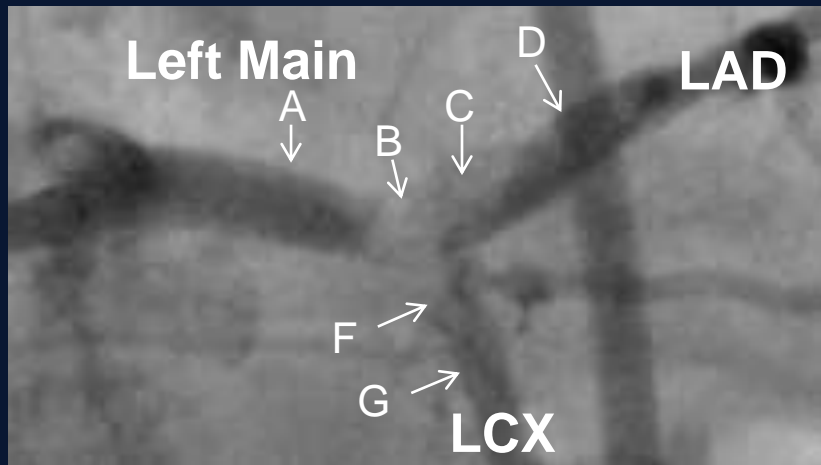
4.6mm ×
4.0mm

← Left Main →

← LCX →

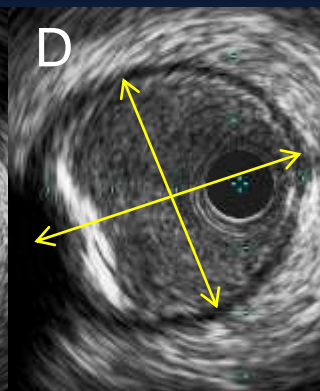
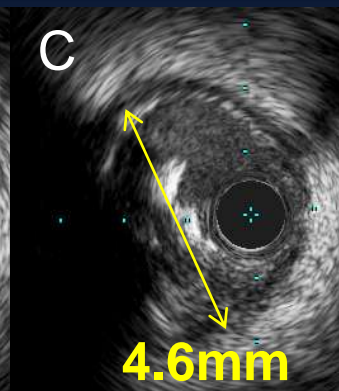
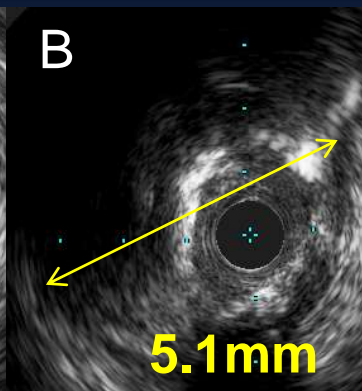
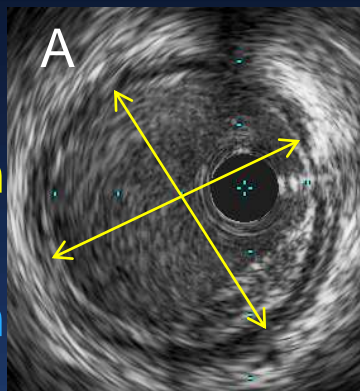


3.5mm ×
3.4mm



← Left Main →

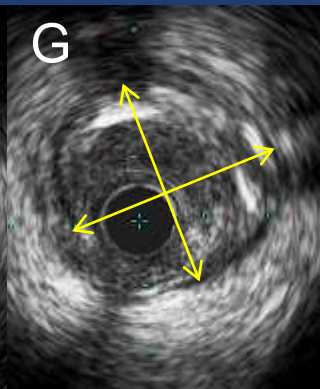
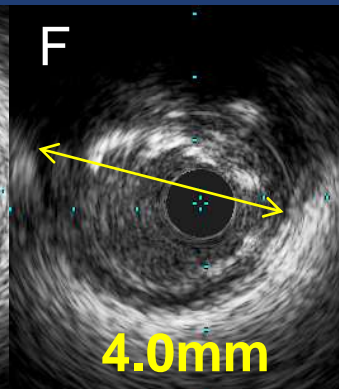
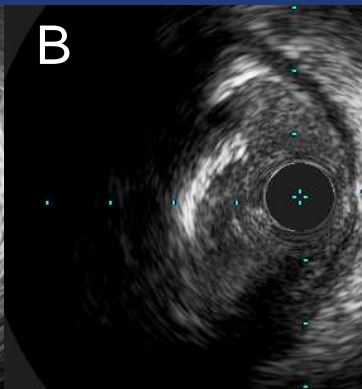
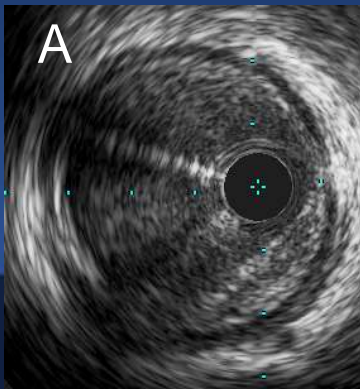
← LAD →



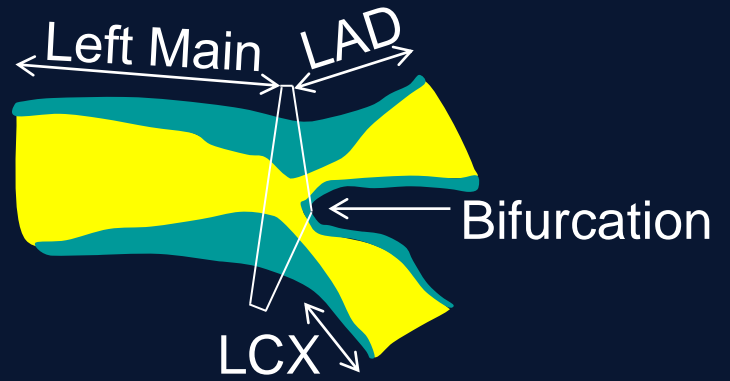
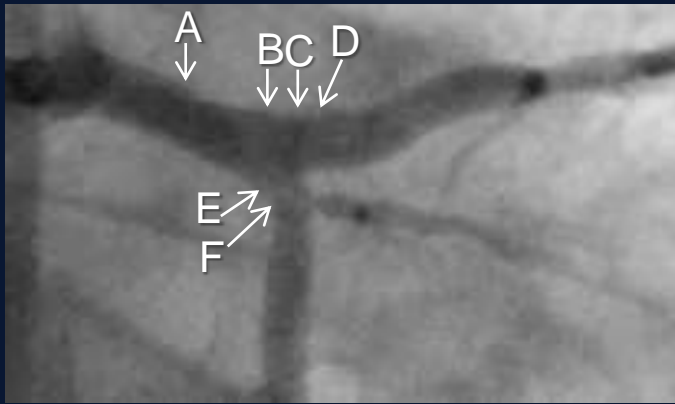
4.6mm × 4.0mm
3.4mm × 3.2mm

← Left Main →

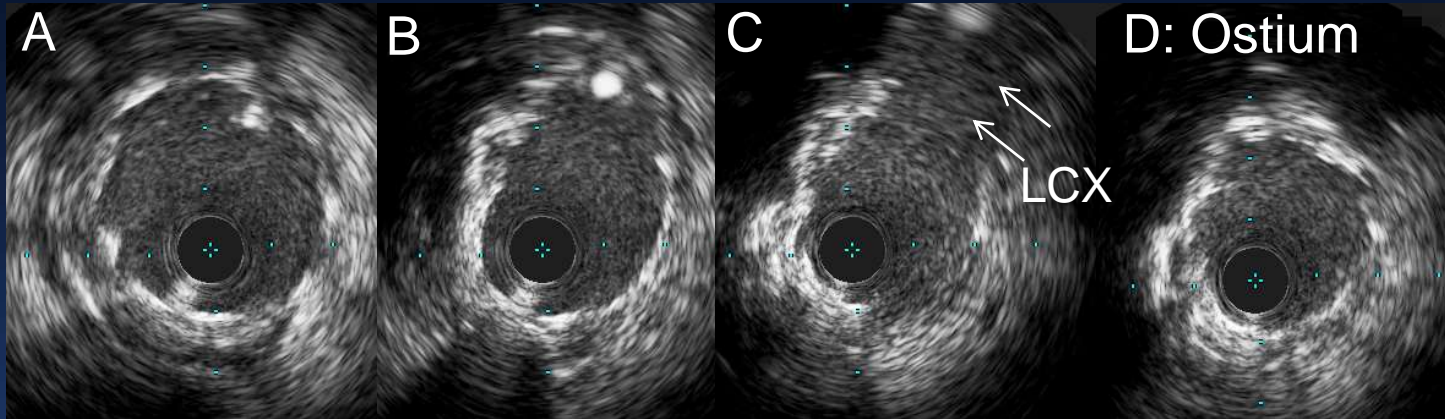
← LCX →



3.5mm × 3.4mm
2.3mm × 2.4mm

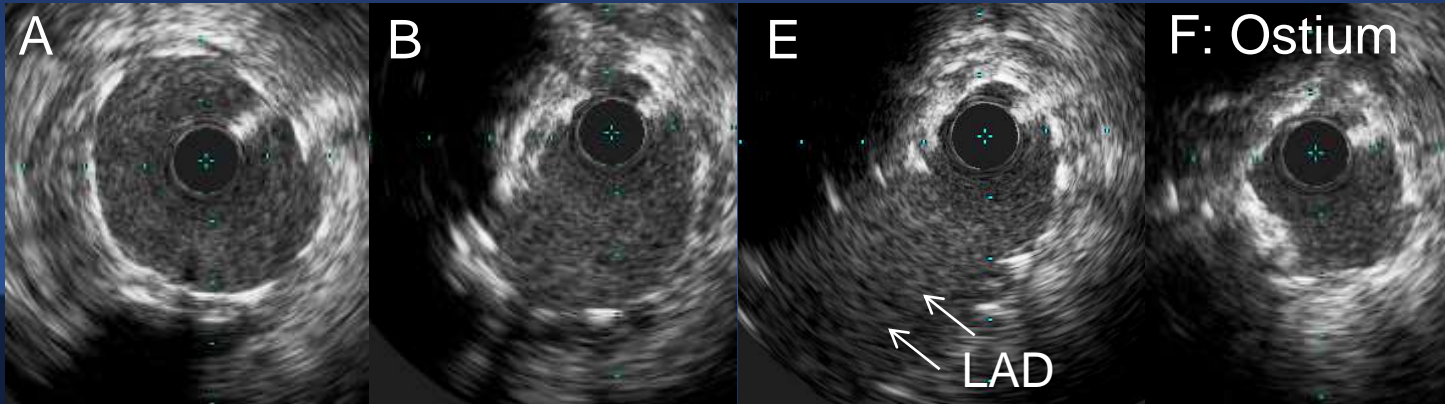


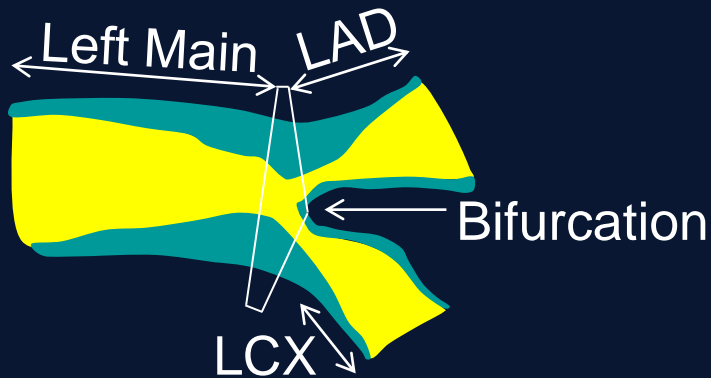
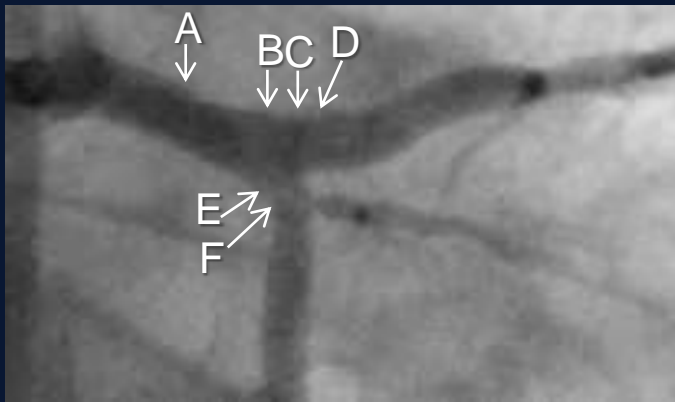
← Left Main → Bifurcation ← LAD →



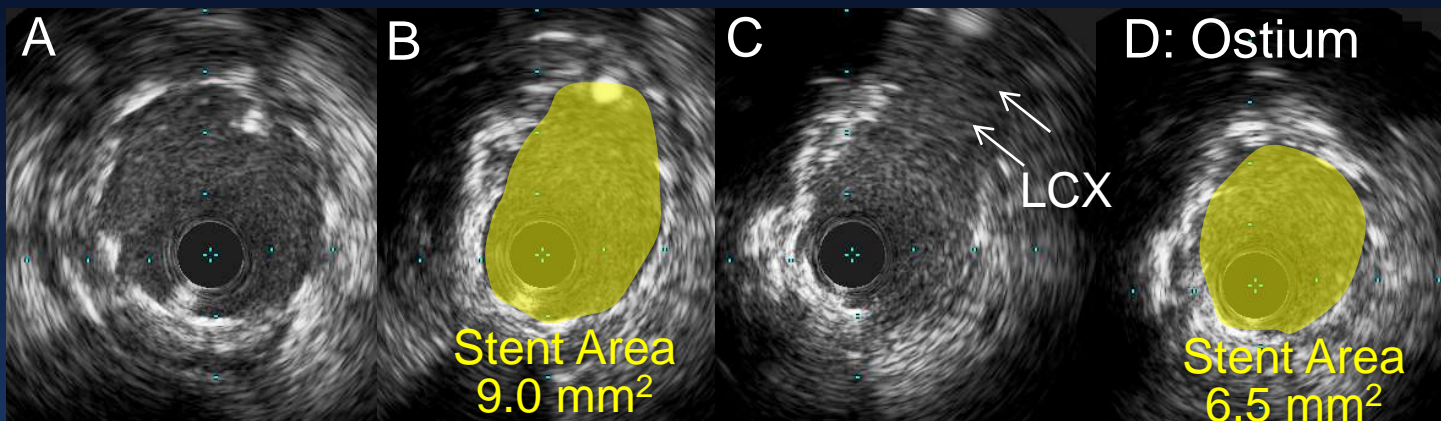
Proximal Distal

← Left Main → Bifurcation ← LCX →

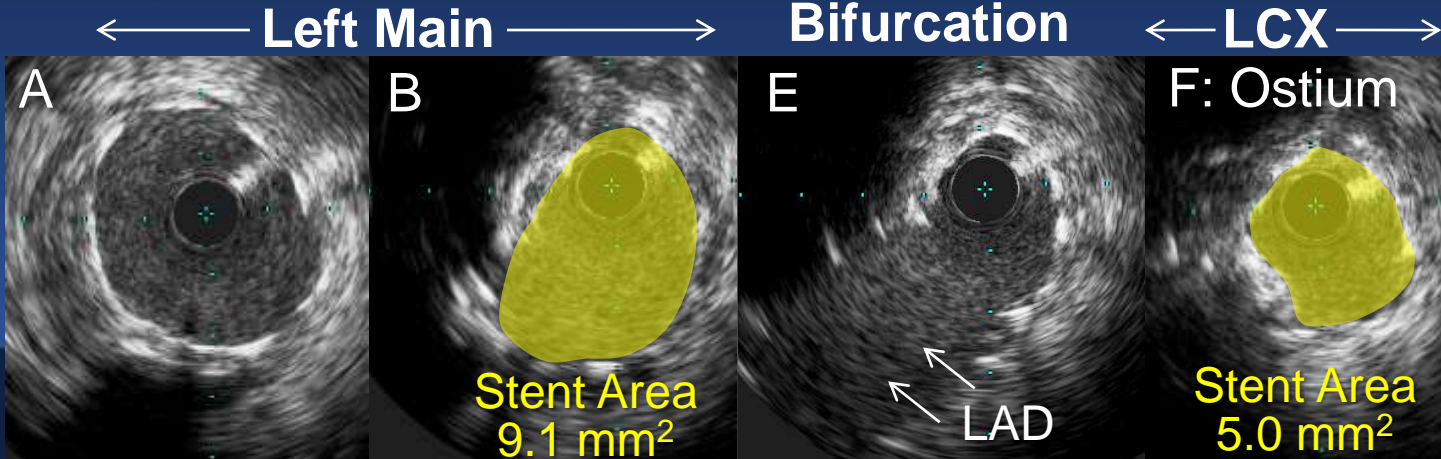




← Left Main → Bifurcation ← LAD →

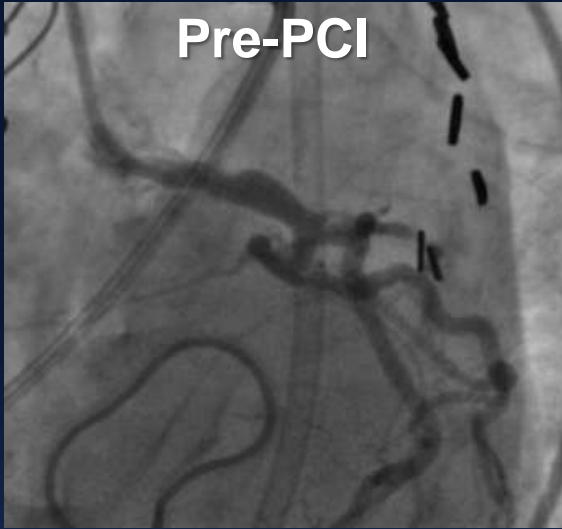


Proximal ← Left Main → Bifurcation ← LCX → Distal

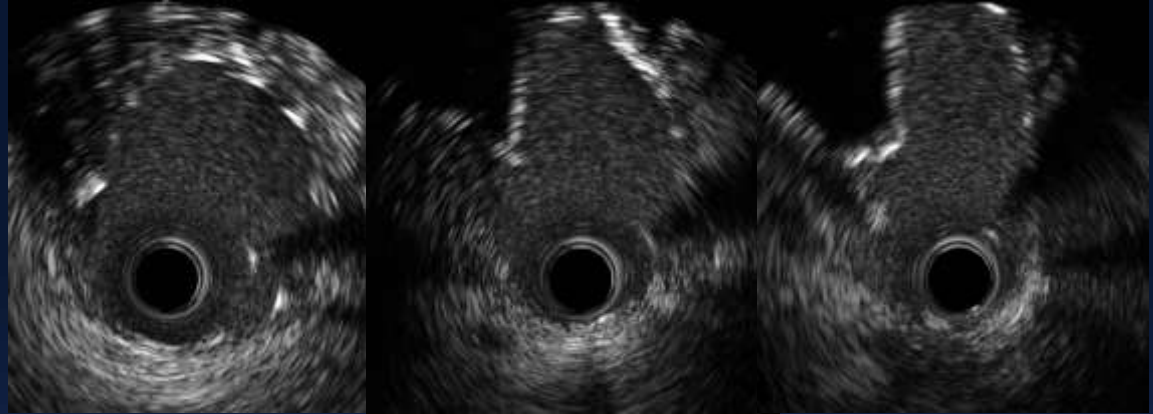

Evaluation of Ostium

Pre-PCI

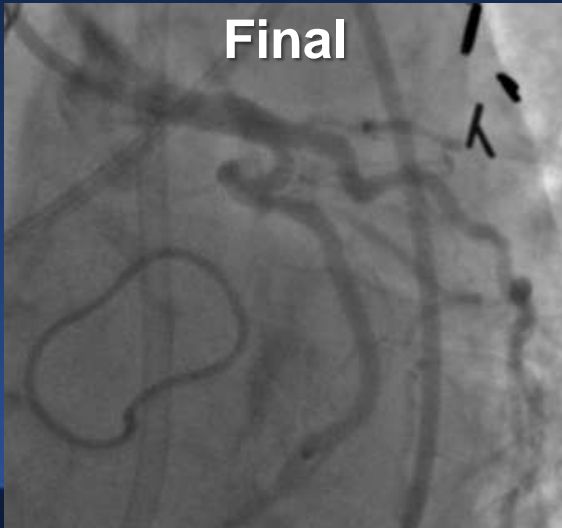

Guiding Engaged

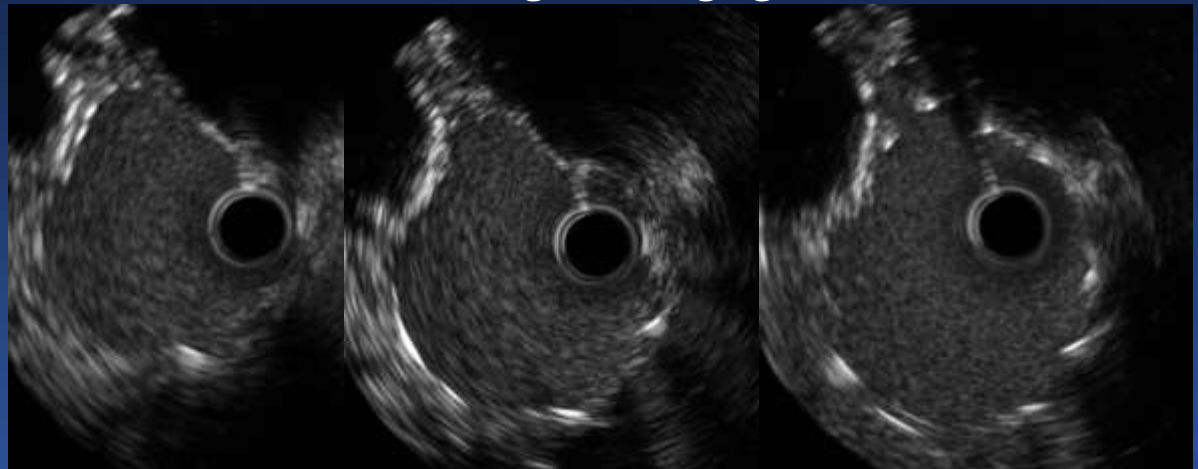


Minimum Lumen Area 7.9 mm²

Final

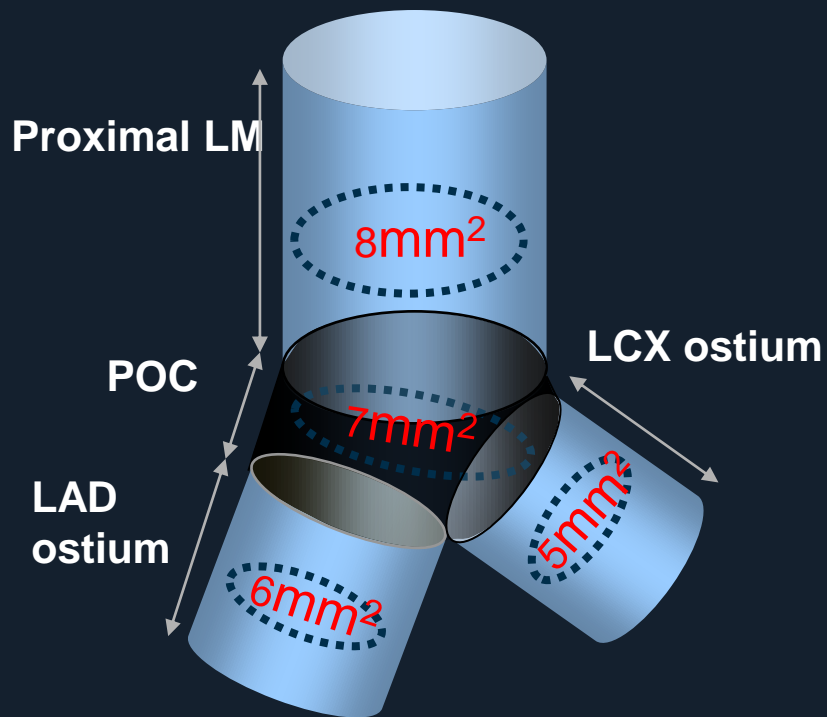


Guiding Disengaged

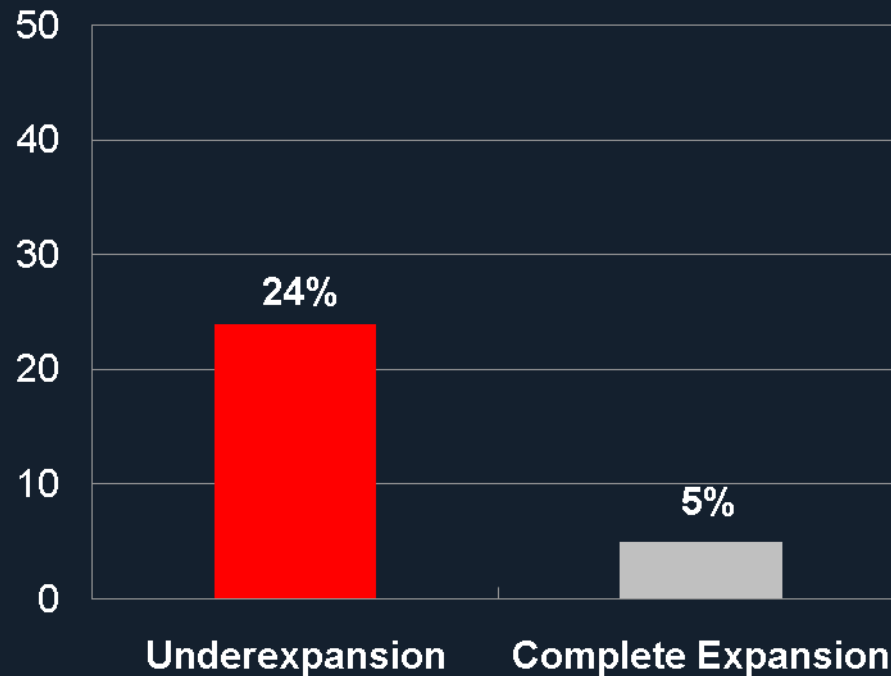


Minimum Lumen Area 12.4 mm²

Optimal Stent Cross Sectional Area After LM 2 Stenting



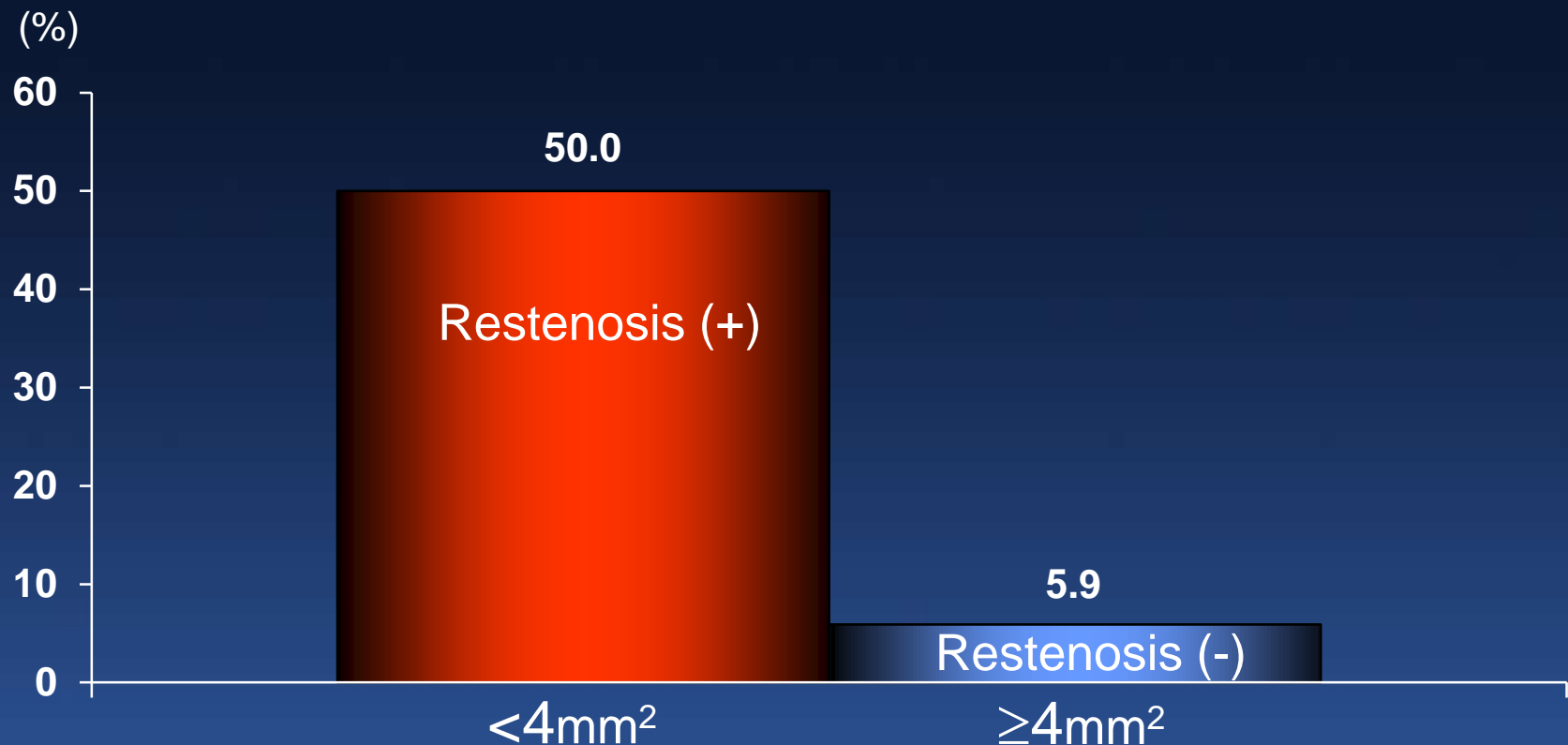
ISR Rate



Kang et al. Circ Cardiovasc Interv 2011 2011;4:1168-74

Predictor of Restenosis in Ostial LCX with both LAD/LCX IVUS Evaluation

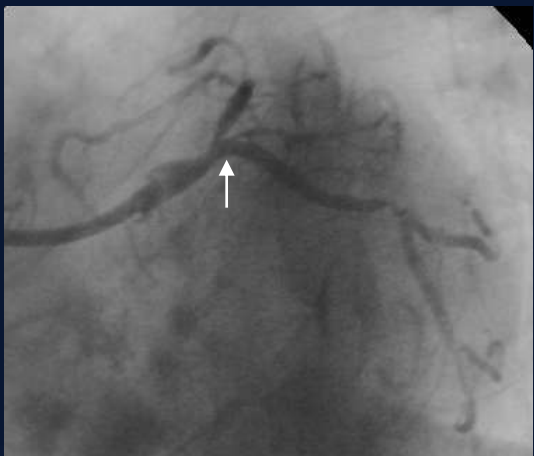Post LCX Minimum Lumen Area



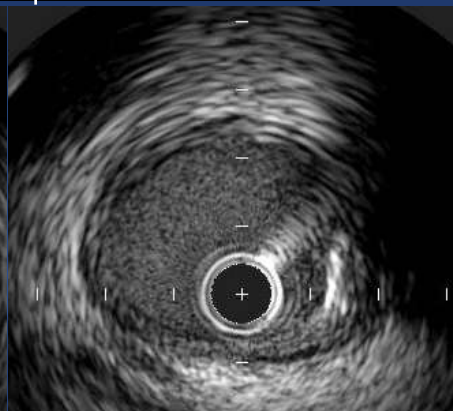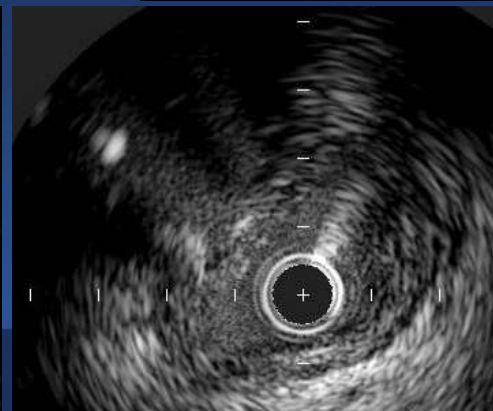
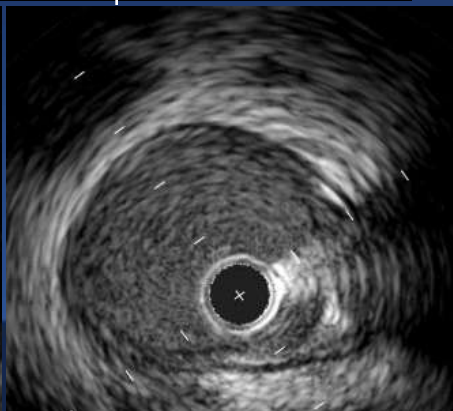
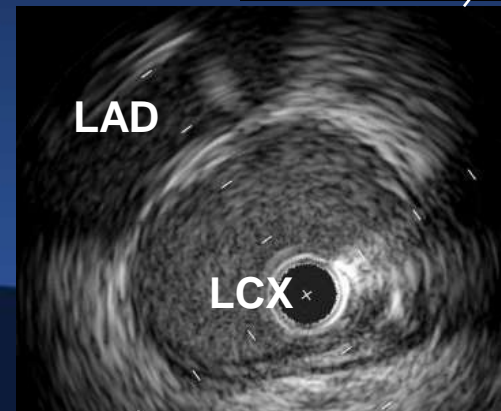
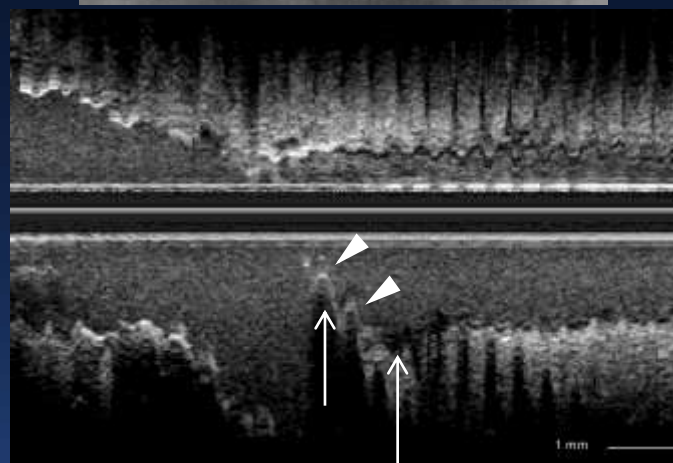
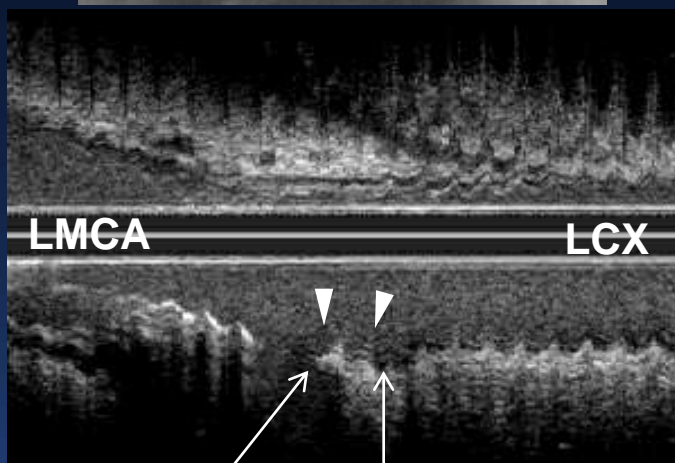
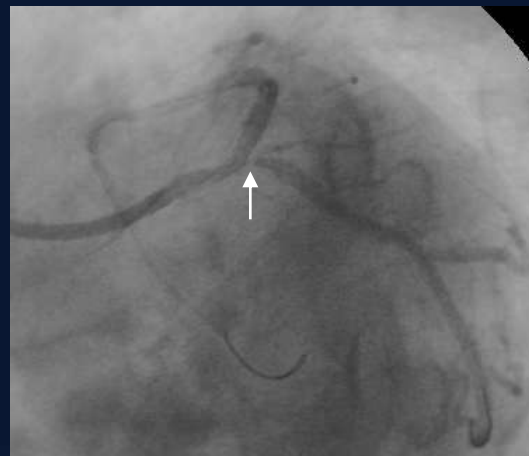
Carina Shift and Prognosis

Carina Shift

Pre -PCI



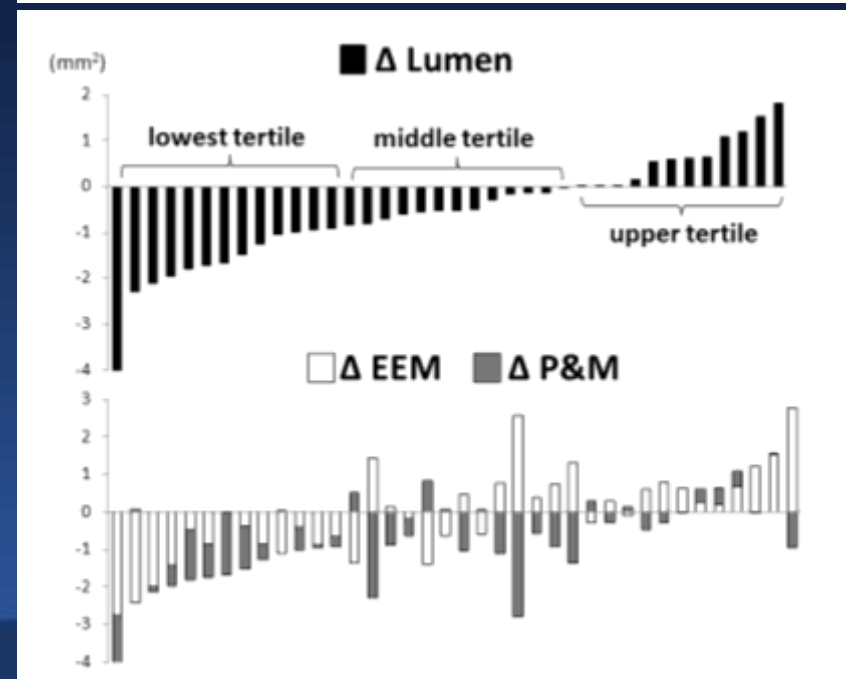
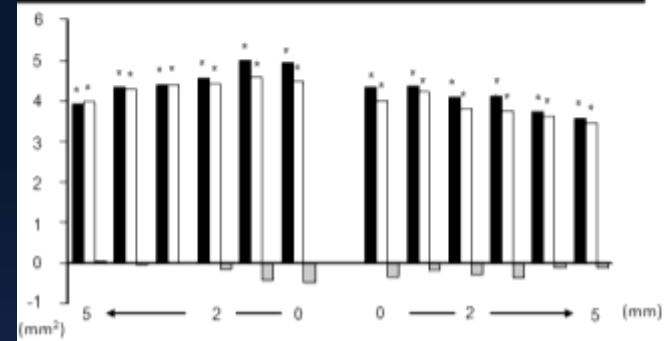
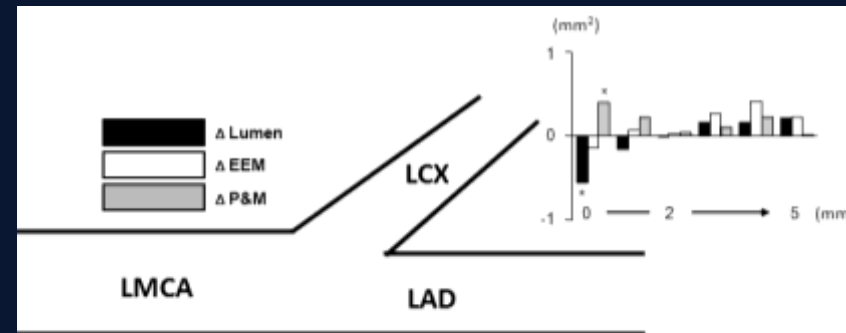
Final



Carina & Plaque Shift

- 38 Pre & Post 3D Comparison -

1. Narrow LAD/LCX Angle
2. Less Plaque Burden at LCX Ostium
3. 60% of Lumen Decrease Due to Carina Shift



Outcome of LCX after Cross-Over Stenting

43 Patients with distal LMCA lesions without LCX disease (DS<50%)

LAD-LMCA Cross-Over Stenting

LCX DS>50%
N=18 (42%)

LCX DS≤50%
N=25

FFR<0.8
N=3 (7%)

FFR≥0.8
N=40

KBT
N=2

KBT
N=4

No KBT
N=37

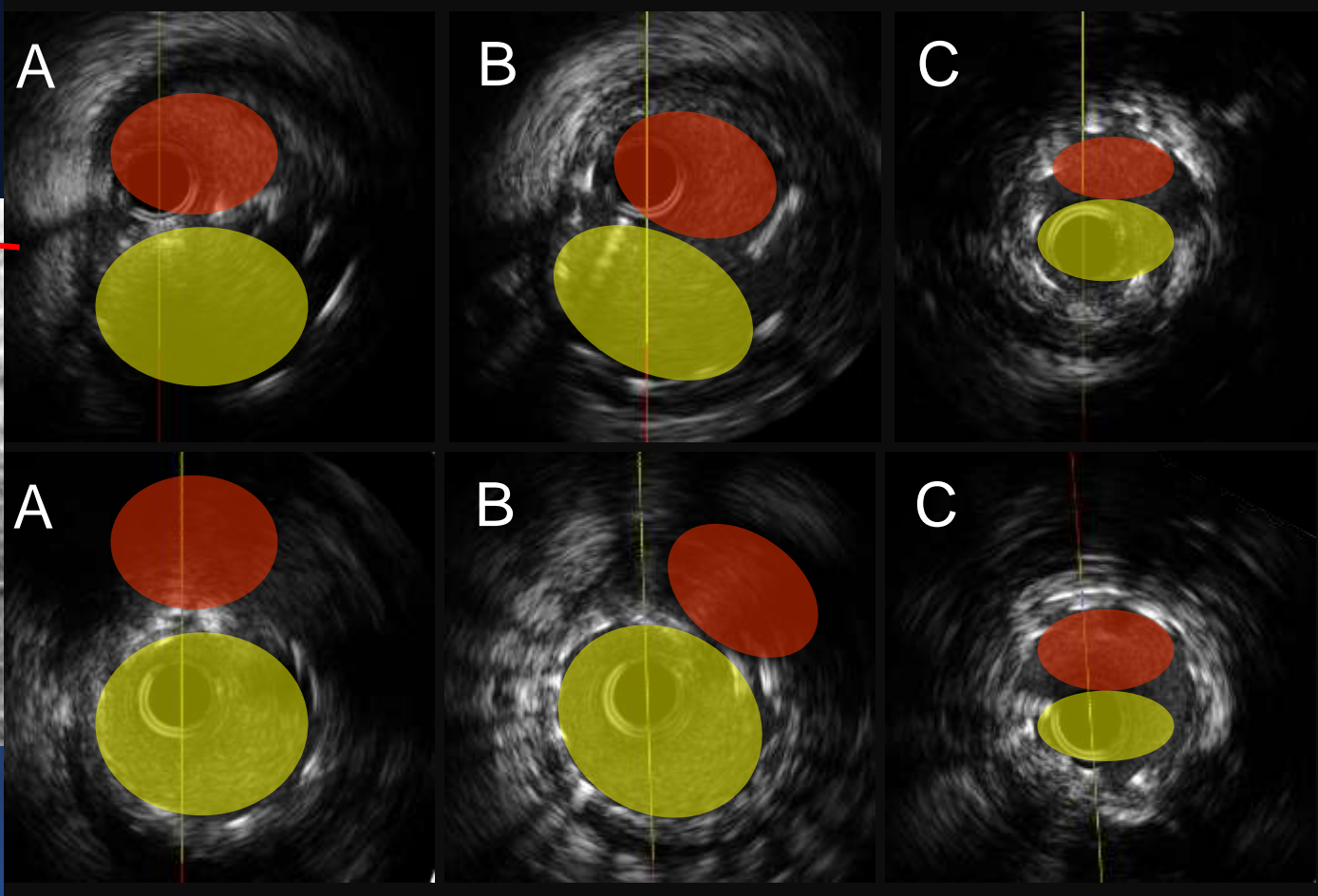
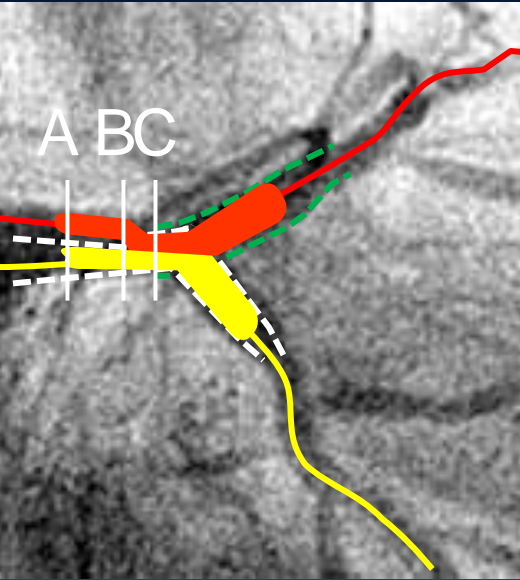
1 Unknown death
in 83 yo patient

1 Unknown death
in 85 yo patient

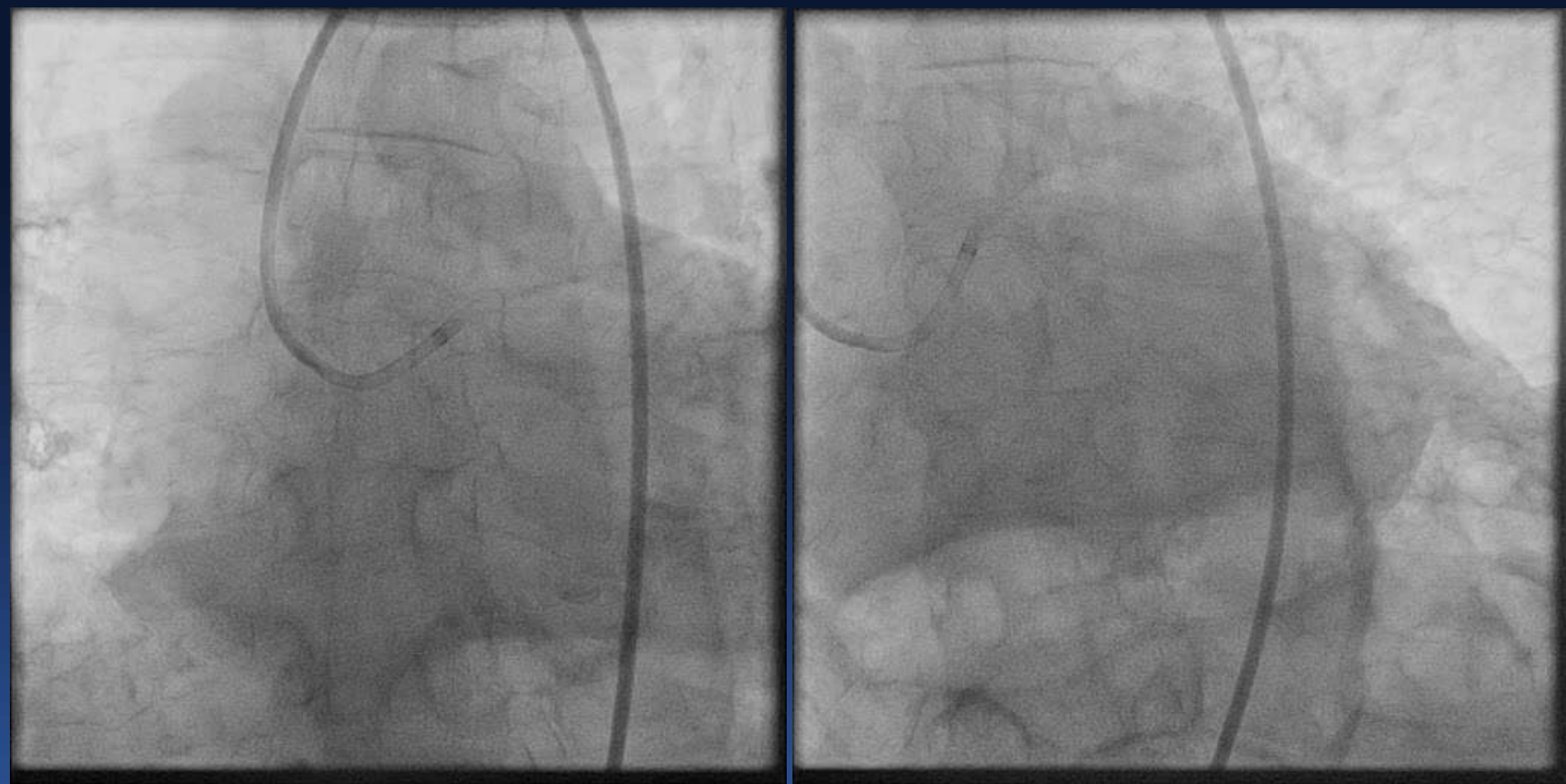- Overall MACE =4.7% (2/43)
- No Ischemic TLR, MI

Complication of Left Main Stenting

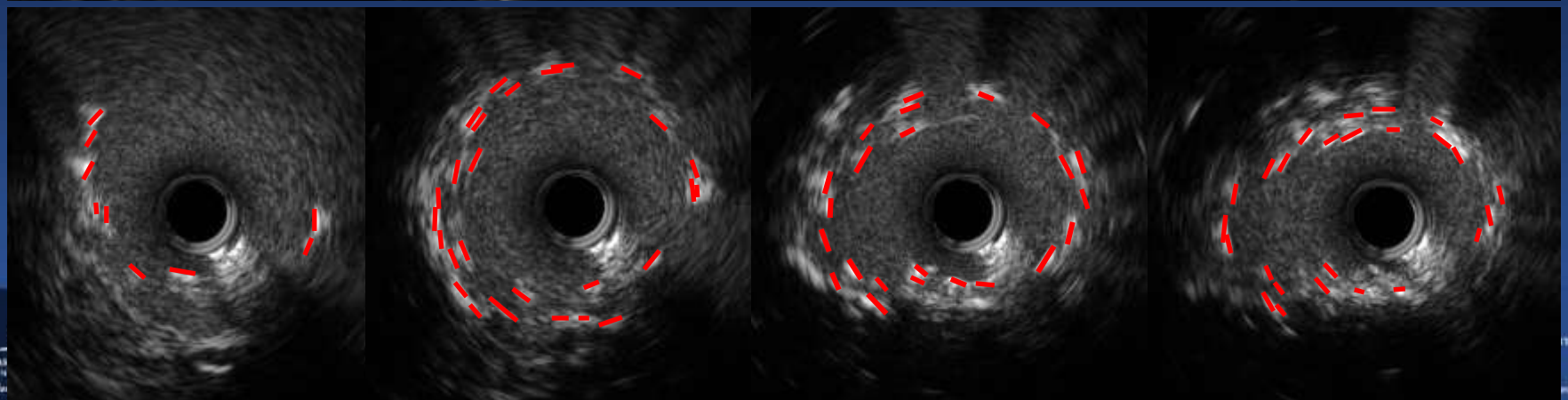
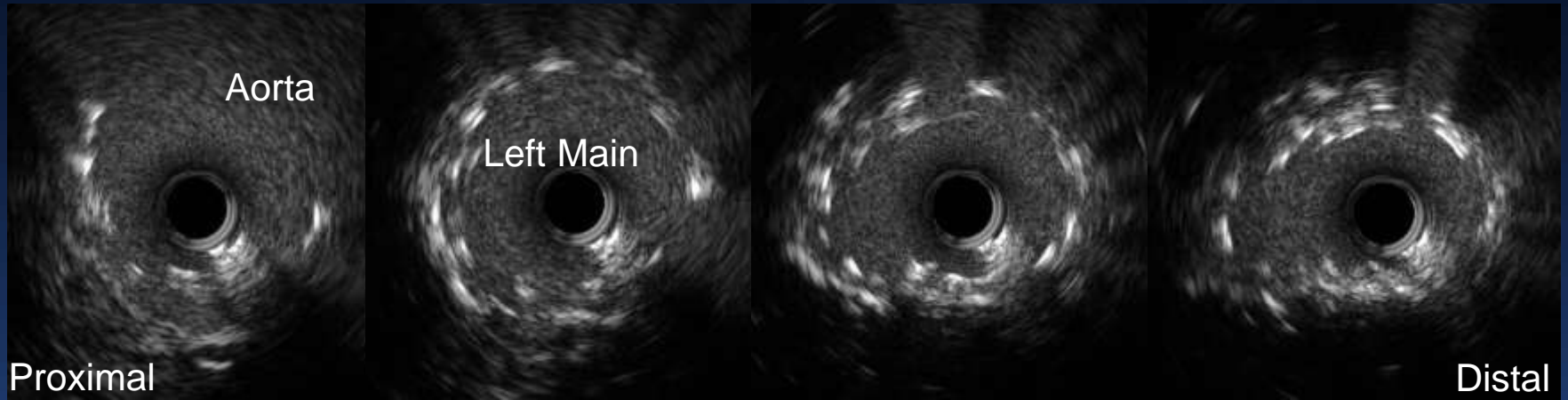
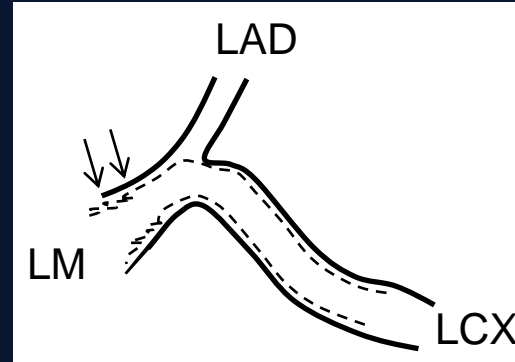
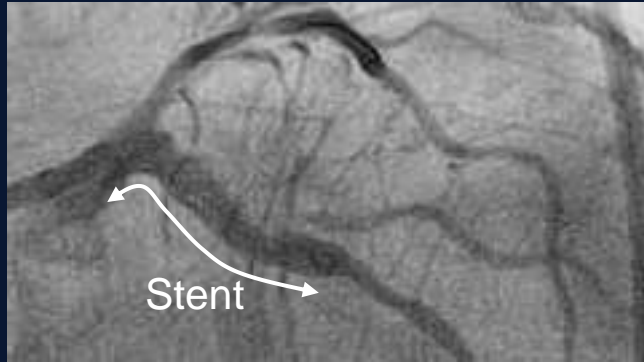
Pullback from LAD



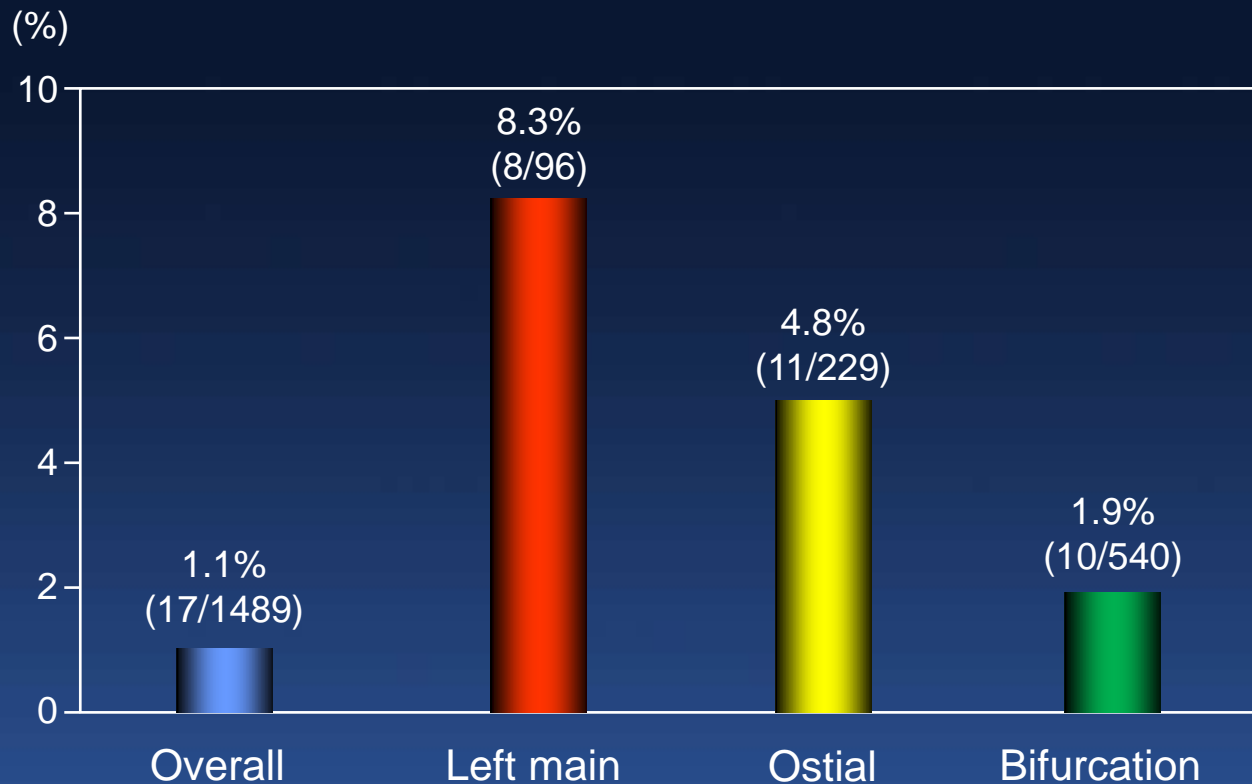
Pullback from LCX



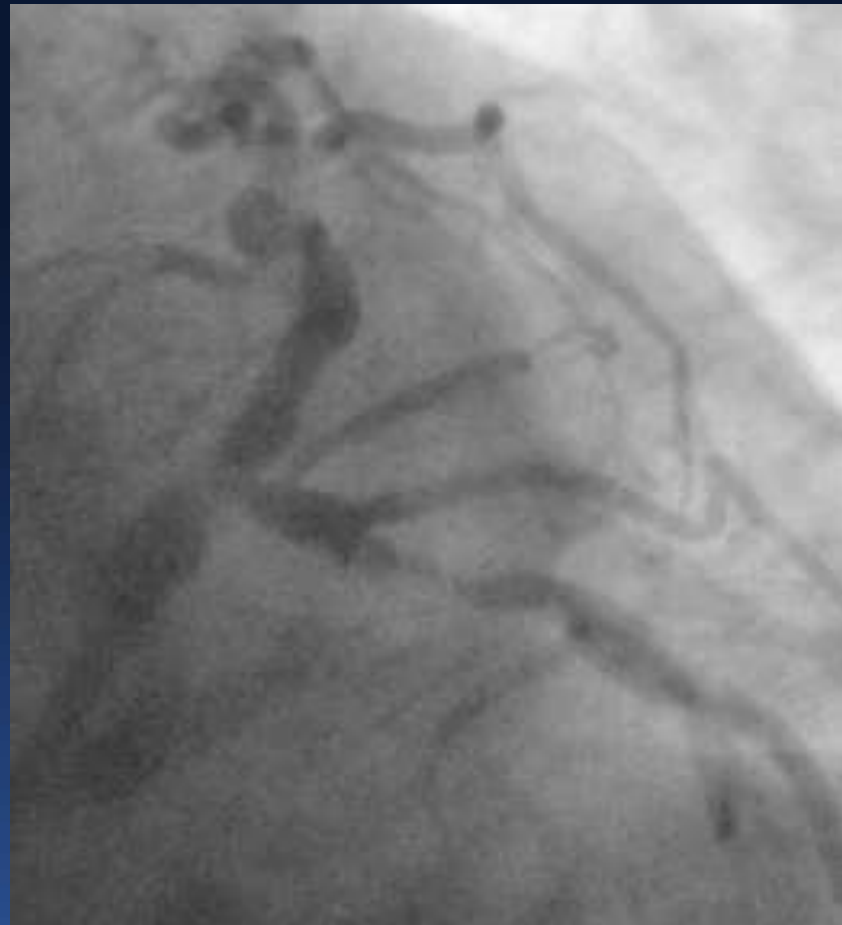
Stent Deformation



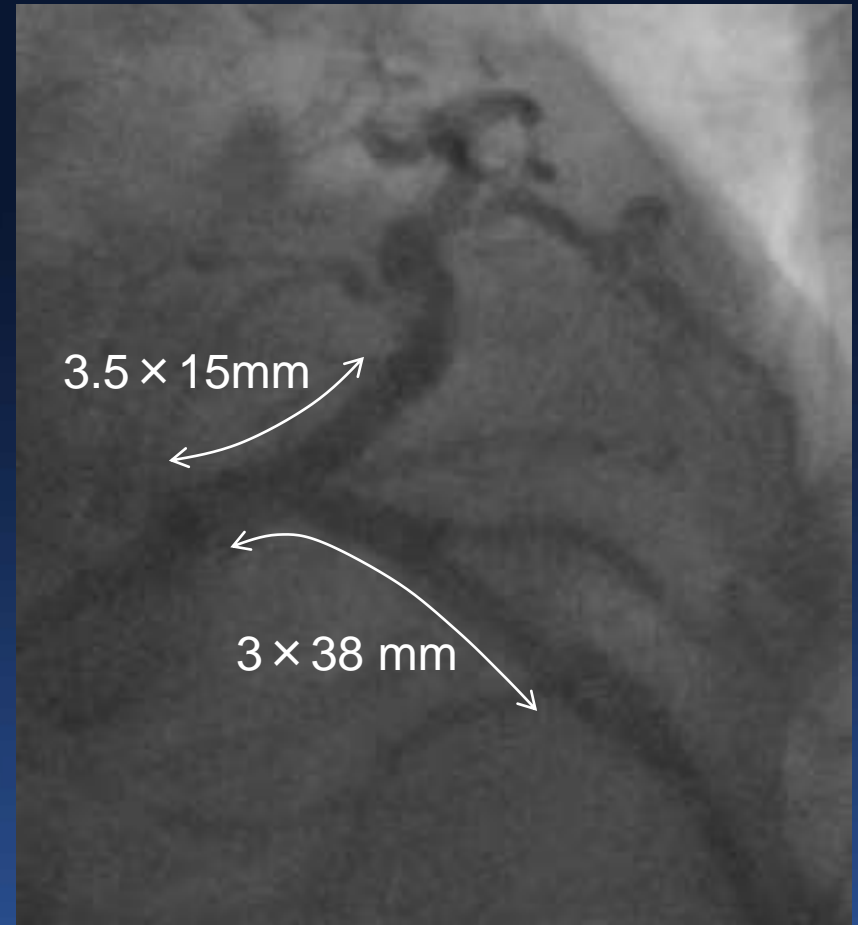
Incidence of Stent Deformation



Pre-PCI

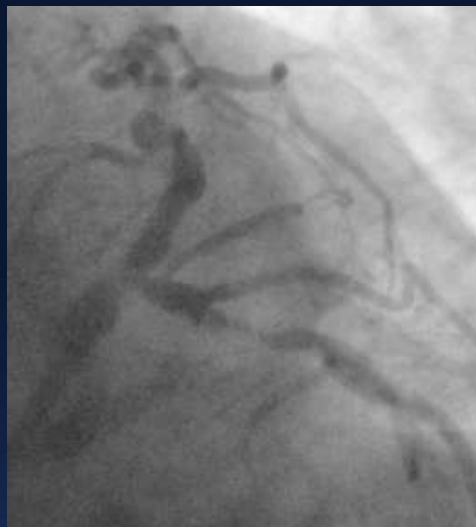

Post-PCI

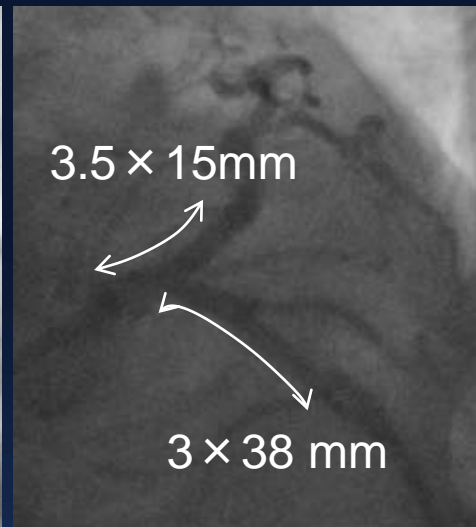


Dissection in Left Main

Pre-PCI

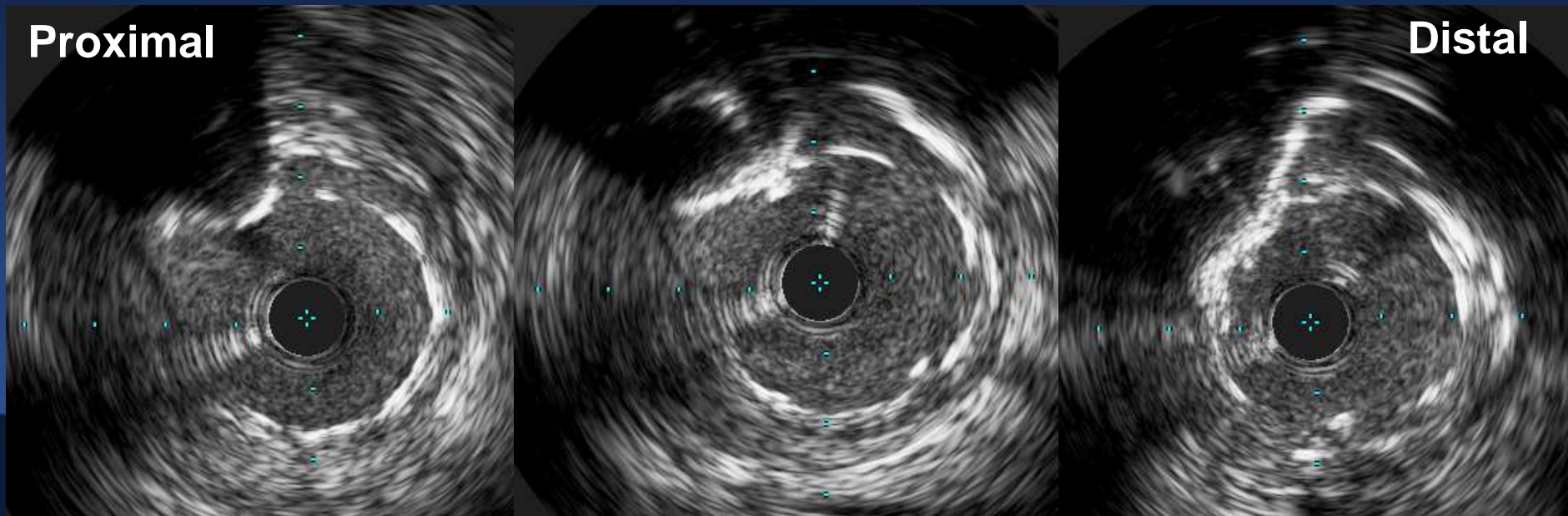


Post-PCI



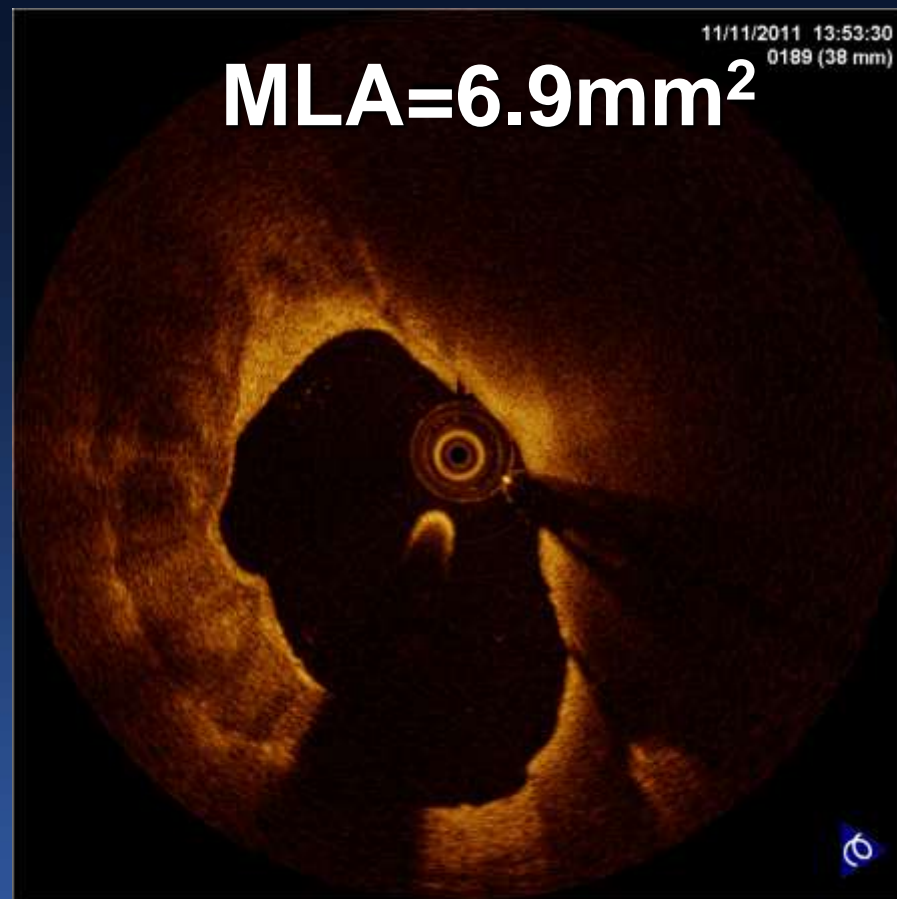
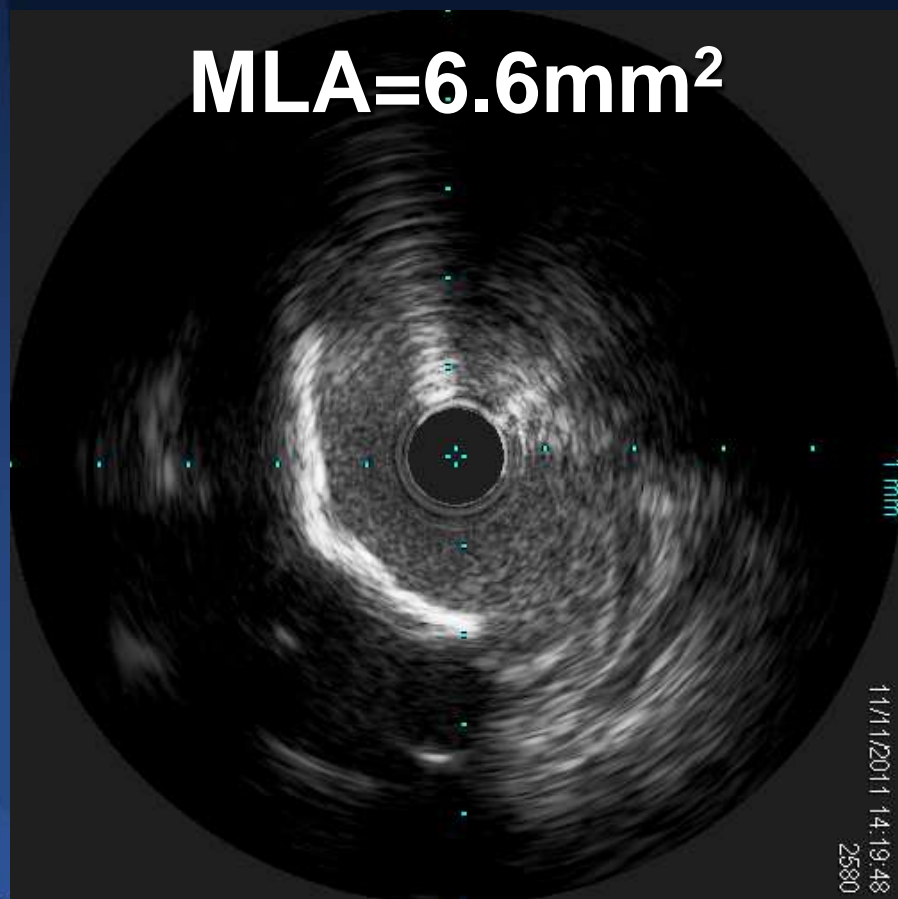
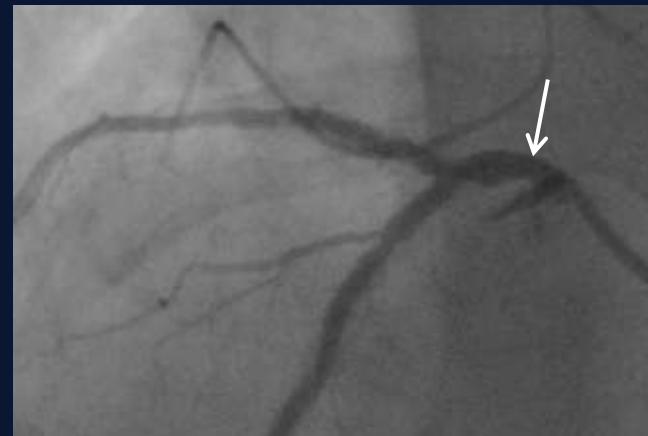Proximal

Distal



OCT in Left Main Stenting

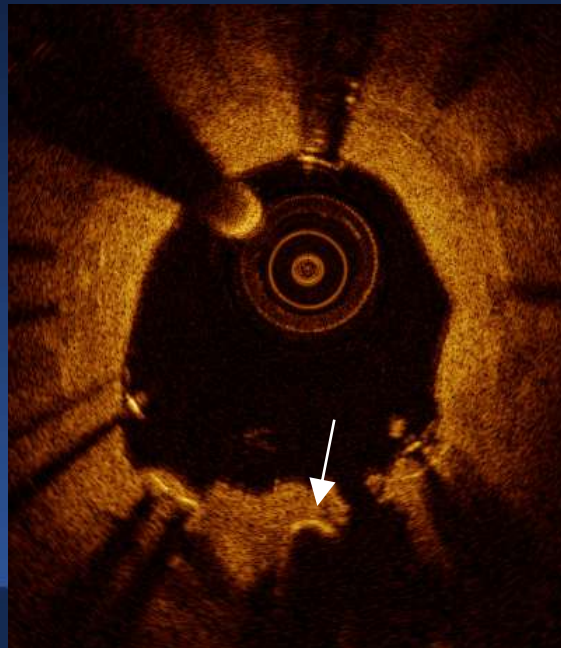
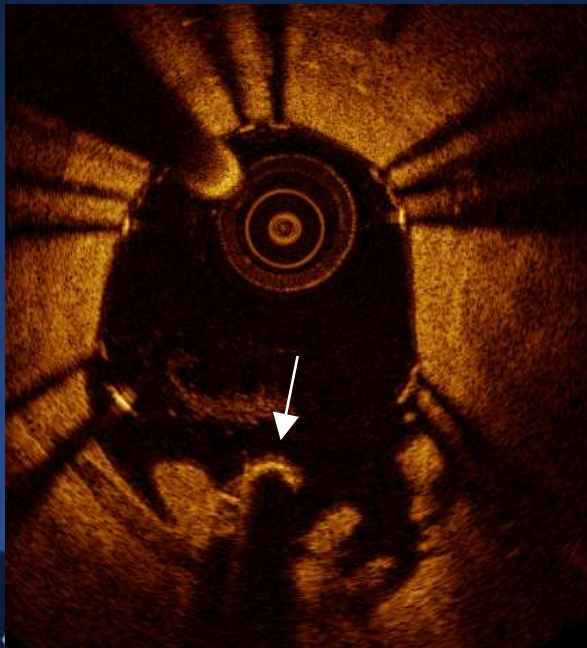
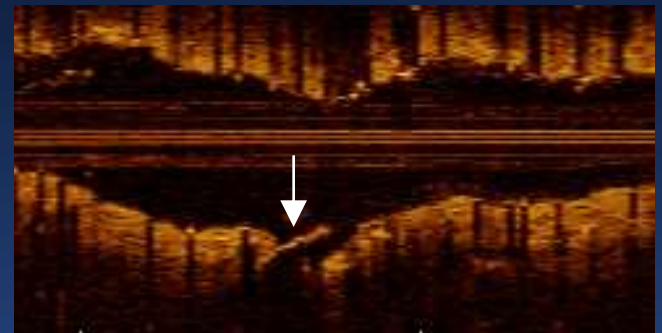

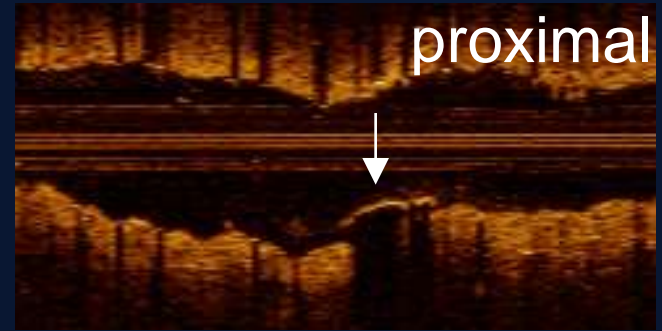

Left Main Evaluation by OCT



OCT Evaluation of Left Main

35 patients with unprotected left main lesions	OCT	IVUS	P-value
<i>Pre PCI</i>			
Proximal evaluation	12.5%	94%	<0.001
Imaged left main length (mm)	6.5±3.4	7.5±3.6	0.002
Minimum lumen area (mm ²)	2.9±1.8	3.5±1.7	0.002
<i>Post PCI</i>			
Proximal evaluation	18%	91%	<0.001
Imaged left main stent length (mm)	7.1±3.6	8.3±3.5	0.014
Minimum stent area (mm ²)	6.8±2.1	6.9±2.0	0.002
Distal edge dissection	30%	6%	0.011

Wire Passage through cross-over Stent



Optimal Left Main Stenting

Diagnosis

- Is this really left main disease?
- What about LCX ostial disease?
- Provisional
- 2 Stent technique

During Procedure

Wire location in left main?

Final Evaluation

- Good enough stent expansion?
- Correct evaluation?
- 2 Stents=5-6-7-8
- 1 Stents=4-6-7-8
- Disengage guiding catheter

Anything else?

- Guiding catheter injury
- Stent deformation at ostium