

# What the tough guys: the doctors or the patient ?

Luo Jianfang MD, Dong Haojian MD  
Guangdong General Hospital

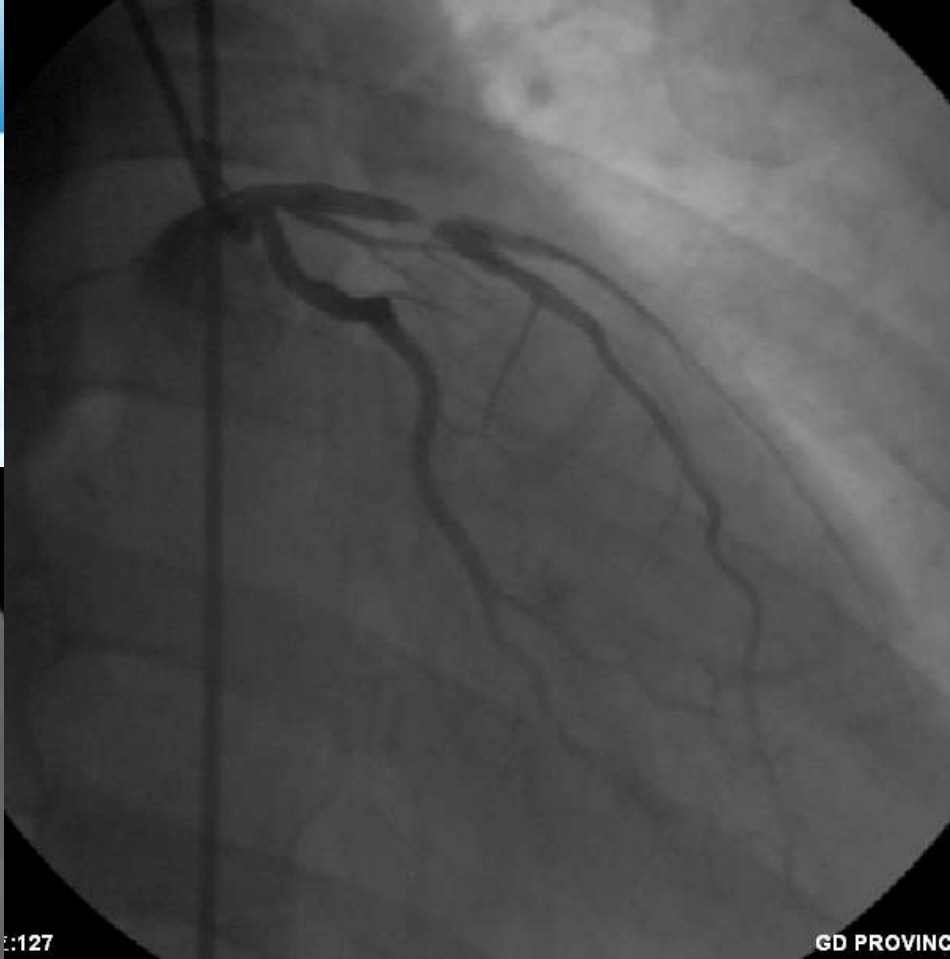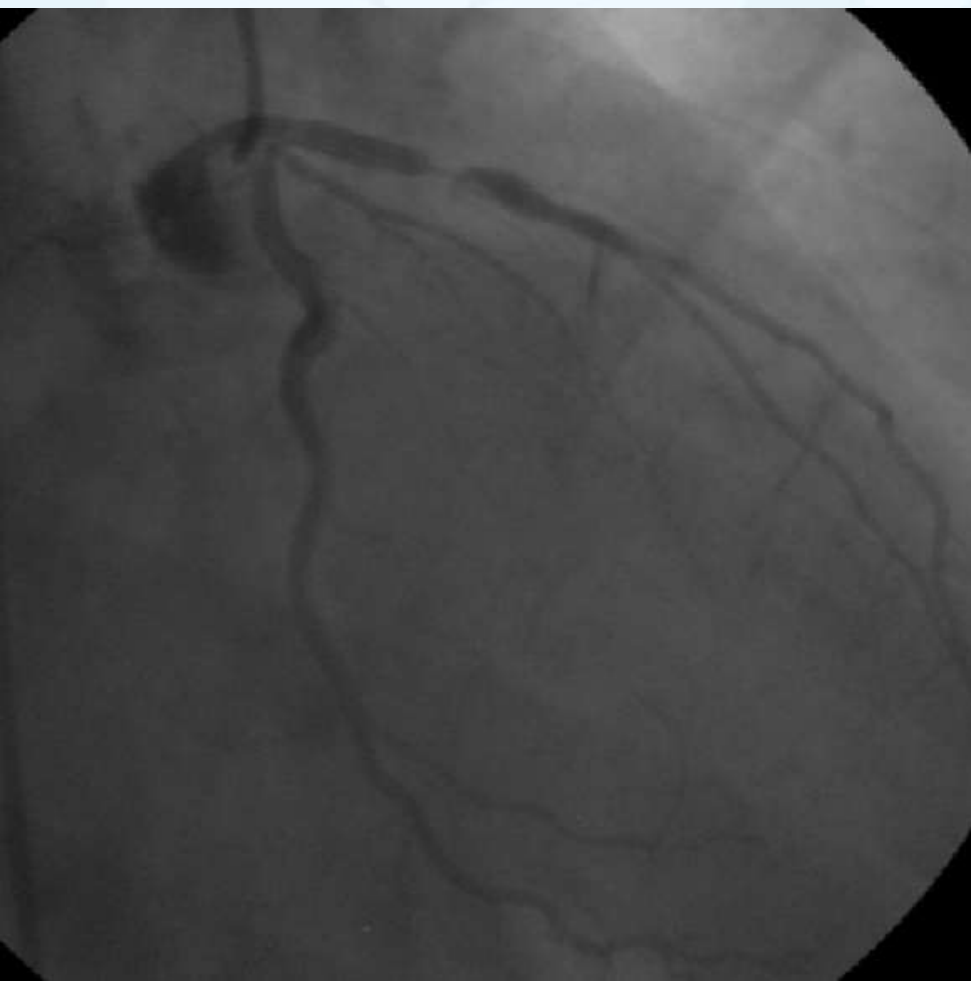


# Medical history

- Male, 56yrs
- Recurrent chest pain for one month
- HT(+),DM(-),Heavy Smoker
- LAD-PCI 10 years ago, with intermittent antiplatelete agent



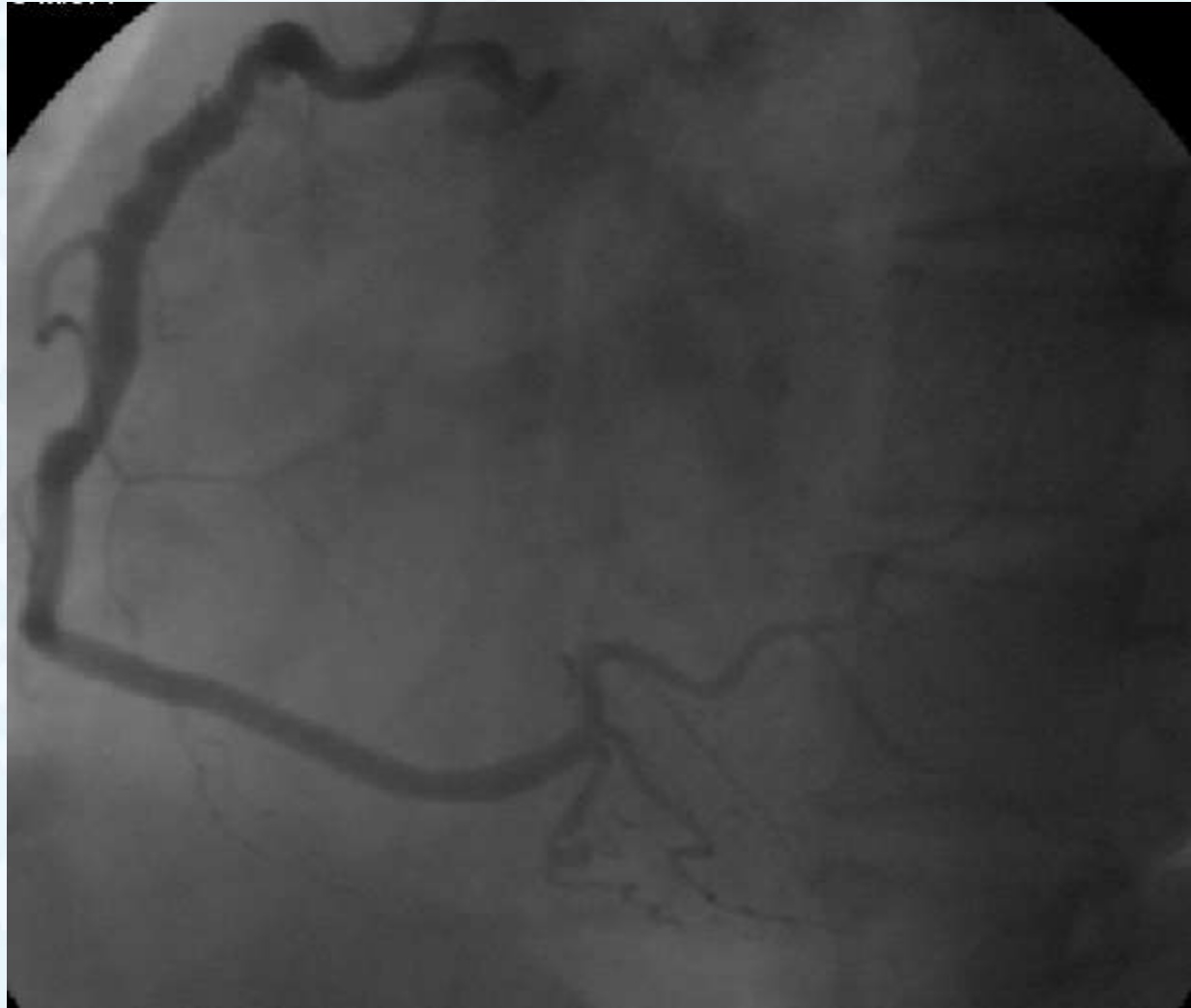# 10 yrs ago

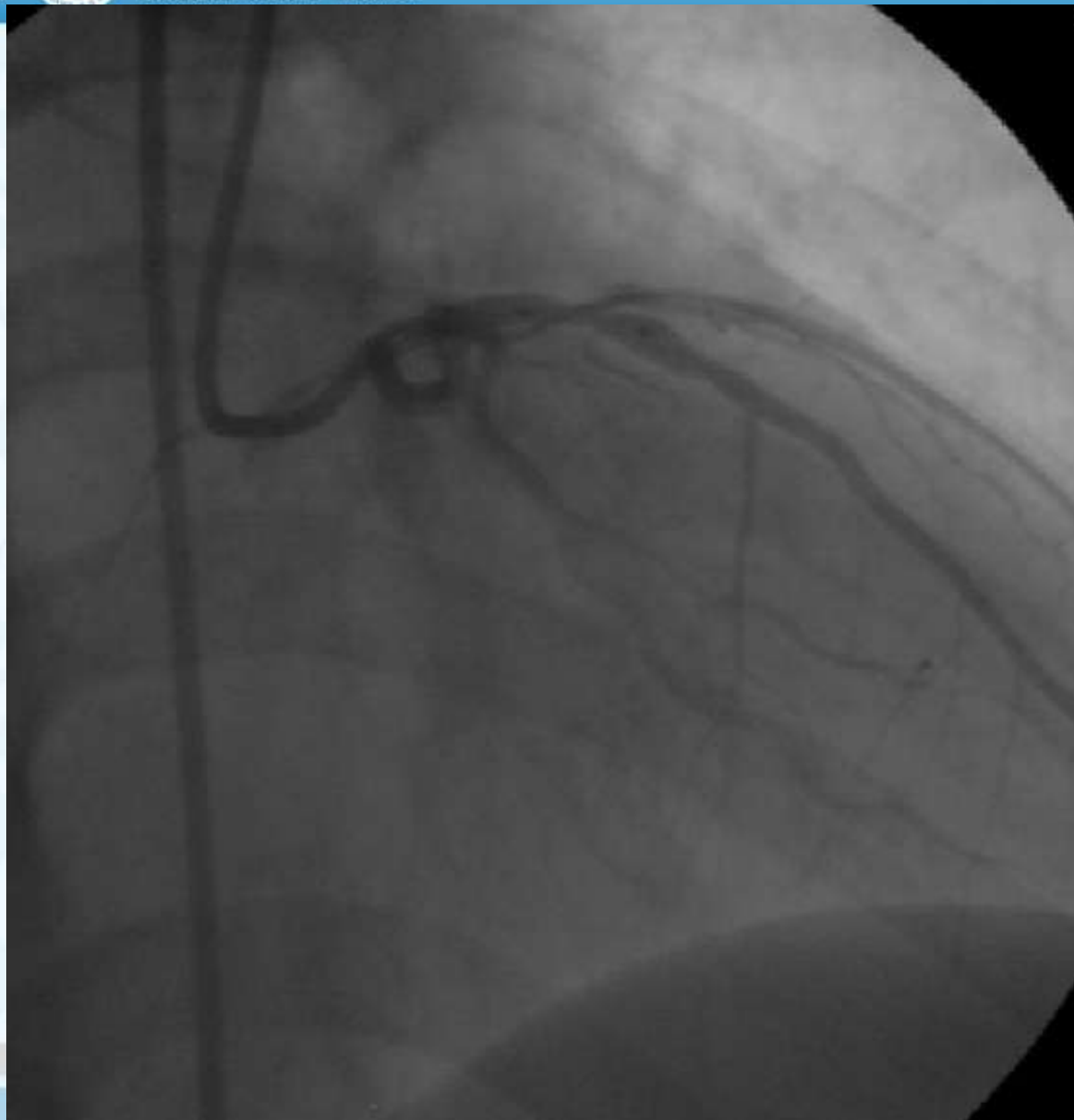


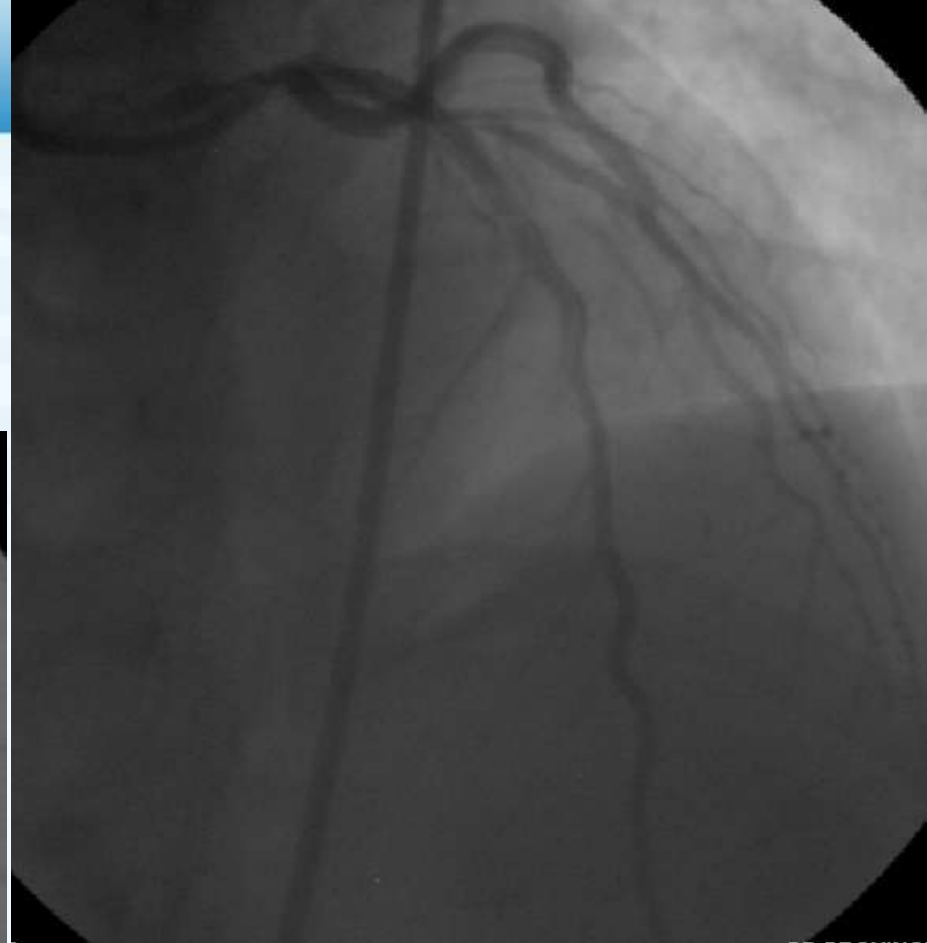
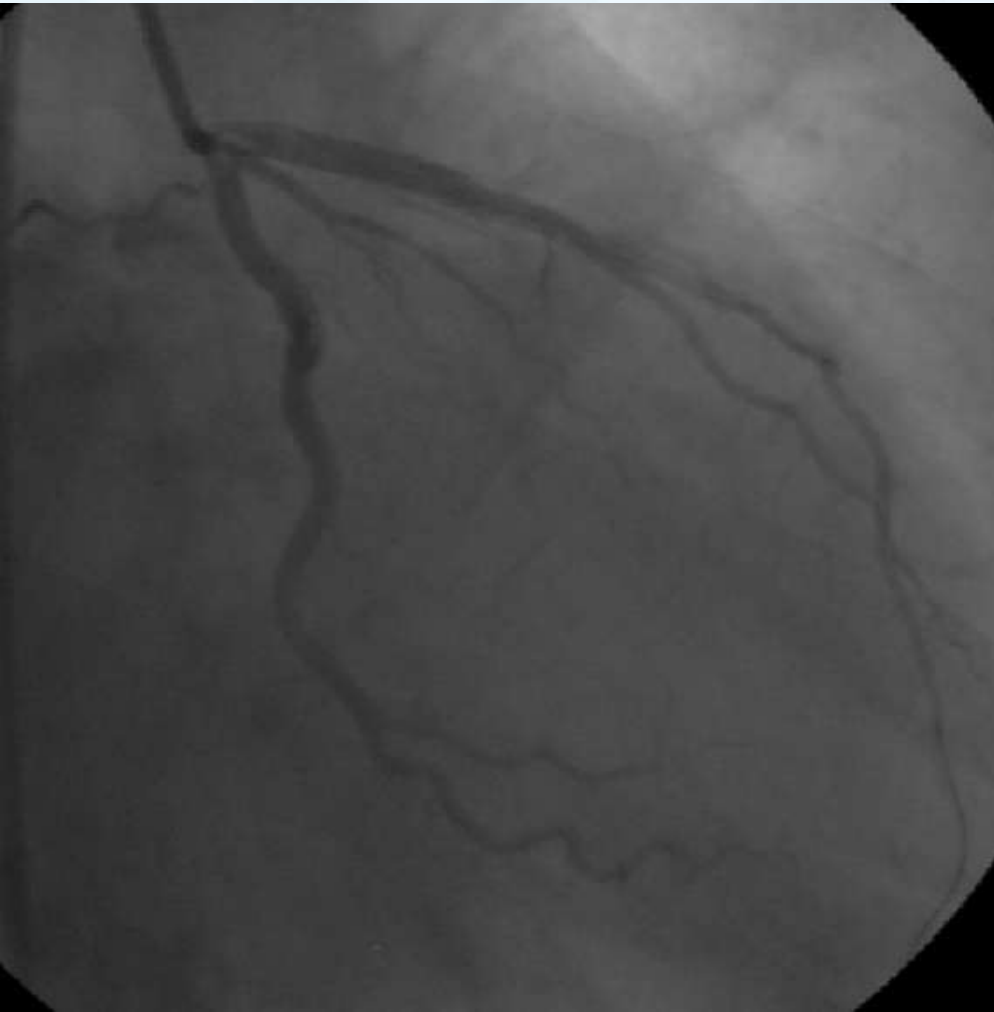127

GD PROVINC







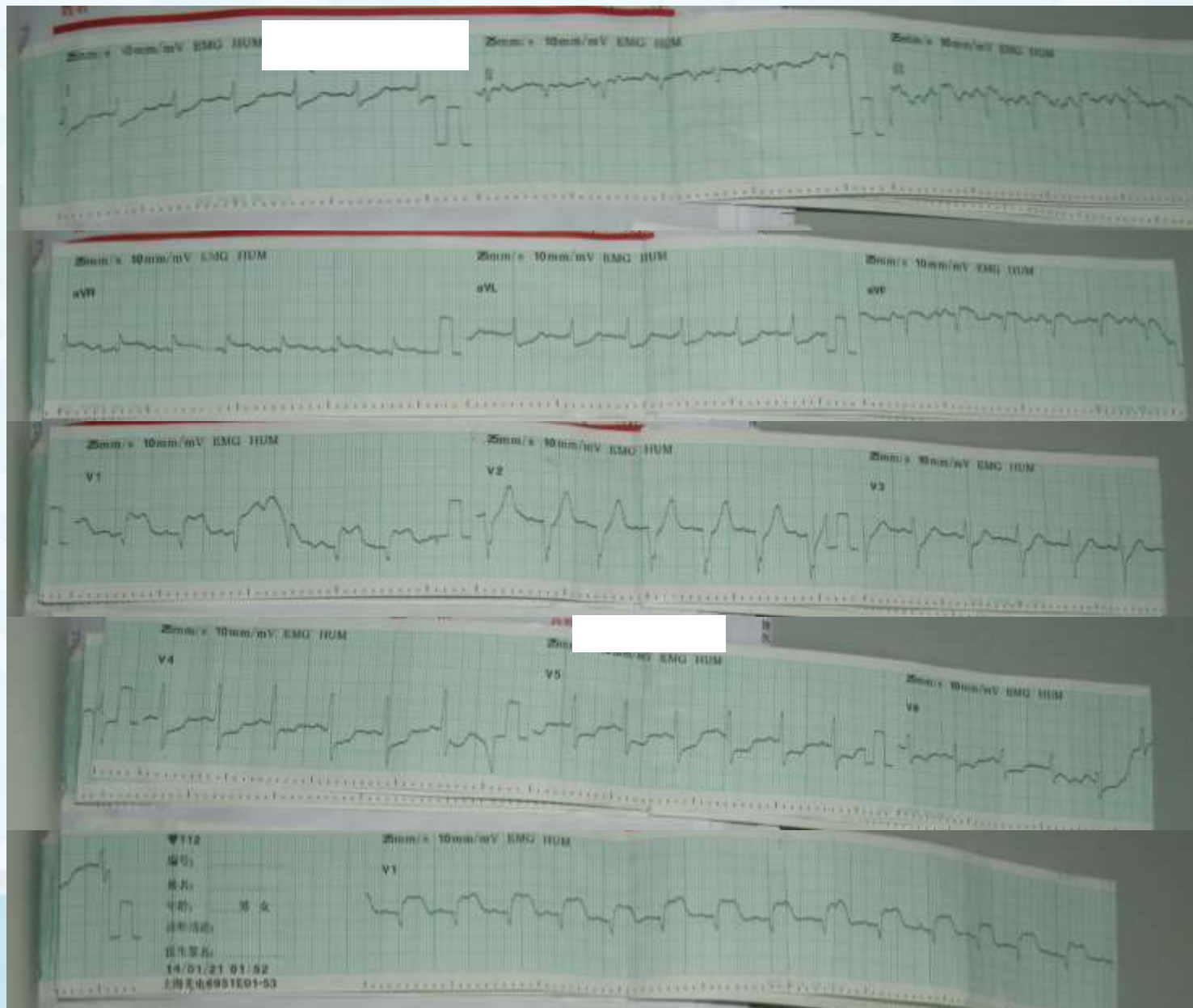


What kind the stent ?

Unknown.



# First ECG after admission



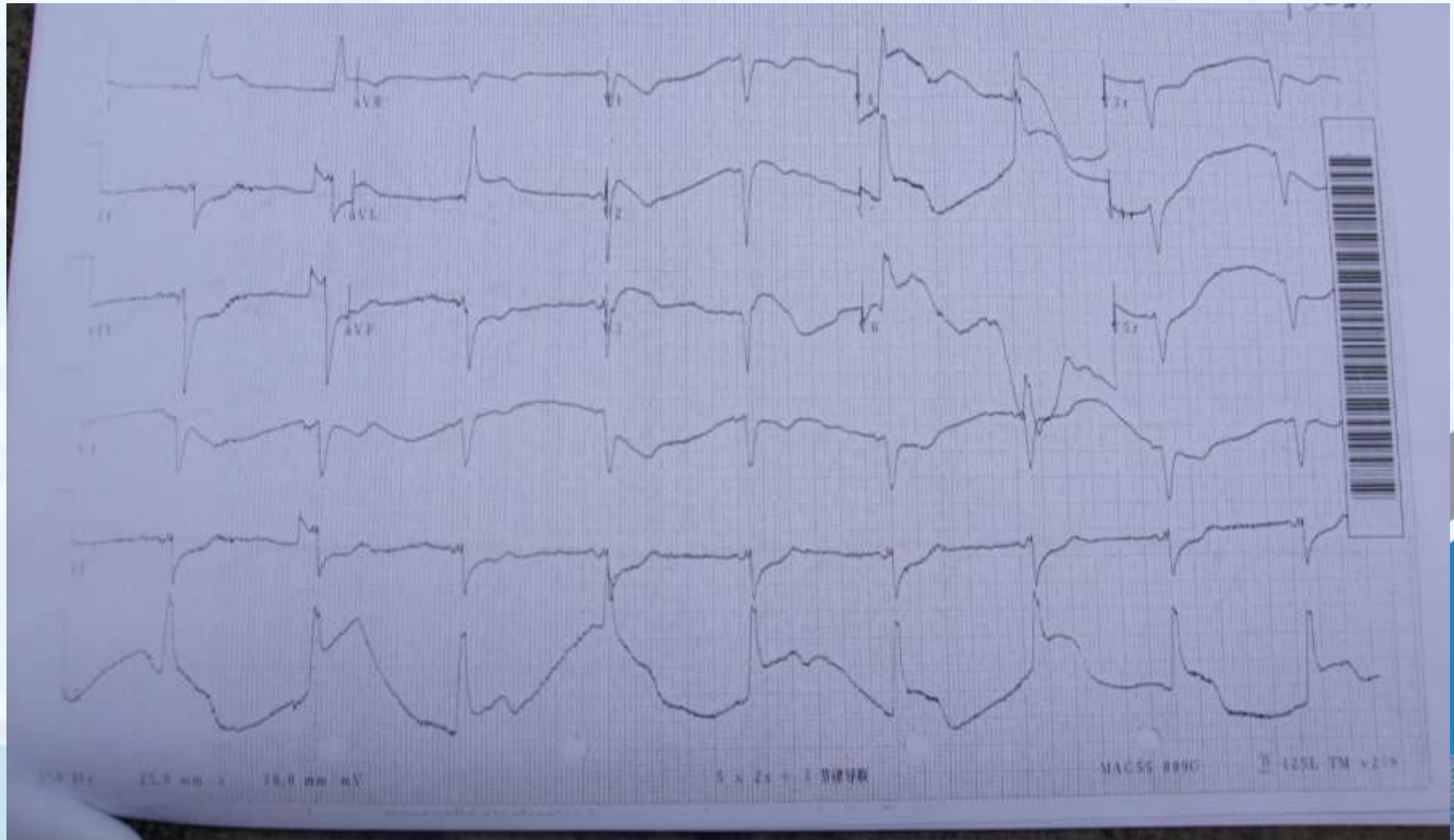
- 2014-1-21  
01:52AM
- HR: 95bpm
- Bp: 117/77  
mmHg
- Tnl (+)
  
- Aspirin 300mg
- Plavix 300mg
- Statin



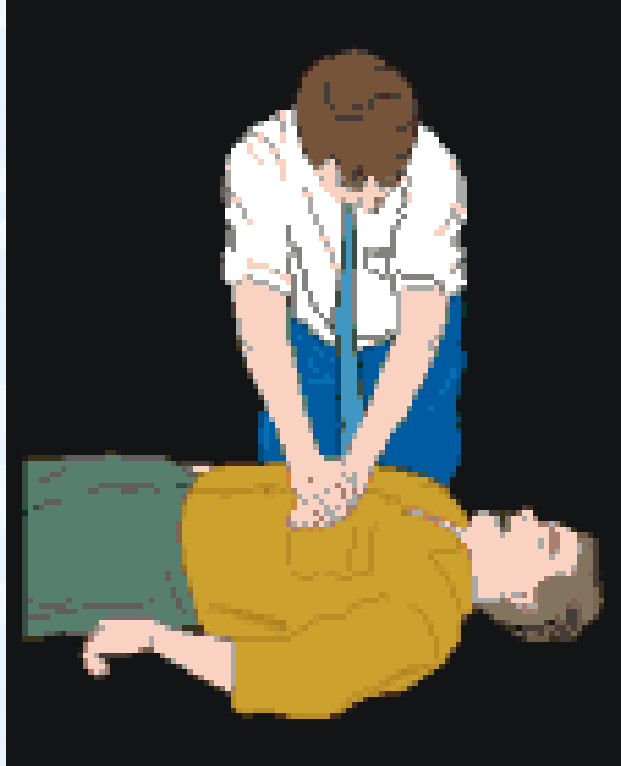# Preparing for the Emergent PCI the pt collapsed!

2014-01-21

02:15 AM







CPR for 30 mins before  
arrived to cath lab

2014-01-21  
02:15 - 02:45



# One doctor - Continuous CPR

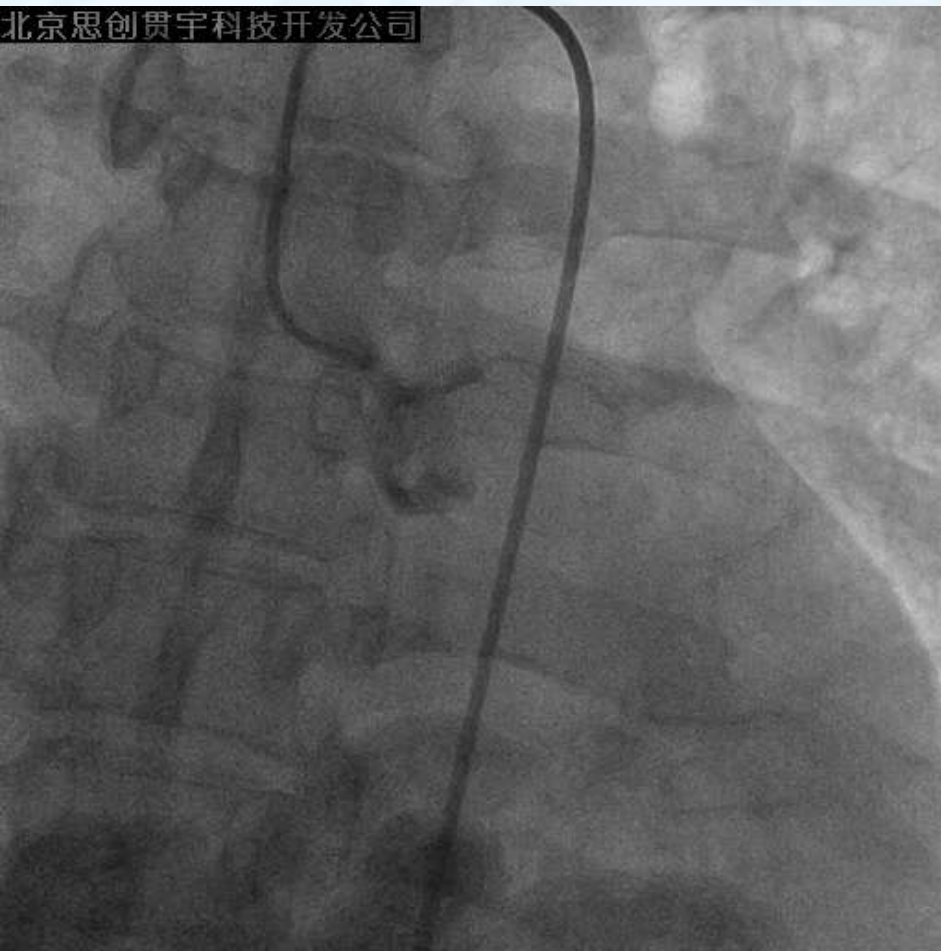
## One doctor - PCI

## One nurse – setting up

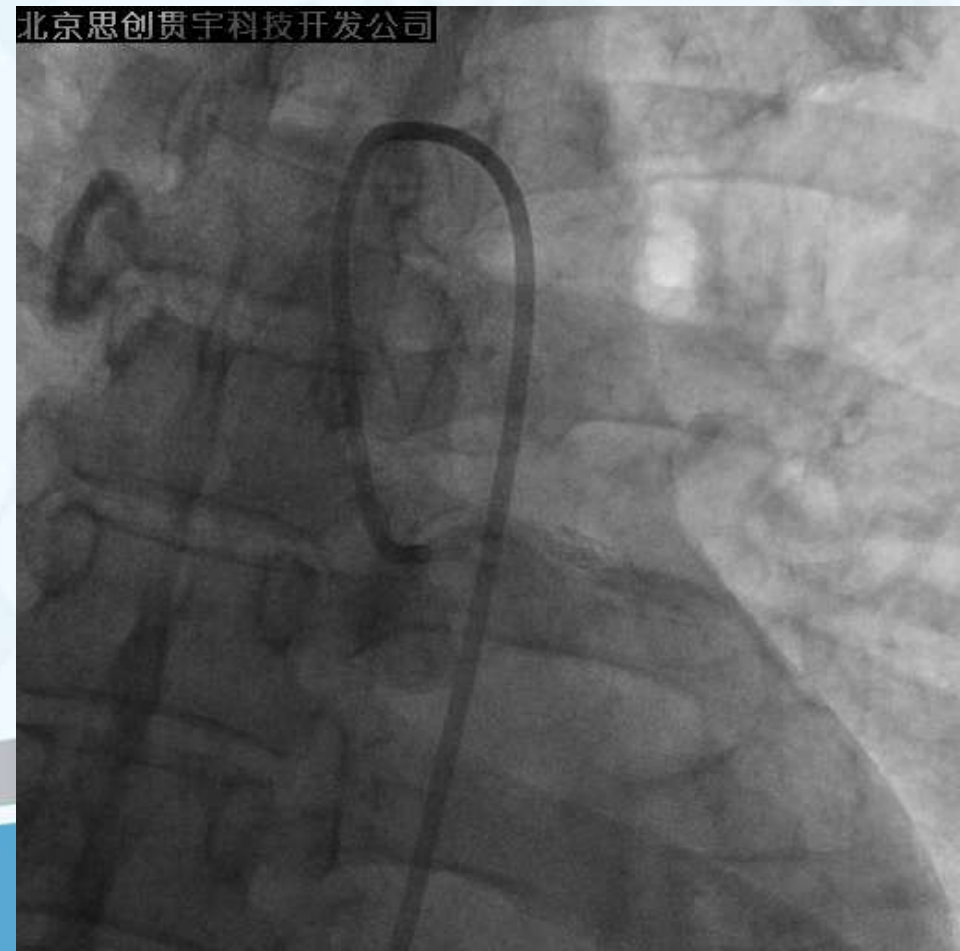
## The pt-supported by ventilator

2014-01-14  
03:00 AM

北京思创贯宇科技开发公司



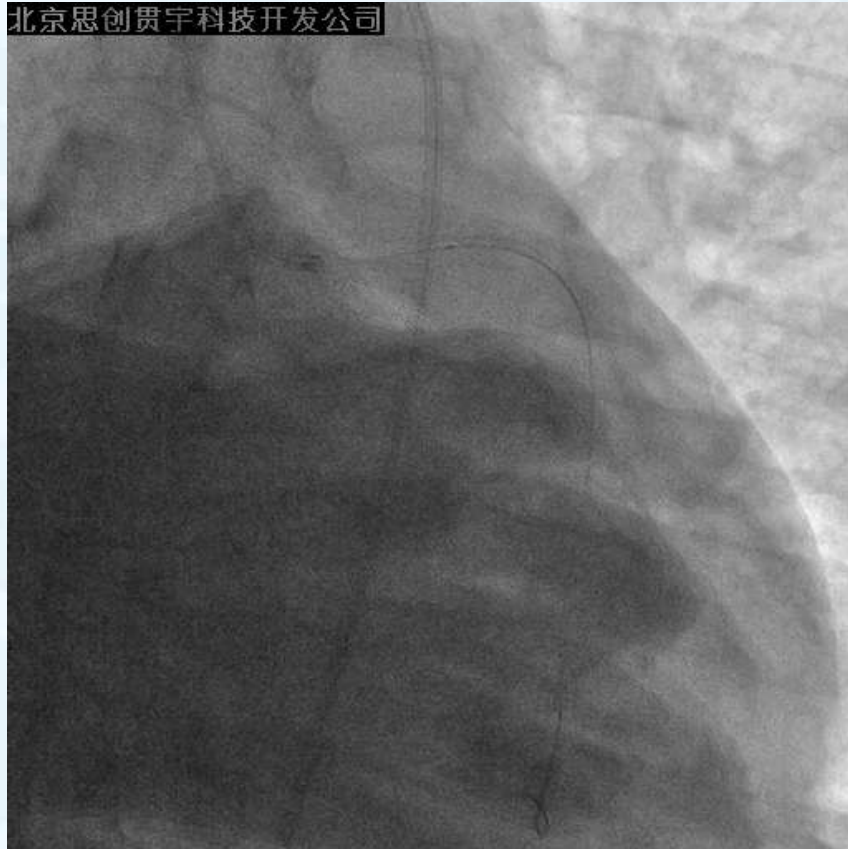
北京思创贯宇科技开发公司



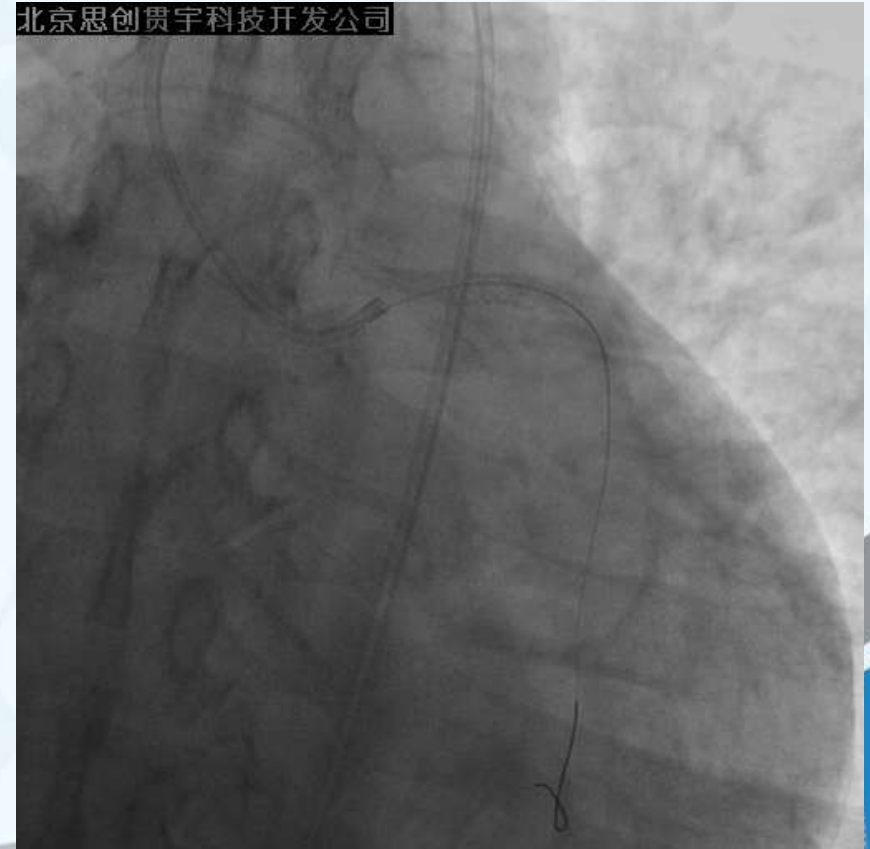# Still no response Another 30 min.

2014-01-21  
03:30

北京恩创贯宇科技开发公司



北京恩创贯宇科技开发公司



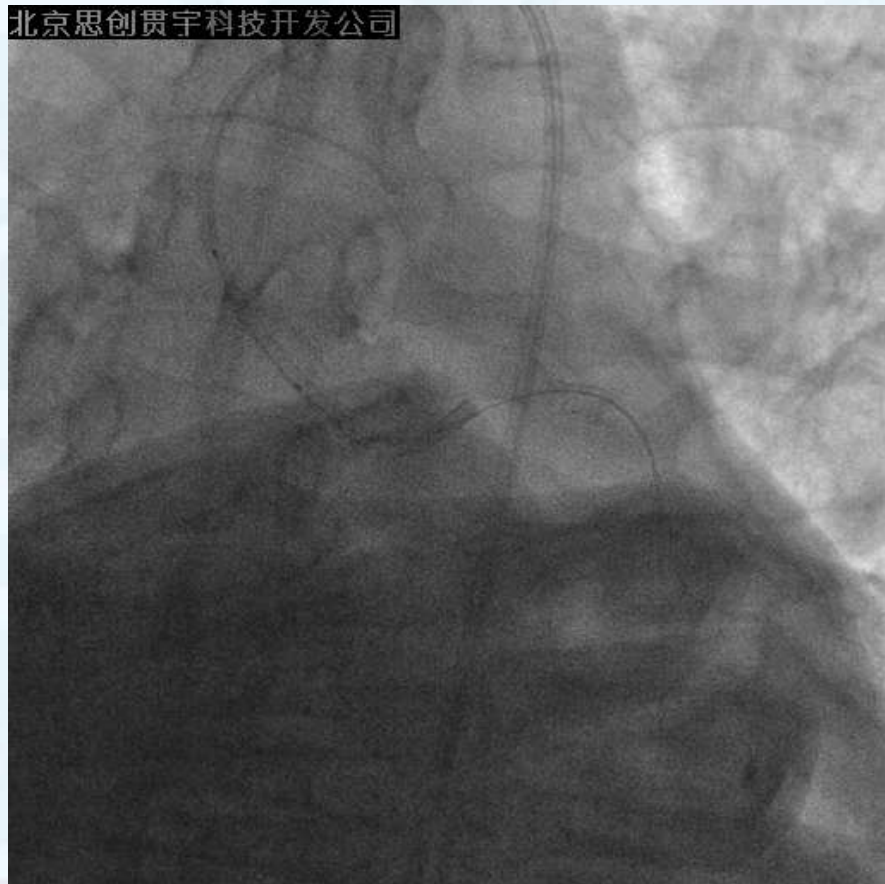
- 6F JL4
- Runthrough / 2.5\*20mm



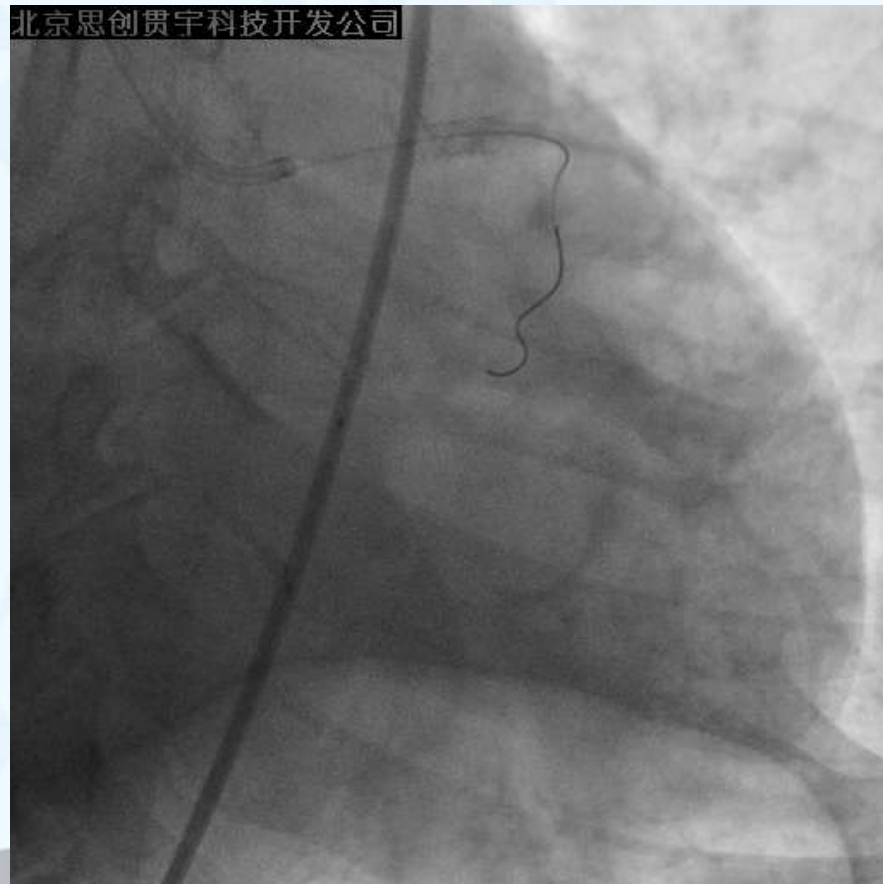
# Don't Stop! Guys!

2014-01-21  
03:35

北京思创贯宇科技开发公司



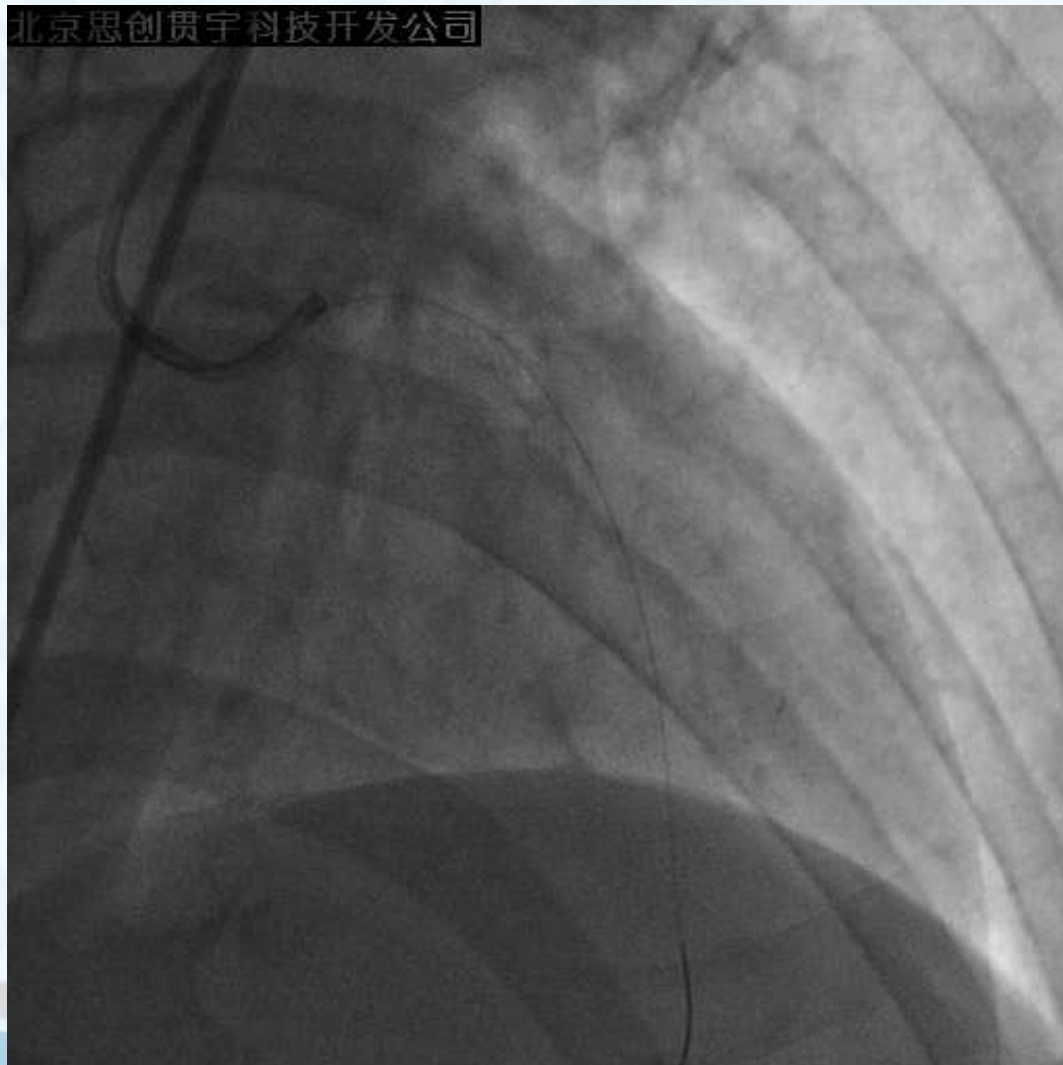
北京思创贯宇科技开发公司



Gp IIb/IIIa



# And... 10 min. later !



2014-01-21  
03:45 AM

- HR 85bpm
- Bp:98/70mmHg

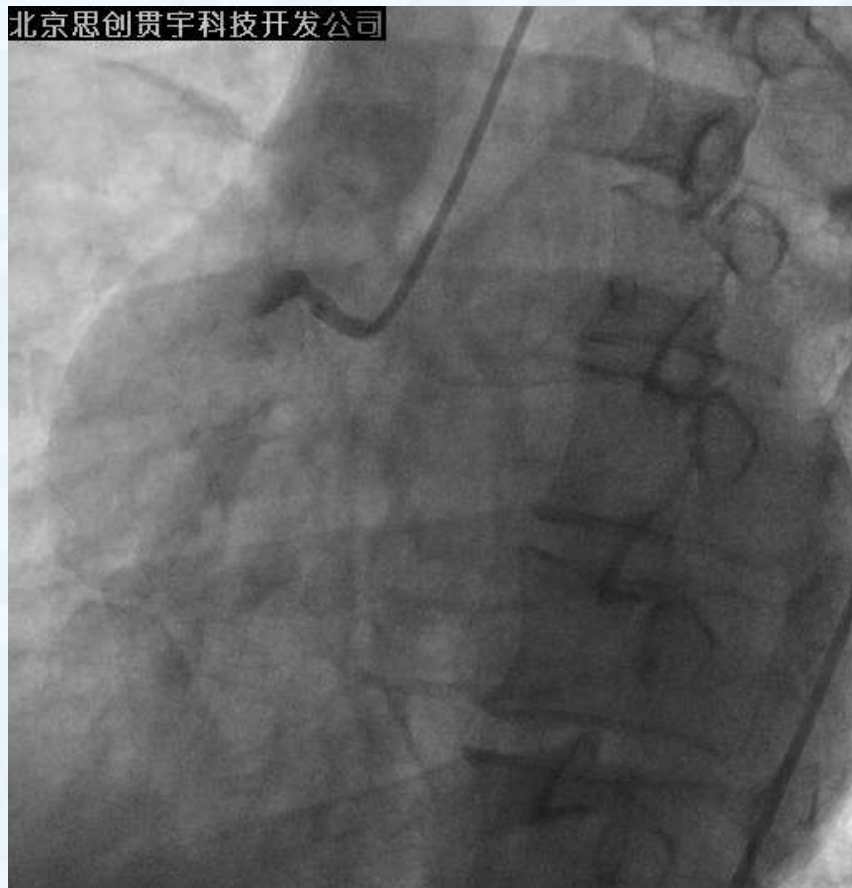


# Hemodynamics more stable but ST still elevated in II/III/aVF

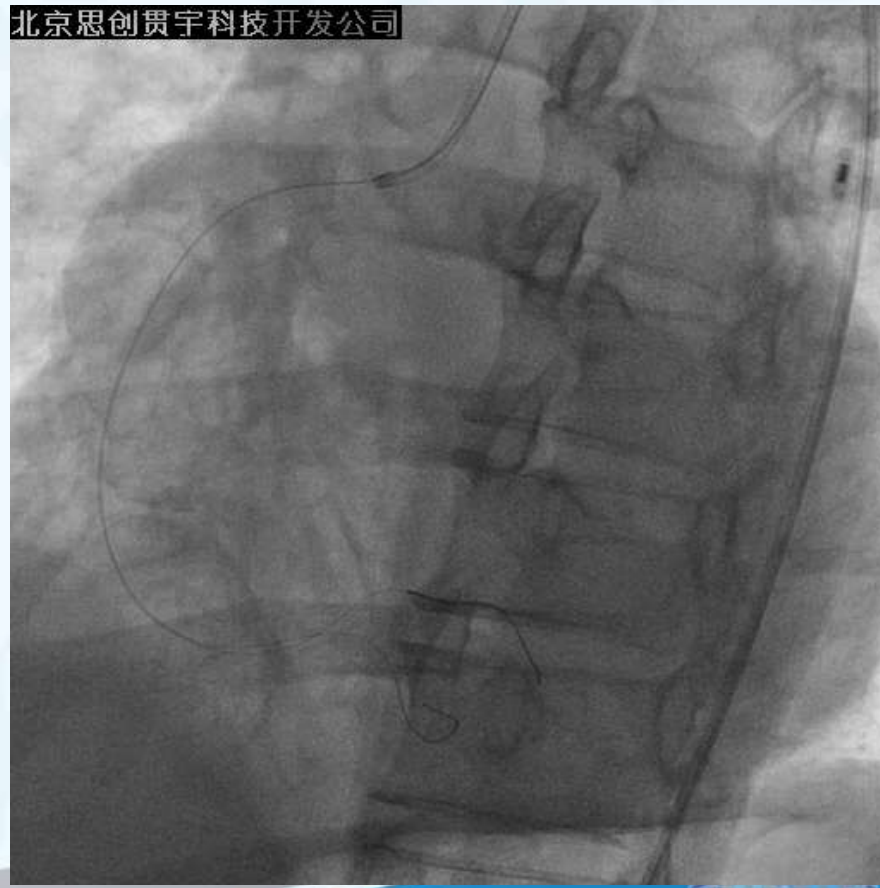## Stent it or not?

2014-01-21  
04:00 AM

北京思创贯宇科技开发公司



北京思创贯宇科技开发公司



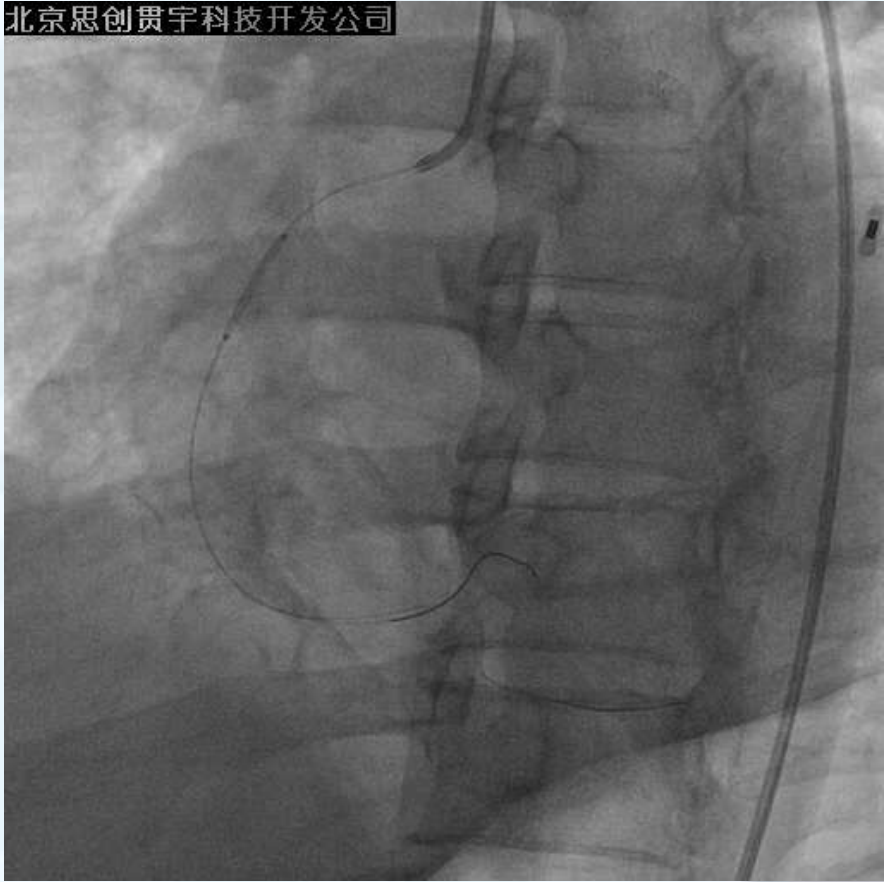
6F JR4, IABP  
Aspiration



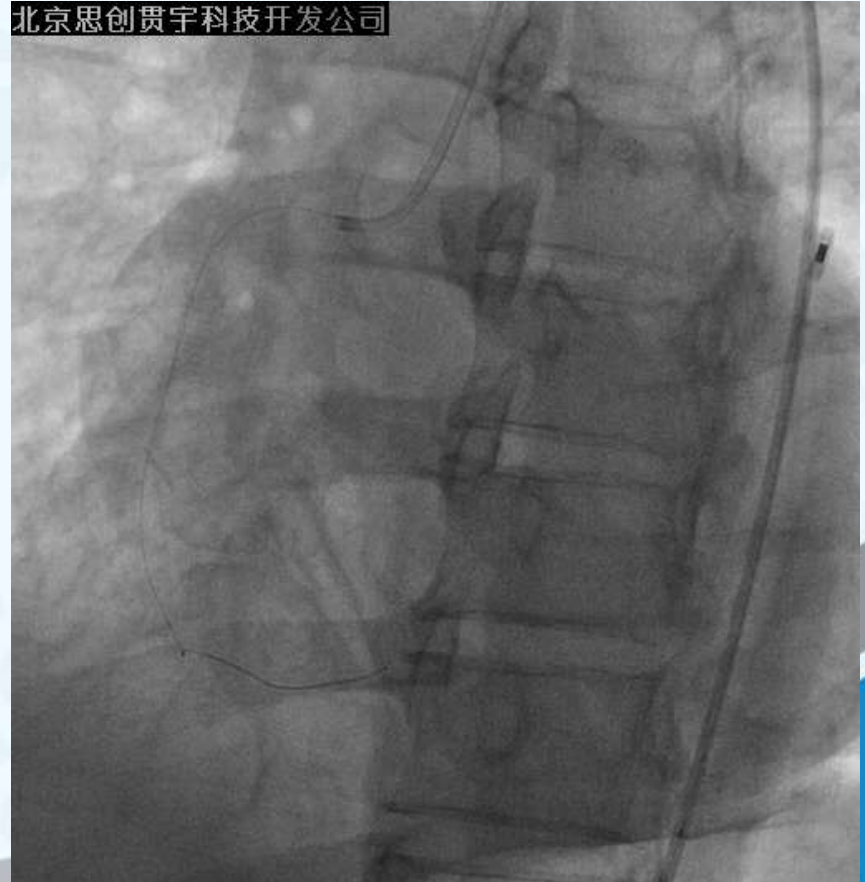
# RCA - PCI

2014-01-21  
04:15 AM

北京思创贯宇科技开发公司



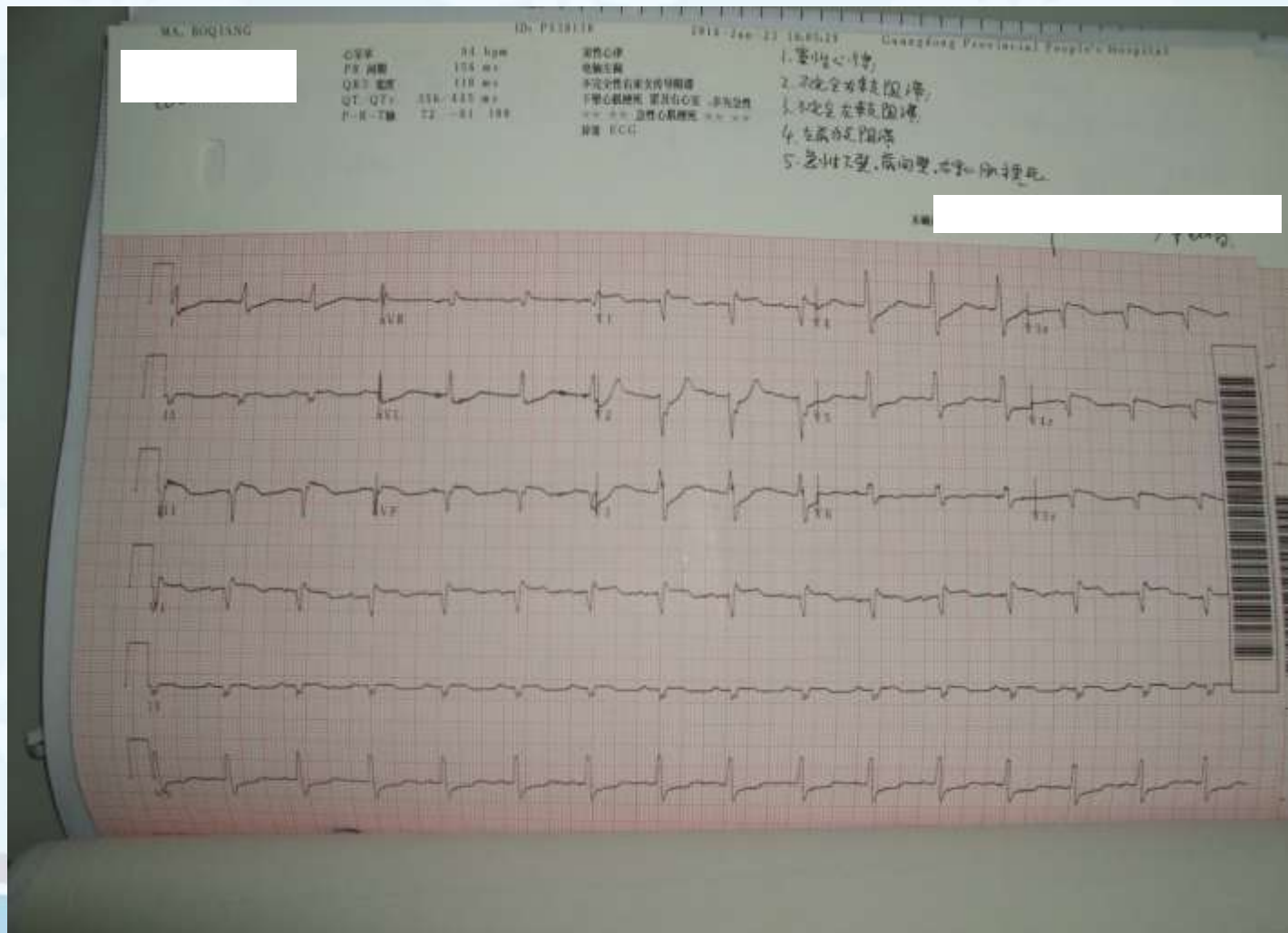
北京思创贯宇科技开发公司



VISION 4.0\*18mm

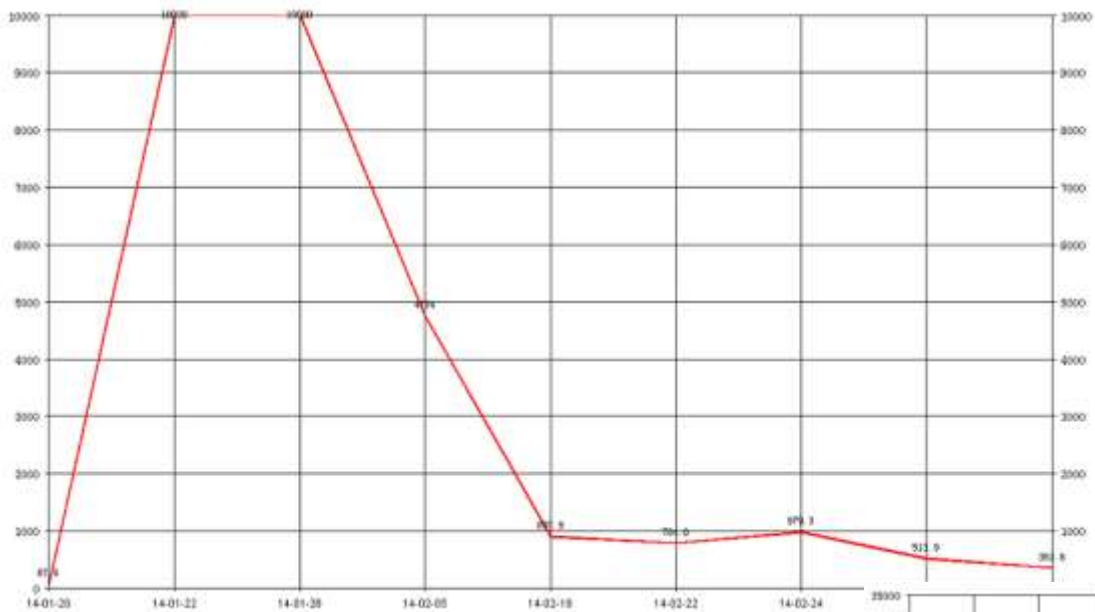


# ECG after PCI

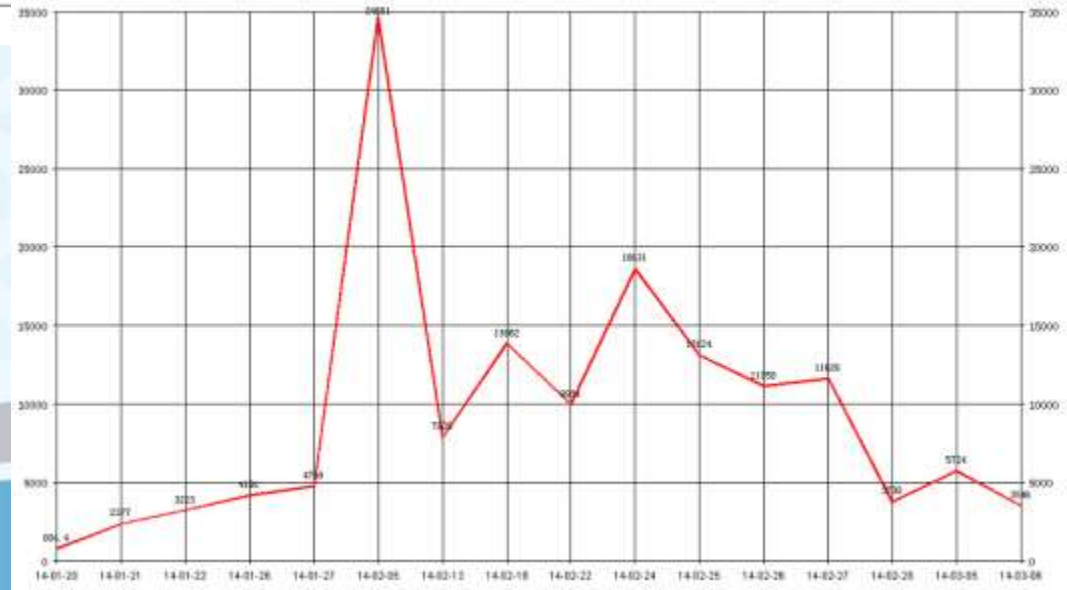




# HS-cTNT



# NT-proBNP



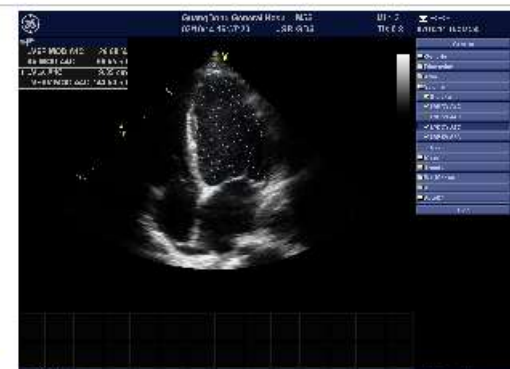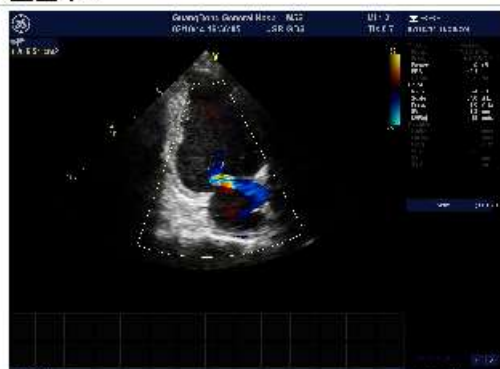# ECHO – post PCI

2014-01-29

**检查参数:**

AO: 26	AAO: 29	LA: 41	LVDd: 66
LVDs: 58	LVEF: 30	IVS厚: 10	LVPW厚: 10
RV常规: 20	MPA: 23	PV: 0.55	AV: 0.73
MV E: 0.69	MV A: 0.58	TV E: 0.46	RA: 47
RV: 57			

**检查图象:**

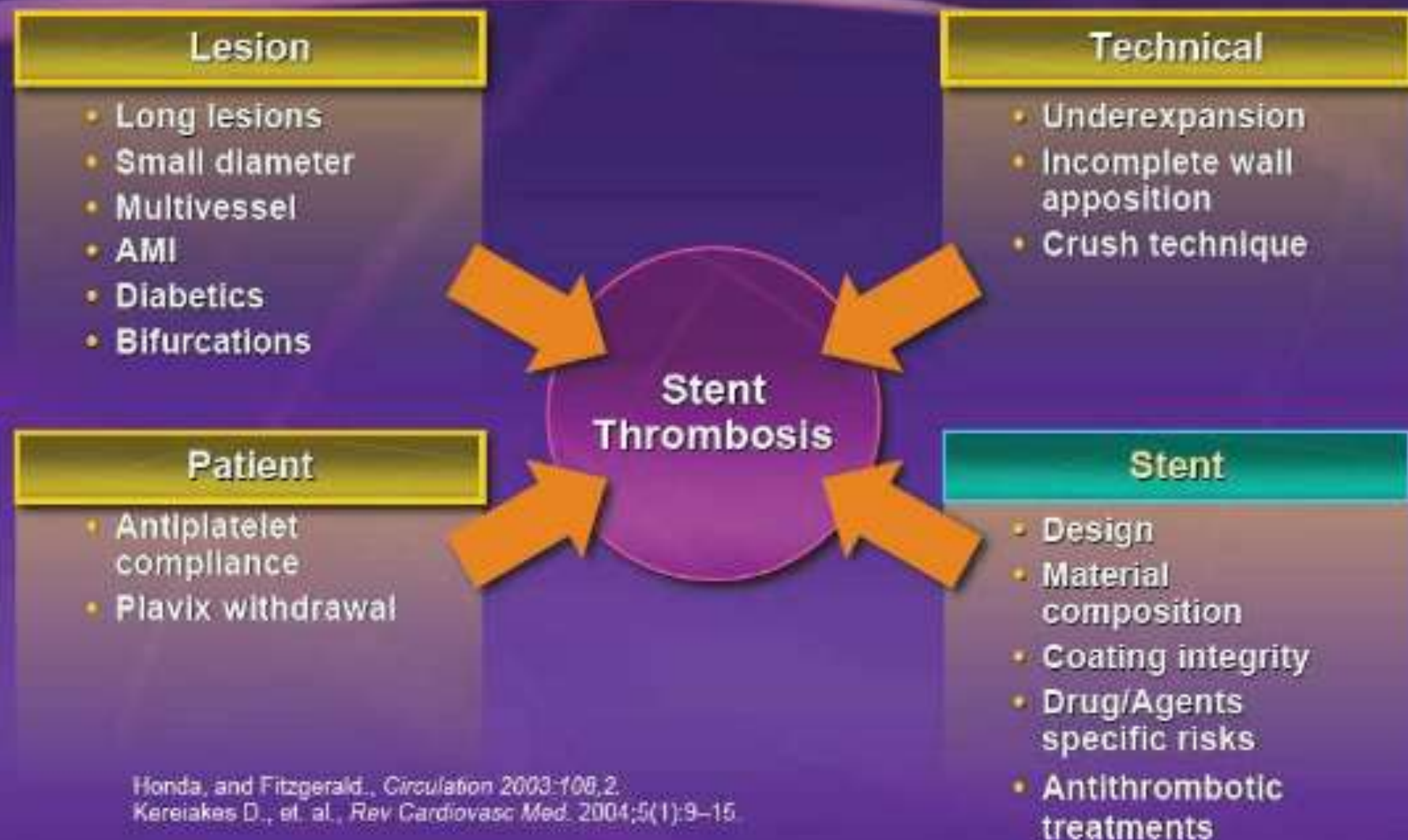


MR 6.5 cm<sup>2</sup>  
LVEF 30%

<b>超声描述:</b>	<p>各瓣膜形态正常; 二尖瓣开放幅度减少, EPSS: 21.4mm; 左心扩大, 左室壁搏动弥漫减弱, 其中左室下壁及前间隔心肌变薄, 搏动明显减弱, 未见血栓; 心包腔可见液性暗区, 右房后壁后 4.5mm;</p> <p>组织多普勒 二尖瓣环室间隔组织速度S' 4cm/s, E' 4cm/s A' 3cm/s;</p> <p>CDFI: 主动脉瓣返流, 彩束面积 1.0cm<sup>2</sup> 二尖瓣返流, 彩束偏心, 面积 6.5cm<sup>2</sup></p>
<b>超声提示:</b>	<p>符合冠心病心肌梗塞后超声改变 左室收缩舒张功能明显减退 中度二尖瓣返流(考虑缺血相关) 轻度主动脉瓣返流 少量心包积液</p>



# Stent Thrombosis is Multifactorial



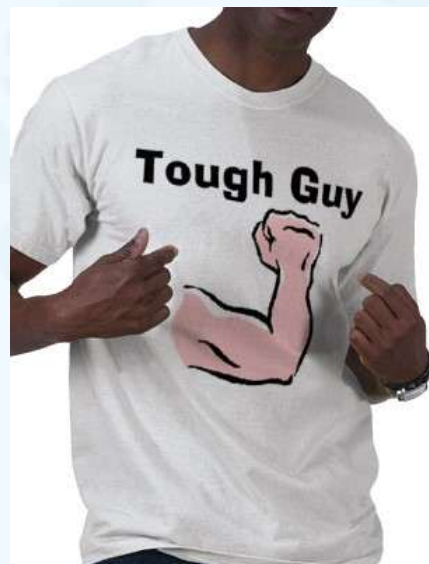# Discussion

- What is the trigger target at the beginning ?
- Was it a very late ST or ...?
- Would intervene RCA in same setting ?
- Thanks for my teammates, the patient as well!



# 堅強

在人生的追求中，难免会或多或少的遇到一些挫折和厄运。此时的我们应该告诉自己，要坚强，用自己的坚强的意志去战胜挫折，毫不气馁。



Thank You!

