



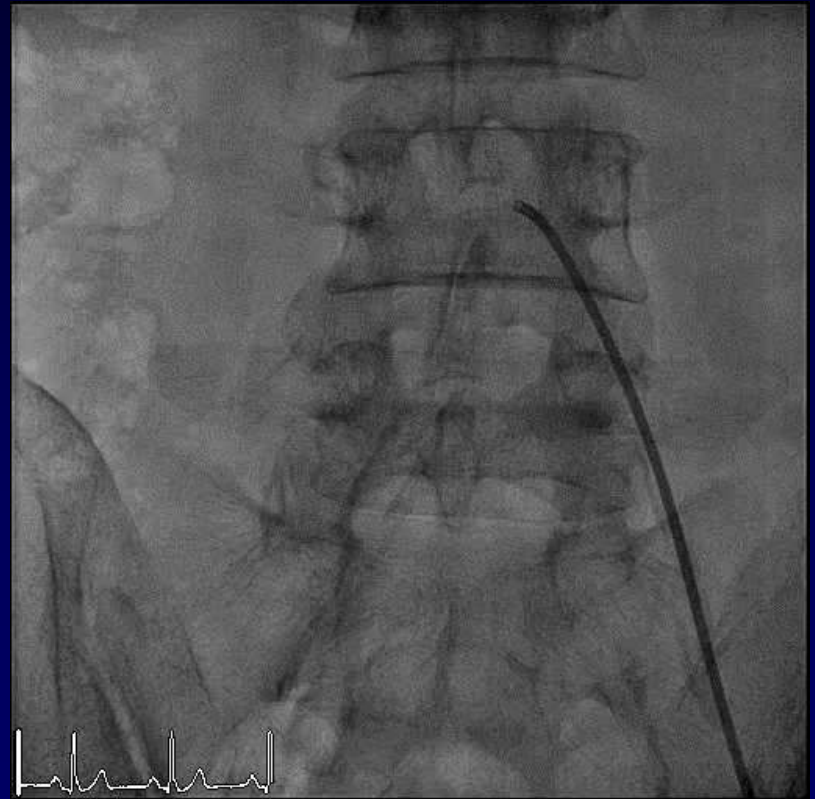
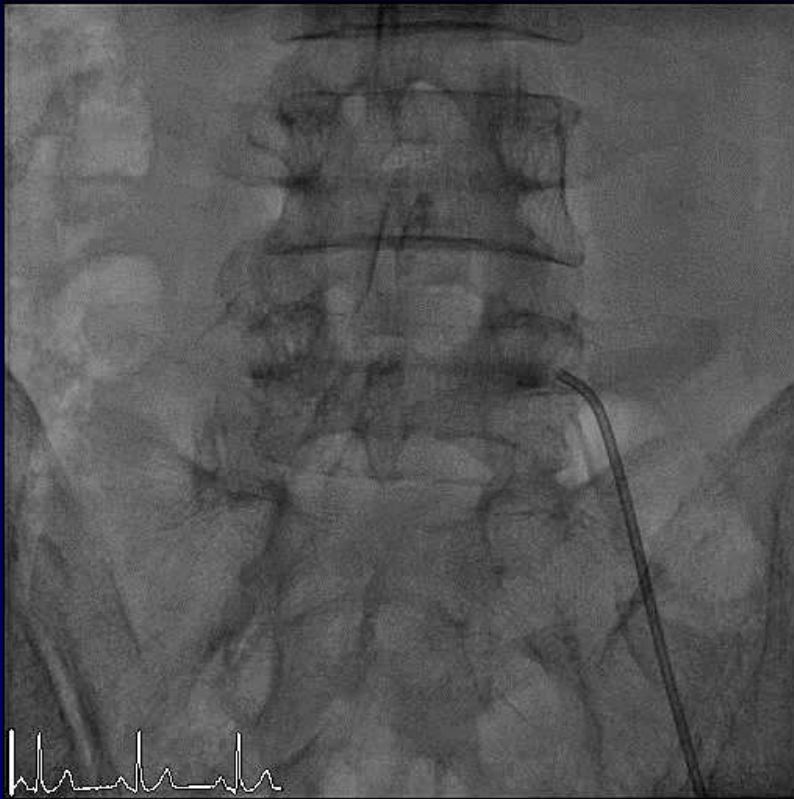My Challenging Case

Wasan Udayachalerm, MD, FAPSC

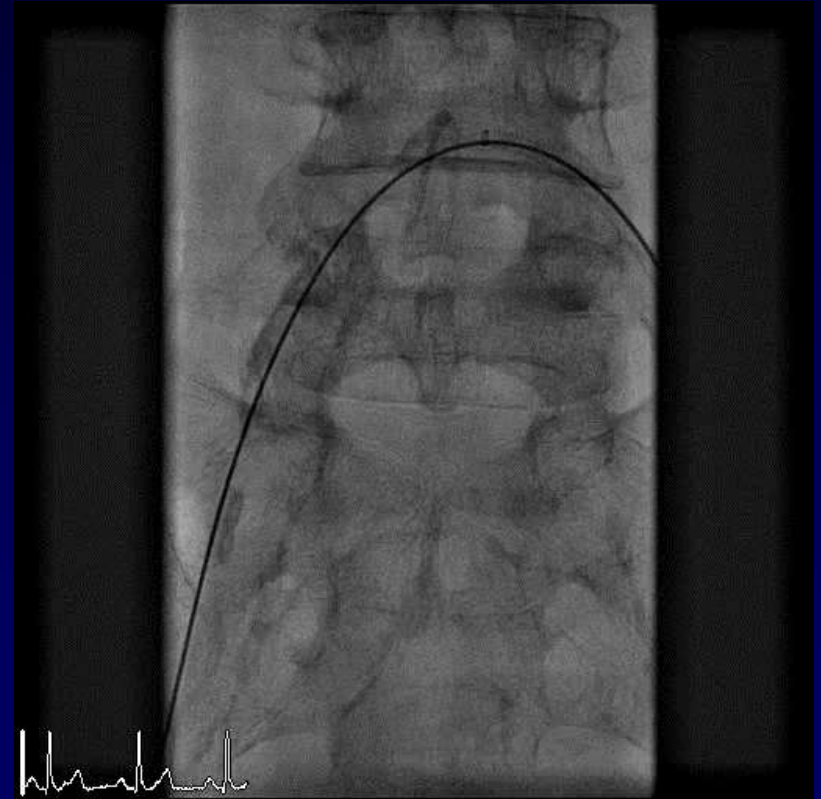
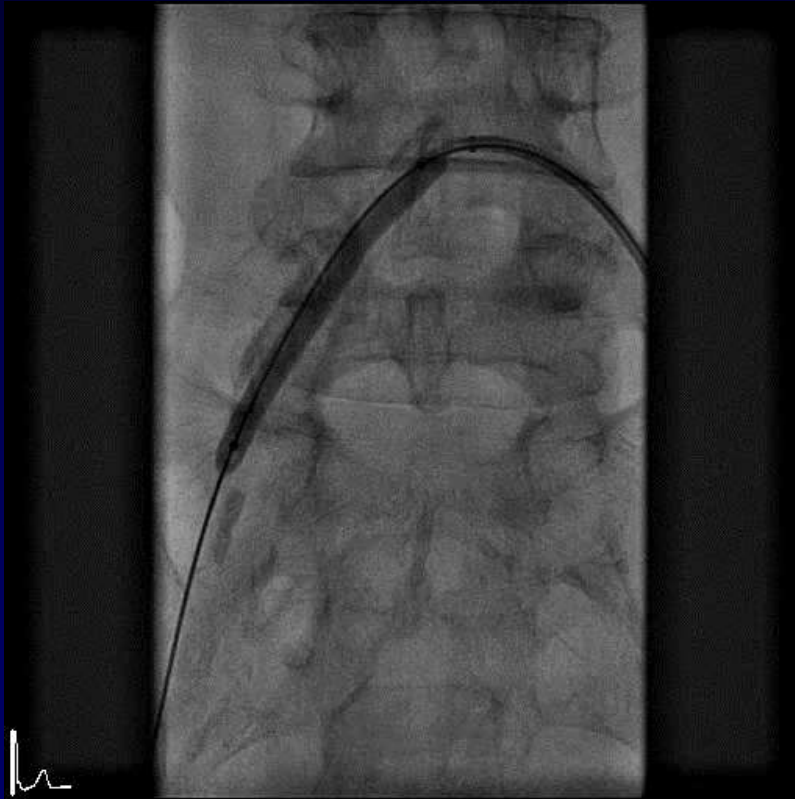Cardiac center

King Chulalongkorn Memorial Hospital

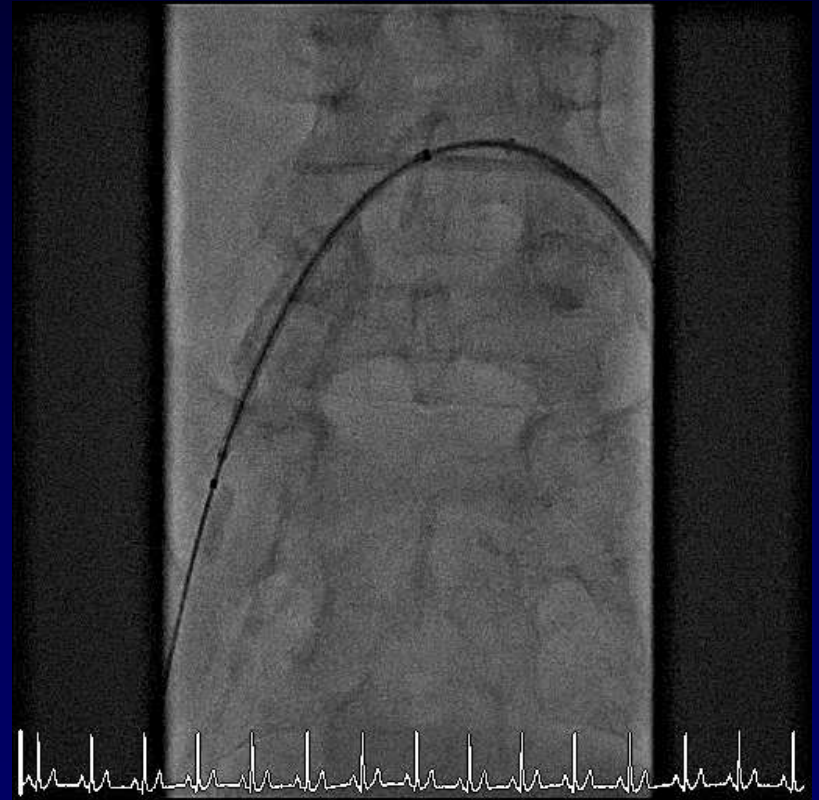
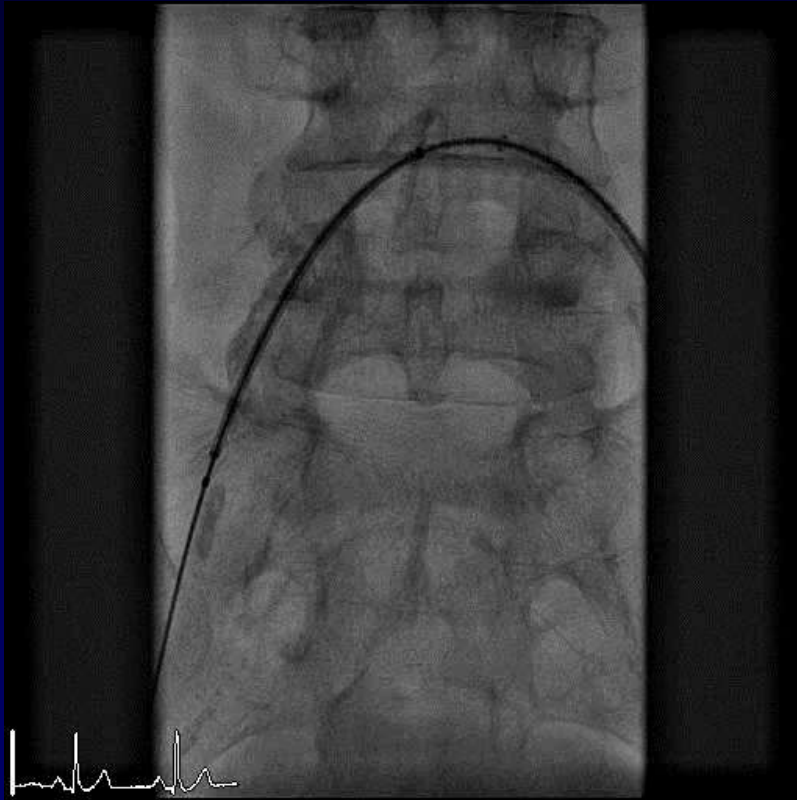
A case of male, 56 y/o with claudication both legs



Change to Stiff guide wire and Balloon predilatation



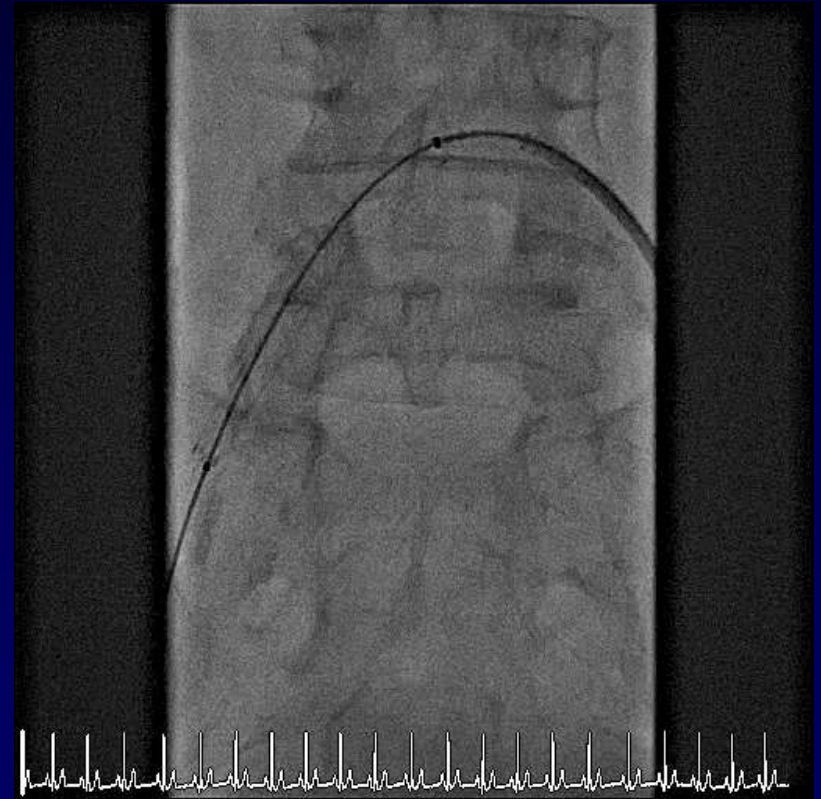
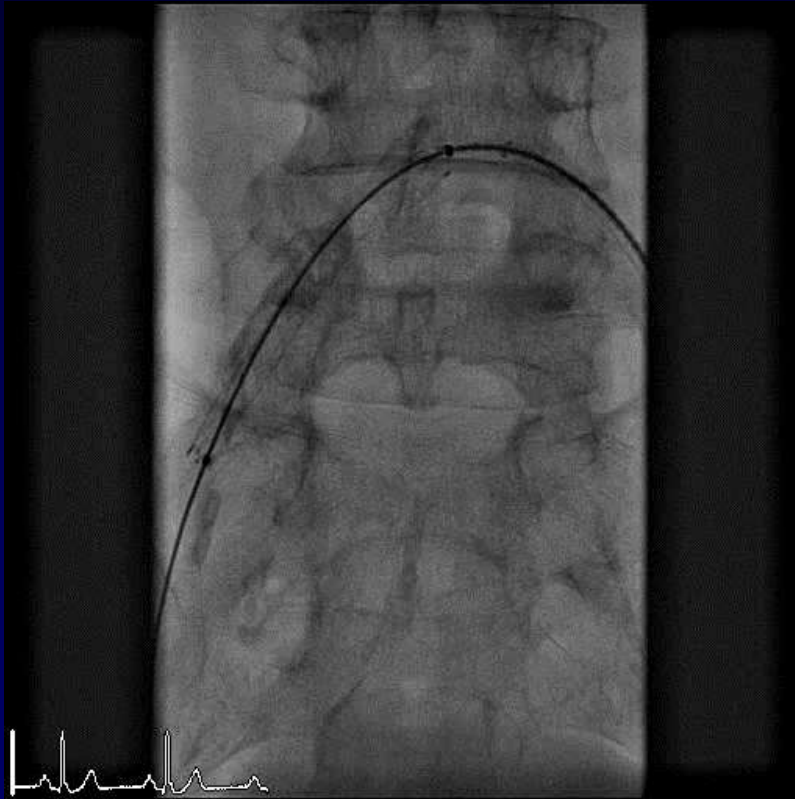SDS system but.....



What should you do?



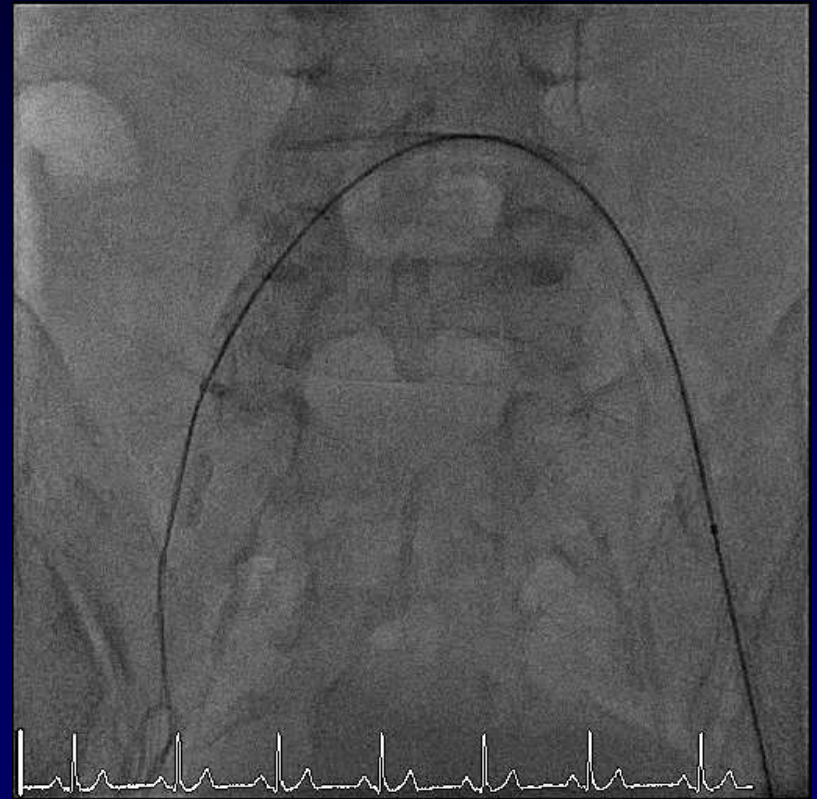
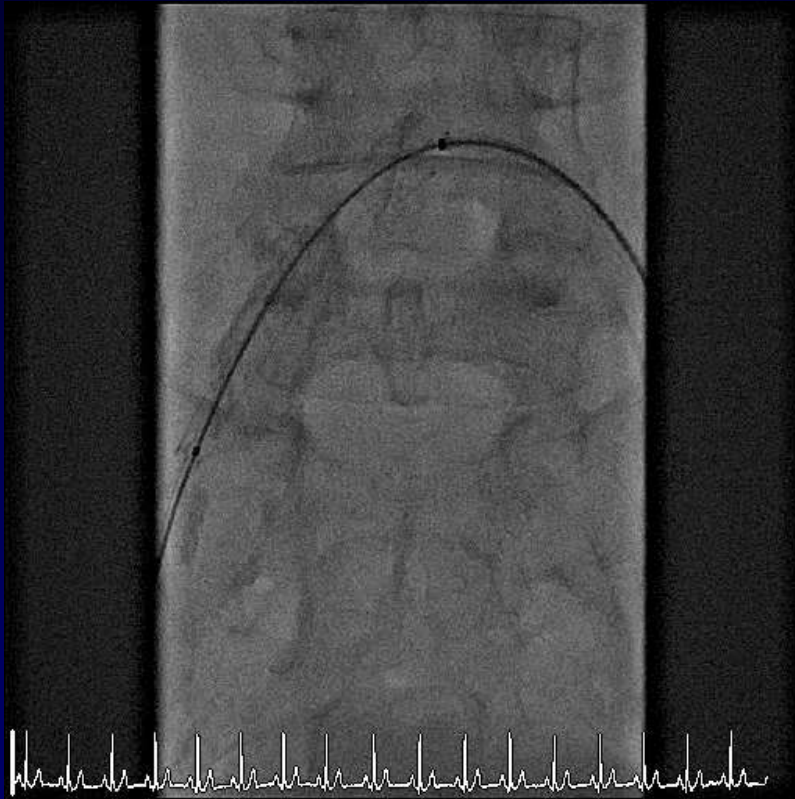
Angio.....Push & Pull



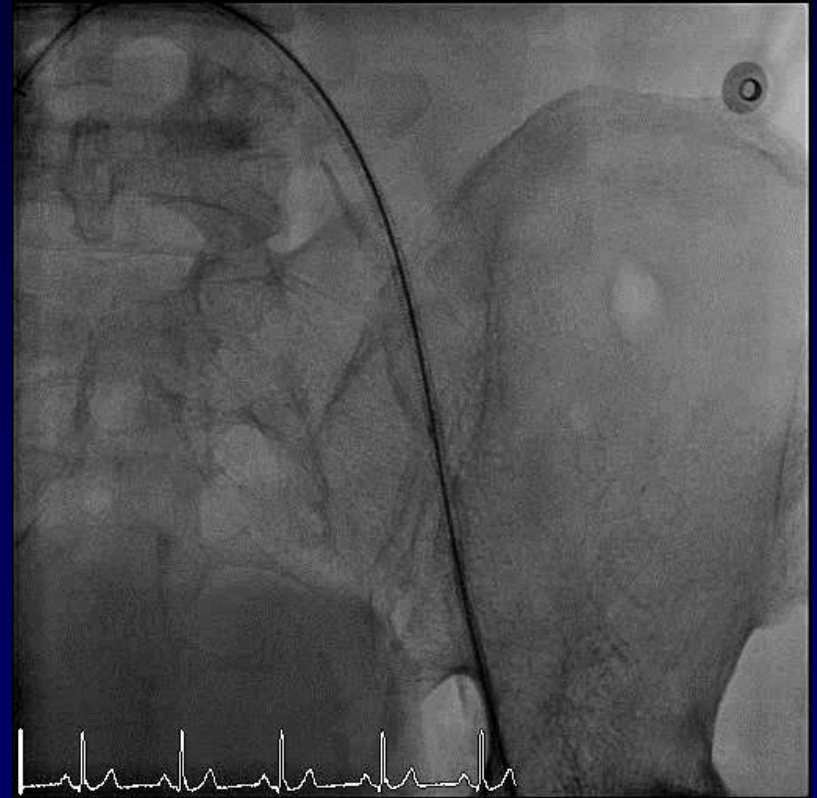
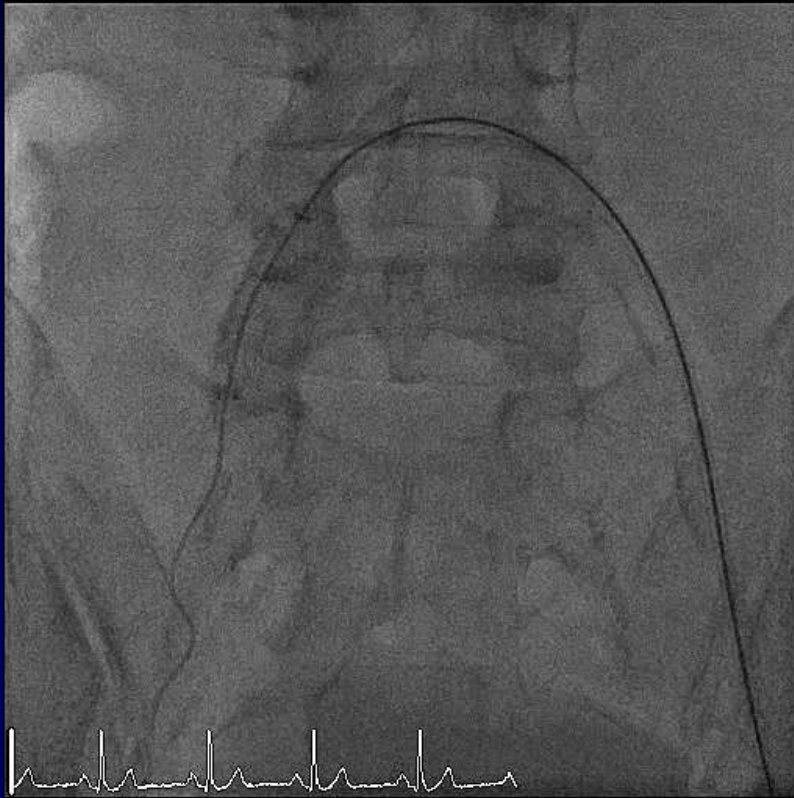
PULL!!



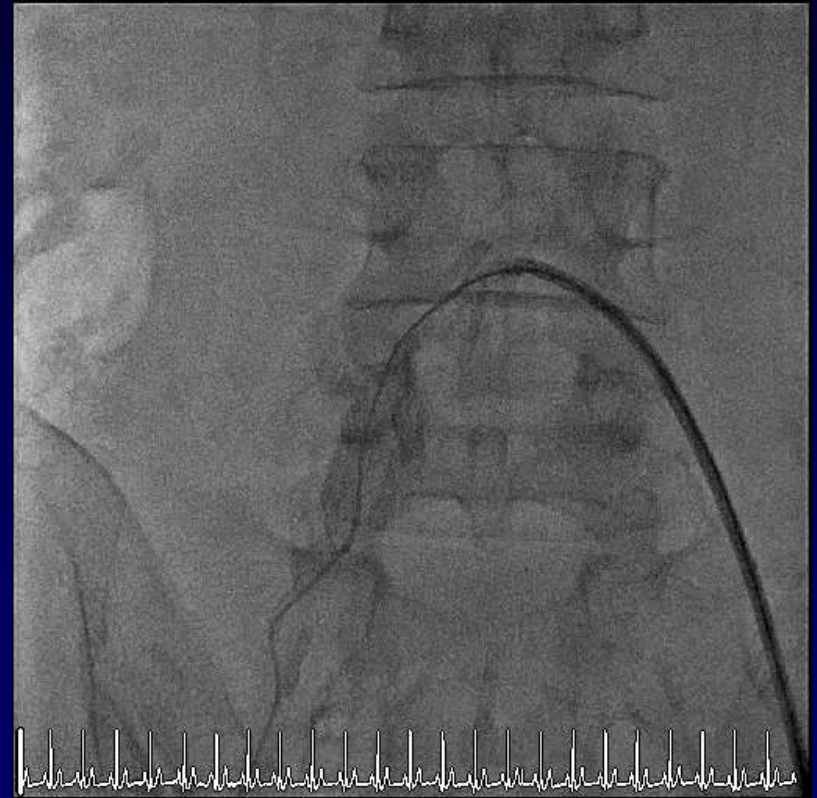
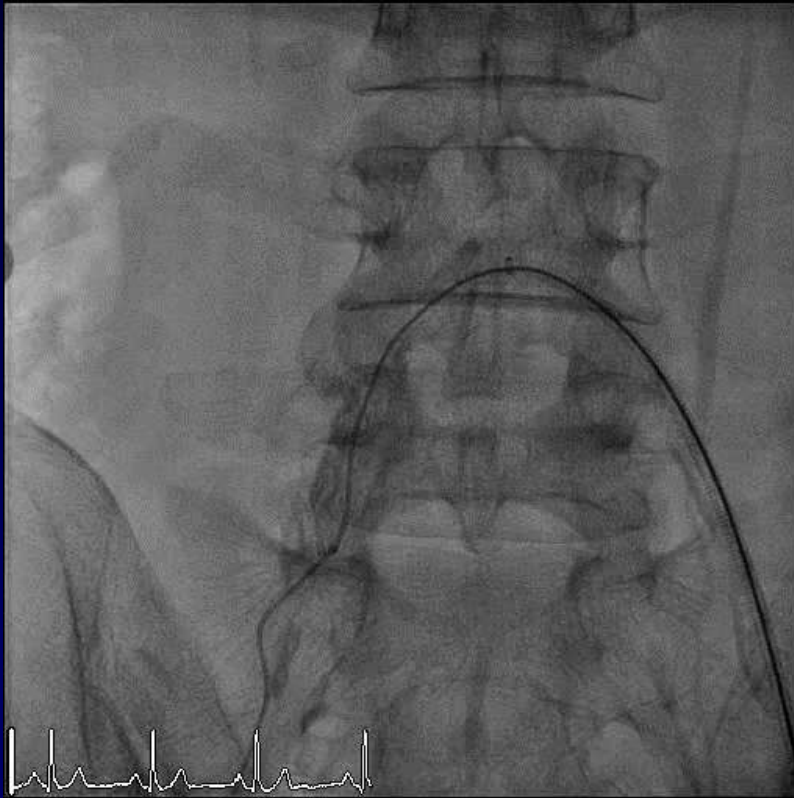Good result?



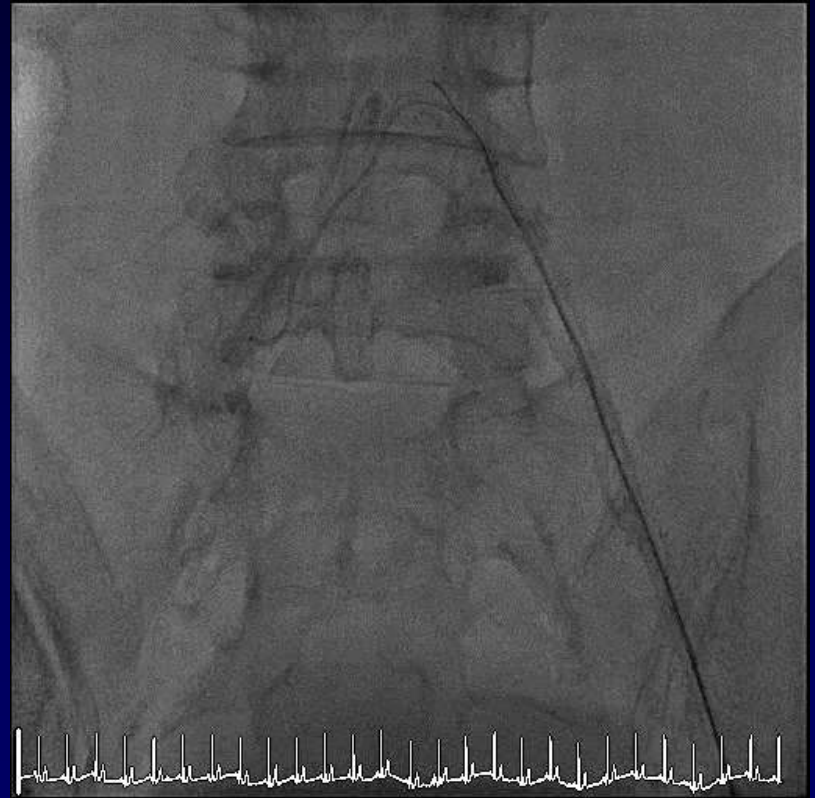
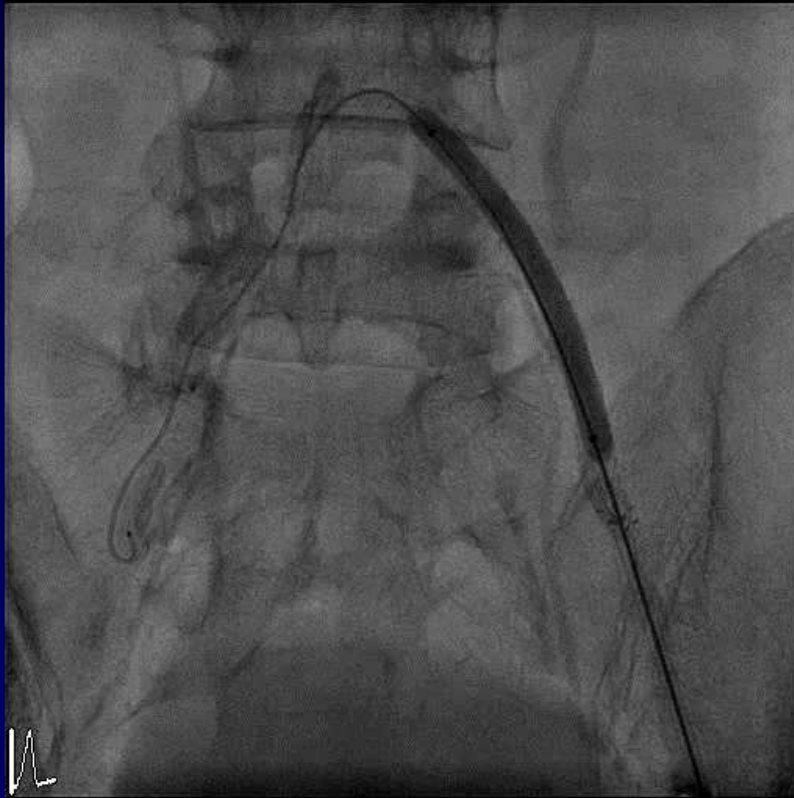
What you see?



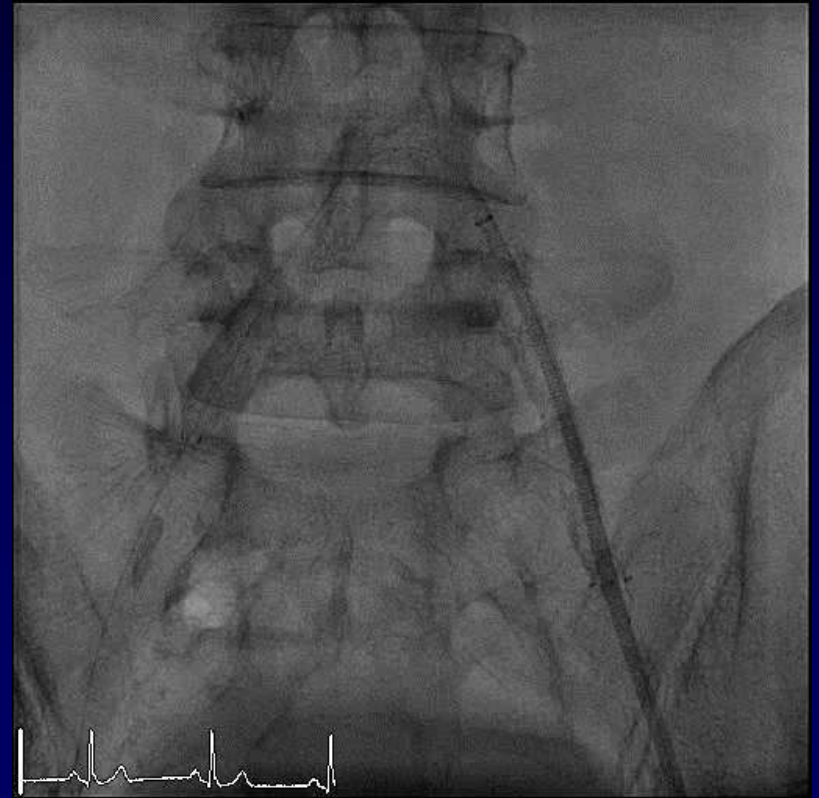
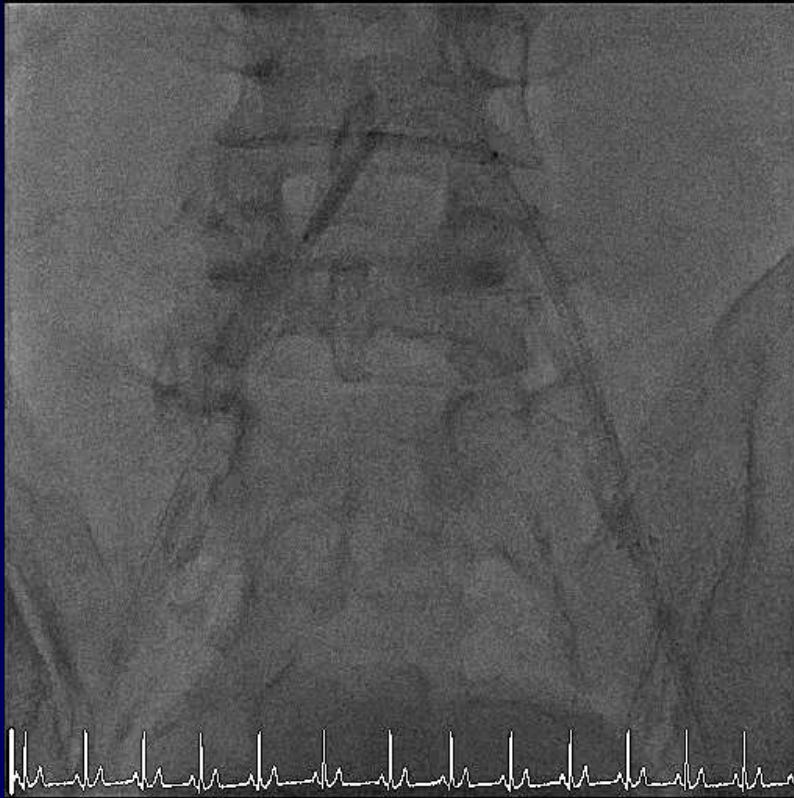Contrast check and.....



Dilated LCIA and wiring



Dilated RCIA

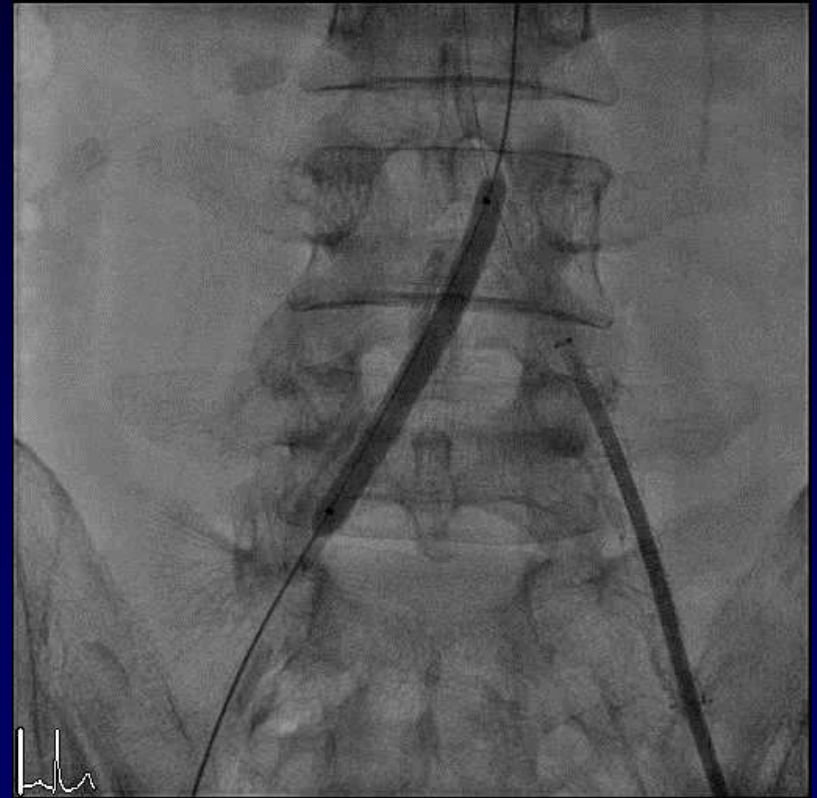
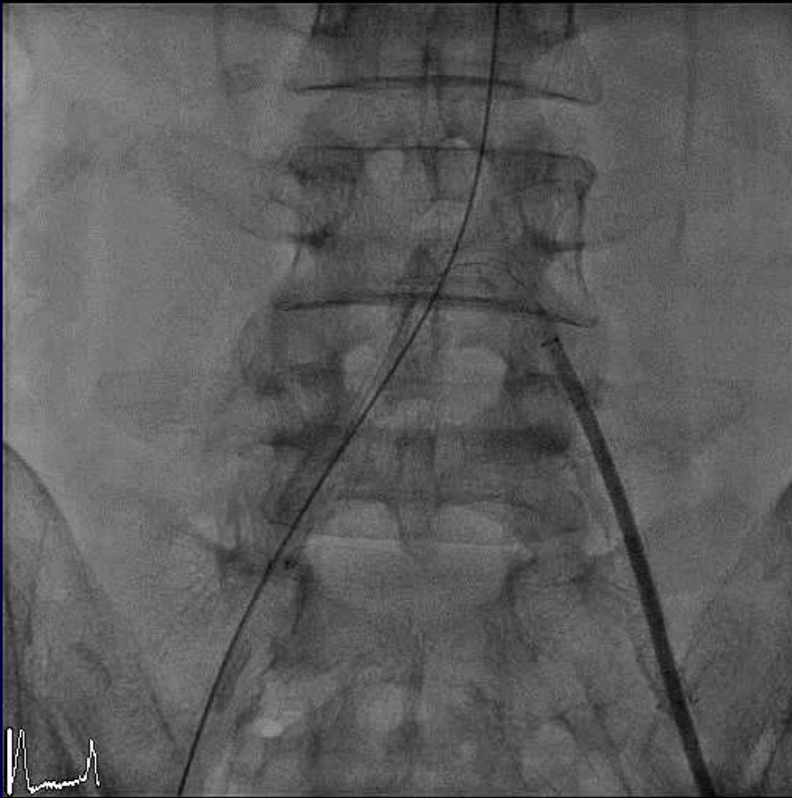


What will you do next?

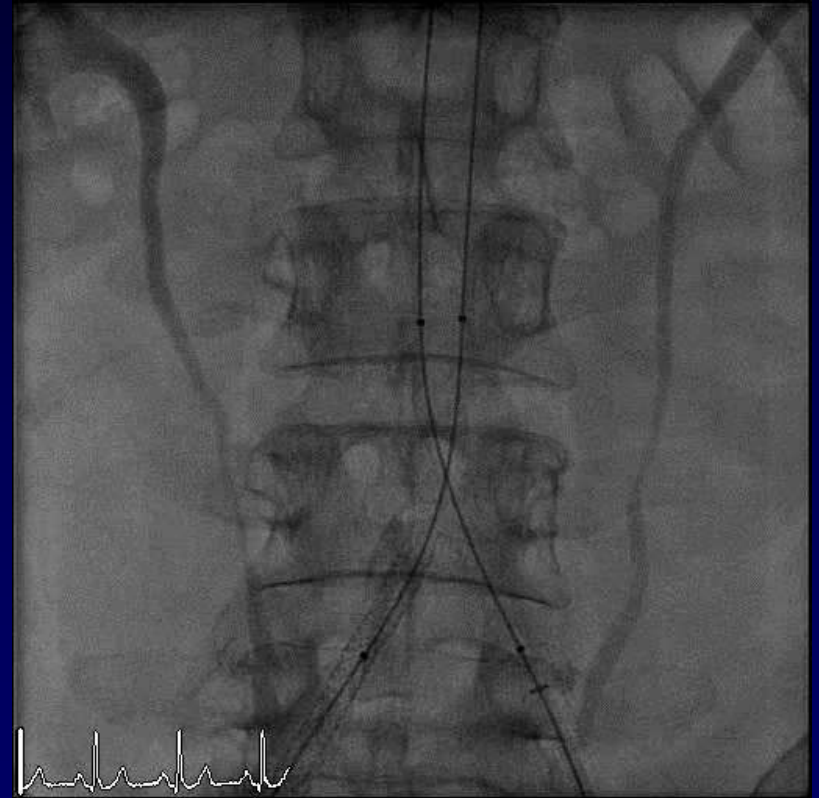
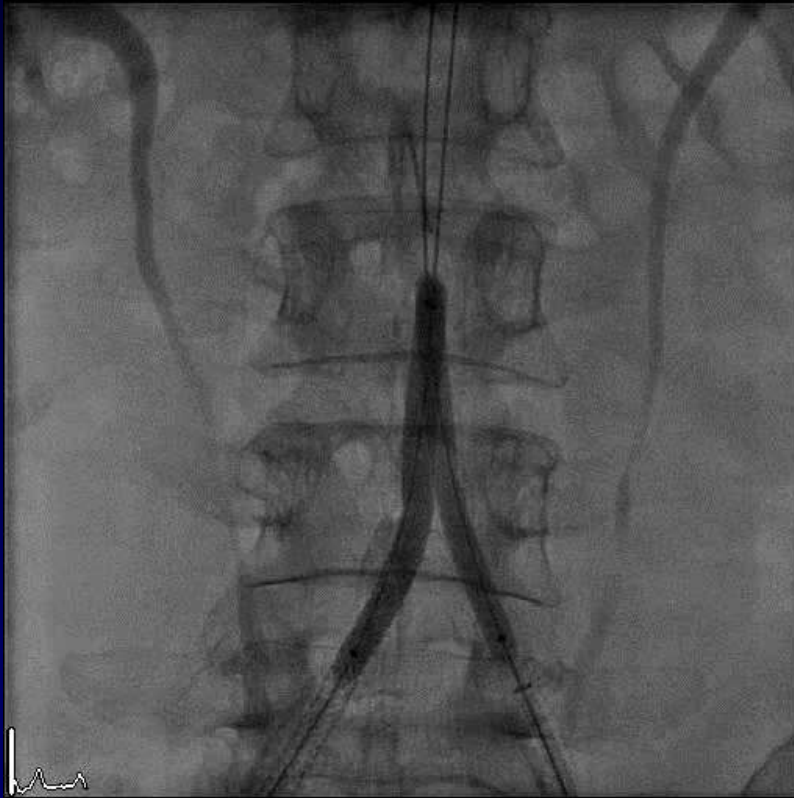Stop the procedure?

Continue?

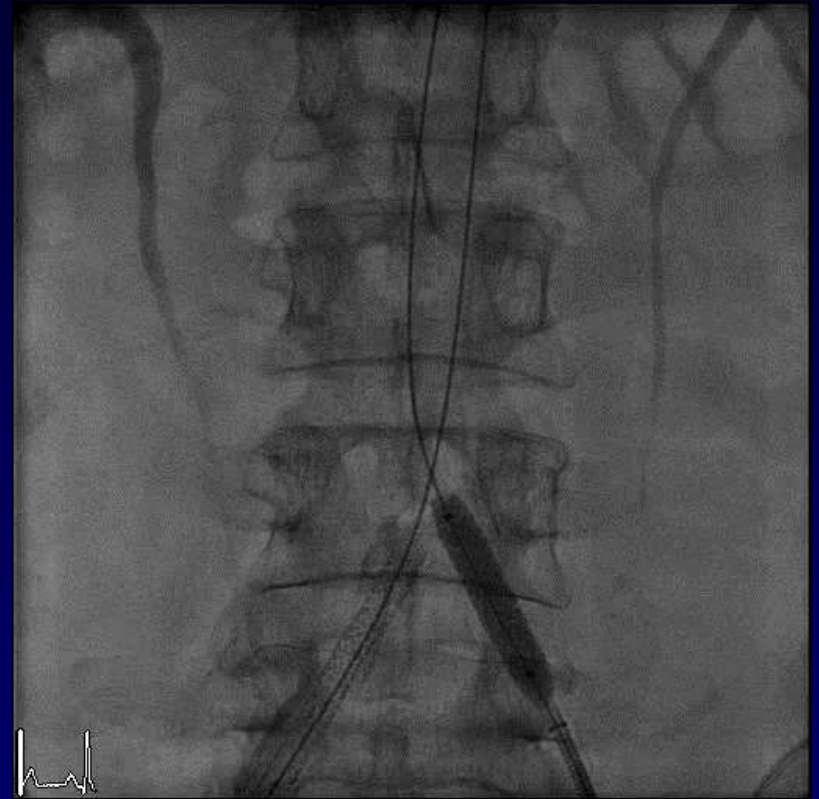
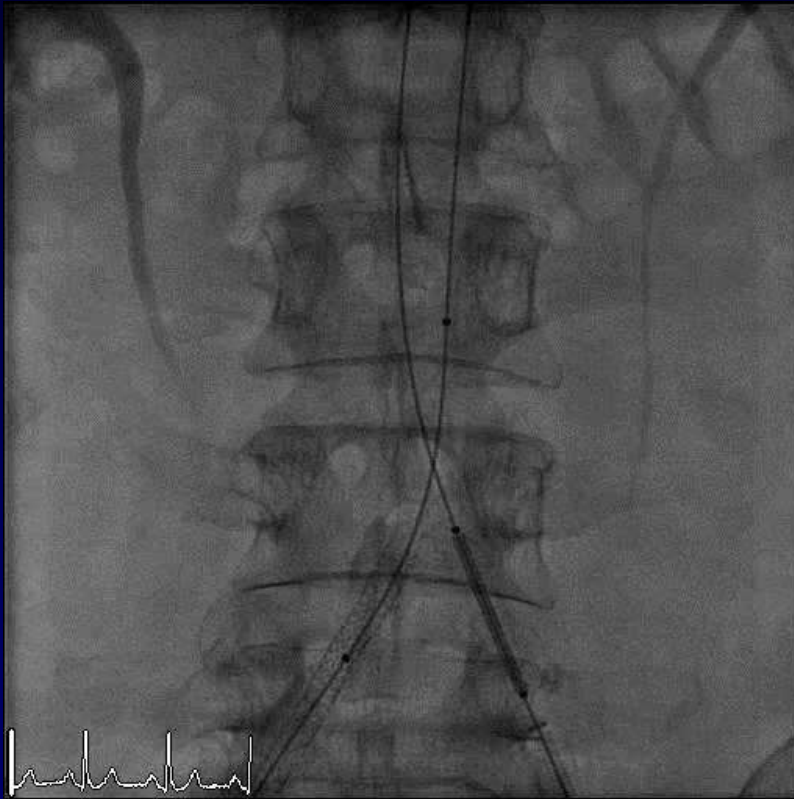
Wiring and dilated & stented RCIA



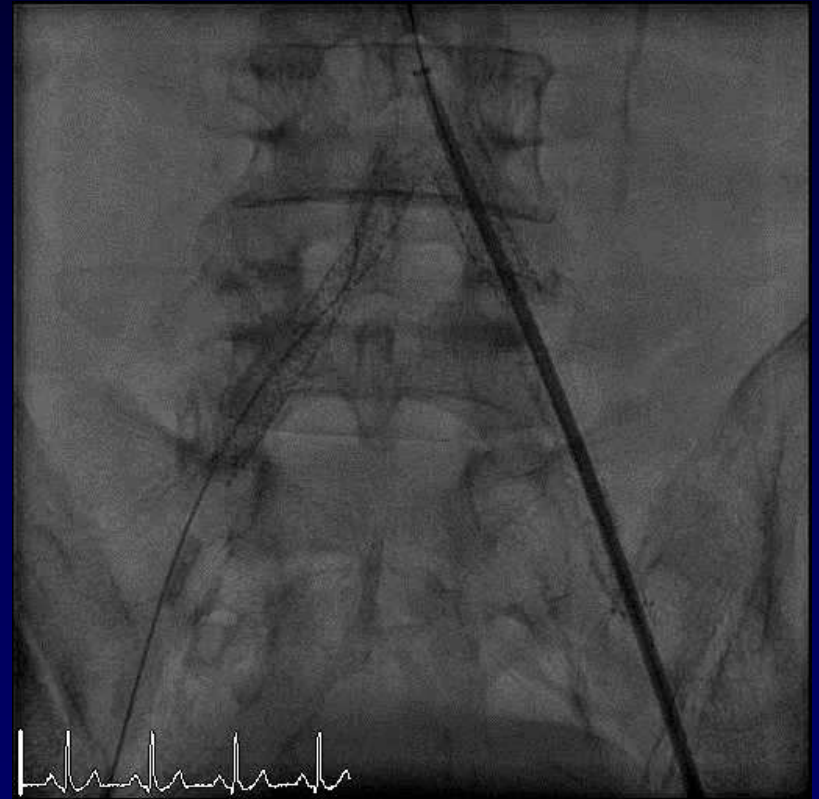
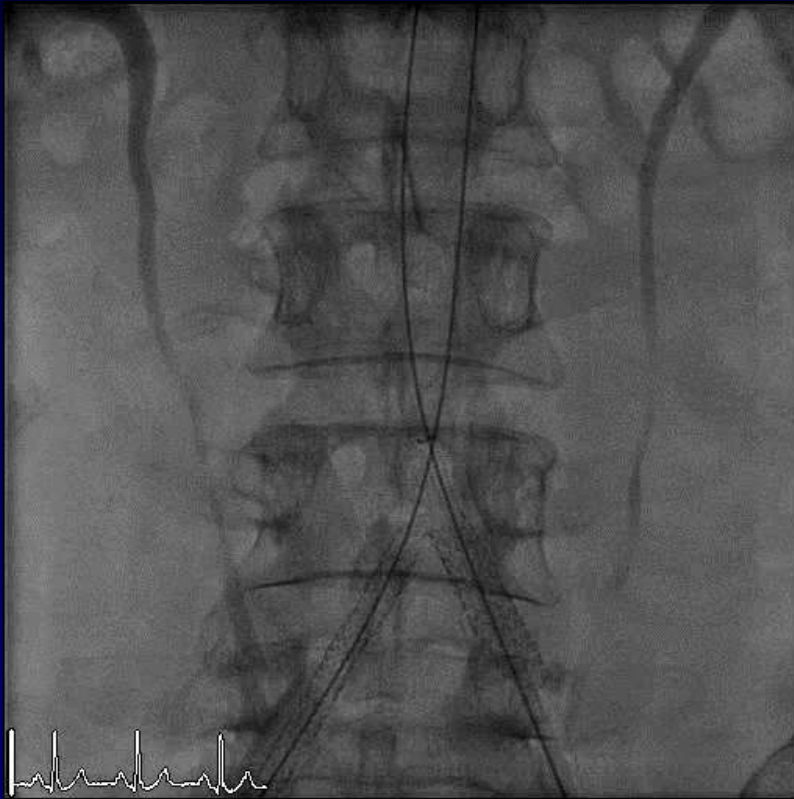Kissing dilatation



Stented LCIA



Final Results



Take Home

- Self-delivery system in bending part should be careful manipulated
- This is an example of delivery system failure and caught one of the proximal struts
- To deal with complications, don't be panic
- Have everything ready in the cath lab!!

