An Acute Coronary Syndrome Case due to Spontaneous Coronary artery Dissection Evaluated by CT, IVUS and OFDI

Best Performance of Cardiac CT Working group

Masaaki Okutsu
Nozaki Tokushukai Hospital
Department of Cardiology
Osaka, Japan

Case

- 33 y.o. female
- continuous chest pain for 3 hours
- Coronary risk factor) none
- Life history) smoking(-), drinking(-)
- Family history) cardiovascular disease(-)

Laboratory data

- AST 44 IU/L
- ALT 35 IU/L
- LD 294 IU/L
- γ-GTP 14 IU/L
- BUN 20.0 mg/dl
- Cr 0.59 mg/dl
- Na 141 mEq/L
- K 3.8 mEq/L
- Cl 106 mEq/L
- CRP 0.08 mg/dl
- Glu 97 mg/dl
- HbA1c 4.9 %

- TG 56 mg/dl
- HDL-C 66 mg/dl
- LDL 102 mg/dl
- CK 297 IU/L
- CK-MB 38 IU/L
- TnI 1.02 ng/ml
- BNP 19.8 pg/ml

- WBC 13910 /μl
- RBC 509×10^4 /μl
- Hb 14.3 g/dl
- Ht 41.0 %
- Plt 27.9×10^4 /μl
- PT INR 1.07
- APTT 24.7 sec
- D-dimer <0.5 μg/ml

ECG

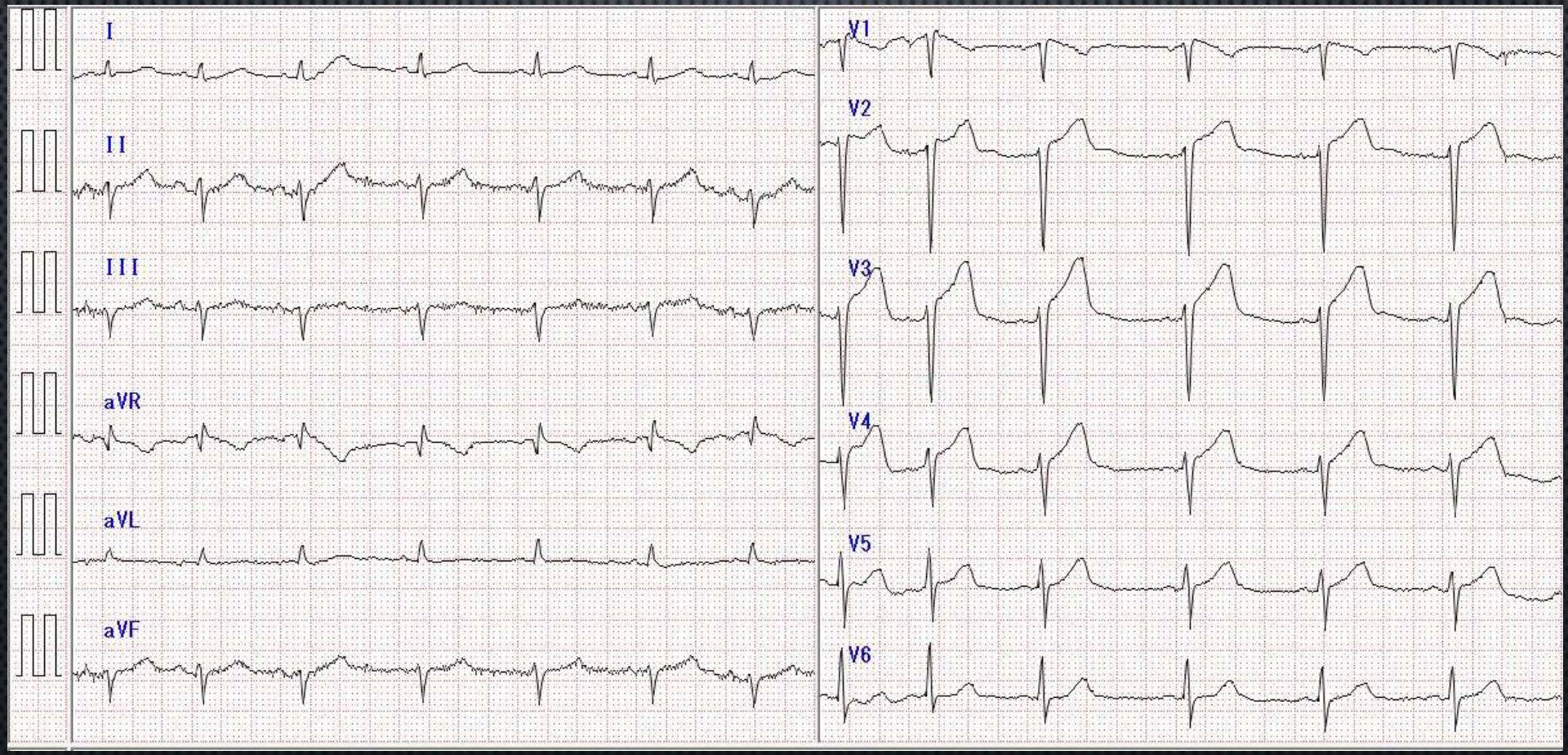

UCG

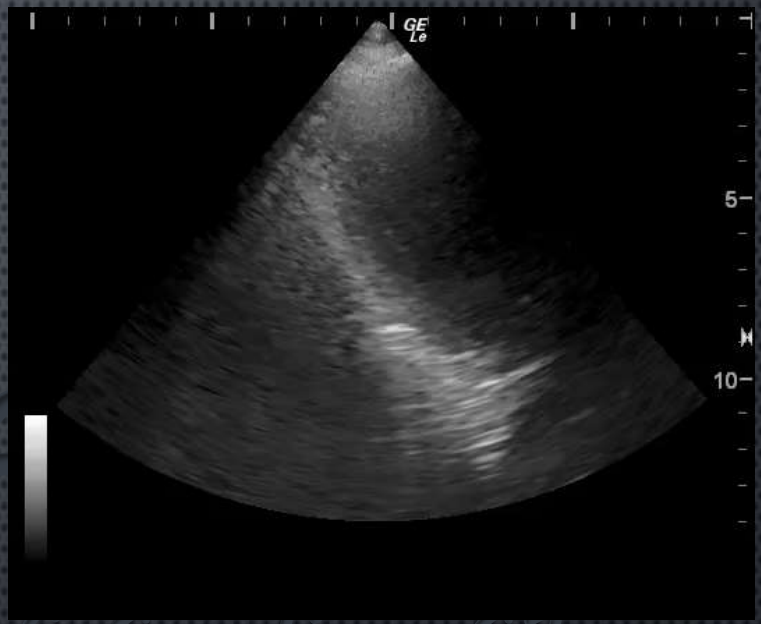

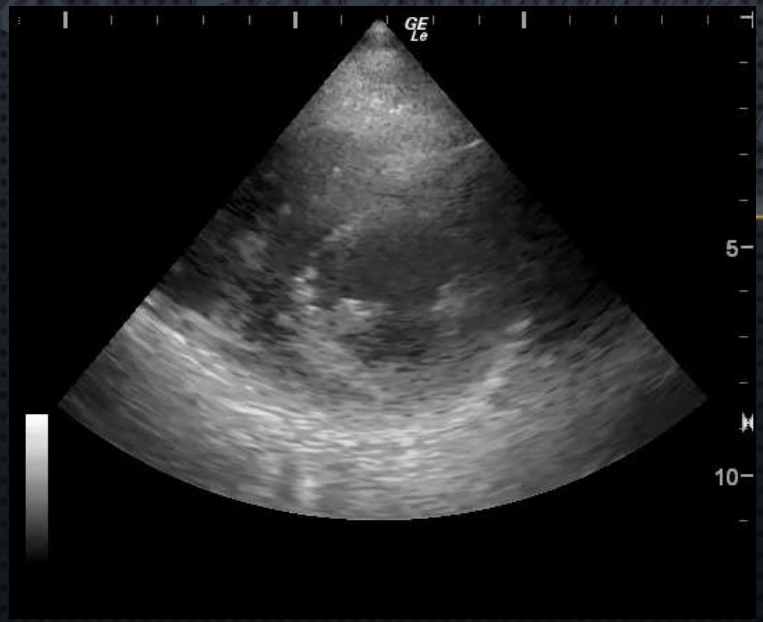

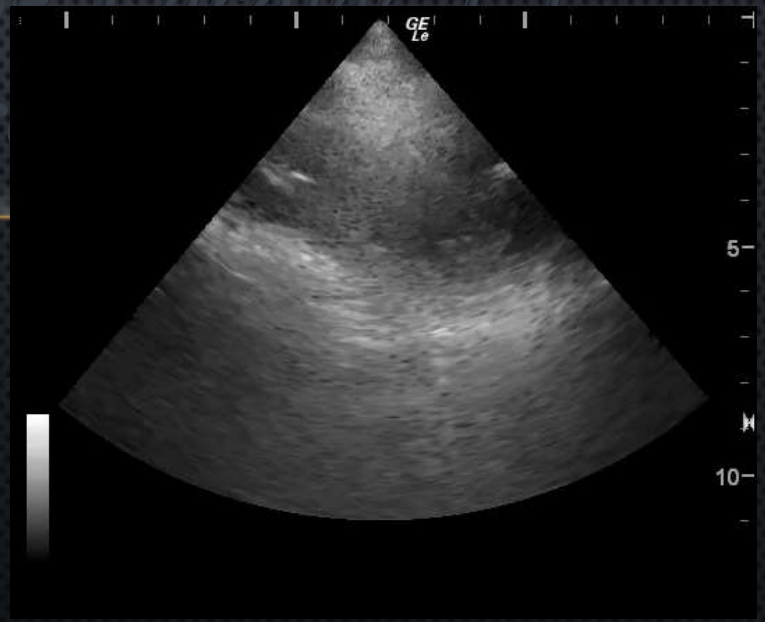

CT

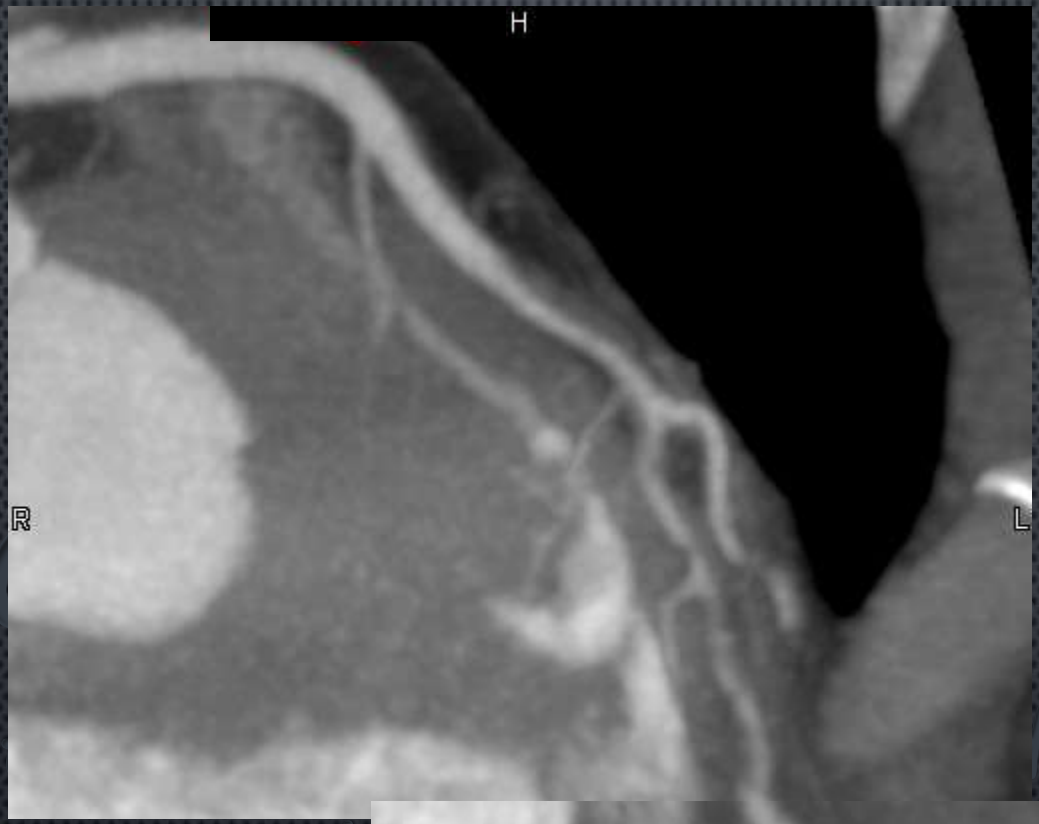

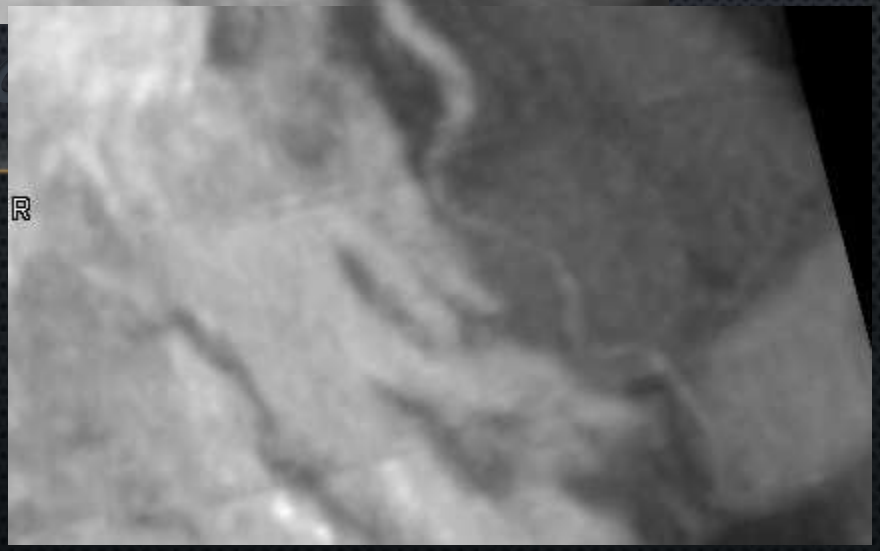

CT LVG

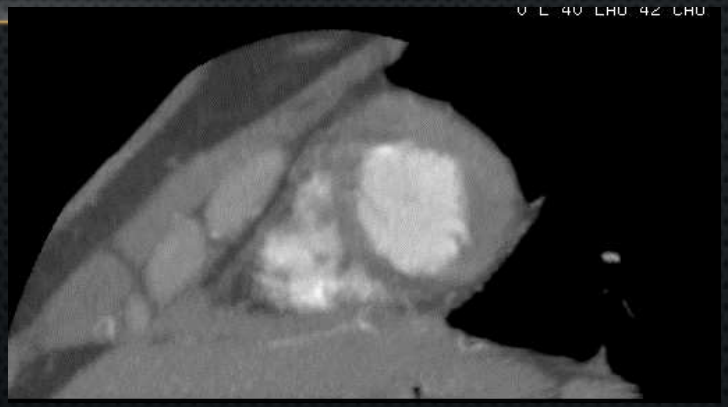

Department of Cardiology, Nozaki Tokushukai Hospital

CAG

IVUS pre

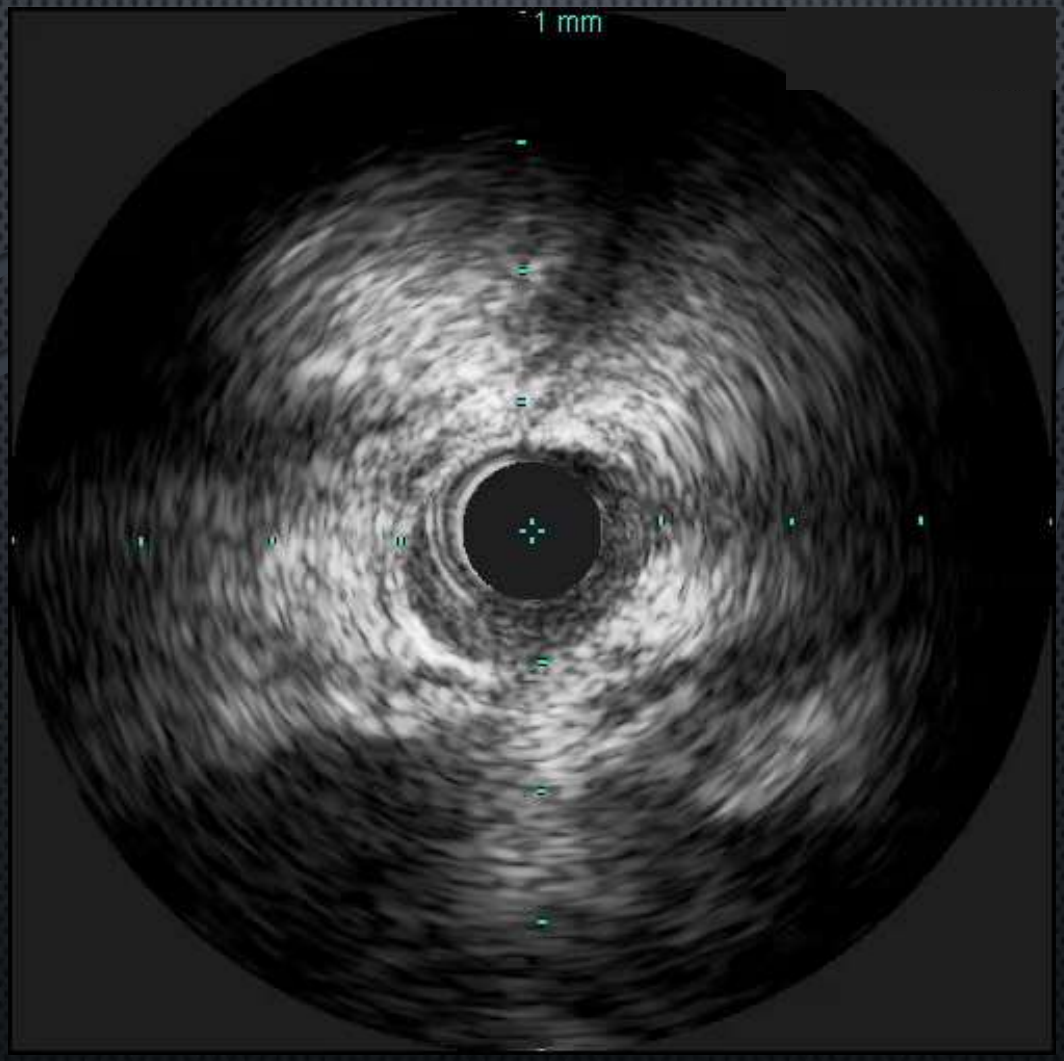

Department of Cardiology, Nozaki Tokushukai Hospital

PCI 1.75mm balloon

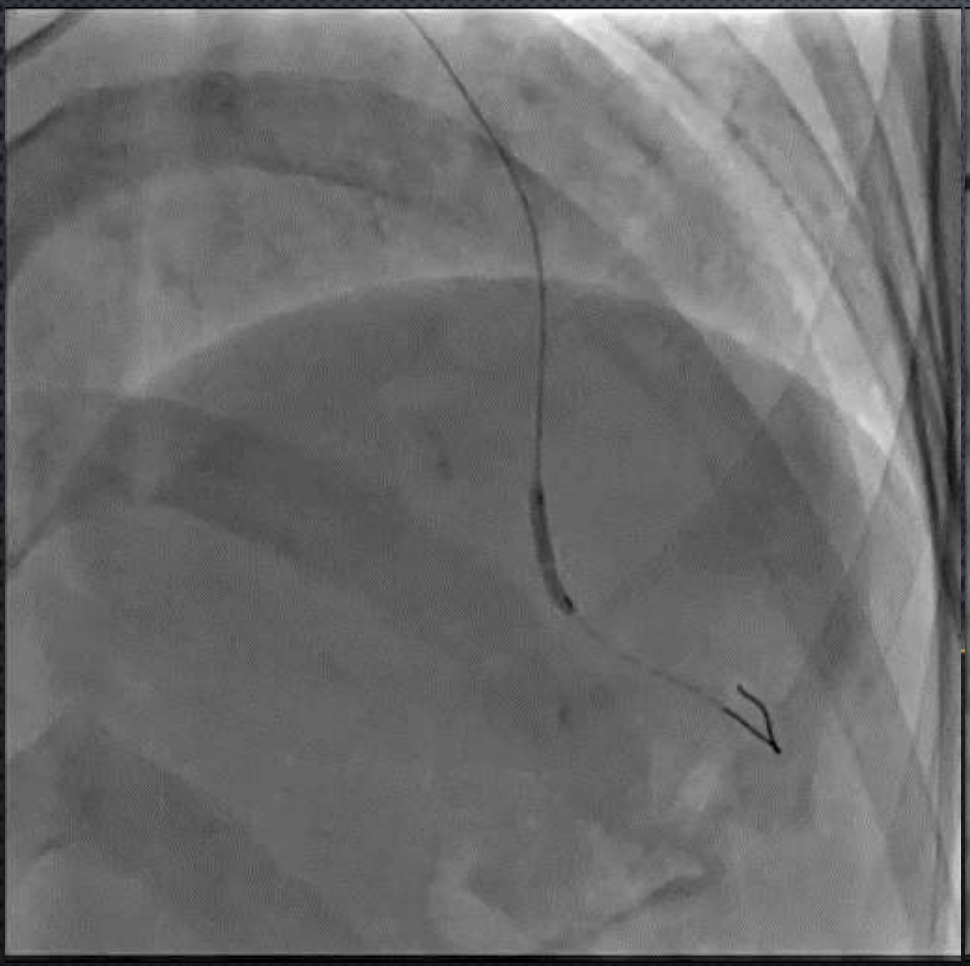

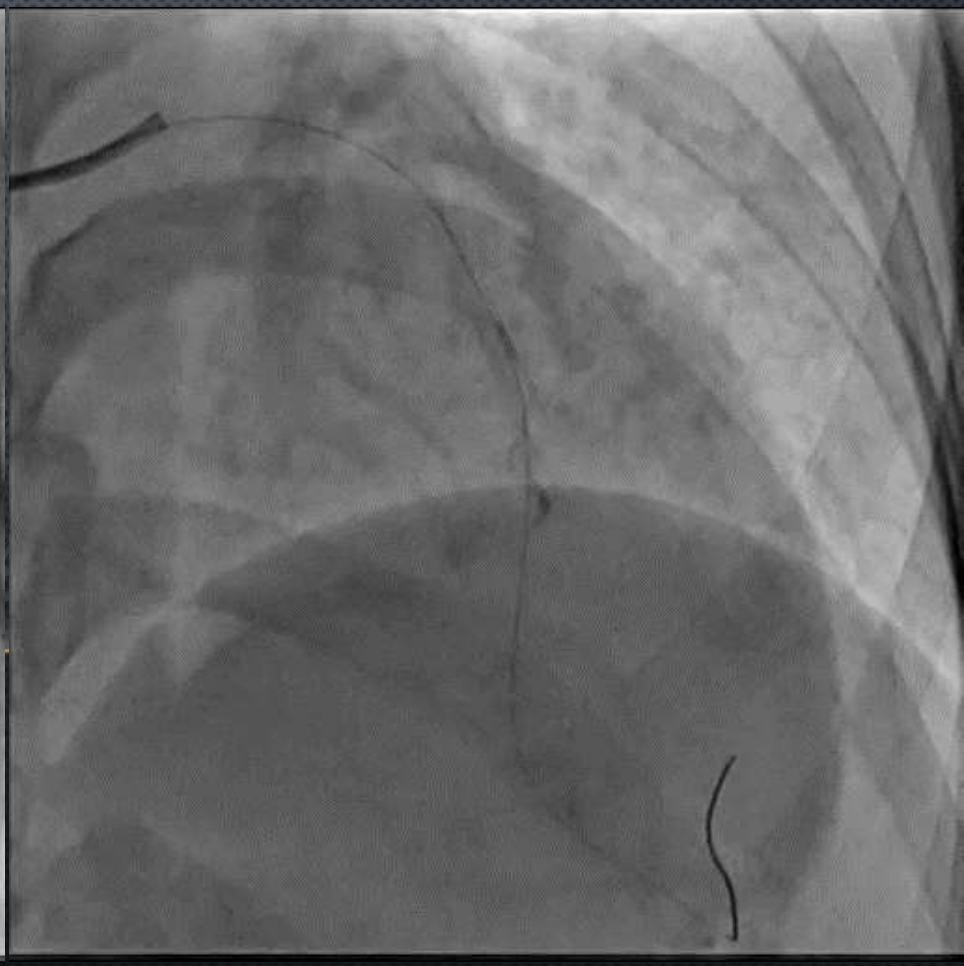

Department of Cardiology, Nozaki Tokushukai Hospital

PCI Laccross NSE 2.25mm

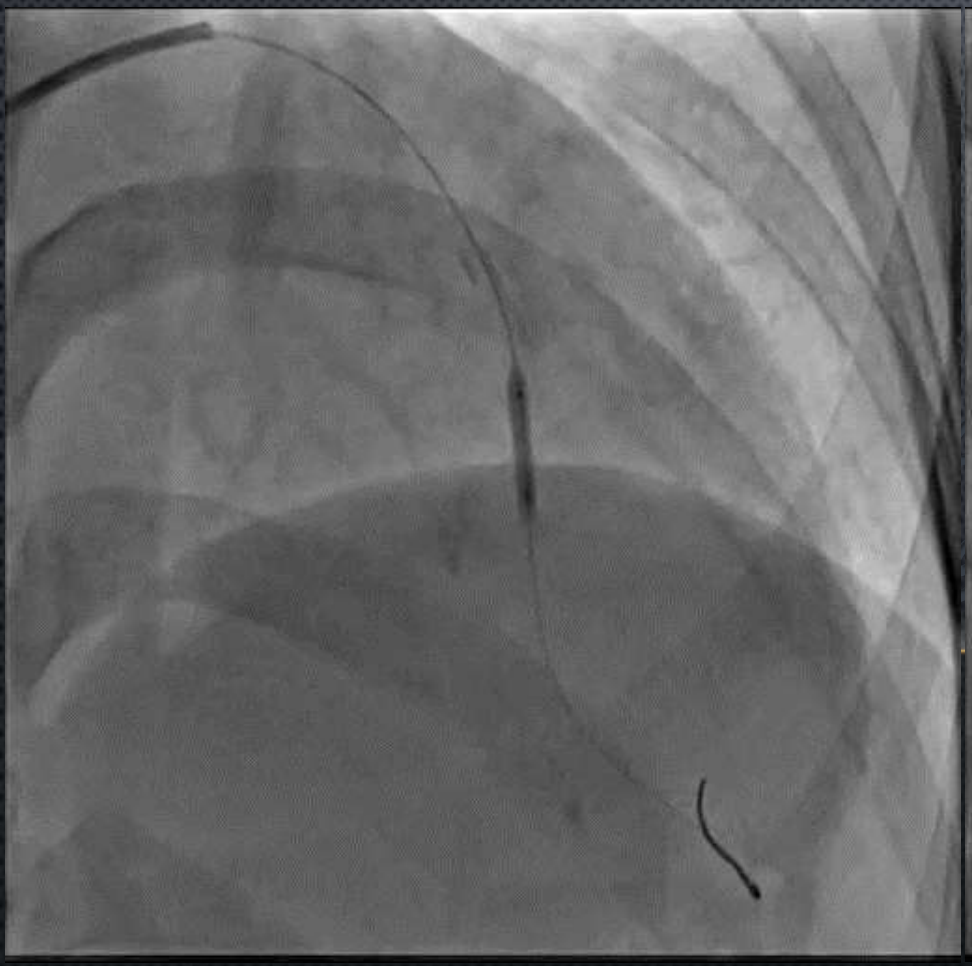

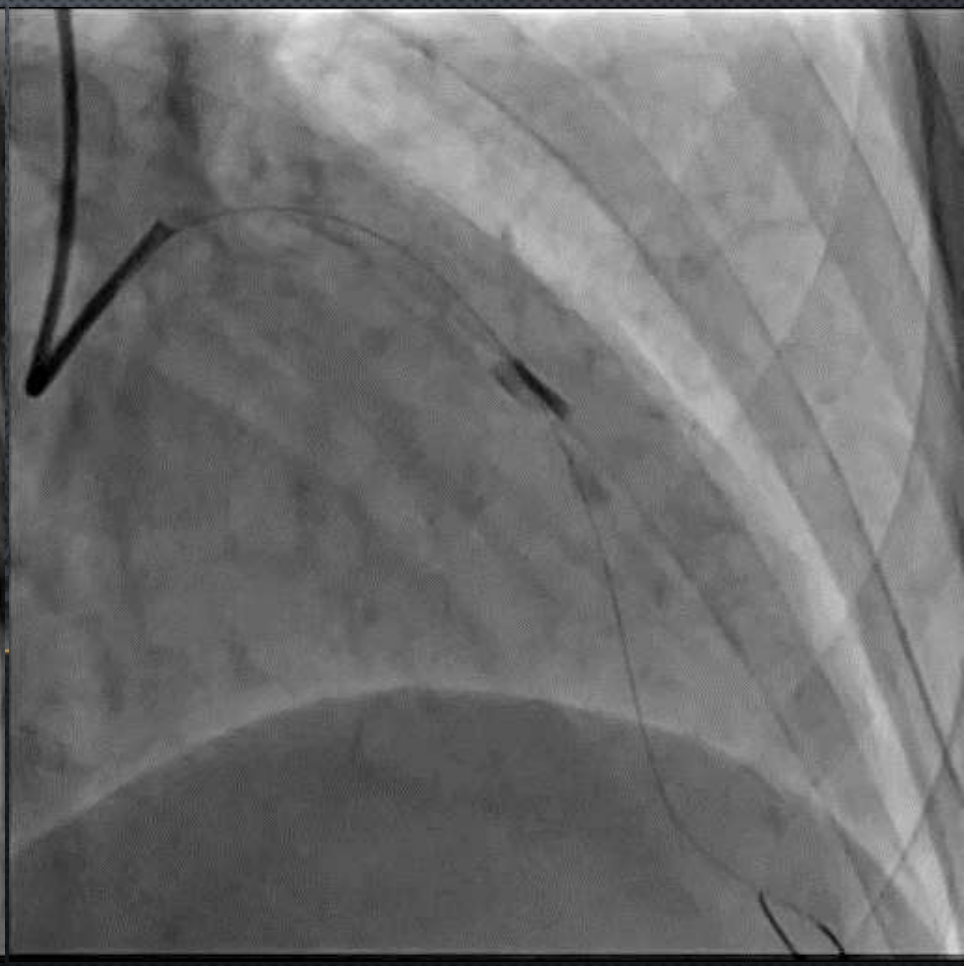

Department of Cardiology, Nozaki Tokushukai Hospital

PCI Laccross NSE 3.5mm

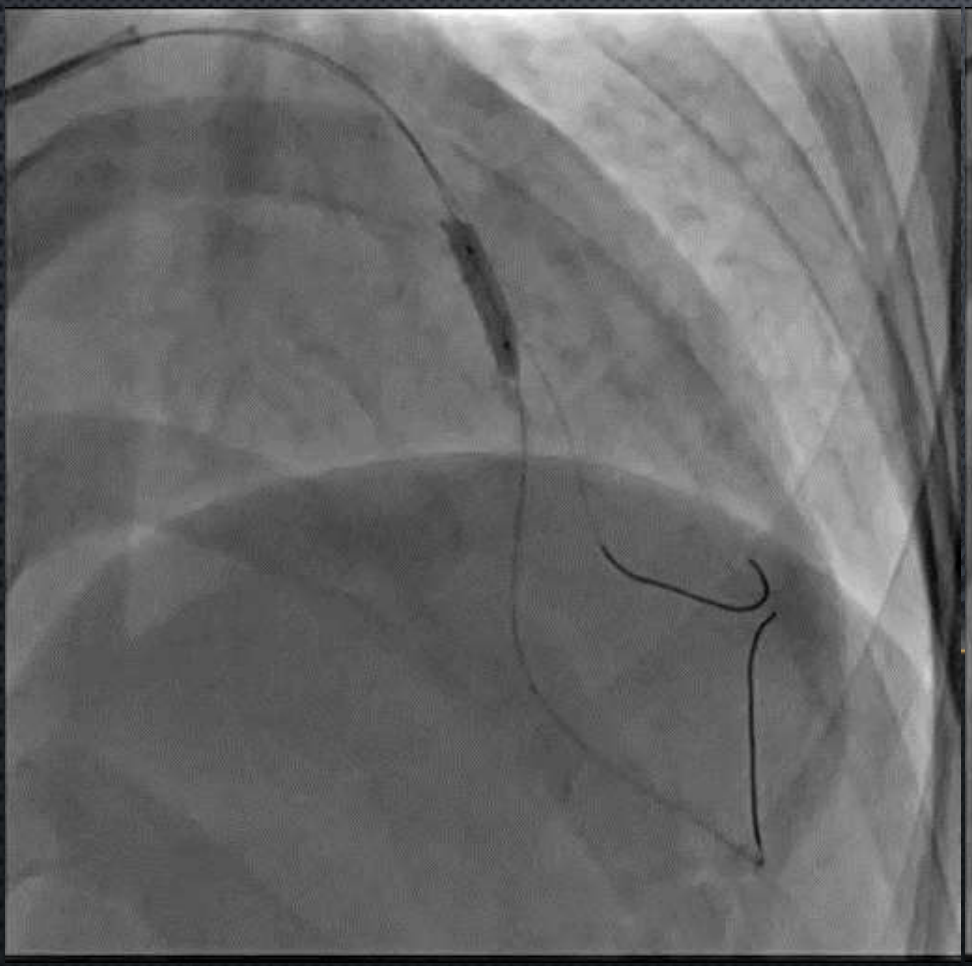

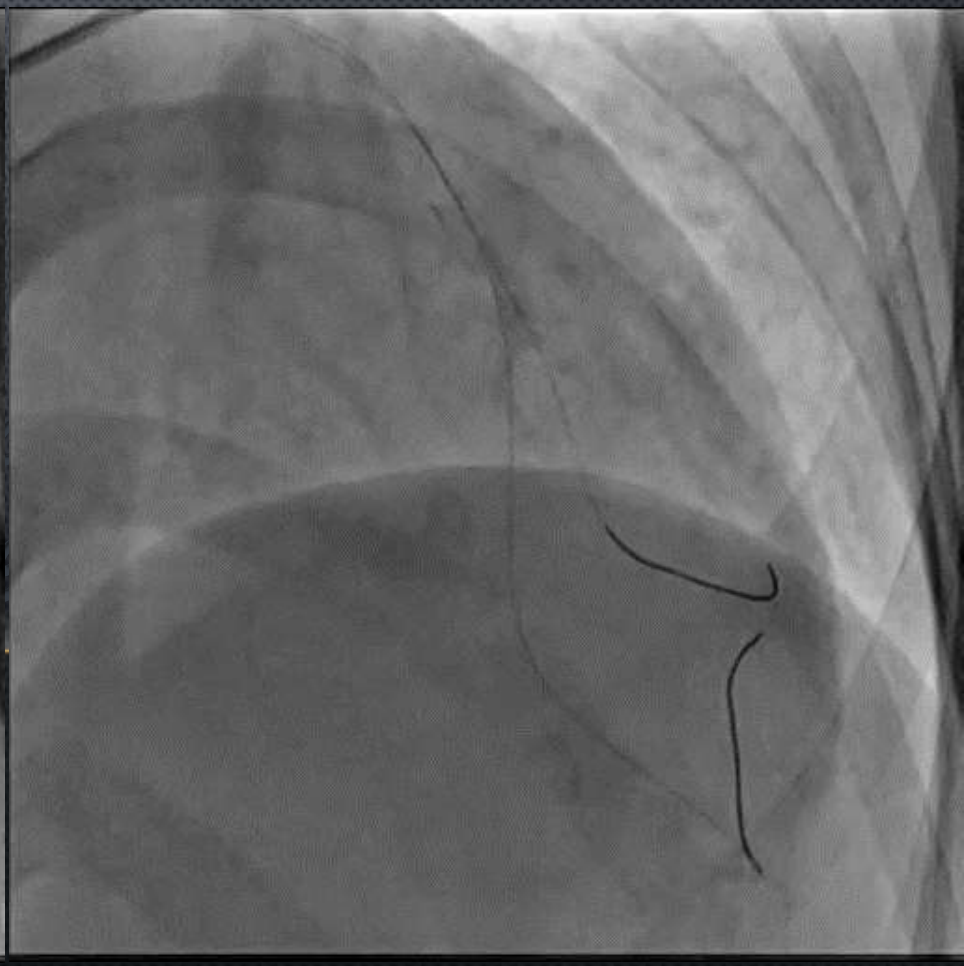

Department of Cardiology, Nozaki Tokushukai Hospital

Final CAG

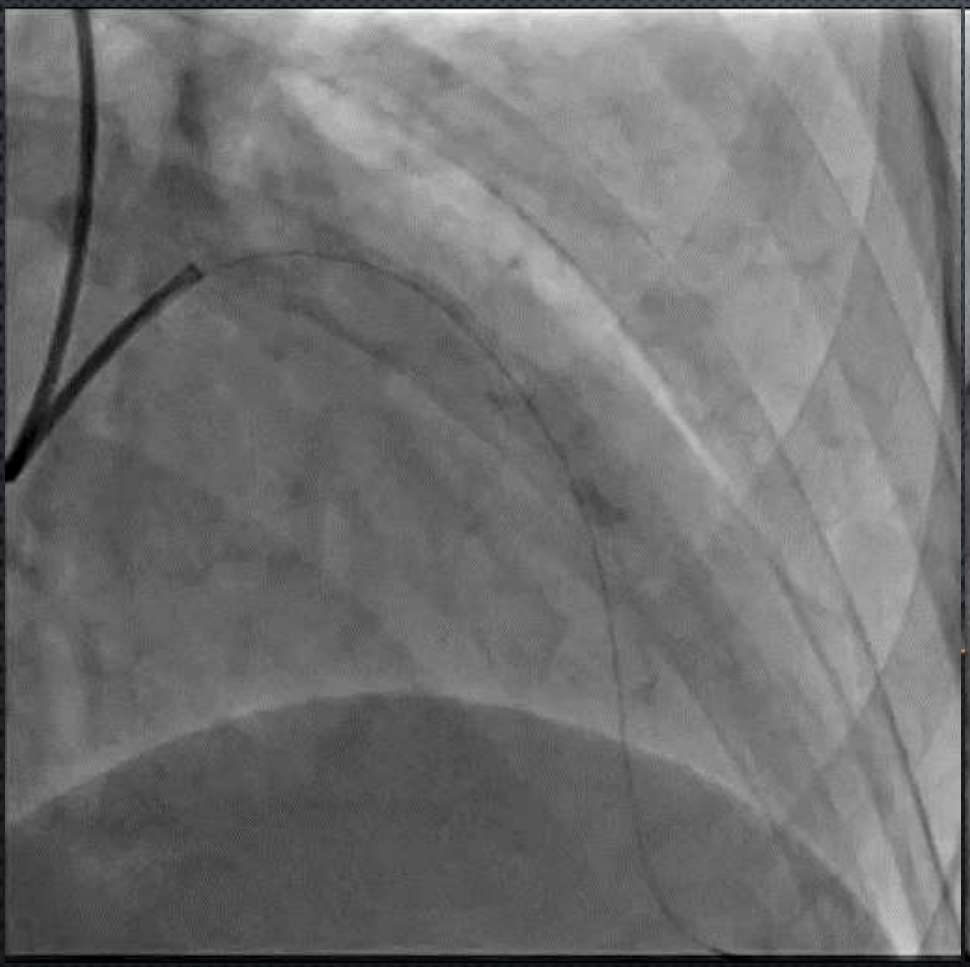

IVUS post

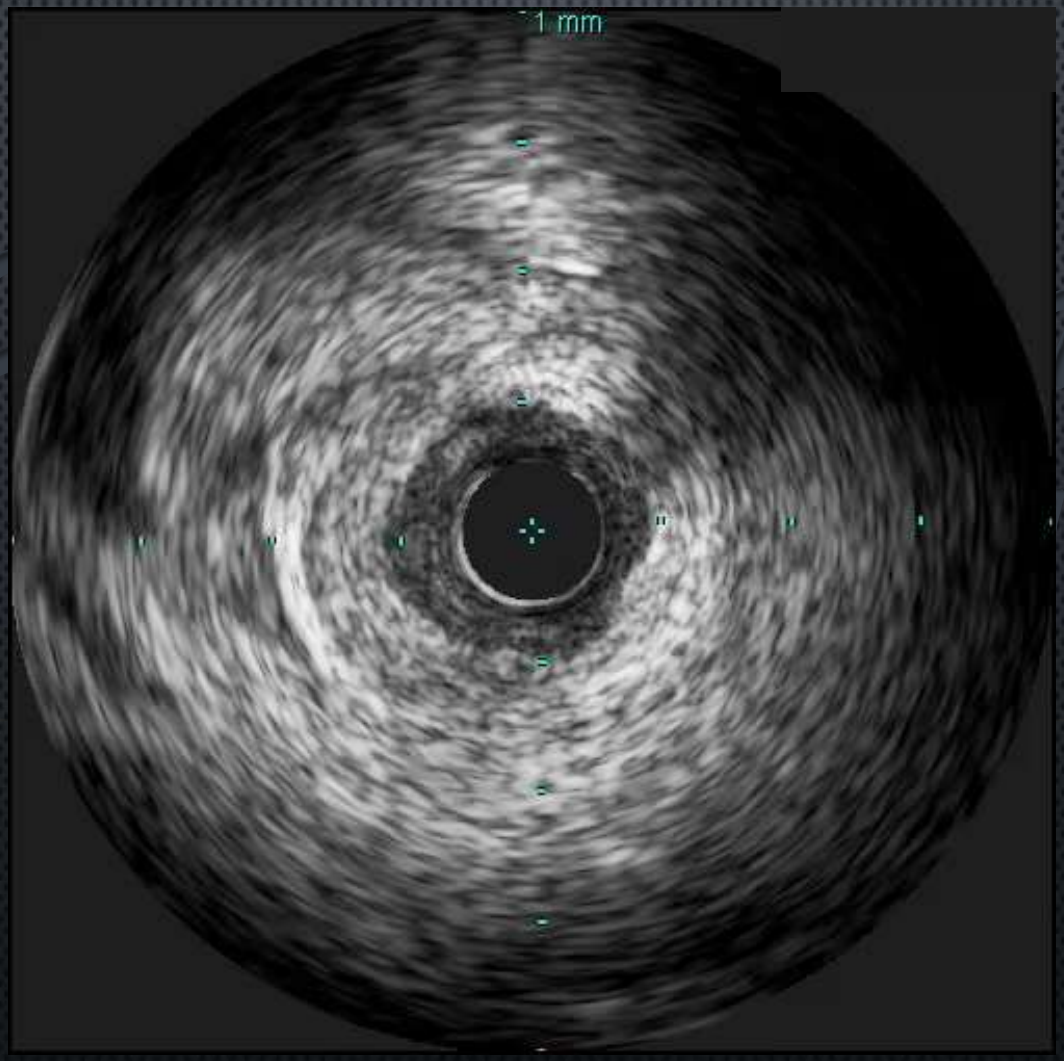

Clinical course after 1st PCI

- Peak CK/CK-MB : 1068/112 IU/L
- She had residual chest pain after discharge from hospital.
- CT examination underwent 1 month after discharge.

CT

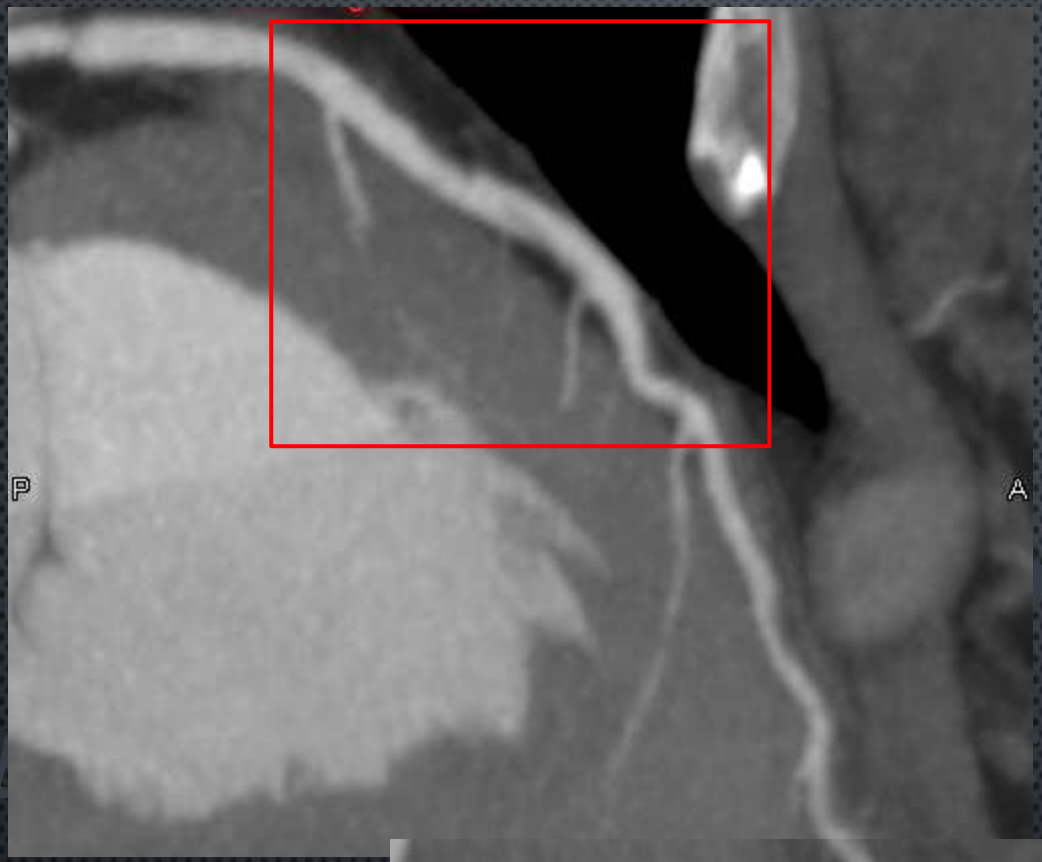

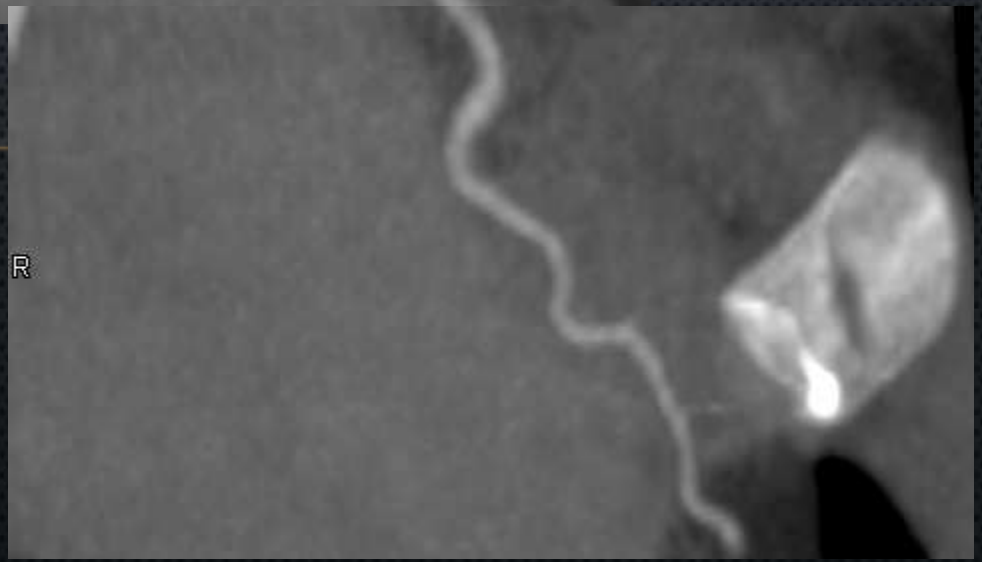

Department of Cardiology, Nozaki Tokushukai Hospital

CT

Department of Cardiology, Nozaki Tokushukai Hospital

CAG

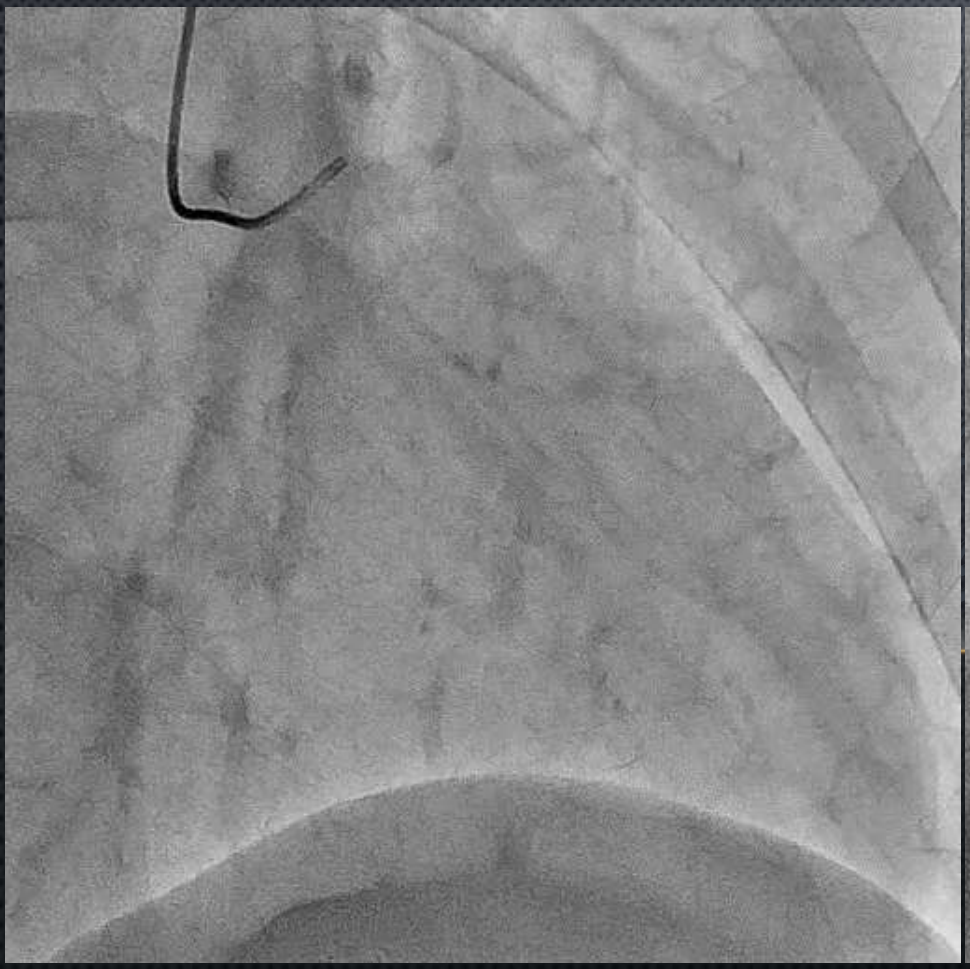

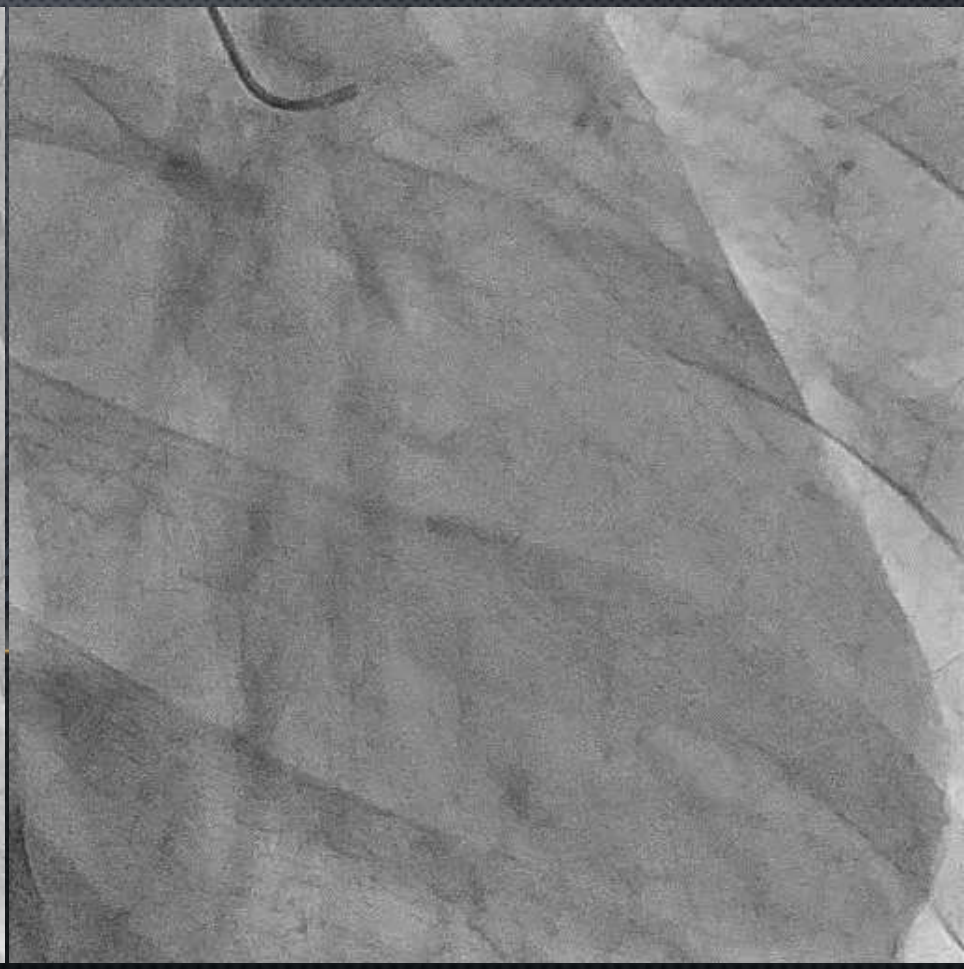

Department of Cardiology, Nozaki Tokushukai Hospital

IVUS pre-1

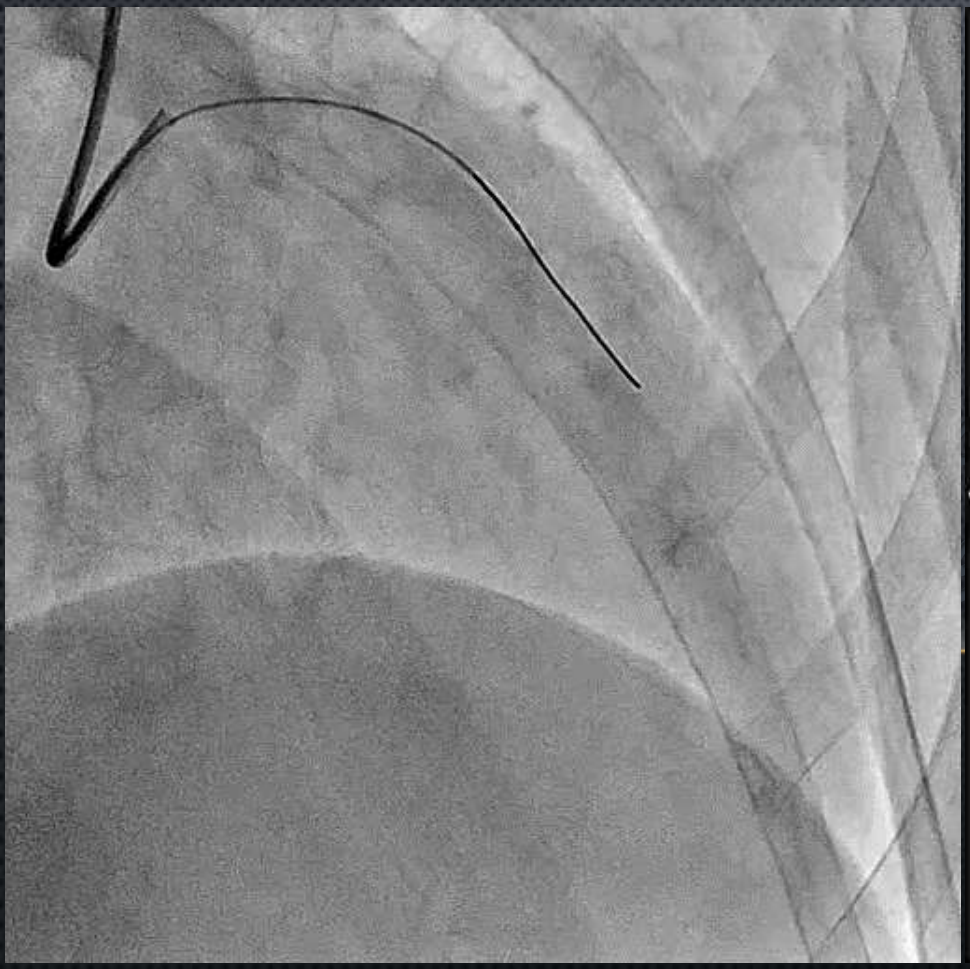

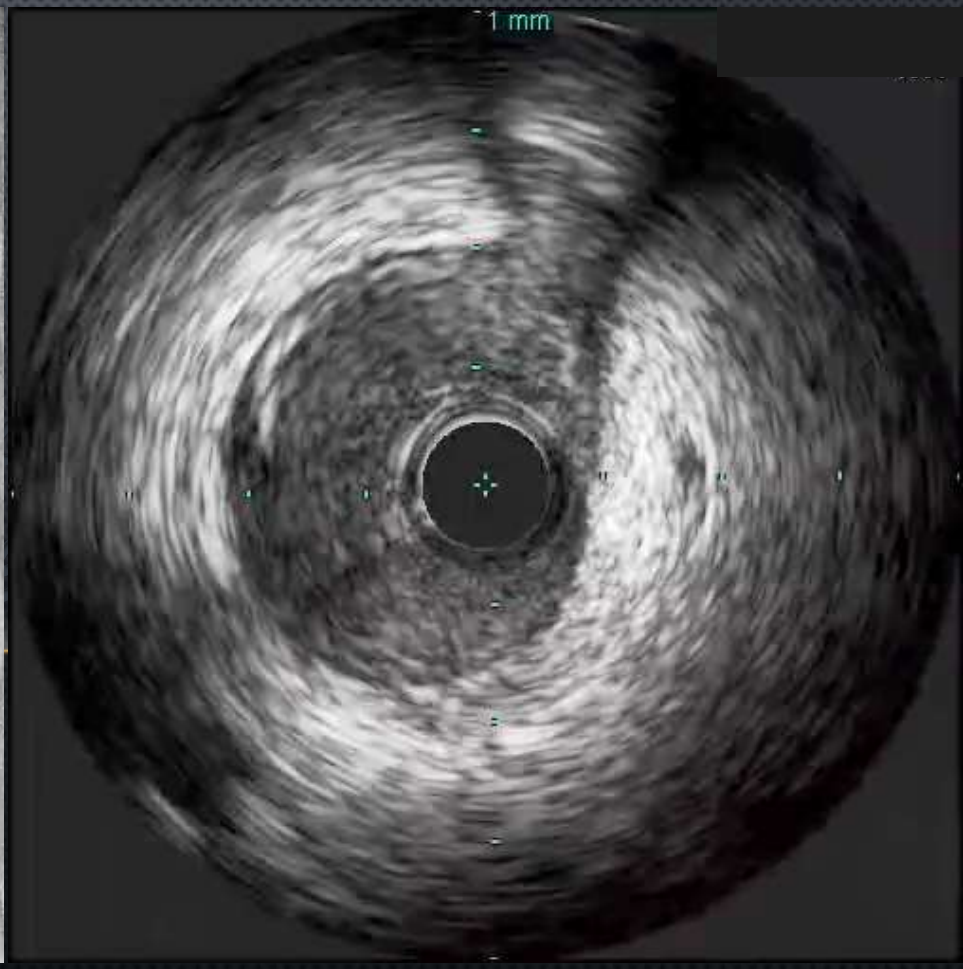

Department of Cardiology, Nozaki Tokushukai Hospital

IVUS pre-2

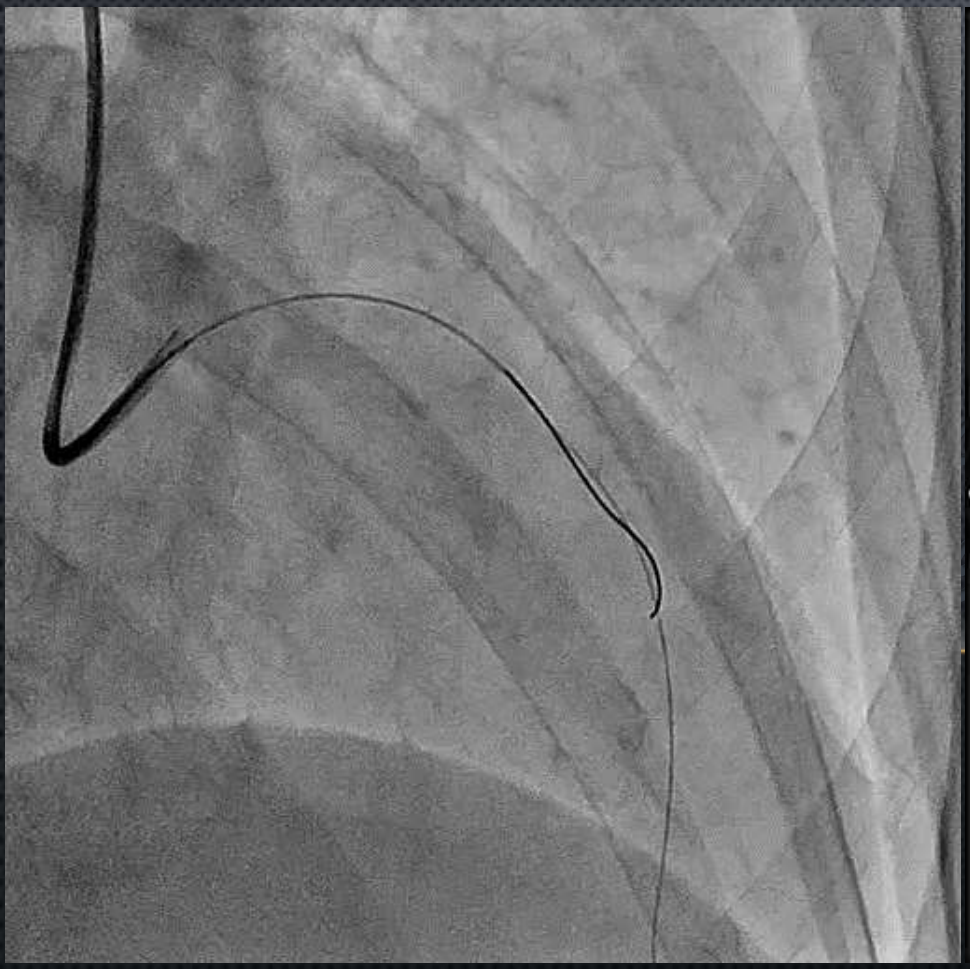

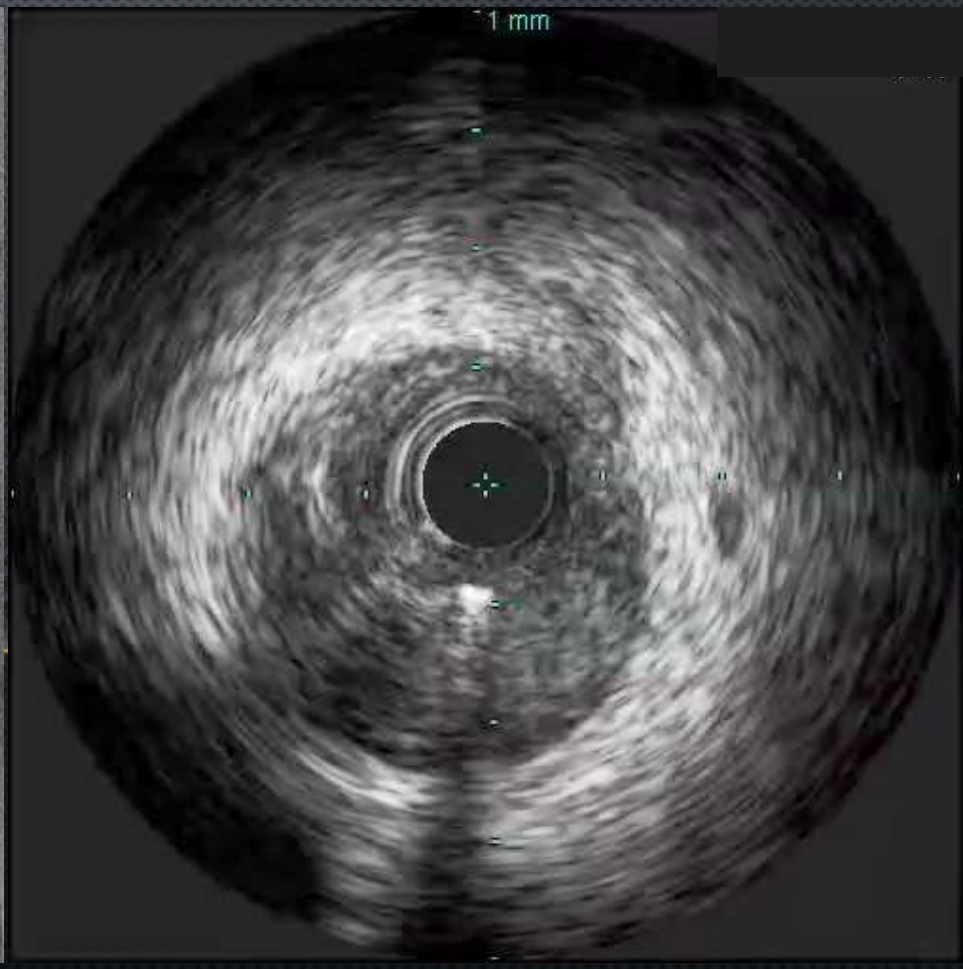

Cutting balloon 3.5mm

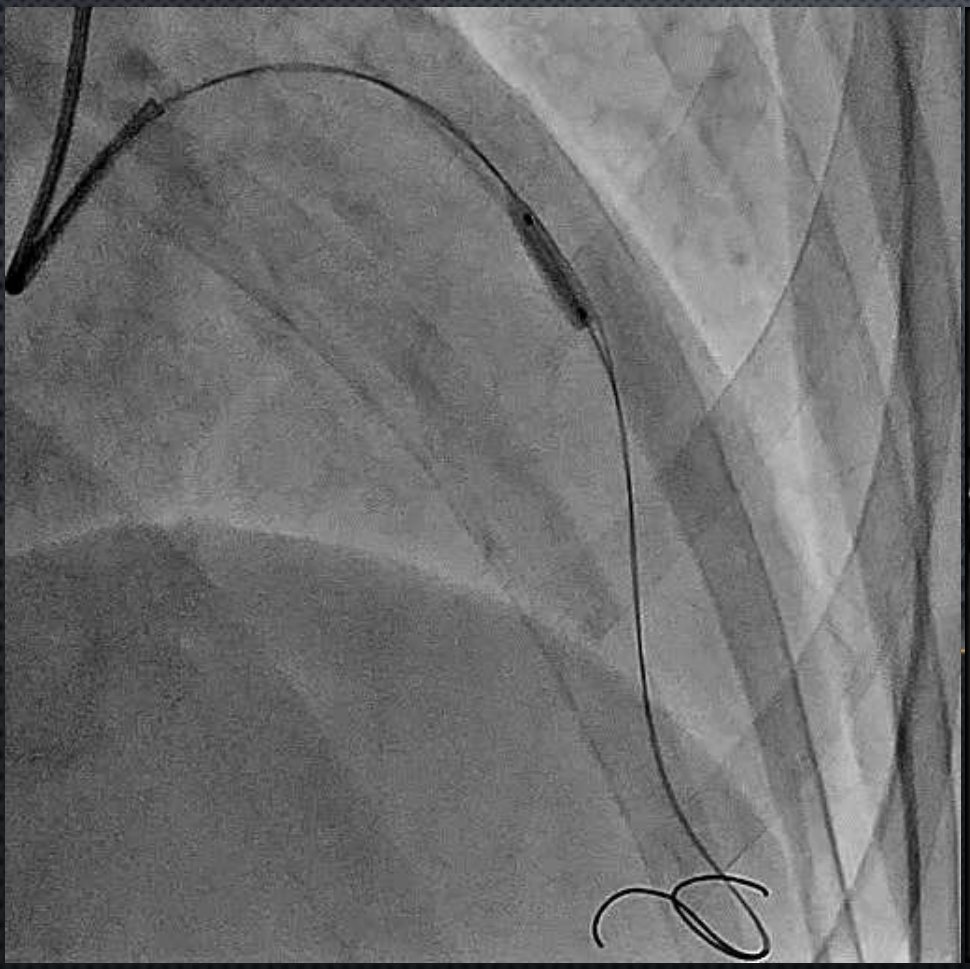

Department of Cardiology, Nozaki Tokushukai Hospital

CAG post Cutting balloon

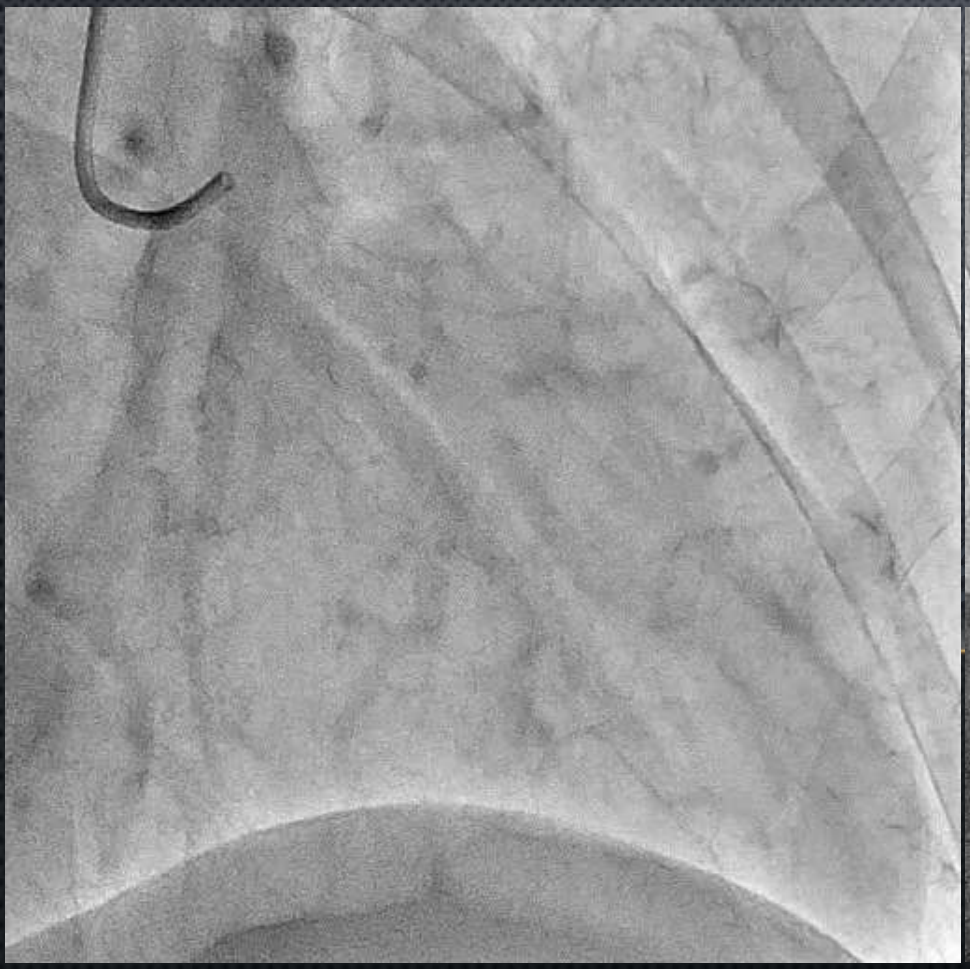

OFDI pre

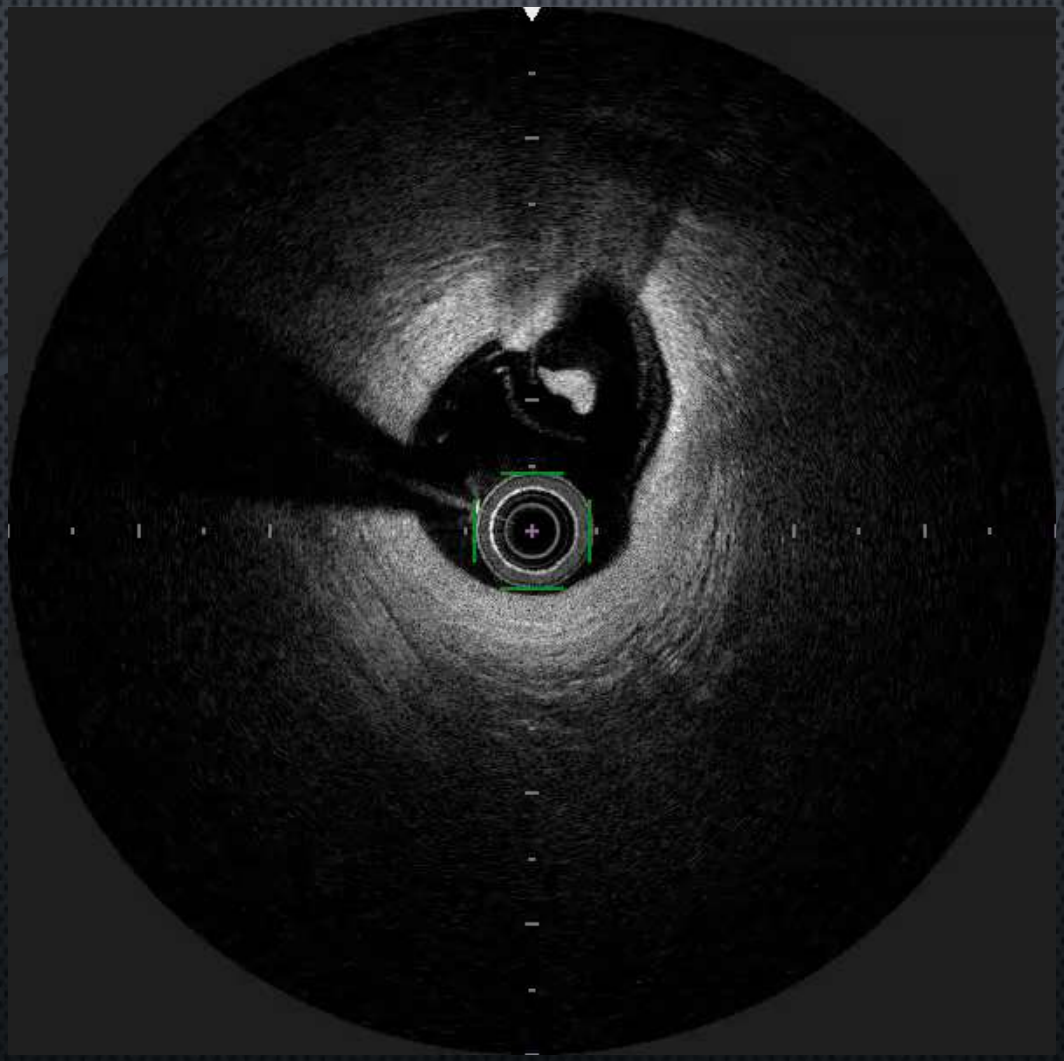

Department of Cardiology, Nozaki Tokushukai Hospital

OFDI second GW

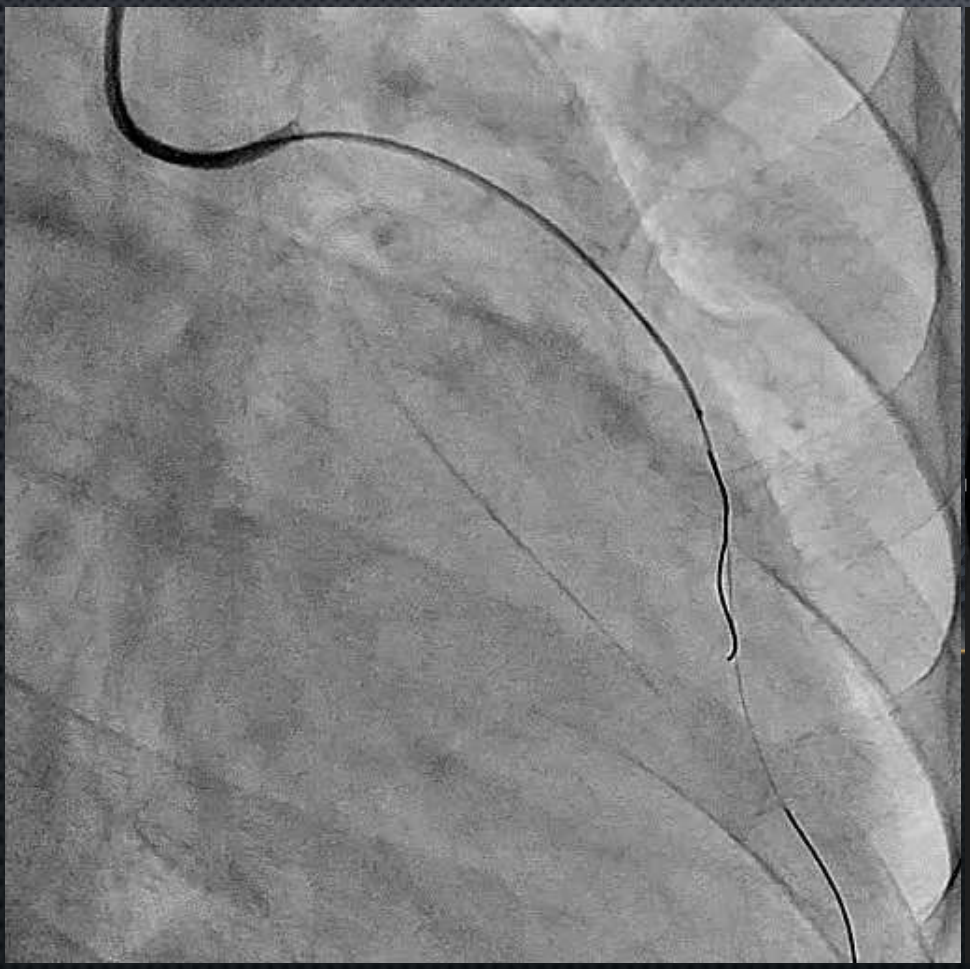

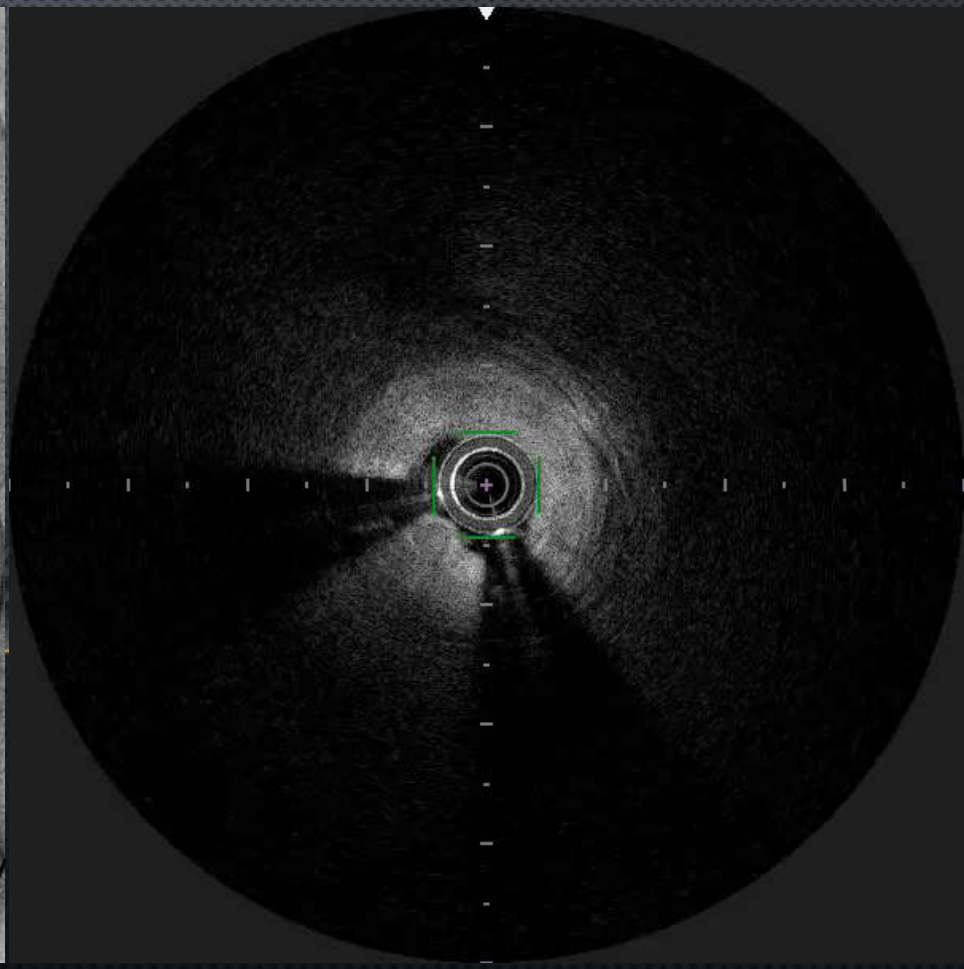

OFDI post POBA

1.75mm balloon

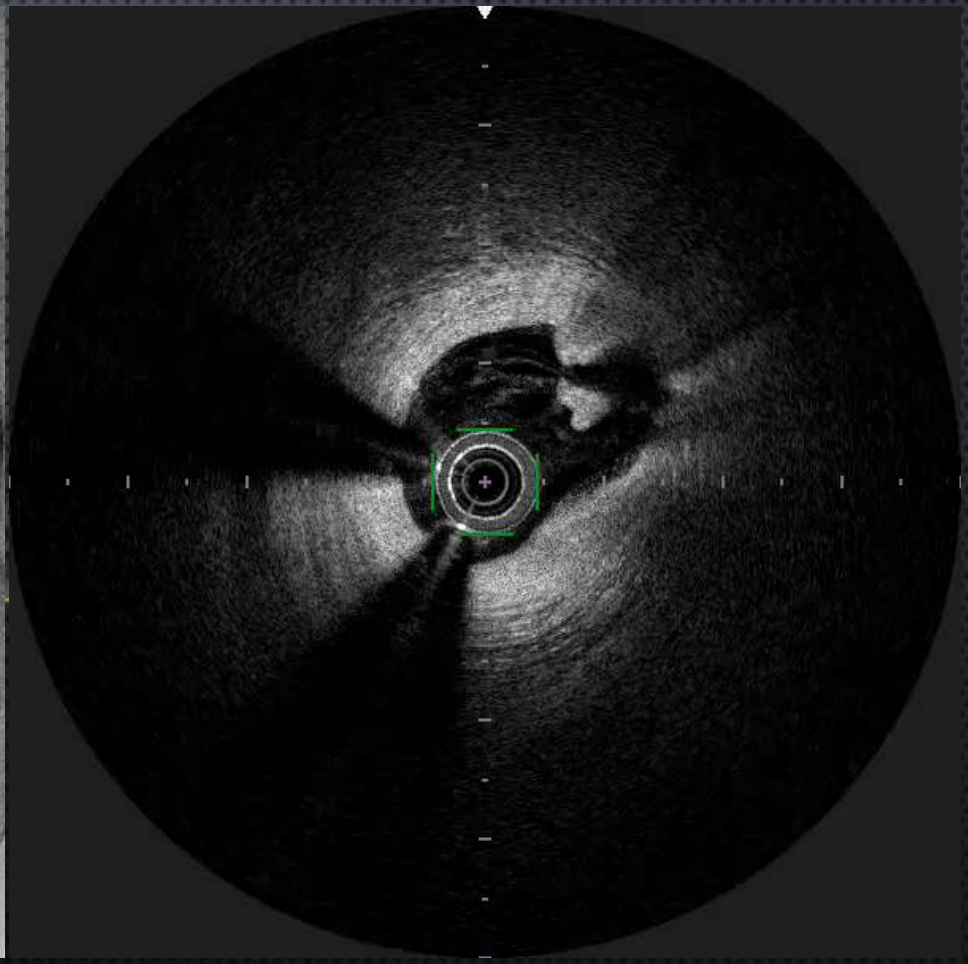

Final CAG

Spontaneous coronary artery dissection (SCAD)

- It has been reported to be an infrequent cause of acute coronary syndrome (0.1%–4%) and sudden cardiac death (0.4%).

- 1. Mortensen KH, et.al. Spontaneous coronary artery dissection: a Western Denmark Heart Registry study. Catheter Cardiovasc Interv. 2009;74:710–717.
- 2. Nishiguchi T, et.al. Prevalence of spontaneous coronary artery dissection in patients with acute coronary syndrome. Eur Heart J Acute Cardiovasc Care.

Spontaneous coronary artery dissection (SCAD)

- Females constituted 77% and all had undergone one or more pregnancies
  - Mortensen KH , et.al. Spontaneous coronary artery dissection: a Western Denmark Heart Registry study. Catheter Cardiovasc Interv. 2009;74:710–717.

Spontaneous coronary artery dissection (SCAD)

- Angopgraphic classification
  - Type 1 (evident arterial wall stain)
  - Type 2 (diffuse stenosis of varying severity)
  - Type 3 (mimic atherosclerosis)

- Saw J , et.al. Coronary angiogram classification of spontaneous coronary artery dissection. Catheter Cardiovasc Interv 2014;84:1115-22

Treatment; revascularization favor

- Early intervention with either CABG or PCI following the diagnosis of SCAD leads to a better outcome and less need for further intervention.
  - Shamloo BK, et.al. Spontaneous coronary artery dissection: aggressive vs. conservative therapy. *J Invasive Cardiol*. 2010.
- … patients undergoing revascularization had a higher risk profile than patients undergoing medical therapy. Despite this, the outcome was favorable and did not mainly differ between the two group.
  - Buja P,et.al. Management and outcome of spontaneous coronary artery dissection: conservative therapy versus revascularization. *Int J Cardiol*. 2013.

Treatment; conservative favor

- PCI for SCAD is associated with high rates of technical failure even in those presenting with preserved vessel flow and does not protect against TVR or recurrent SCAD. A strategy of conservative management with prolonged observation may be preferable.
  - Marysia S. Tweet, et.al. Spontaneous Coronary Artery Dissection Revascularization Versus Conservative Therapy. Circ Cardiovasc Interv. 2014

Summary

- We suspected SCAD by Cardiac CT and performed PCI in acute phase.
- IVUS detected coronary dissection and balloon angioplasty improve coronary flow but chest pain remained.
- Before 2nd PCI, CT detected true lumen stenosis of mid LAD. During PCI, IVUS and OFDI detected true and false lumen, and balloon angioplasty improved coronary flow of true lumen.

Conclusion

- The imaging was very helpful to make diagnosis and to decide PCI strategy for SCAD.
- PCI for SCAD is controversial but it may be indication for ACS and persisting sever myocardial ischemia case.

Department of Cardiology, Nozaki Tokushukai Hospital

CCTI Conference

Best Performance of Cardiac CT Working group