

Stent Dislodging in Left Main Case Studies

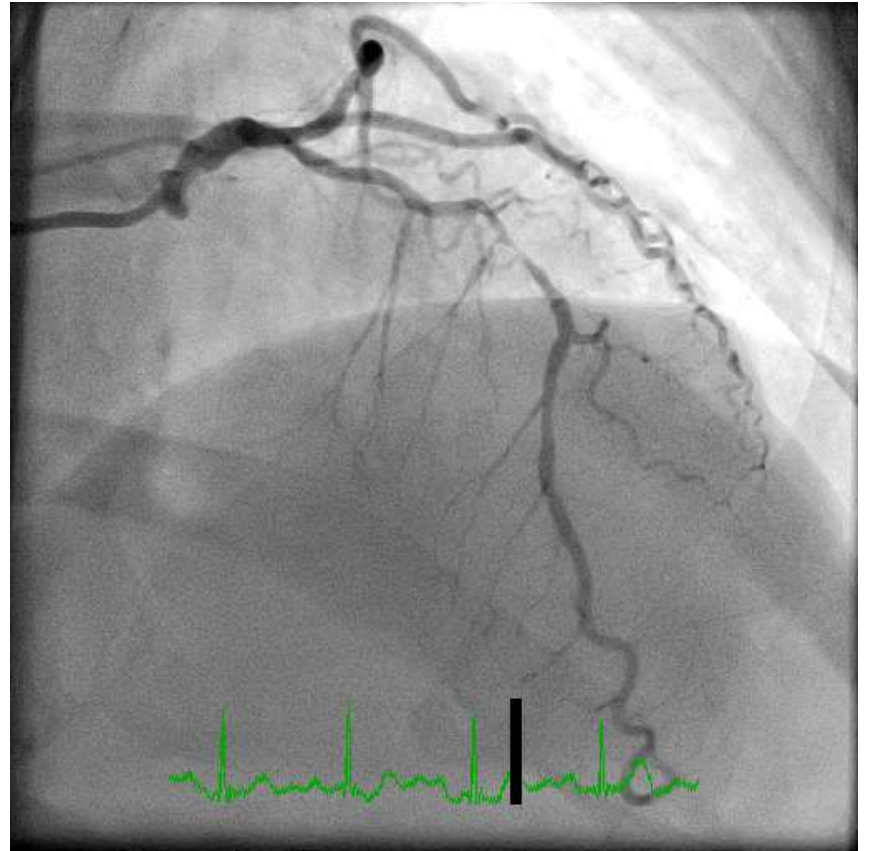
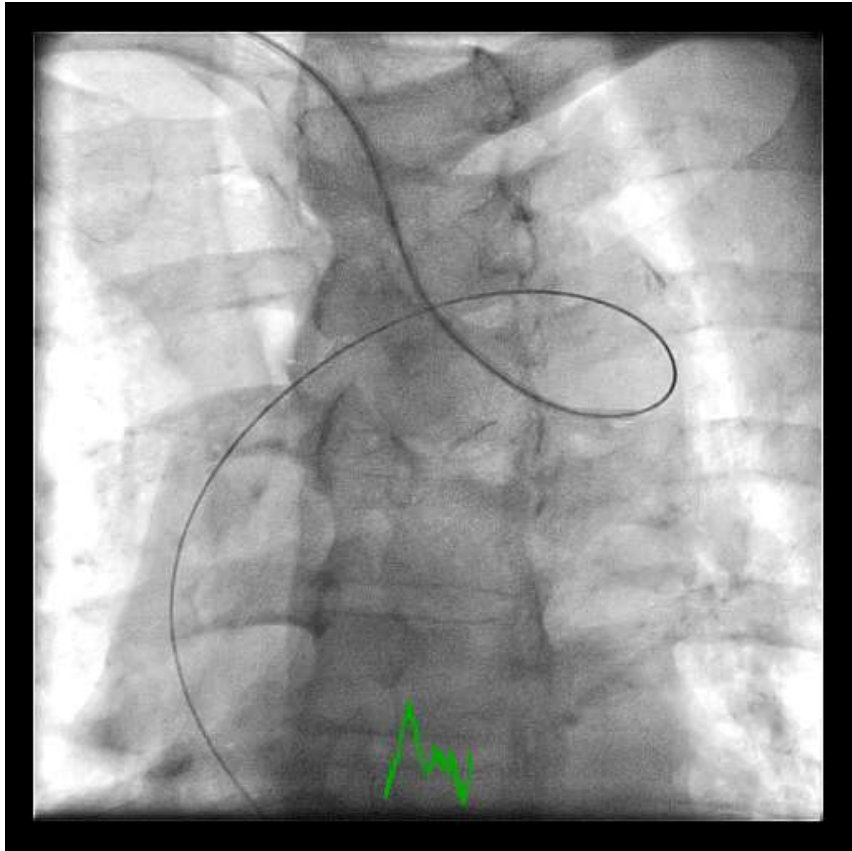
Dr Ping Tim Tsui

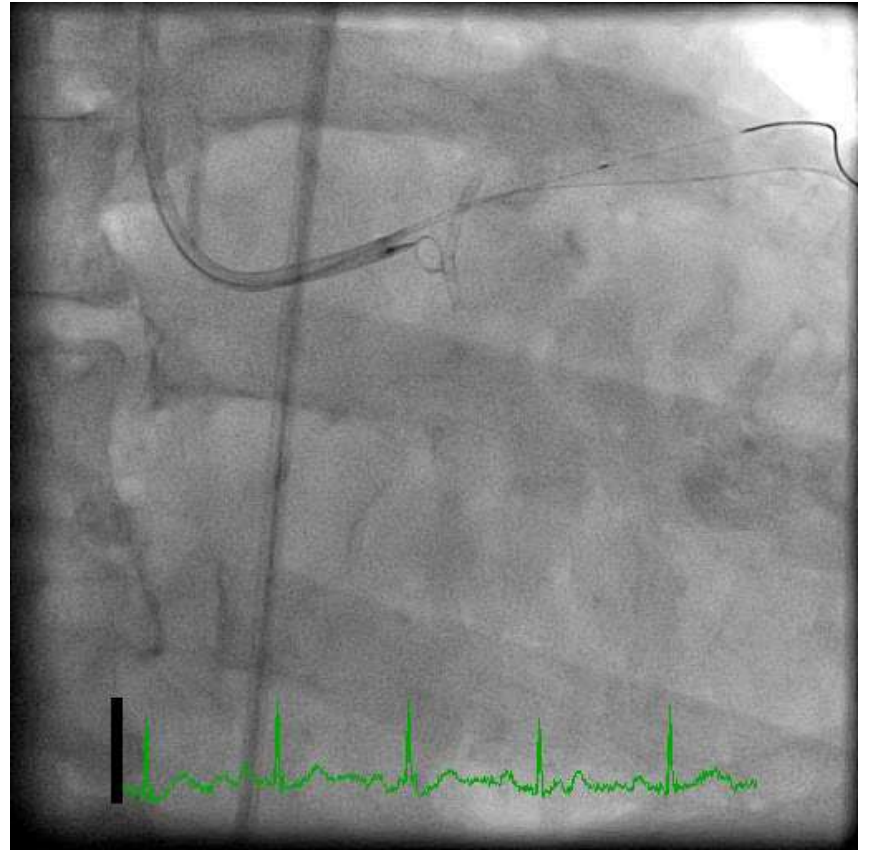
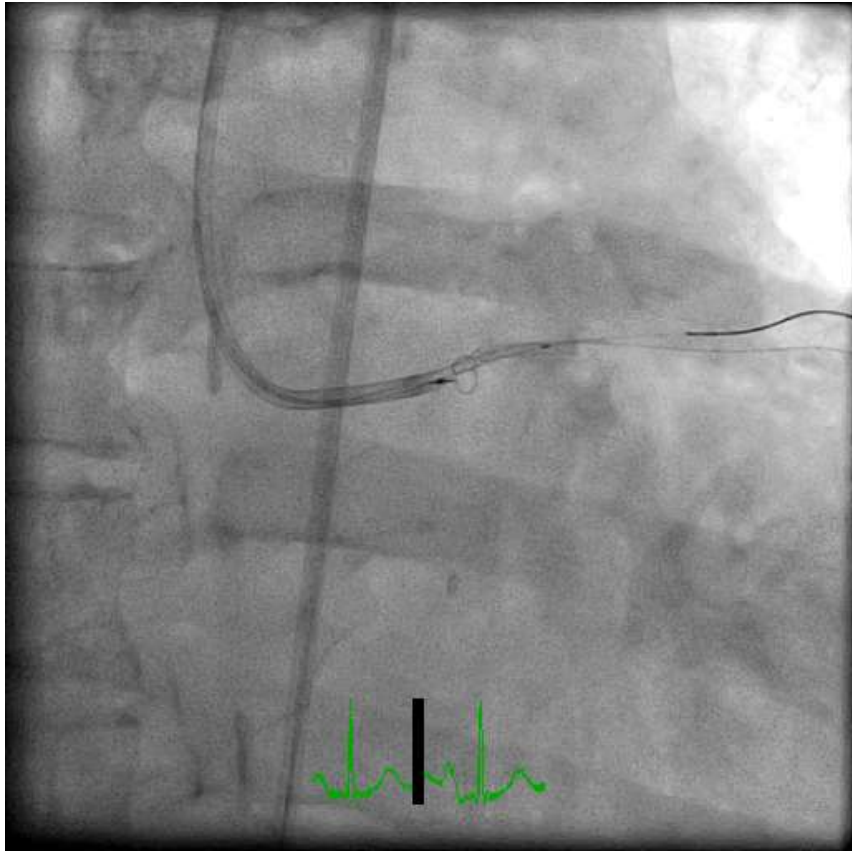
Princess Margaret Hospital

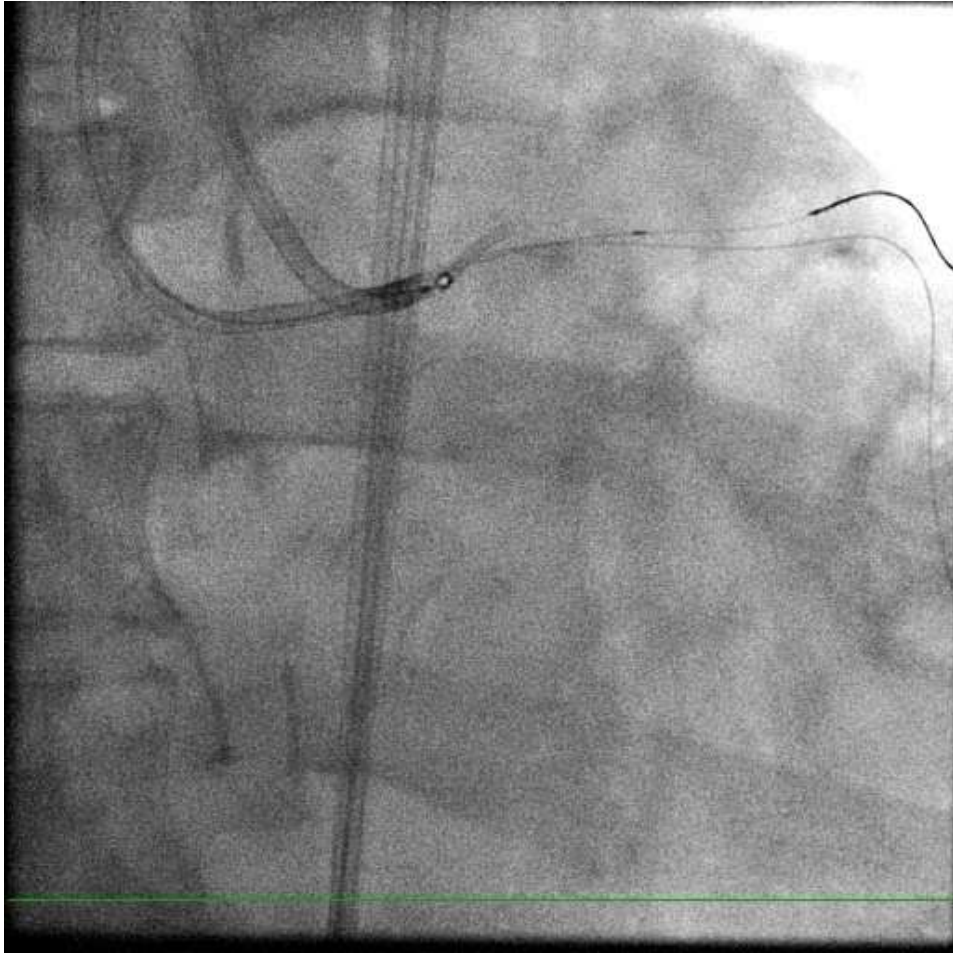
Hong Kong



Case 1

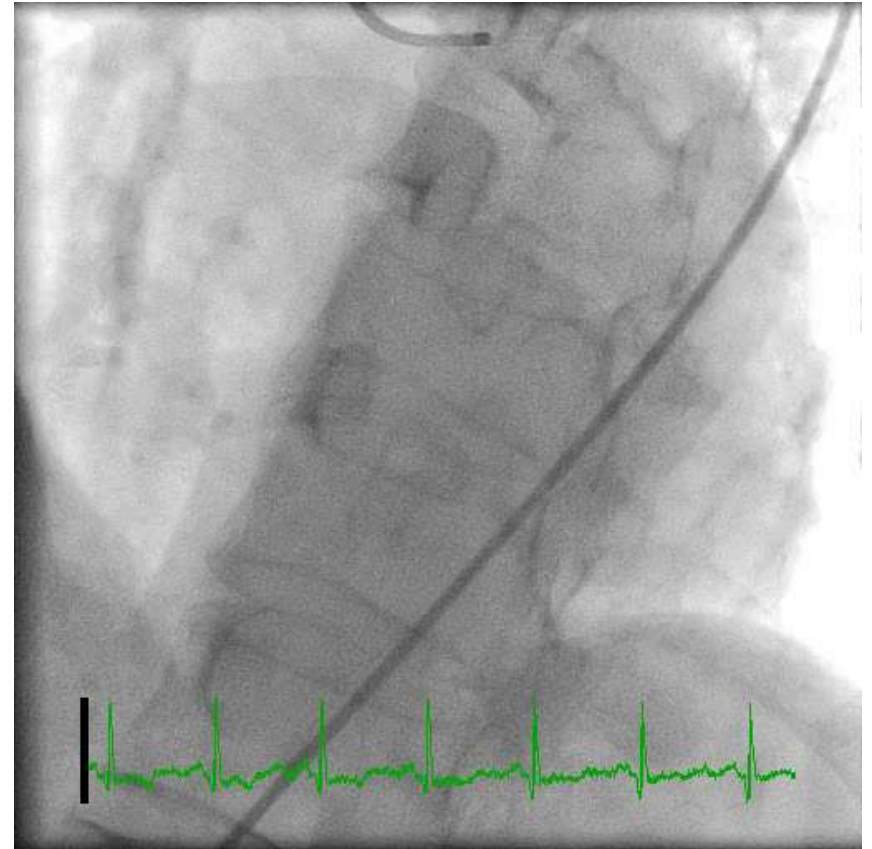
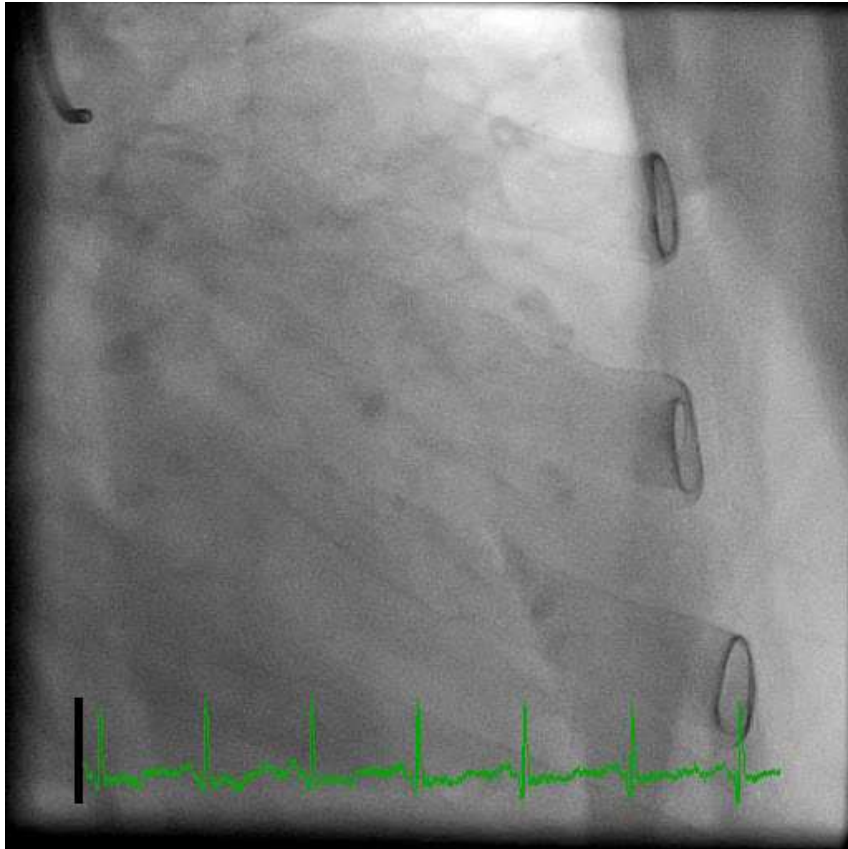




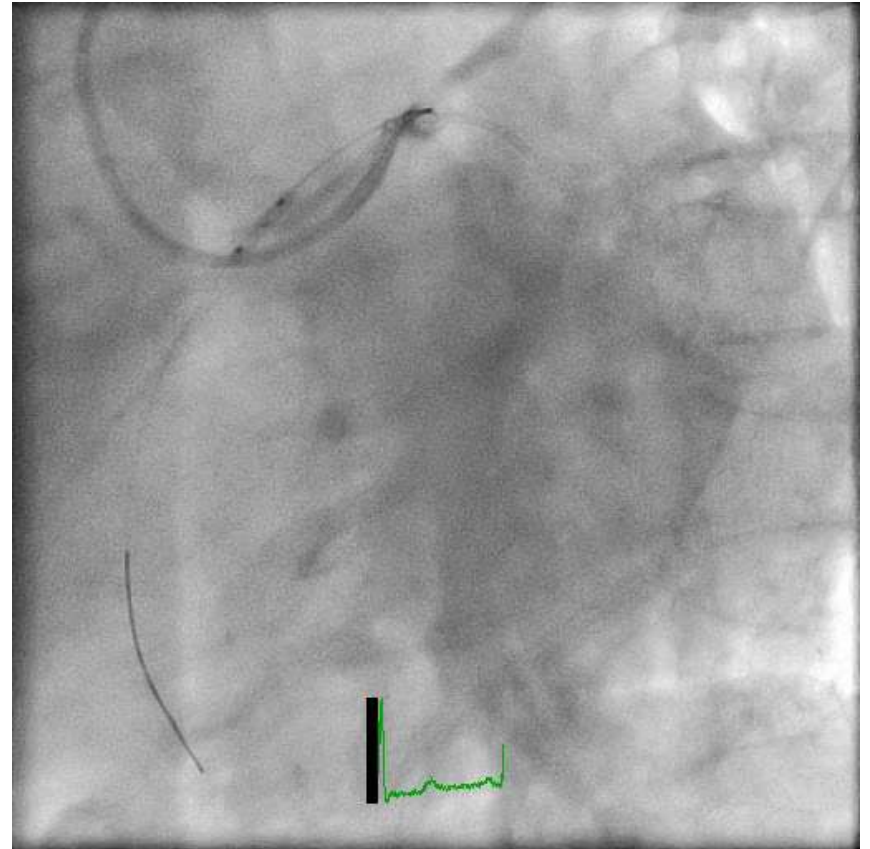
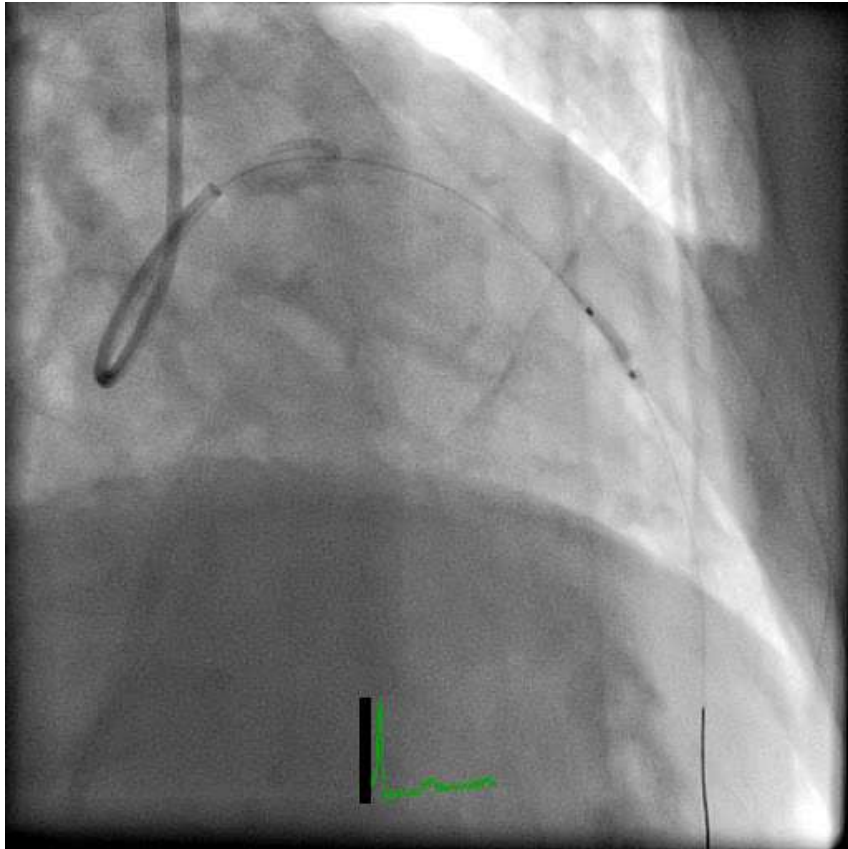


Case 2

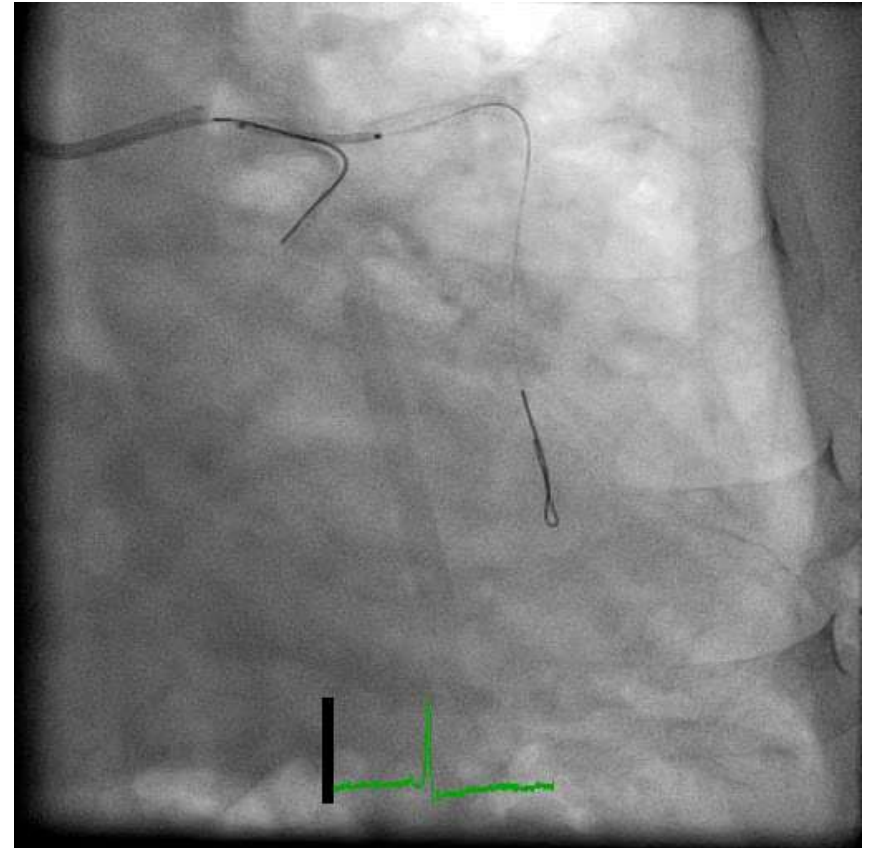
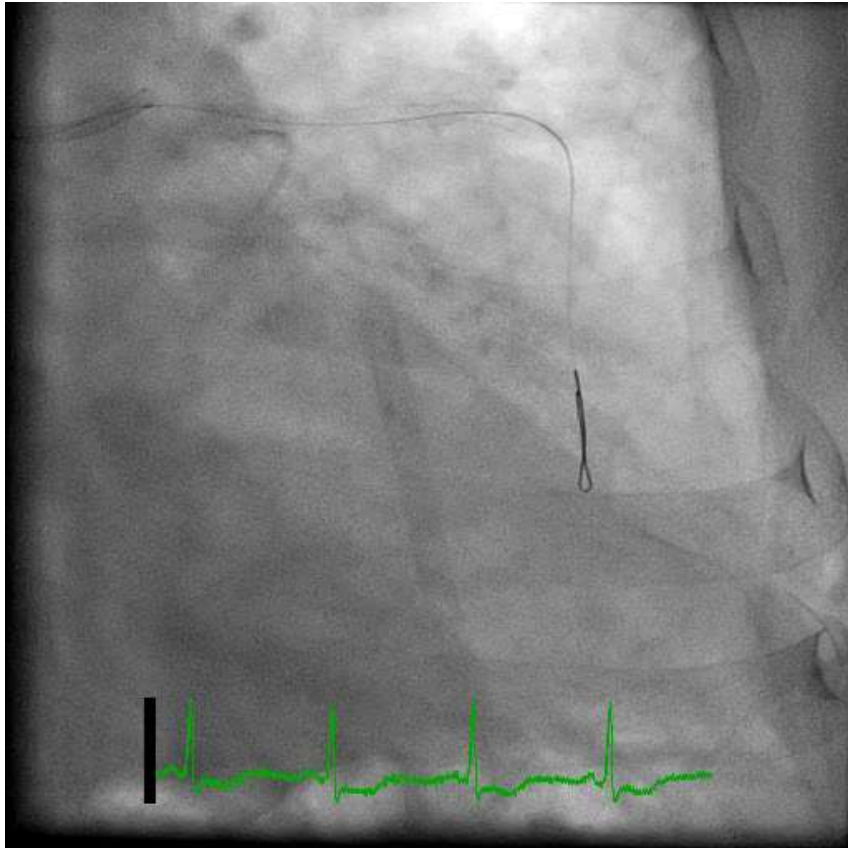
Diffuse LCA disease



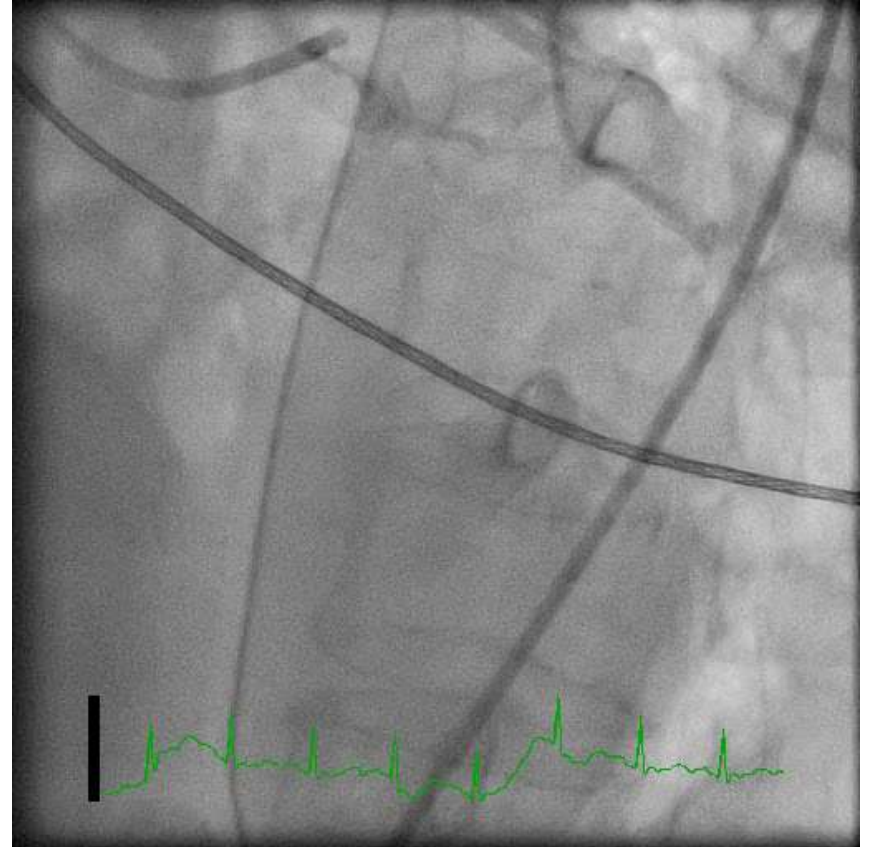
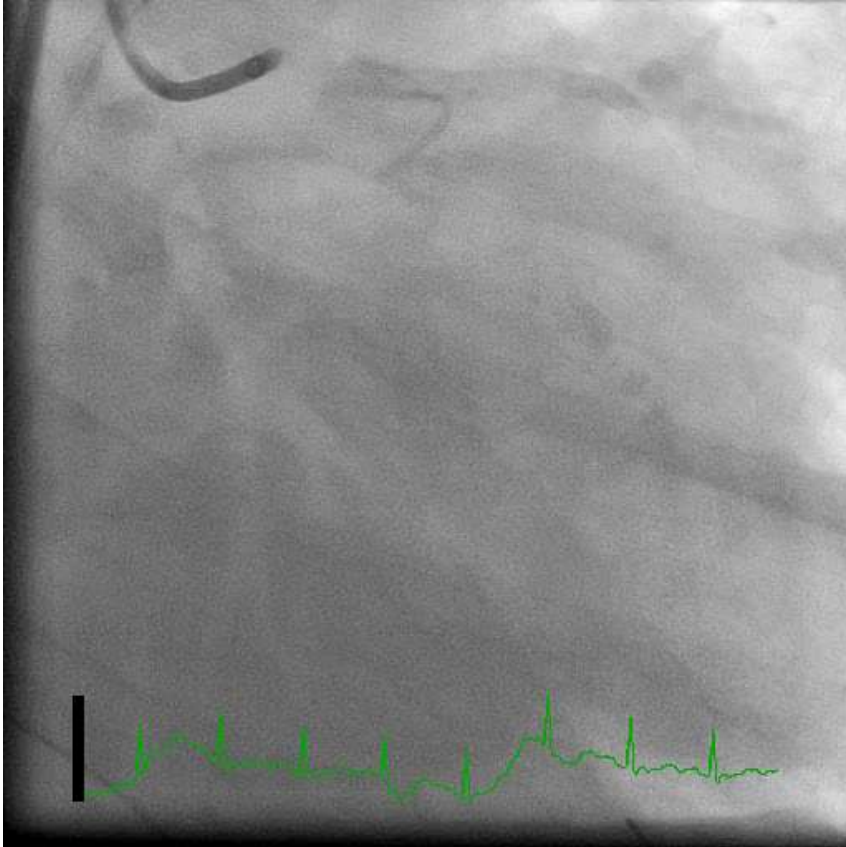
Failed to deliver LCX DES, POBA LAD



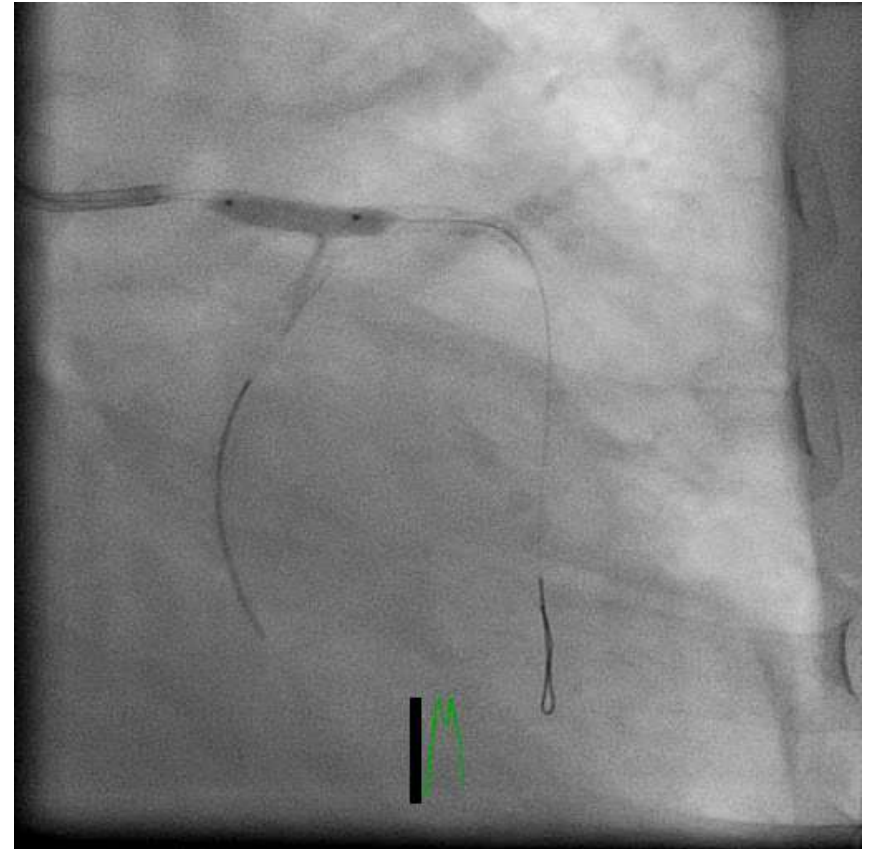
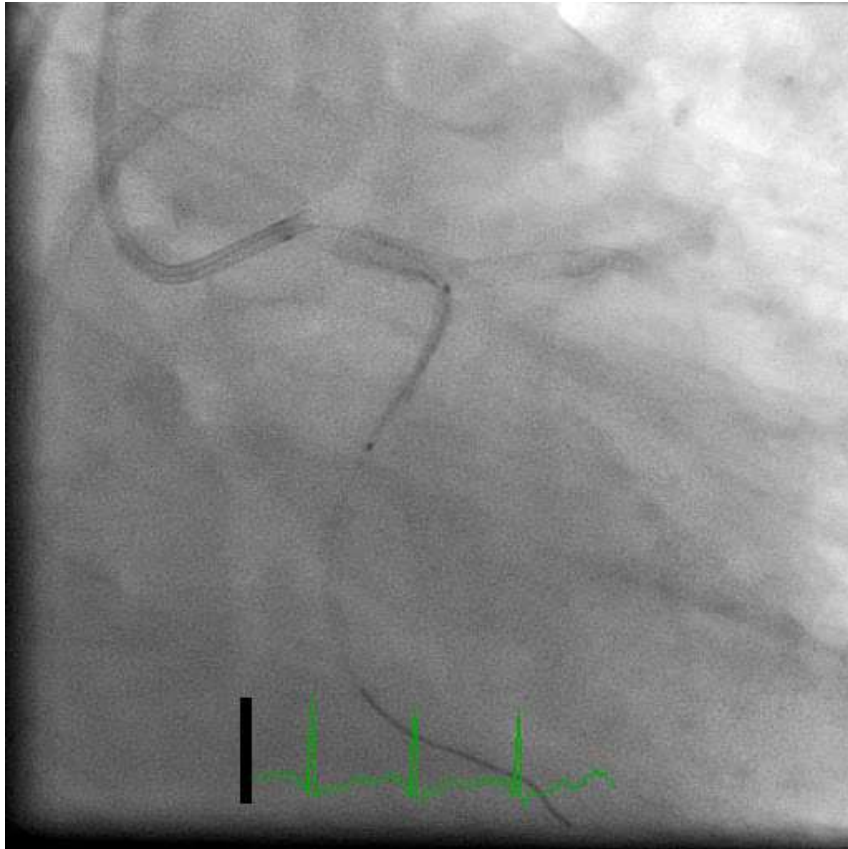
“Two” DES in LAD; One DES in LM



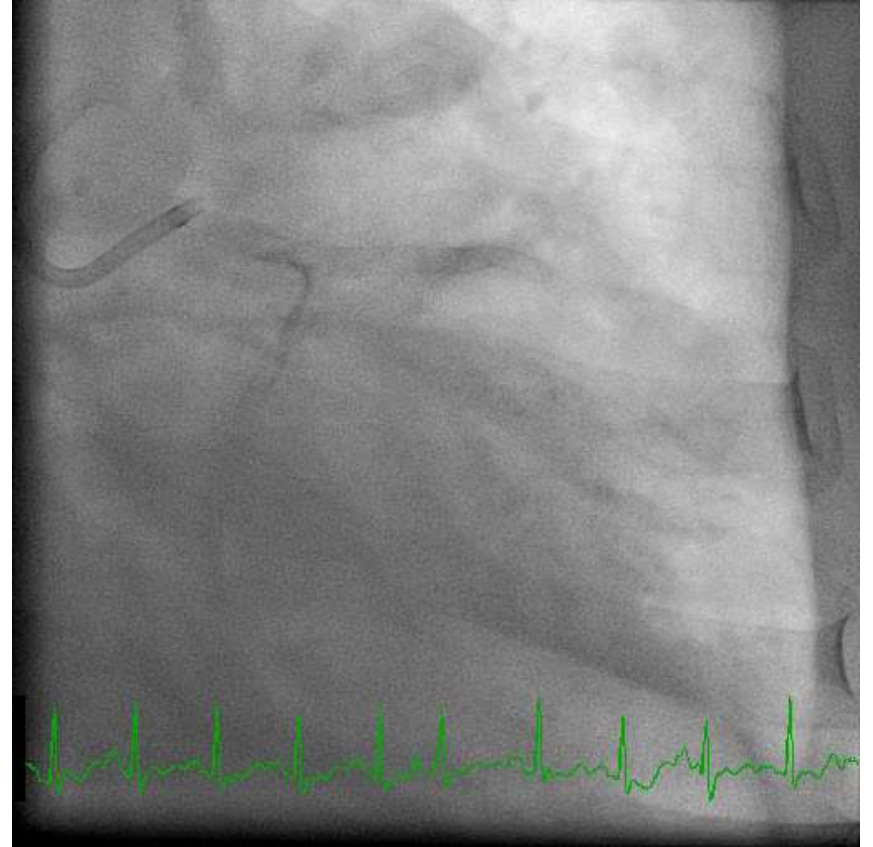
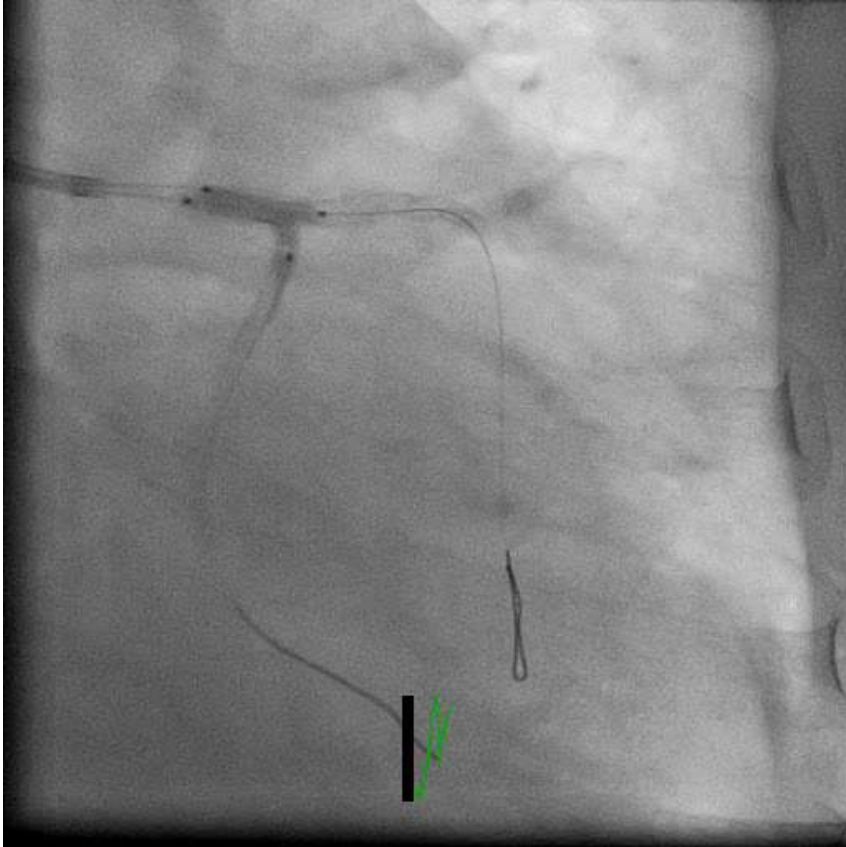
“Final”




Second DES in LCX



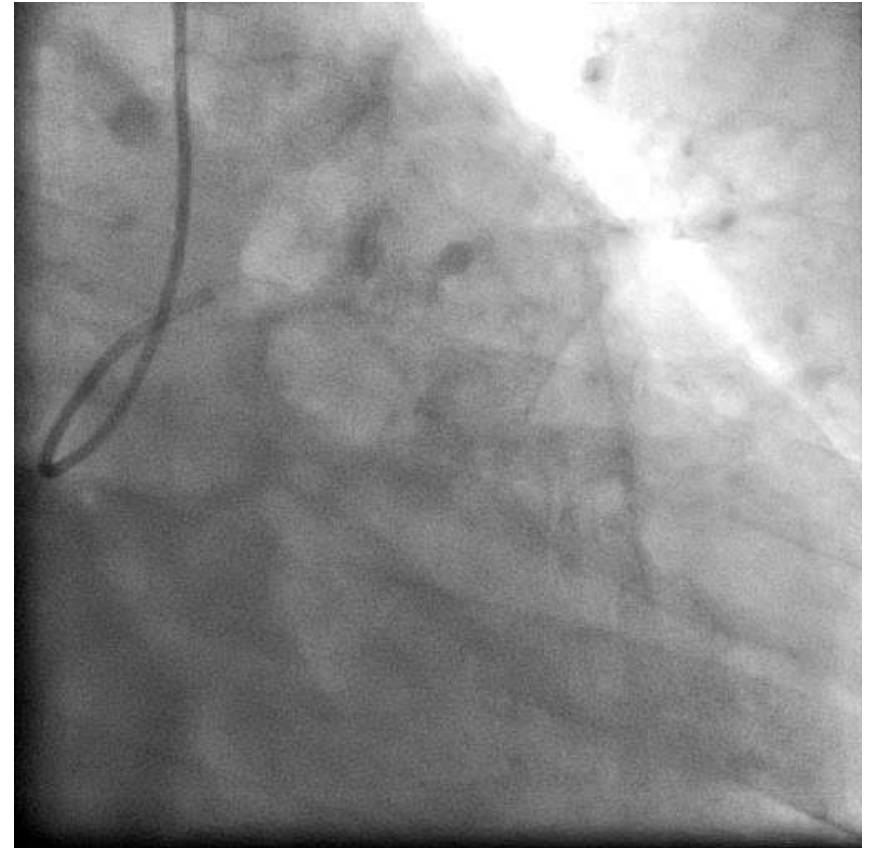
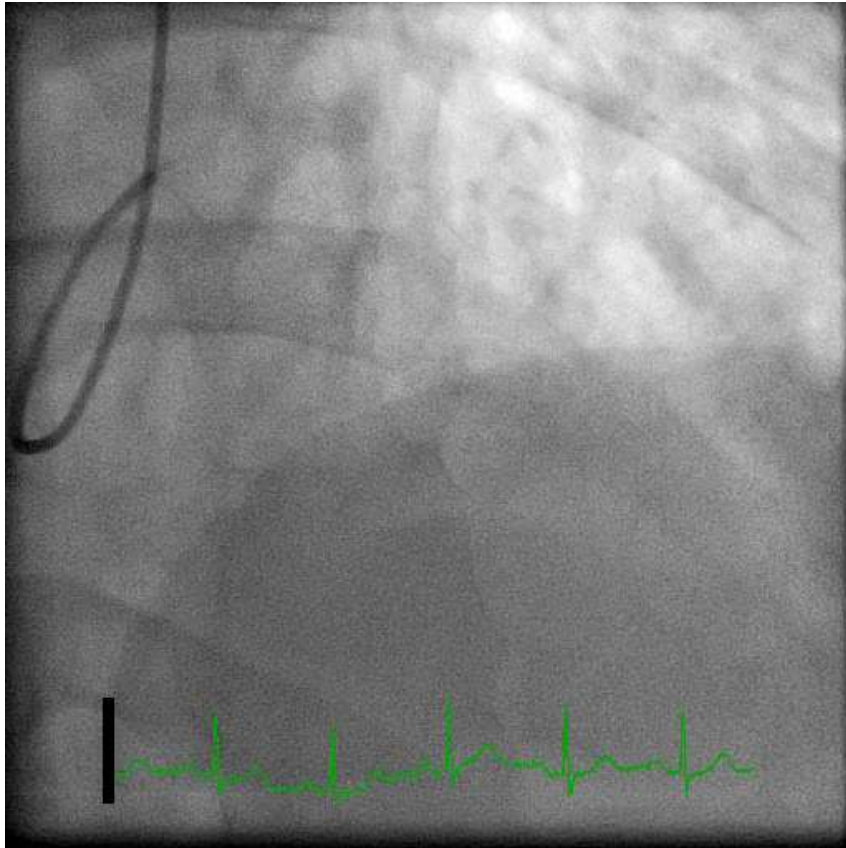
Final



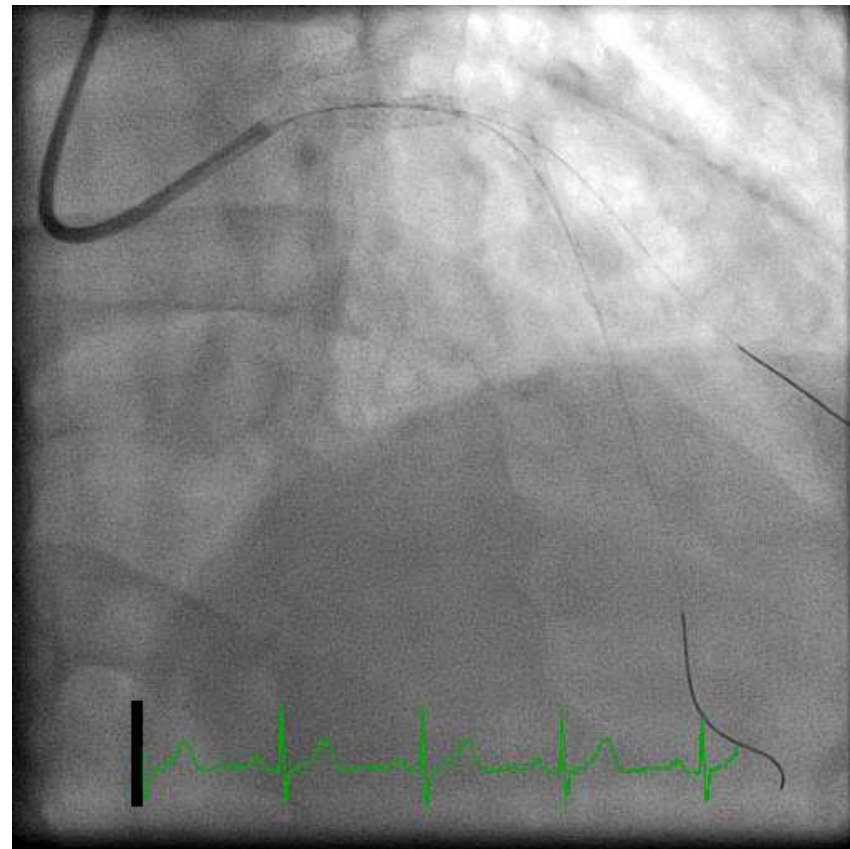
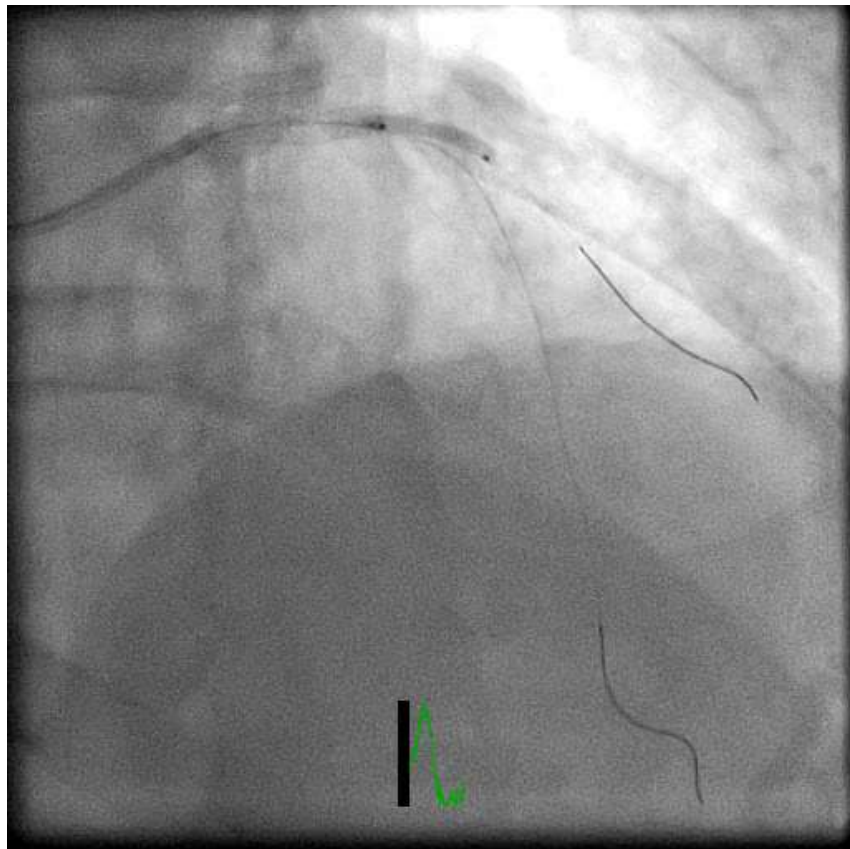


Case 3

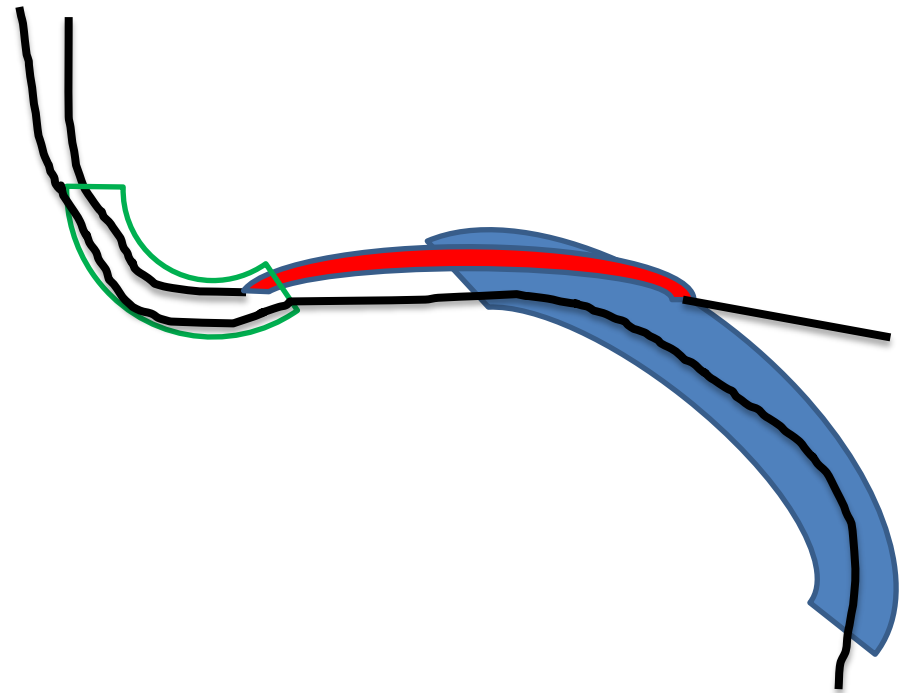
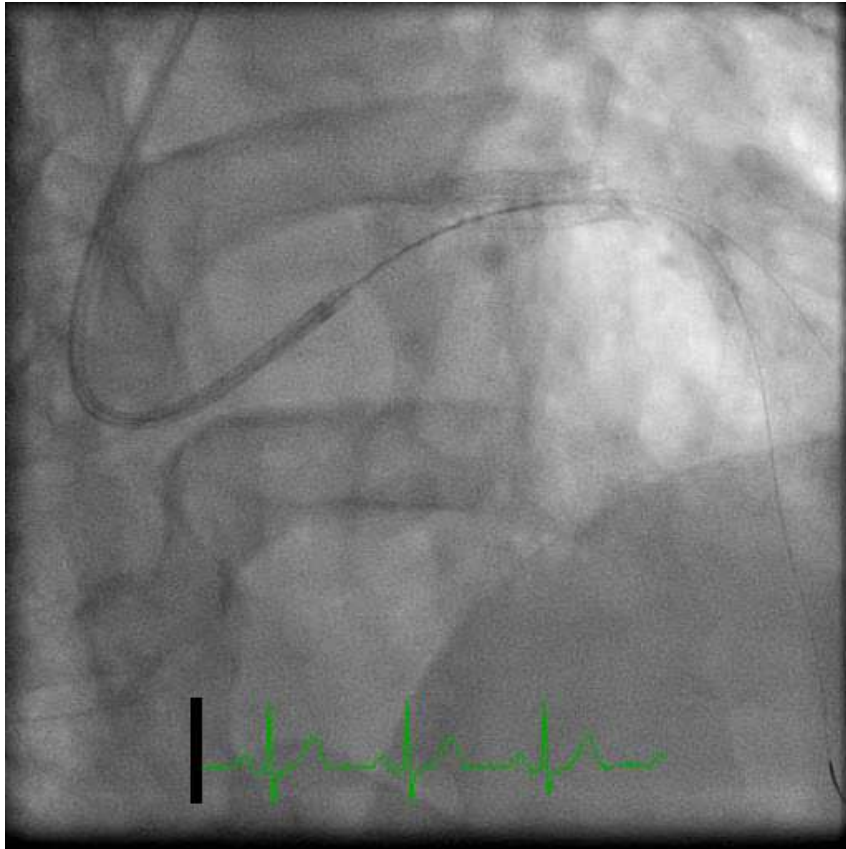
LAD+LCX Disease



Diagonal Dissection after POBA

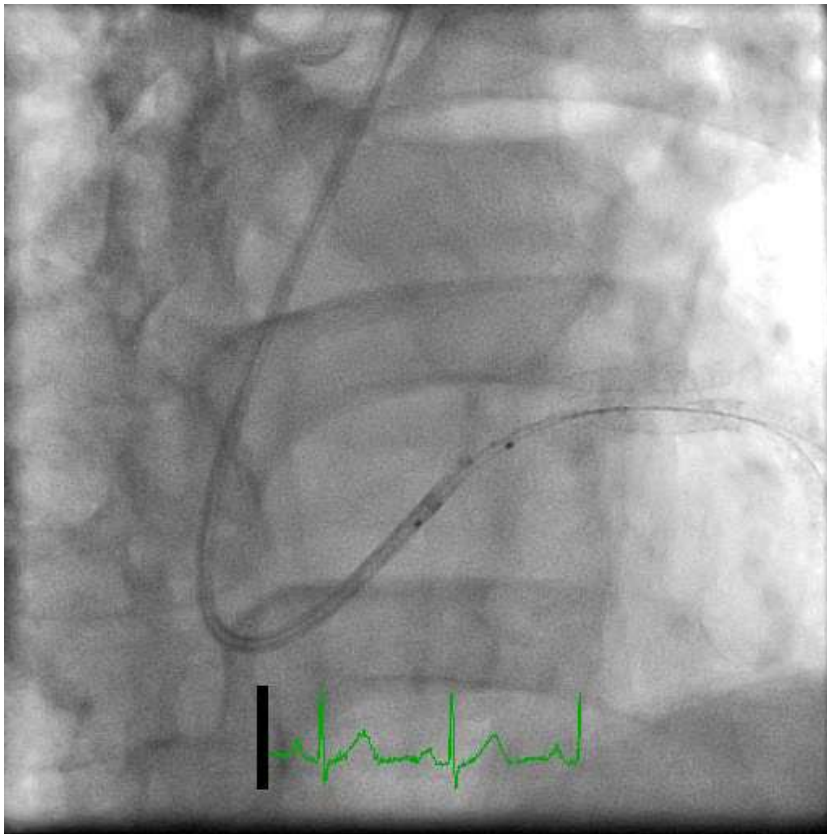


Difficulty in retrieving diagonal DES

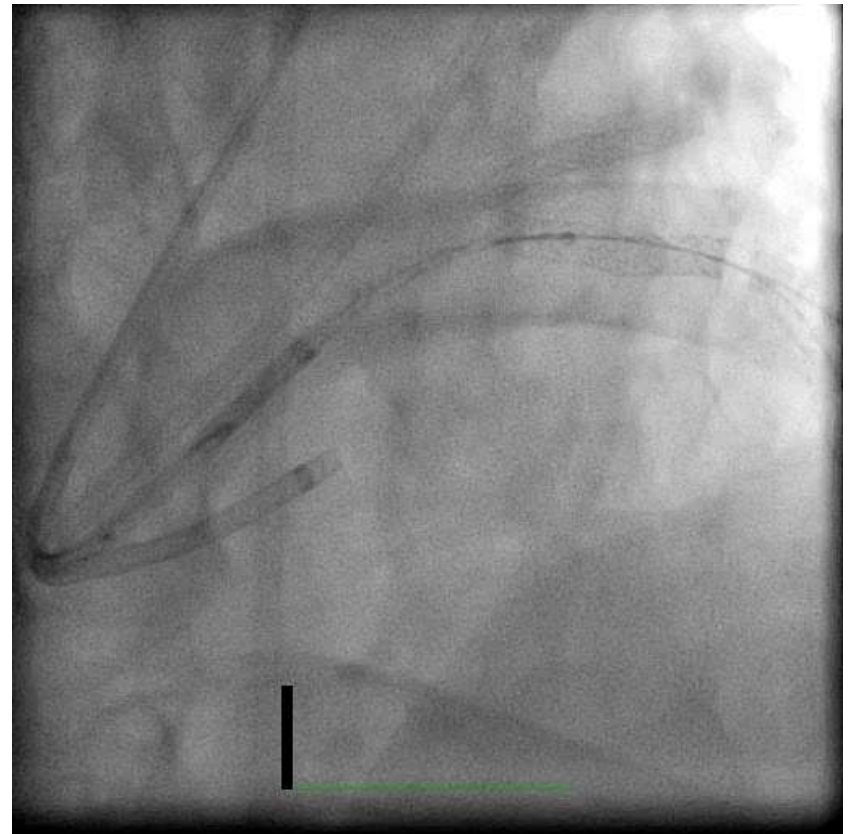


Stent Trapped during Retrieval

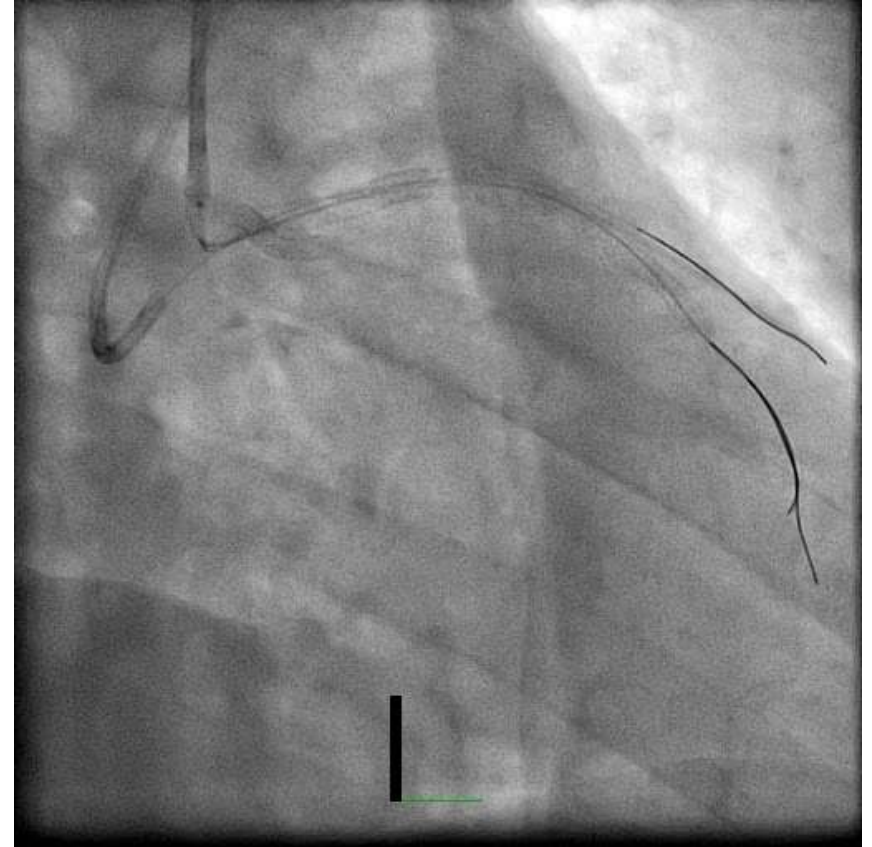
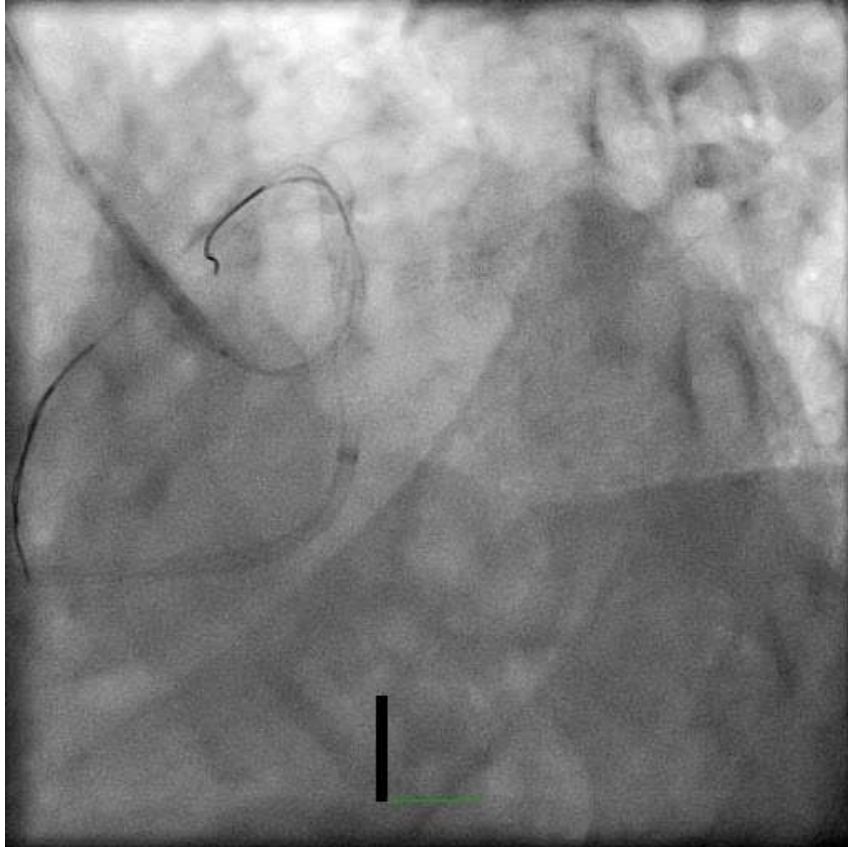
Failed to pass a balloon over LAD wire



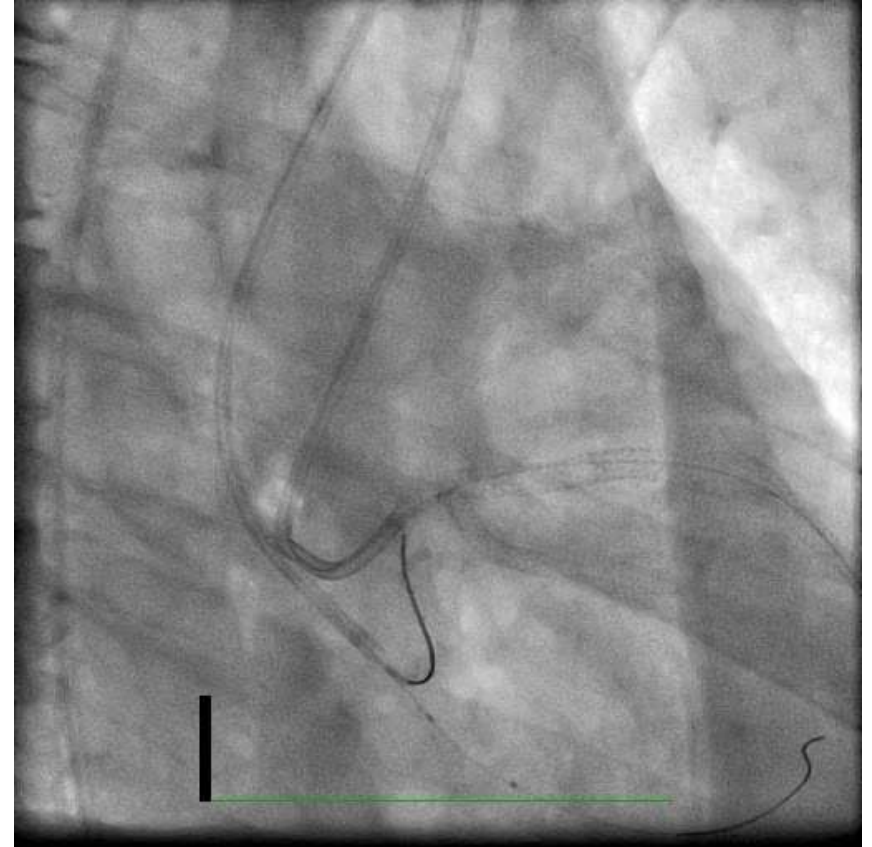
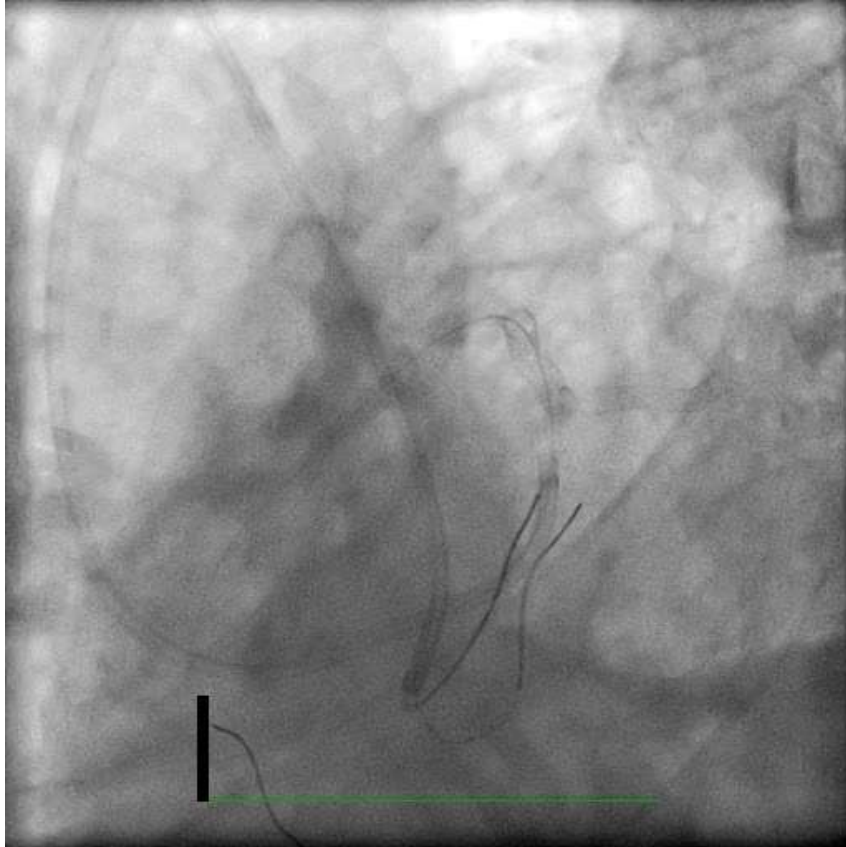
Failed Micro-snare Technique



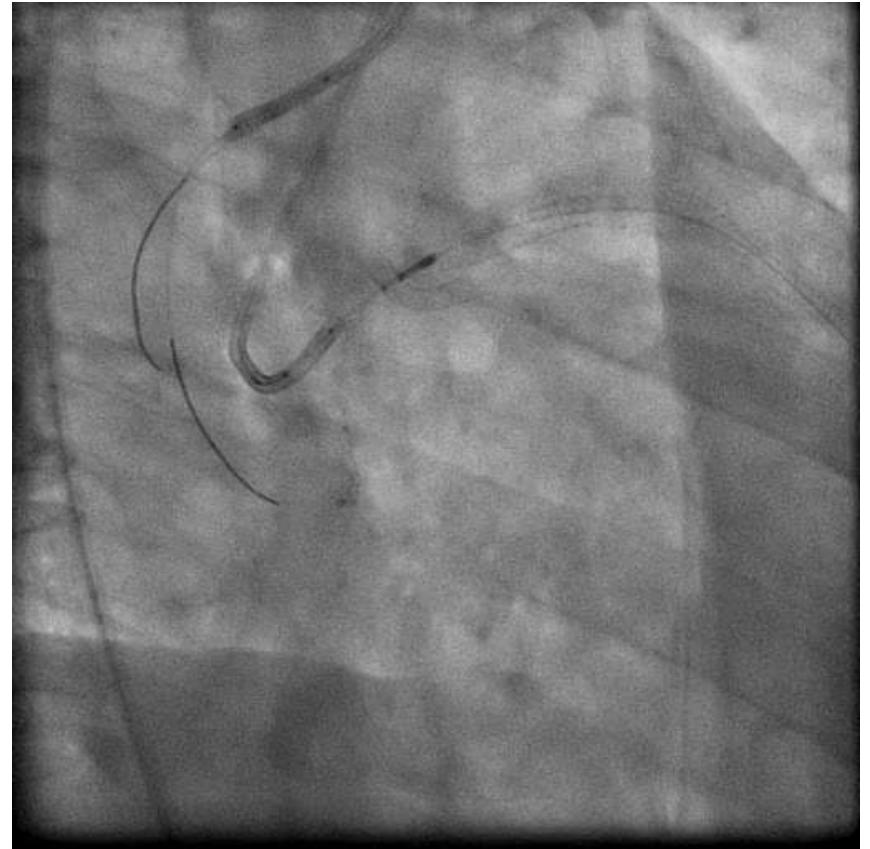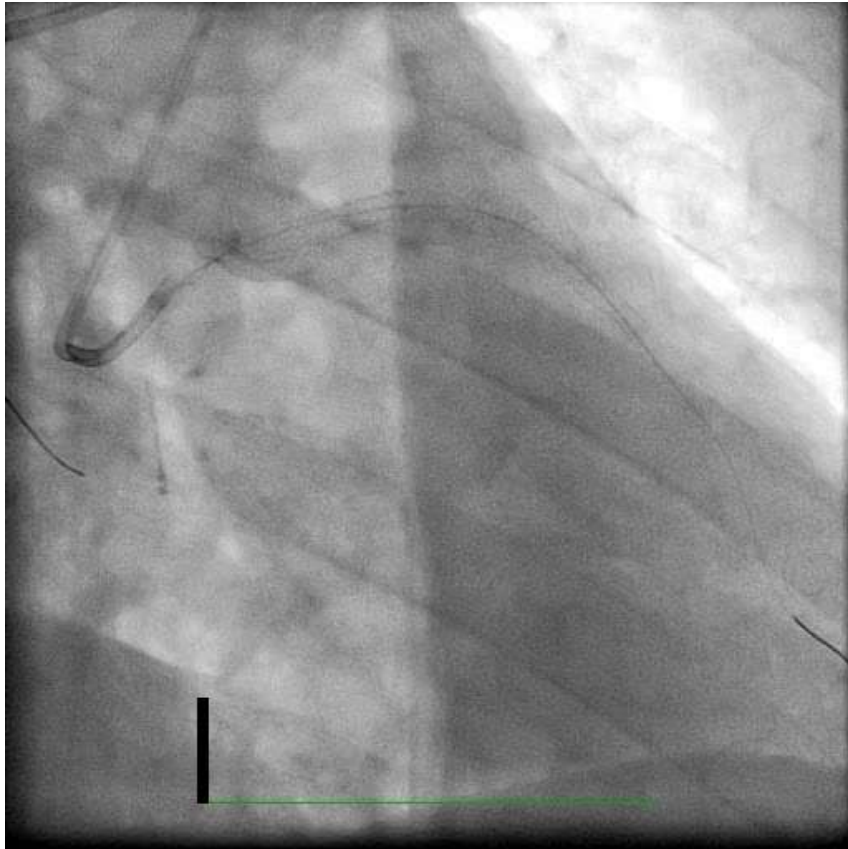
Tried Balloon Trapping Technique



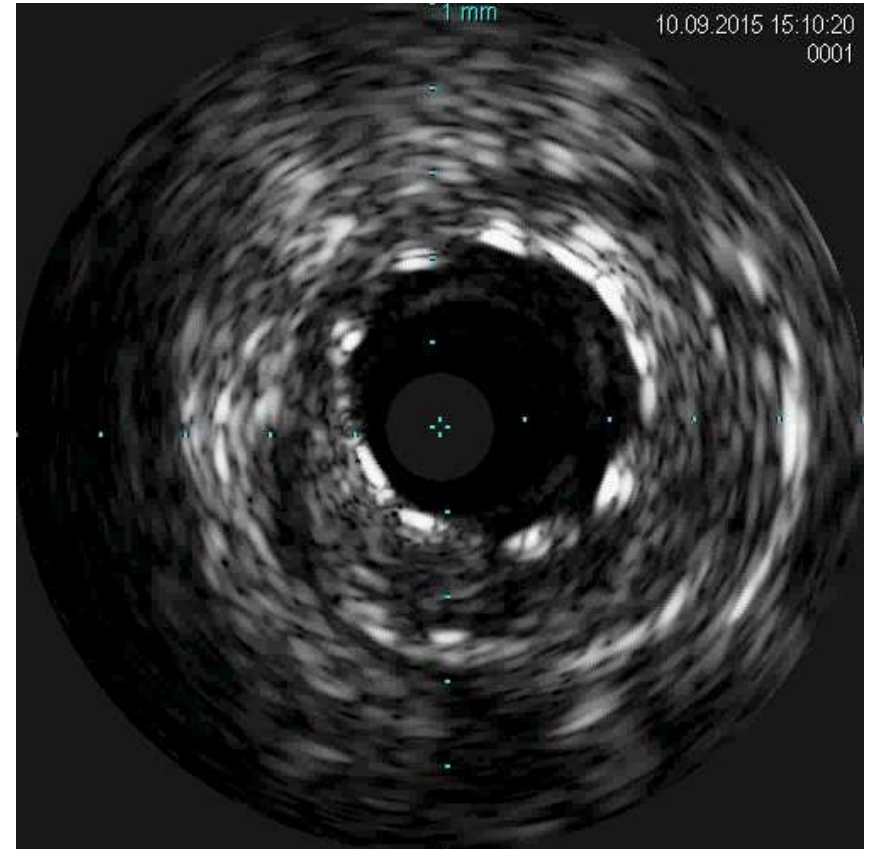
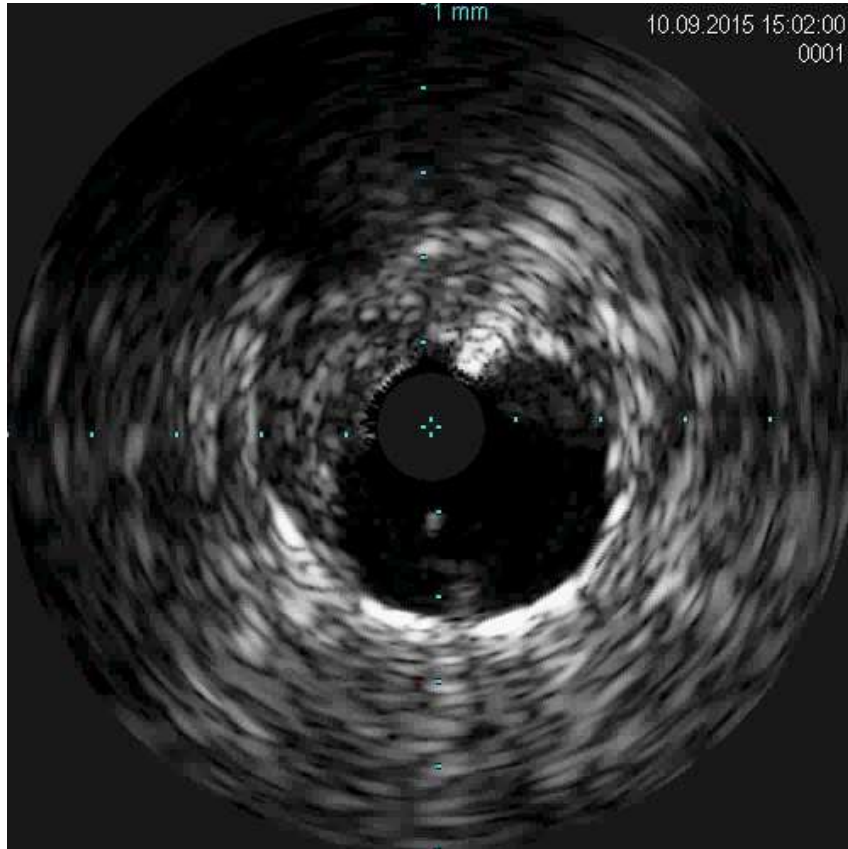
Failed Balloon Trapping Technique



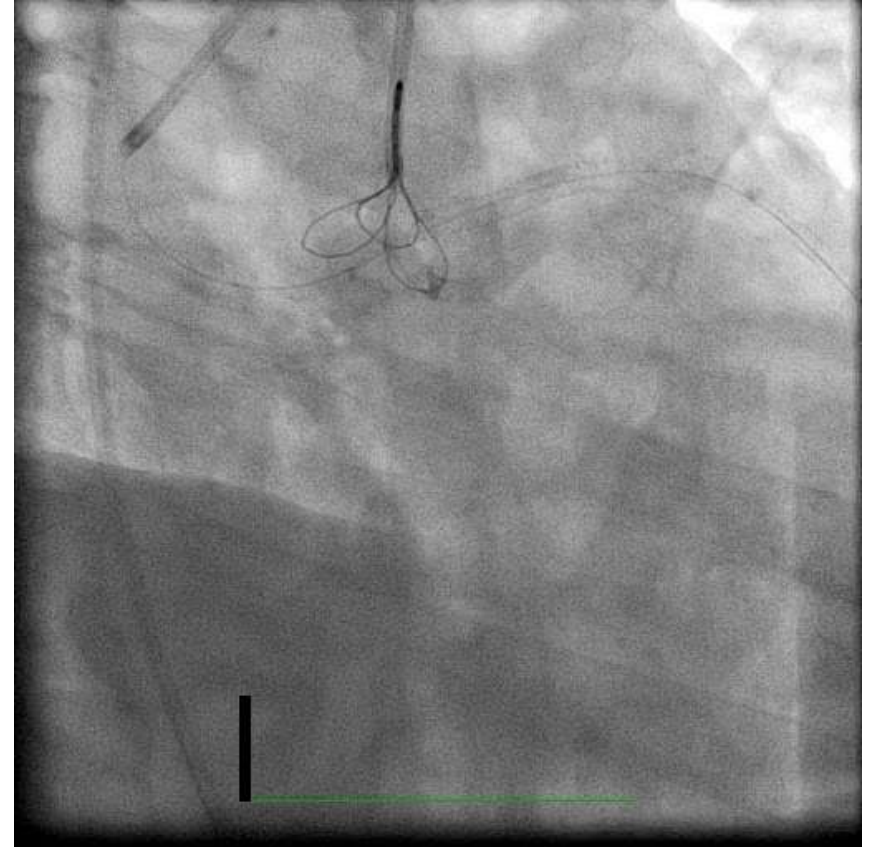
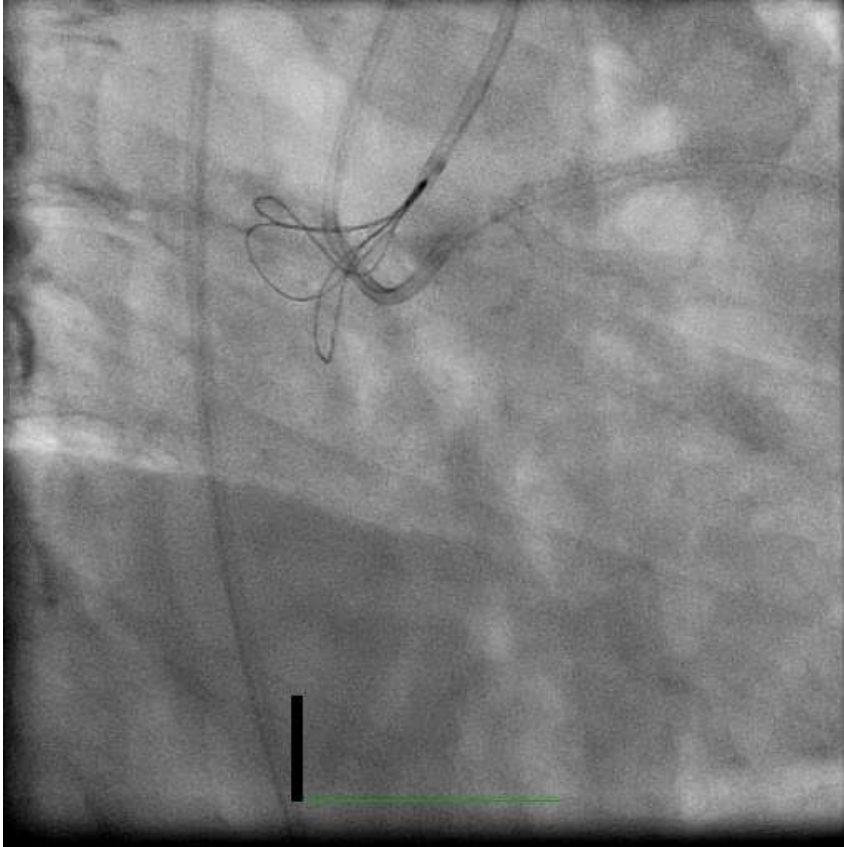
Stent Migrated to Coronary Sinus



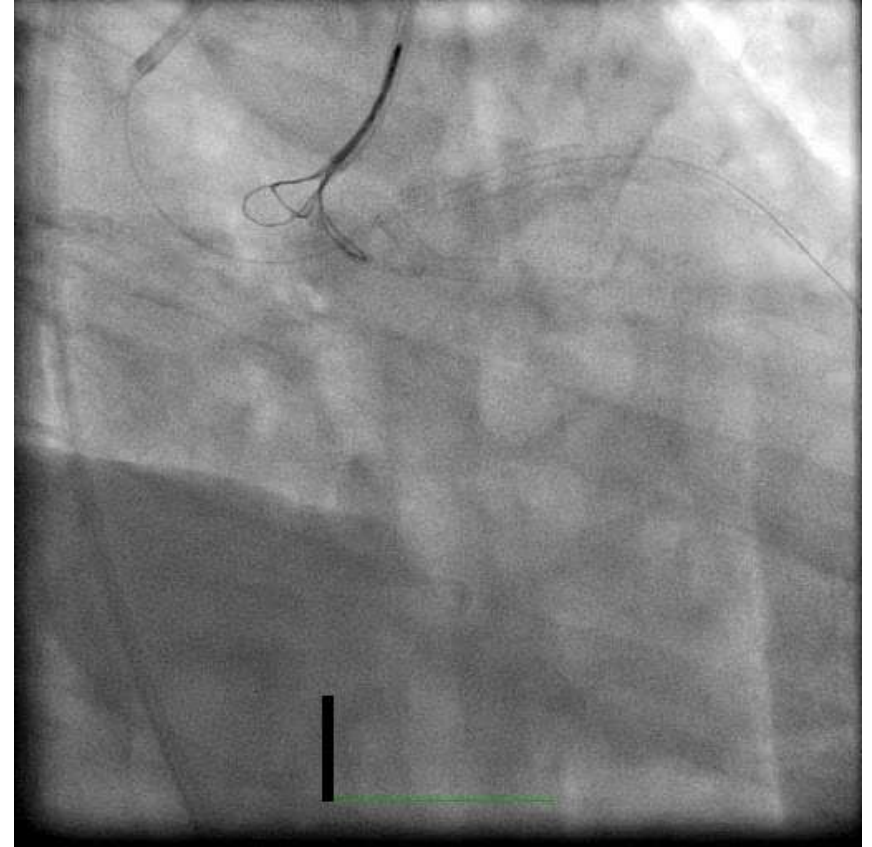
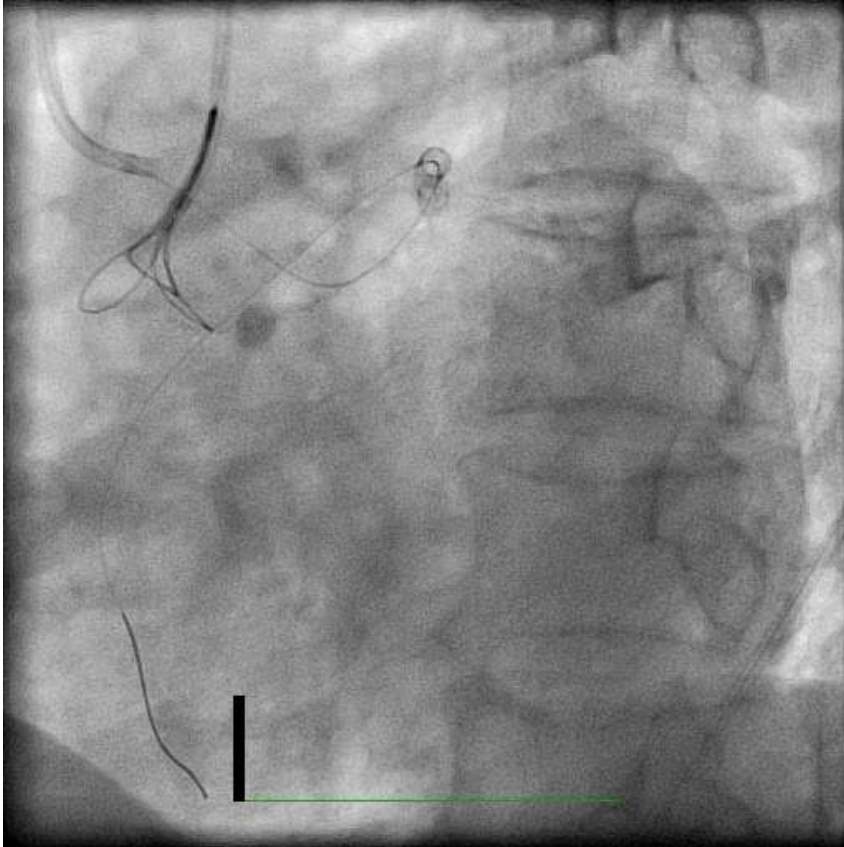
IVUS



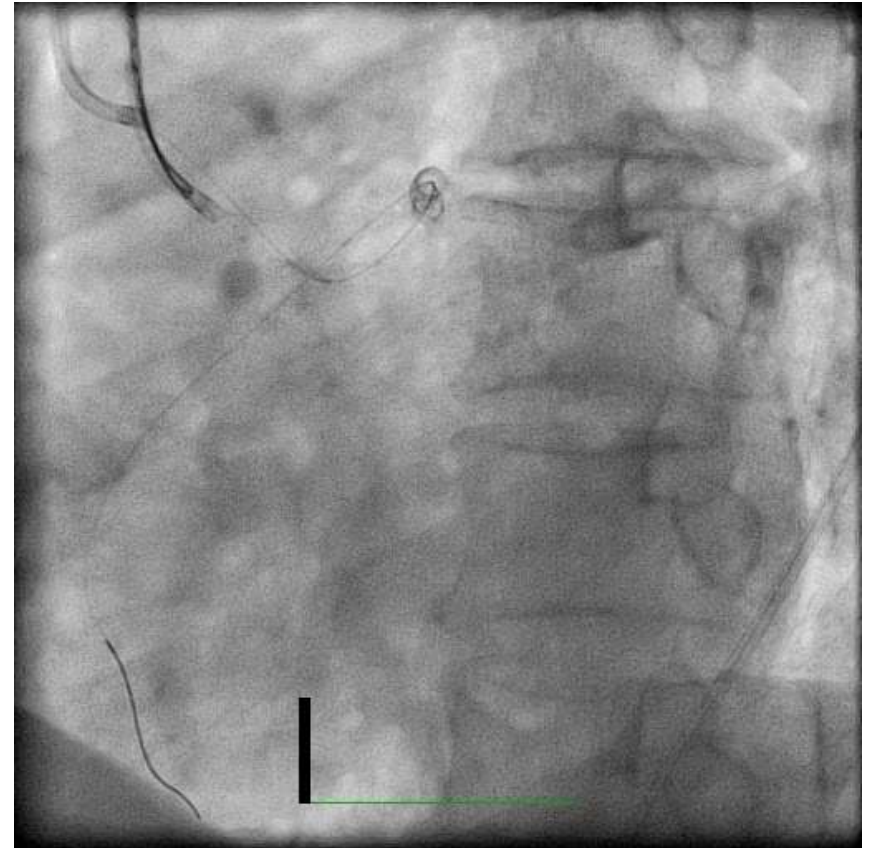
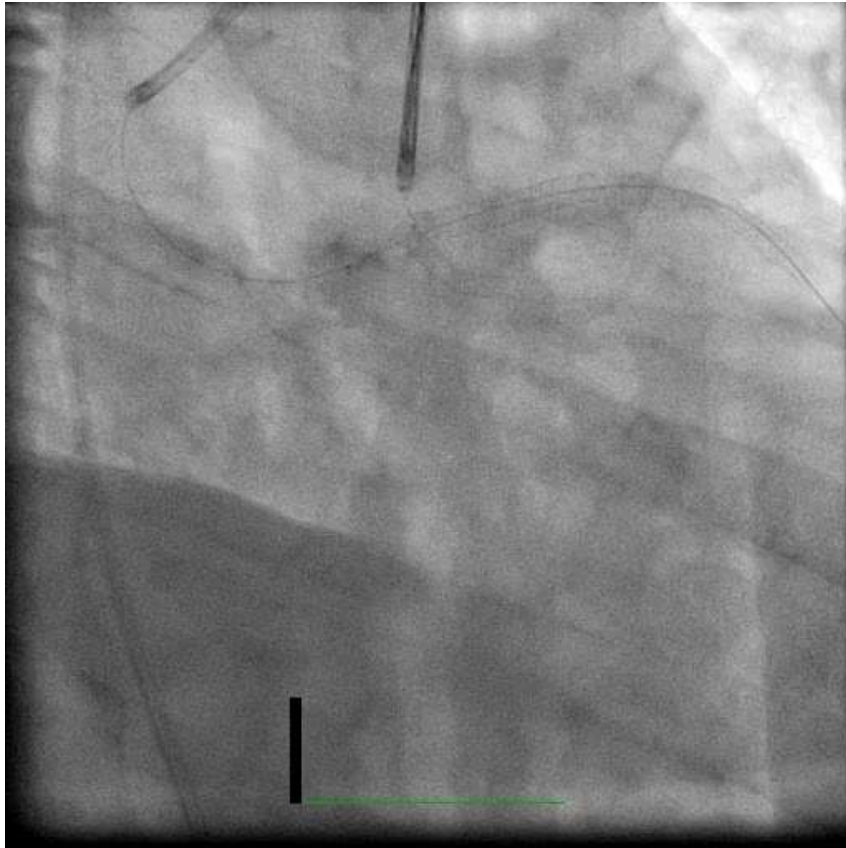
Tri-loop Snare Technique



Tri-loop Snare Technique

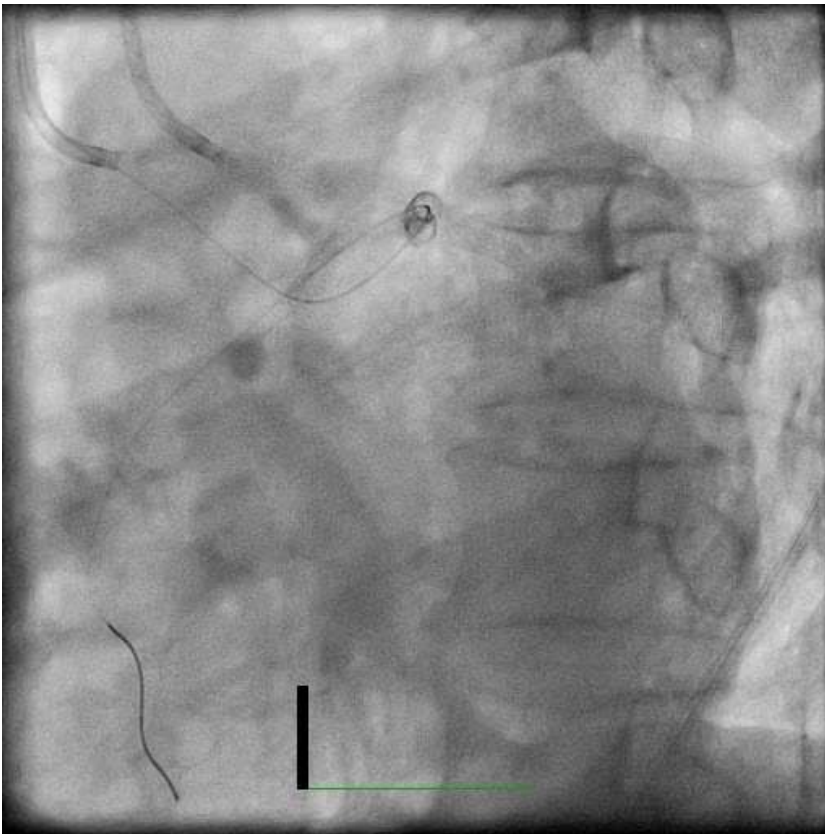


Stent Trapped by Tri-loop Snare

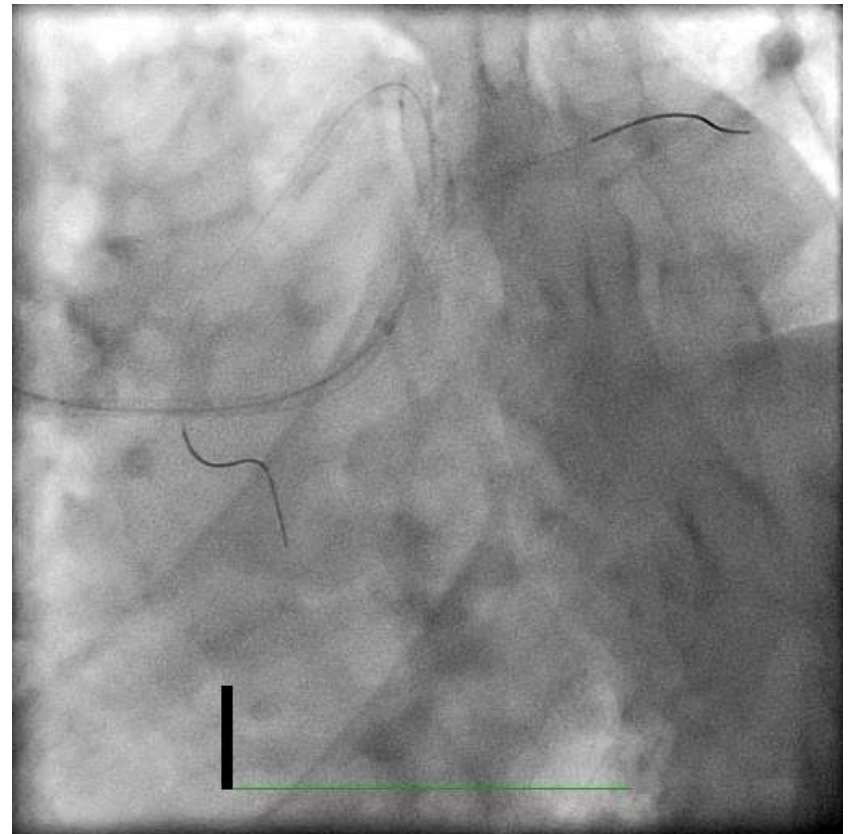


Successful Retrieval of Dislodged Stent

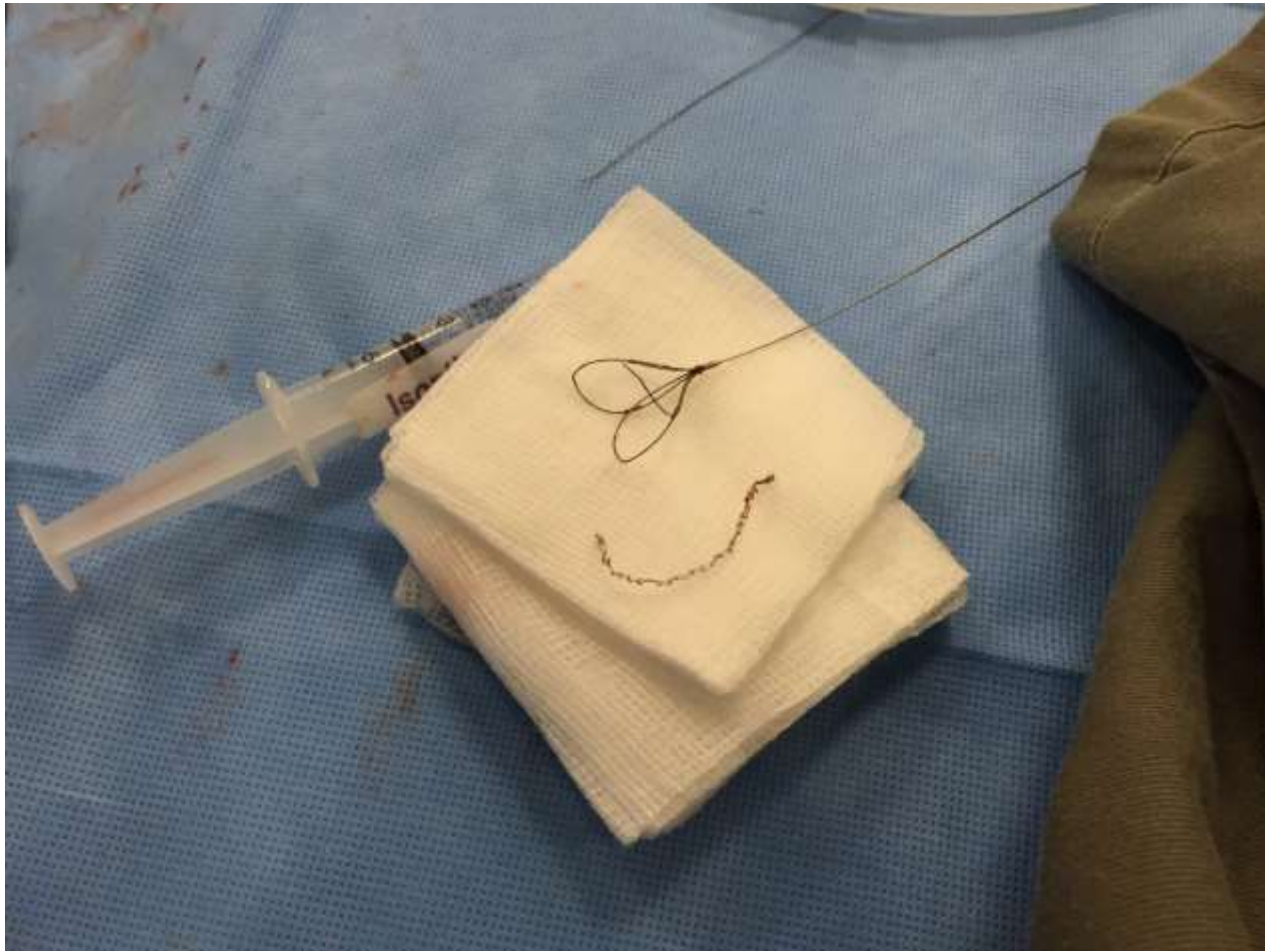
Dislodge Stent Removed



Final after LM Stenting



Retrieved Dislodged Stent



Be careful when retrieving stent

