Prepare & Predict:
Role of Intracoronary Imaging for Calcified Lesion PCI

Akiko Maehara, MD

Columbia University Medical Center

Cardiovascular Research Foundation

Cardiovascular Research Foundation

Columbia University Medical Center
NewYork-Presbyterian

Disclosure Statement of Financial Interest

Within the past 12 months, I or my spouse/partner have had a financial interest/arrangement or affiliation with the organization(s) listed below.

Affiliation/Financial Relationship	Company
• Grant/Research Support	• Boston Scientific, Abbott Vascular
• Consultant	• Boston Scientific, Abbott Vascular, Conavi Medical Inc., Philips

79 yo Male, Stable Angina

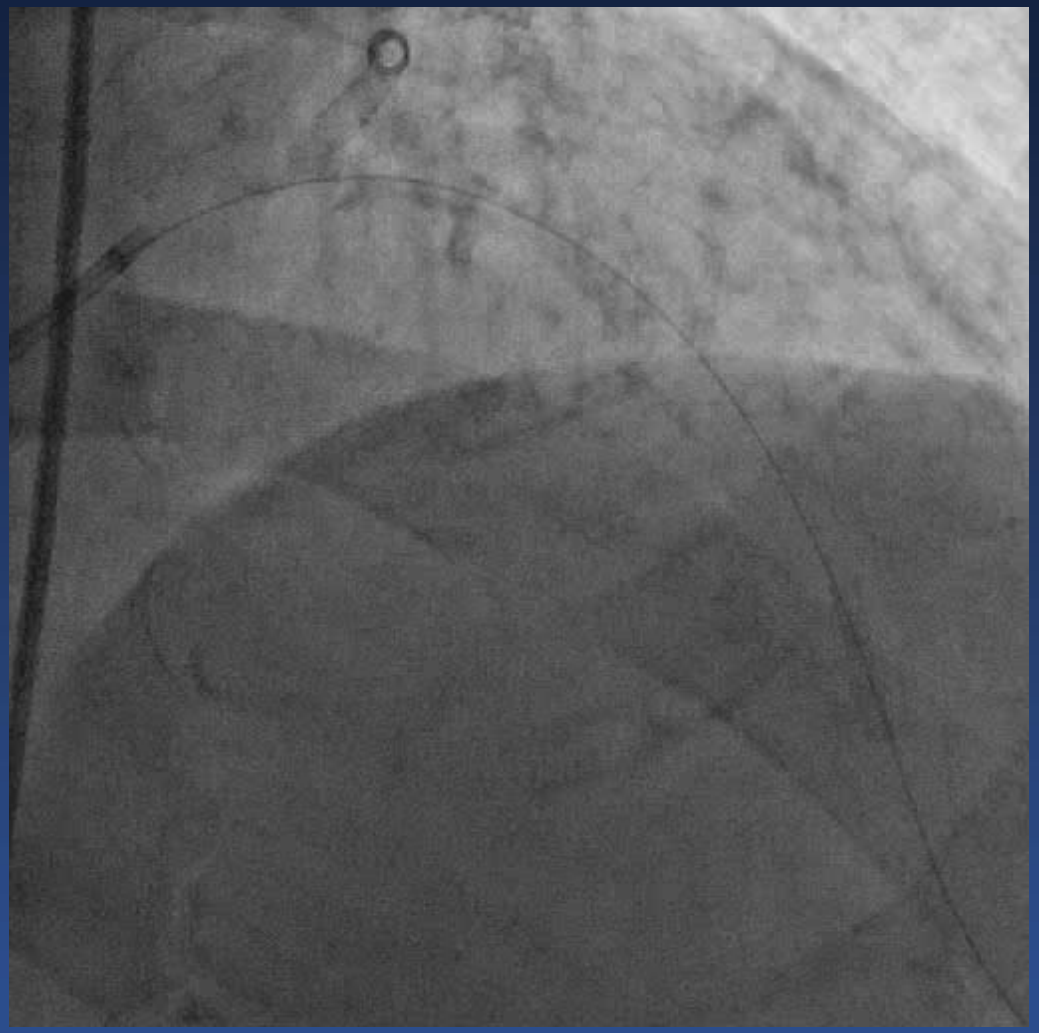

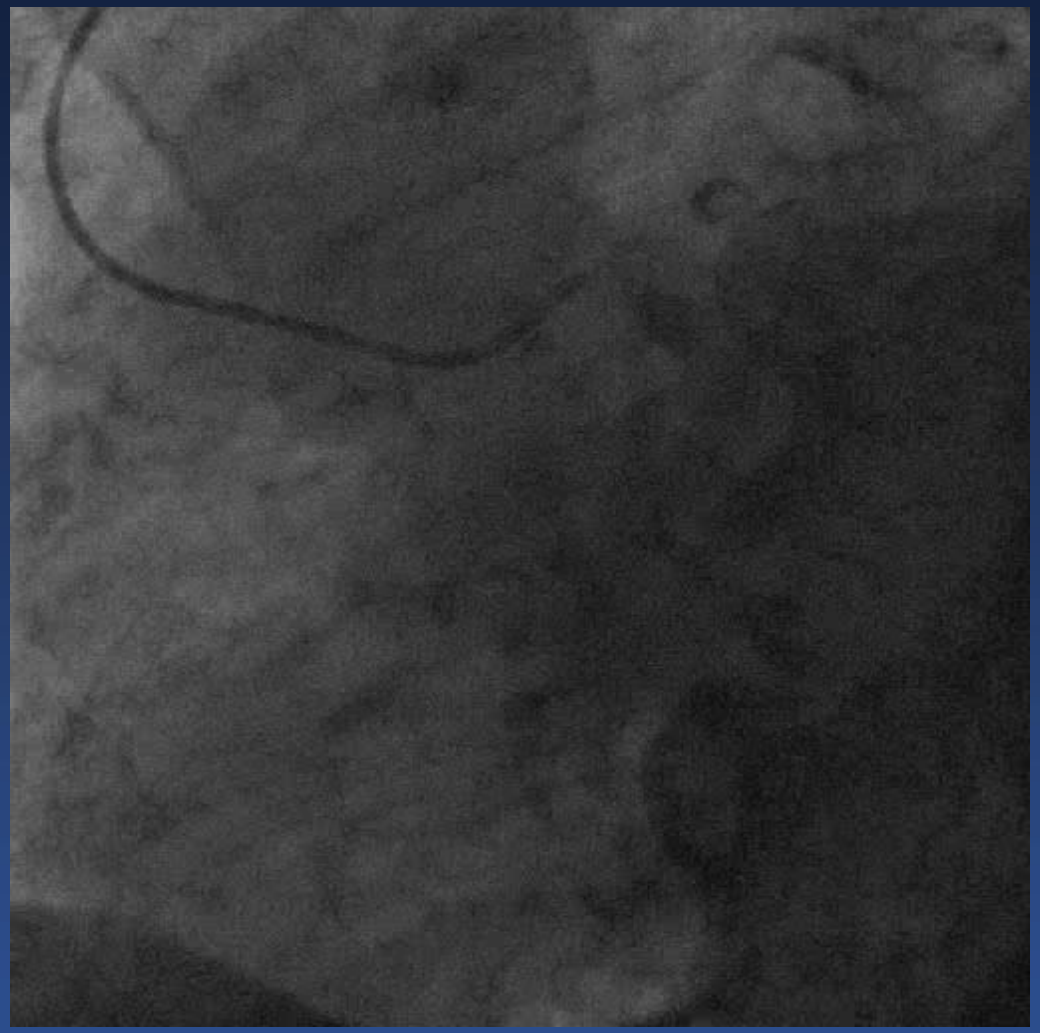

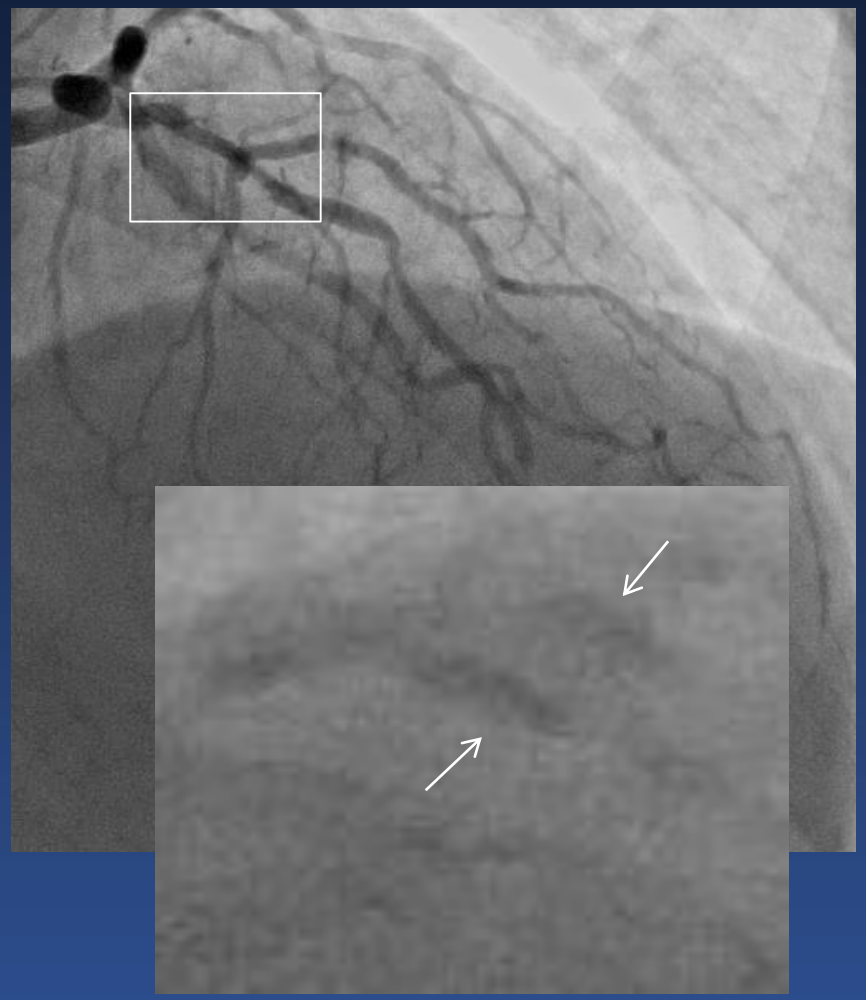

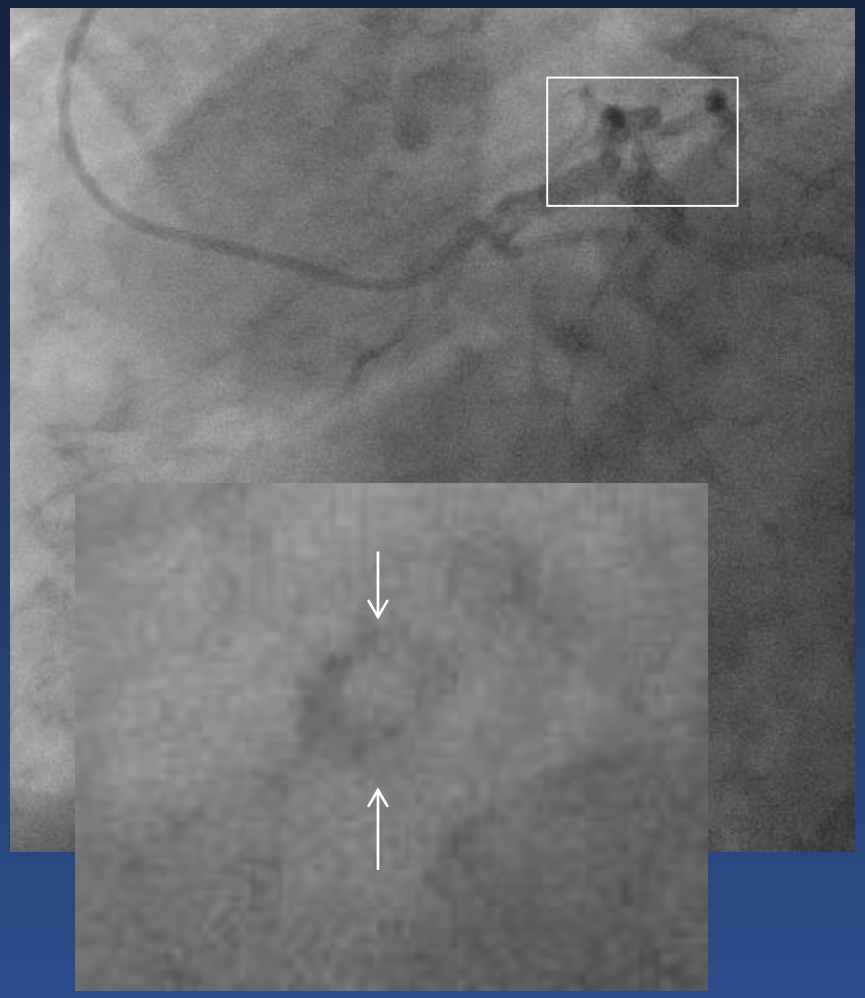

1-year later, Pre-PCI OCT

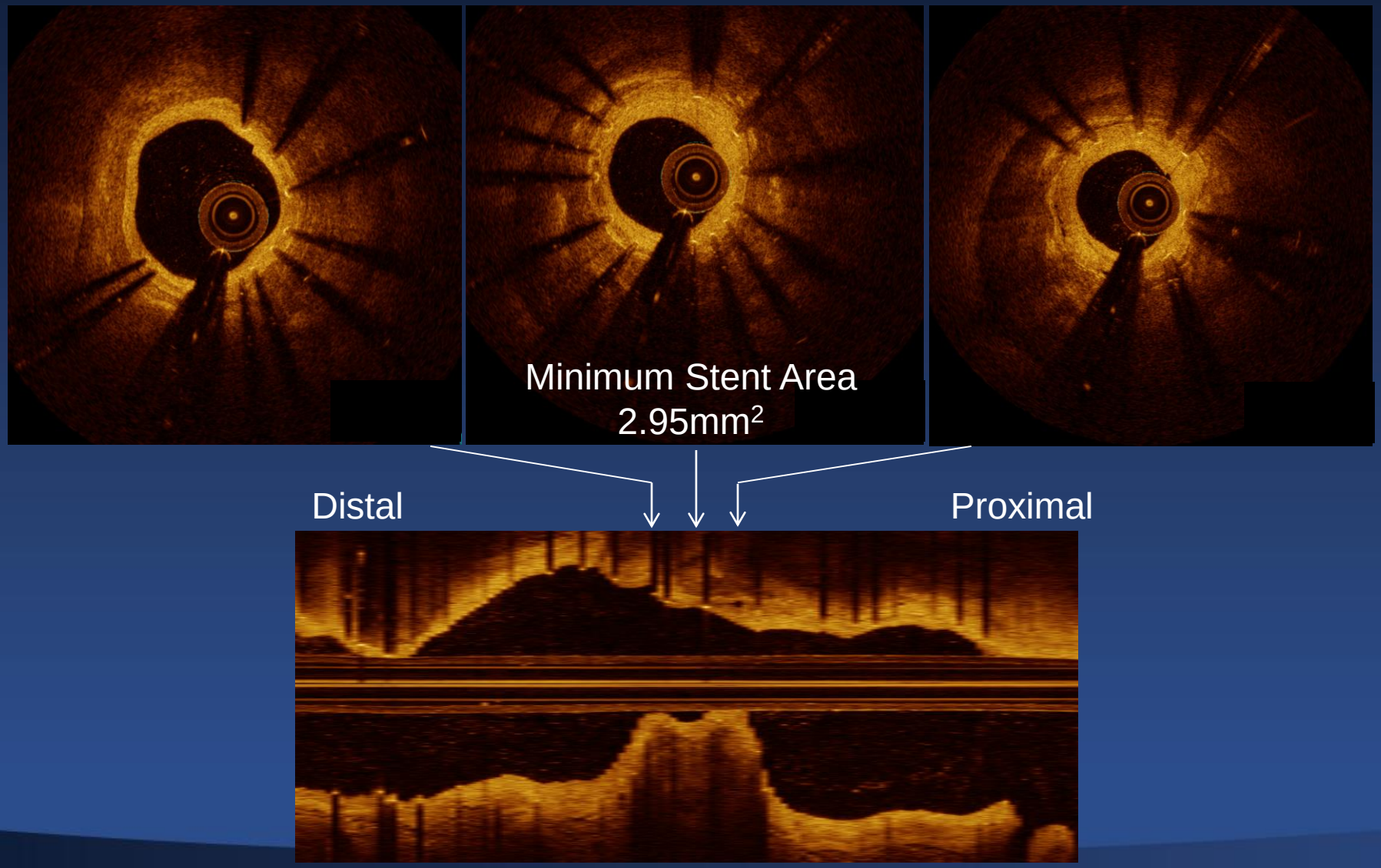

Treated with ECLA/NC-Balloon

Pre

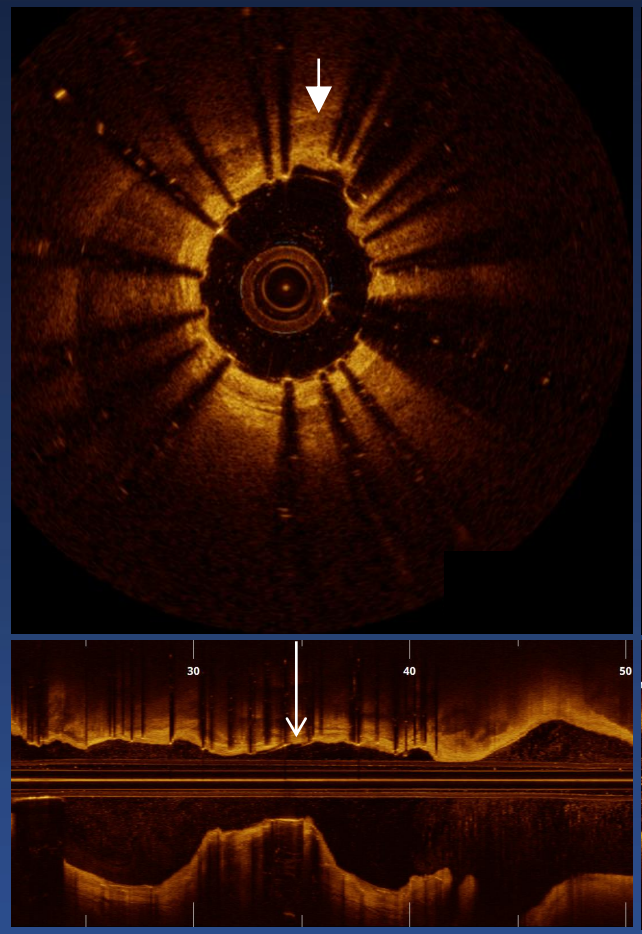

Minimum Lumen Area
2.76 mm^2

Post-ELCA

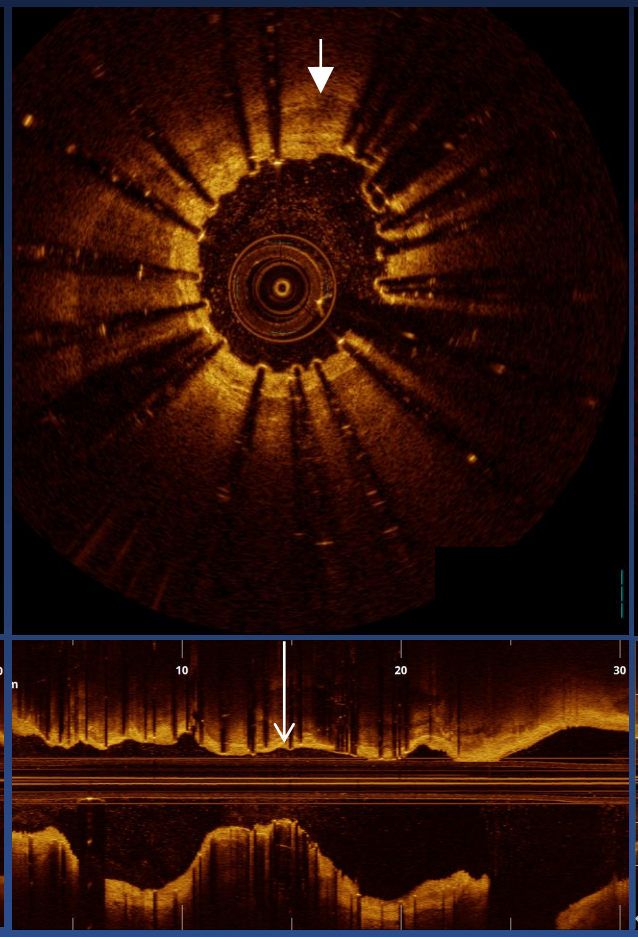

Post-Balloon

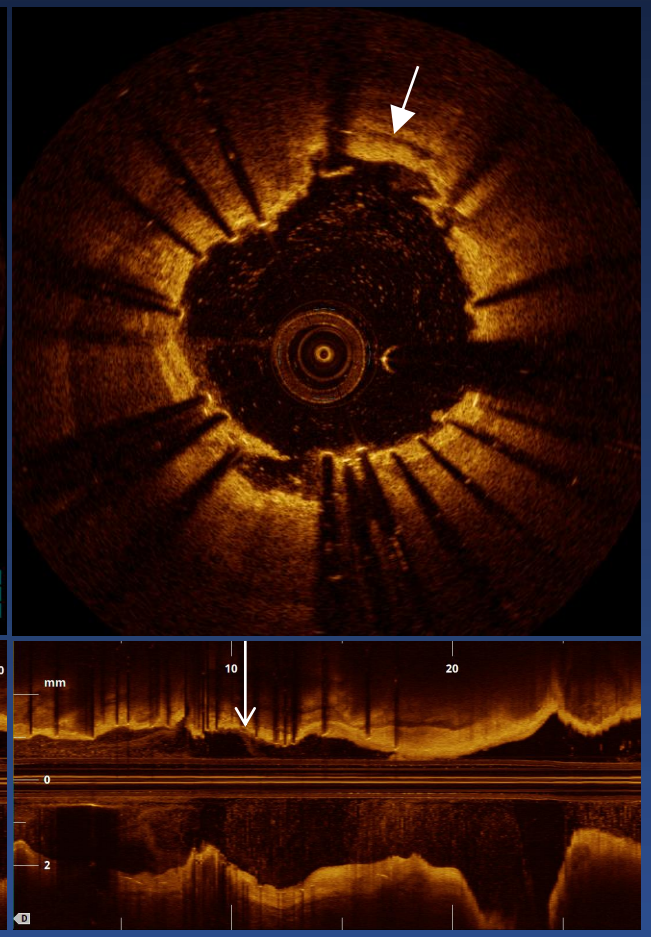

Minimum Lumen Area
6.34 mm^2

Cardiovascular Research Foundation

Columbia University Medical Center
NewYork-Presbyterian

IVUS or OCT and Angiographic Calcium (n=440)

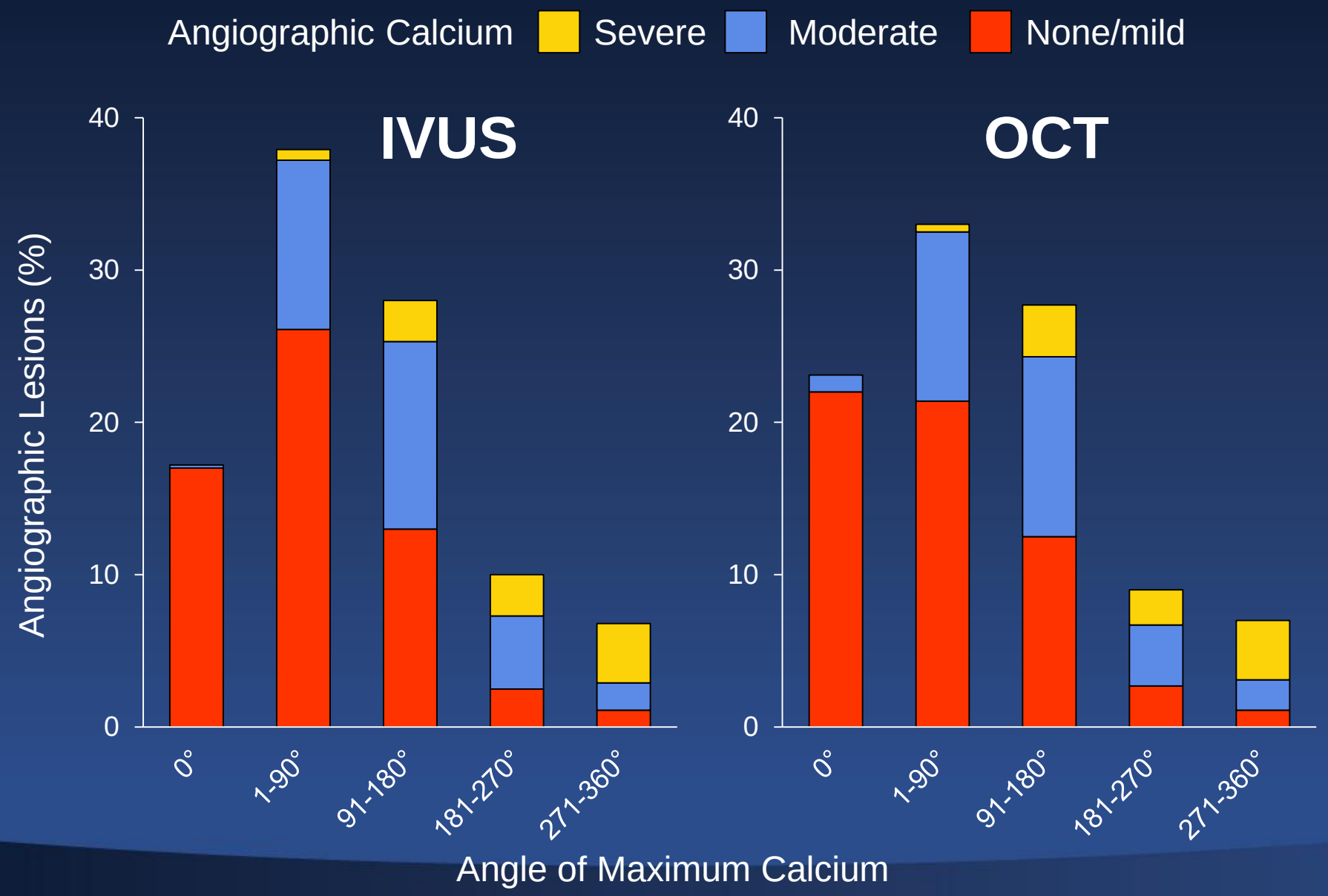

Wang X and Matsumura M, et al. JACC Img 2017;10: 869-79.

OCT Thin Calcium Not Visible by Angio

Proximal

Distal

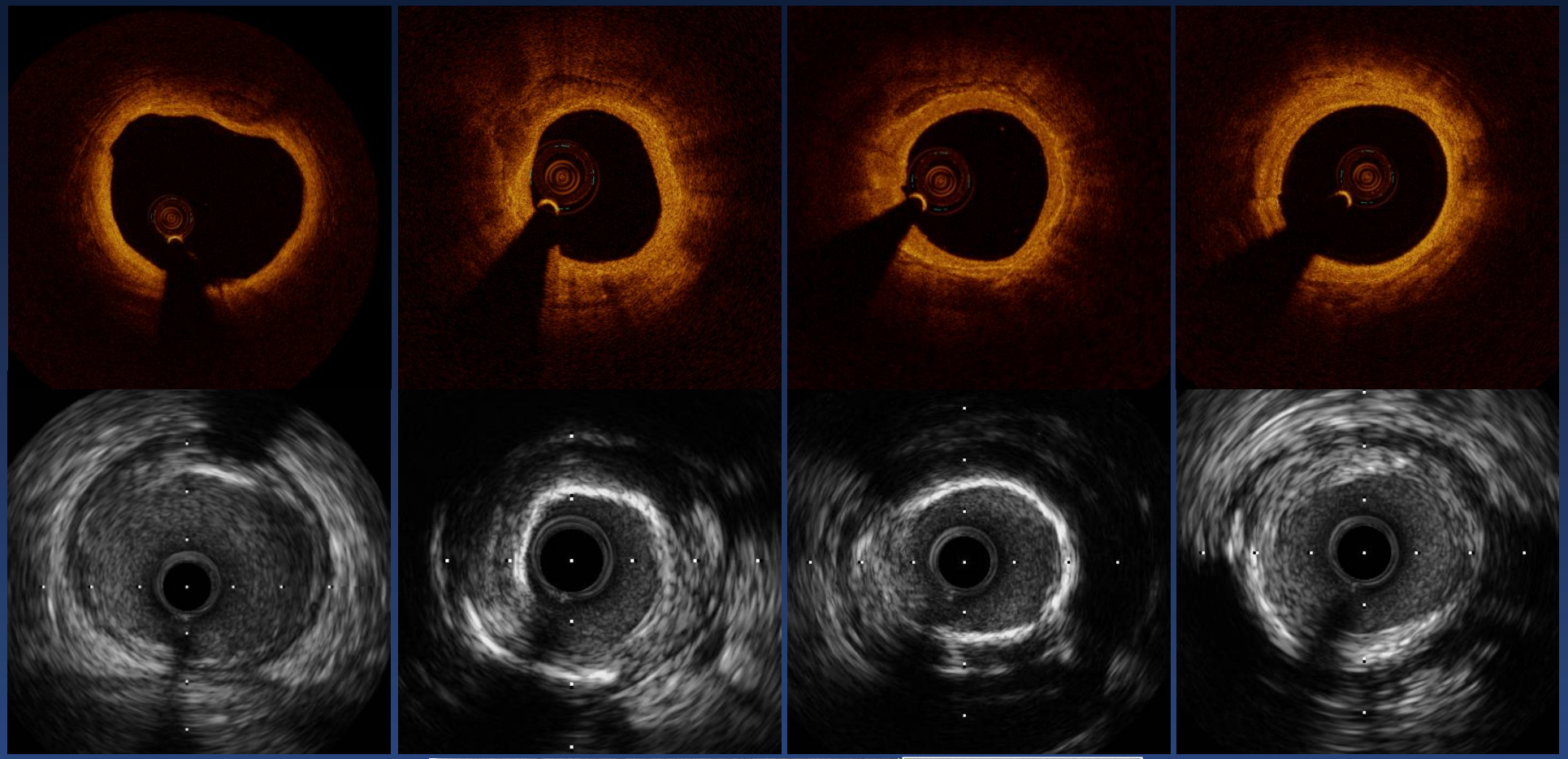

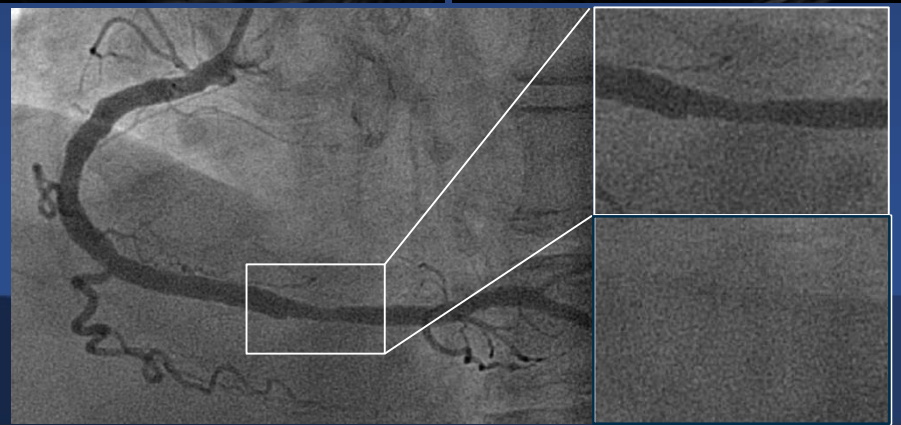

Cardiovascular Research Foundation

Columbia University Medical Center

NewYork-Presbyterian

With vs Without Angio Ca Visibility in IVUS Max Ca Angle>180°

	Angio Non-Visible (n=16)	Angio Visible (n=58)	p
Pre IVUS max Ca angle, °	228 (190, 286)	259 (230, 322)	0.03
Pre-OCT			
Presence of Ca	100%	98%	0.99
Max Ca angle, °	190 (146, 300)	250 (174, 320)	0.15
<0.5mm thickness, °	160 (69, 249)	96 (0, 131)	0.002
≥0.5mm thickness, °	61 (10, 92)	171 (98, 242)	<0.001
Mean Ca angle,	44 (33, 90)	68 (43, 146)	0.047
Max Ca thickness, mm	0.71 (0.52, 0.89)	0.95 (0.75, 1.15)	0.004
Ca length, mm	11.0 (6, 18)	16.0 (11, 23)	0.01
Post-OCT			
Minimum stent area, mm^2	8.1 (6.6, 9.3)	5.9 (4.6, 7.3)	0.001
Stent expansion, %	80.8 (75, 107)	91.7 (78, 101)	0.88

Wang X and Matsumura M, et al. JACC Img 2017;10: 869-79.

Multivariate Linear Regression Model to Predict Stent Expansion

Covariate	Regression Coefficient	95% Confidence Interval	p Value
Maximum calcium angle (per 180°)	-7.43	-12.6 to -2.21	<0.01
Maximum calcium thickness (per 0.5 mm)	-3.40	-6.35 to -0.45	0.02
Calcium length (per 5 mm)	-3.32	-4.09 to -0.55	0.01

The variables that were included in the model, but found not significant: The number of calcium deposits, Total stent length, Maximum inflation pressure, Balloon-to-artery ratio.

Fujino A et al. EuroIntervention. 2018;13:e2182-9.

Calcium Scoring System

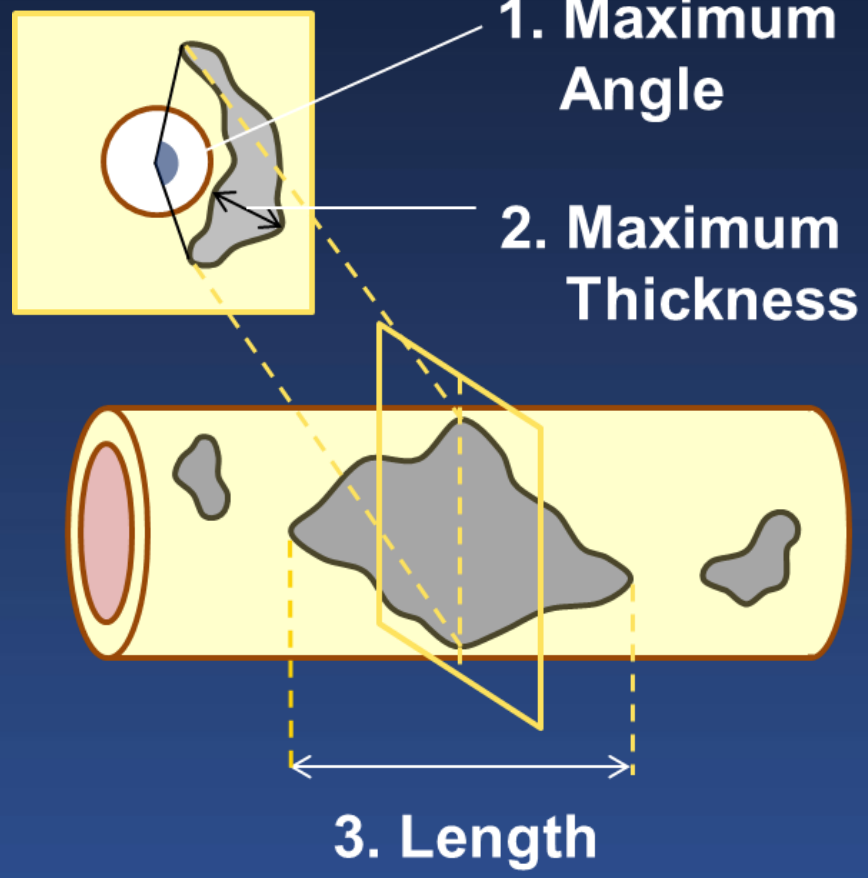

OCT-based CVI Score		
Angle	≤ 180°	0 point
	> 180°	2 points
Thickness	≤ 0.5 mm	0 point
	> 0.5 mm	1 point
Length	≤ 5.0 mm	0 point
	> 5.0 mm	1 point
Total score: 0 to 4 points		

Fujino A et al. EuroIntervention. 2018;13:e2182-9.

Calcium Score Predicts Stent Expansion

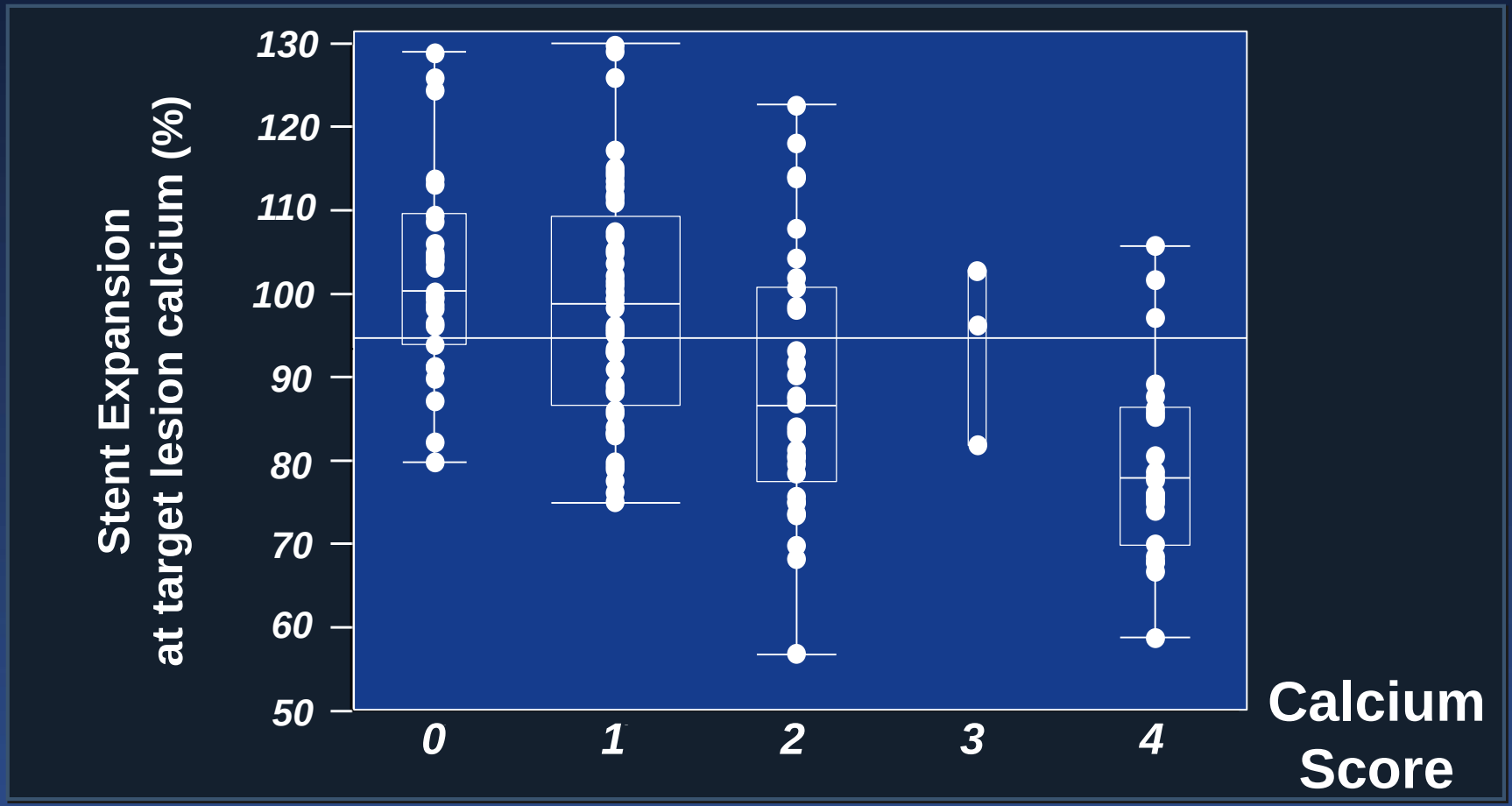

CVI score	0	1	2	3	4	p Value
Expansion at target lesion calcium, %	99	98	86	98	78	<0.01
Expansion at minimum stent area, %	91	85	80	82	69	<0.01

Cardiovascular Research Foundation

Columbia University Medical Center
NewYork-Presbyterian

Ca Morphology to Predict Ca Fracture without Atherectomy

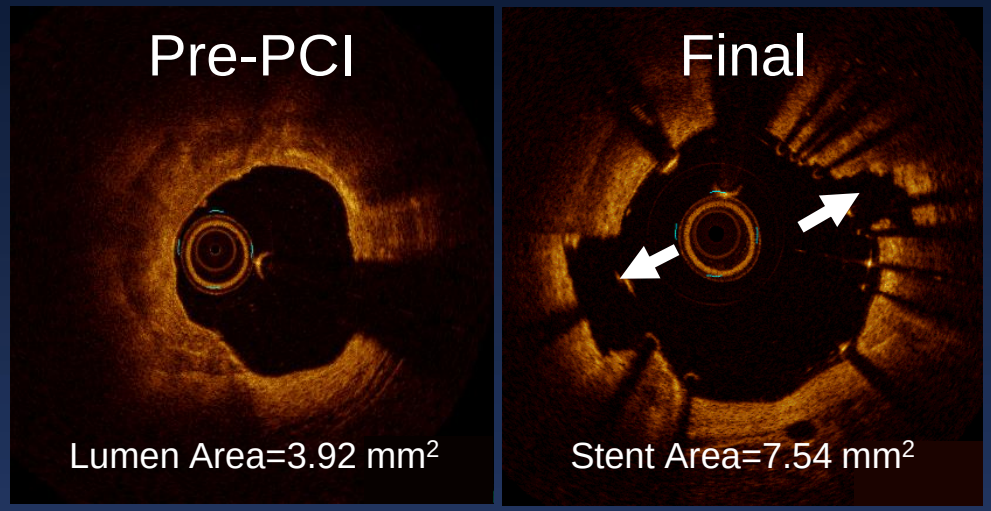

Calcium Fracture

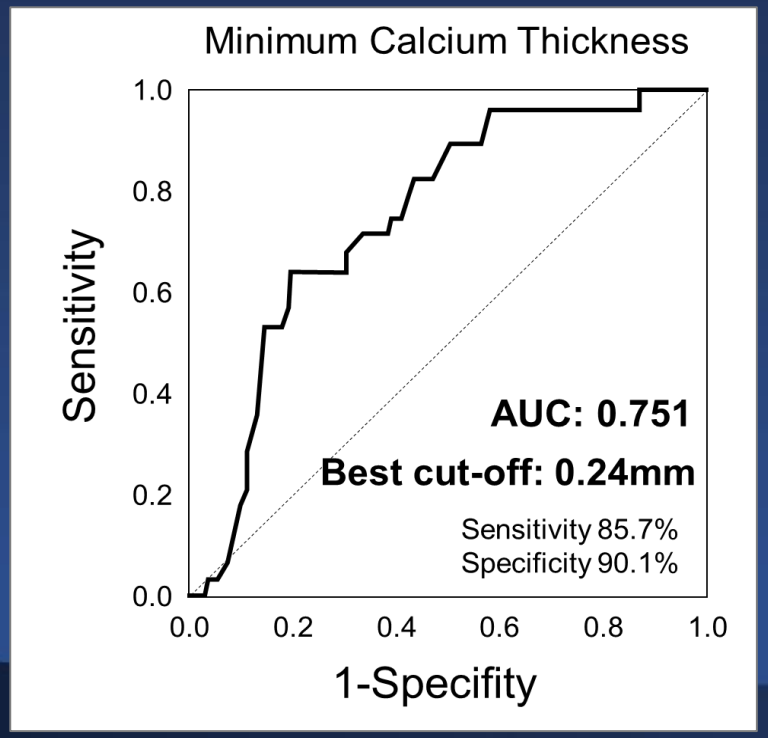

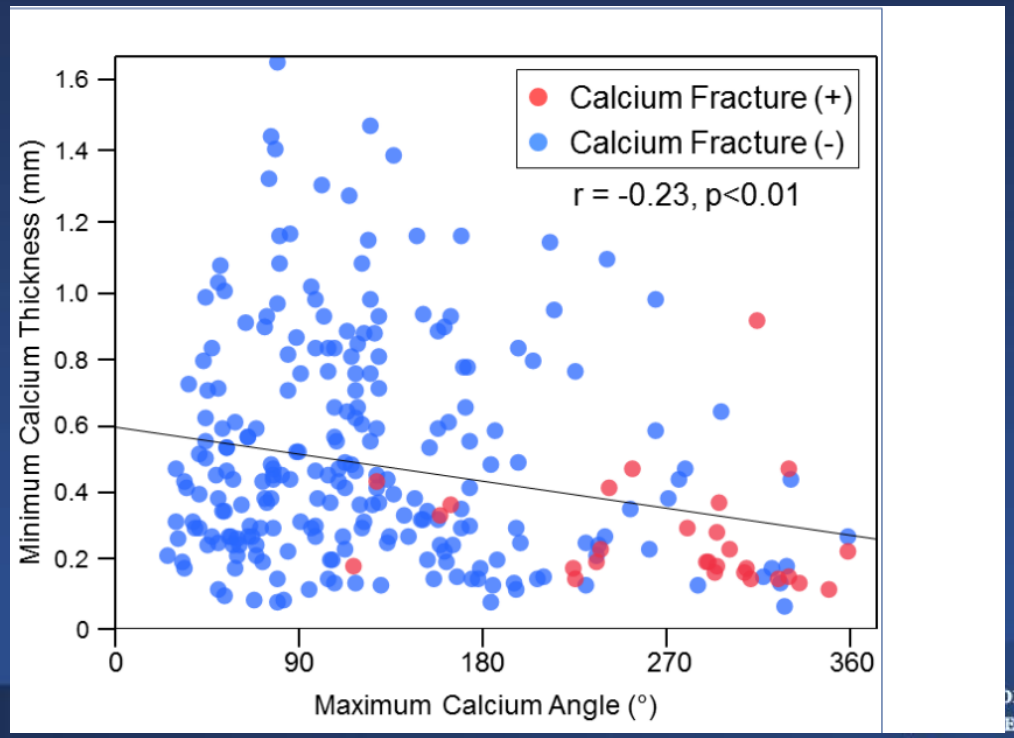

Fujino A JACC Interv 2018;11:1015-17.

Angiographic calcium ?

Yes ↓

IVUS: Maximum Calcium >270° ?

Yes ↓

Calcium Score Calculation: 0~4, if ≥2?

Yes = Point 1, No = Point 0 ↓

Consider atherectomy

Calcium >270° longer than 5mm?

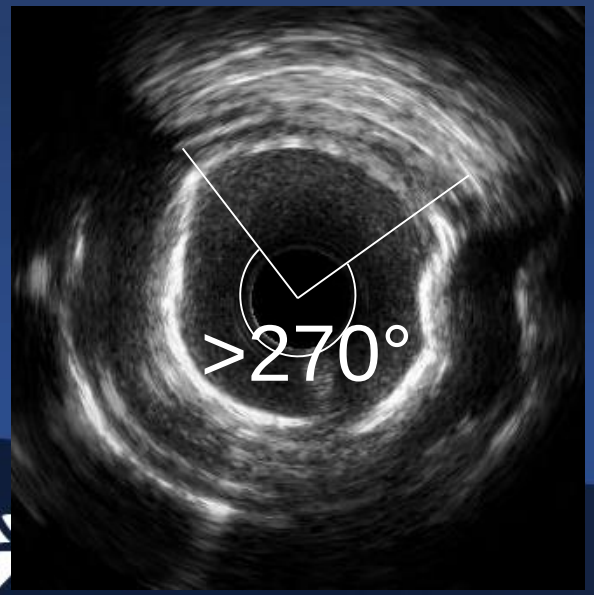

360° of calcium?

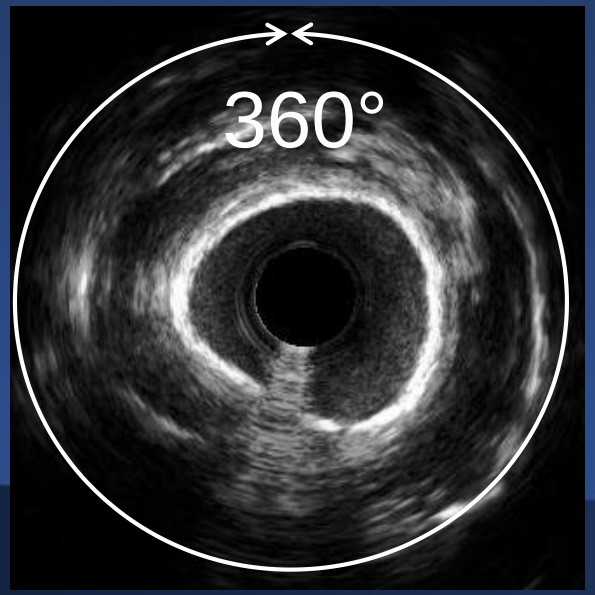

Calcified nodule?

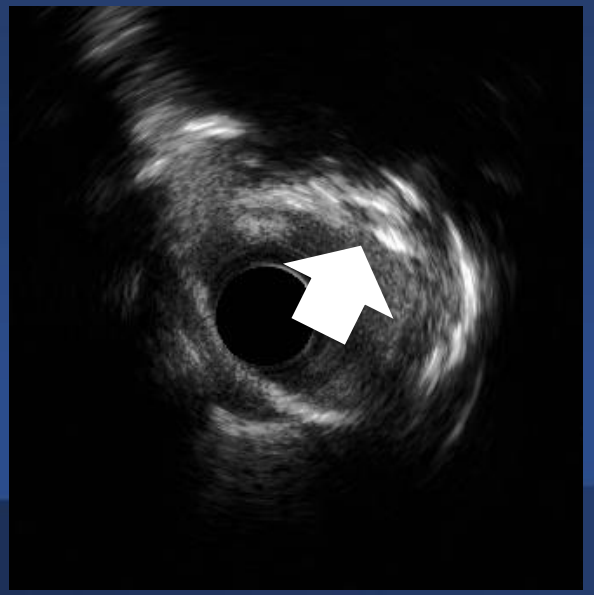

Vessel diameter <3.5mm ?

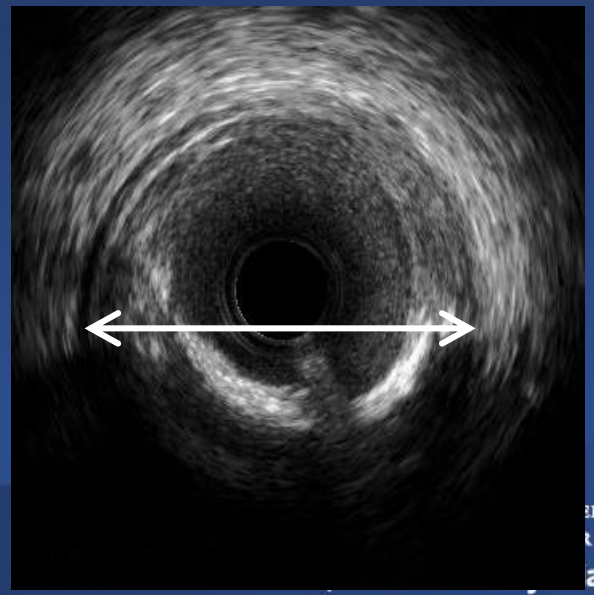

Calcium Score=2
Treated by Rota

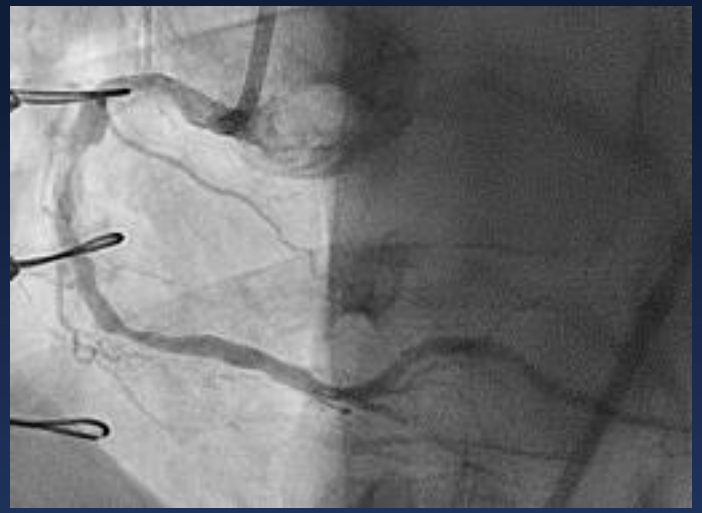

Rota Burr 1.25/1.5, NC-B

Rota Burr 2.0, NC-B

Final

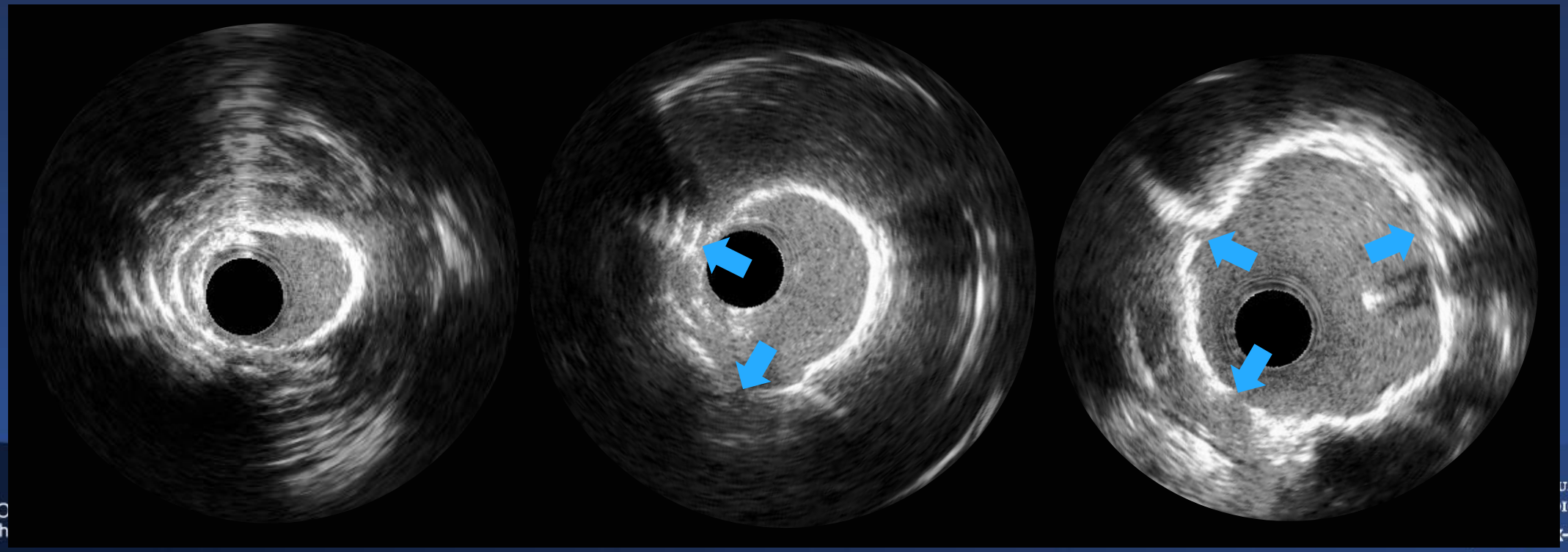

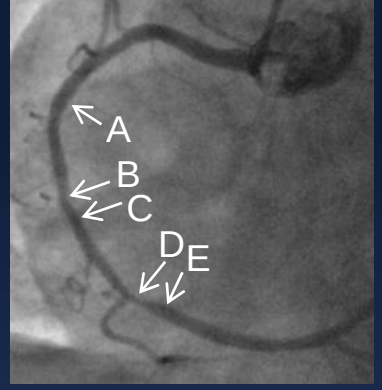

Proximal

Distal

Pre

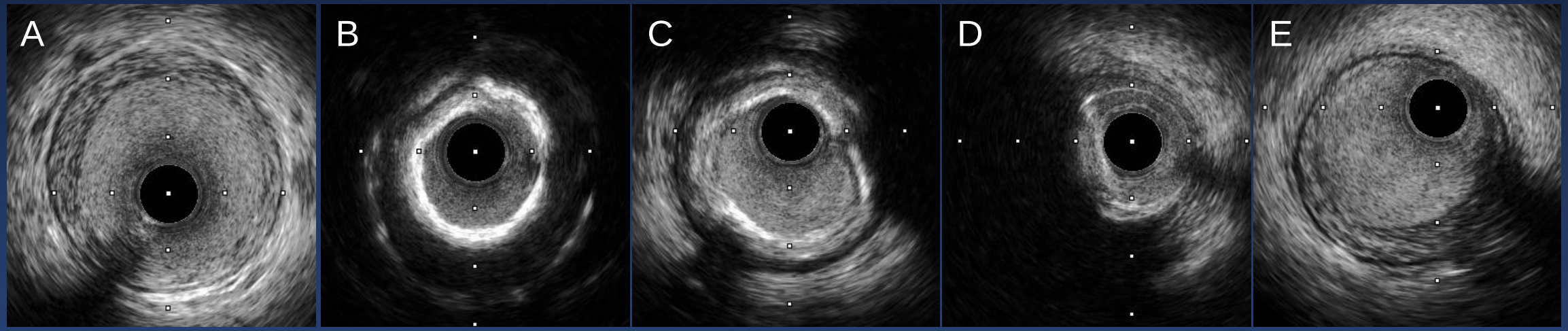

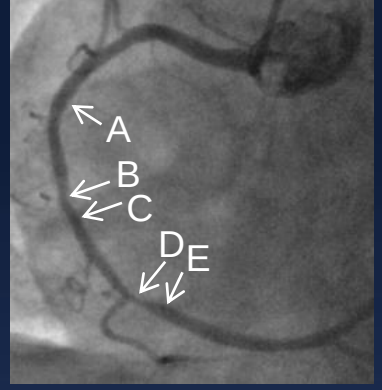

Proximal

Distal

Pre

Final

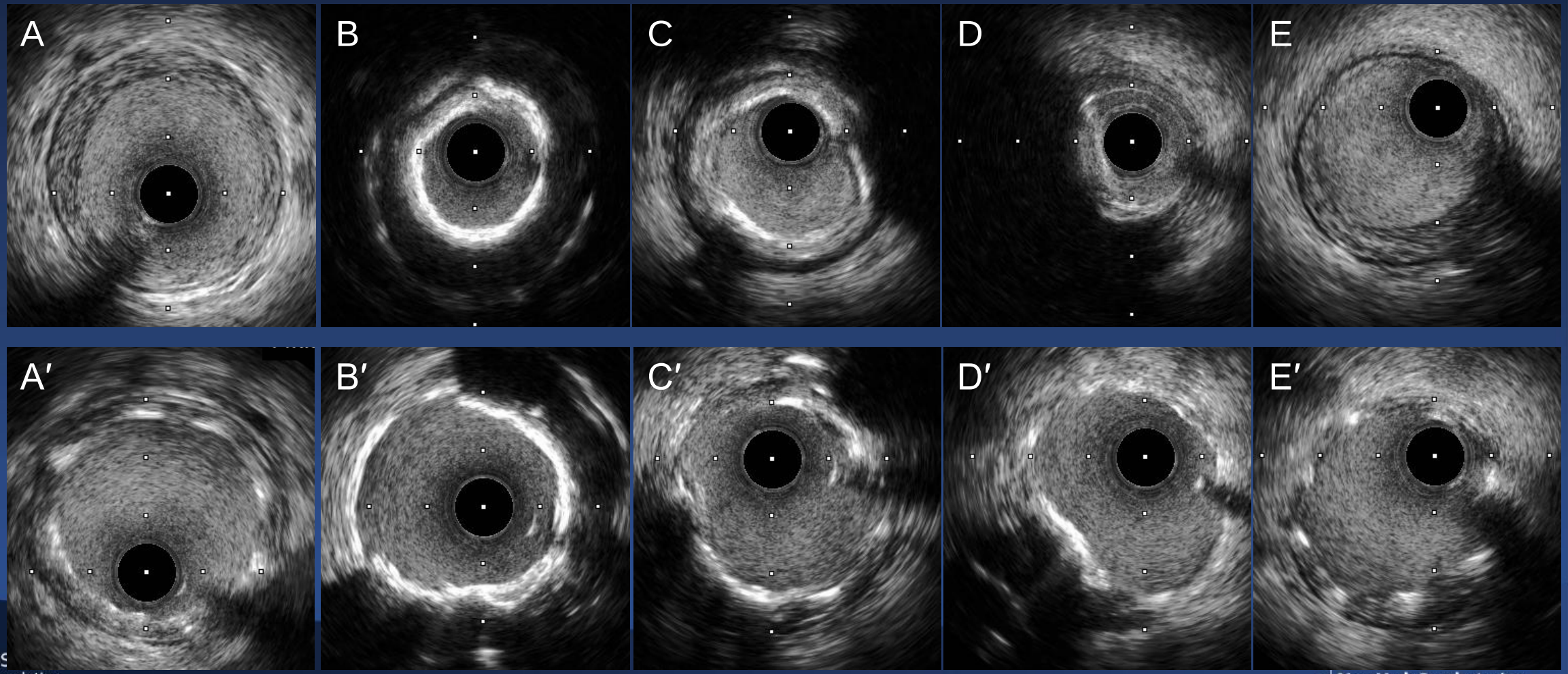

Detection of Calcium Fracture

Post-Balloon

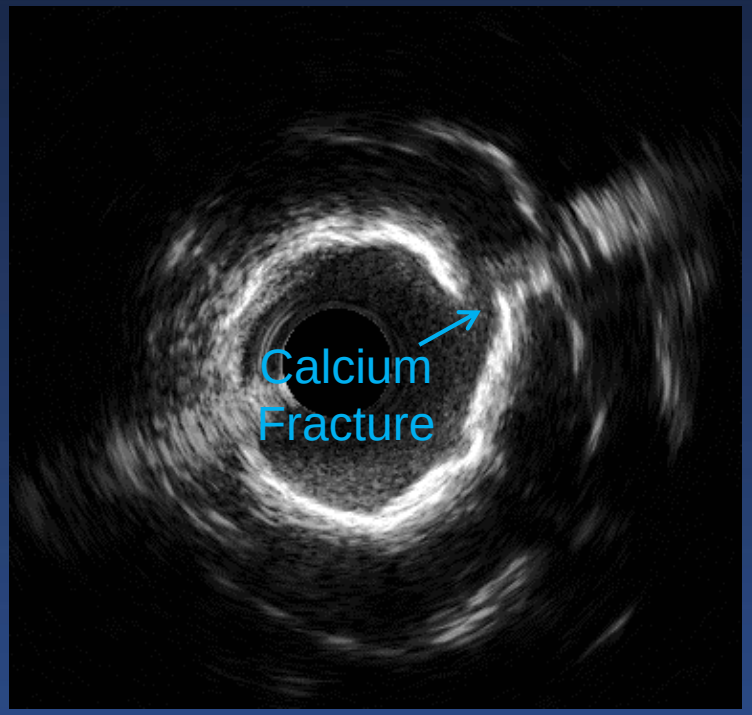

Post-Stent Final

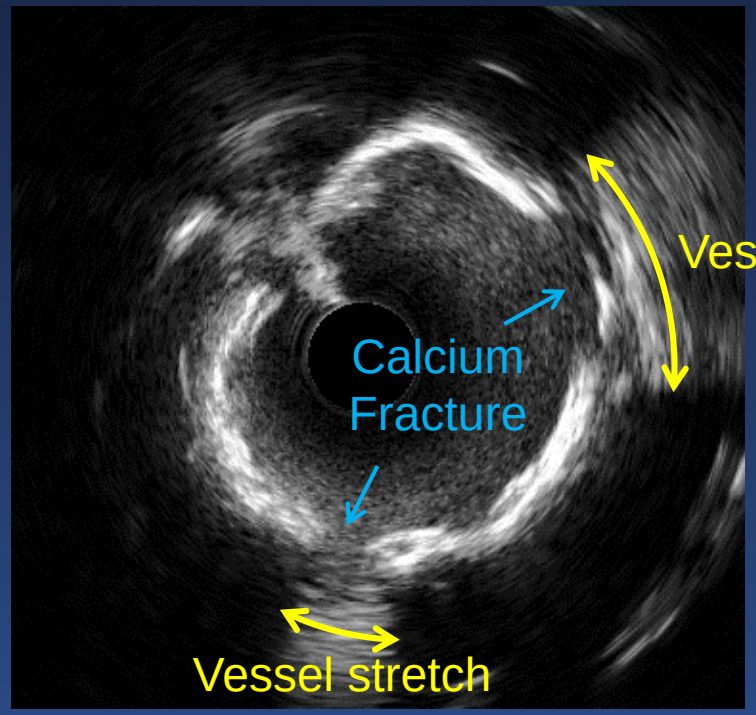

Stent Expansion Correlates with Calcium Score

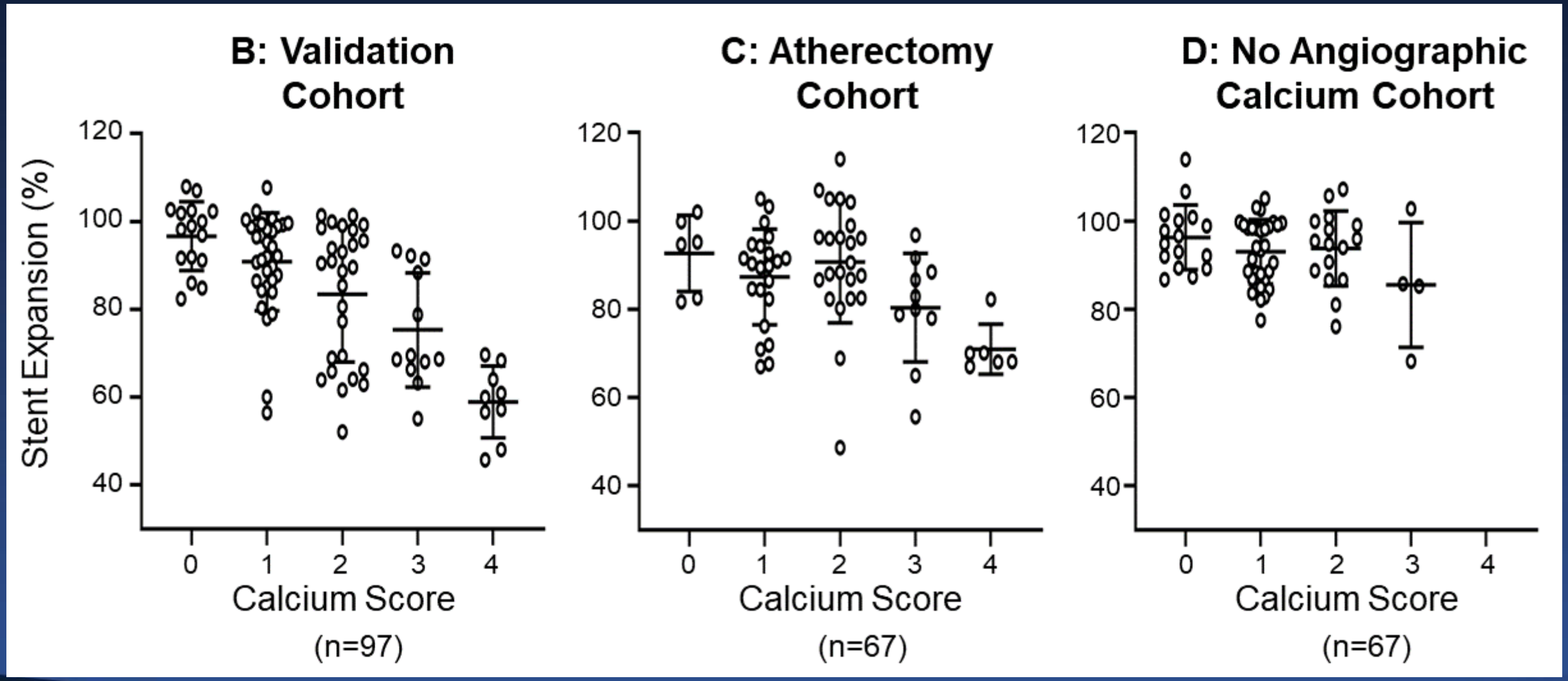

Zhang et al. Circ Interv 2021: 14e010296.

Effect of Atherectomy for Stent Expansion

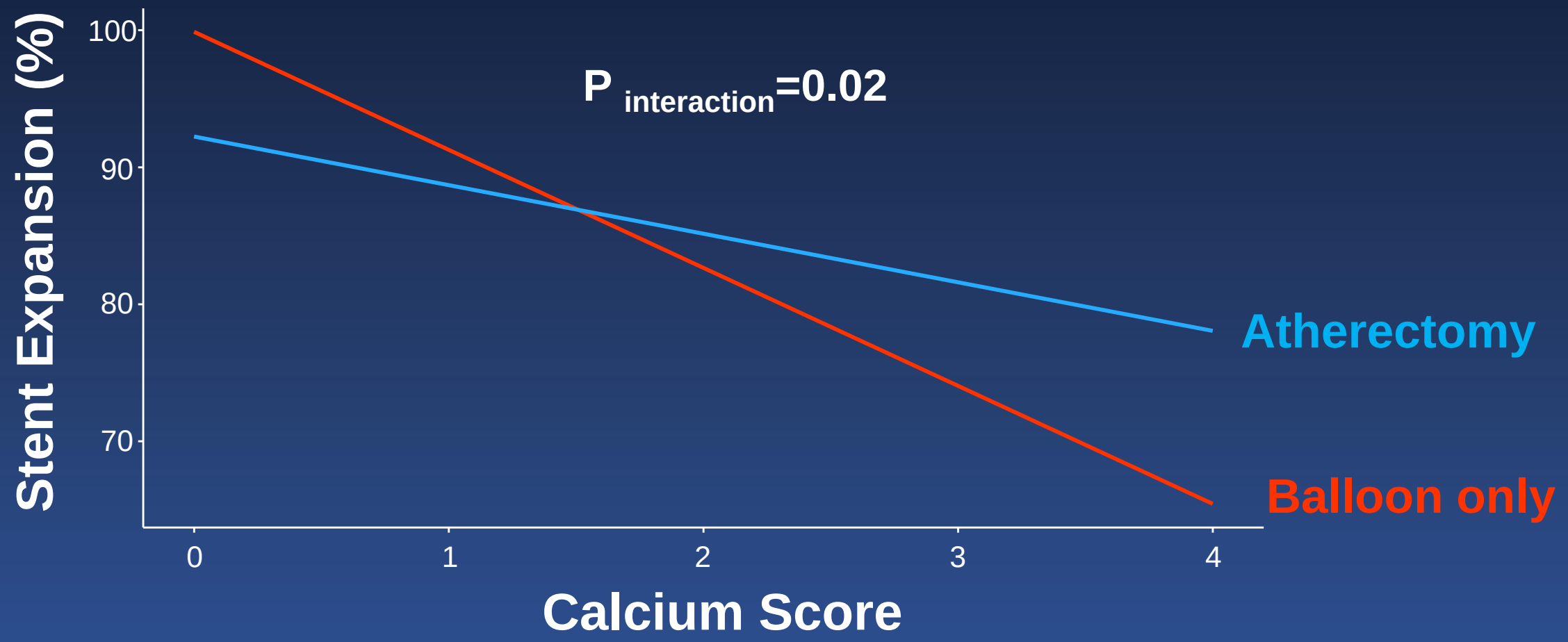

Zhang et al. Circ Interv 2021: 14e010296.

Calcified Nodule

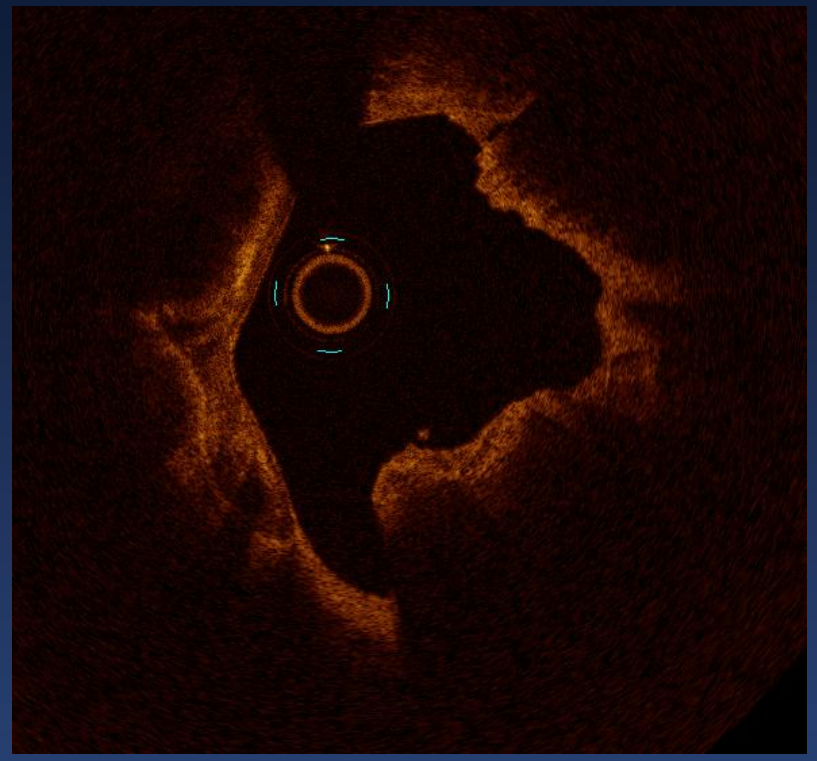

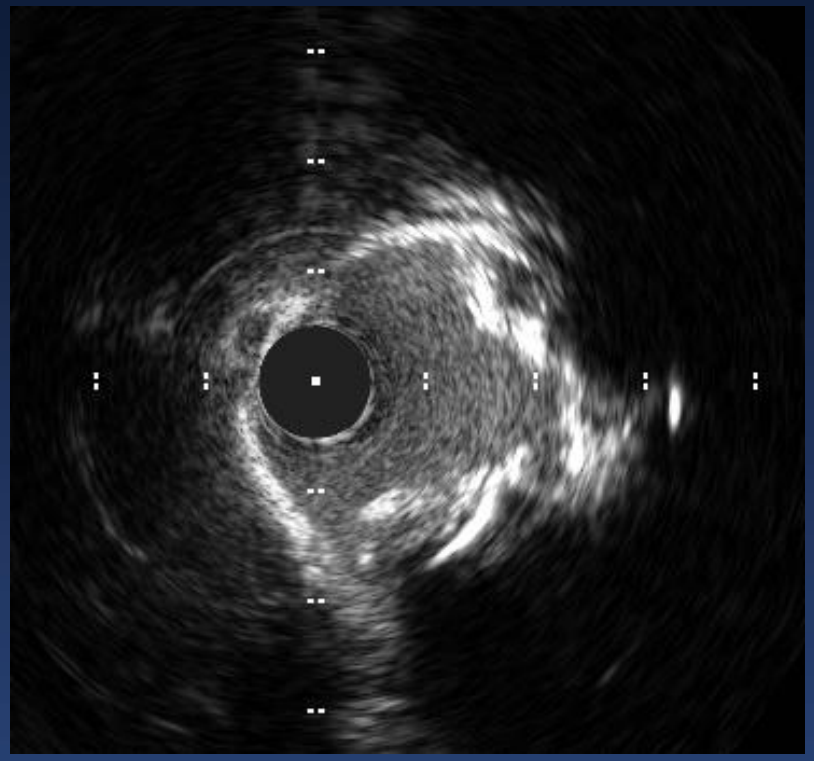

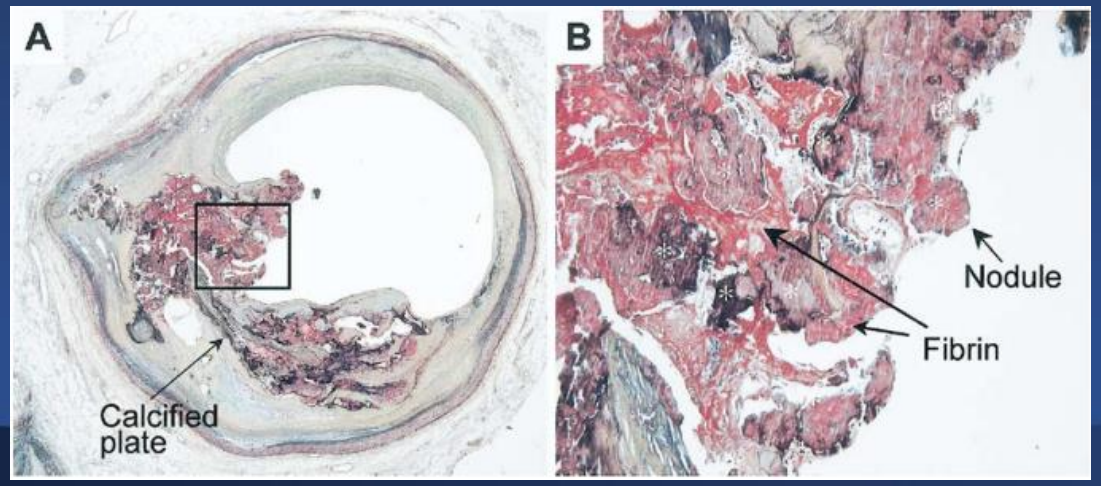

Virmani R et al. J Am Coll Cardiol 18;47:C13-8.

87 y.o. Male. Progressive Angina, CKD (Cre=1.7 mg/dL), Severe MR, 3 vessel disease

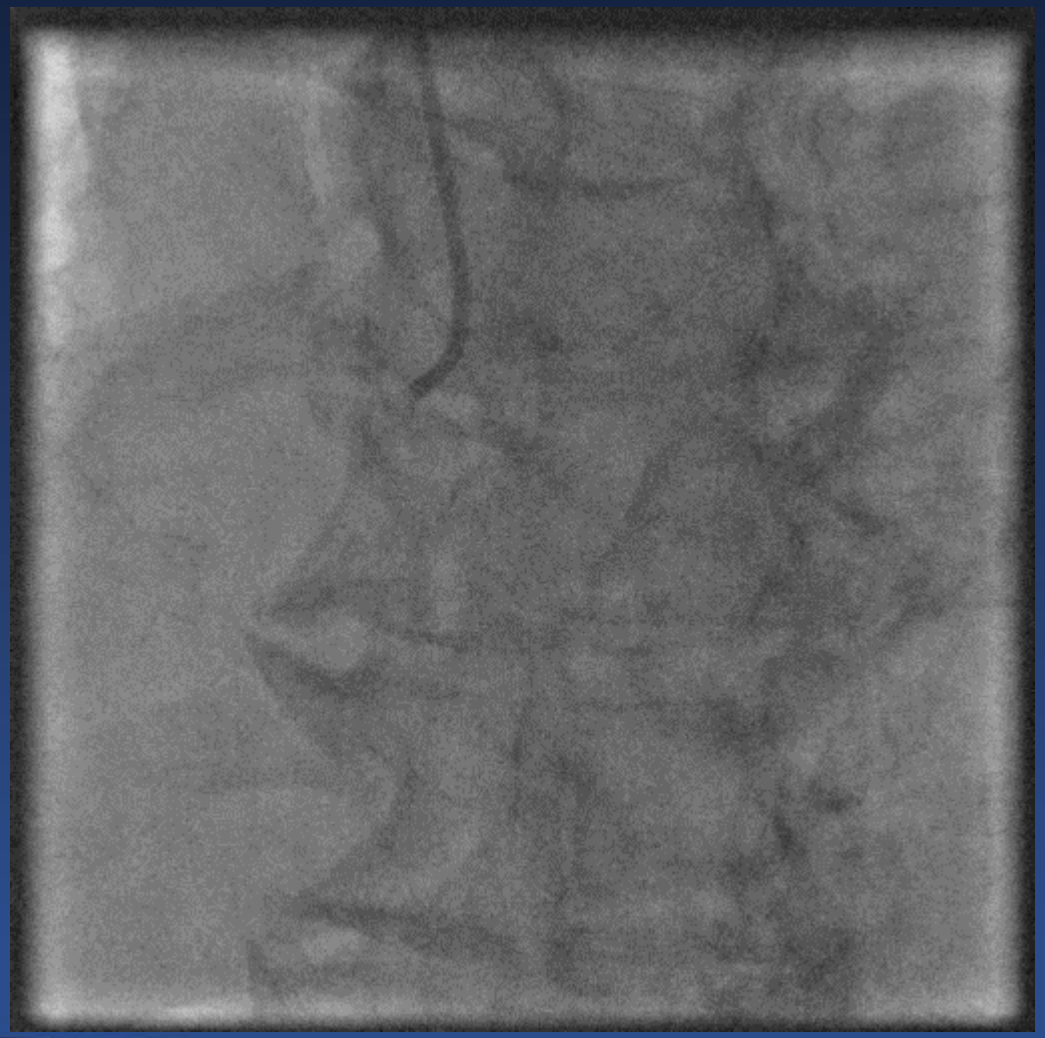

Final

2 Months Later

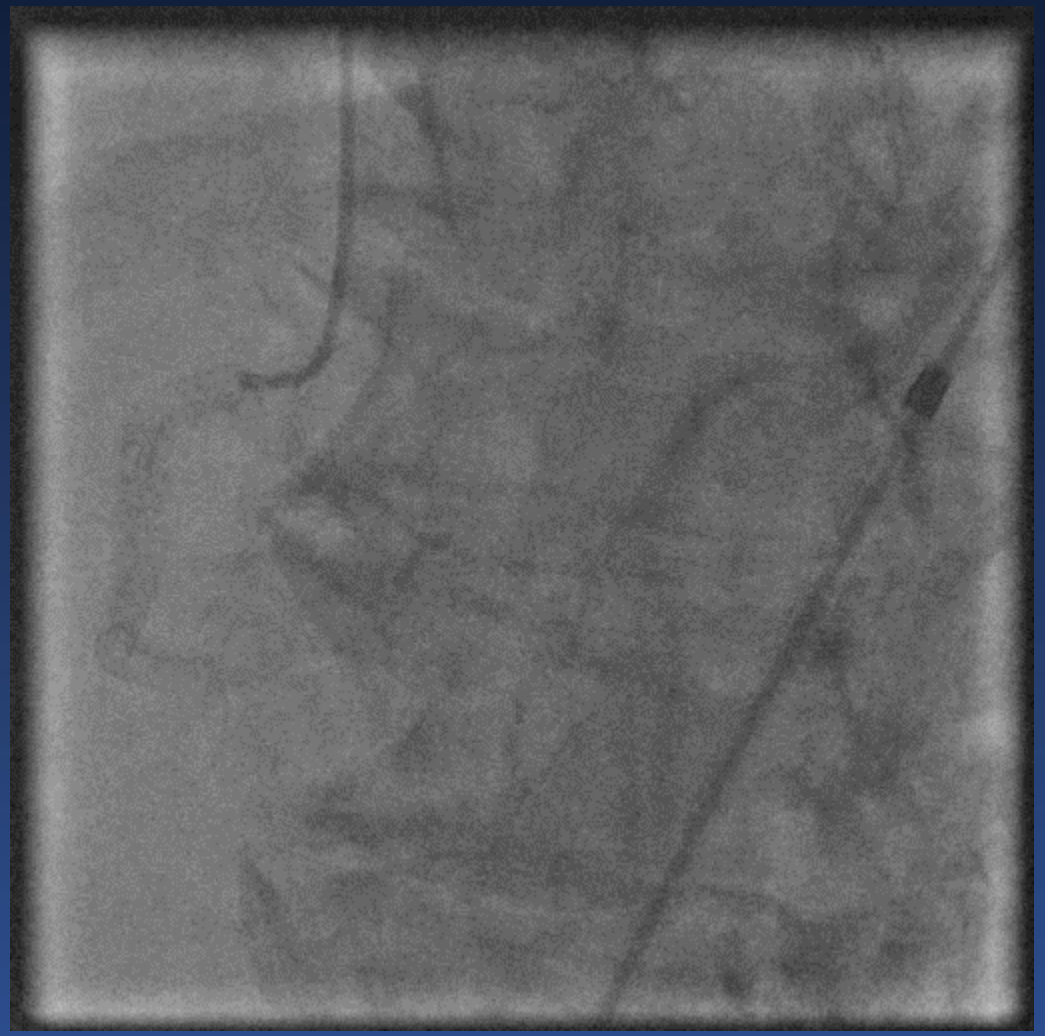

Serial IVUS Findings at Calcified Nodule

Index Post Rota/Balloon

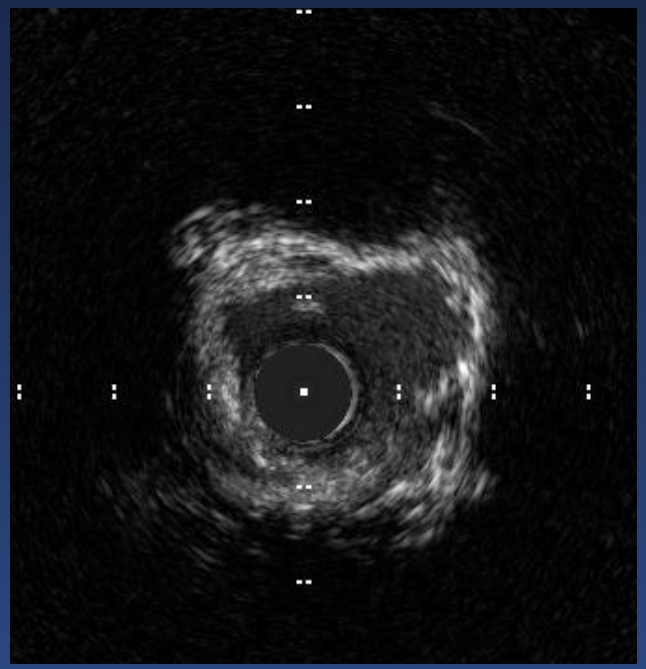

Index Final

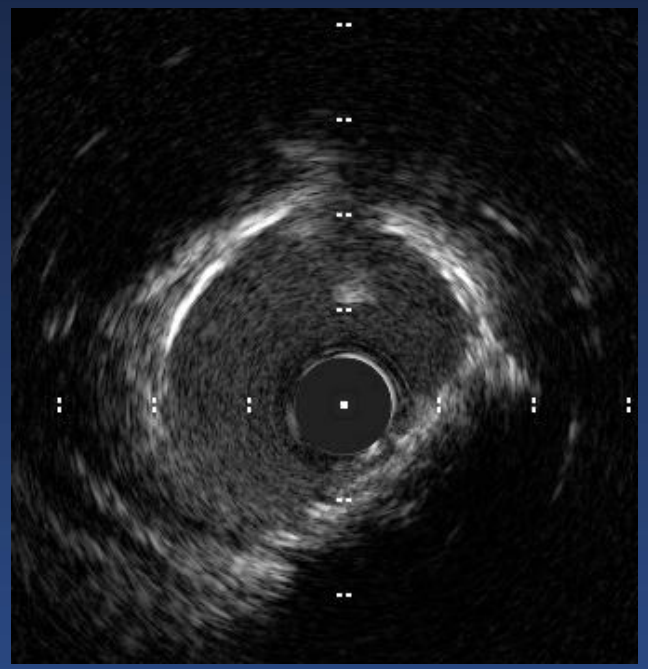

Minimum Stent Area=6.6mm^2

2 Months Later

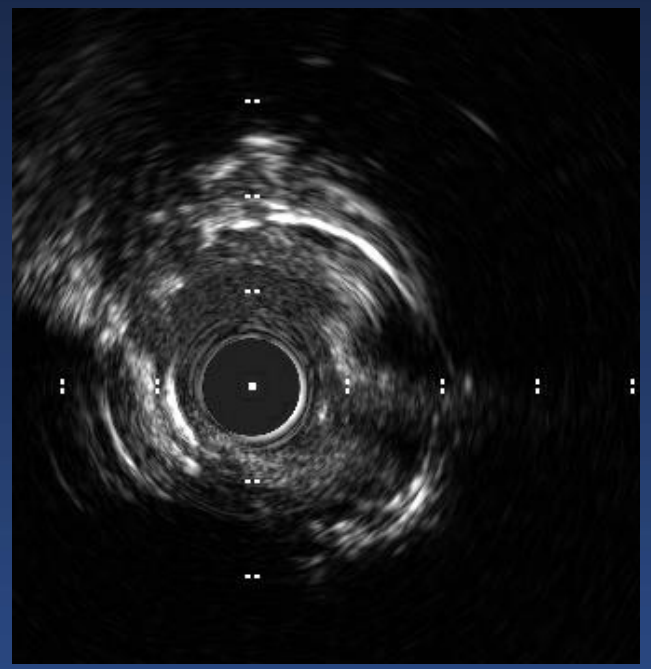

Outcomes after pts with ACS and IVUS-CN were treated with newer-generation DES

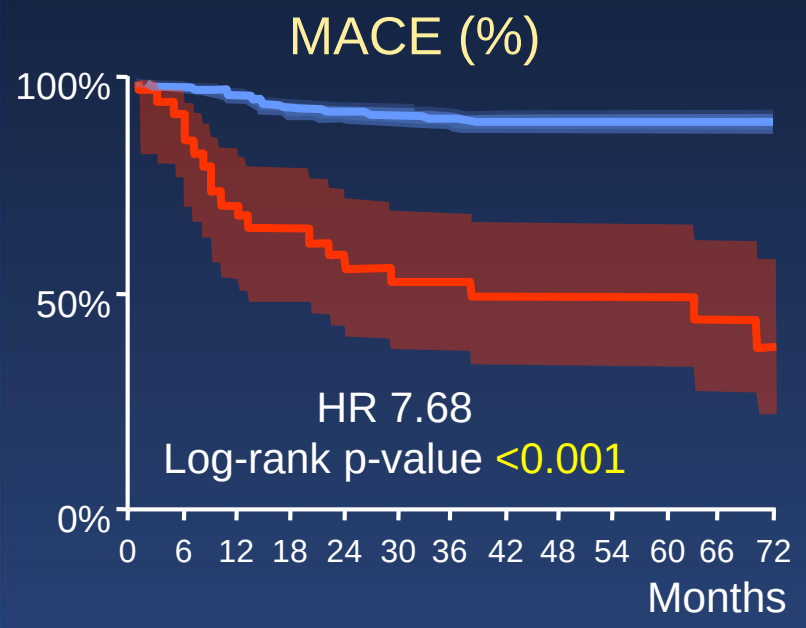

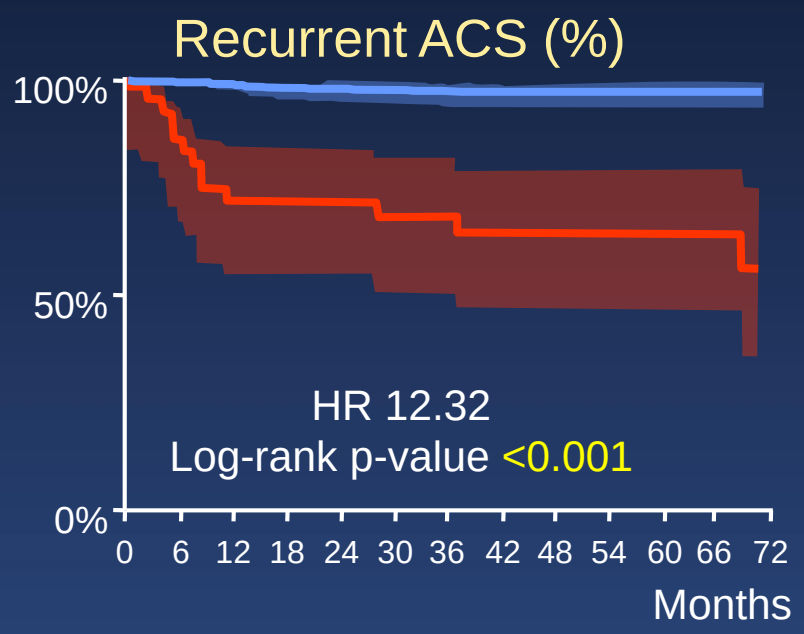

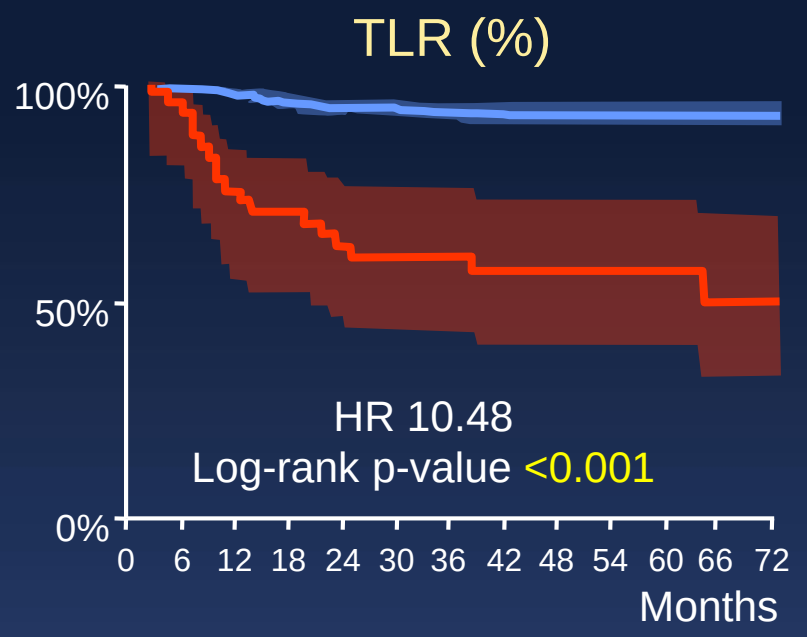

- CN in 5.3% (35/657) of pts presenting with ACS.
- Pts with a CN more likely had hypertension, CKD (eGFR<60), hemodialysis, and PCI history.
- Independent predictors of MACE: smoking, lower eGFR, no statins, smaller MSA, and CN

CN+

CN -

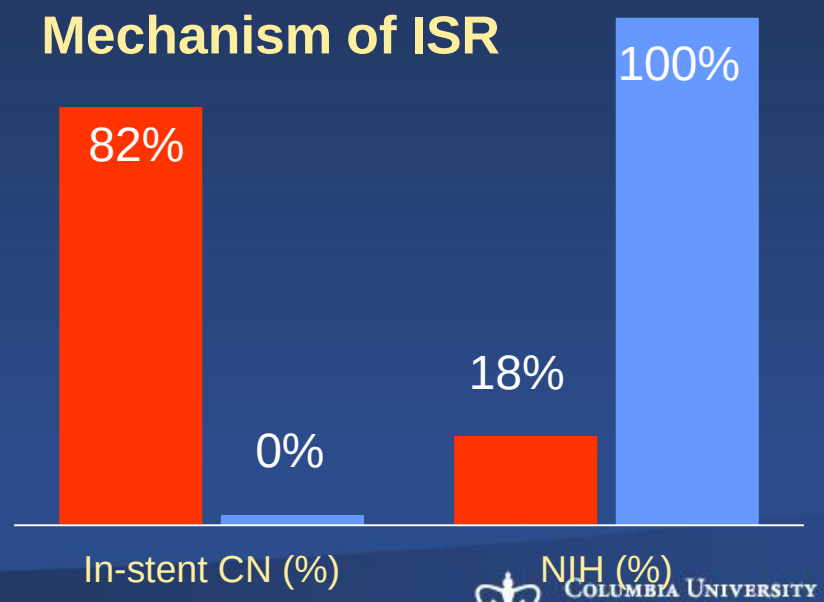

Cardiovascular Research Foundation

Sugane et al. Atherosclerosis 2021;318:70-75

Columbia University Medical Center
NewYork-Presbyterian

Case Reports of Re-protruding Calcified Nodule

- Hinge motion in RCA
- Accompanying stent fracture
- MI presentation at event
- Recurrent ISR
- Early ISR from index procedure
- Hemodialysis patients

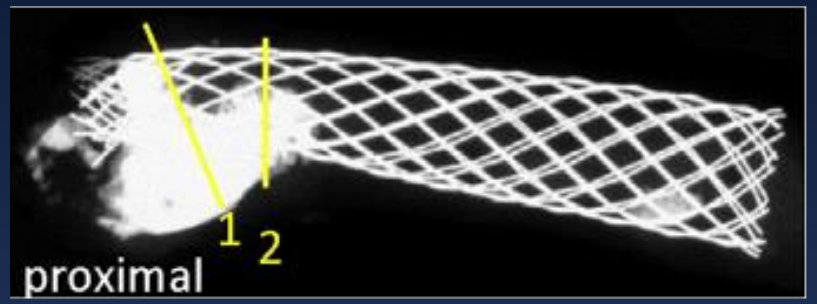

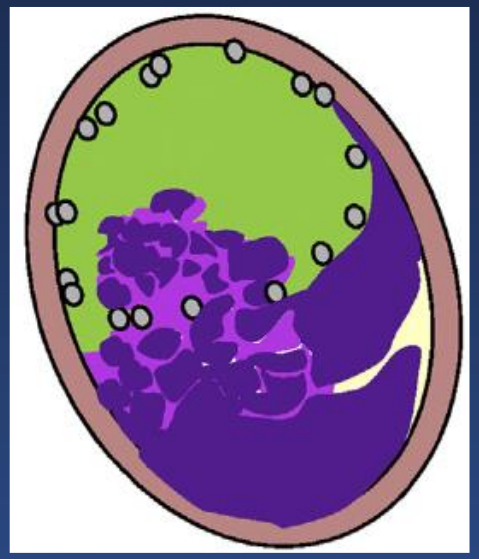

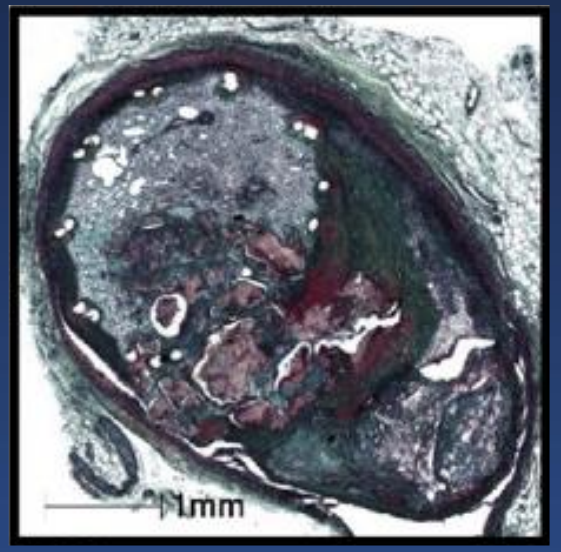

Nakano H, et al. JACC case Rep 2020 in press, Yumoto K et al. Cardiovasc Interv Ther 2018; 33:169-70. Kawai K et al. J Cardiol Cases 2019; 19:12-4. Kaihara T, et al. Cardiovas Revasc Med 2020 E-pub of print, McCutcheon K, et al. CCI 2020. E-pub of print, Mori H, et al. JACC Interv 2016 9, e125-6.

Shockwave - Lithotripsy -

Baseline | **Post Lithoplasty** | **Final**

3.6mm RVD
87.6% stenosis
37.5mm length

4.0mm
Lithoplasty

4.0% stenosis
Acute gain 3.1
Stent length 40.5mm

Cardiovascular Research Foundation

Ali Z, et al. JACC Img 2017;10:897-906.

Columbia University Medical Center
NewYork-Presbyterian

Shockwave - Lithotripsy -

Pre	Post-Lisotripsy	Post-Stent
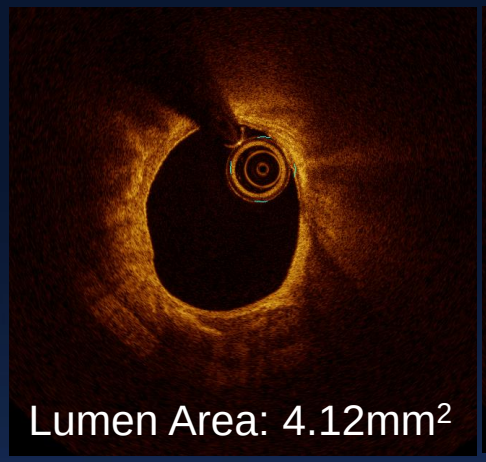 Lumen Area: 4.12mm^2	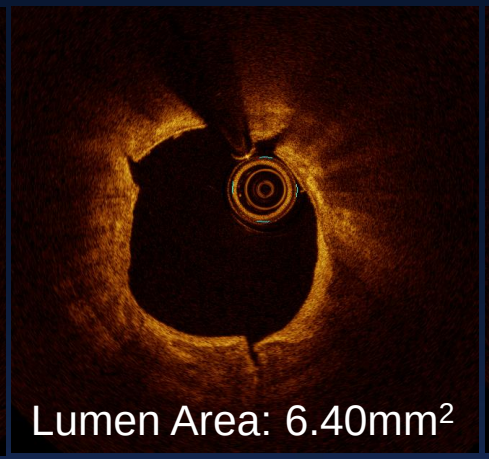 Lumen Area: 6.40mm^2	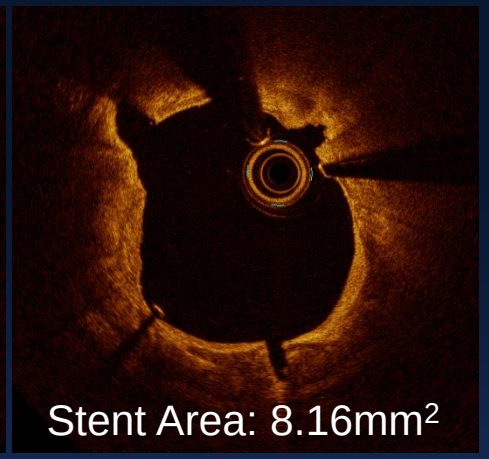 Stent Area: 8.16mm^2
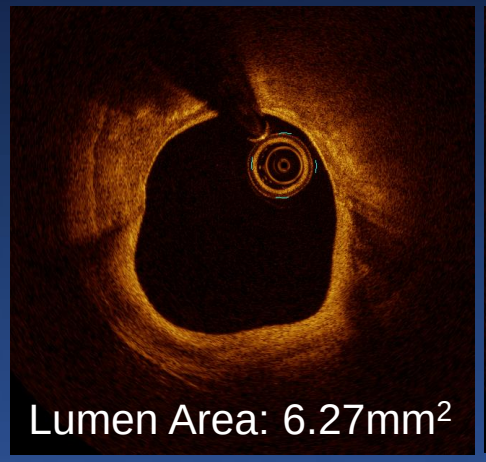 Lumen Area: 6.27mm^2	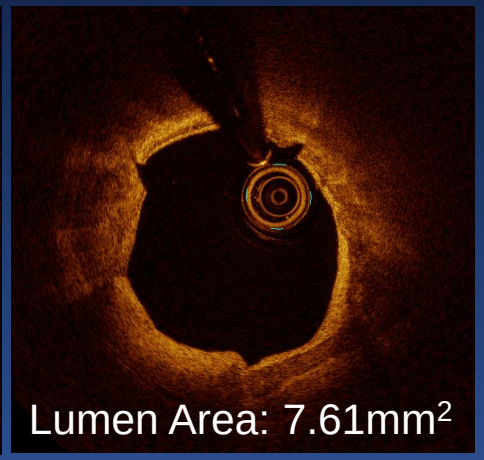 Lumen Area: 7.61mm^2	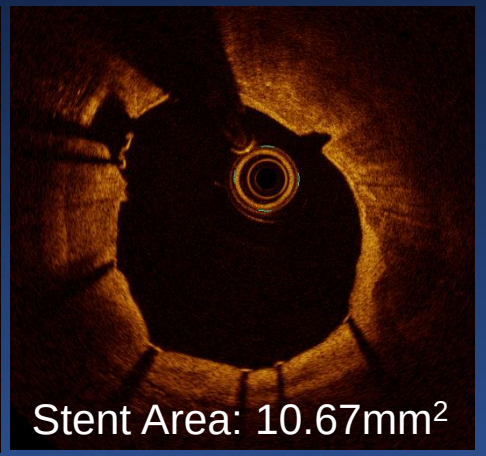 Stent Area: 10.67mm^2

Ali Z, et al. JACC Img 2017;10:897-906.

Prevalence of Neoatherosclerosis (NA) in 2nd GEN DES

Neointimal calcified plate

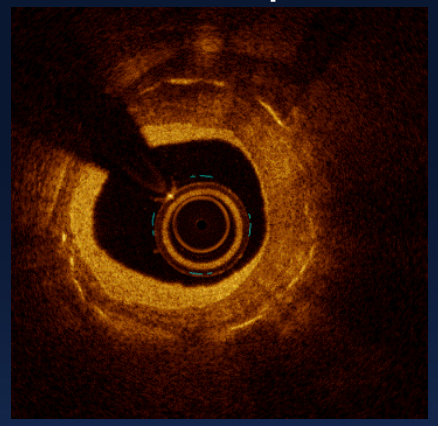

Neointimal calcified nodule

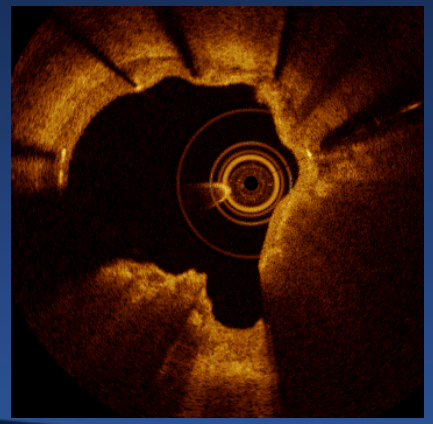

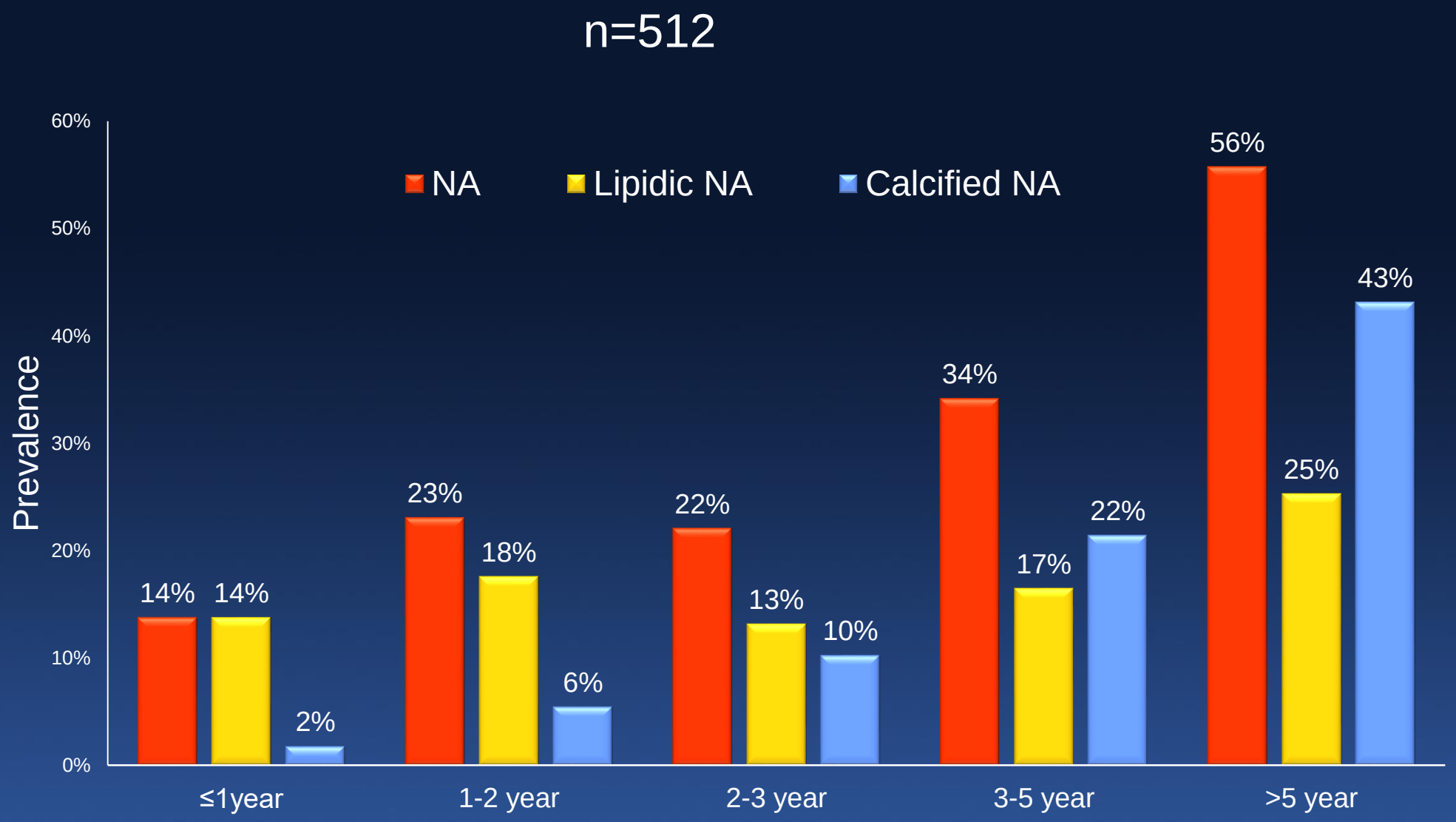

Chen Z et al. ACC2019

Neointimal Calcium Predict New Stent Expansion

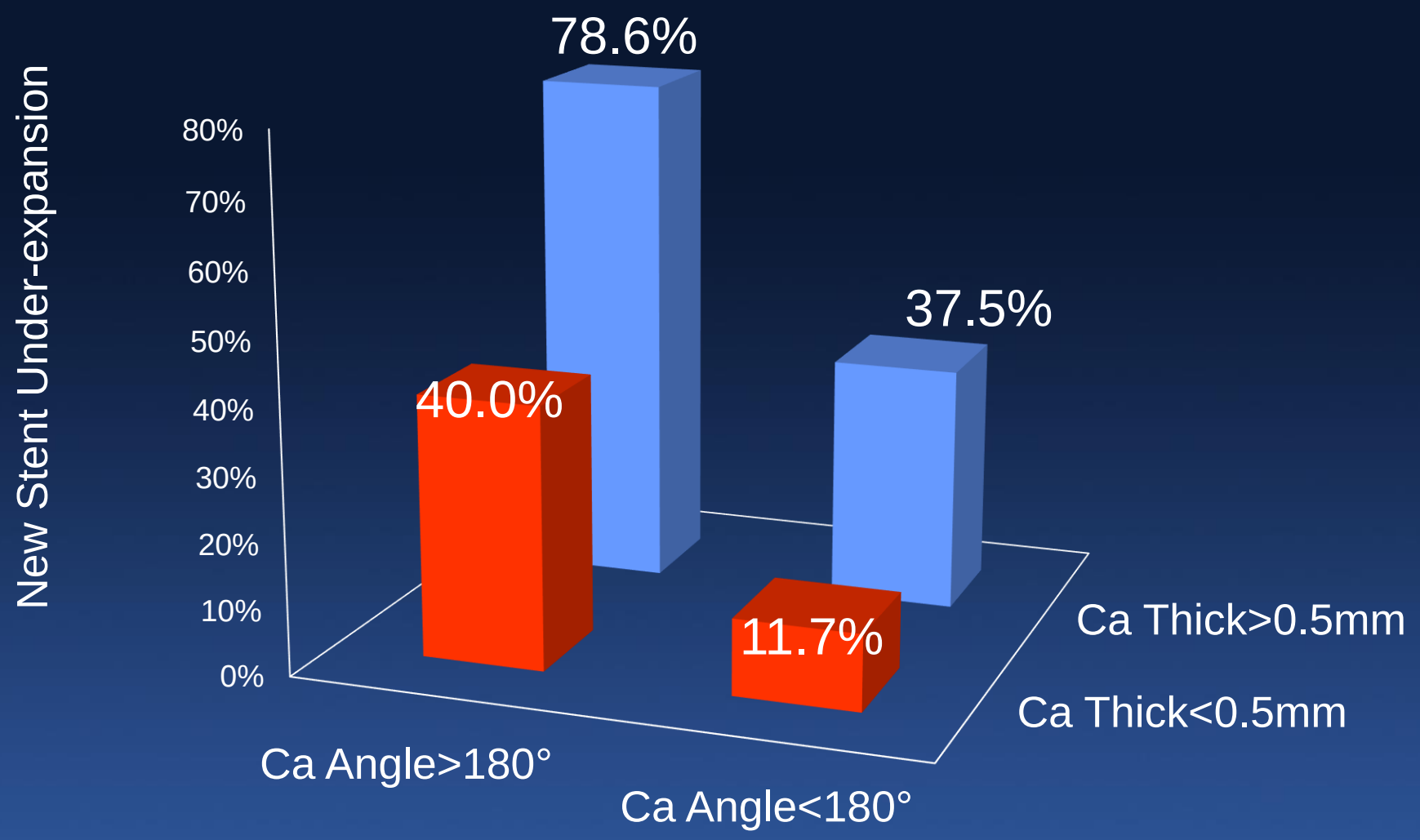

Yin D et al. Eurointervention 2020 16 e335-343.

Summary

1. OCT or IVUS calcium score has been established. The importance is to recognize “total volume of calcium”.
2. Angiographic evaluation is also important to start with.
3. We need to understand the best treatment for calcified nodule.