The Global CTO Crossing Algorithm

Dr Eugene B Wu

Disclosures:

Director of APCTO Club Ltd which receives research funding from Asahi Intecc, OrbusNeich, Abiomed.

Honorarium for Consultant fees - Boston Scientific, Abbott Vascular.

Introduction.

There is improvement of success rates of CTO PCI from 50-70% to 85-94% over the past 10 years.[1]

This is due to technological advances as well as the adoption of an algorithmic approach to CTO PCI.

1. Patel VG et al. Angiographic Success and Procedural Complications in Patients Undergoing Percutaneous Coronary Chronic Total Occlusion Interventions. JACC: Cardiovascular Interventions. 2013;6(2):128-136. doi:10.1016/j.jcin.2012.10.011; Lamelas et al. In-stent chronic total occlusion angioplasty in the LATAM-CTO registry. Catheter Cardiovasc Interv. 2021;97(1). doi:10.1002/ccd.2893; Konstantinidis et al. Temporal Trends in Chronic Total Occlusion Interventions in Europe: 17 626 Procedures From the European Registry of Chronic Total Occlusion. Circ Cardiovasc Interv. 2018;11(10). doi:10.1161/CIRCINTERVENTIONS.117.006229; Wu EB et al. Retrograde Versus Antegrade Approach for Coronary Chronic Total Occlusion in an Algorithm-Driven Contemporary Asia-Pacific Multicentre Registry: Comparison of Outcomes. Heart Lung Circ. 2020;29:894-903. Tajti et al. The Hybrid Approach to Chronic Total Occlusion Percutaneous Coronary Intervention: Update From the PROGRESS CTO Registry. J Am Coll Cardiol Intv 2018;11:1325-1335.

In 2012 Brilakis et al published the first CTO algorithm, the Hybrid algorithm[2].

Subsequently, in 2017, Harding et al published the APCTO algorithm[3].

In 2018 Wu et al published the APCTO retrograde algorithm[4] and Ge J published the China CTO Club algorithm[5].

This was followed in 2019 by the Japanese Algorithm by Tanaka et al[6], and the EuroCTO Club consensus document by Galassi et al[7].

2. Brilakis ES et al. A Percutaneous Treatment Algorithm for Crossing Coronary Chronic Total Occlusions. J Am Coll Cardiol Intv 2012;5:367-379.
3. Harding SA et al. A new algorithm for crossing chronic total occlusions from the Asia Pacific Chronic Total Occlusion Club. J Am Coll Cardiol Intv 2017;10:2135–43.
4. Wu EB et al. The retrograde algorithm for chronic total occlusion from the asia pacific chronic total occlusion Club. Asian Interv 2018;4:98-107.
5. Ge J, on behalf of CTOCC. Strategic roadmap of percutaneous coronary intervention for chronic total occlusions. Cardiology Plus 2018:3:30-37.
6. Tanaka H et al. A Novel Algorithm for Treating Chronic Total Coronary Artery Occlusion. J Am Coll Cardiol. 2019;74(19):2392-2404. doi:10.1016/j.jacc.2019.08.1049.
7. Galassi AR, et al. Percutaneous recanalisation of chronic total occlusions: 2019 consensus document from the EuroCTO Club. EuroIntervention. 2019;15:198-208.

A. Hybrid.

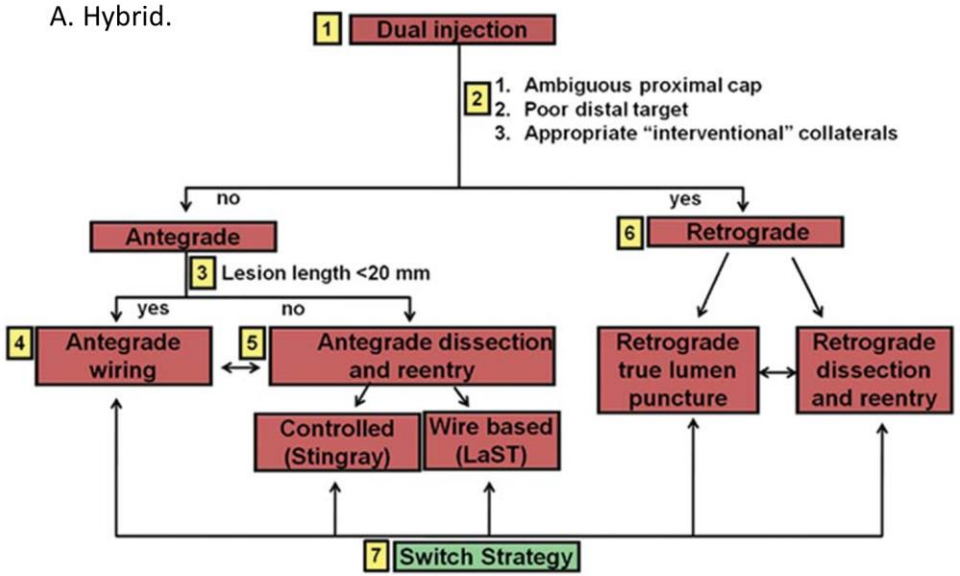

C. CTO Club China.

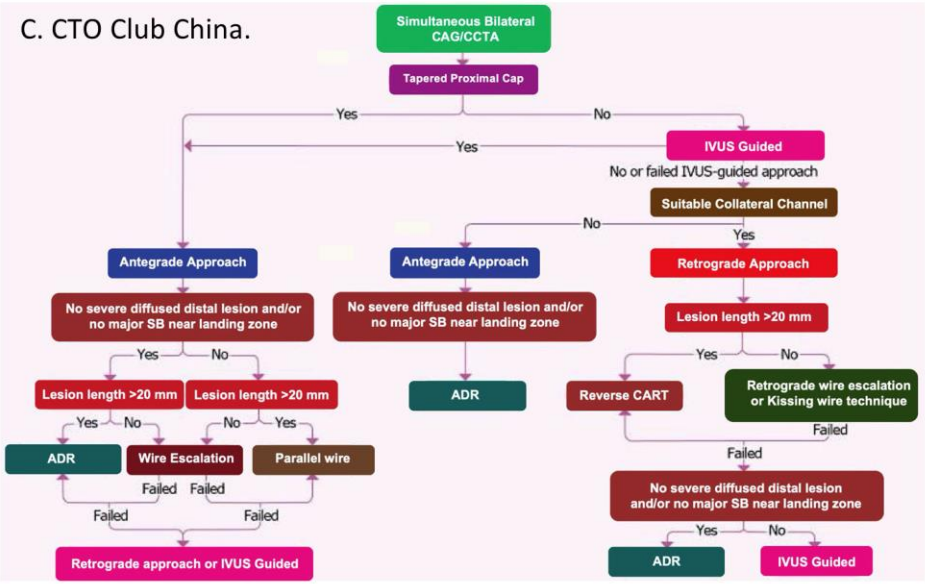

B. APCTO

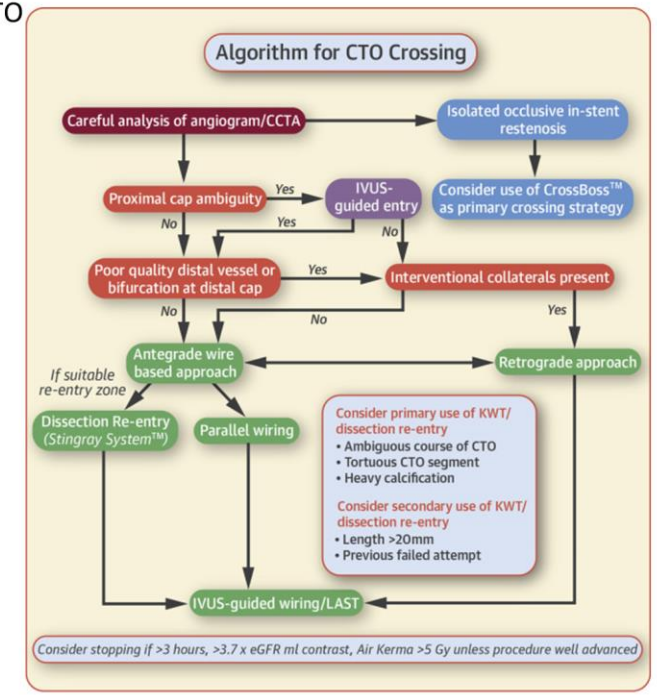

D. Euro CTO Club.

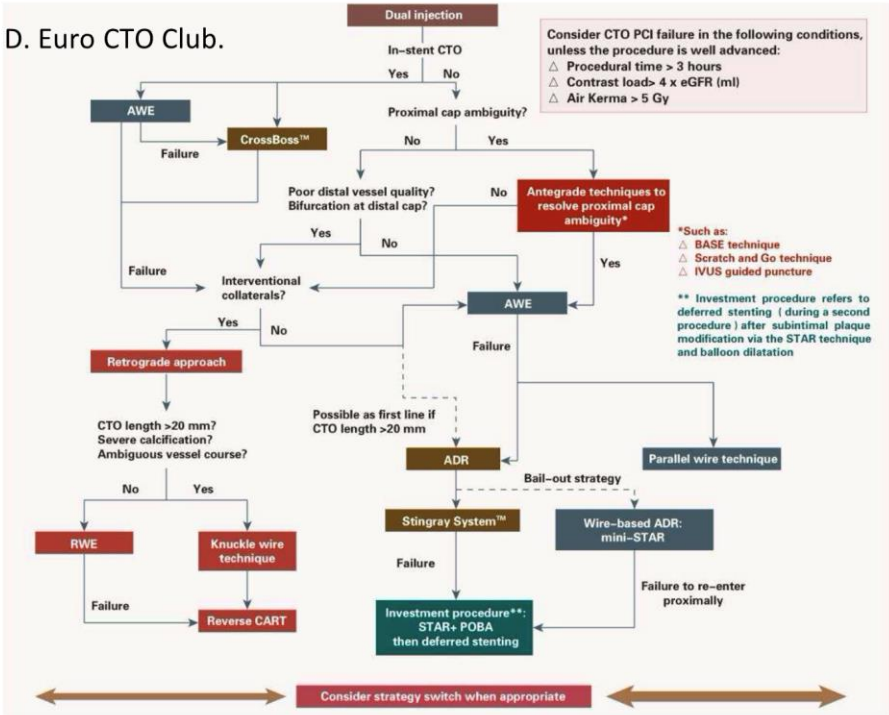

	Hybrid	Asia Pacific	EuroCTO	Chinese CTO	J-CTO	GLOBAL
1. Dual angiography	+	+	+	+	+	+
1b. CCTA		+		+		+
1. Careful angiographic review	+	+	+	+	+	+
ISR	No specific recommendation	+ (CrossBoss)	+ (CrossBoss)	+ (CrossBoss)	Antegrade	No specific recommendation.
3b. Solutions to proximal ambiguity	Retrograde	Retrograde, IVUS	Retrograde, IVUS, move the cap	Retrograde, IVUS, move the cap	Retrograde	IVUS, retrograde, move the cap
1. Poor distal vessel or bifurcation	+ (Retrograde)	+ (Retrograde)	+ (Retrograde)	+ (Retrograde)		+ (Retrograde)
1. Retrograde option	+	+	+	+	+	+
1. Antegrade wiring strategies	ADR for length ≥20 mm	AWE, Parallel wiring Primary ADR for ambiguous CTO course, tortuous CTO segment, heavy calcification Secondary ADR: length ≥20 mm, prior failed attempt	AWE preferred – ADR possible as first line if length ≥20 mm	ADR preferred if severe diffuse distal disease and major side branch near landing zone	ADR or parallel wiring after AWE failure	AWE preferred
1. Retrograde	Ambiguous proximal cap, poor distal vessel + INTERV COLLATERALS	Ambiguous proximal cap (if IVUS fails), poor distal vessel + INTERV COLLATERALS	Ambiguous proximal cap, poor distal vessel + INTERV COLLATERALS	Ambiguous proximal cap + no or failed IVUS-guided approach + INTERV COLLATERALS	Reattempt, CTO length of ≥20 mm, and no stump + INTERV COLLATERALS	Ambiguous proximal cap, poor distal vessel + FEASIBLE RETROGRADE OPTION

	Hybrid	Asia Pacific	EuroCTO	Chinese CTO	J-CTO	GLOBAL
7b. RDR preferred over RWE	Length ≥20 mm	Length ≥15 mm	Length ≥20 mm Severe calcification Ambiguous vessel course	Length ≥20 mm		Length ≥20 mm Severe calcification Ambiguous vessel course
7c. RDR preferred technique	Reverse CART	Contemporary reverse CART	Reverse CART	Reverse CART		Reverse CART
1. Change	+	+	+	+	After 20 min wire manipulation time	+
1. Investment			+			+
1. When to stop	Air kerma >10 Gray	Procedure duration >3 hours Air kerma >5 Gray Contrast >3.7x eGFR	Procedure duration >3 hours Air kerma >5 Gray Contrast >4x eGFR		Procedure duration >3 hours	Procedure duration >3 hours Air kerma >5 Gray Contrast >3x eGFR Complication & fatigue.

4 main authors drafted an initial algorithm and then 125 authors from 50 countries wrote the paper.

Eugene B Wu, M.D. a, Emmanouil S Brilakis, M.D., Ph.D. b, Kambis Mashayekhi. M.D. c, Etsuo Tsuchikane. M.D., Ph.D. d, Khaldoon Alaswad, M.D. e, Mario Araya, M.D. f, Alexandre Avran, M.D. g, Lorenzo Azzalini, M.D., M.Sc., Ph.D. h, Avtandil M. Babunashvili, M.D. i, Baktash Bayani, M.D. j, Michael Behnes, M.D. k, Ravinay Bhindi, M.D. l, Nicolas Boudou, M.D. m, Marouane Boukhris, M.D. n, Nenad Z. Bozinovic, M.D. o, Leszek Bryniarski, M.D. p, Alexander Bufe, M.D. q, Christopher E. Buller, M.D. r, M. Nicholas Burke, M.D. b, Achim Buttner, M.D. s, Pedro Cardoso, M.D. t, Mauro Carlino, M.D. u, Ji-Yan Chen, M.D. v, Evald Hoej Christiansen, M.D. w, Antonio Colombo, M.D. x, Kevin Croce, M.D., Ph.D. y, Felix Damas de los Santos, M.D., M.E.T. z, Tony de Martini, M.D. aa, Joseph Dens, M.D., Ph.D. ab, Carlo di Mario, M.D. ac, Kefei Dou, M.D. ad, Mohaned Egred, M.D. ae, Basem Elbarouni, M.D. af, Ahmed M. ElGuindy, M.D. ag, Javier Escaned, M.D. ah, Sergey Furkalo, M.D. ai, Andrea Gagnor, M.D. aj, Alfredo R. Galassi, M.D. ak, Roberto Garbo, M.D. al, Gabriele Gasparini, M.D. am, Junbo Ge, M.D. an, Lei Ge, M.D. an, Pravin Kumar Goel, M.D. ao, Omer Goktekin, M.D. ap, Nieves Gonzalo, M.D. aq, Luca Grancini, M.D. ar, Allison Hall, M.D. as, Franklin Leonardo Hanna Quesada, M.D. at, Colm Hanratty, M.D. au, Stefan Harb, M.D. av, Scott A. Harding, M.D. aw, Raja Hatem, M.D. ax, Jose P.S. Henriques, M.D. ay, David Hildick-Smith, M.D. az, Jonathan M. Hill, M.D. ba, Angela Hoye, M.D. bb, Wissam Jaber, M.D. bc, Farouc A. Jaffer, M.D., Ph.D. bd, Yangsoo Jang, M.D. be, Risto Jussila, M.D. bf, Artis Kalnins, M.D. bg, Arun Kalyanasundaram, M.D., M.PH. bh, David E. Kandzari, M.D. bi, Hsien-Li Kao, M.D. bj, Dimitri Karmpaliotis, M.D., Ph.D. bk, Hussien Heshmat Kassem, M.D., Ph.D. bl, Jaikirshan Khatri, M.D. bm, Paul Knaapen, M.D. bn, Ran Kornowski, M.D. bo, Oleg Krestyaninov, M.D. bp, A. V. Ganesh Kumar, M.D. bq, Pablo Manuel Lamelas, M.D., M.Sc. br, Seung-Whan Lee, M.D. bs, Thierry Lefevre, M.D. bt, Raymond Leung, M.D. bu, Yu Li, M.D. bv, Yue Li, M.D. bw, Soo-Teik Lim, M.D. bx, Sidney Lo, M.D. by, William Lombardi, M.D. bz, Anbukarasi Maran, M.D. ca, Margaret McEntegart, M.D., Ph.D. cb, Jeffrey Moses, M.D. cc, Muhammad Munawar, M.D. cd, Andres Navarro, M.D. ce, Hung M. Ngo, M.D., Ph.D. cf, William Nicholson, M.D. cg, Anja Oksnes, M.D. ch, Goran K. Olivecrona, M.D., Ph.D. ci, Lucio Padilla, M.D. cj, Mitul Patel, M.D. ck, Ashish Pershad, M.D. cl, Marin Postu, M.D. cm, Jie Qian, M.D. cn, Alexandre Quadros, M.D. co, Nidal Abi Rafeh, M.D. cp, Truls Råmunddal, M.D., Ph.D. cq, Vithala Surya Prakasa Rao, M.D. cr, Nicolaus Reifart, M.D., Ph.D. cs, Robert F. Riley, M.D. ct, Stephane Rinfret, M.D. cu, Meruzhan Saghatelyan, M.D. cv, George Sianos, M.D., Ph.D. cw, Elliot Smith, M.D. cx, Anthony Spaedy, M.D. cy, James Spratt, M.D. cz, Gregg Stone, M.D. da, Julian W. Strange, M.D. db, Khalid O. Tammam, M.D., Ph.D. dc, Craig A. Thompson, M.D. dd, Aurel Toma, M.D. de, Jennifer A Tremmel, M.D., M.S. df, Ricardo Santiago Trinidad, M.D. dg, Imre Ungi, M.D., Ph.D. dh, Minh Vo, M.D. di, Vu Hoang Vu, M.D. dj, Simon Walsh, M.D. au,Gerald Werner, M.D. dk, Jaroslaw Wojcik, M.D. dl, Jason Wollmuth, M.D. dm, Bo Xu, M.D. dn, Masahisa Yamane, M.D. do, Luiz F. Ybarra, M.D. dp, Robert W. Yeh, M.D. dq, Qi Zhang, M.D. dr,

CENTRAL ILLUSTRATION The Global Chronic Total Occlusion Crossing Algorithm

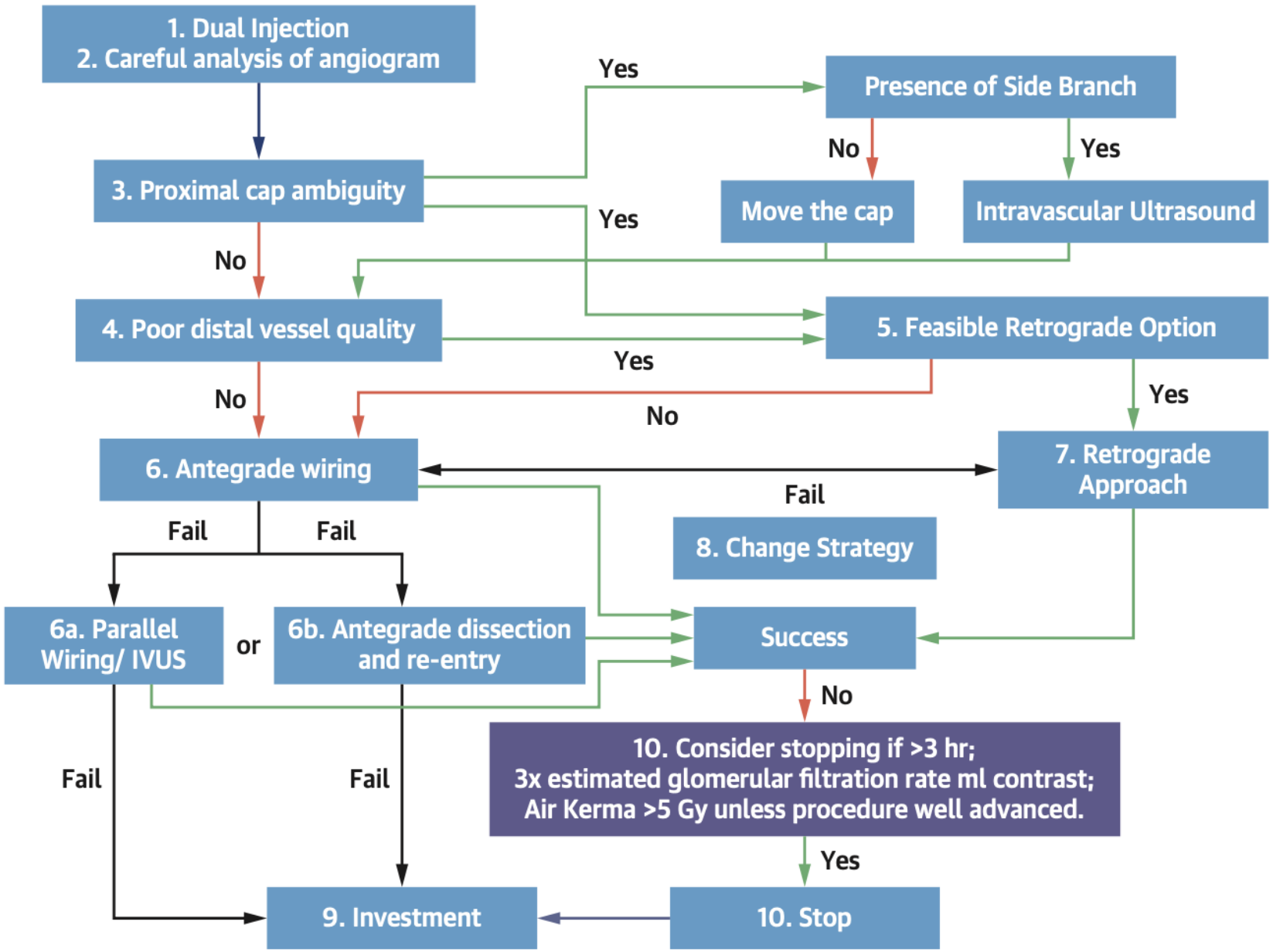

Wu, E.B. et al. J Am Coll Cardiol. 2021;78(8):840-853.

The Global CTO Crossing Algorithm

1. Dual angiography is cornerstone of CTO PCI/ after ic nitro/ CTCA useful.
2. Careful angiographic review / Proximal cap morphology, CTO length and composition, distal vessel quality, and collateral circulation.
3. Approaching proximal cap ambiguity we recommend IVUS, retrograde, move the cap but not stepwise, rather based on anatomy.

Approaching Proximal cap ambiguity

The principle of “anatomy dictates strategy”.

Comparing risks of IVUS guidance vs move the cap vs retrograde, there is a stepwise increase of risk.

However, this stepwise increase of risk should not dictate strategy because anatomy dictates strategy more.

If anatomy allows two strategies to be used, then the lower risk strategy should be used first.

Therefore, in the paper “Instead, the strategy that optimizes safety and increases the likelihood of success should be selected based on the CTO anatomy.”

Proximal cap ambiguity.

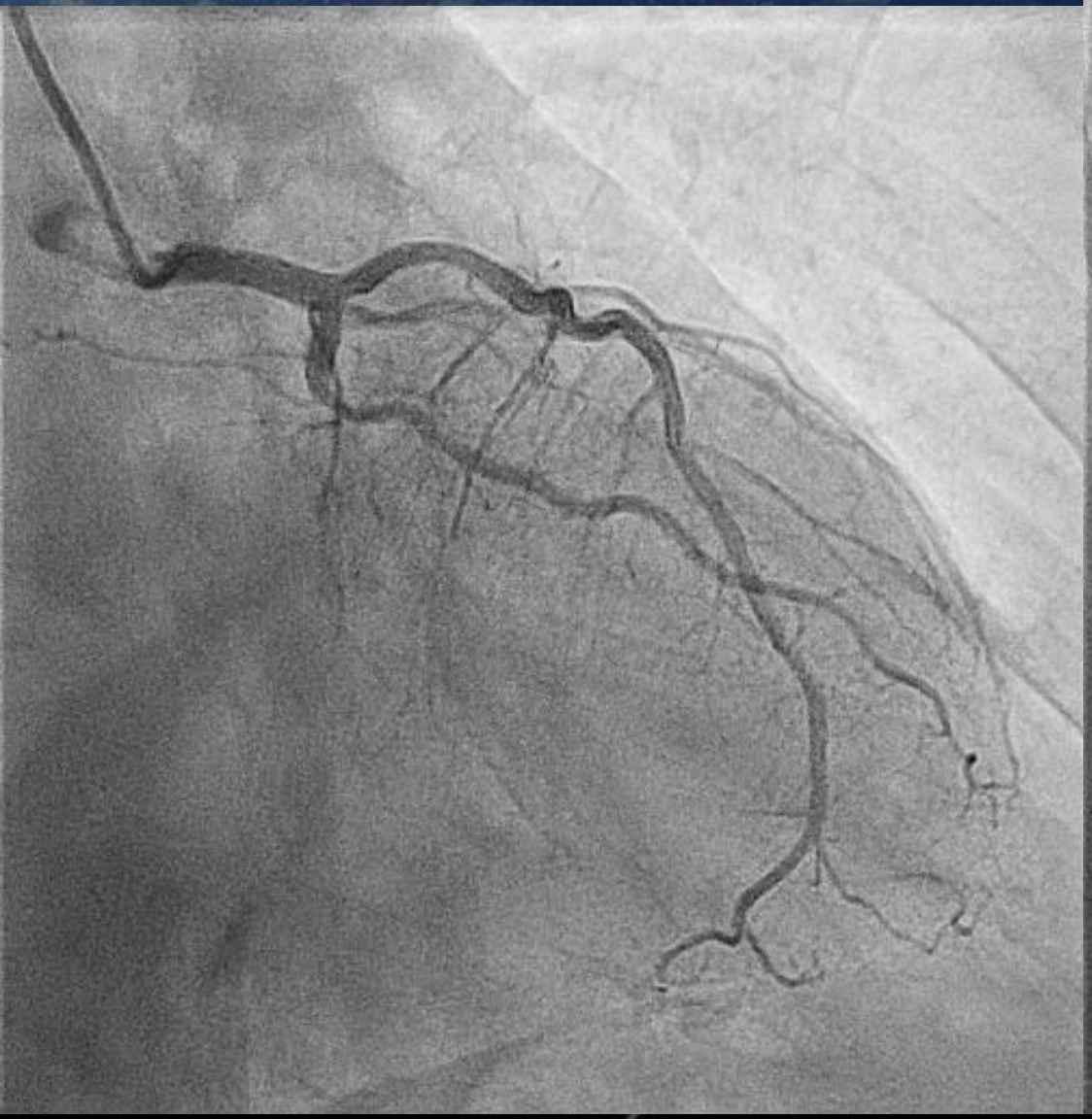

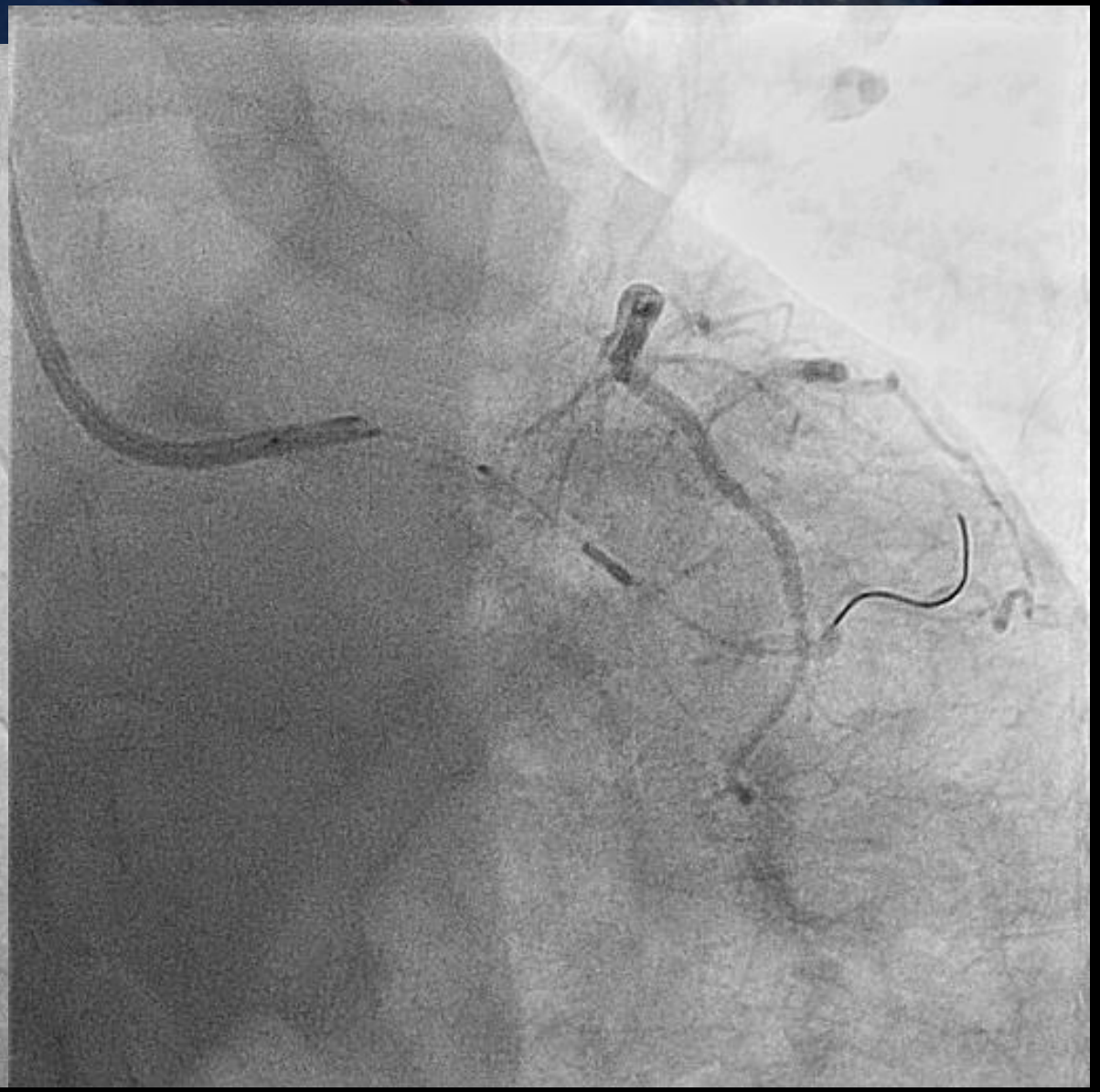

Proximal cap ambiguity.

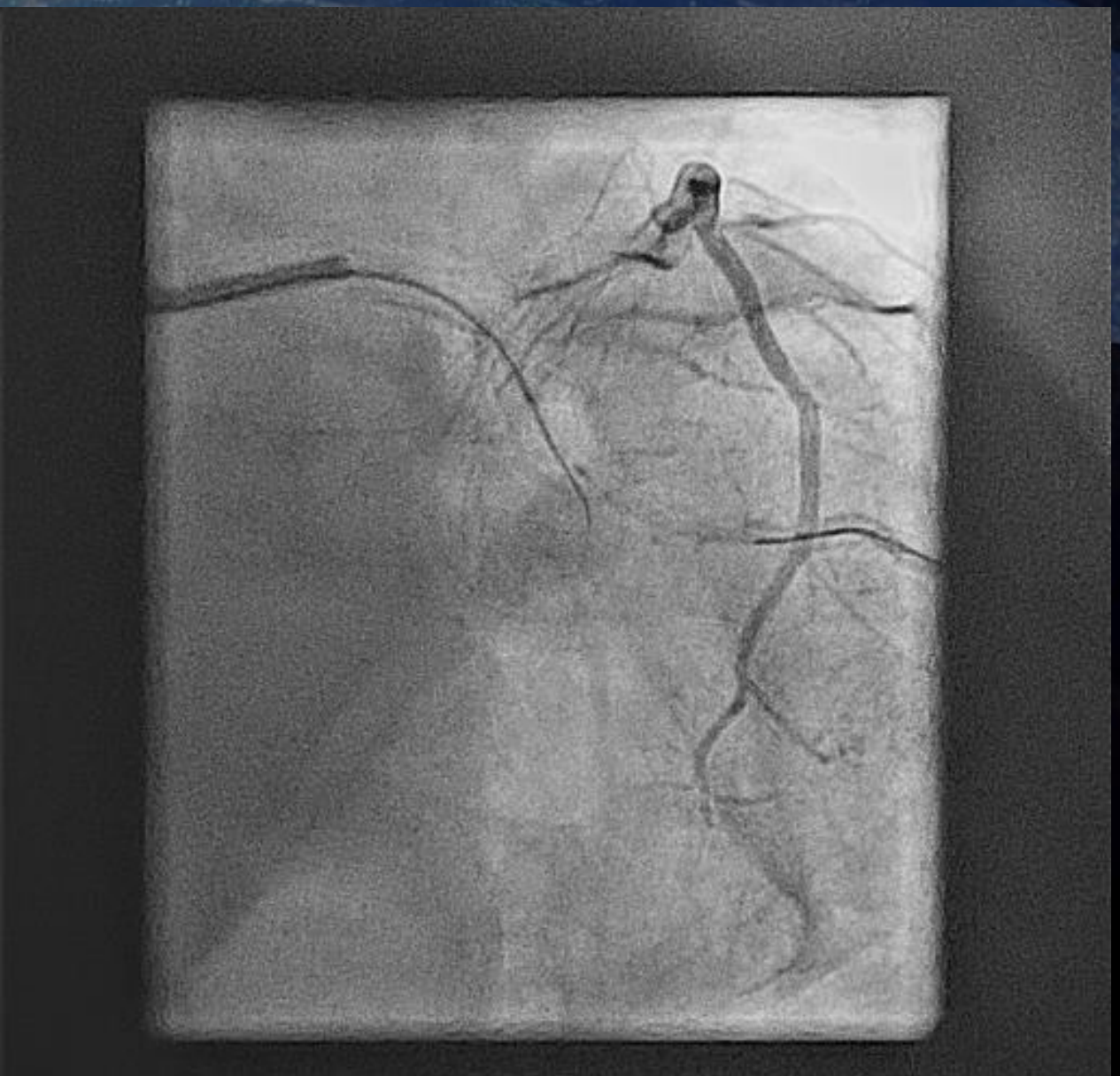

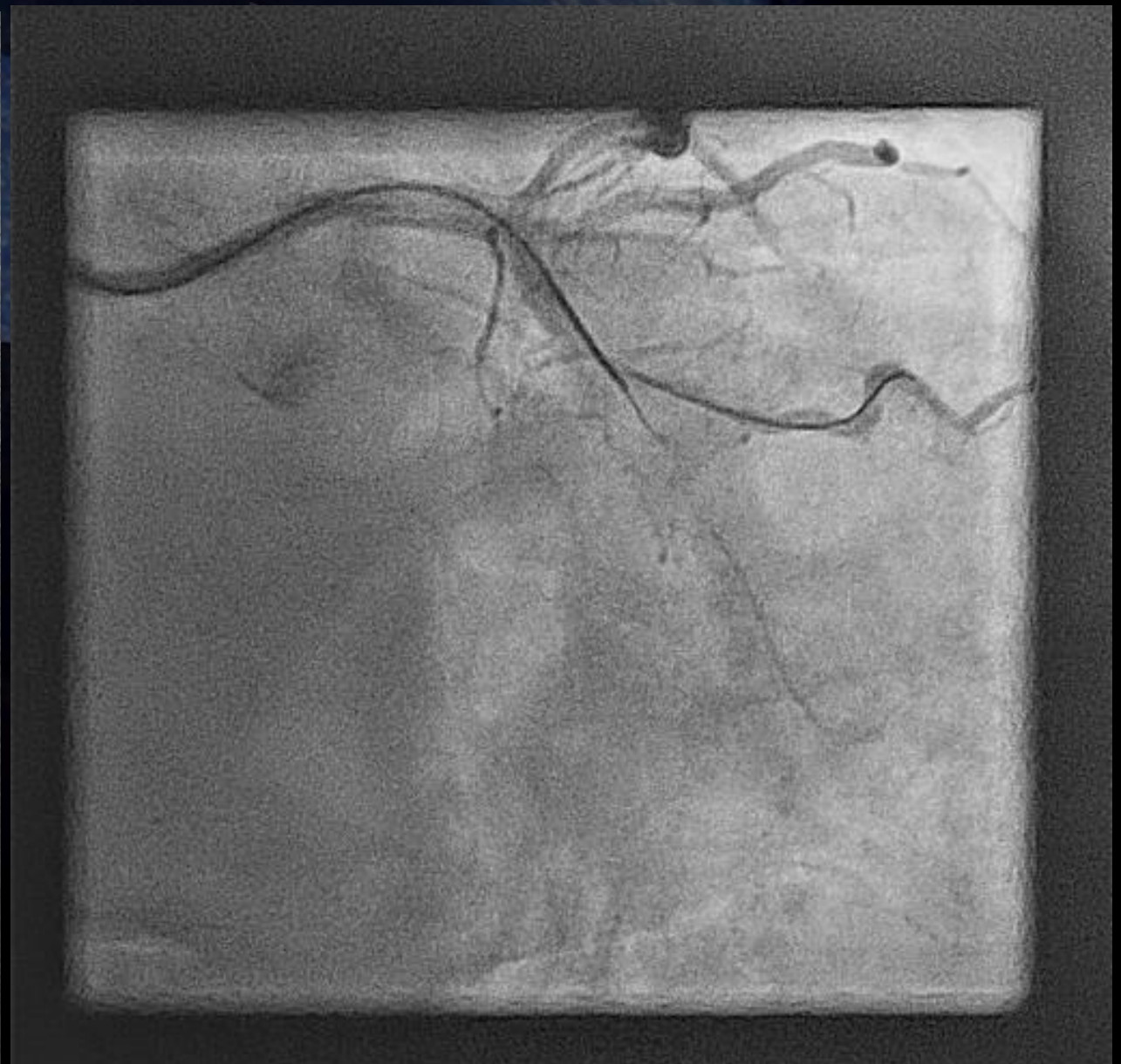

Proximal cap ambiguity.

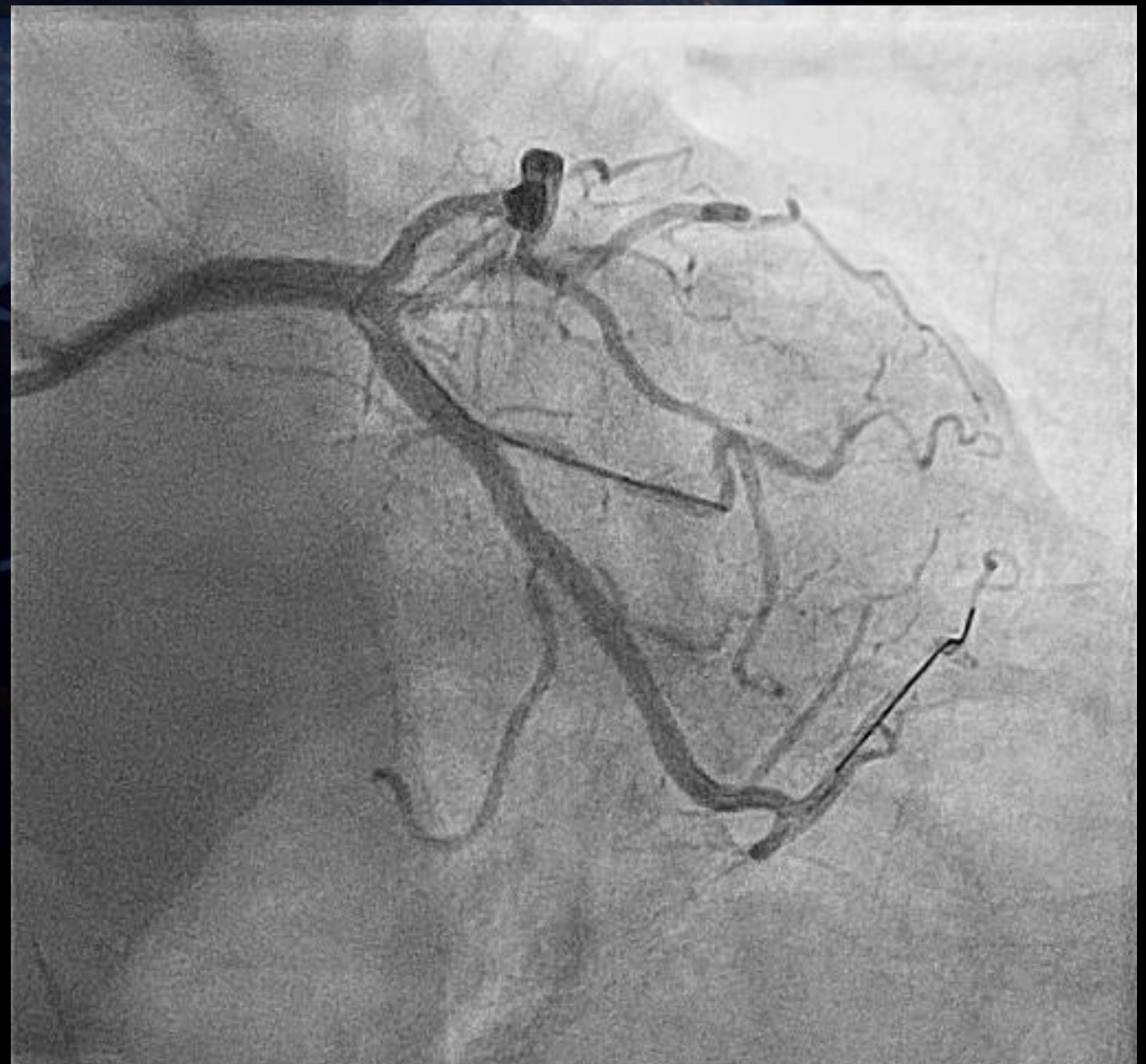

Proximal cap ambiguity.

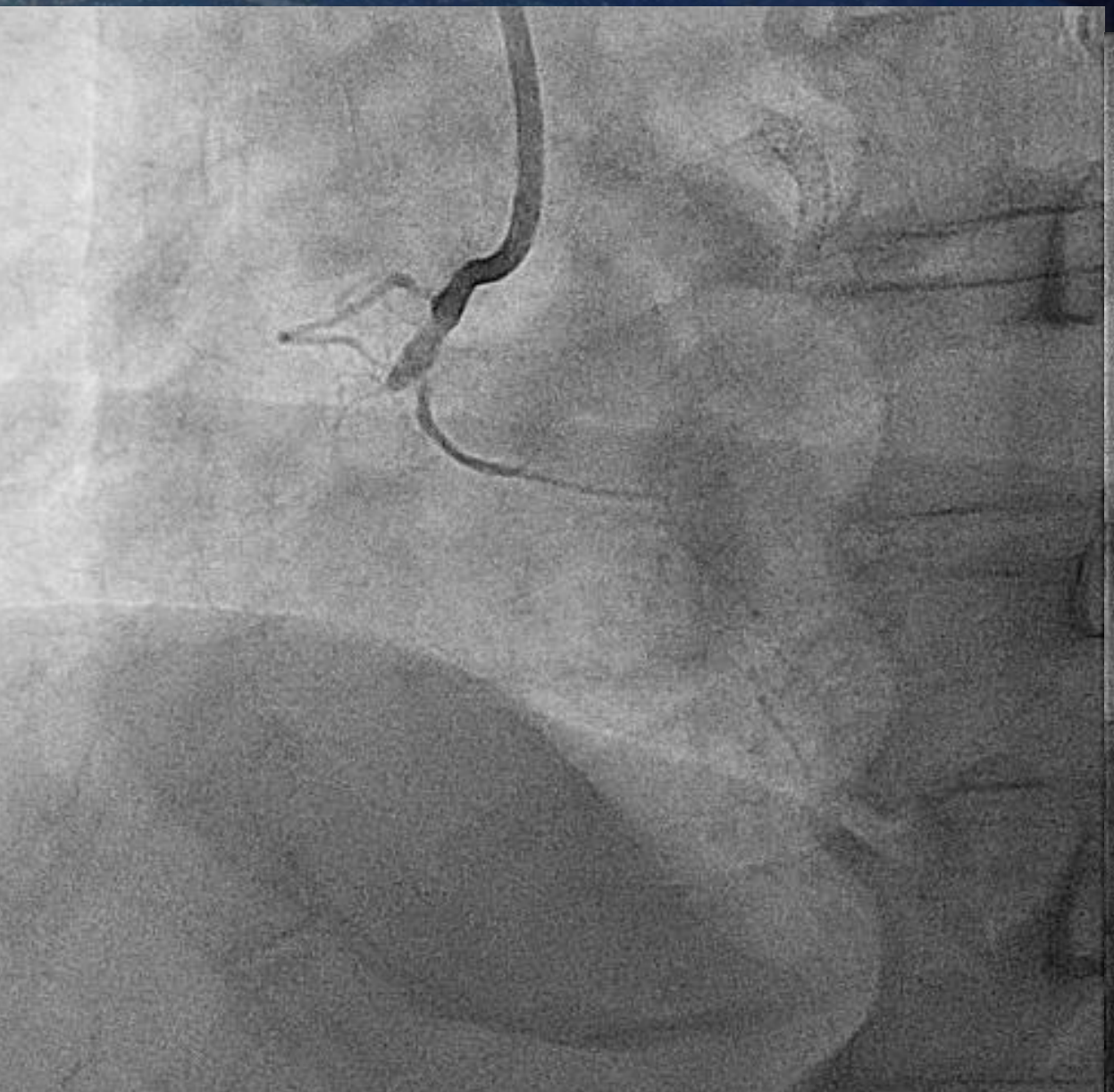

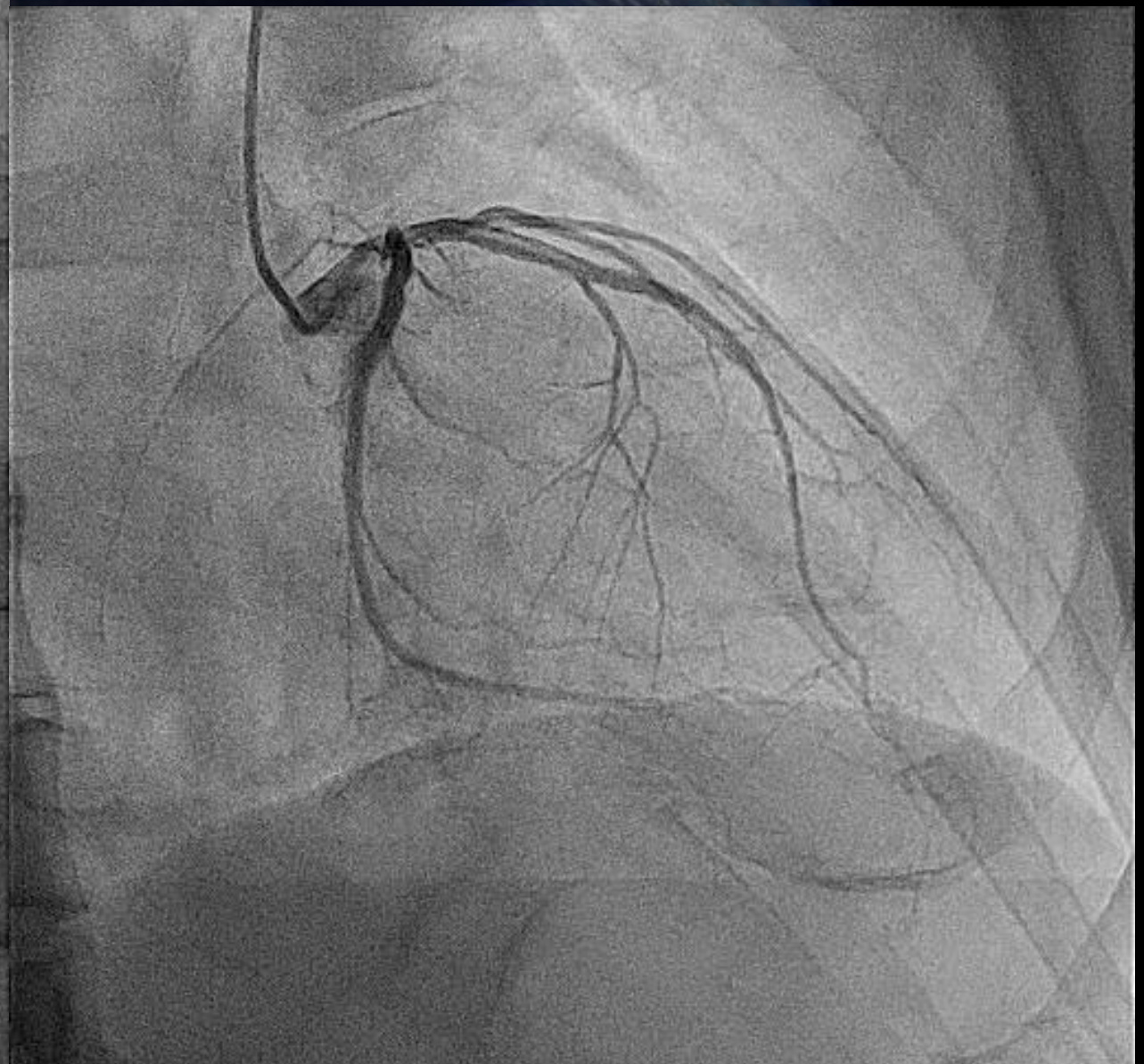

Proximal cap ambiguity.

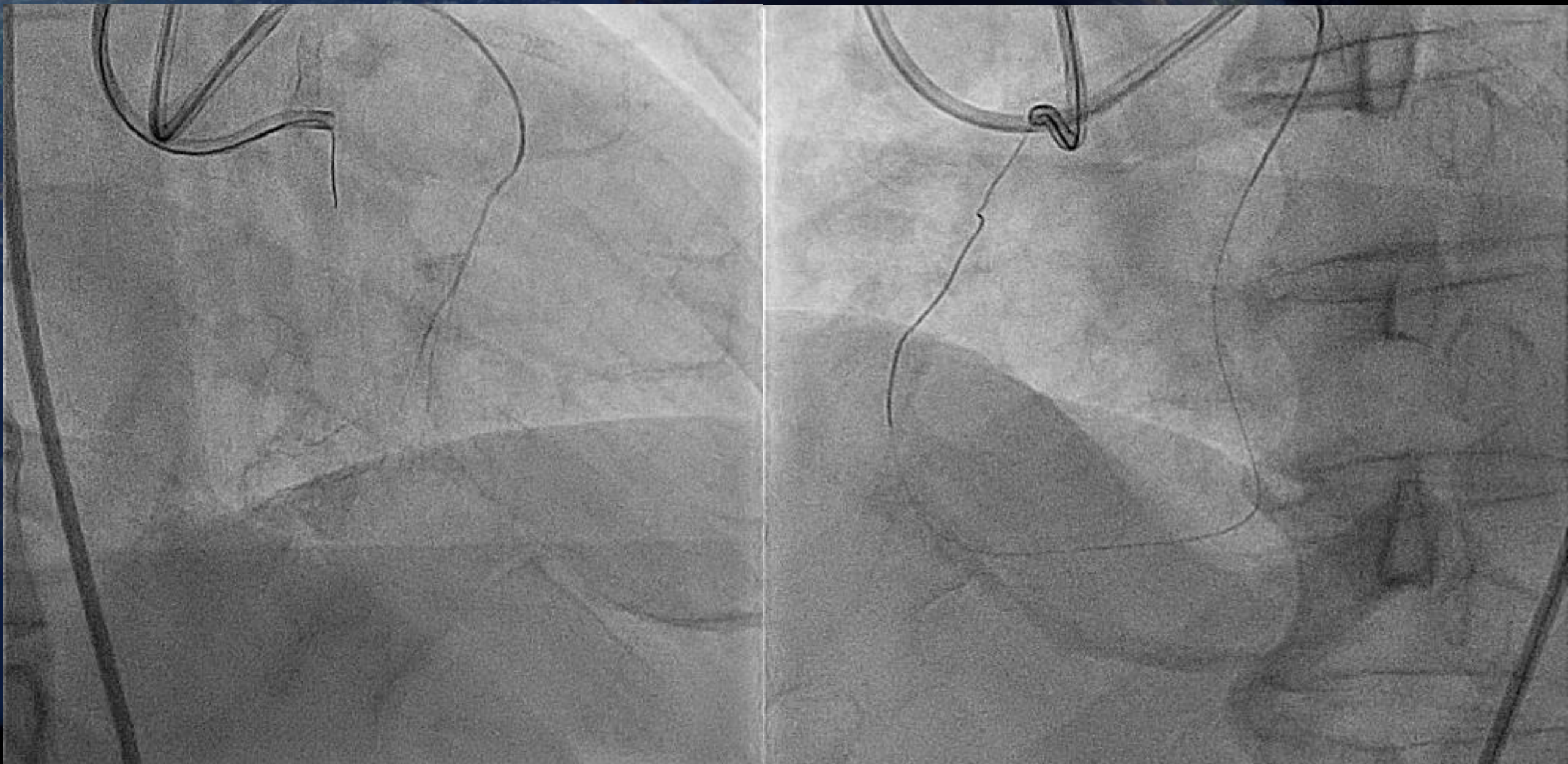

The Global CTO Crossing Algorithm

1. Dual angiography is cornerstone of CTO PCI/ after ic nitro/ CTCA useful.
2. Careful angiographic review / Proximal cap morphology, CTO length and composition, distal vessel quality, and collateral circulation.
3. Approaching proximal cap ambiguity we recommend IVUS, retrograde, move the cap but not stepwise, rather based on anatomy.
4. Approaching poor distal vessel quality or bifurcation in the distal cap. Recommendations for retrograde approach, IVUS check, Dual lumen catheter to access sidebranch.
5. Feasible retrograde options. Including grafts. Recommendation of septals > epicardials due to risks.
6. Antegrade wiring strategies. ADR: ≥20 mm occlusion length, calcification, tortuosity, and presence of an appropriate reentry zone of large caliber and without major side branches.

CENTRAL ILLUSTRATION The Global Chronic Total Occlusion Crossing Algorithm

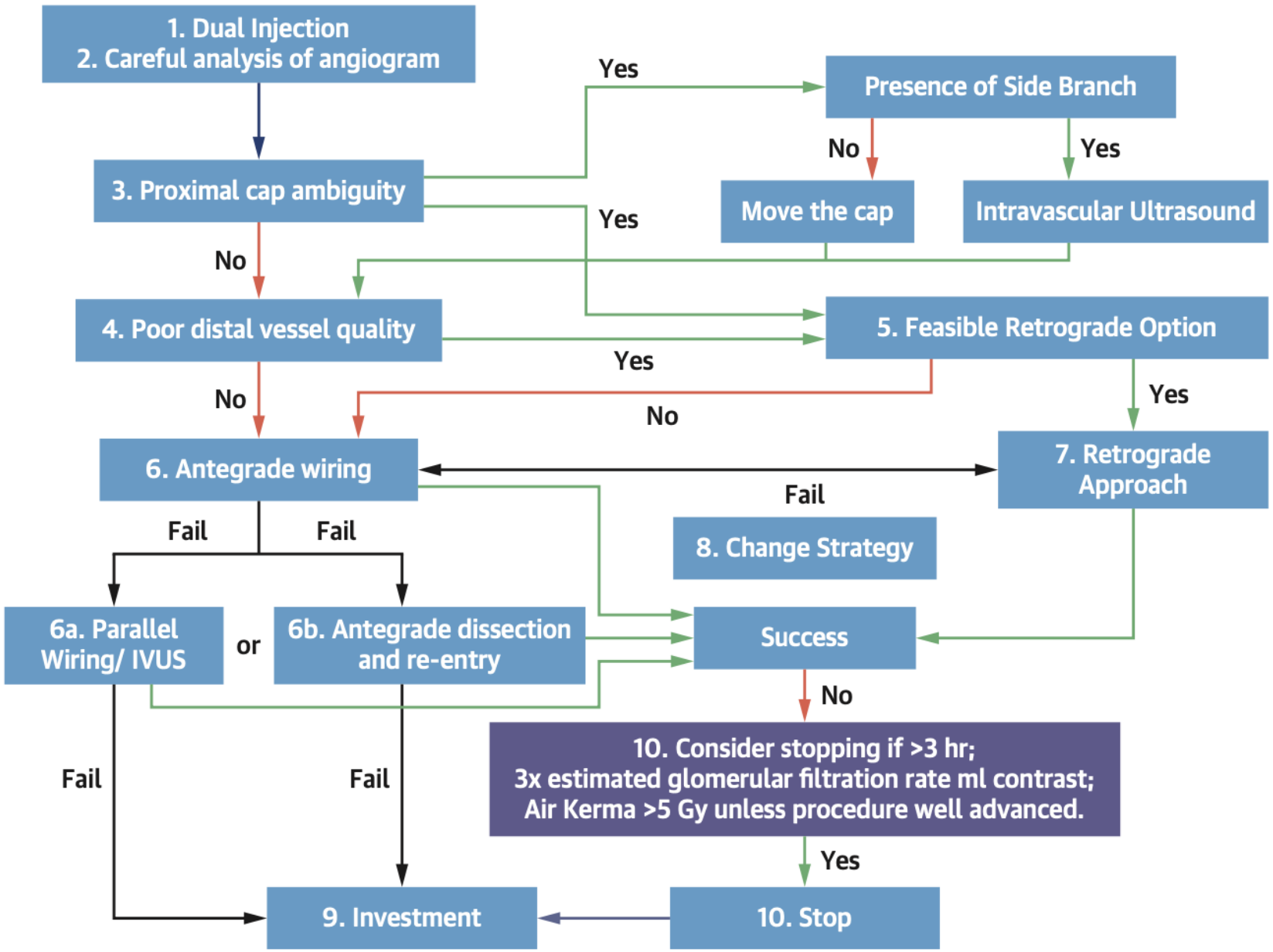

Wu, E.B. et al. J Am Coll Cardiol. 2021;78(8):840-853.

Figure 4.

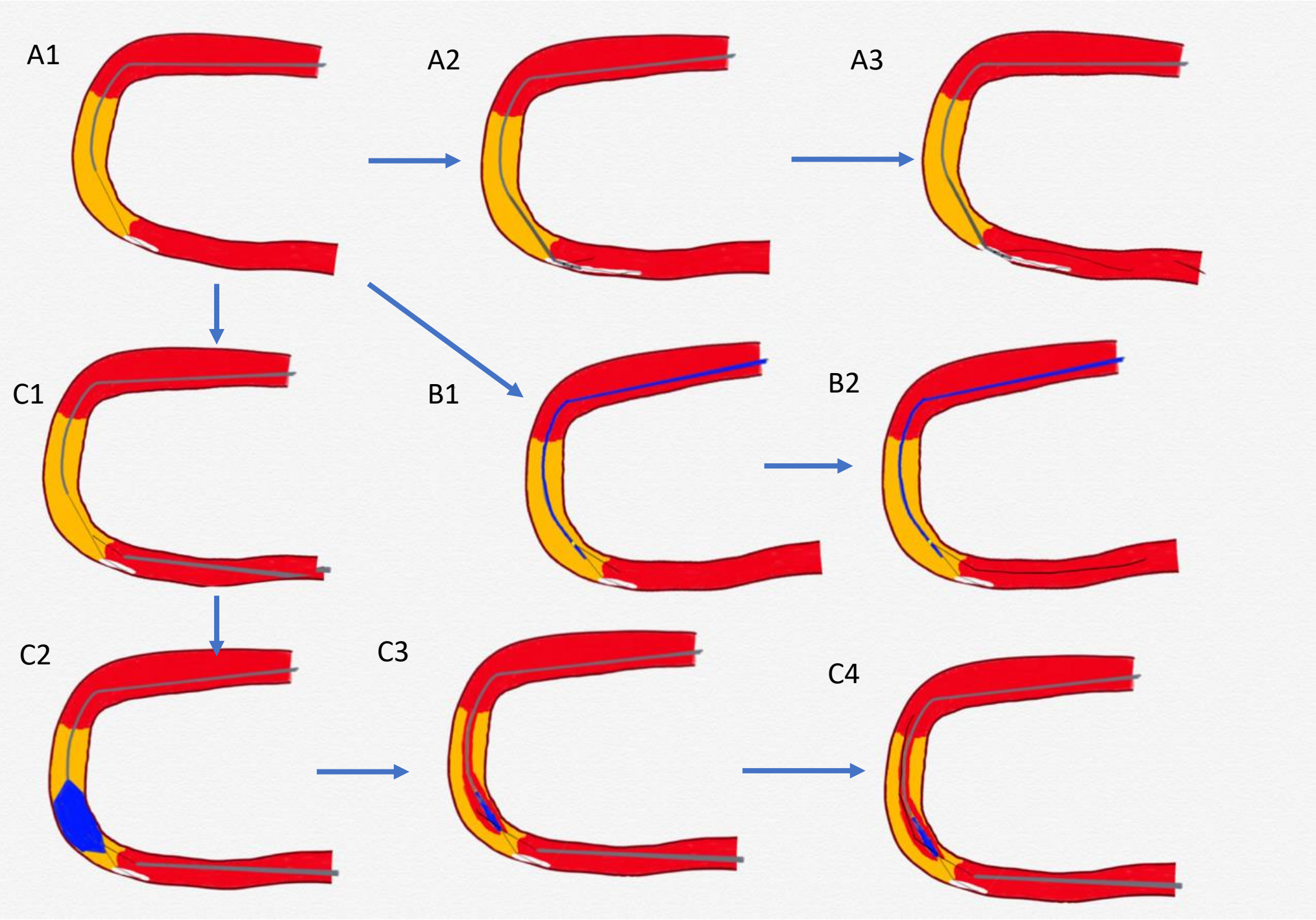

The Global CTO Crossing Algorithm

7. Retrograde approach - long occlusion length (≥20 mm), severe tortuosity and calcification and lack of large side branches -> RDR.
8. Change – avoid stuck in failure.
9. Investment procedure when "anticipated benefit exceeds the potential harm"[8].
10. When to Stop.
    [A] Procedure time is >3 hours, contrast volume is >3 x the estimated glomerular filtration rate, or if the air kerma radiation dose is >5 Gray, unless the procedure is well advanced.
    [B] advanced crossing strategies, such as retrograde crossing or antegrade dissection/re-entry are needed for successful crossing but the operator does not have expertise in those techniques.
    [C] There is significant operator or patient fatigue.
    [D] Occurrence of a serious complication.

8. Hirai T et al. Impact of subintimal plaque modification procedures on health status after unsuccessful chronic total occlusion angioplasty. Catheter Cardiovasc Interv 2018;91:1035-1042. Xenogiannis I et al. Outcomes of subintimal plaque modification in chronic total occlusion percutaneous coronary intervention. Catheter Cardiovasc Interv 2020;96:1029-1035.Hirai T et al. Impact of Subintimal or Plaque Modification on Repeat Chronic Total Occlusion Angioplasty Following an Unsuccessful Attempt. JACC Cardiovasc Interv 2020;13:1010-1012.

Conclusions.

CTO crossing algorithms are useful tools for optimizing the success and safety of CTO PCI.

The global CTO crossing algorithm reflects the consensus of several experienced operators from multiple countries around the world and could help further improve the outcomes of these challenging procedures.

This algorithm could help expand discussion, research, collaboration, and training in CTO PCI.

CENTRAL ILLUSTRATION The Global Chronic Total Occlusion Crossing Algorithm

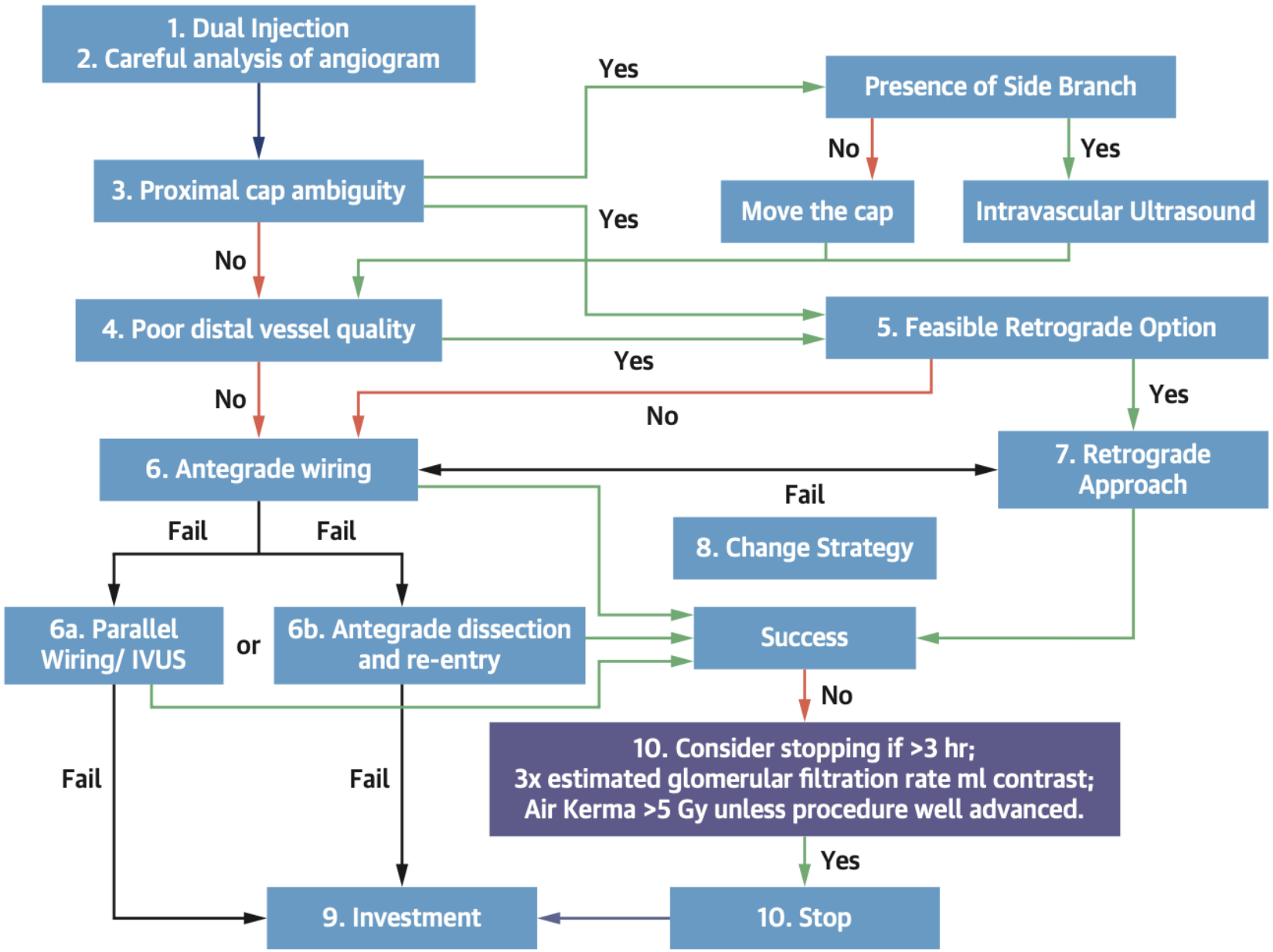

Wu, E.B. et al. J Am Coll Cardiol. 2021;78(8):840-853.

THANK YOU

I would like to extend special personal thanks to
Dr Emmanouil S Brilakis,
Dr Kambis Mashayekhi,
and Dr Etsuo Tsuchikane.

Global Consensus Recommendations on Improving the Safety of Chronic Total Occlusion Interventions.

Eugene B Wu, M.D. [a], Arun Kalyanasundaram, M.D.[b], Emmanouil S Brilakis, M.D., Ph.D. [c], Kambis Mashayekhi, M.D. [d], Etsuo Tsuchikane, M.D., Ph.D. [e], Pierfrancesco Agostoni, MD. PhD.[f], Khaldoon Alaswad, M.D. [g], Mario Araya, M.D. [h], Alexandre Avran, M.D. [i], Mohamed Ayoub, M.D.[j], Lorenzo Azzalini, M.D., M.Sc., Ph.D. [k], Avtandil M. Babunashvili, M.D. [l], Baktash Bayani, M.D. [m], Michael Behnes, M.D. [n], Ravinay Bhindi, M.D. PhD. [o], Nicolas Boudou, M.D. [p], Marouane Boukhris, M.D. [q], Nenad Z. Bozinovic, M.D. [r], Leszek Bryniarski, M.D. PhD. [s], Alexander Bufe, M.D. [t], Christopher E. Buller, M.D. [u], M. Nicholas Burke, M.D. [c], Achim Buttner, M.D. [v], Pedro Cardoso, M.D. [w], Mauro Carlino, M.D. [x], Chi-Kin Chan, M.D.[y], Jiyan Chen, M.D. PhD. [z], Evald Hoej Christiansen, M.D. [aa], Antonio Colombo, M.D. [bb], Kevin Croce, M.D., Ph.D.[cc], Felix Damas de los Santos, M.D., M.E.T. [dd], Tony de Martini, M.D. [ee], Joseph Dens, M.D., Ph.D. [ff], Carlo di Mario, M.D. [gg], Darshan Doshi, M.D.[hh], Kefei Dou, M.D. [ii], Mohaned Egred, M.D. [jj], Basem Elbarouni, M.D. [kk], Ahmed M. ElGuindy, M.D. [ll], Javier Escaned, M.D. [mm], Sergey Furkalo, M.D. [nn], Andrea Gagnor, M.D. [oo], Alfredo R. Galassi, M.D. FACC, FESC[pp], Roberto Garbo, M.D. [qq], Gabriele L.Gasparini, M.D. [rr], Junbo Ge, M.D. [ss], Lei Ge, M.D. [ss], Pravin Kumar Goel, M.D. [tt], Oliver Goktekin, M.D. [uu], Nieves Gonzalo, M.D.. PhD. [vv], Sevket Gorgulu, M.D.[ww], Luca Grancini, M.D. [xx], Allison B. Hall, M.D. [yy], Franklin Leonardo Hanna Quesada, M.D. [zz], Colm Hanratty, M.D. [aaa], Stefan Harb, M.D. [bbb], Scott A. Harding, M.D. [ccc], Raja Hatem, M.D. [ddd], Farrel Hellig, M.D.[eee], Jose P.S. Henriques, M.D. [fff], David Hildick-Smith, M.D. [ggg], Jonathan M. Hill, M.D. [hhh], Angela Hoye, M.D. [iii], Wissam Jaber, M.D. [jjj], Farouc A. Jaffer, M.D., Ph.D. [hh], Yangsoo Jang, M.D. [kkk], Risto Jussila, M.D. [lll], Artis Kalnins, M.D. [mmm], Sanjog Kalra, M.D., M.Sc[nnn], David E. Kandzari, M.D. [ooo], Hsien-Li Kao, M.D. [ppp], Dimitri Karmpaliotis, M.D., Ph.D. [qqq], Hussien Heshmat Kassem, M.D., Ph.D. [rrr], Kathleen Kearney, M.D.[sss], Jimmy Kerrigan, M.D.[ttt], Jaikirshan Khatri, M.D. [uuu], Dmitri Khelimskii, M.D.[vvv], Ajay J Kirtane, M.D.[www], Paul Knaapen, M.D. [xxx], Ran Kornowski, M.D. [yyy], Oleg Krestyaninov, M.D. [zzz], A. V. Ganesh Kumar, M.D. [aaaa], Prathap Kumar, M.D.[bbbb], Pablo Manuel Lamelas, M.D., M.Sc. [cccc], Seung-Whan Lee, M.D. [dddd], Thierry Lefevre, M.D. [eeee], Gregor Leibundgut M.D.[ffff], Raymond Leung, M.D. [gggg], Sum-Kin Leung, M.D.[hhhh], Yu Li, M.D. [iiii], Yue Li, M.D. [jjjj], Soo-Teik Lim, M.D. [kkkk], Sidney Lo, M.D. [llll], William Lombardi, M.D.[mmmm], Anbukarasi Maran, M.D.[nnnn], Margaret McEntegart, M.D., Ph.D. [www], Jeffrey Moses, M.D. [www&oooo], Muhammad Munawar, M.D. [pppp], Wataru Nagamatsu, M.D.[qqqq], Andres Navarro, M.D. [rrrr], Hung M. Ngo, M.D., Ph.D. [ssss], William Nicholson, M.D. [jjj], Anja Oksnes, M.D. [tttt], Goran K. Olivecrona, M.D., Ph.D. [uuuu], Lucio Padilla, M.D. [vvvv], Mitul Patel, M.D. [wwww], Ashish Pershad, M.D. [xxxx], Marin Postu, M.D. [yyyy], Stylianos Pyxaras, MD, PhD [zzzz], Jie Qian, M.D. [aaaaa], Alexandre Quadros, M.D. [bbbbb], Nidal Abi Rafeh, M.D. [ccccc], Truls Råmunddal, M.D., Ph.D. [ddddd], Vithala Suryaprakasa Rao, M.D. [eeeee], Sudhir Rathore, M.D.[fffff], Nicolaus Reifart, M.D., Ph.D. [ggggg], Robert F. Riley, M.D. [hhhhh], Stephane Rinfret, M.D. [iiiii], Meruzhan Saghatelyan, M.D. [jjjjj], Ricardo Santiago, M.D.[kkkkk], Ashok Seth, M.D.[lllll], Georgios Sianos, M.D., Ph.D. [mmmmm], Elliot Smith, M.D. [nnnnn], Anthony Spaedy, M.D. [ooooo], James Spratt, M.D. [ppppp], Gregg W. Stone, M.D. [qqqqq], Julian W. Strange, M.D. [rrrrr], Khalid O. Tammam, M.D., Ph.D. [sssss] Craig A. Thompson, M.D. [ttttt], Aurel Toma, M.D. [uuuuu], Jennifer A Tremmel, M.D., M.S. [vvvvvv], Imre Ungi, M.D., Ph.D [wwwww], Giuseppe Vadalà, M.D.[xxxxx], Minh Vo, M.D. [yyyyy], Vu Hoang Vu, M.D. [zzzzz], Simon Walsh, M.D. [aaaaaa], Daniel Weilenmann, M.D.[bbbbbb], Gerald S. Werner, M.D. PhD. [cccccc], Jaroslaw Wojcik, M.D. [dddddd], Jason Wollmuth, M.D. [eeeeee], Chiung-Jen Wu, M.D.[ffffff], Bo Xu,

Central Illustration