

CTO PCI: The Role of Intravascular Ultrasound

Dimitri Karpaliotis, MD, PhD FACC, FSCAI

*Director of CTO, and Advanced Coronary Therapeutics
Director of Rescue the Heart and Recovery Program
Morristown Medical*

TCTAP, Seoul, Korea, May 6-9, 2023

Email: dkarmp@gmail.com



@DKarpaliotis

Disclosure Statement of Financial Interest

Within the past 12 months, I have had a financial interest/arrangement or affiliation with the organization(s) listed below.

Affiliation/Financial Relationship

Consulting Fees/Honoraria

Equity

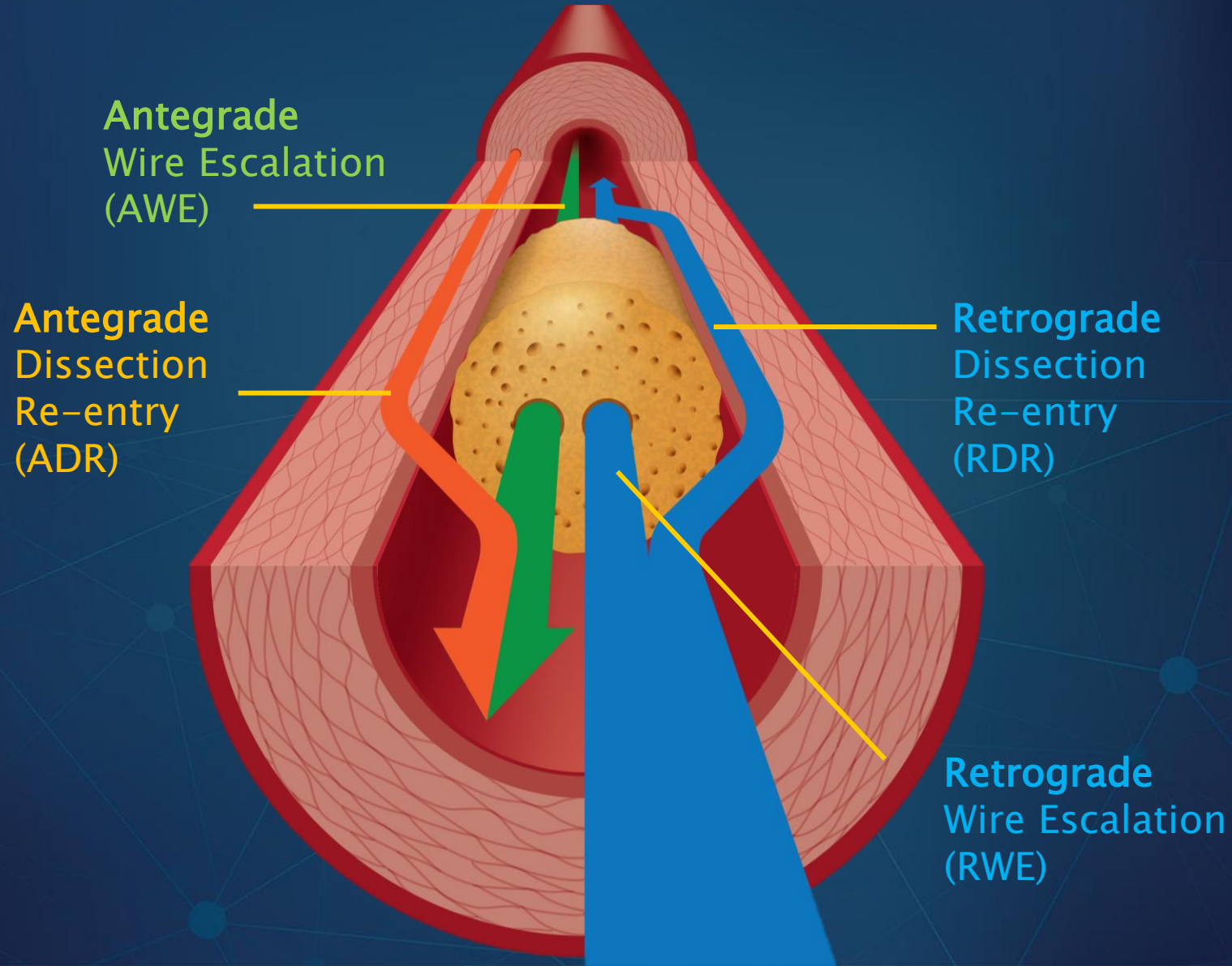
Company

Abott Vascular, Boston Scientific

Soundbite, Saranas, Traverse Vascular

- Identify Proximal Cap
- Trouble-Shoot Difficult R-CART
- Identify Dissection planes in distal bifurcations
- Size STENTS after Crossing
- Research

4 options to crossing CTOs



Columbia CTO IVUS Study

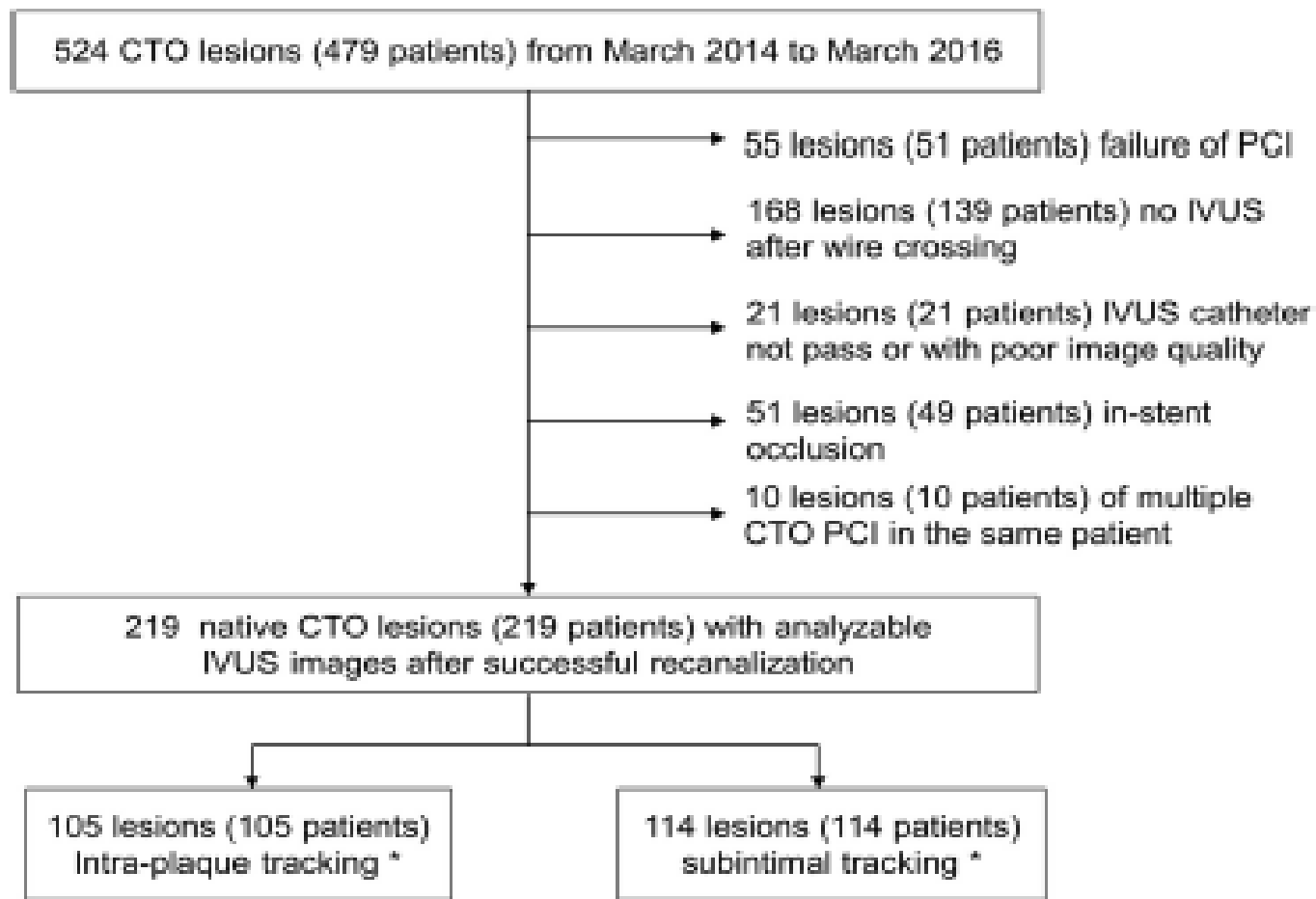
ARTICLE IN PRESS

JACC: CARDIOVASCULAR INTERVENTIONS
© 2017 PUBLISHED BY ELSEVIER ON BEHALF OF THE
AMERICAN COLLEGE OF CARDIOLOGY FOUNDATION

VOL. ■, NO. ■, 2017
ISSN 1936-8798/\$36.00
<http://dx.doi.org/10.1016/j.jcin.2017.02.043>

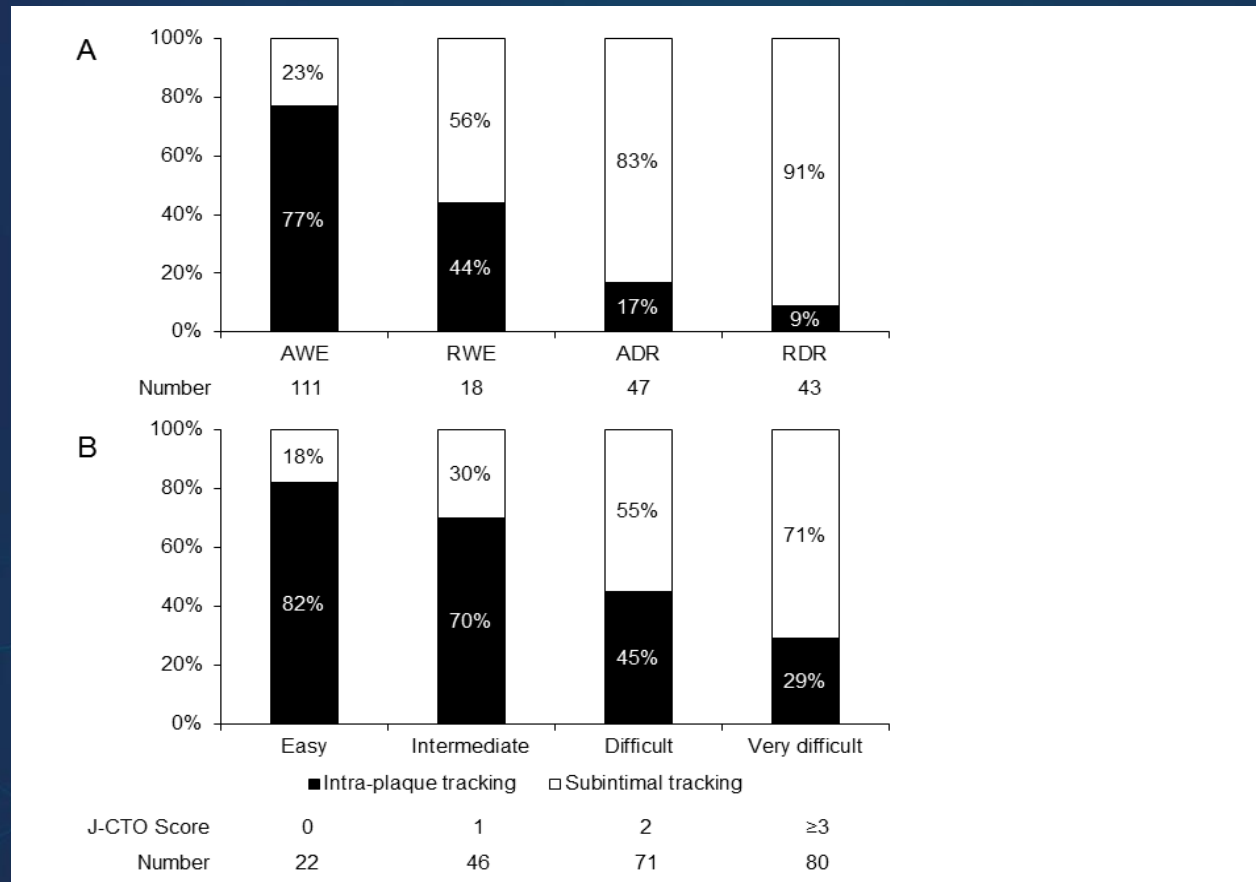
Intravascular Ultrasound Analysis of
Intraplaque Versus Subintimal Tracking in
Percutaneous Intervention for Coronary
Chronic Total Occlusions and Association
With Procedural Outcomes

FIGURE 1 Flow Chart of Patient Inclusion in the Current Study



*IVUS visualized. CTO = chronic total occlusion; IVUS = intravascular ultrasound; PCI = percutaneous coronary intervention.

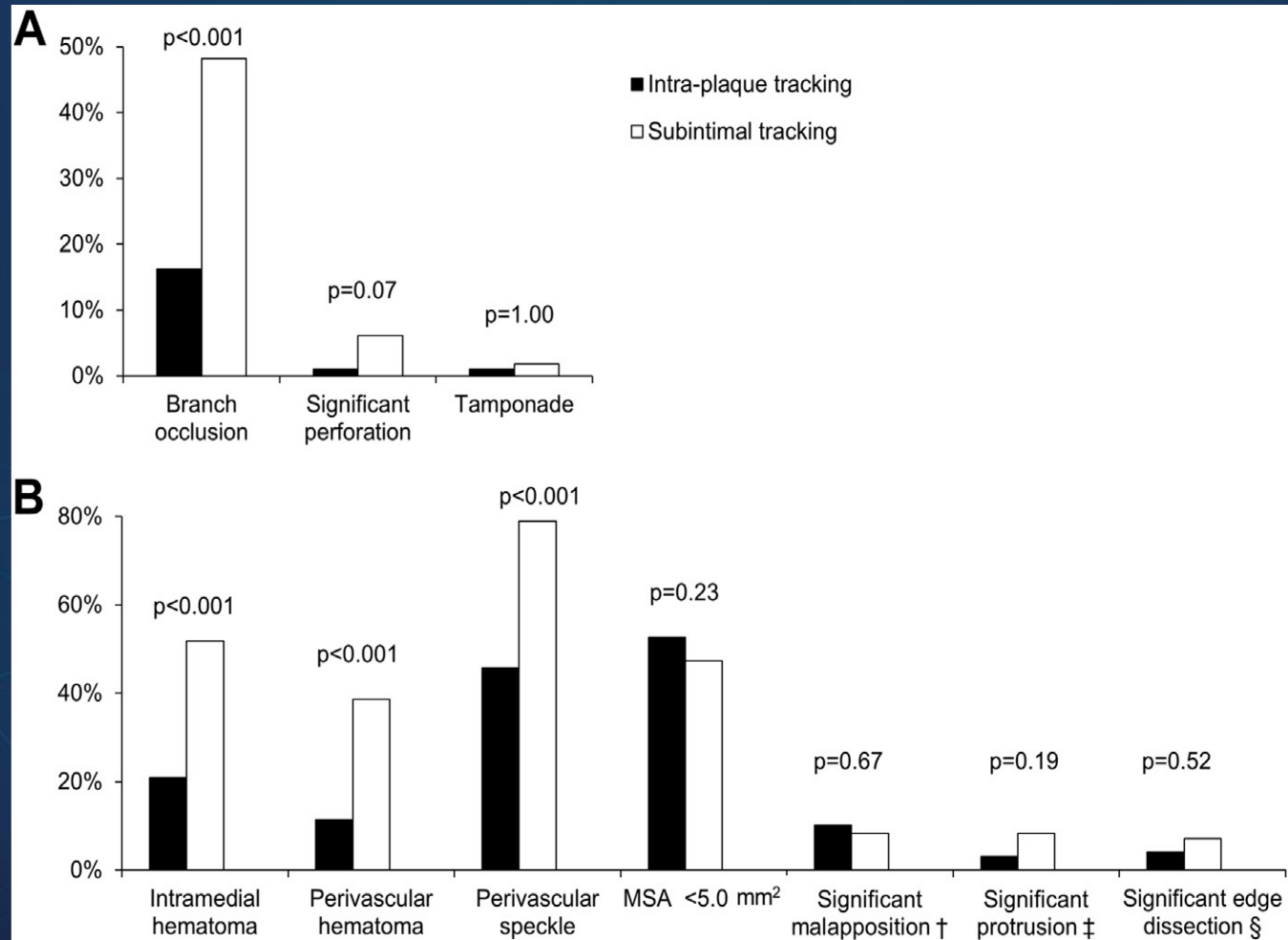
Tracking Pattern Percentages



Guidewire Tracking Pattern Compared with Angiography Defined Successful Approach and Difficulty Grades

(A) Guidewire tracking pattern and successful approach by angiography. (B) Guidewire tracking pattern and difficulty grades.

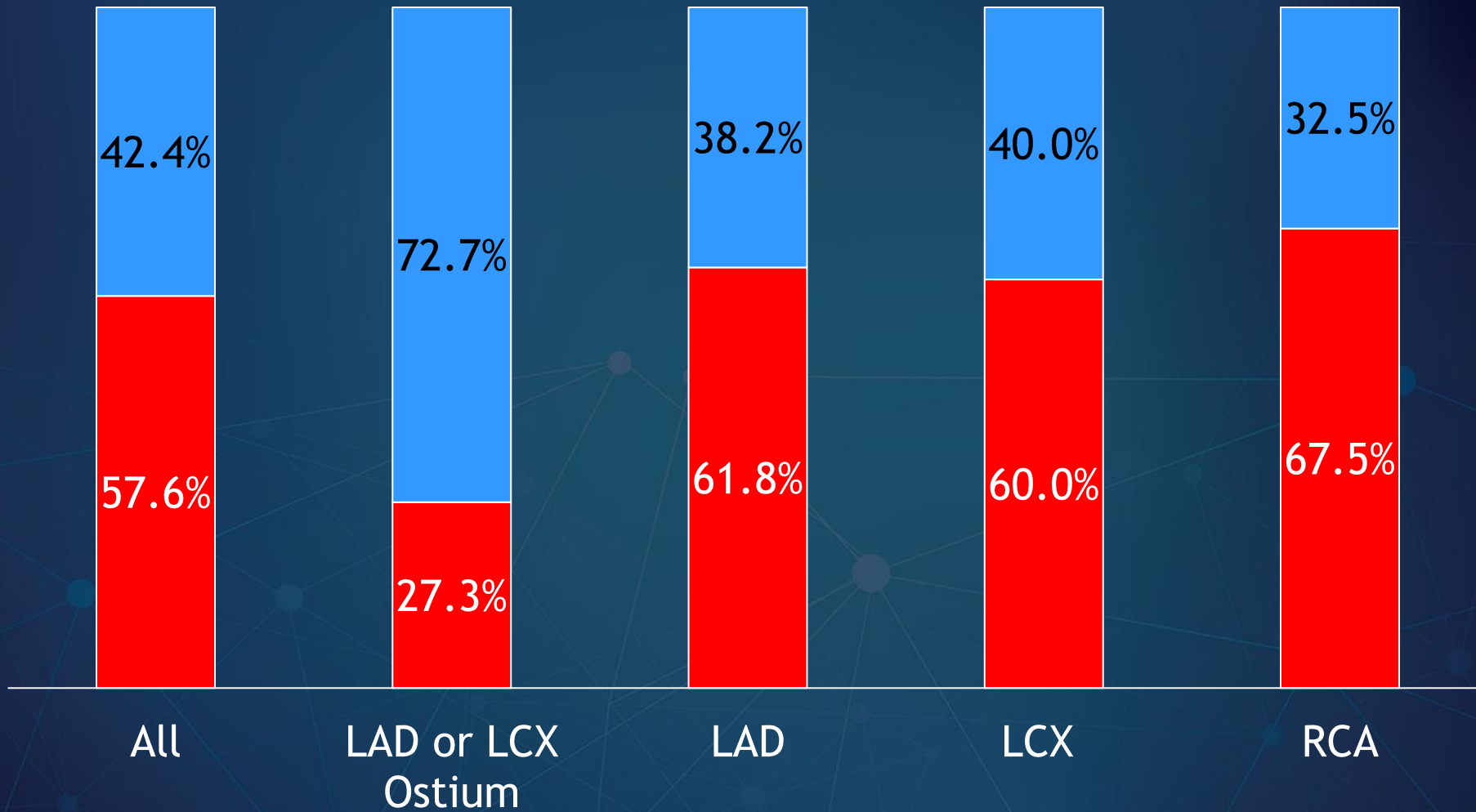
Procedure related outcomes



Proximal Cap

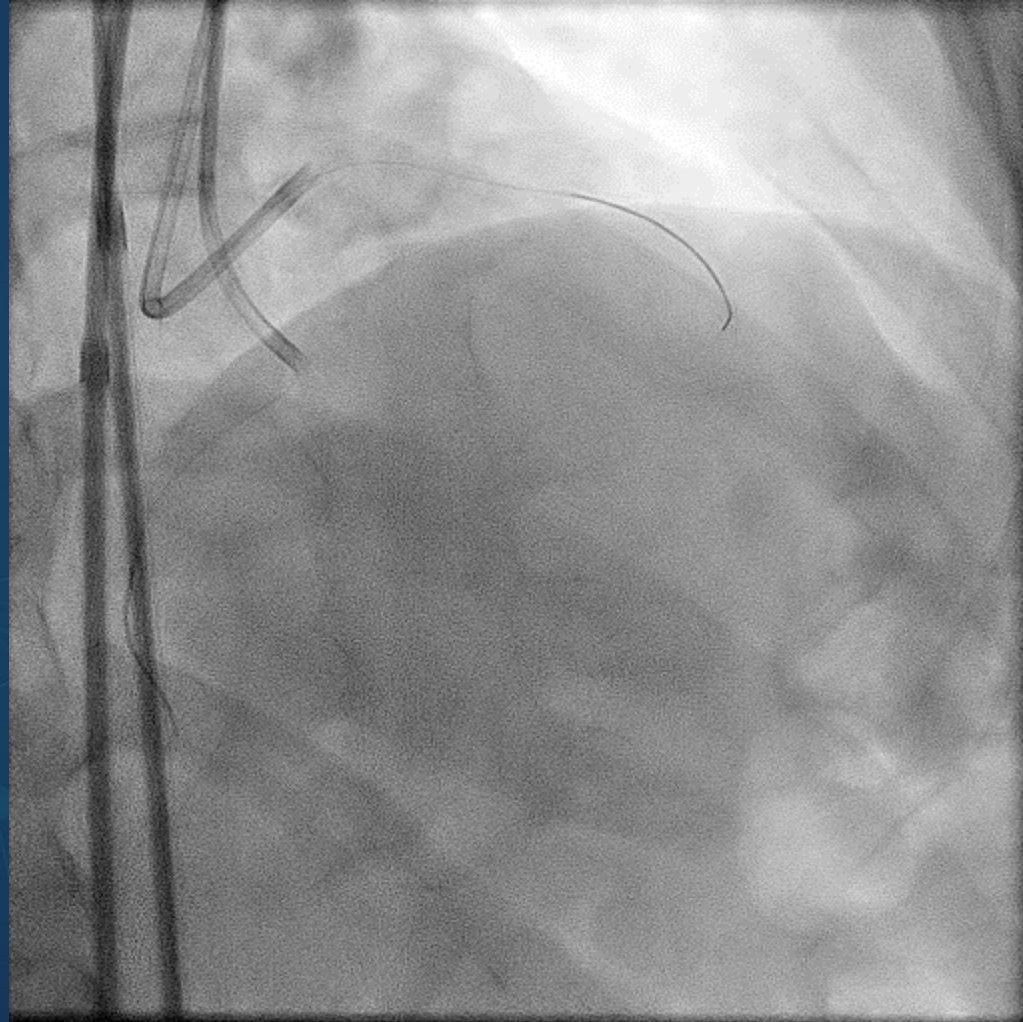
IVUS Evaluation of Proximal Cap

■ Unclear Proximal Cap ■ Clear Proximal Cap

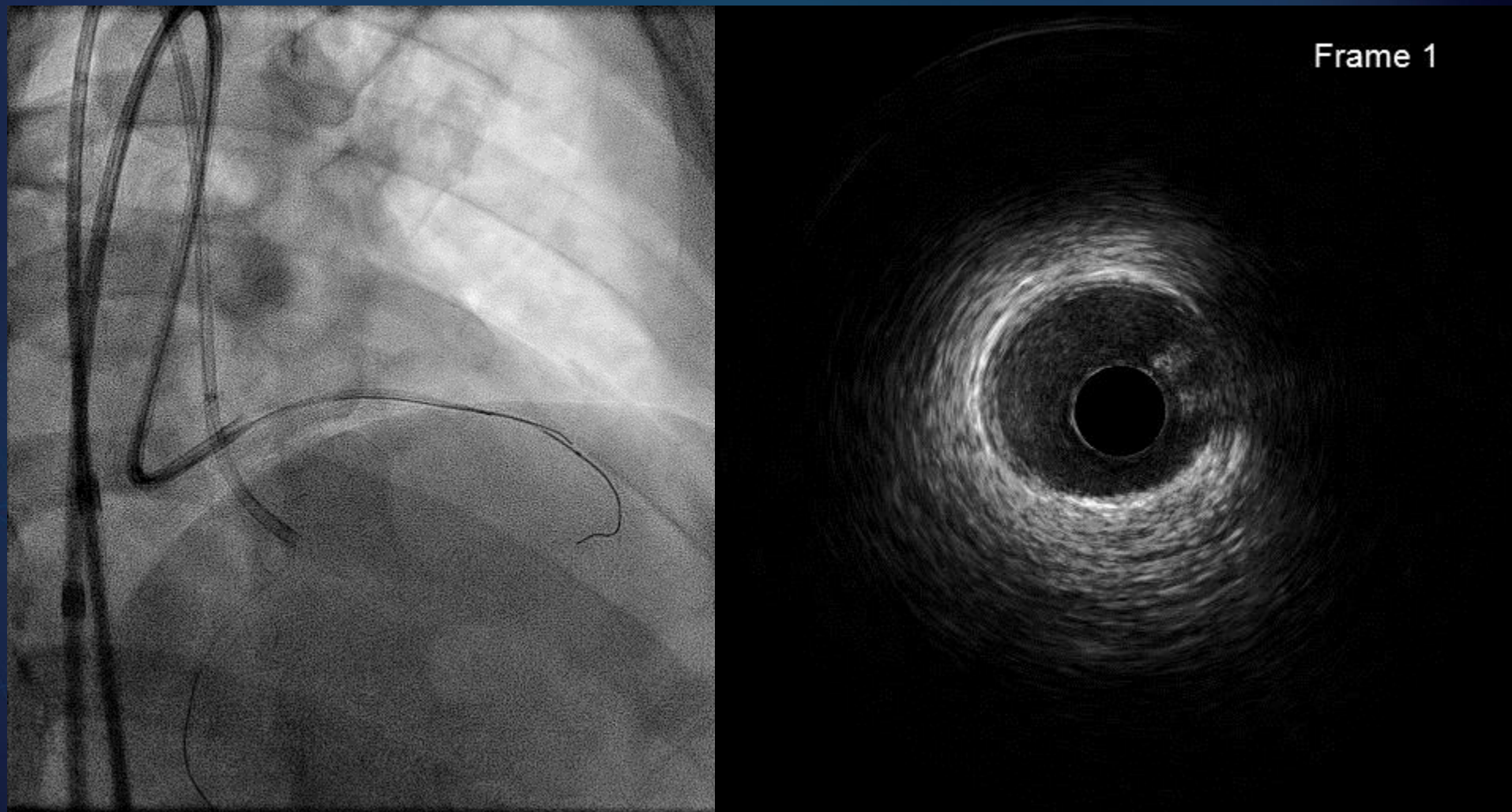


CASE 1

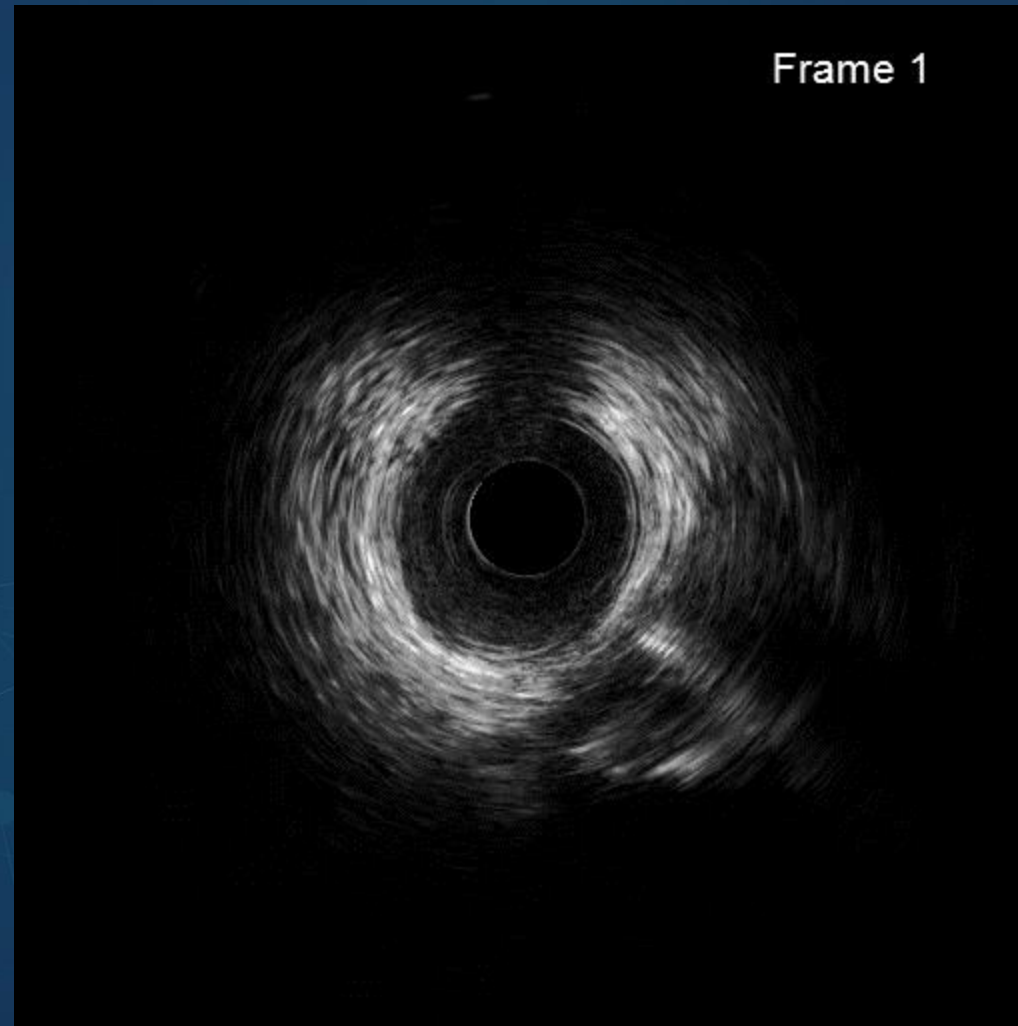
Dual Injections



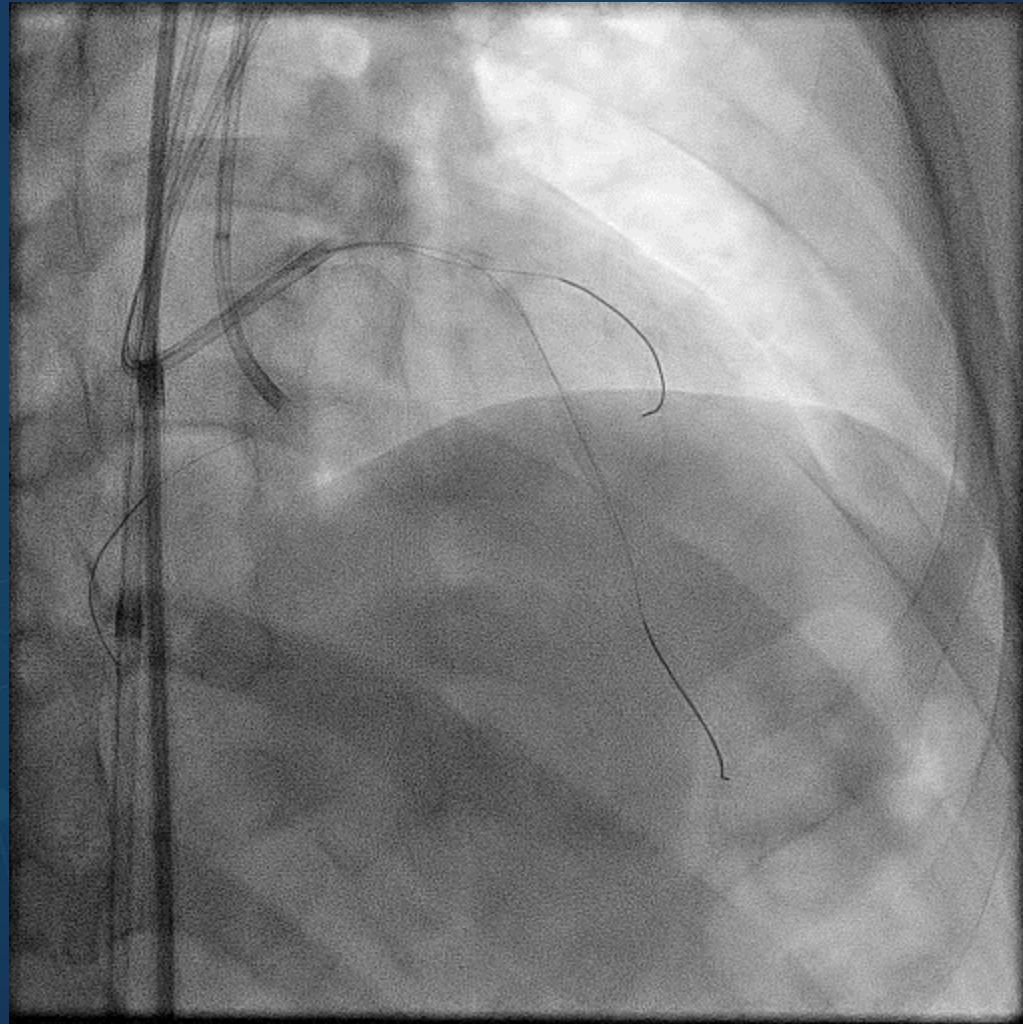
IVUS – Run 1



IVUS – Run 2



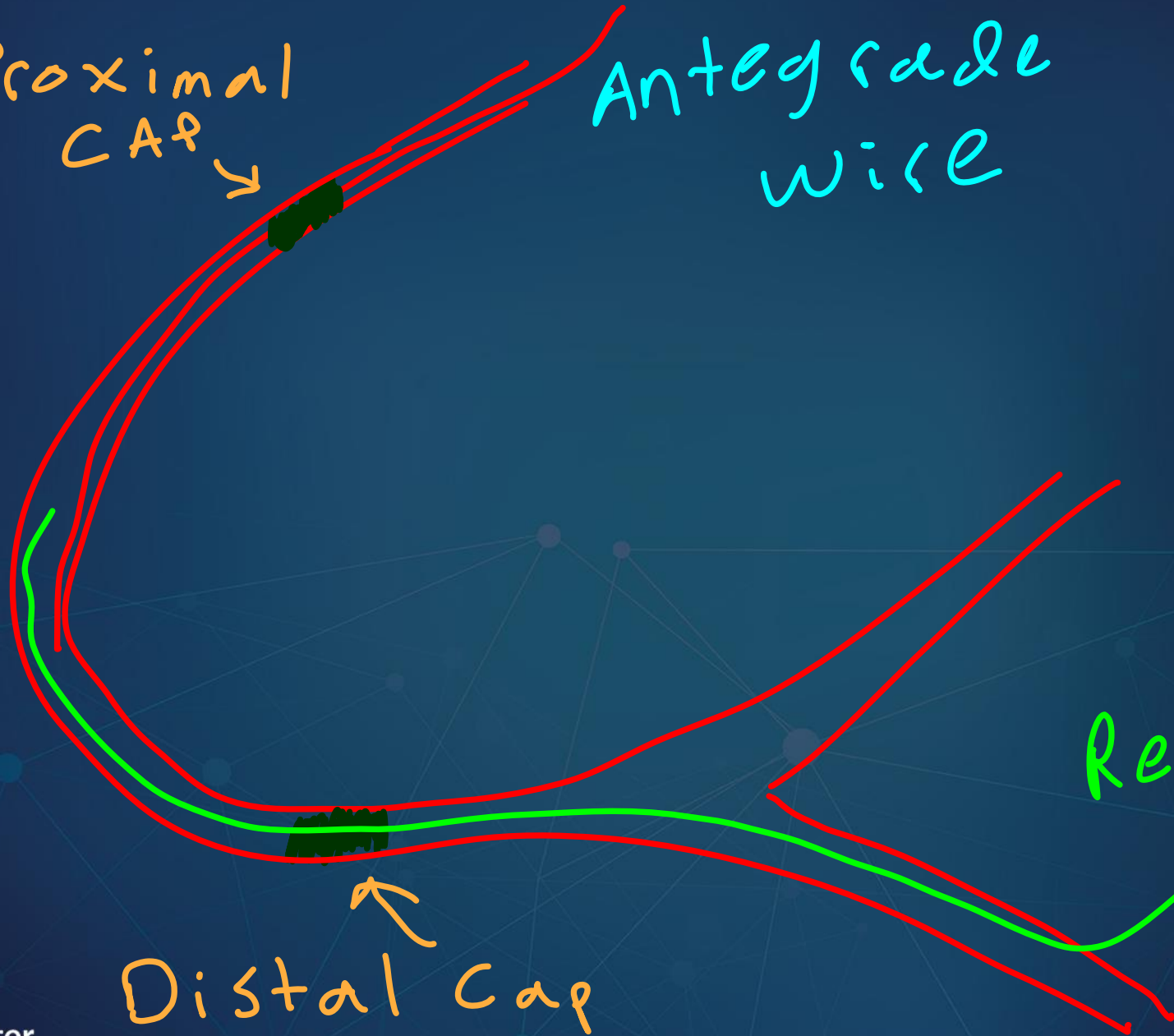
Final Result



Trouble-Shoot Difficult R-CART

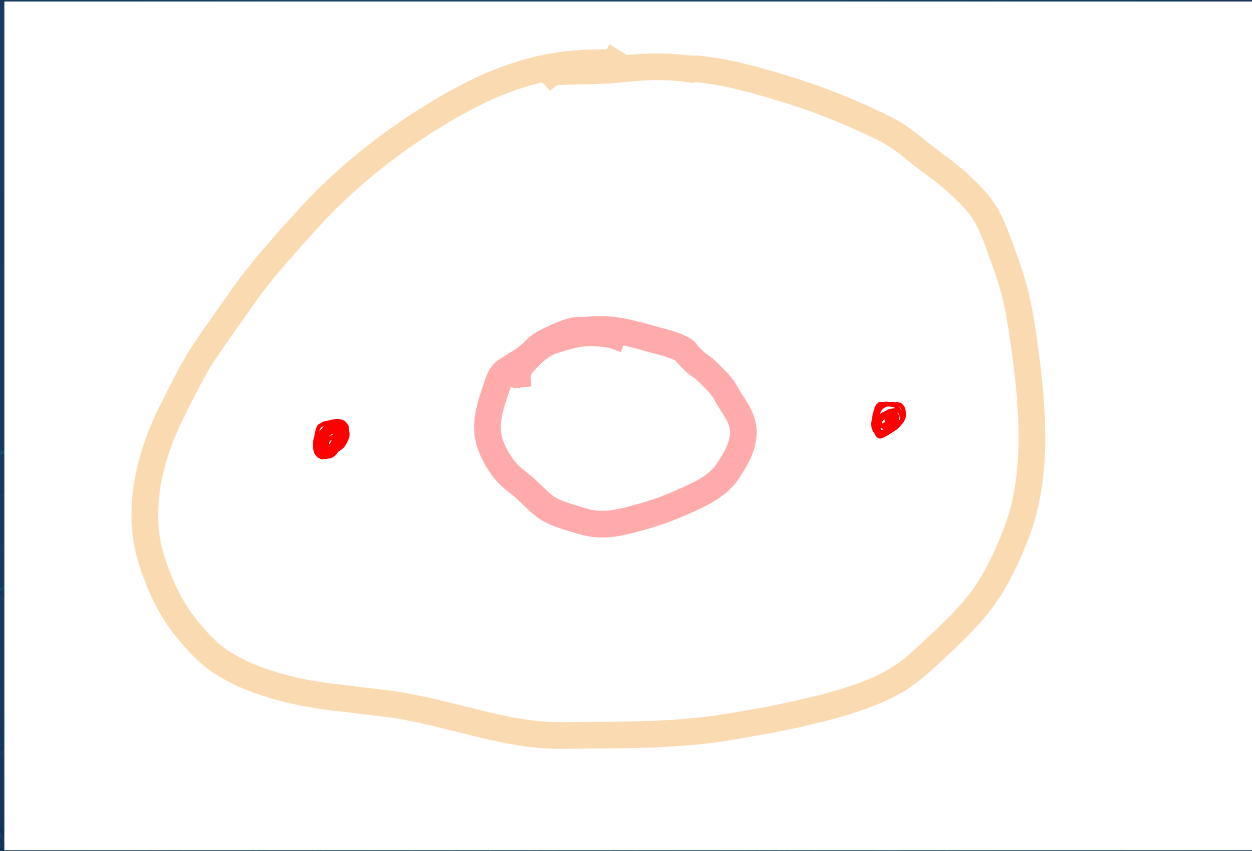
Proximal
CAP

Antegrade
wire



Retrograde
wire

Distal Cap

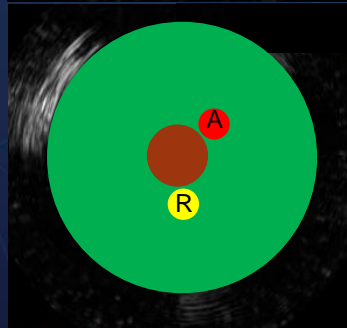
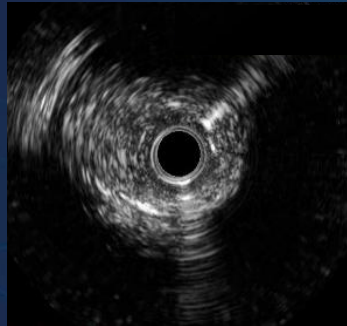
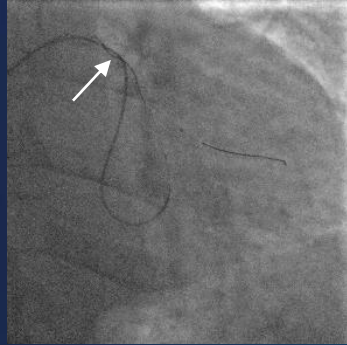


Reasons for Difficult R-CART

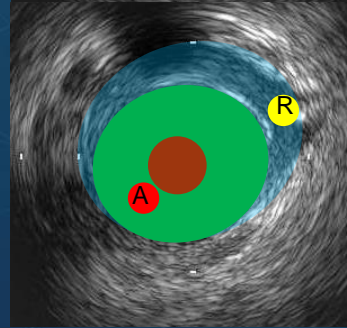
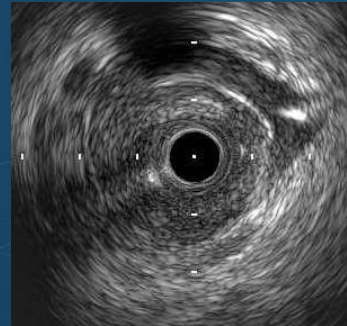
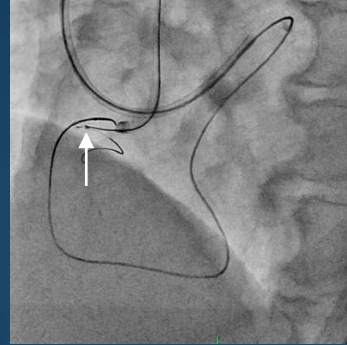
- Vessel Tortuosity
- Calcification
- R-CART performed not in the optimal position
- Balloon dilatation not performed all the way back to the true lumen proximally
- Knuckles have caused big hematomas
- Antegrade and Retrograde wires not in Sub-Intimal space

Four Patterns of AW and RW

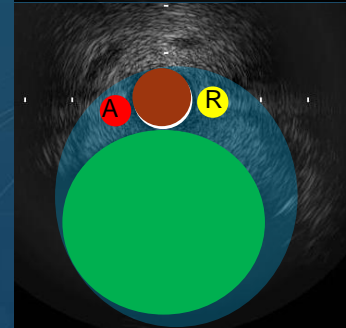
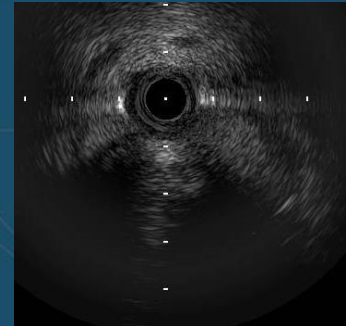
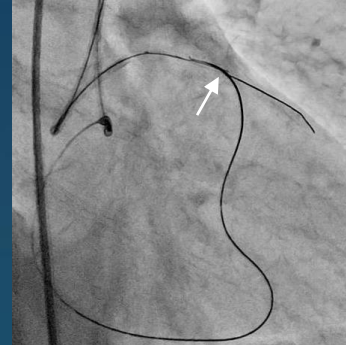
AW-Intra
RW-Intra



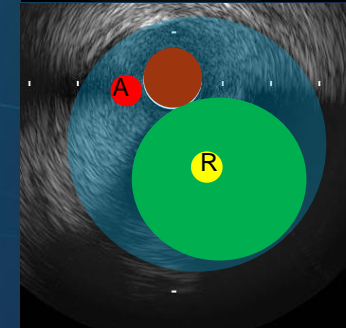
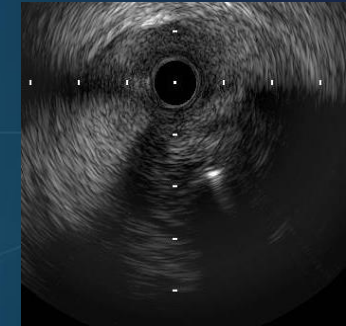
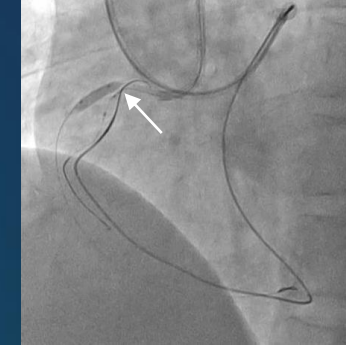
AW-Intra
RW-Sub



AW-Sub
RW-Sub



AW-Sub
RW-Intra

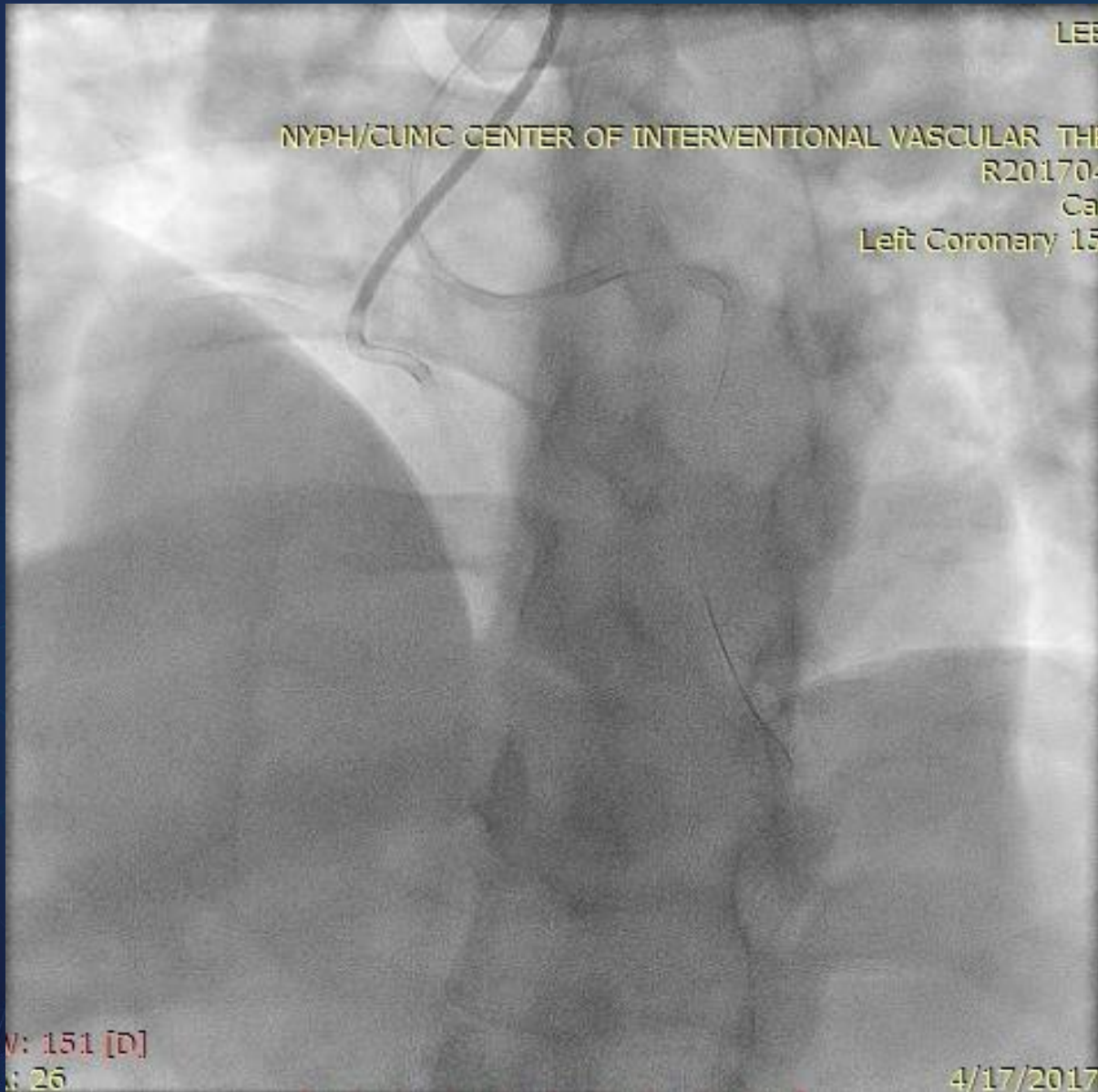


CASE 2

CTO-RCA

BI-RADIAL REVERSE CART WITH EAGLE EYE IVUS GUIDANCE

CTO-RCA

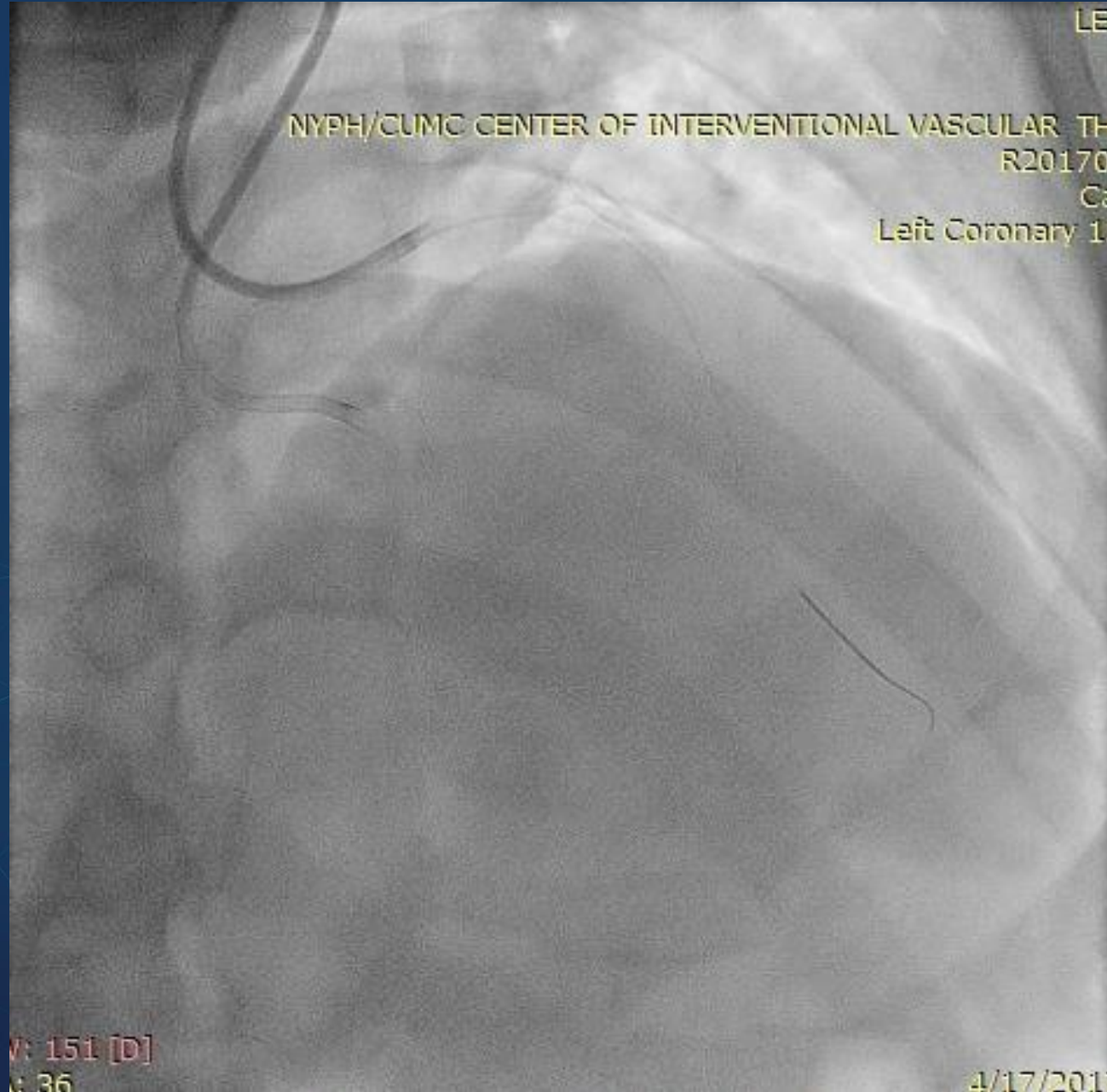


7Fr Slender Sheaths

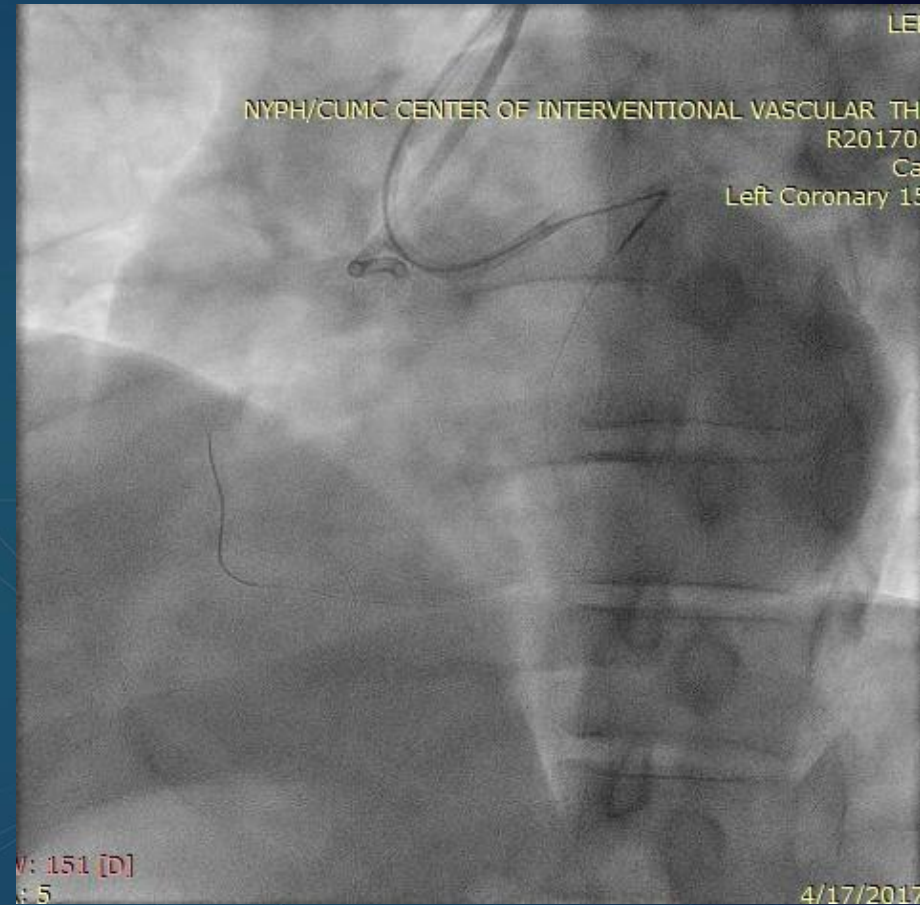
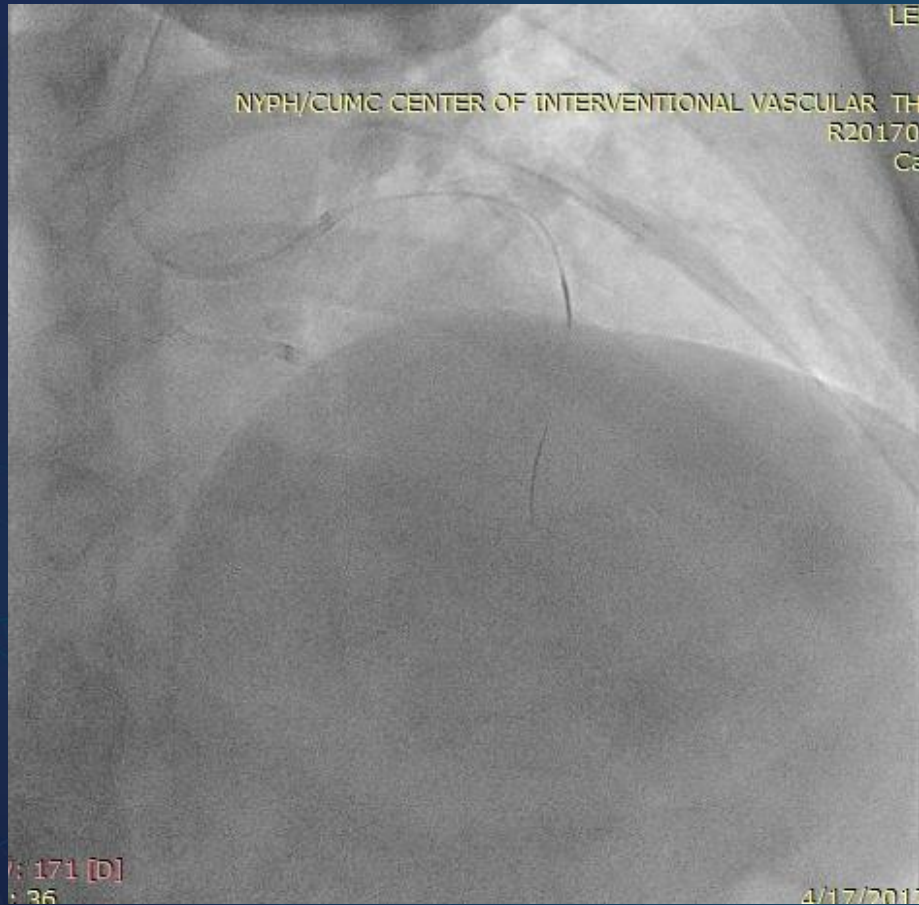Right Radial Artery
7Fr AL0.75
switched later to
JR4.0 SH 90cm

Left Radial Artery
7Fr EBU3.5 90cm

CTO-RCA

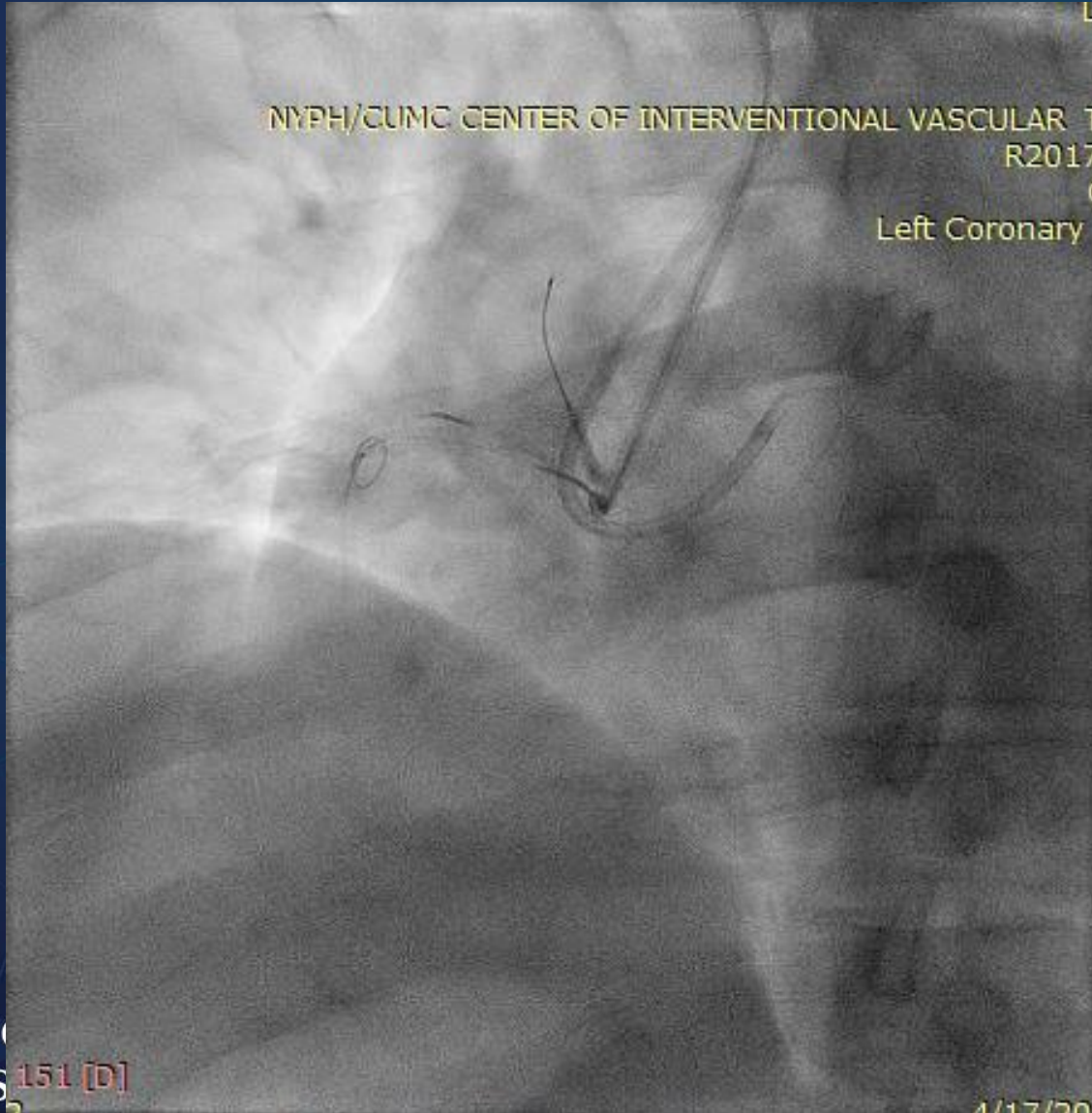

Retrograde via LAD septals



TurnPike LP 150 cm
Sion Wire

Antegrade and Retrograde systems dancing together

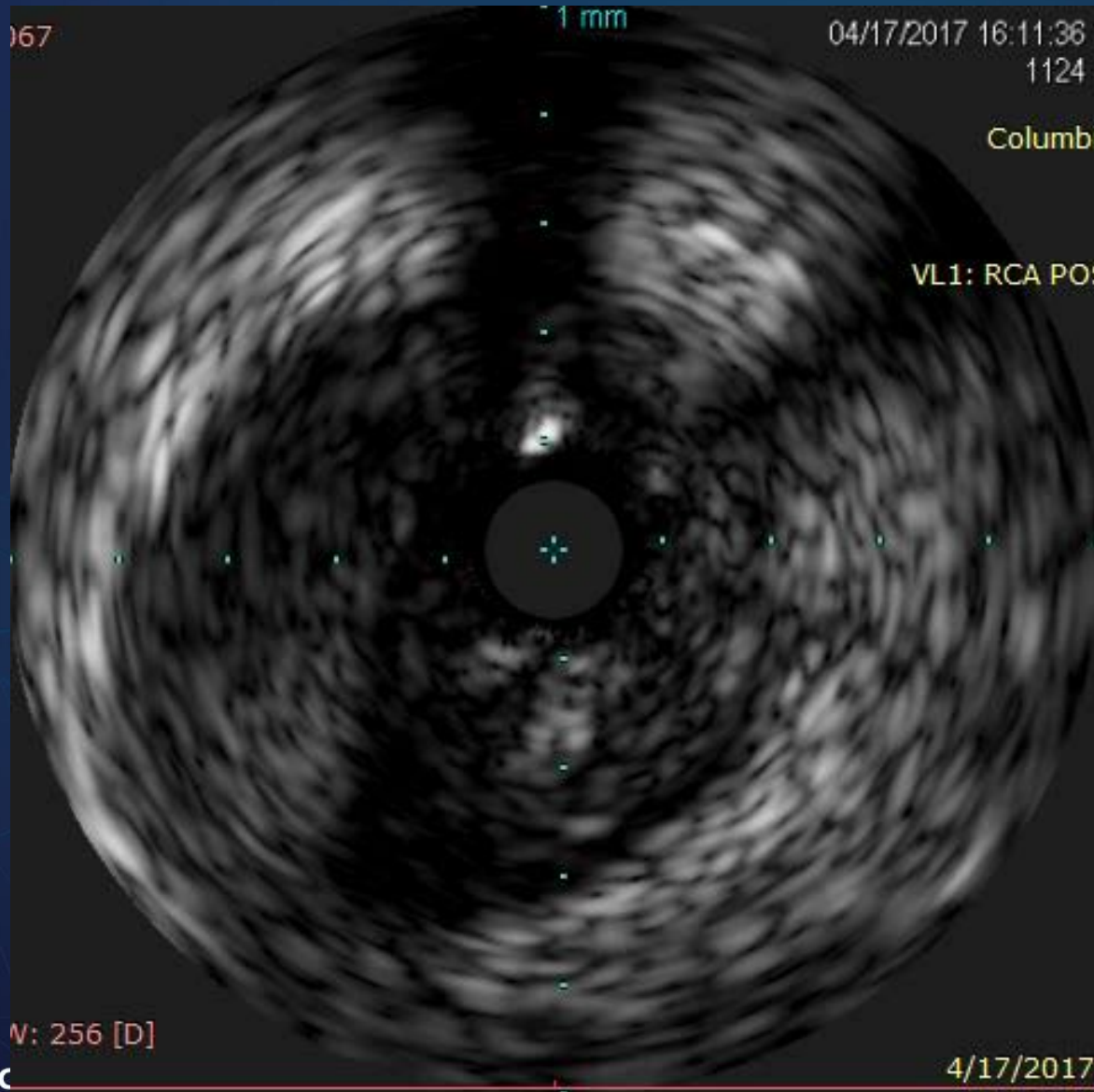


2.0 x 12 mm **Anchoring Balloon** in a conus branch to add support to the 7Fr JR4.0 Guide

Antegrade TurnPike Spiral 135cm with Knuckled Pilot 200 wire

Retrograde TurnPike LP 150 cm

Eagle Eye IVUS Guidance

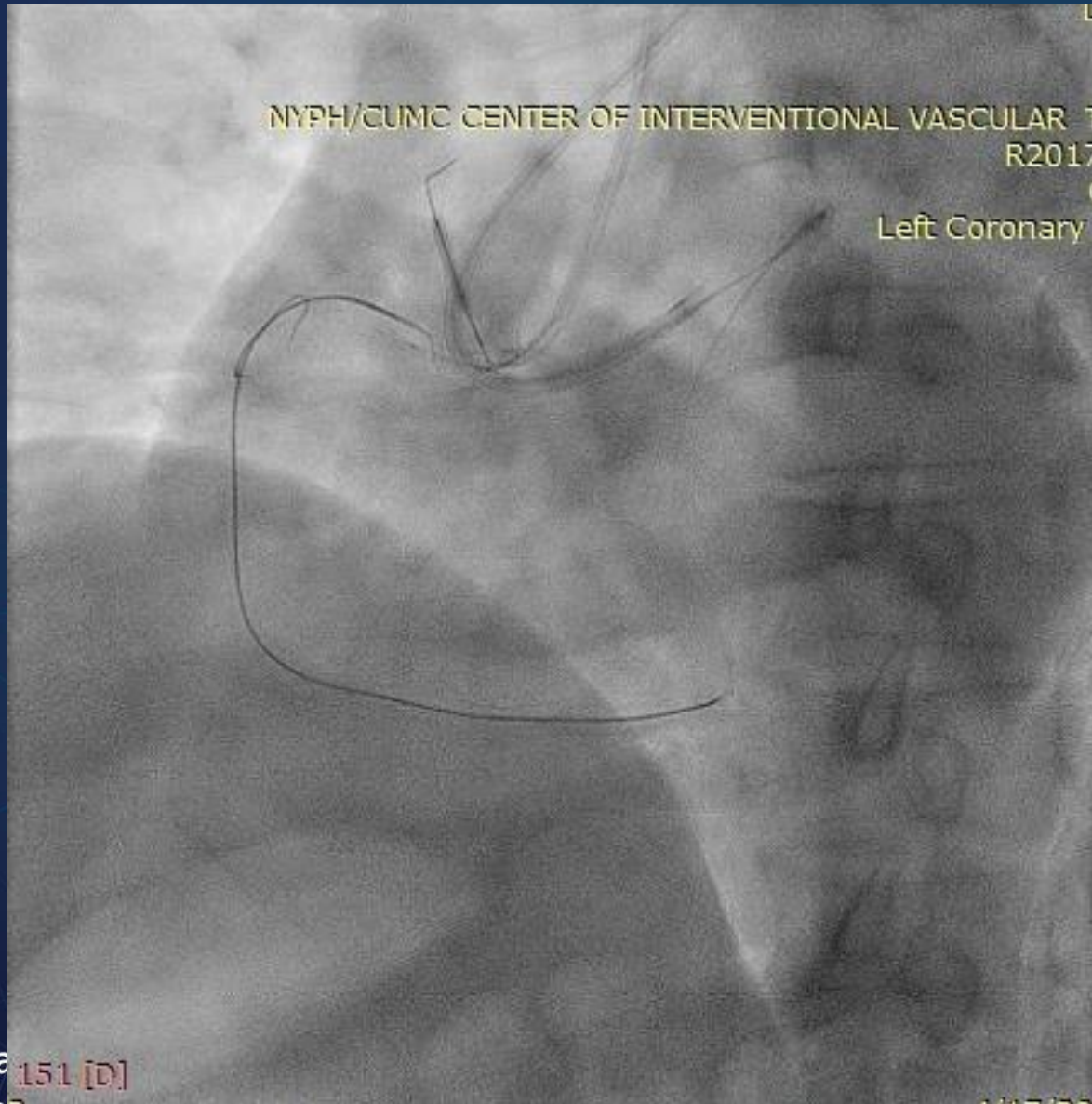

Antegrade IVUS probe
to determine optimal
location for Reverse
CART

“Two white dots”
Represent Retrograde
Knuckled Wire in Sub-
Intimal Space

Antegrade system
confirmed to be
intraplaque and true
lumen

Setting for Reverse CART

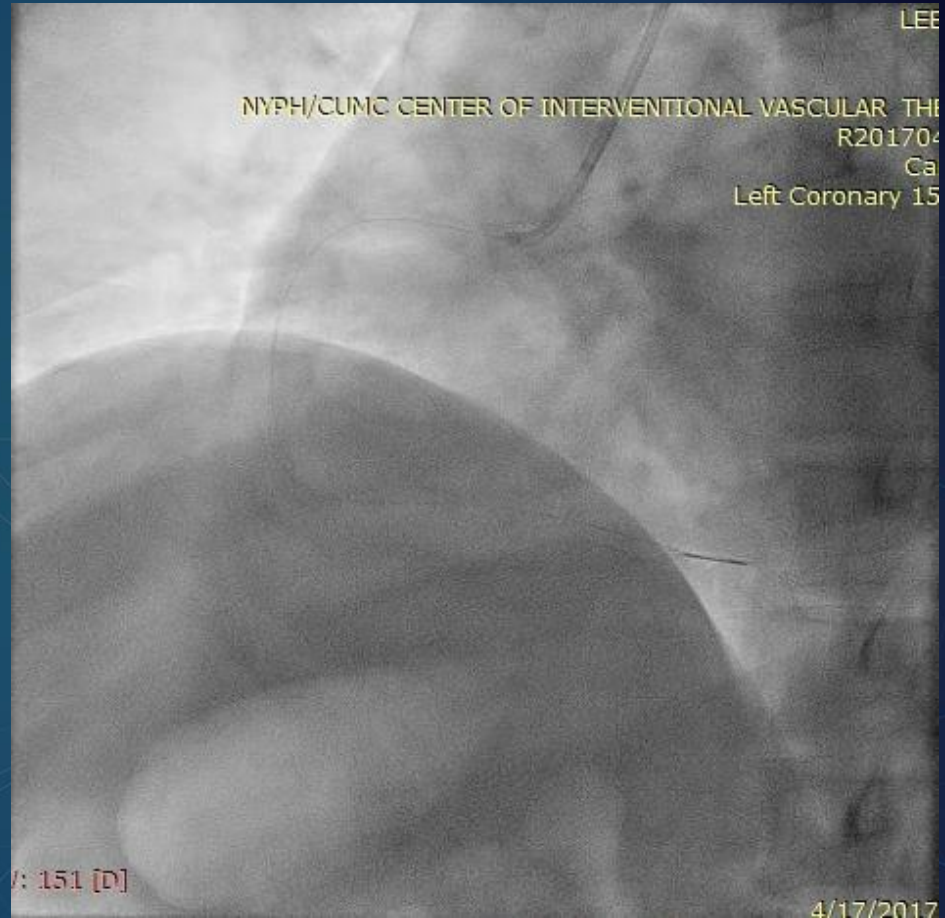
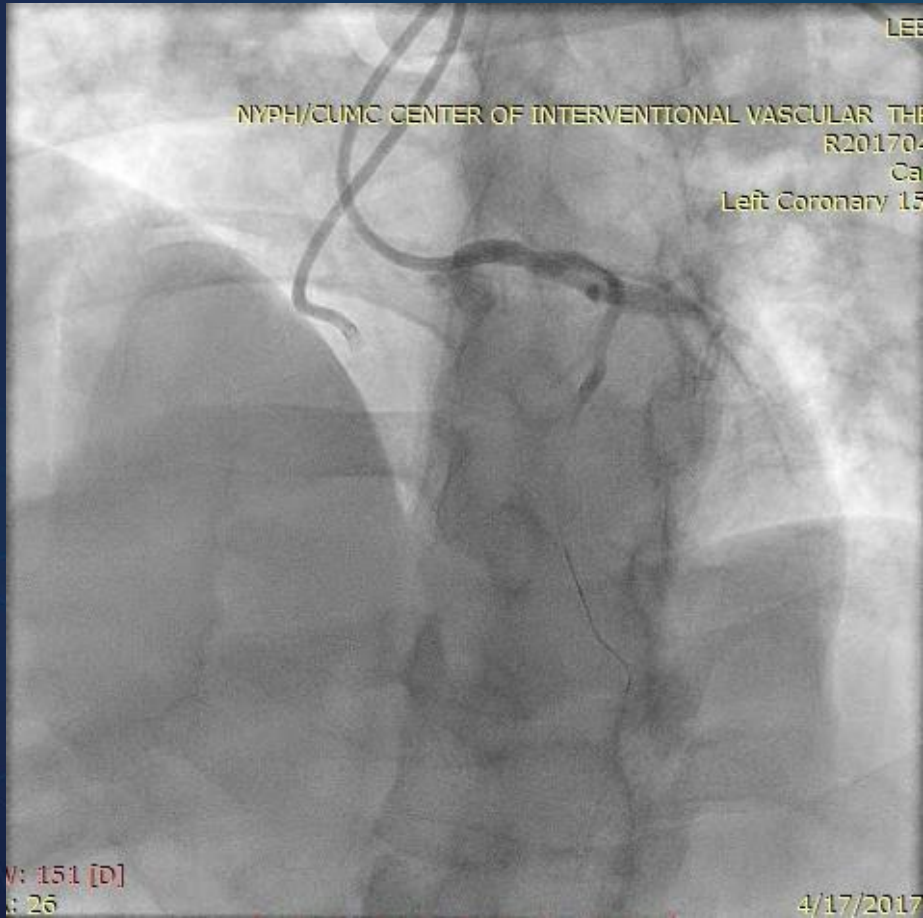


2.0 x 12 mm **Anchoring Balloon** in a conus branch to add support to the 7Fr JR4.0 Guide

Antegrade 4.0 x 20 mm Balloon to create dissection and get into the sub-intimal space

Retrograde TurnPike LP 150 cm with Confianza Pro 12 wire

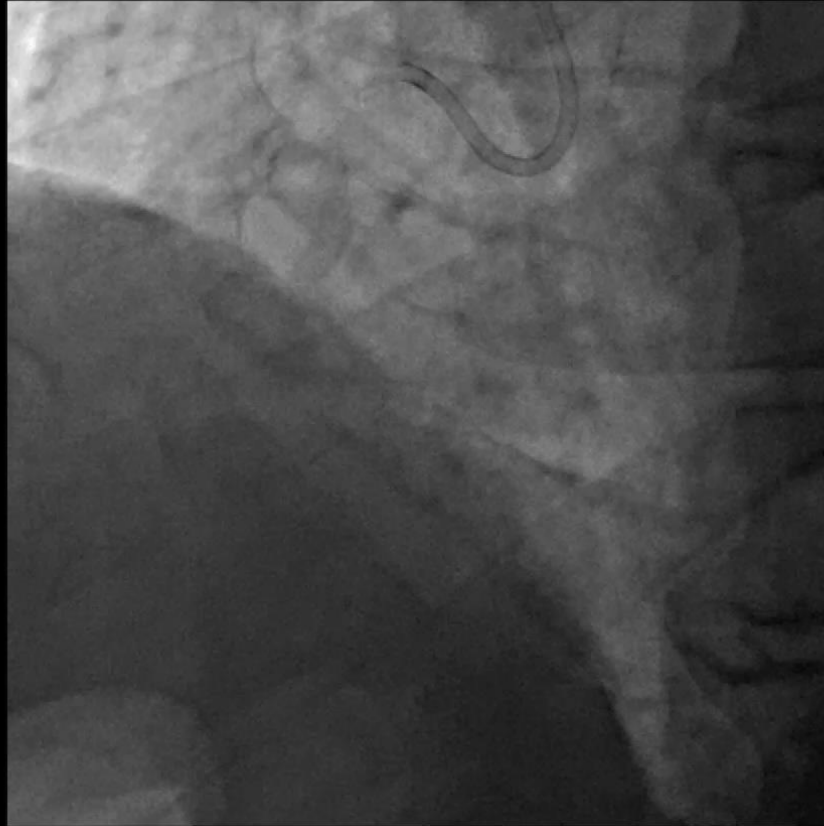
Final Results after IVUS guided Stenting



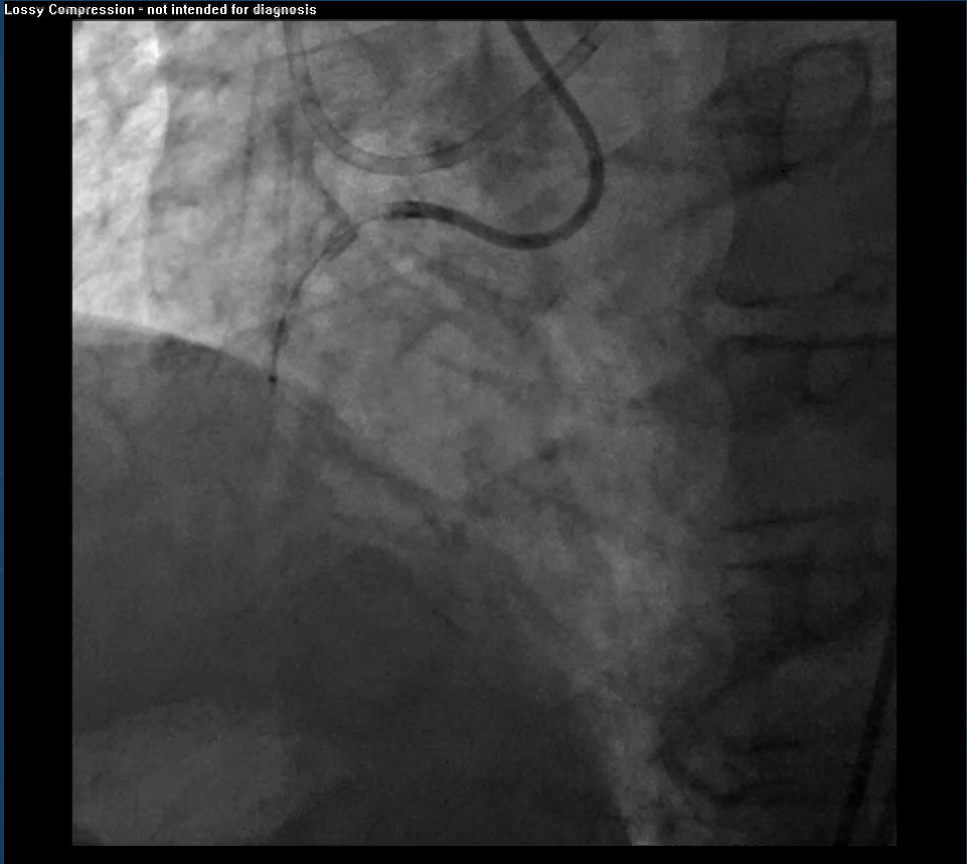
Identify Dissection Planes in Distal Bifurcations

CASE 3

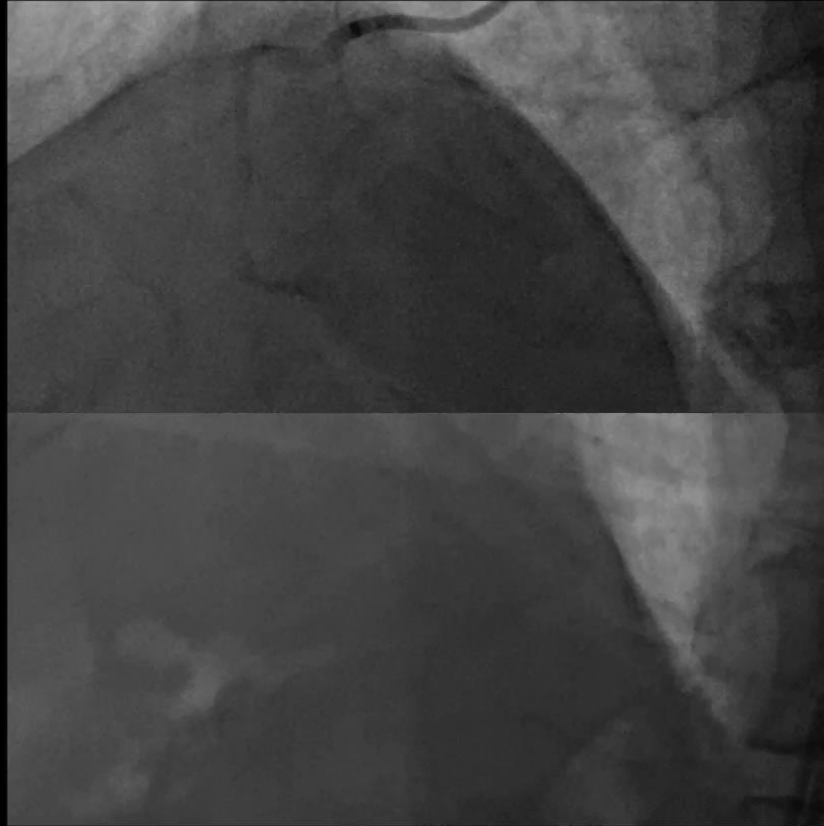
Lossy Compression - not intended for diagnosis



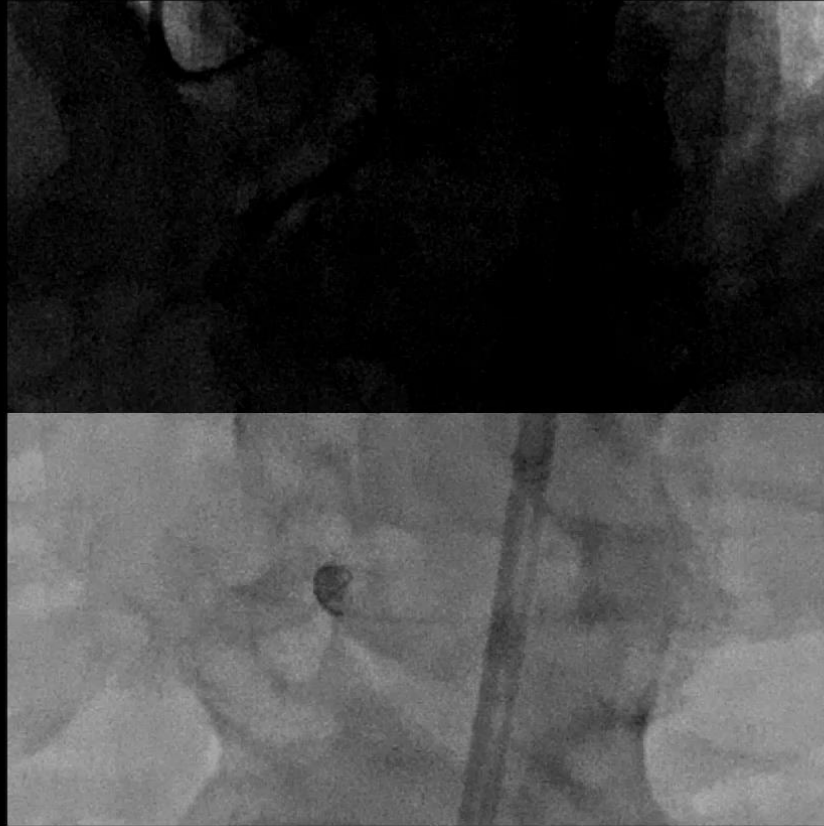
Lossy Compression - not intended for diagnosis



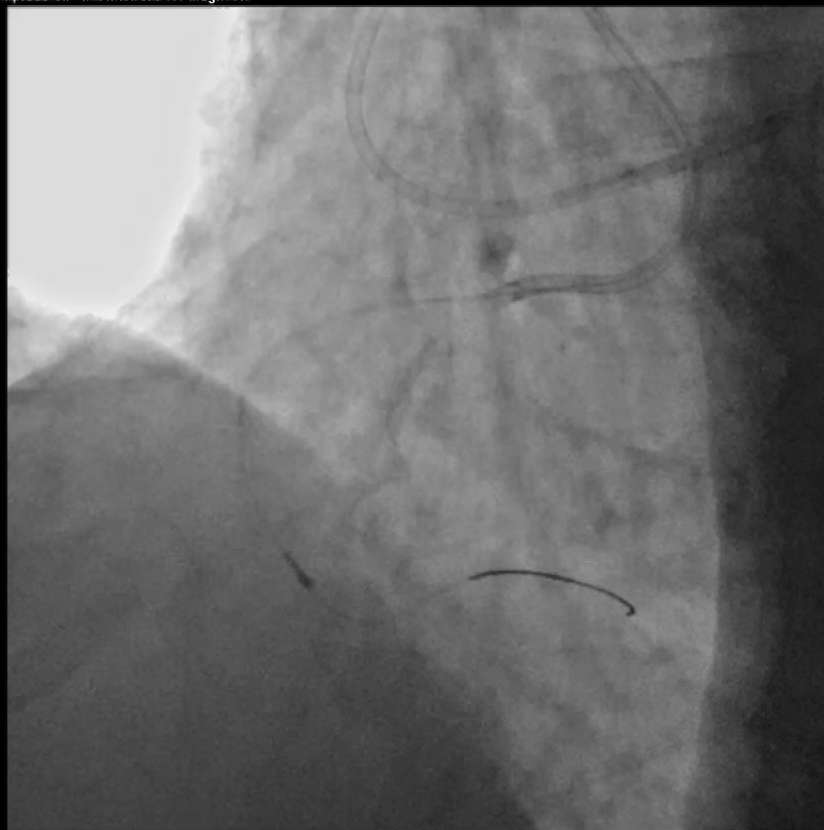Lossy Compression - not intended for diagnosis



Lossy Compression - not intended for diagnosis

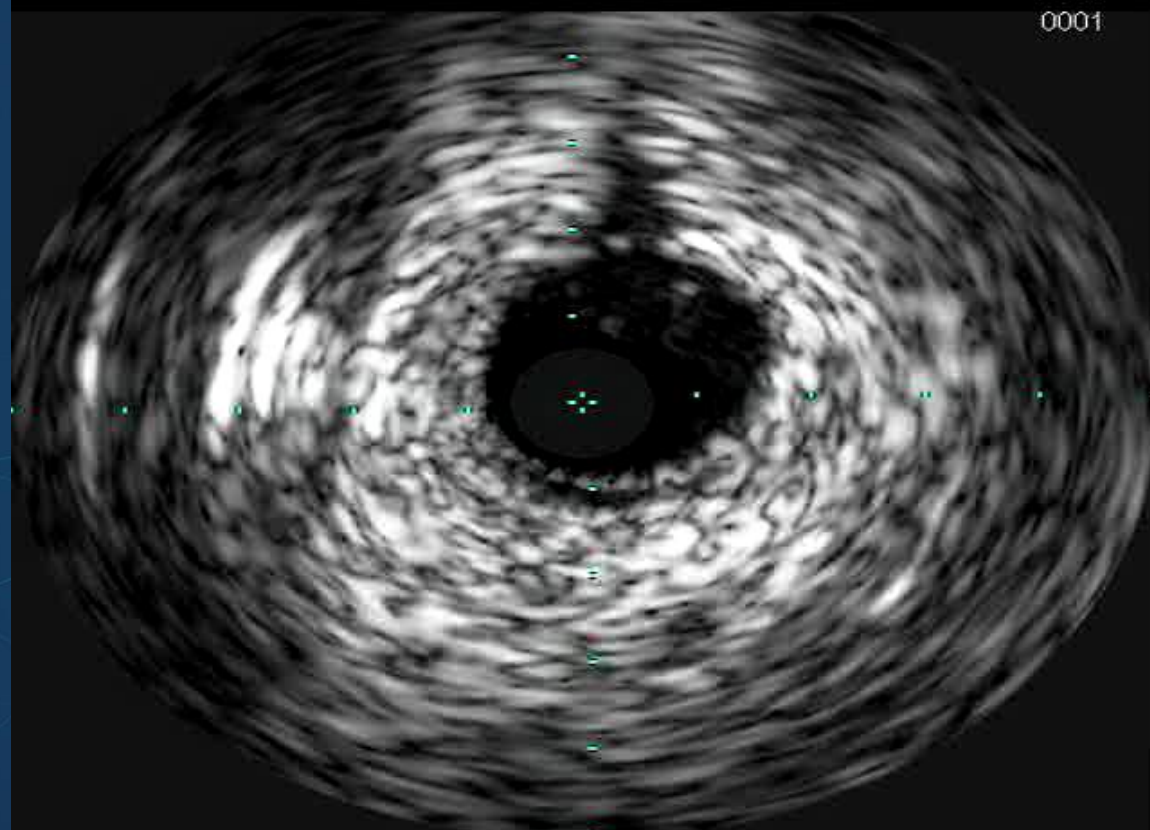


Lossy Compression - not intended for diagnosis

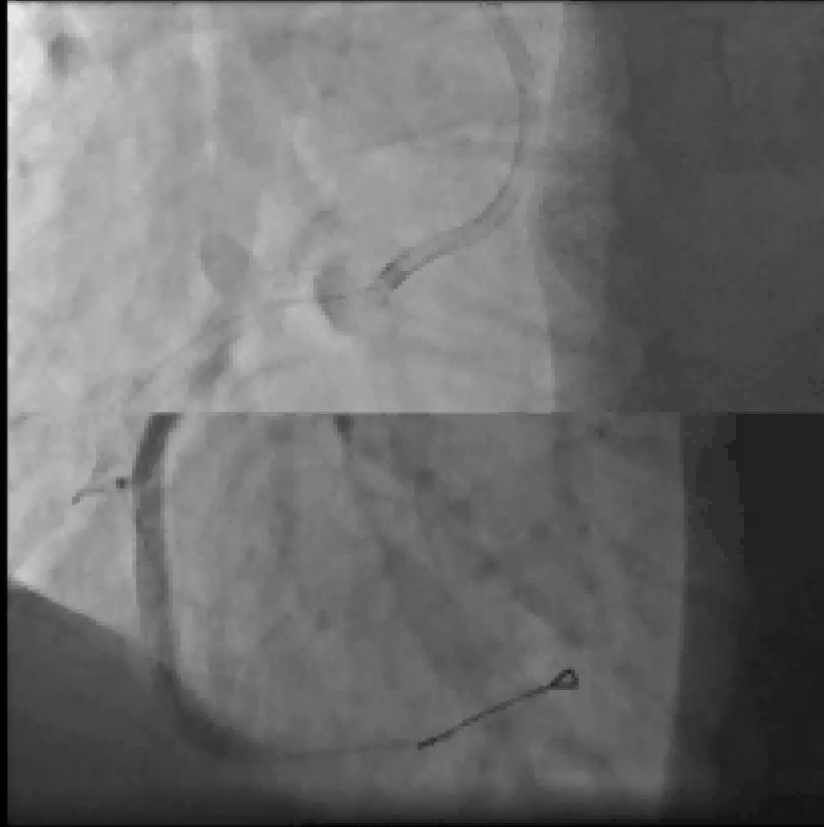


Lossy compression - not intended for diagnosis

0001

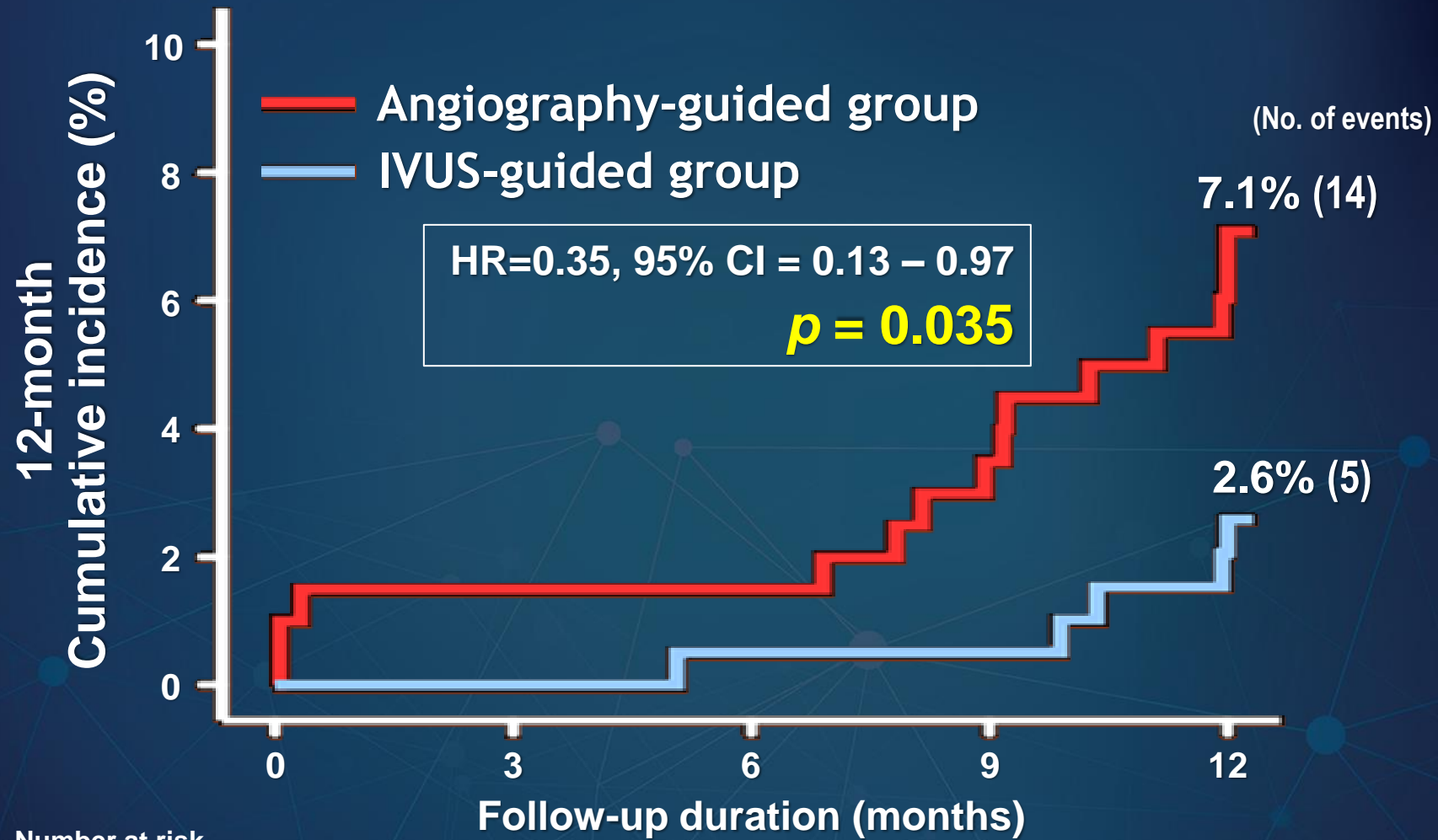


Laxay Compression - not included for diagnosis



Size STENTS After Crossing

Primary endpoint (Cardiac death, MI, TVR)



Number at risk

Angiography-guided 201

198

179

IVUS-guided 201

198

186