

**25, April 2024 TCTAP workshop**  
**CTO-PCI : To Treat, or Not To Treat**  
**Case 4. CT-guided CTO-PCI**

**Masaaki Okutsu, MD, PhD**

**Cardiovascular Medicine, New Tokyo Hospital, Japan**

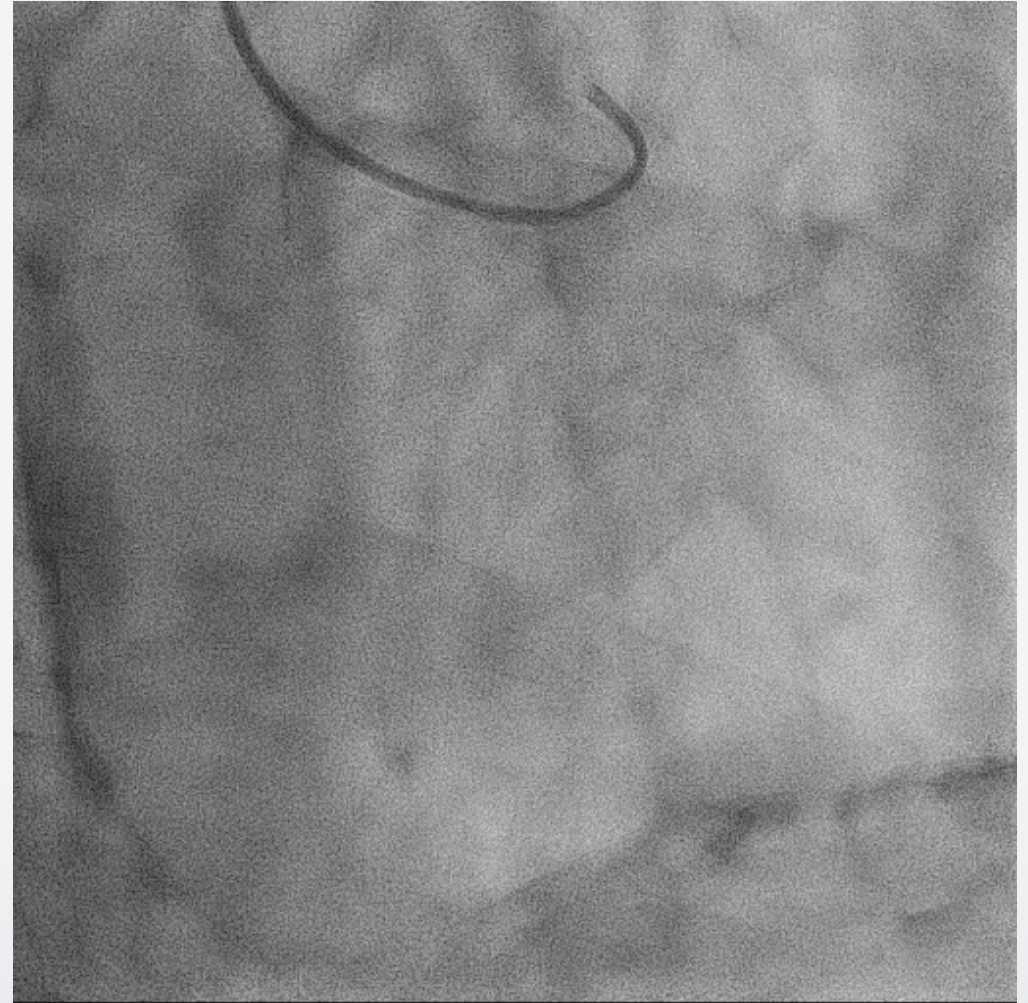
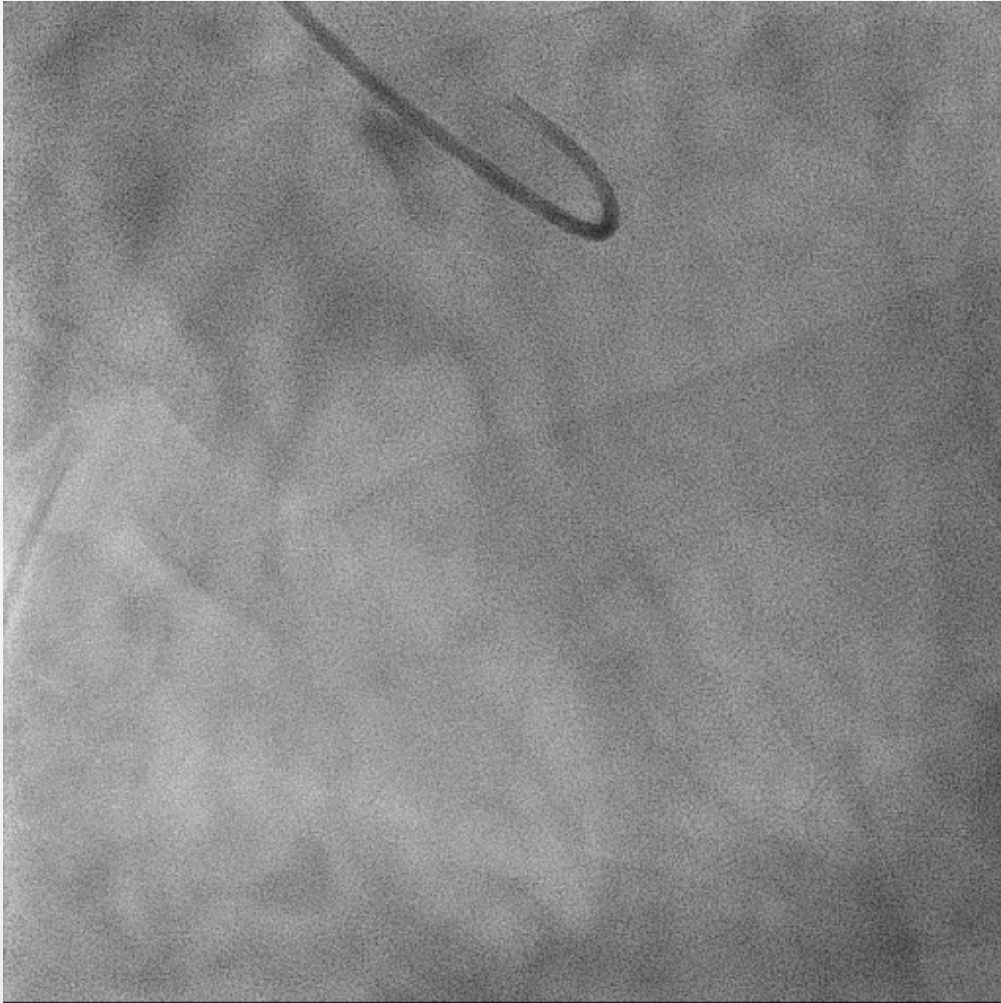
# Disclosure

- Kaneka Medics: consultant

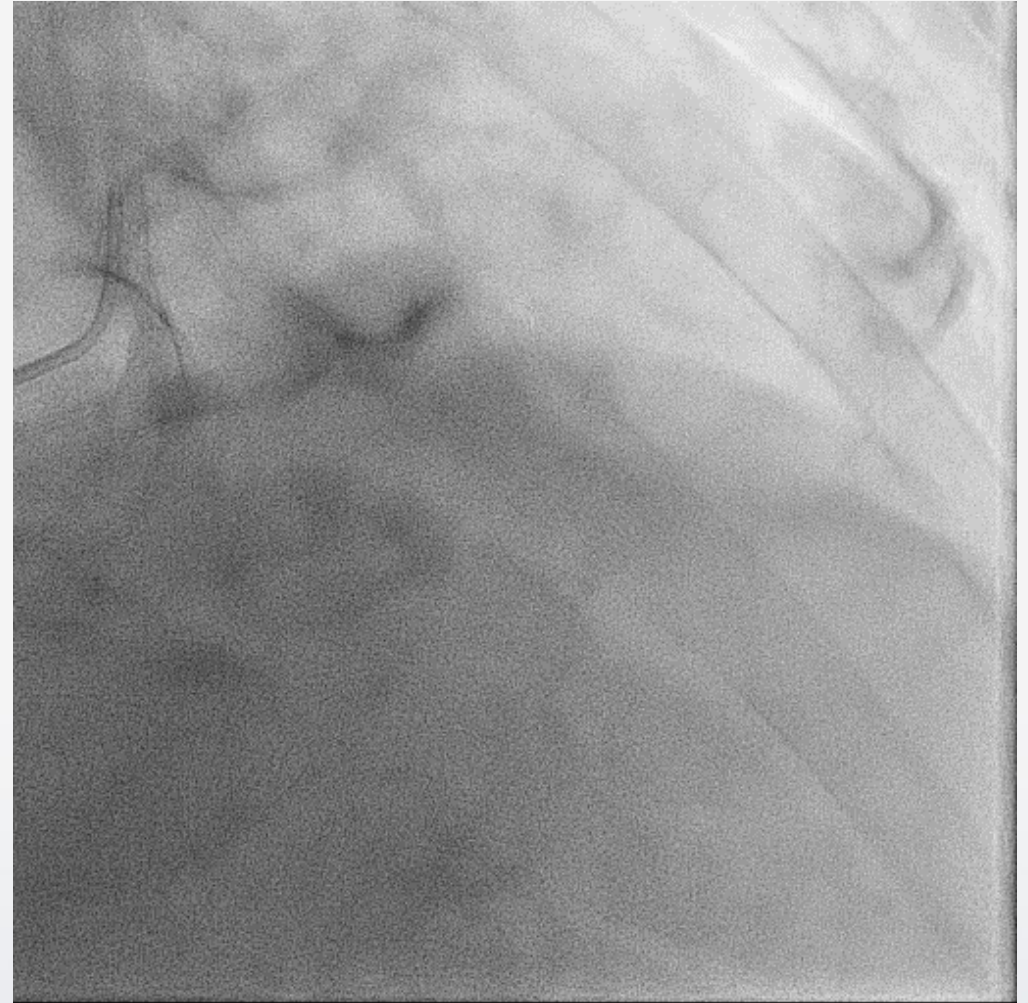
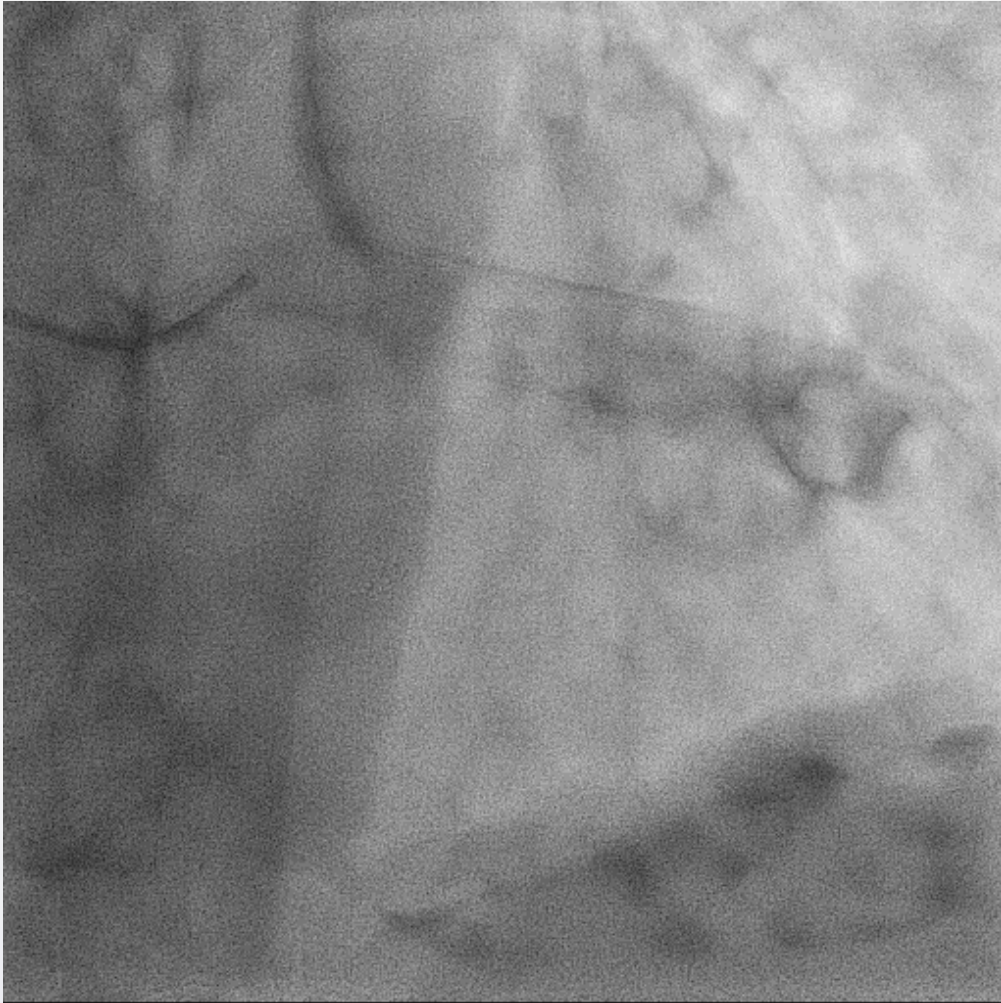# Case Information

- 69 y.o. Male
- Diagnosis: Effort angina pectoris (CCS2), 3 vessel disease
- Target lesion: CTO in mid RCA
- 1<sup>st</sup> PCI: prox-mid LAD: Xience Skypoint 3.0\*48mm
- UCG: diffuse hypokinesis, LVEF:45%, Moderate MR
- Cr: 0.9mg/dl, eGFR:65mL/min/1.73m<sup>2</sup>
- Coronary risk factor: Hypertension, Dyslipidemia, Diabetes Mellitus

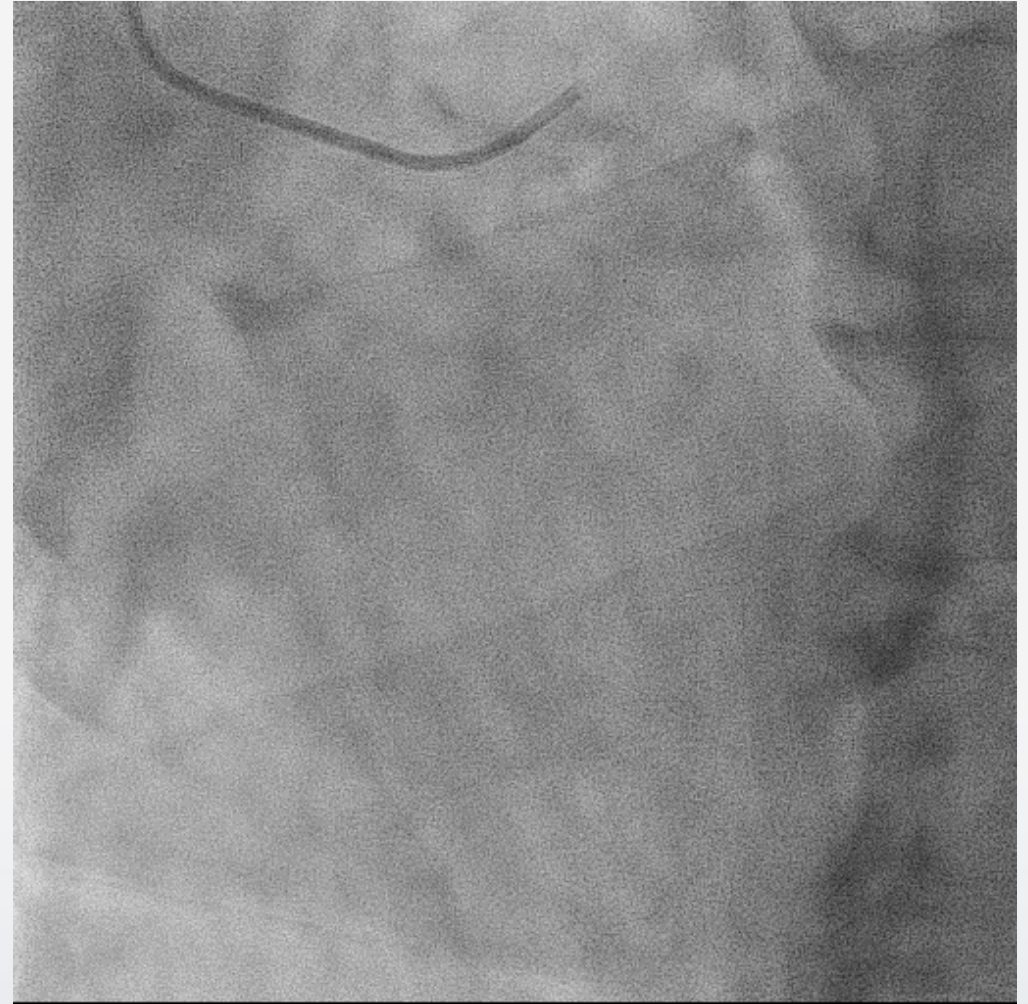
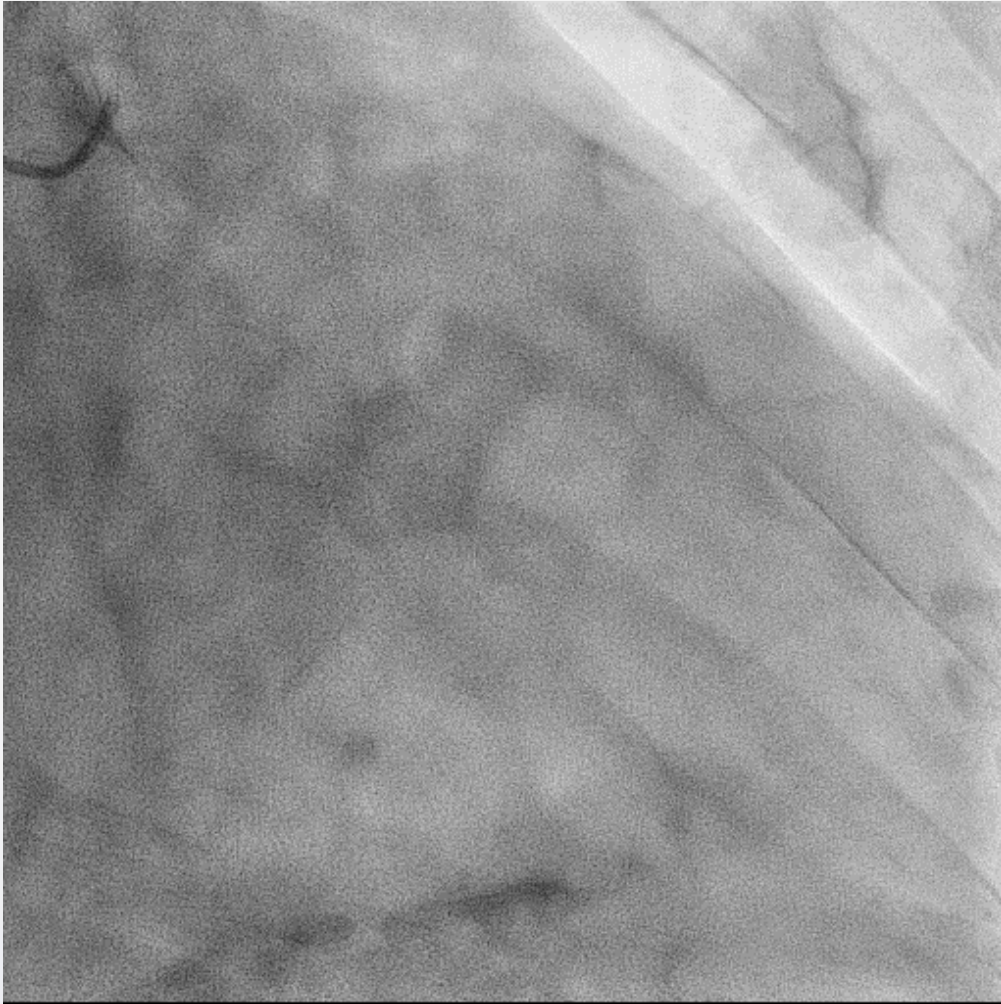# CAG



# CAG

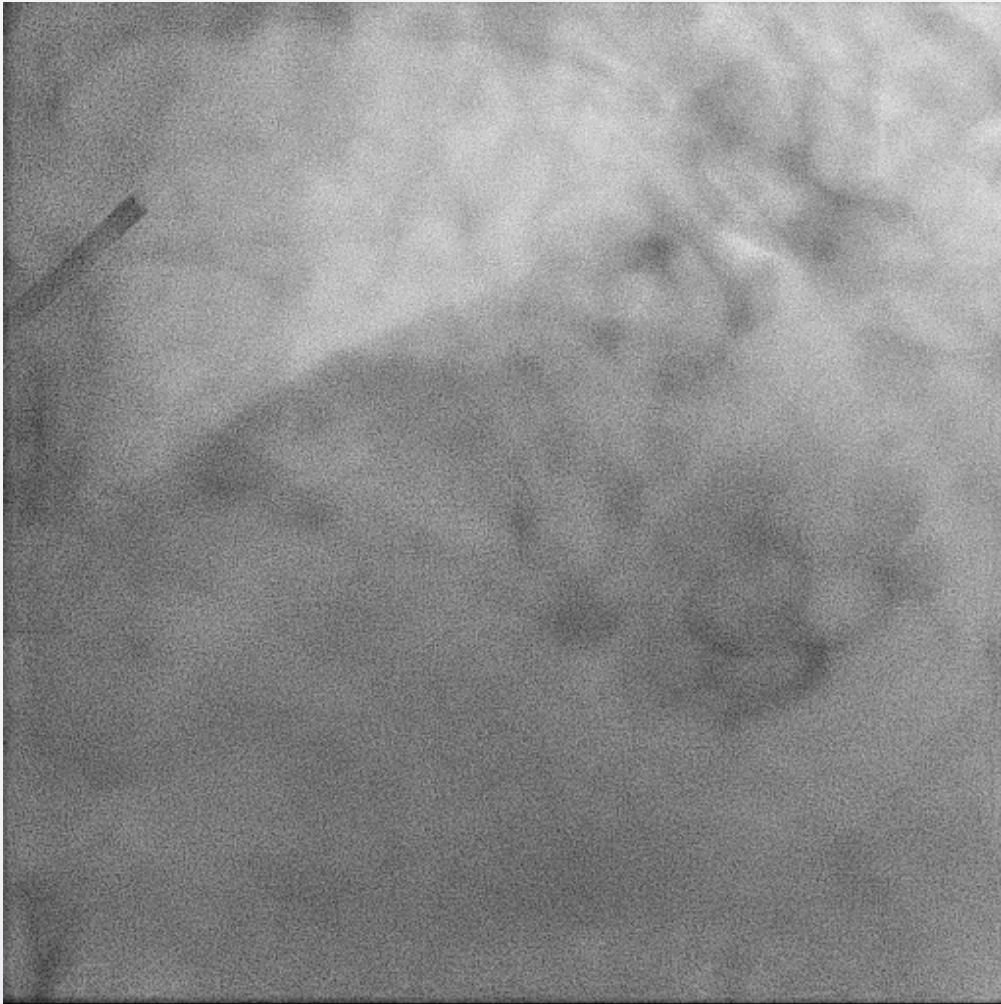

# CAG

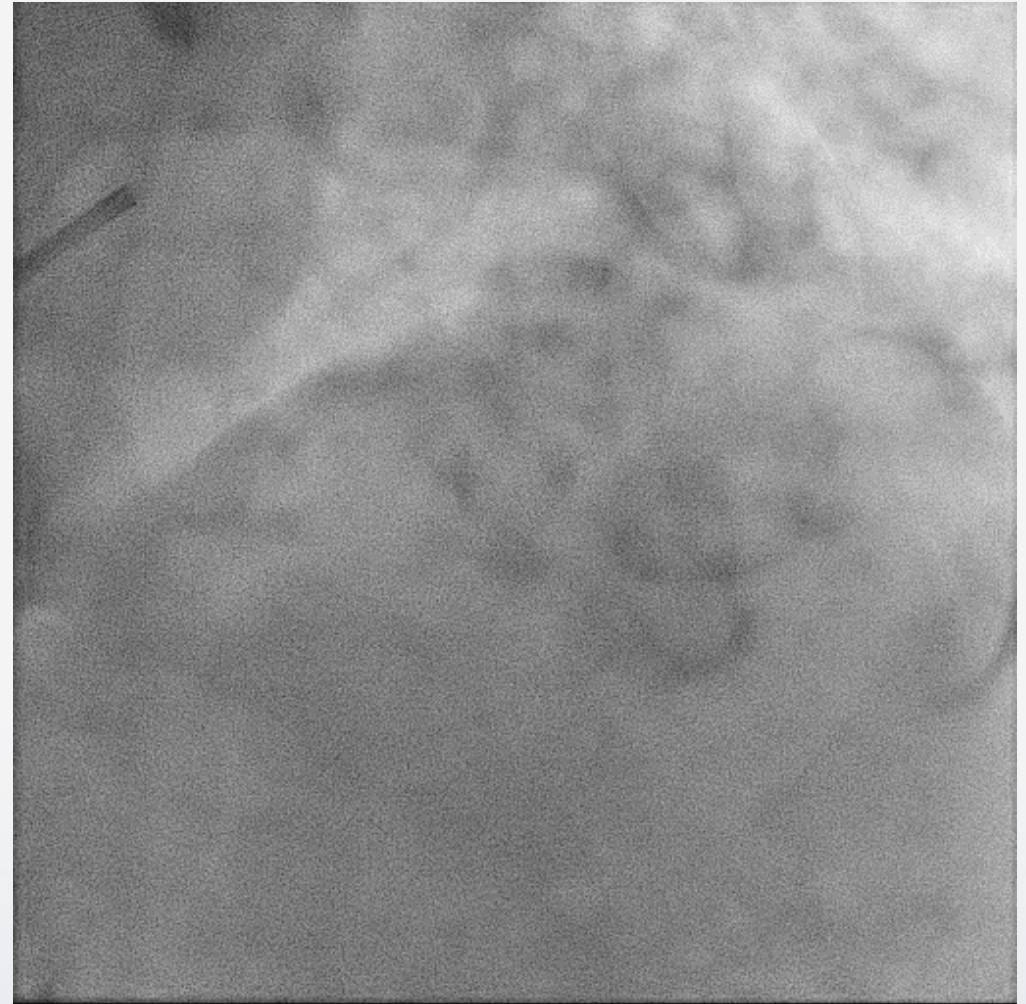

# 1<sup>st</sup> PCI for LAD

*Pre PCI*

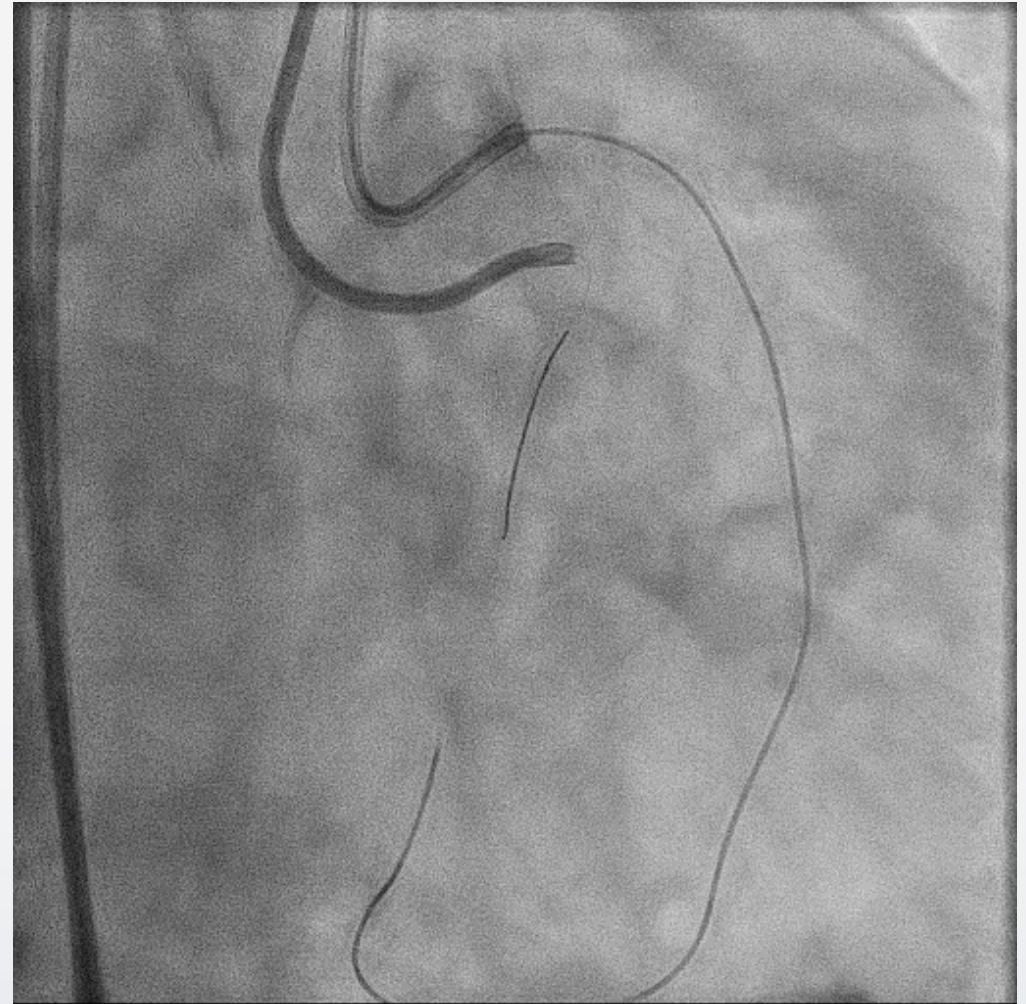
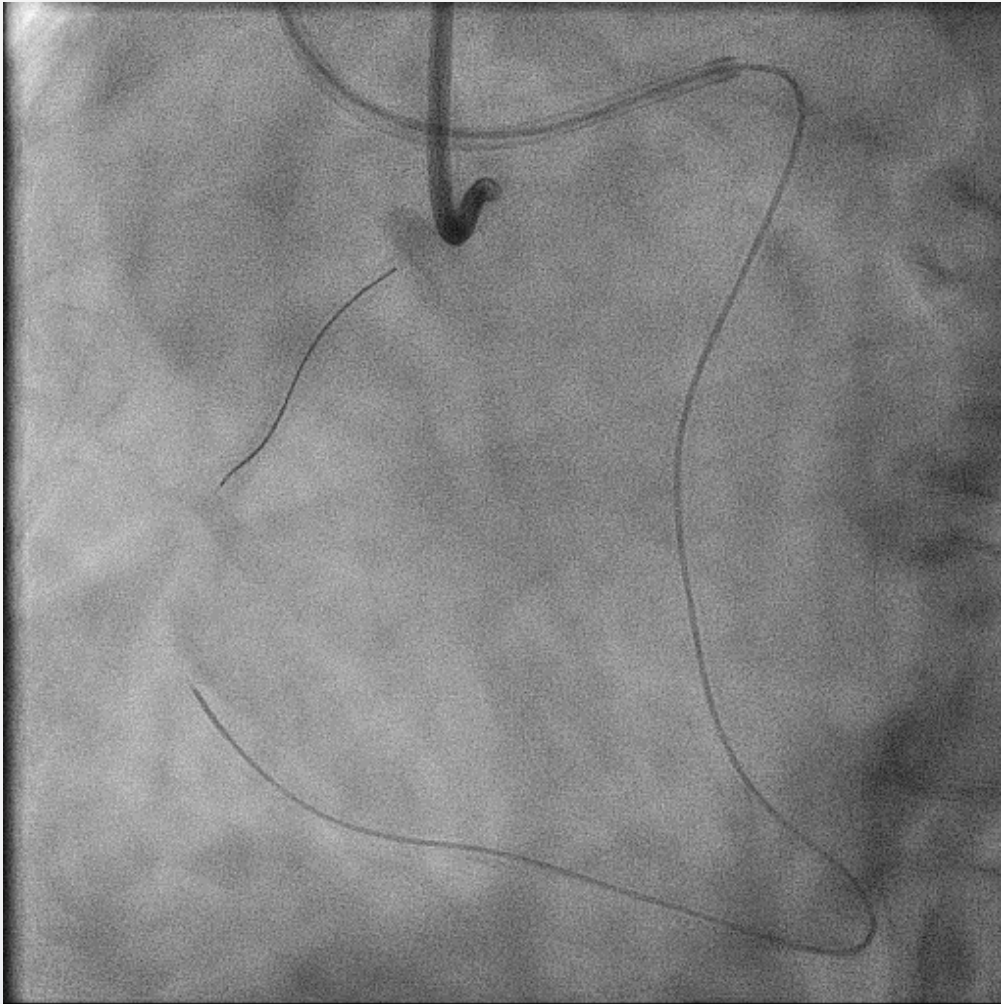


*Post PCI*



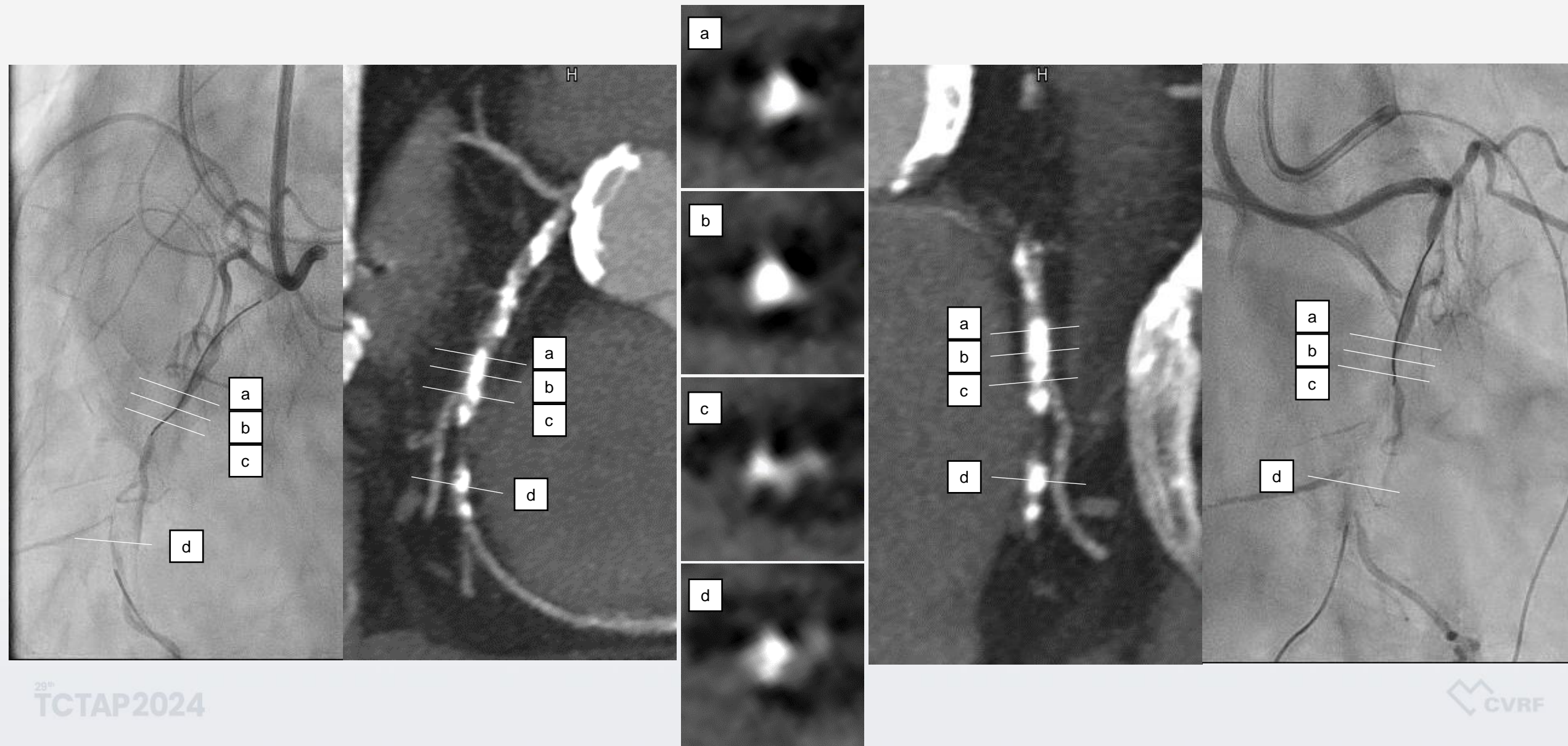
# PCI for RCA CTO

*Ante-GC: 7Fr.Hyperion SAL1.0 / Retro-GC: 7Fr.Hyperion SPB4.0SH*

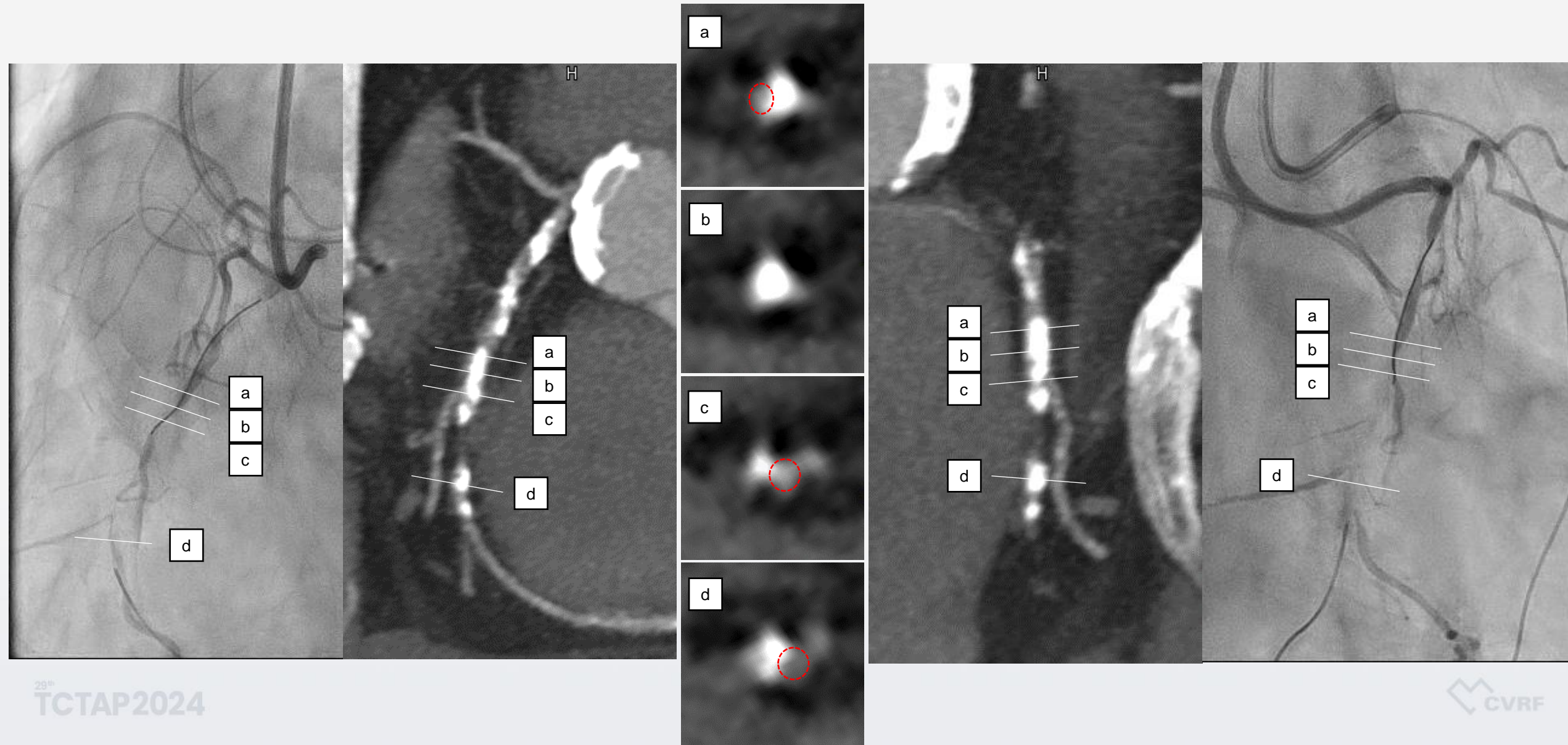




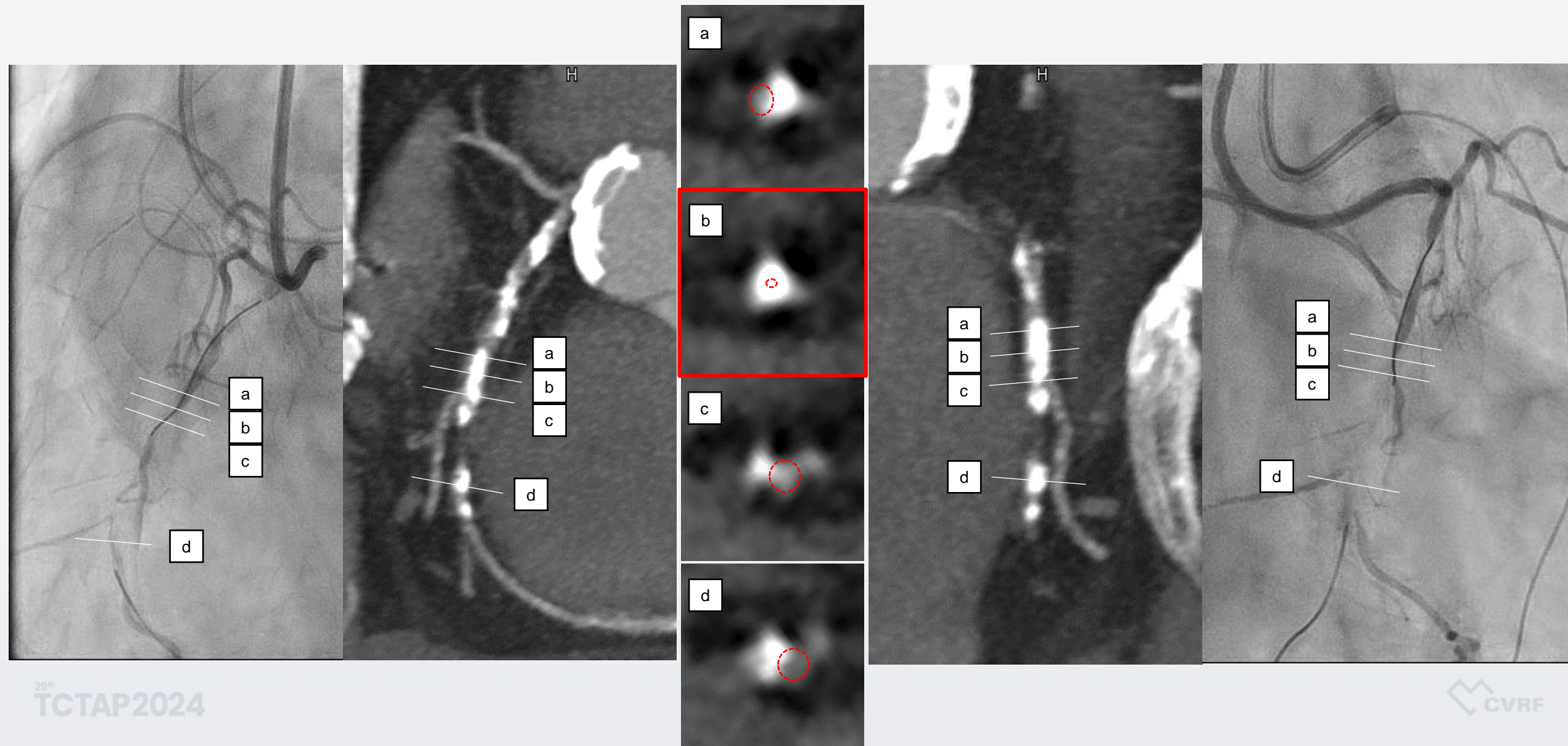
# CT analysis of Calcium



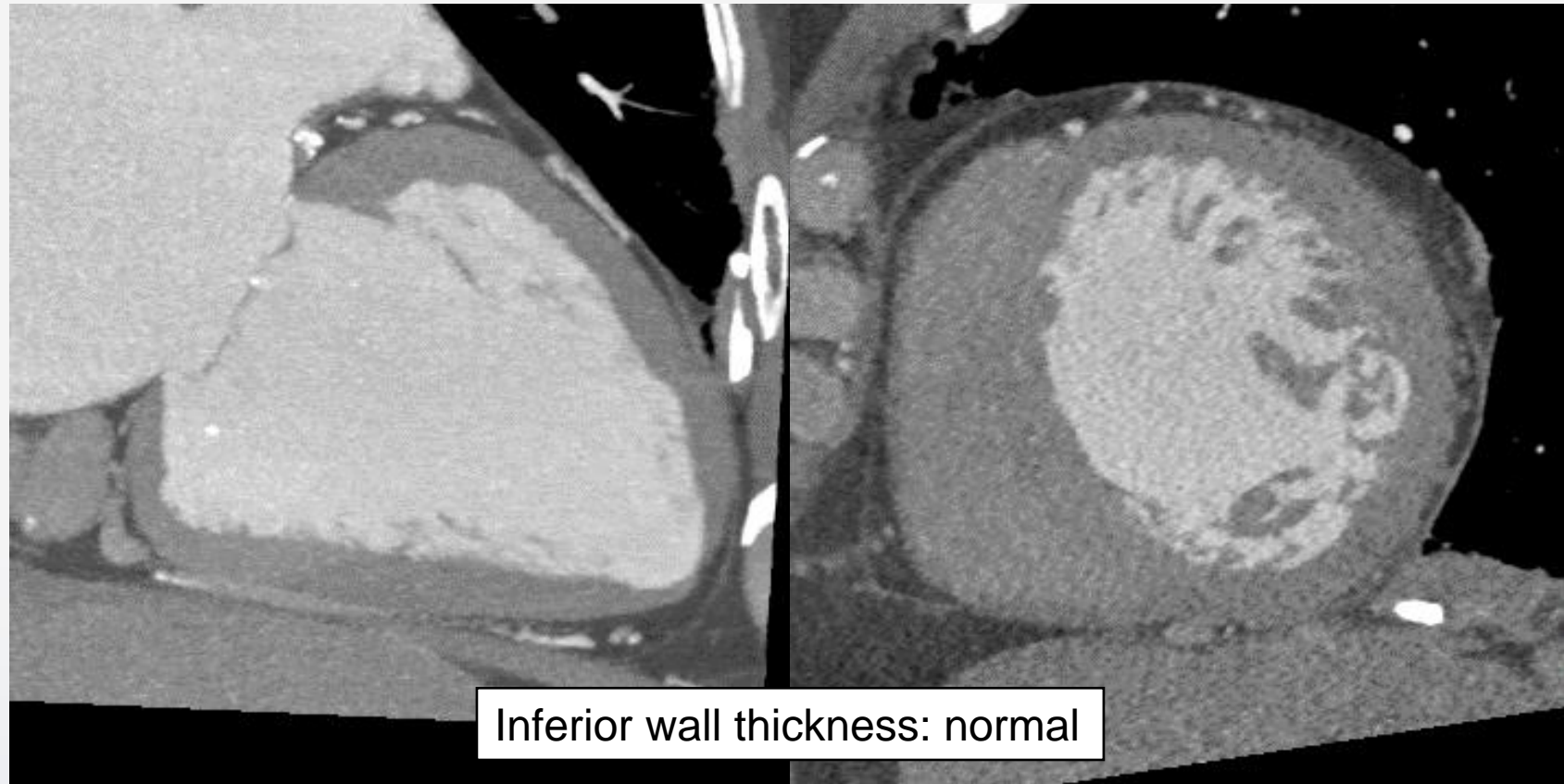
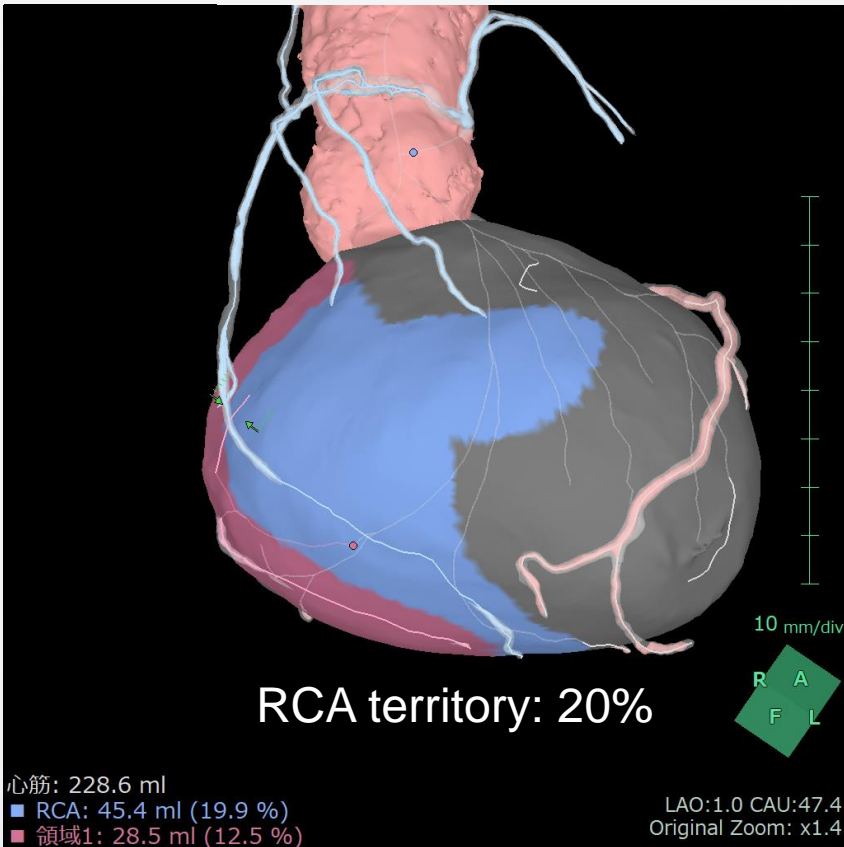
# CT analysis of Calcium



# CT analysis of Calcium

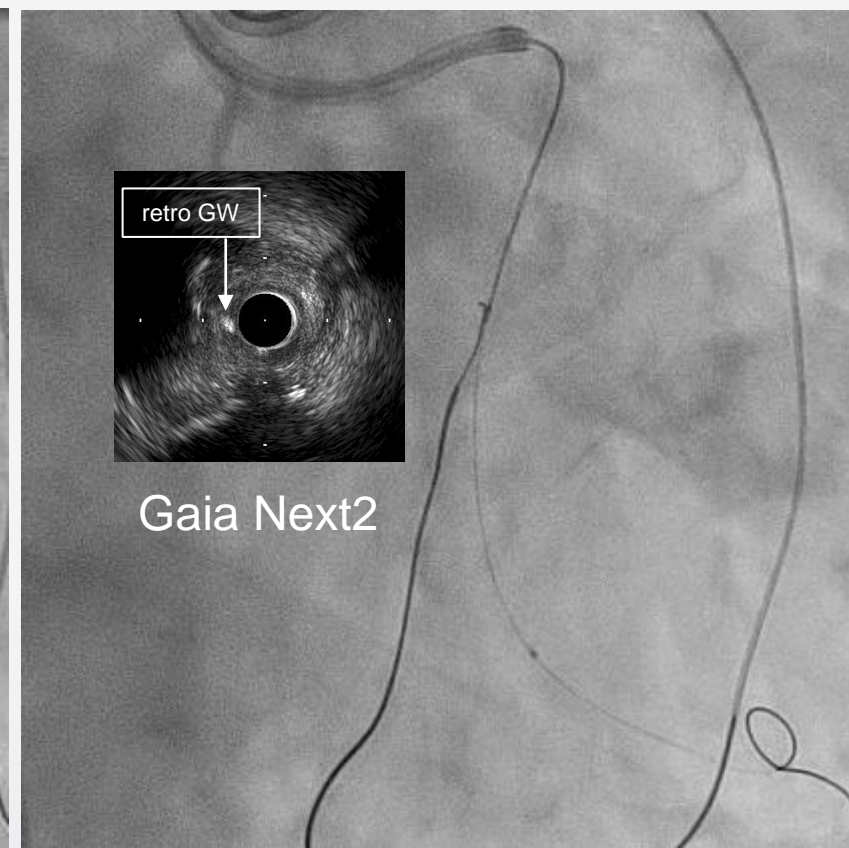
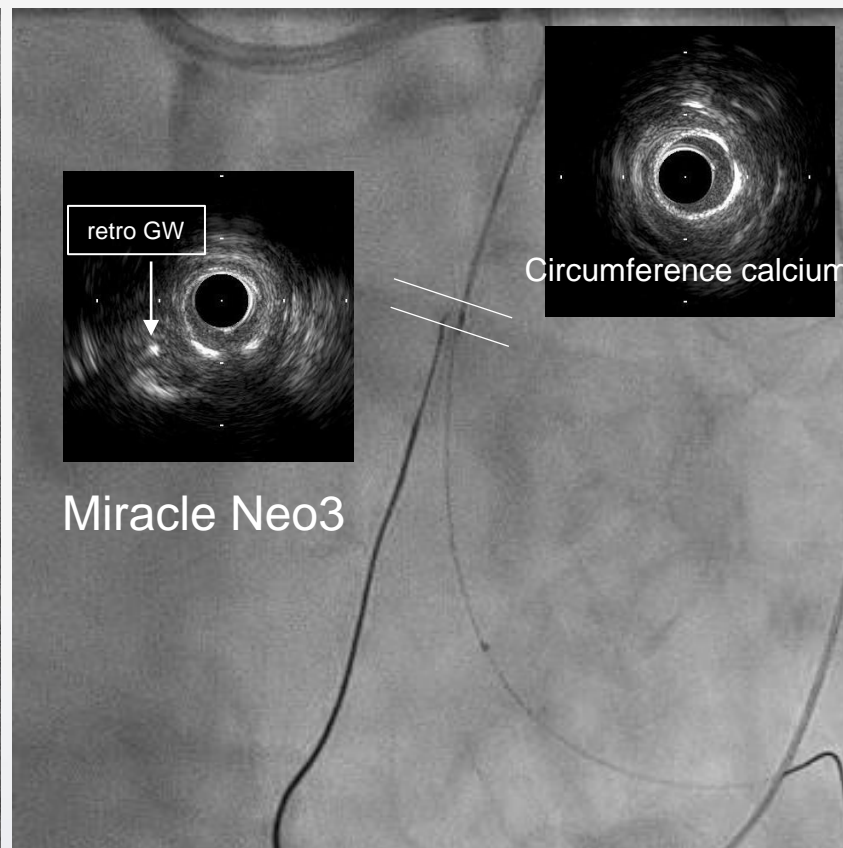
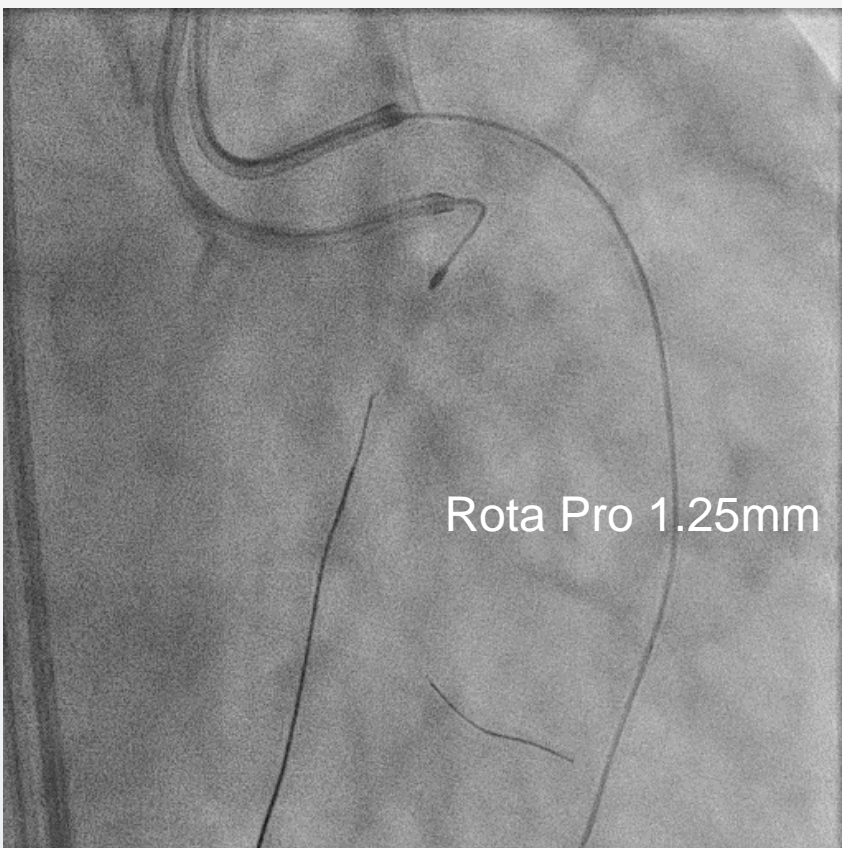


# CT analysis of CTO-vessel territory and viability



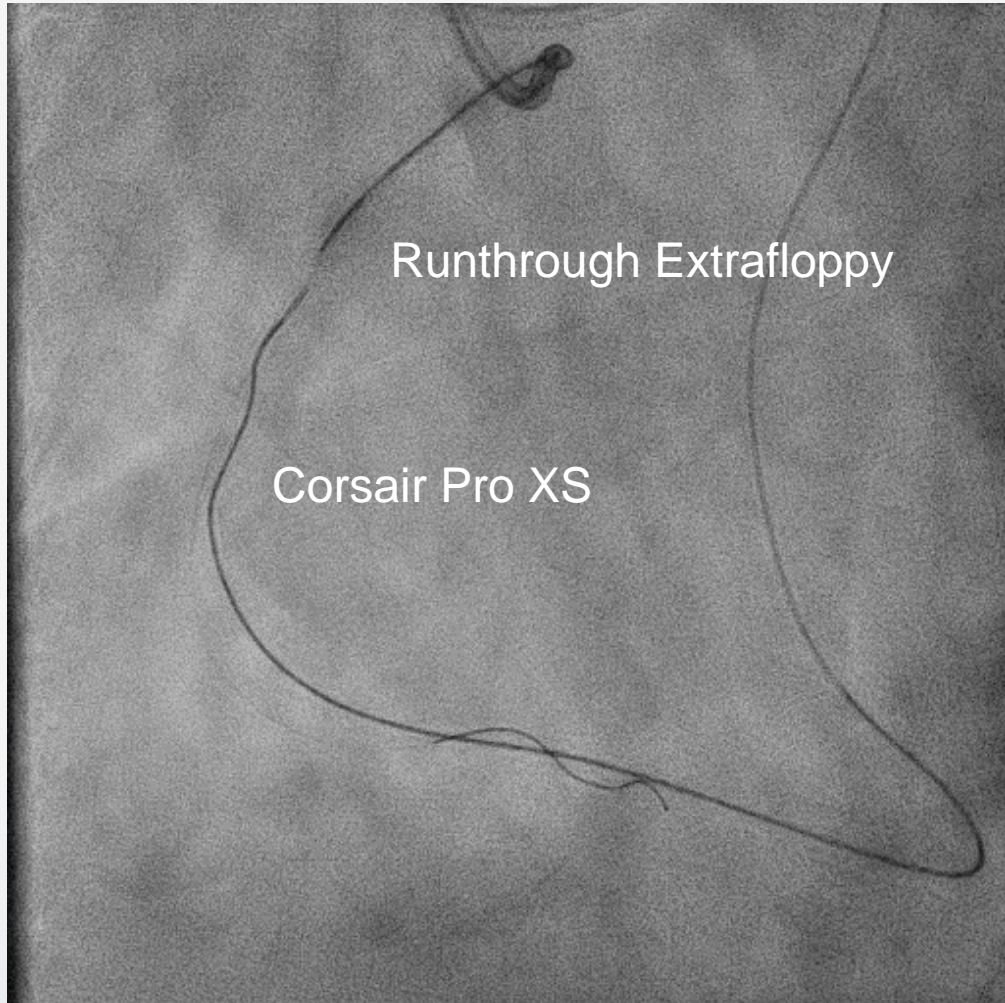
# Retrograde wire cross

*After advancement of retro-GW (Miracle Neo3) to near the CTO proximal cap, antegrade IVUS, 1.5mm balloon and Tornus Pro could not pass to RV branch...*

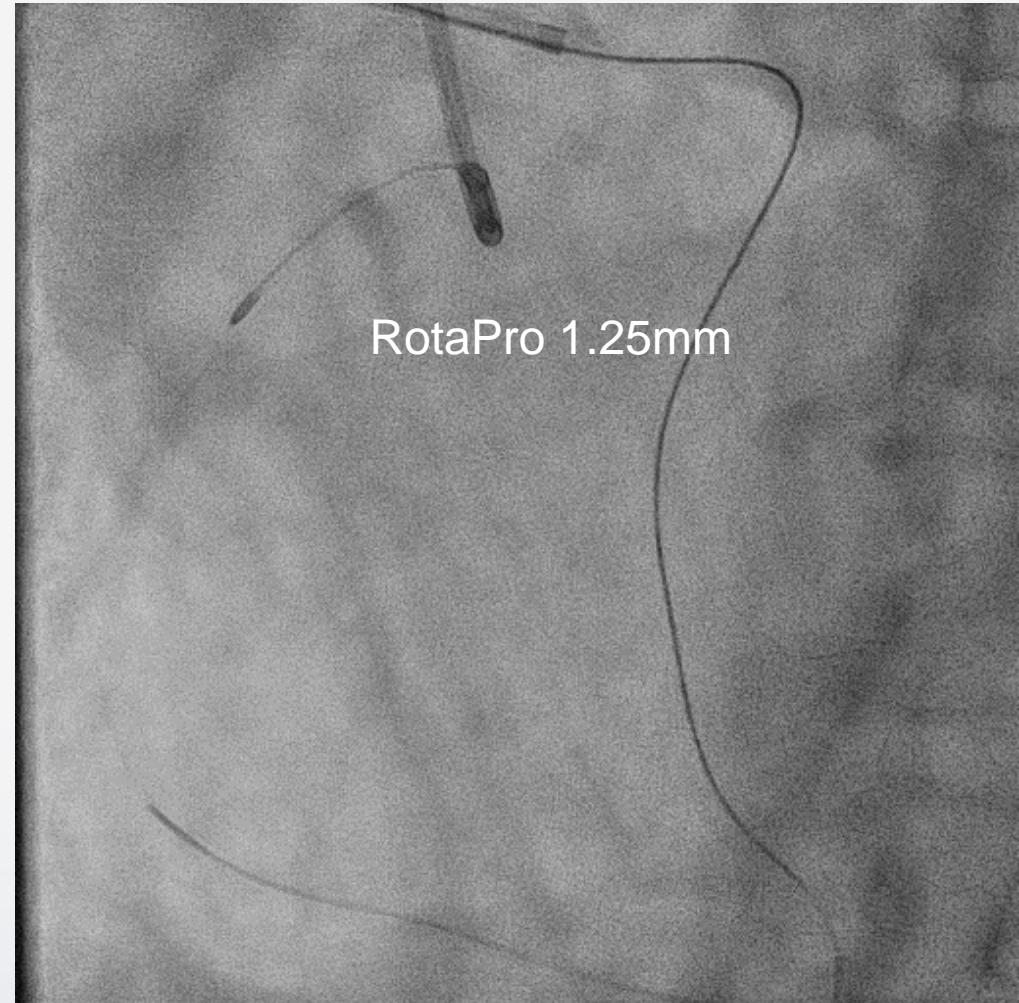


# Rendezvous wiring and Rotablator

*Retro-Corsair Pro XS could not pass to proximal lumen blocking by calcification...*



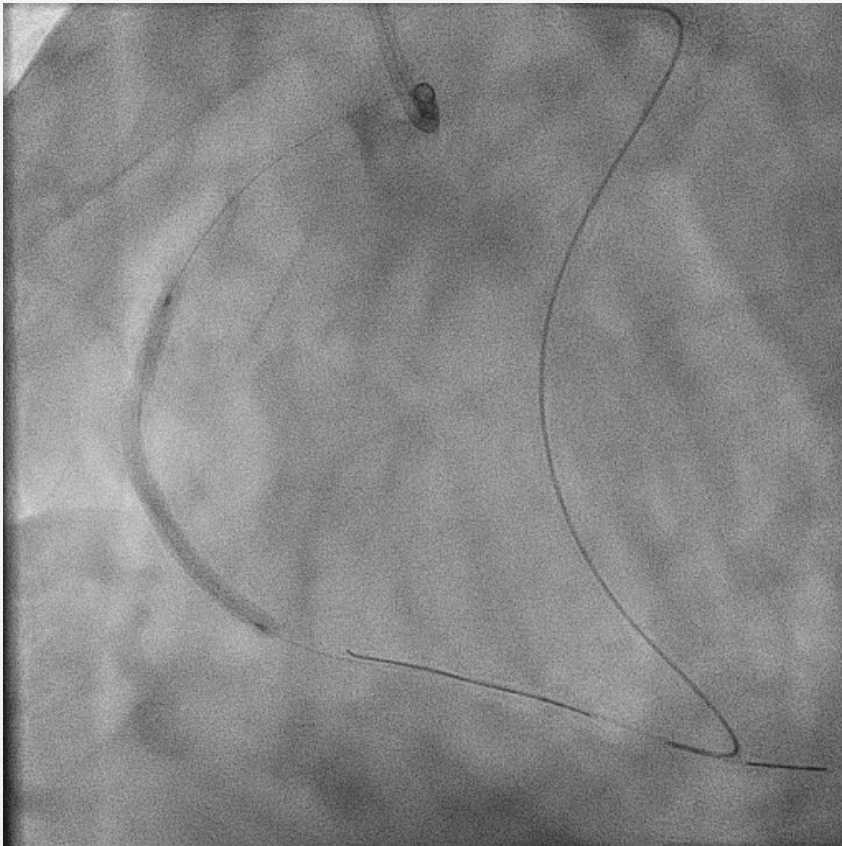
*Antegrade IVUS and 1.5mm balloon could not pass the lesion...*



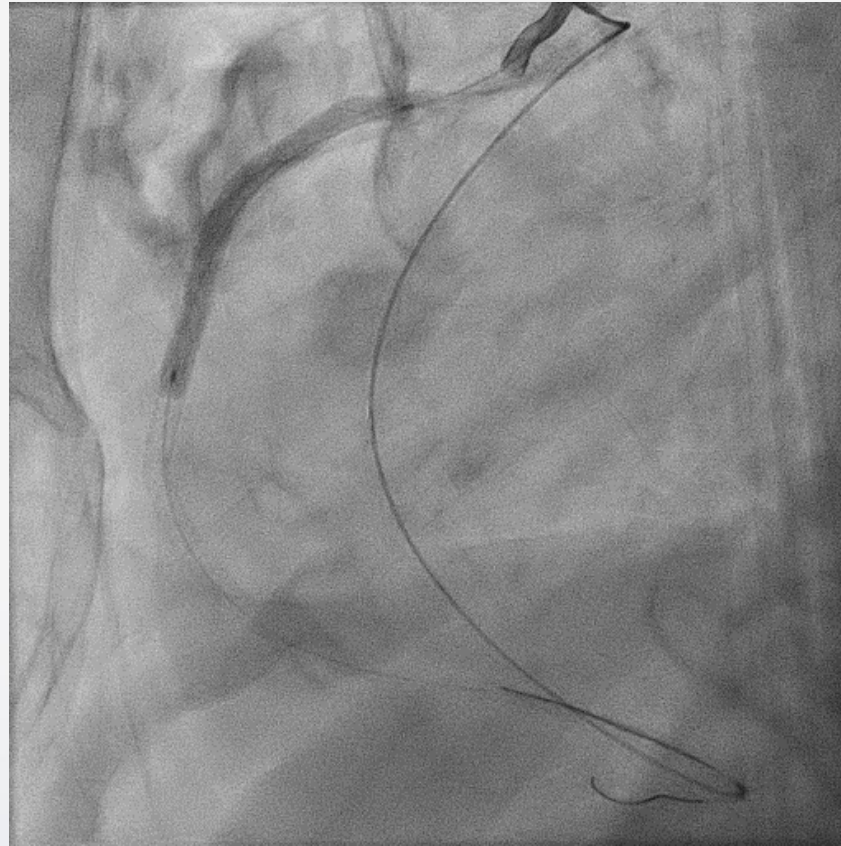
# Stenting

*After pre-dilatation by 2.5mm balloon...*

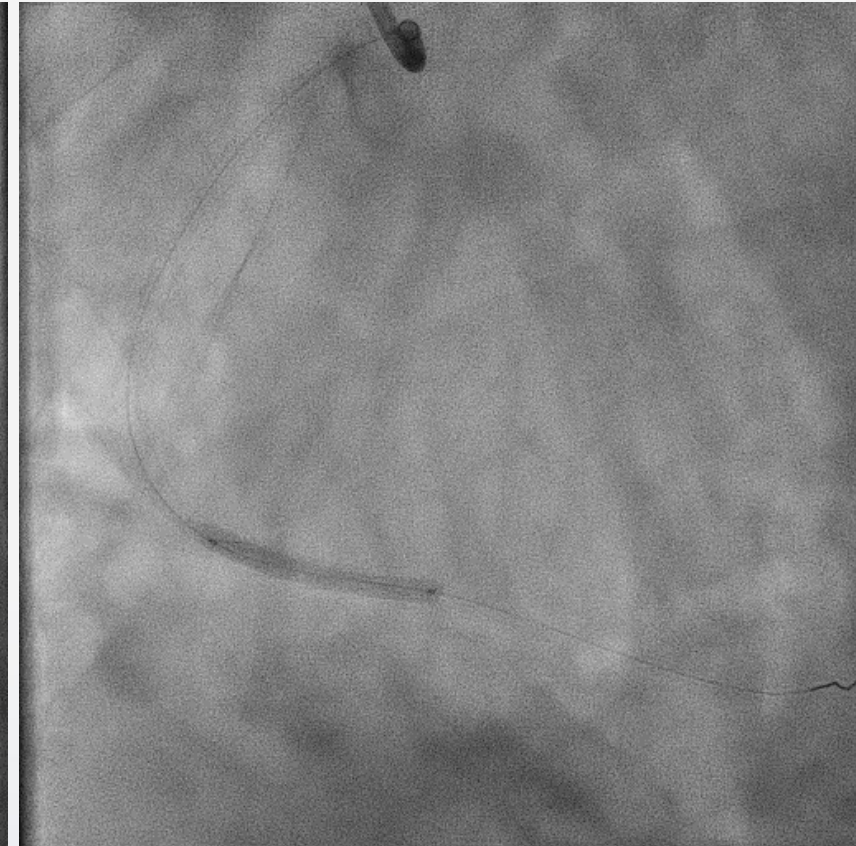
Xience Skypoint 2.5\*48mm



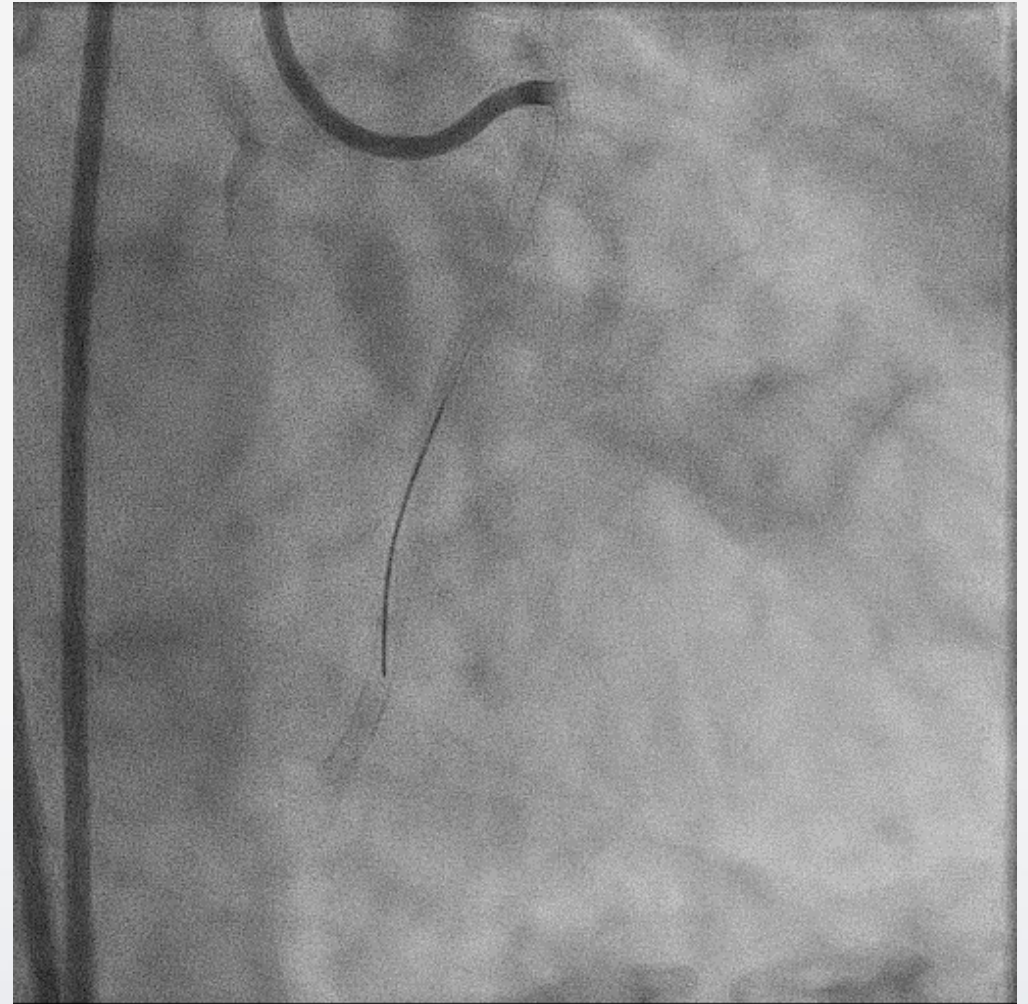
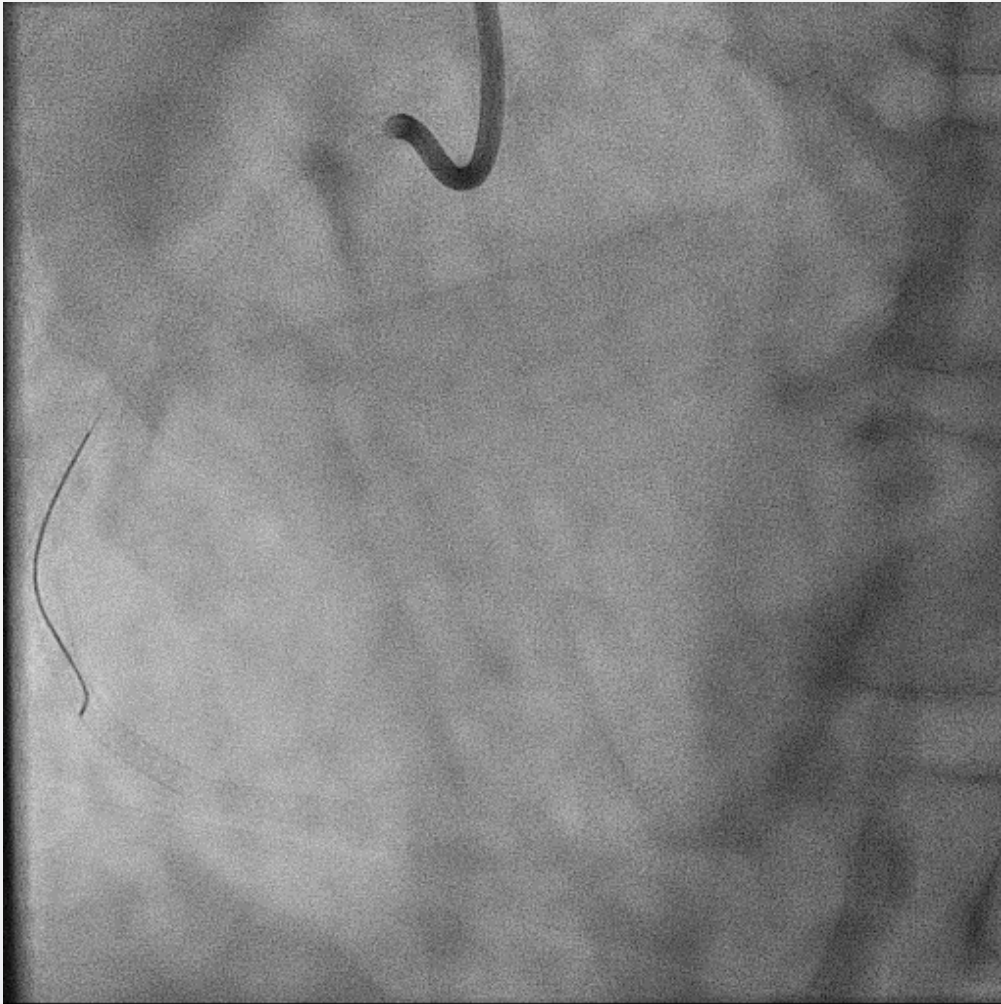
Xience Skypoint 3.0\*48mm



Xience Skypoint 2.5\*28mm



# Final CAG





## Practical utilization of cardiac computed tomography for the success in complex coronary intervention

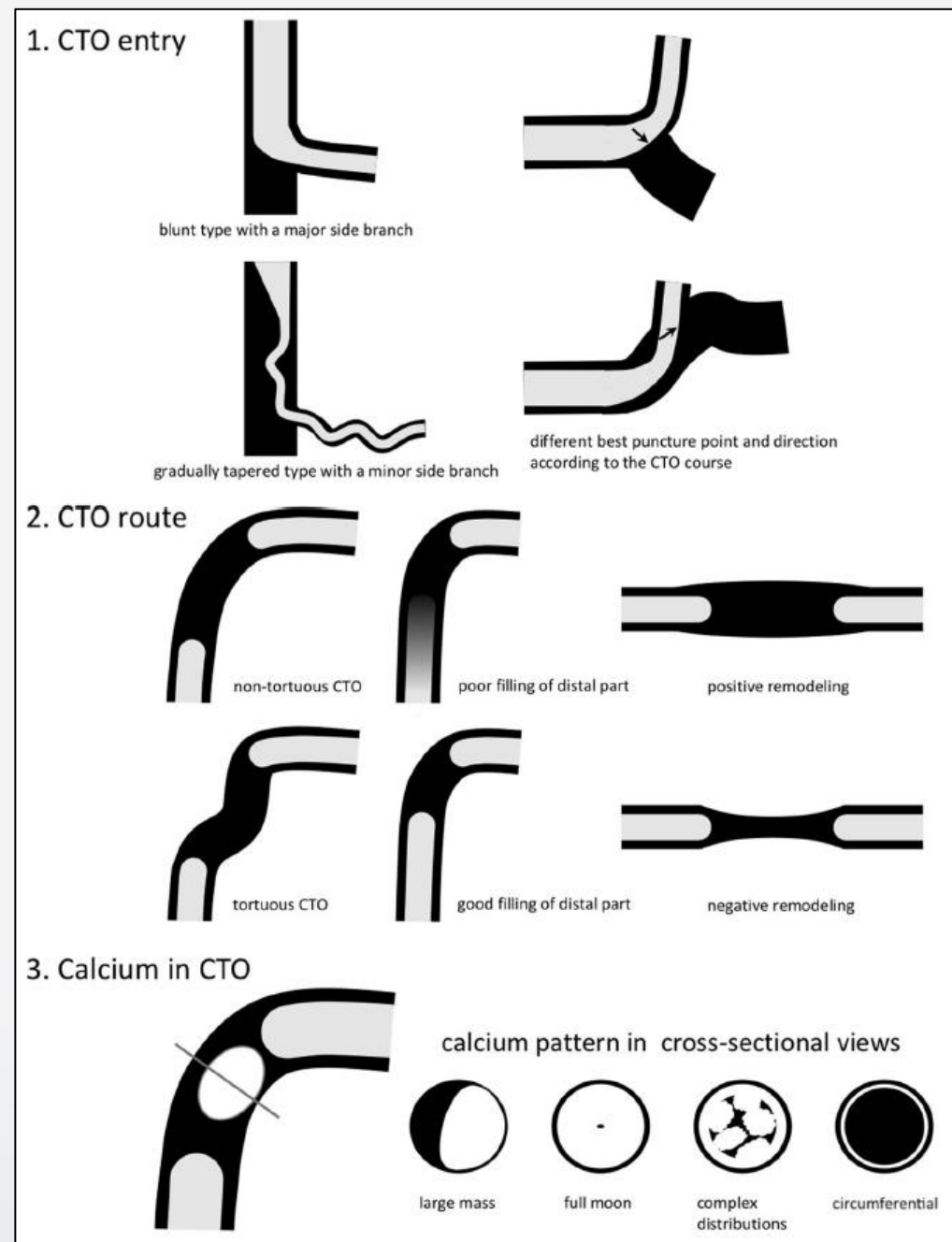
Kenji Sadamatsu<sup>1</sup> · Masaaki Okutsu<sup>2</sup> · Satoru Sumitsuji<sup>3</sup> · Tomohiro Kawasaki<sup>4</sup> · Sunao Nakamura<sup>2</sup> · Yoshihiro Fukumoto<sup>5</sup> · Kenichi Tsujita<sup>6</sup> · Shinjo Sonoda<sup>7</sup> · Yoshio Kobayashi<sup>8</sup> · Yuji Ikari<sup>9</sup>

# 3 Keywords

🔑 Entry

🔑 Route

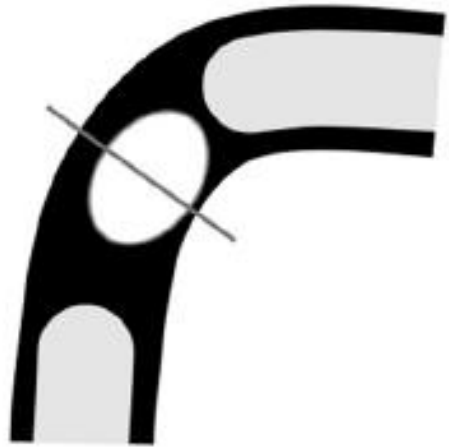🔑 Calcification



(Sadamatsu K, Okutsu M et al, Cardiovasc Interv Ther. 2021)

# 3rd : Calcification

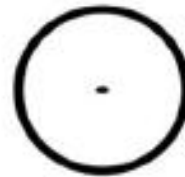
## 3. Calcium in CTO



calcium pattern in cross-sectional views



large mass



full moon



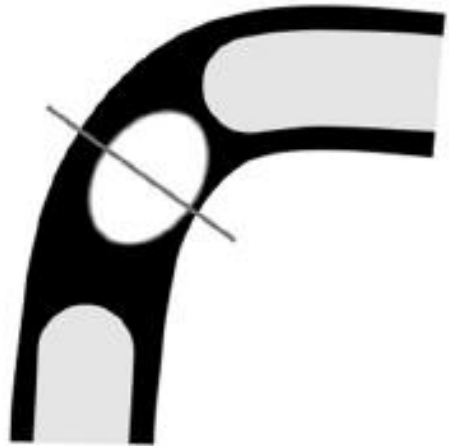complex distributions



circumferential

# 3rd : Calcification


## 3. Calcium in CTO



calcium pattern in cross-sectional views



large mass



full moon



complex distributions



circumferential

# Don't underestimate a small enemy!

