



**Imaging and Physiology Summit
November, 21th, 2009**



Huge Aneurysm Formation with Stent Dislocation after Implantation of Two TAXUS Stents

**Young Joon Hong
The Heart Center of Chonnam National University Hospital,
Gwangju, Korea**

64-Year-Old Male

CC Chest discomfort

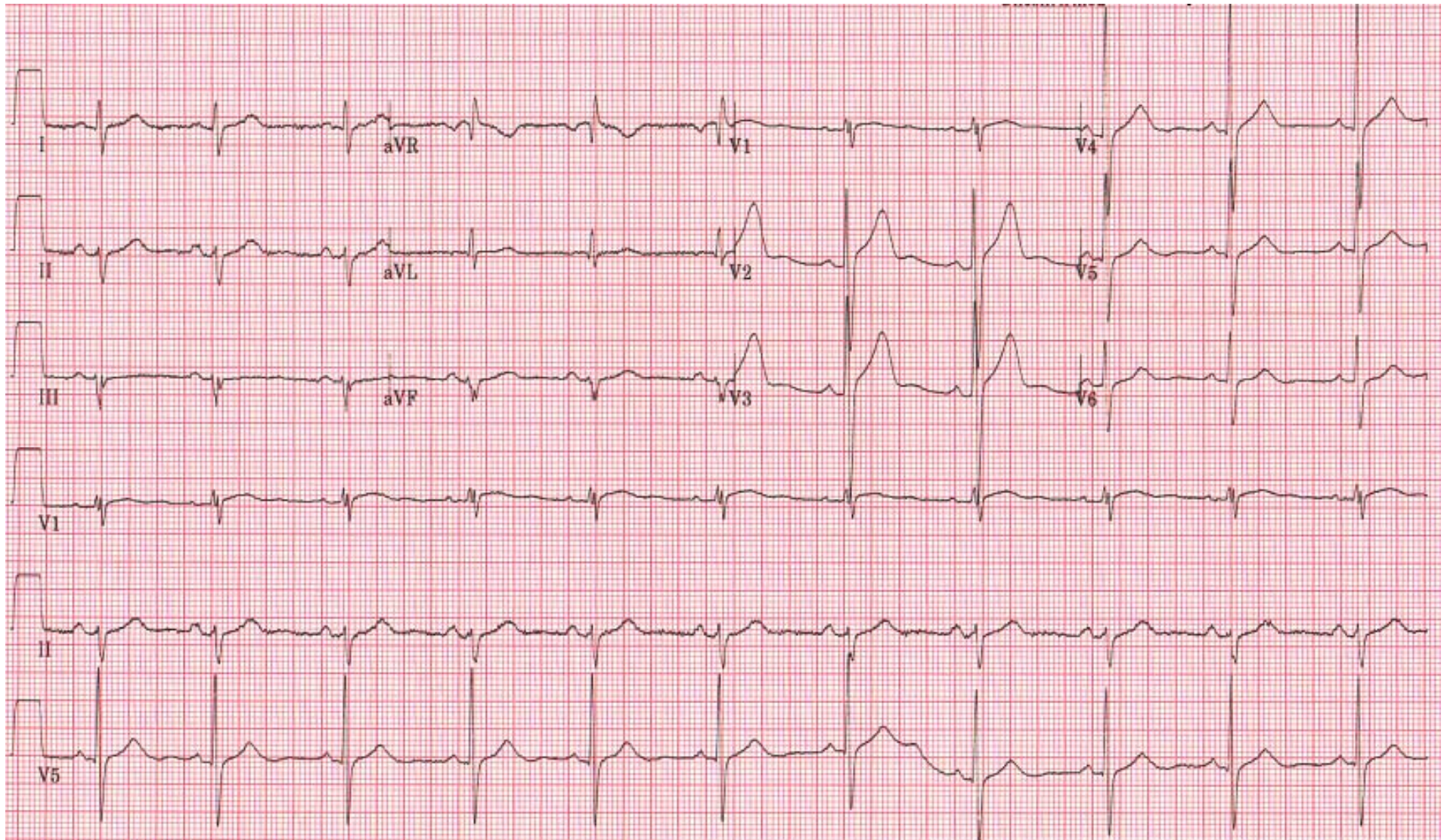
PH HT (-), DM (-)

SH Smoking: 40 PYS current smoker
Alcohol: social drinker

FH Negative for CAD

VS BP 130/80 mmHg, PR 65 beats/min

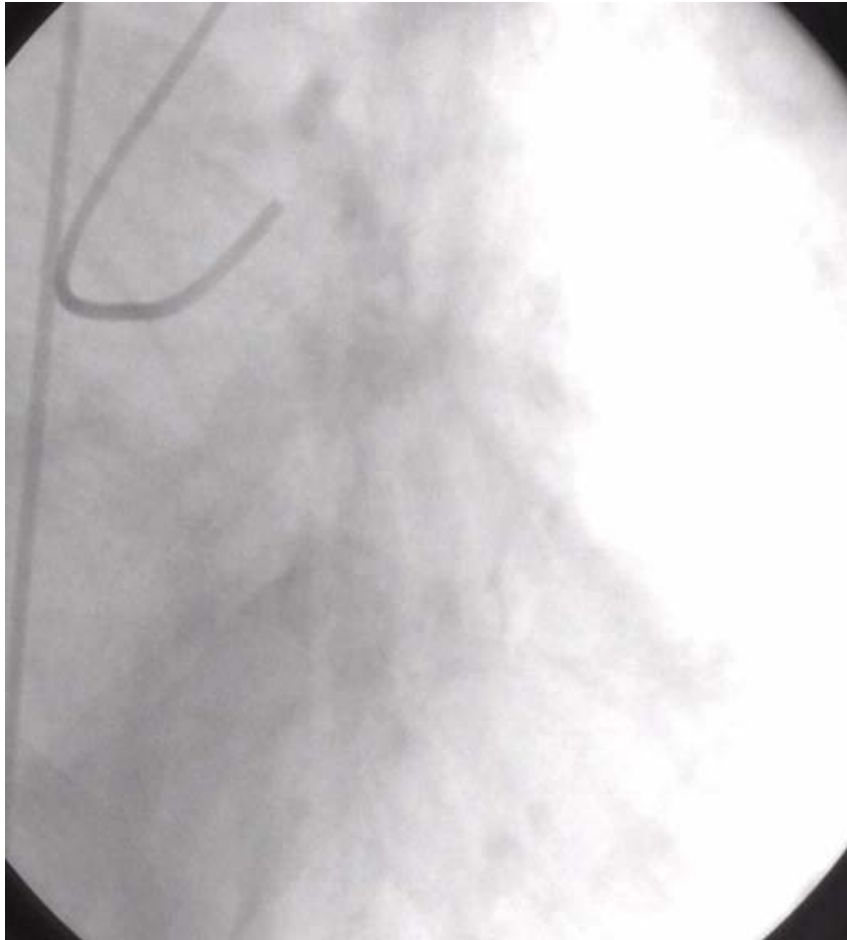ECG



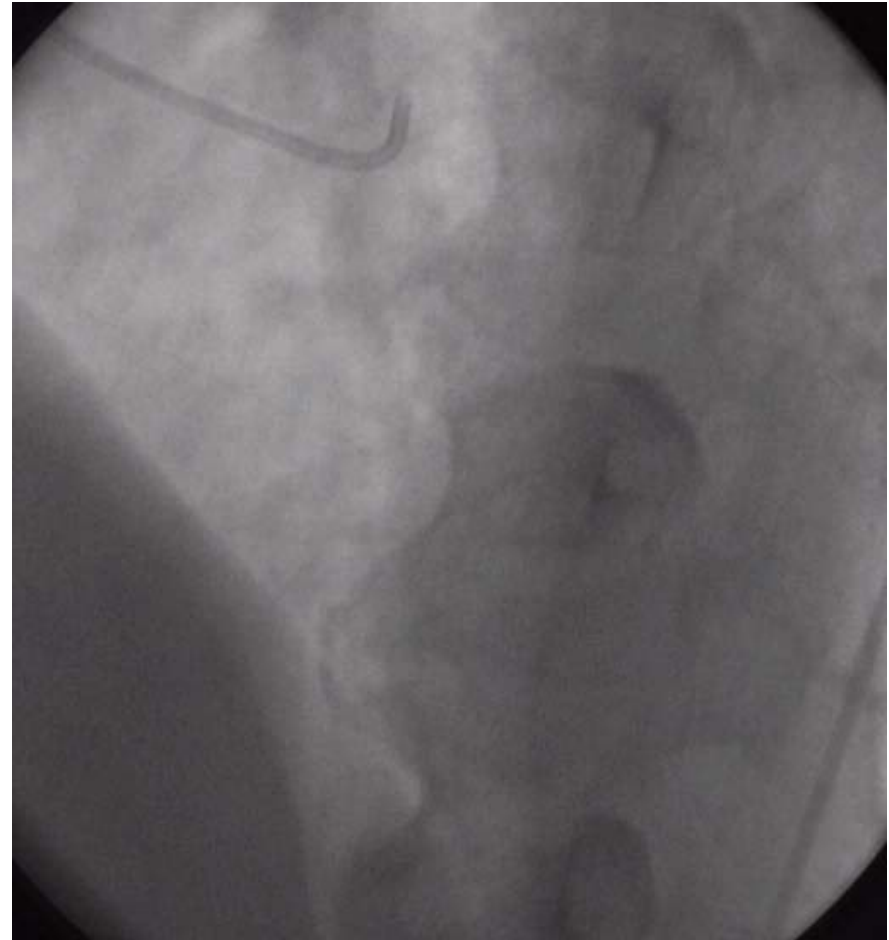LAB

WBC	7,400 /mm³	APTT	34.8 /sec
Hgb	13.7 g/dL	PT INR	1.01
PLT	177k /mm³	TC	174 mg/dL
		TG	55 mg/dL
AST	18 U/L	LDL	116 mg/dL
ALT	26 U/L	HDL	51.3 mg/dL
		LP(a)	61.5 mg/dL
hs-CRP	0.081 mg/dL	Tn-I	0.03 ng/mL
NT-proBNP	94.94 pg/mL	CK	126 U/L
		CK-MB	54 U/L

CAG (2006-06-13)

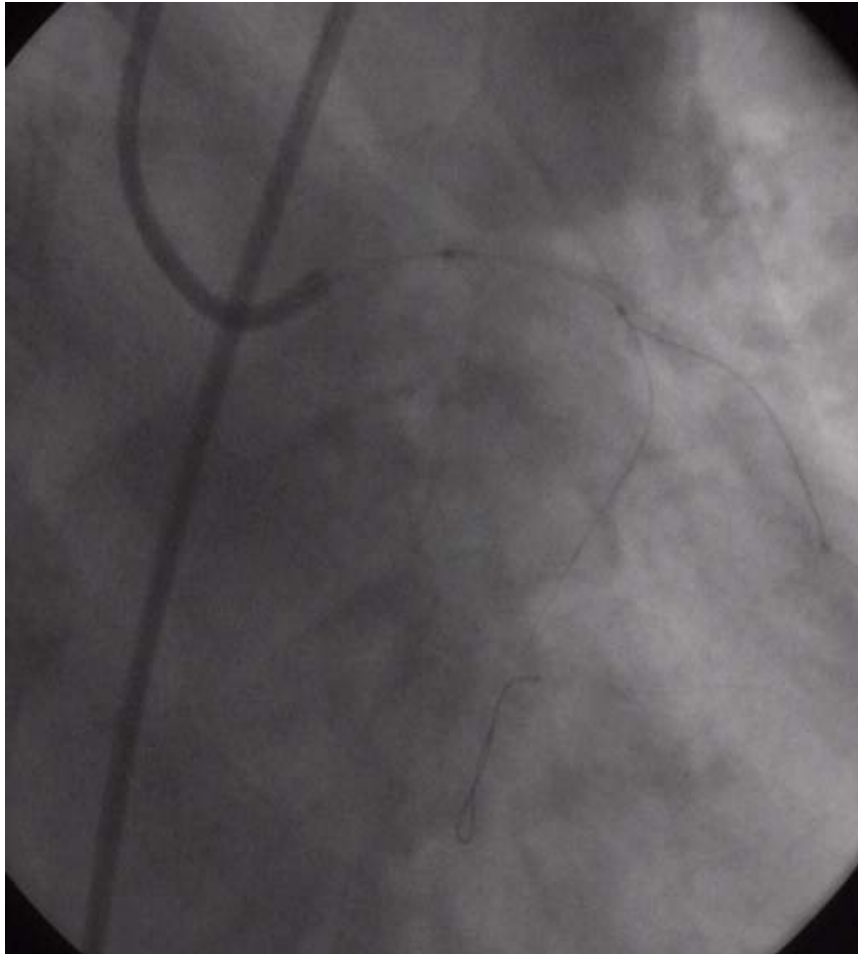


RAO

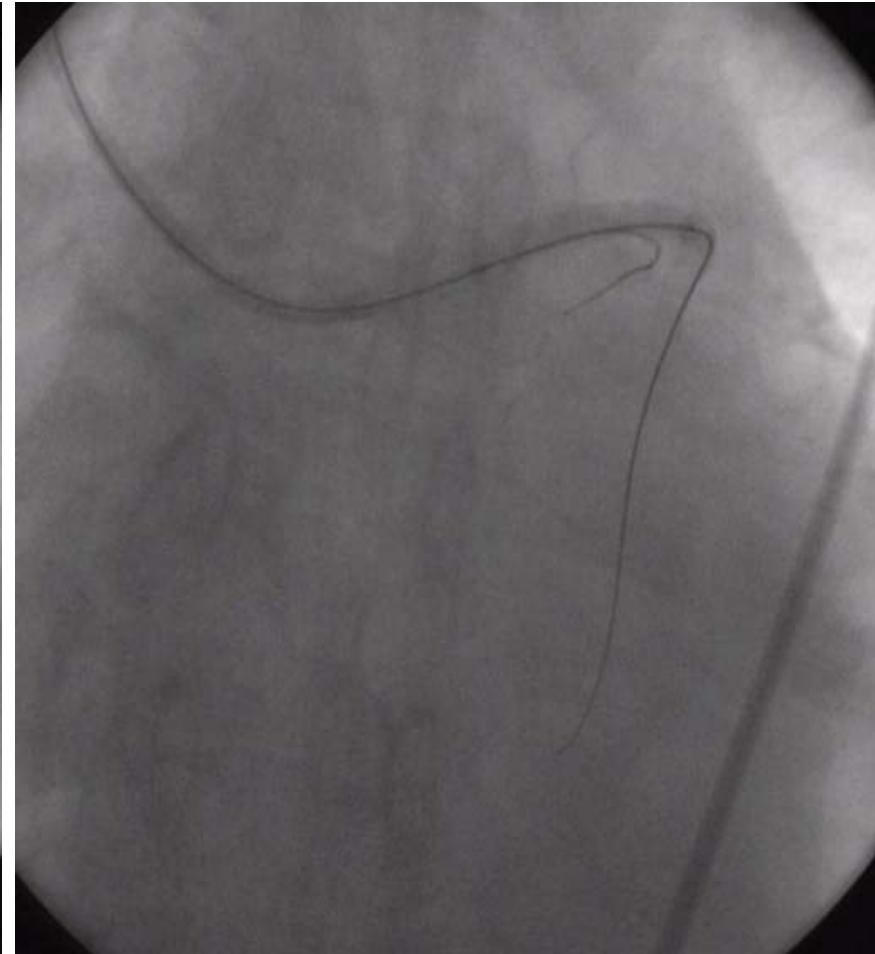


LAO

CAG (2006-06-13)



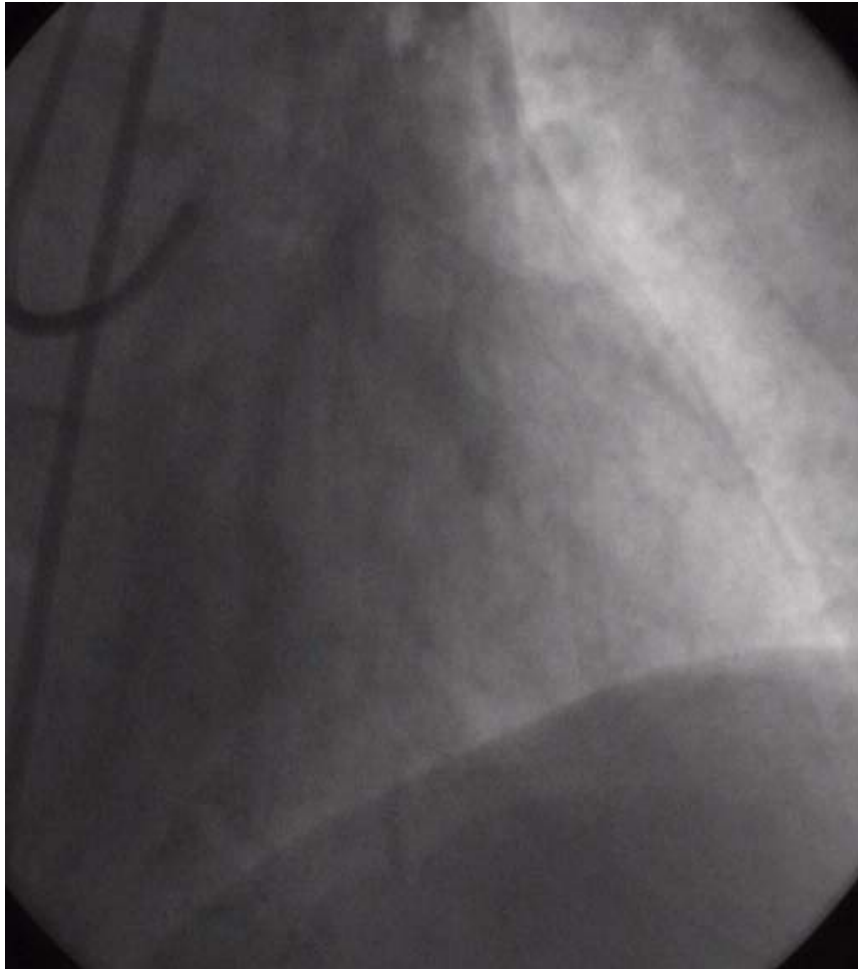
RAO



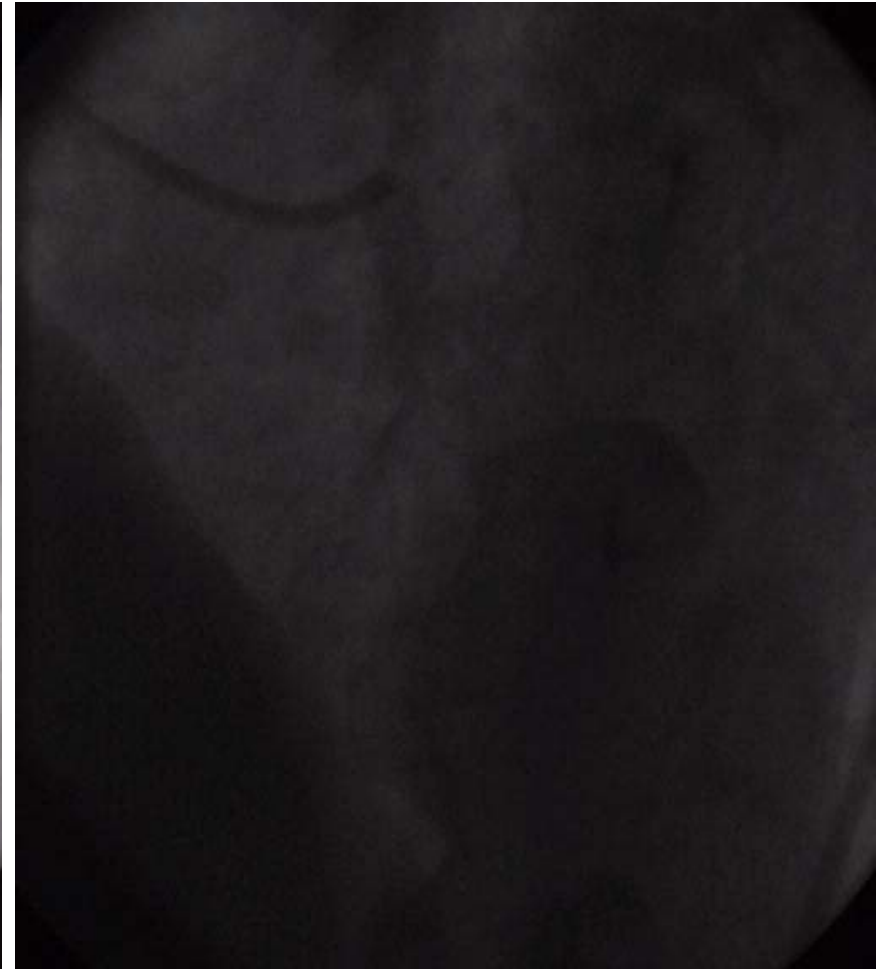LAO

3.0mm balloon → 3.0X28mm X2 Taxus stent implantation

CAG (2006-06-13)



RAO



LAO

Discharge Medications

Aspirin 100mg

Plavix 75mg

Pletaal 200mg

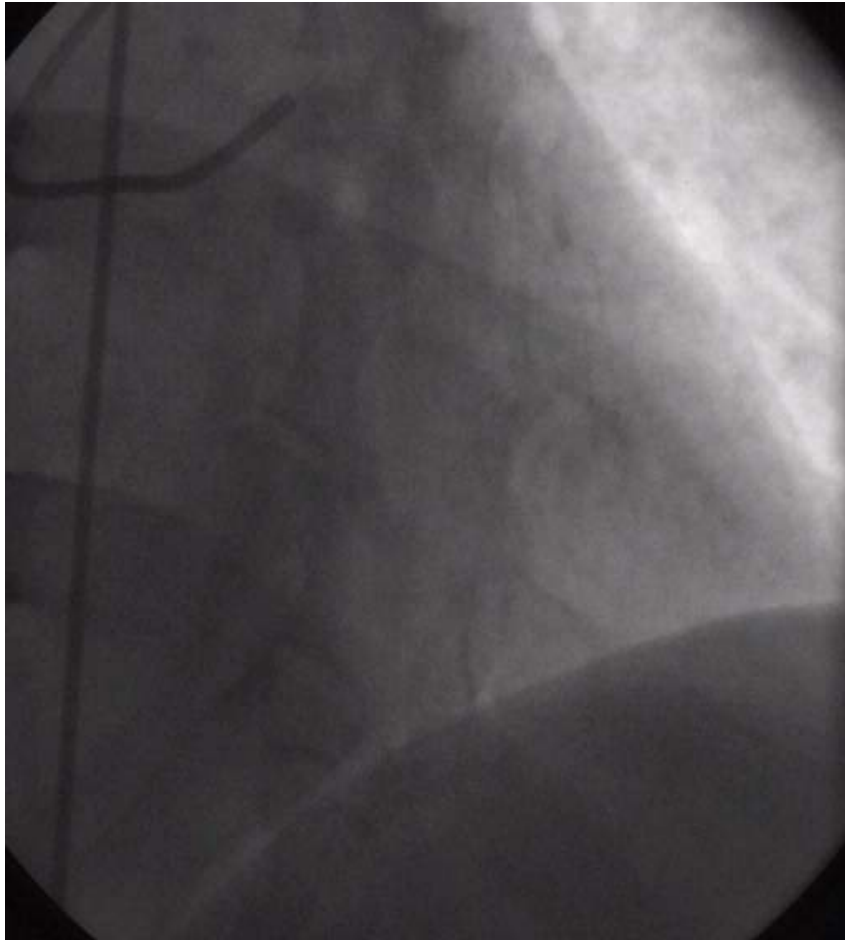
Prastan 20mg

Molsiton 4mg

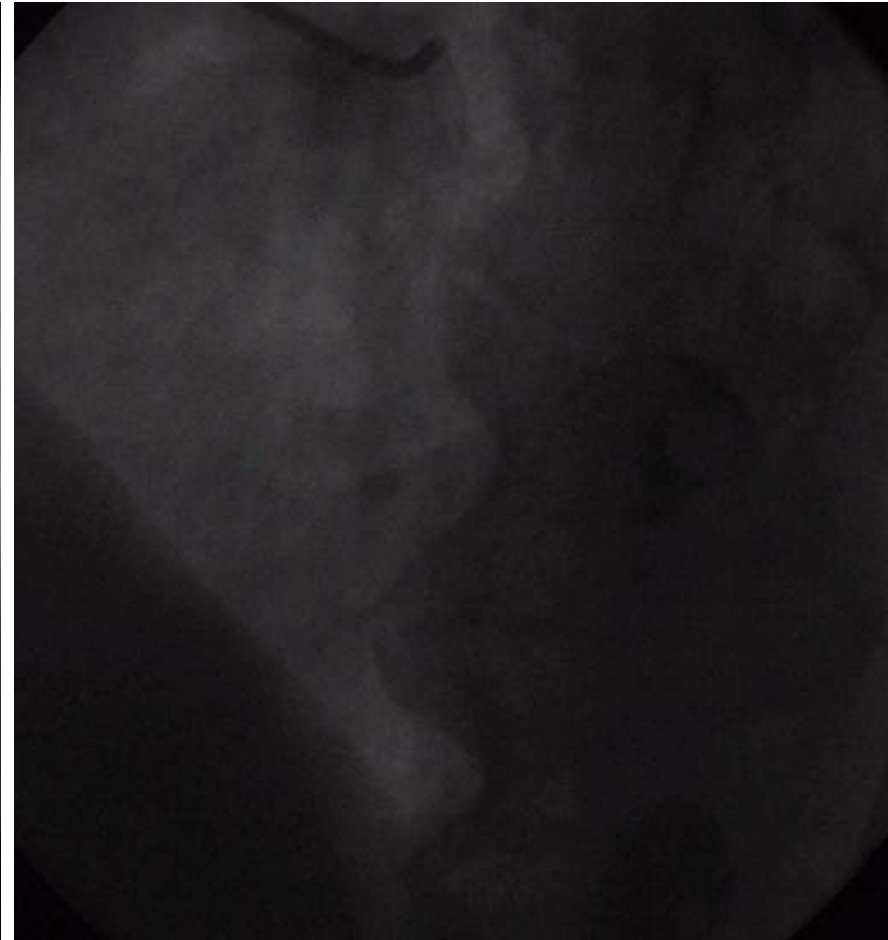
Dilatrend 3.625mg

Tritace 5mg

No Angina, 15M FU CAG (2007-09-20)



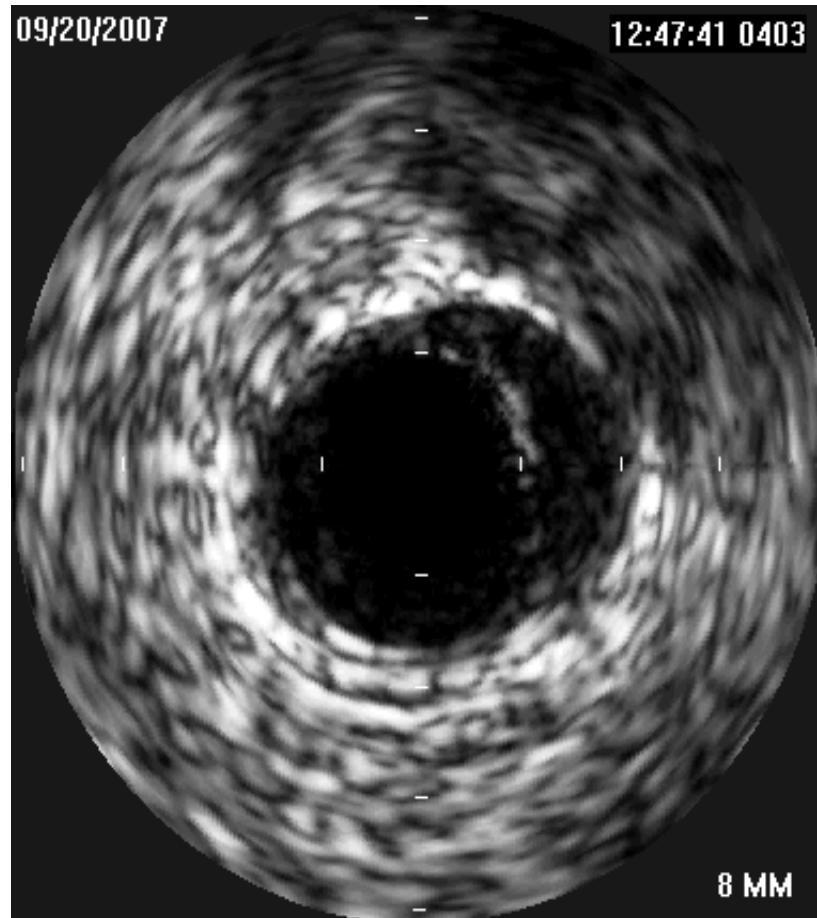
RAO



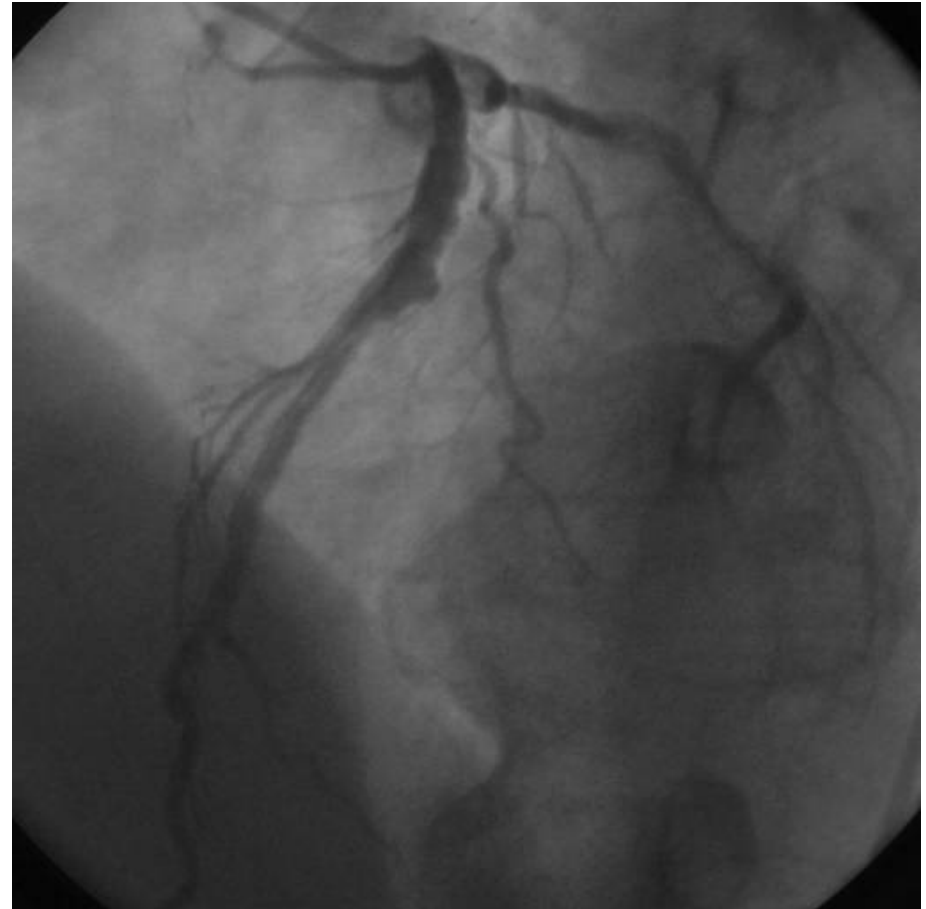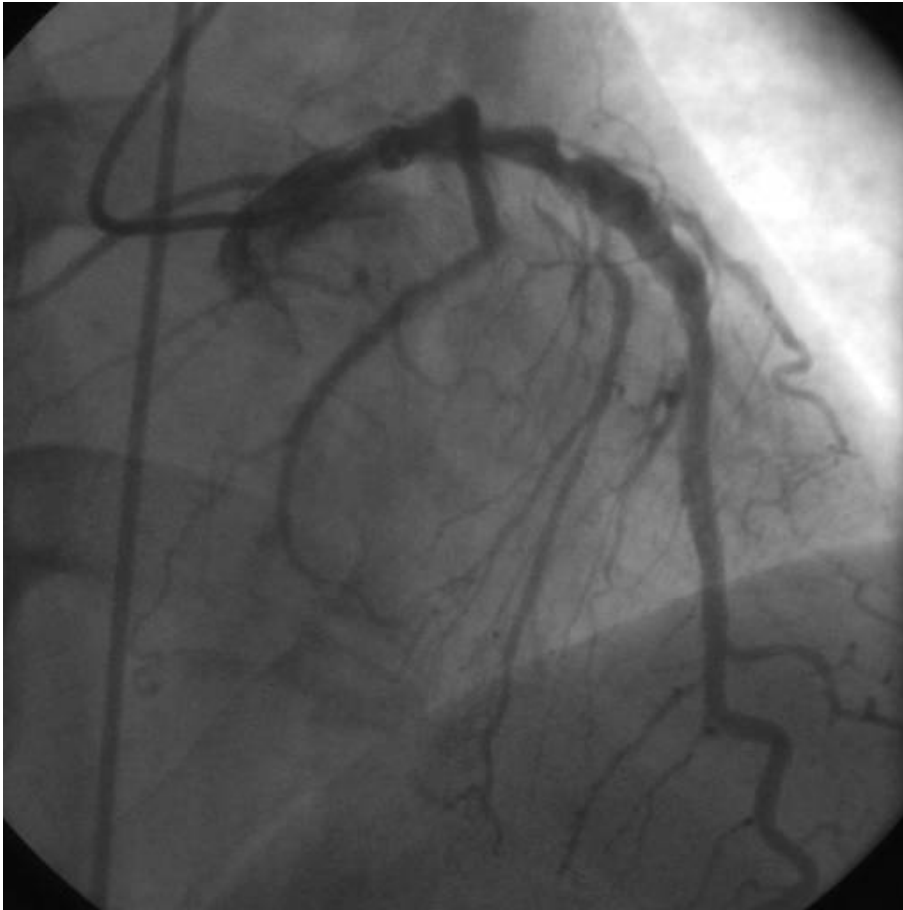LAO

Aneurysm

15M FU IVUS (2007-09-20)

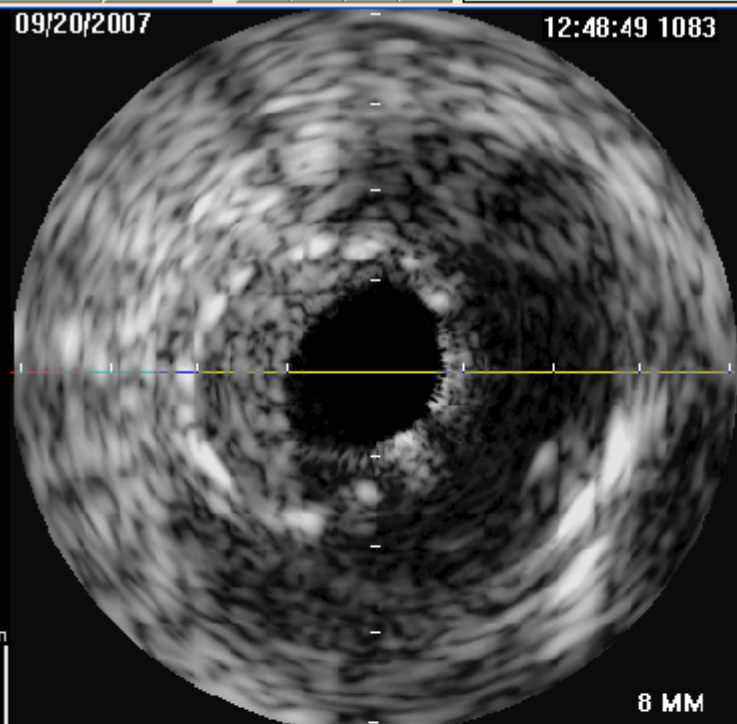


15M FU CAG (2007-09-20)



09/20/2007

12:48:49 1083



8 MM

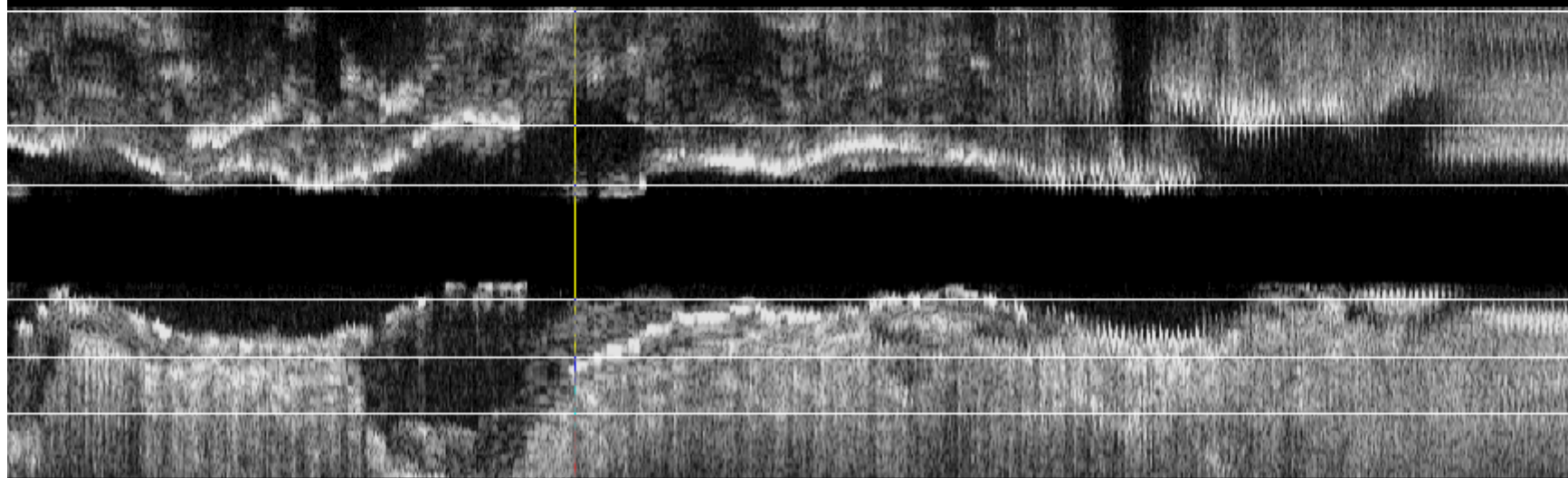
Dist : 53.09 / 85.39 mm

Frame : 1083 / 1742

Proximal edge of distal Taxus

Stent CSA=5.8mm²

EEM CSA=40mm²



1 mm

Acquisition

Analysis

Processing


Options...

Range...

Render

Measures

Volume...



Data/Result

Patient...

DataView...

Reporting

Bookmark

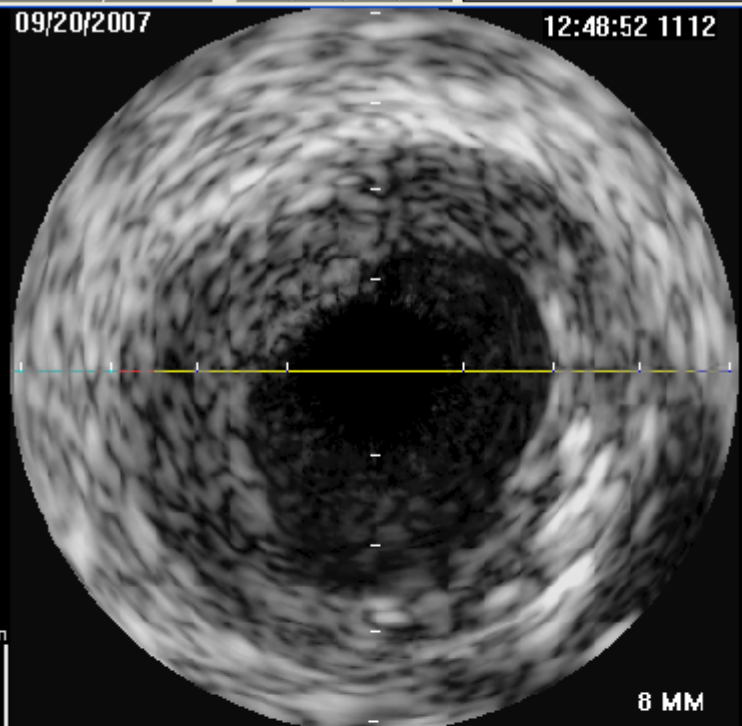
Report

Screen Sho

inserting new slides

09/20/2007

12:48:52 1112



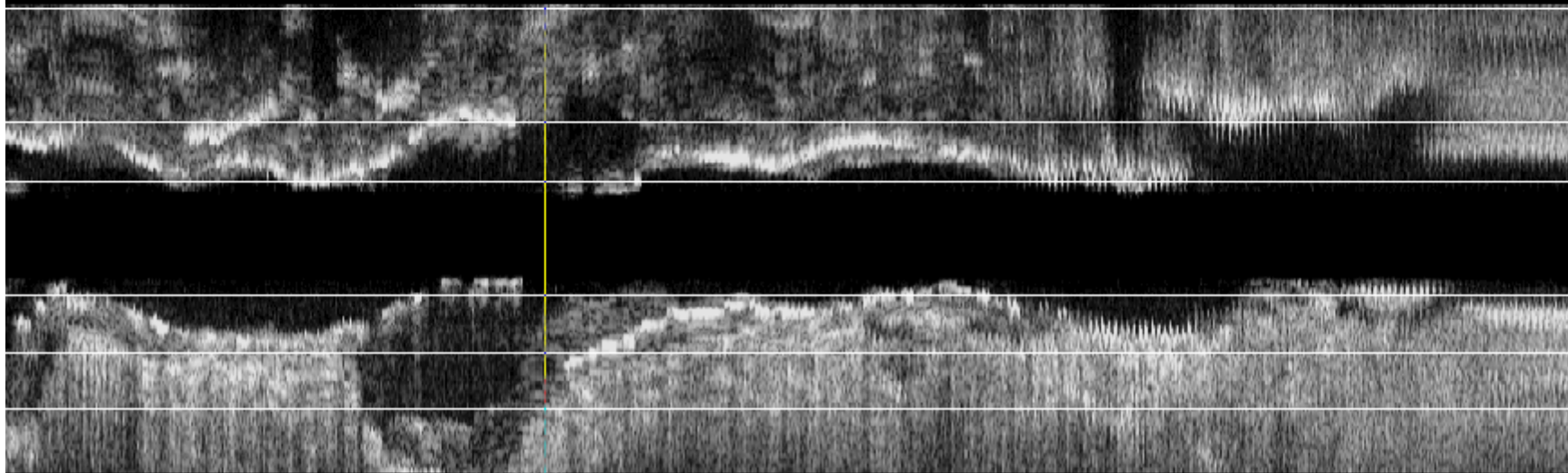
8 MM

Dist : 54.51 / 85.39 mm

Frame : 1112 / 1742

Gap

- Acquisition
- Analysis
- Processing
 - Options...
 - Range...
 - Render
- Measures
 - Volume...
 -
 -
 -
 -
 -
- Data/Result
 - Patient...
 - DataView...
- Reporting
 - Bookmark
 - Report
 - Screen Sho

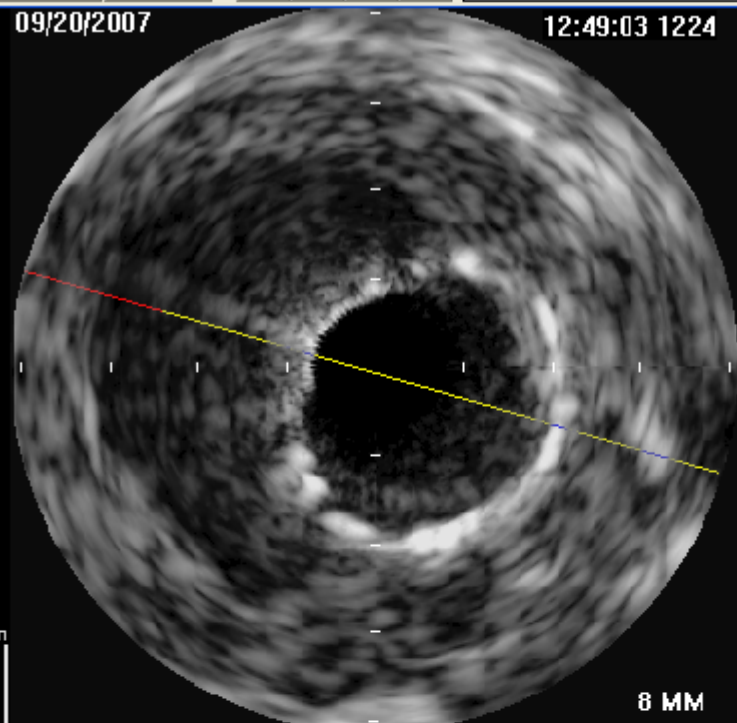


1 mm

Inserting new slides

09/20/2007

12:49:03 1224



8 MM

Dist : 60.00 / 85.39 mm

Frame : 1224 / 1742

Distal portion of proximal Taxus

Stent CSA=6.4mm²

EEM CSA=48mm²

Acquisition

Analysis

Processing


Options...

Range...

Render

Measures

Volume...



Data/Result

Patient...

DataView...

Reporting

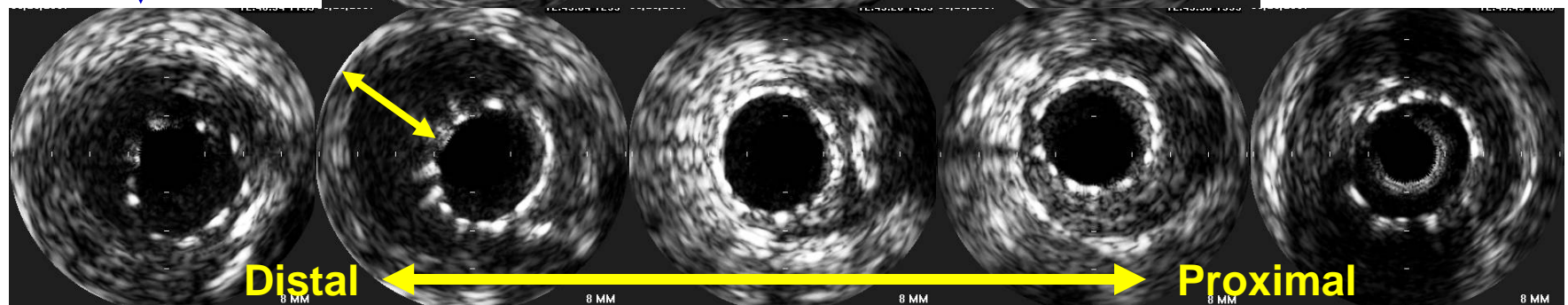
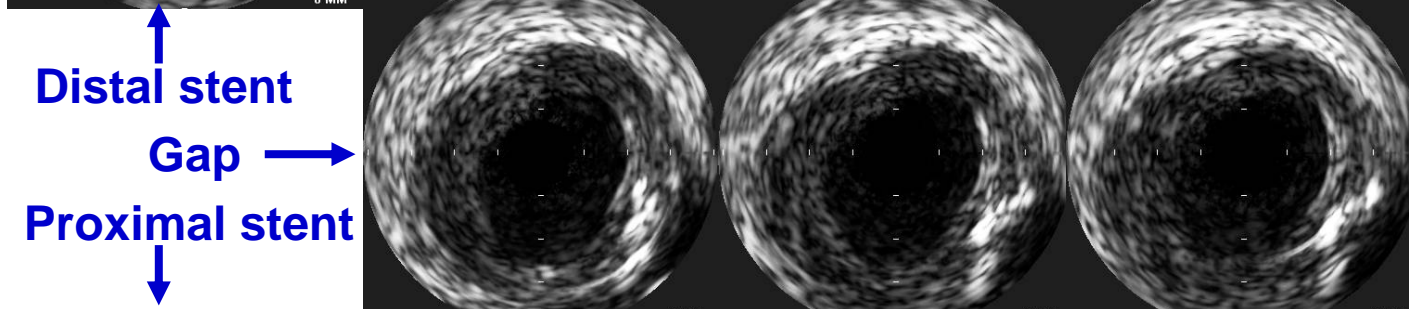
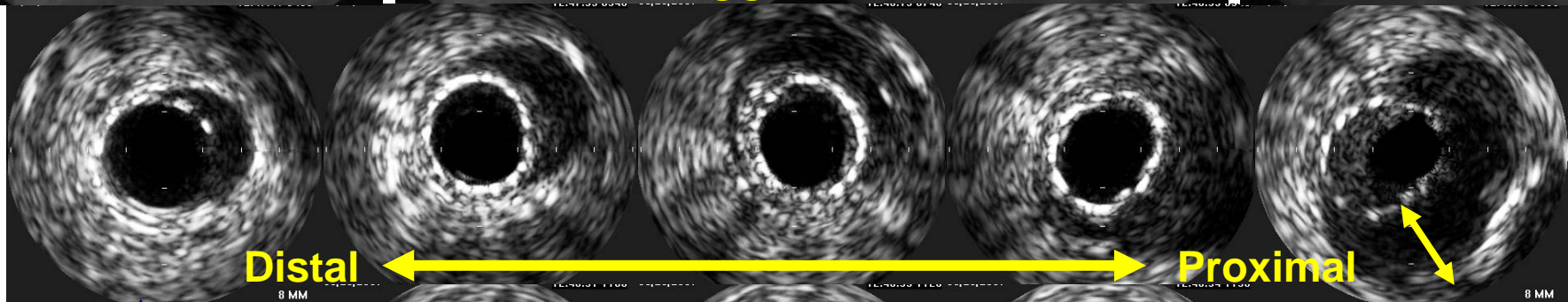
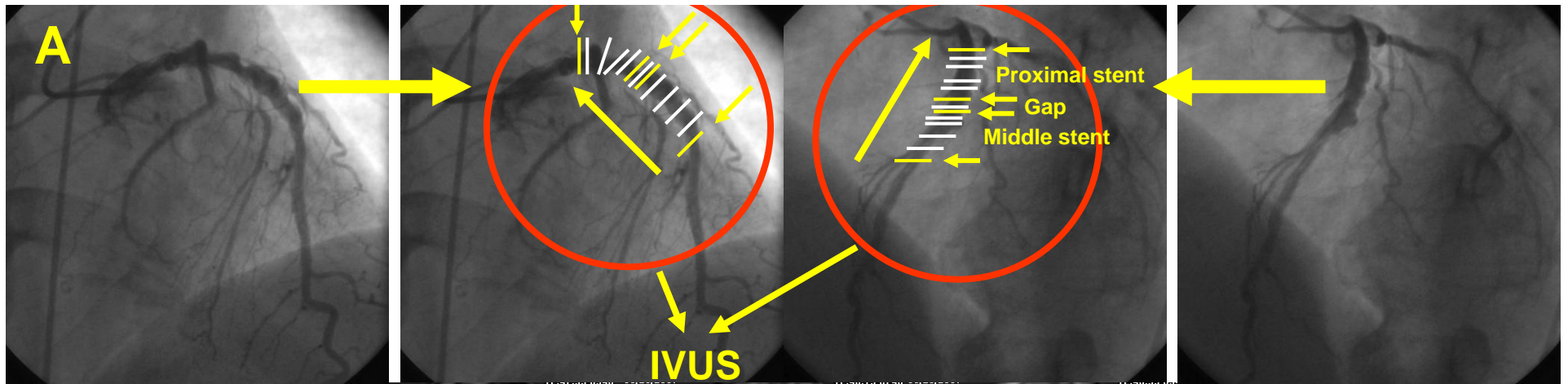
Bookmark

Report

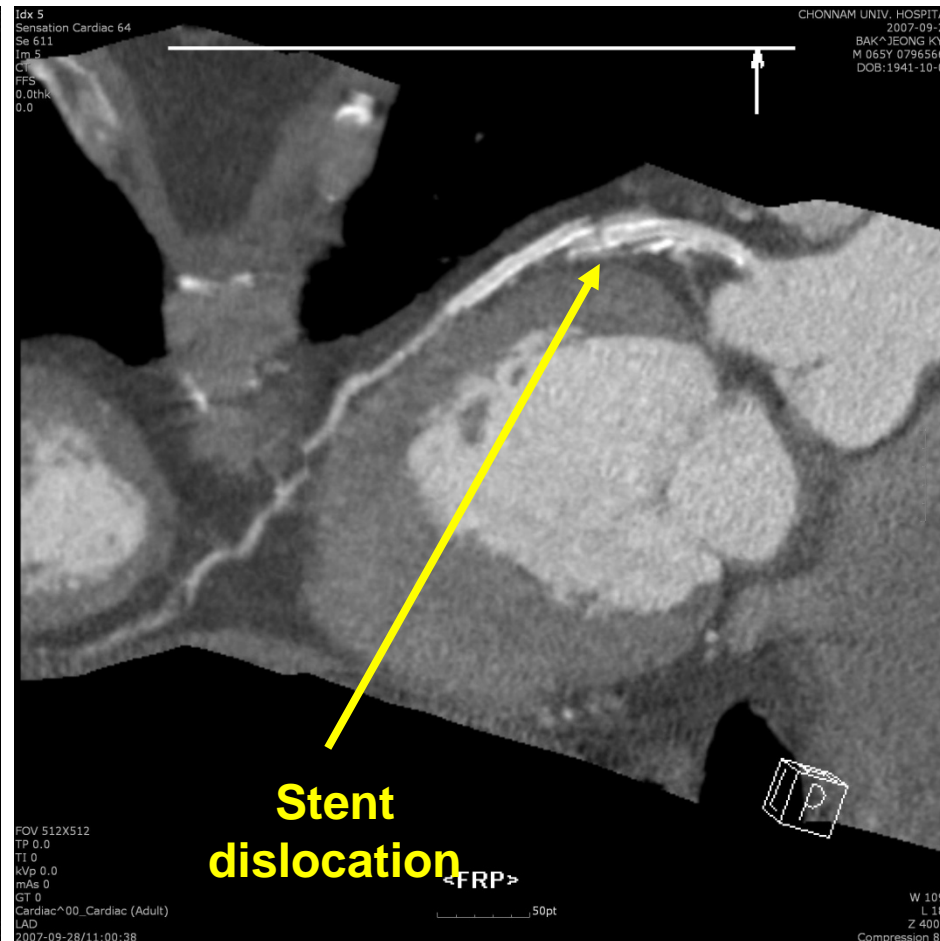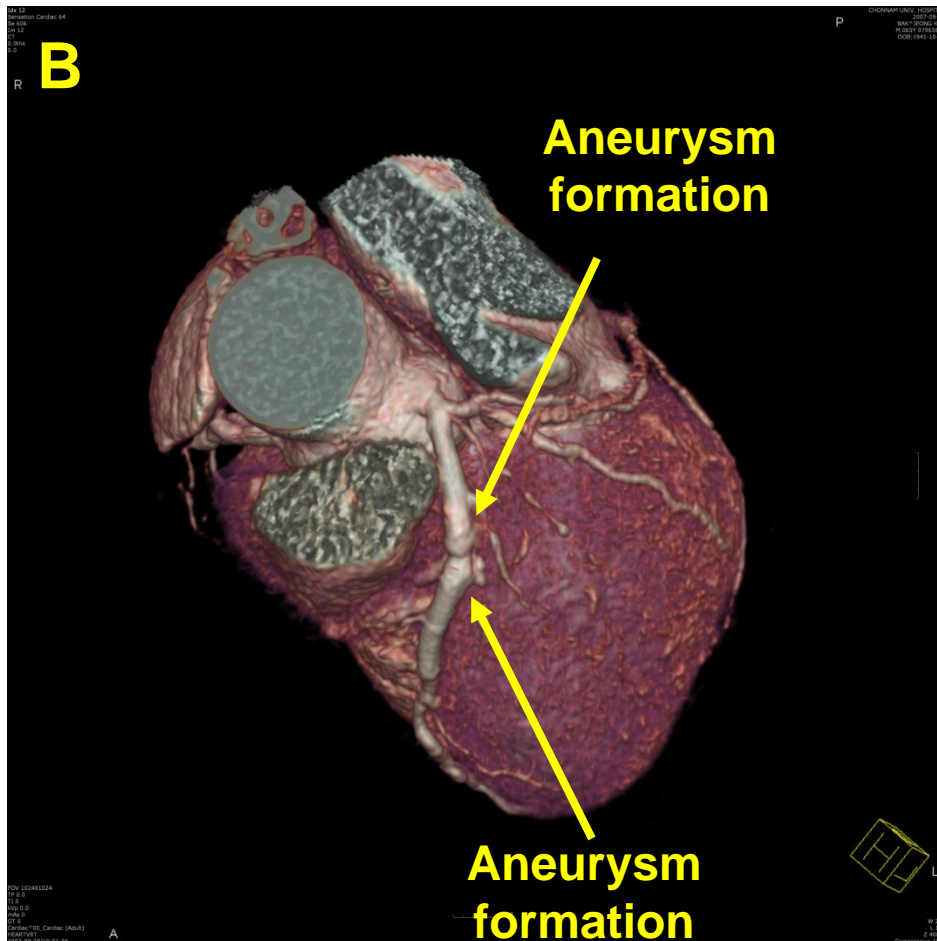
Screen Sh

Inserting new slides

1 mm



Cardiac CT (2007-09-28)



Discharge Medications

Aspirin 100mg

Plavix 75mg

Pletaal 200mg

Prastan 20mg

Molsiton 4mg

Dilatrend 3.625mg

Tritace 5mg

Discussion

- 1. What is the cause of stent dislocation by the formation of huge aneurysm in this patient ?**
- 2. What is the best medical treatment option ?**