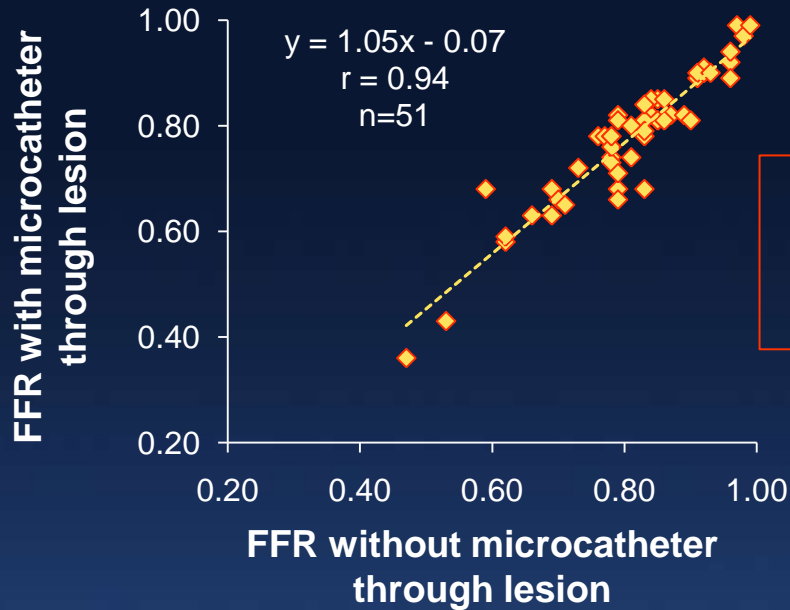
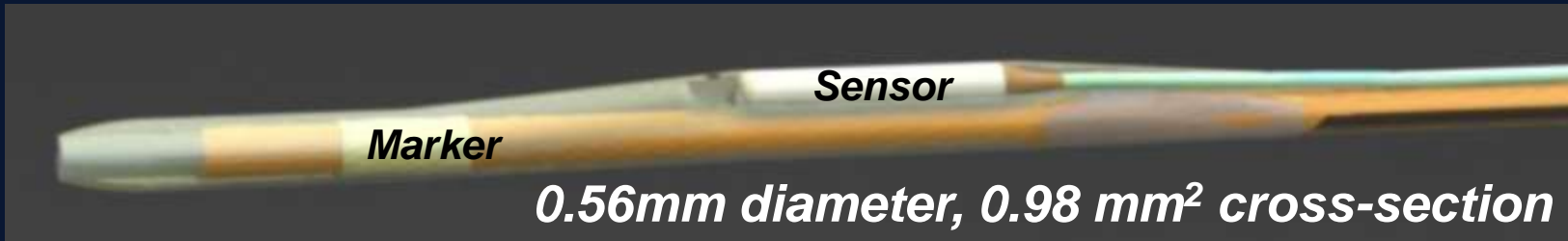


Next Generation Invasive Imaging: Where Are We Going?

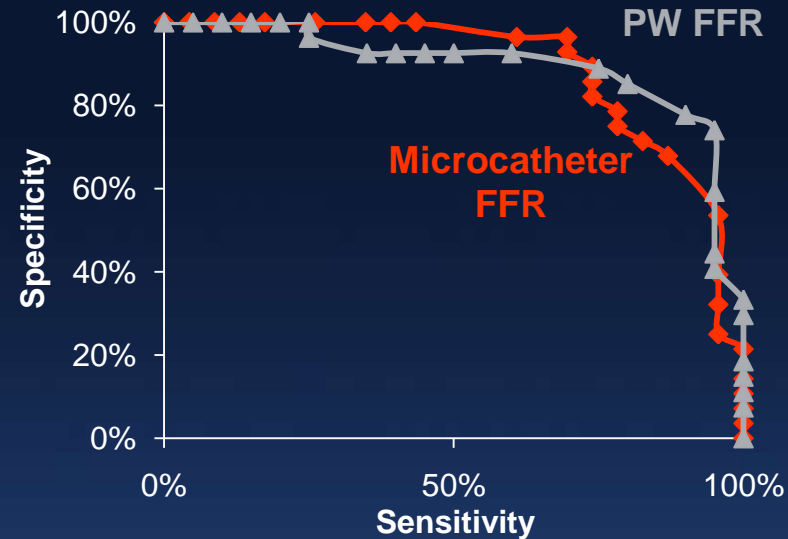
Gary S. Mintz, MD

Cardiovascular Research Foundation

Rapid Exchange FFR Microcatheter



Data in >2.5mm arteries

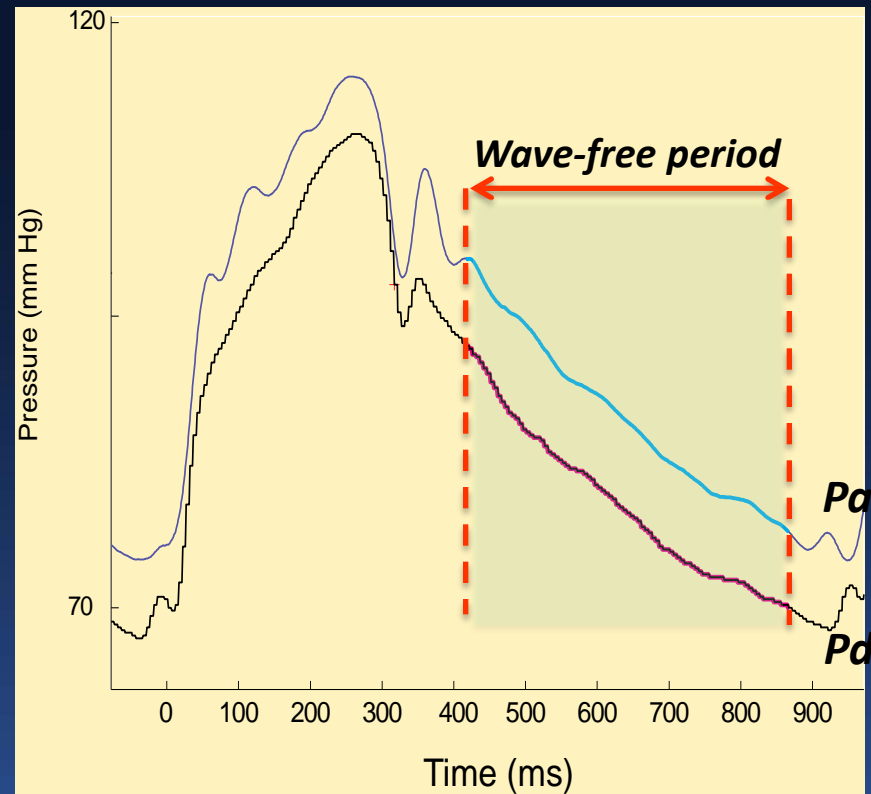


	FFR microcatheter	Pressure wire	P
Drift greater than ± 0.03	13%	33%	0.022
Mean Drift	0.016	0.056	0.014

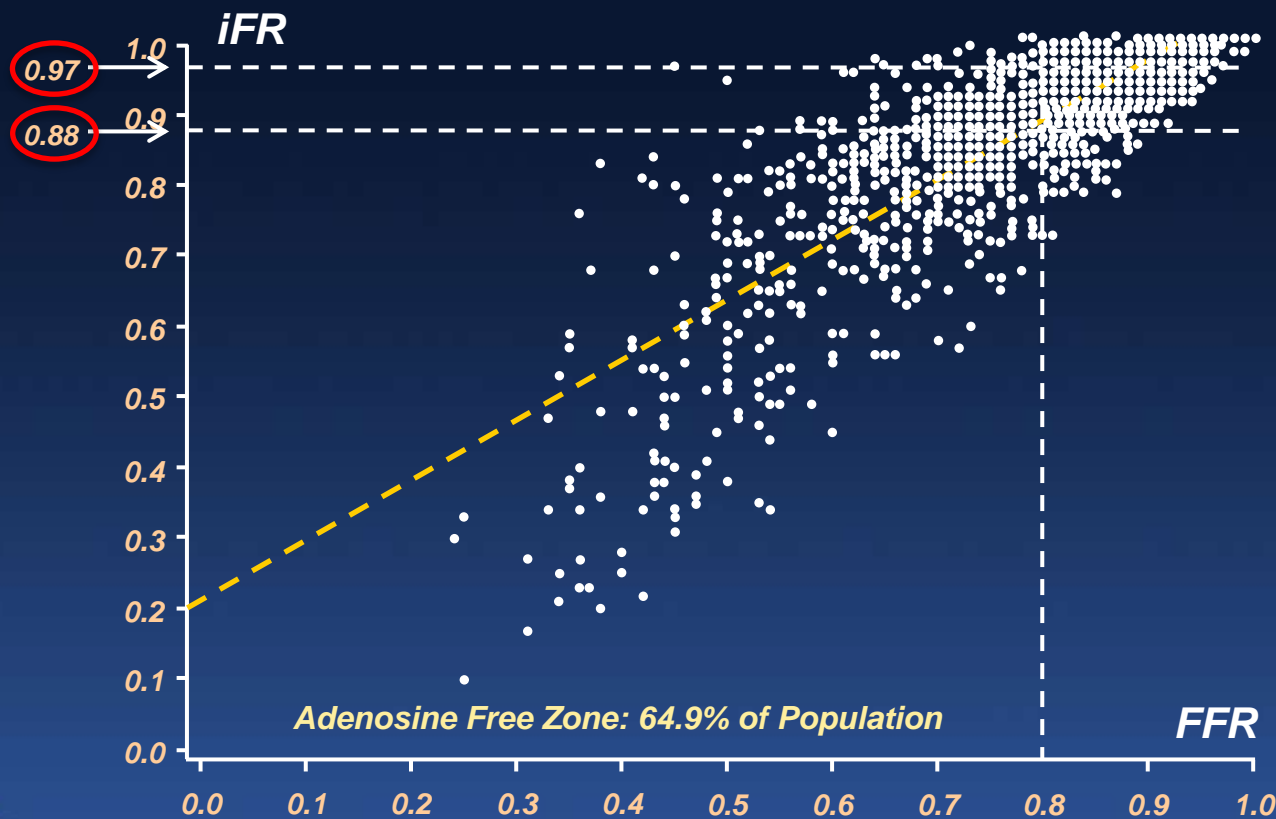
iFR = instantaneous wave-free ratio

Definition:

Instantaneous pressure ratio, across a stenosis during the wave-free period, when resistance is naturally constant and minimised in the cardiac cycle

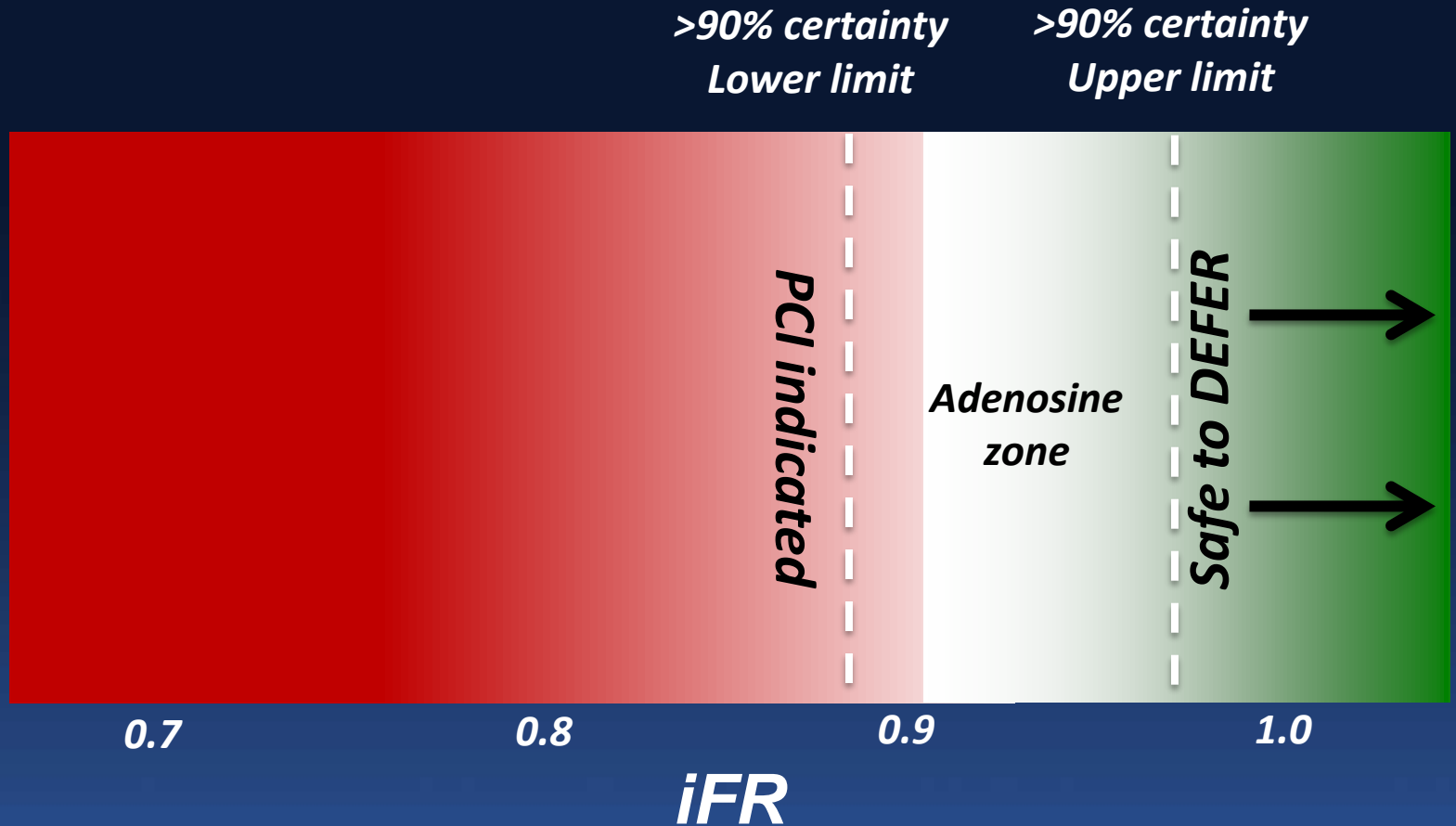


Proportion of pts with	Cut-off	PPV	NPV	Total
90% precision	>0.97		12.9%	57.1%
	<0.88	44.2%		
95% precision	0.82	24.3%		24.3%

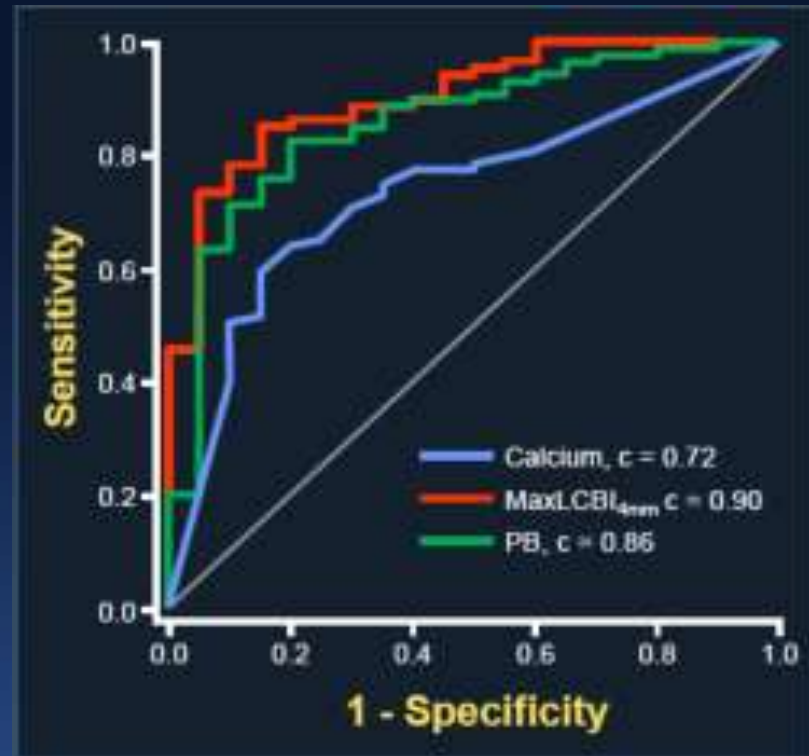
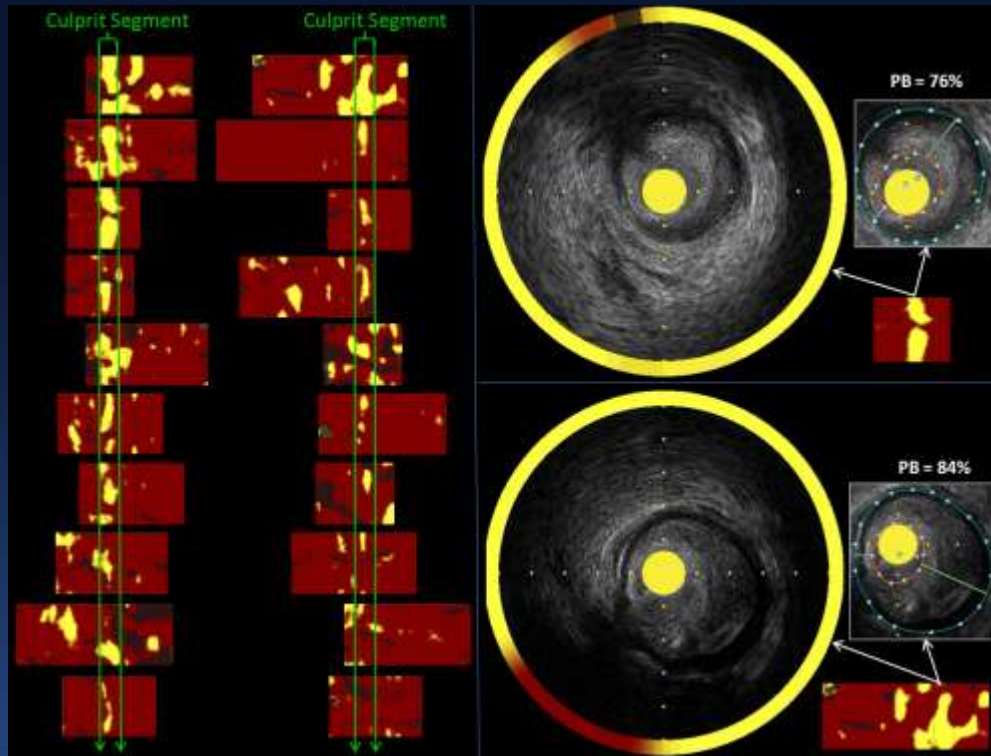


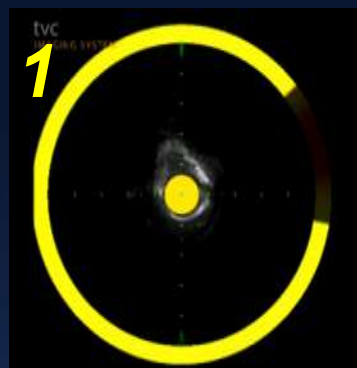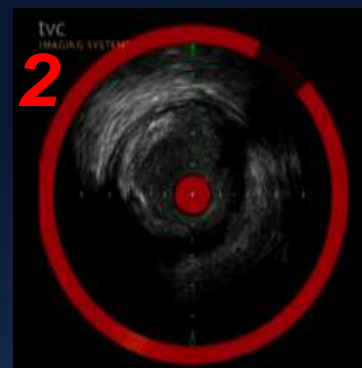
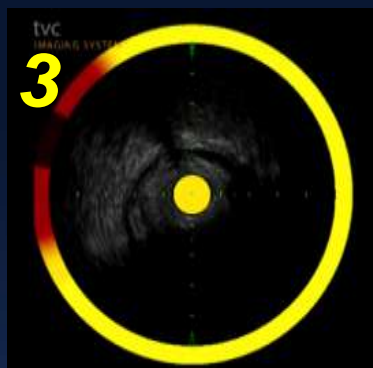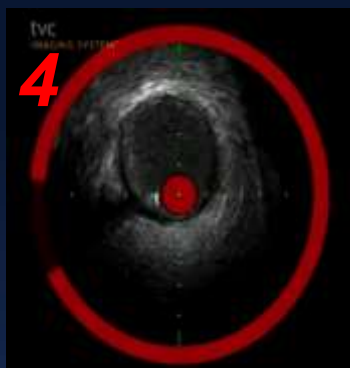
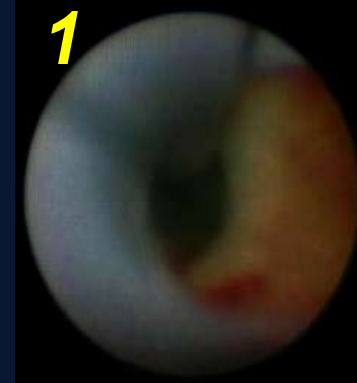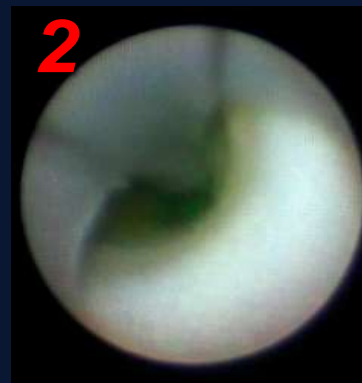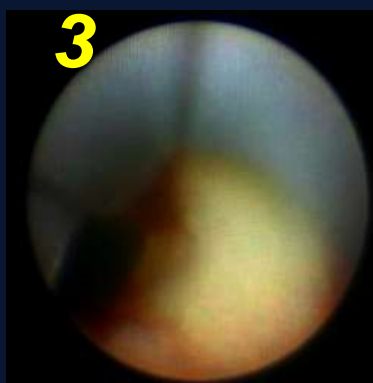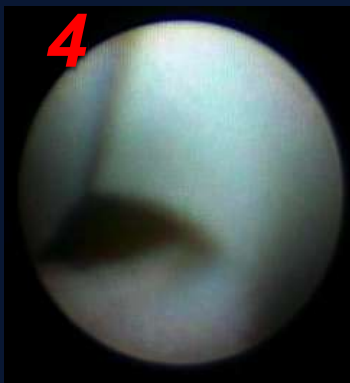C-Statistic 0.81
Sensitivity 78.9%
Specificity 82.4%
PPV 85.2%

Hybrid iFR-FFR Approach

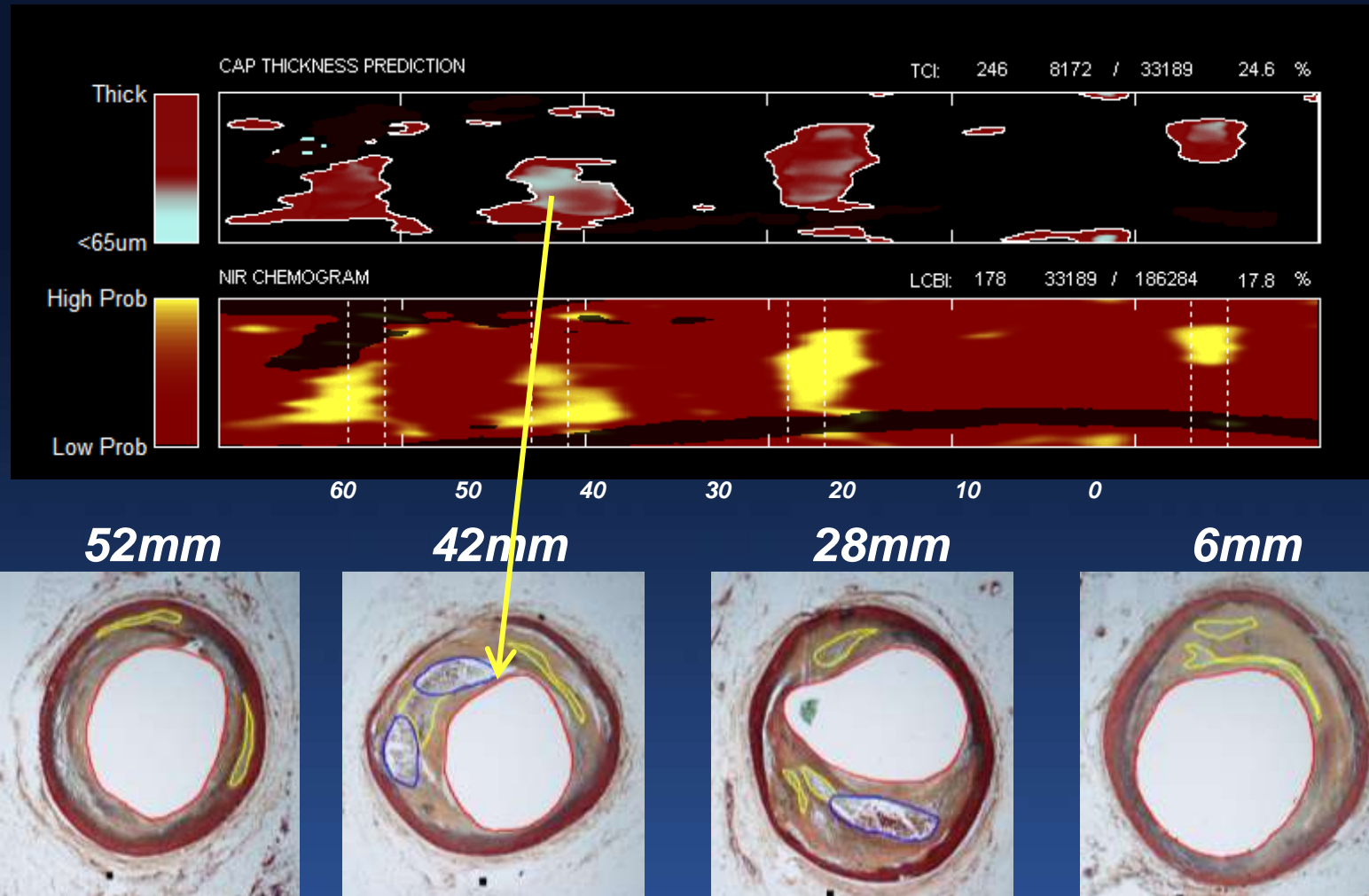


Culprit segments contained lipid rich plaque in 19 of 20 STEMI cases (95%), all with a large plaque burden.







Spectral differences can be used to distinguish LCP with thin fibrous cap (less collagen) from LCP with thicker fibrous cap (more collagen)

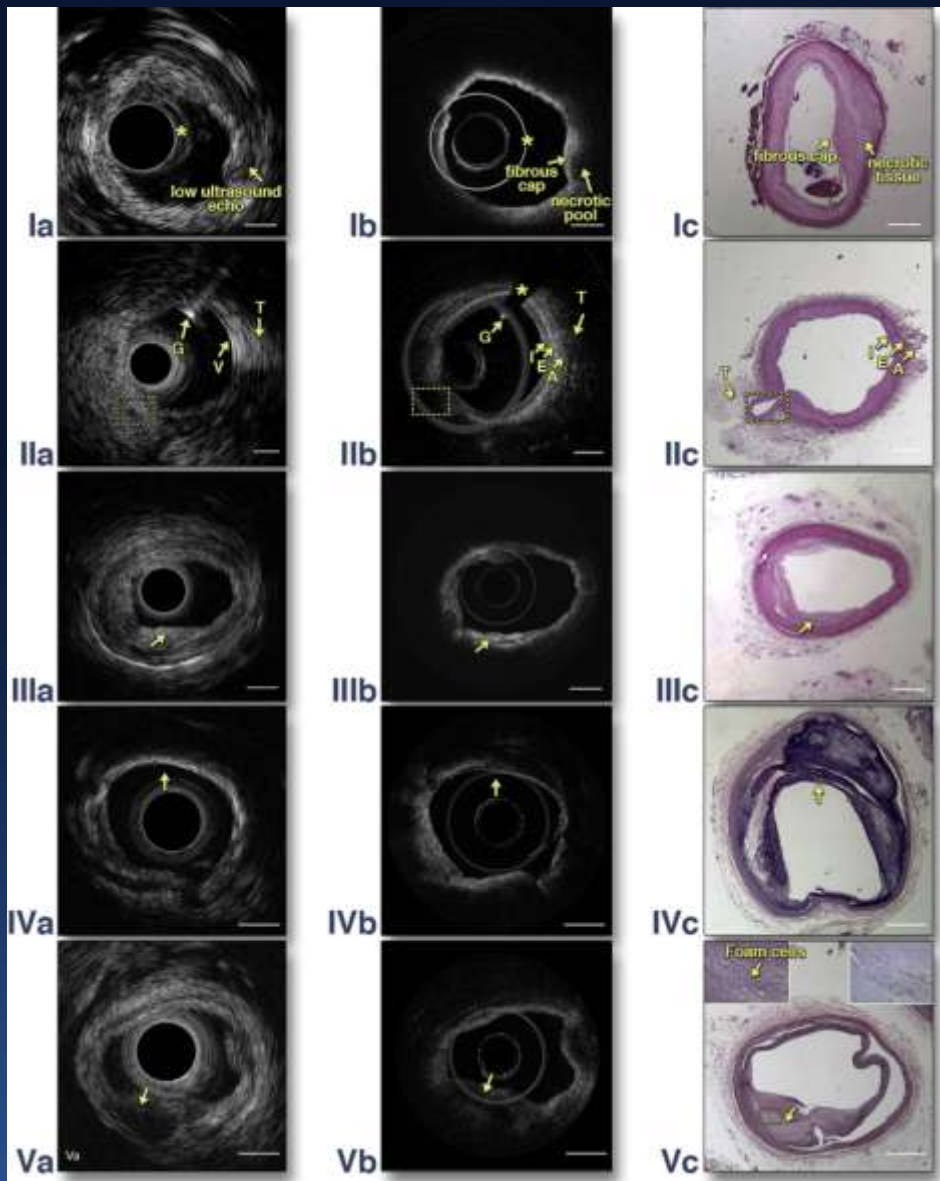


Hybrid IVUS/OCT Catheter - I

- **The imaging catheter was constructed using the following materials:**
 - **External nylon sheath with an outer diameter of 4F**
 - **Custom-built 42 MHz ultrasound transducer, with a 42% 6 dB bandwidth**
 - **1310nm single mode fibre optic spliced to a GRIN lens and beam directing prism (200x200x150 microns) with a focal length of 1.2 mm**
 - **Torque cable, micro-coaxial cable and protective housing for the distal tip**
- **The beam directing prism was positioned at the same location along the longitudinal axis of the catheter as the center of the ultrasound transducer. This configuration was chosen to provide optimal alignment of the ultrasound and optical imaging planes during cross-sectional imaging.**

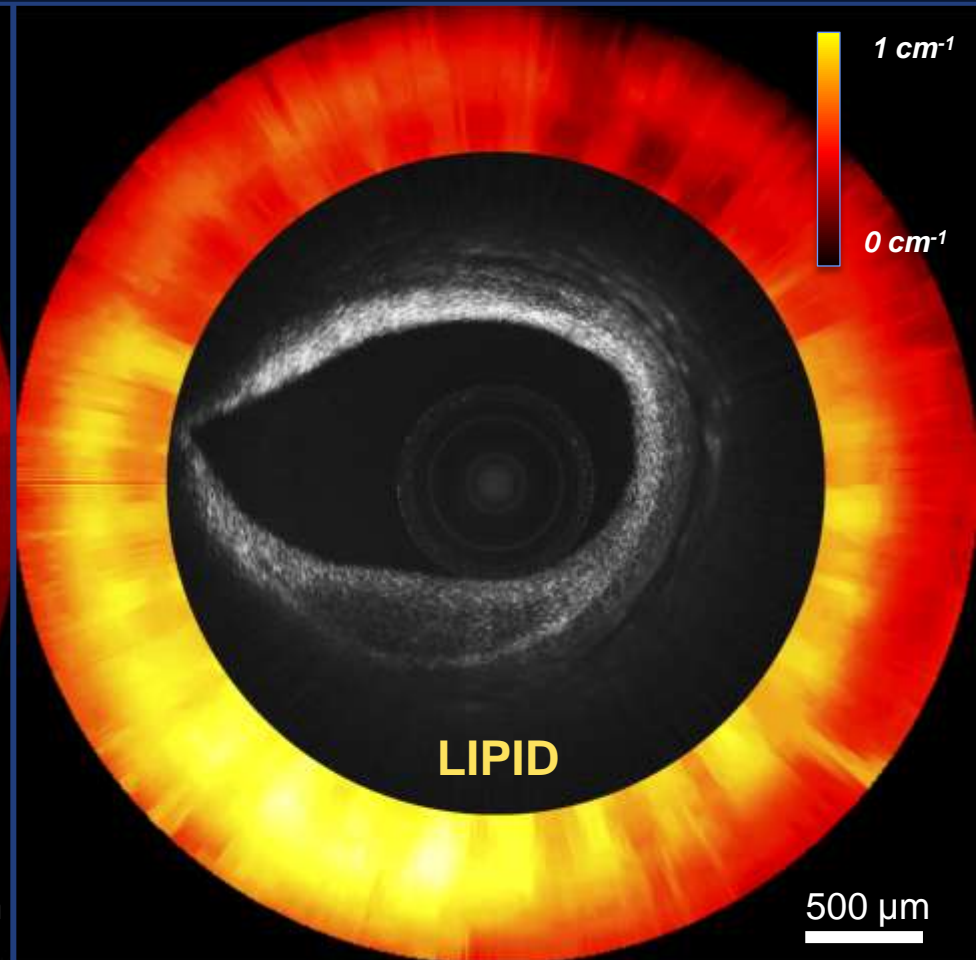
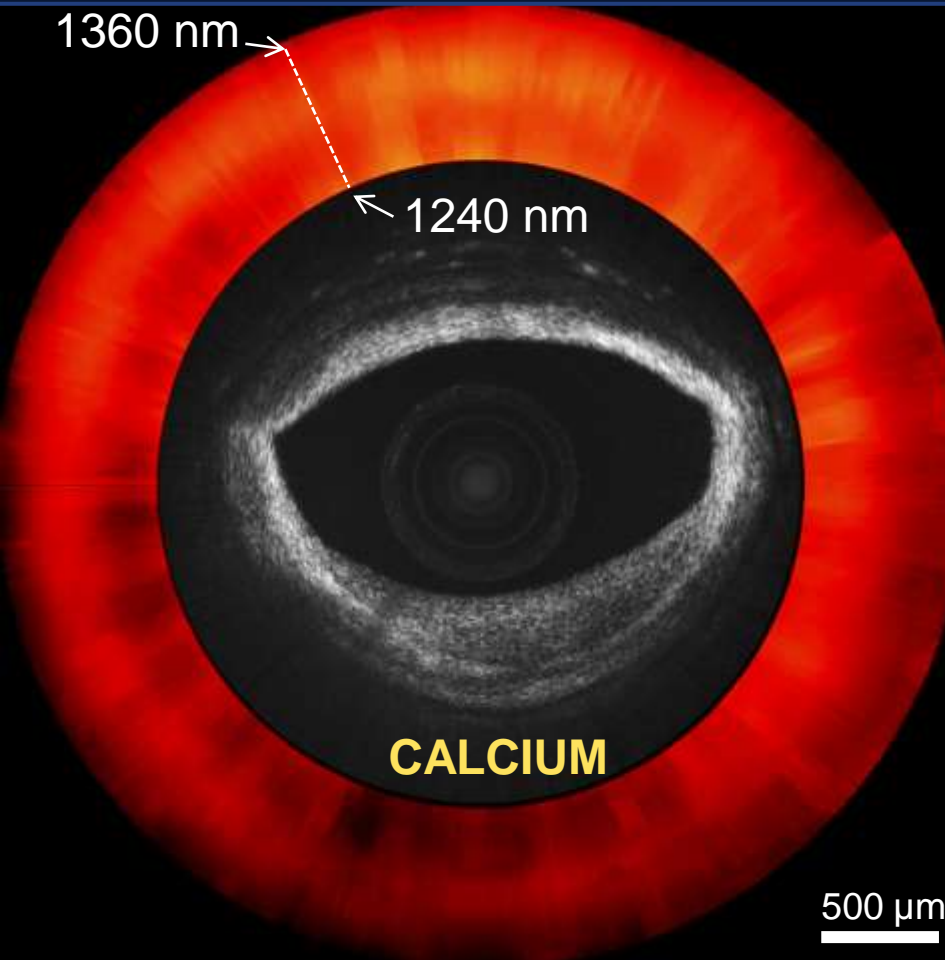


Plaques in rabbit aortas imaged using an integrated 3.4F OCT-IVUS system



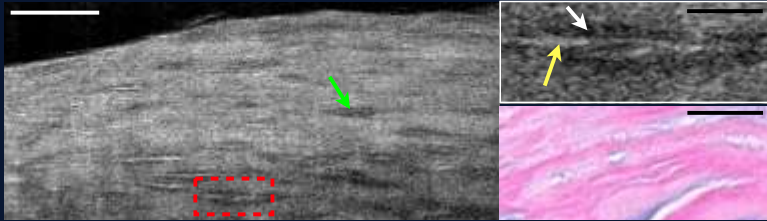
OCT-NIRS

Cadaver Coronary Plaques

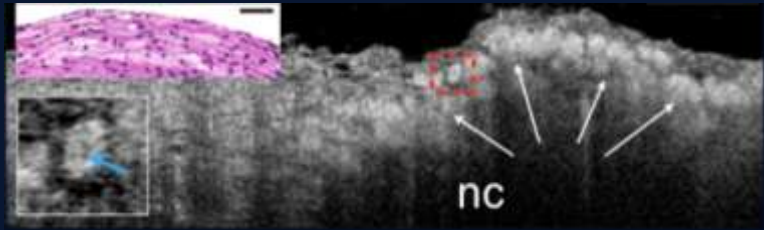


Micro OCT with <1-2 micron resolution

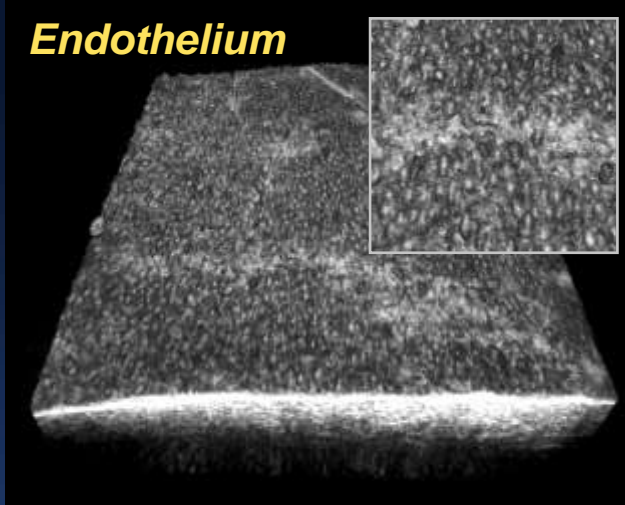
Smooth Muscle Cells



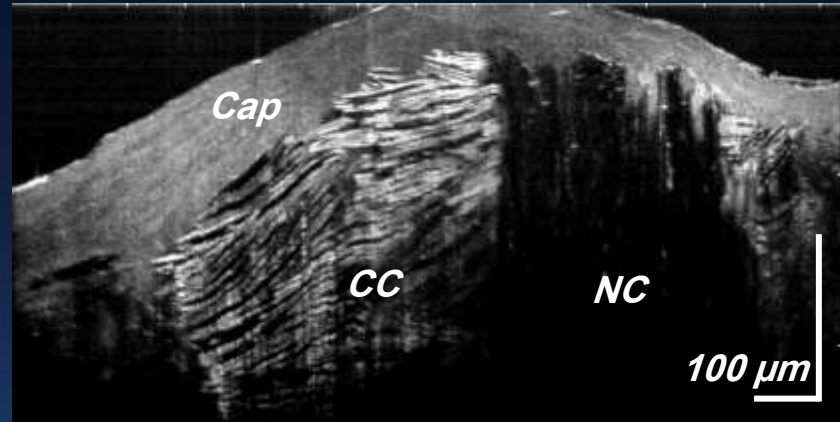
Macrophages



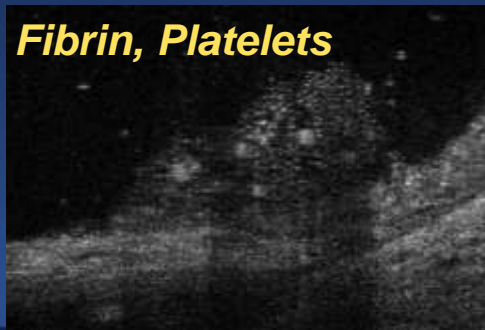
Endothelium



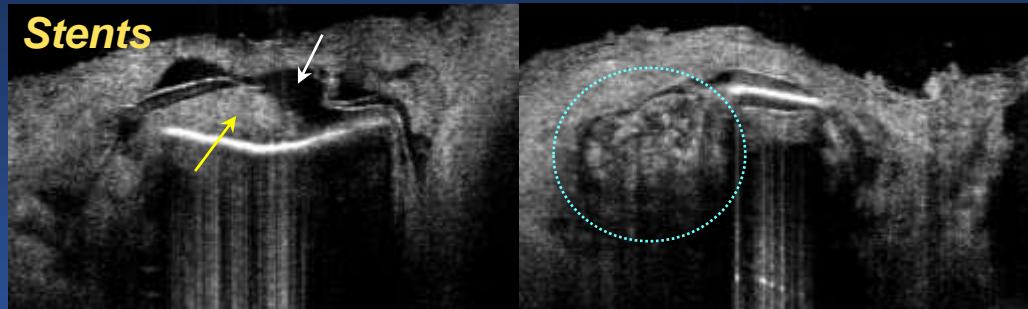
Necrotic Core Cholesterol Crystals



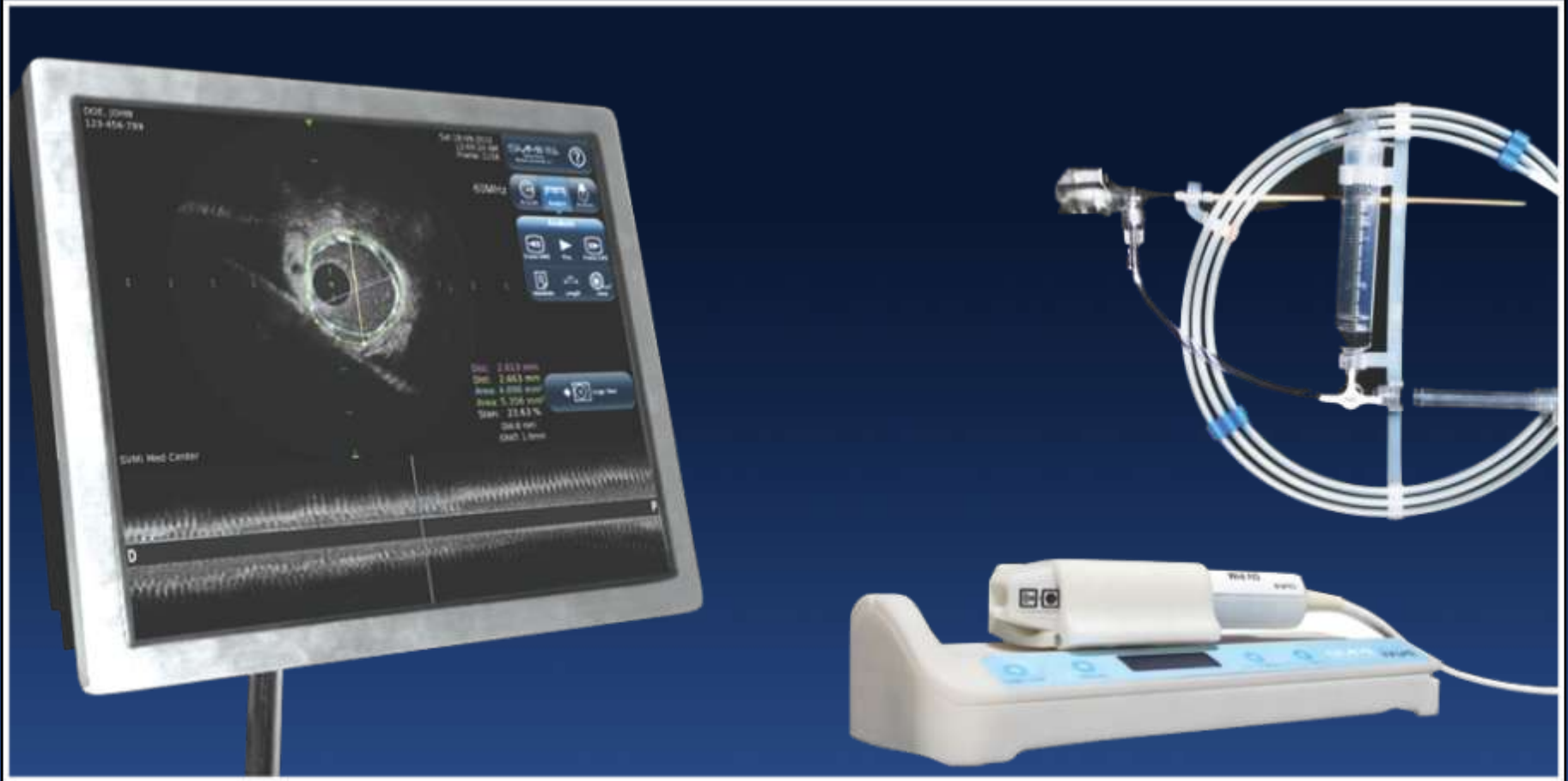Fibrin, Platelets



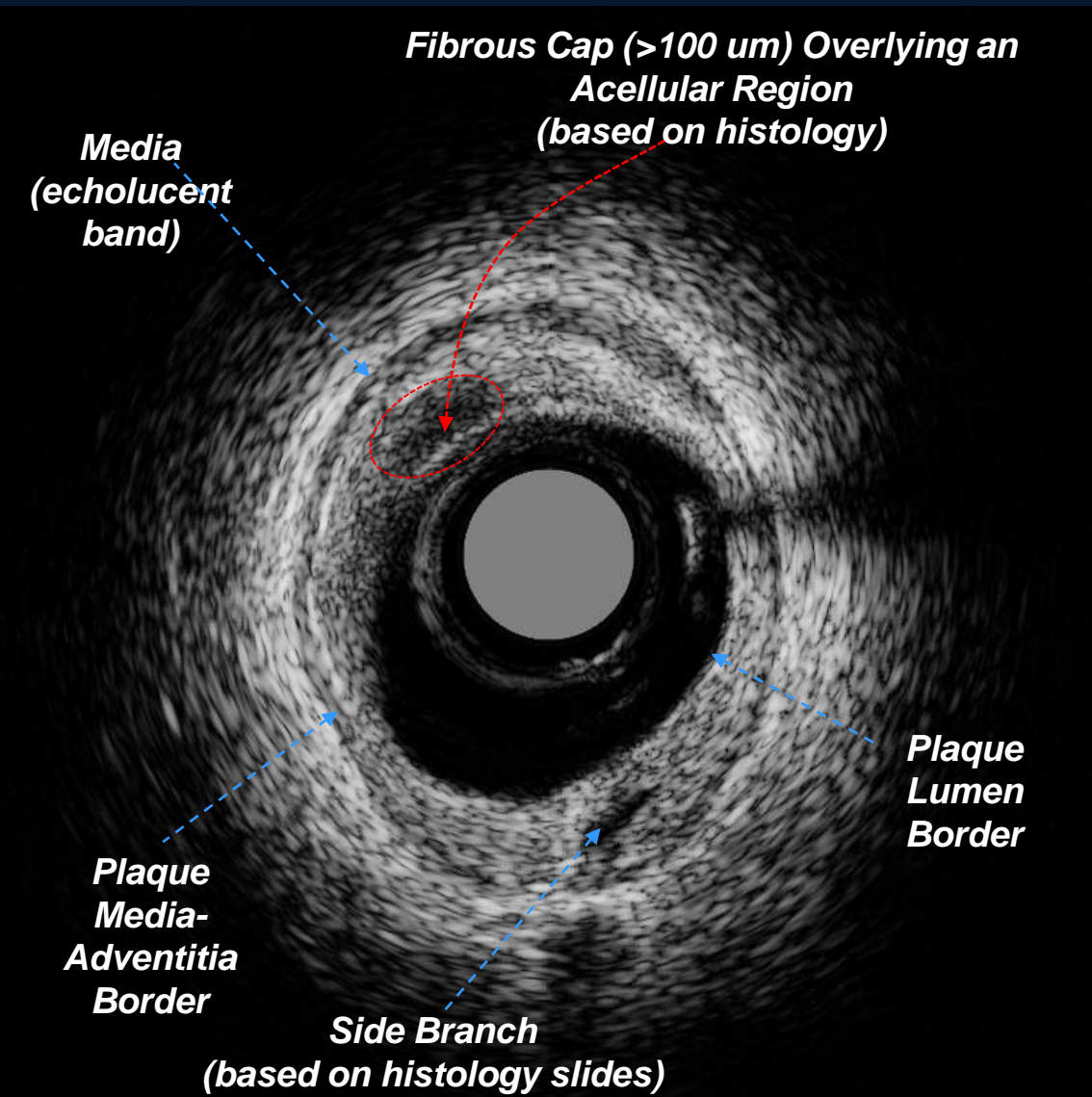
Stents

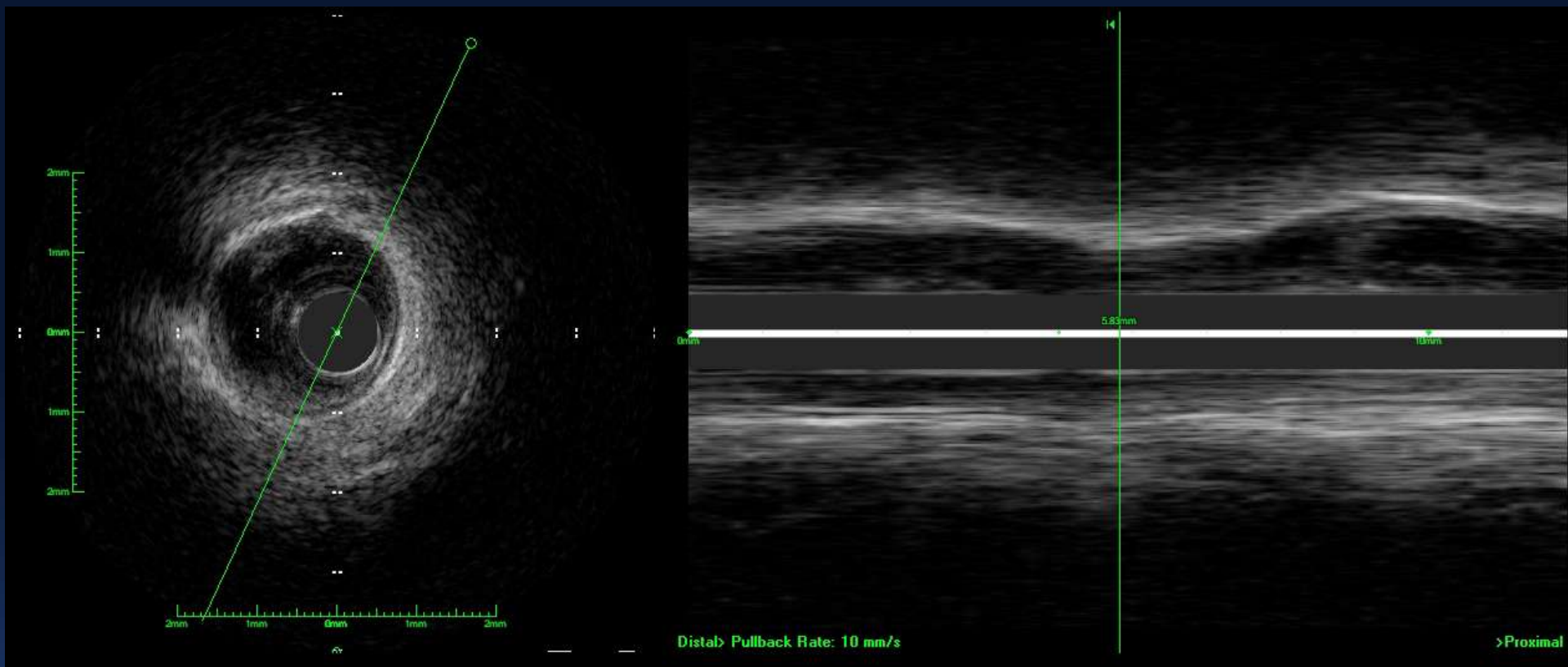


New generation, high resolution IVUS



Axial Resolution	<50 μm
Lateral Resolution	~200 μm
Max. Frame Rate	60 fps
Max. Pullback Speed	10 mm/sec
Frame Spacing	5-167 μm
Pullback length	120 mm
Tissue Penetration	~3 mm @ 60 Mhz
Imaging in Blood	Yes





60MHz @ 60 frame/sec

Pullback speed: 10.0 mm/sec

567 Frames acquired (200 viewed)

File size: 149 MB (10MB WMV viewed)

Acquisition time: 10 sec

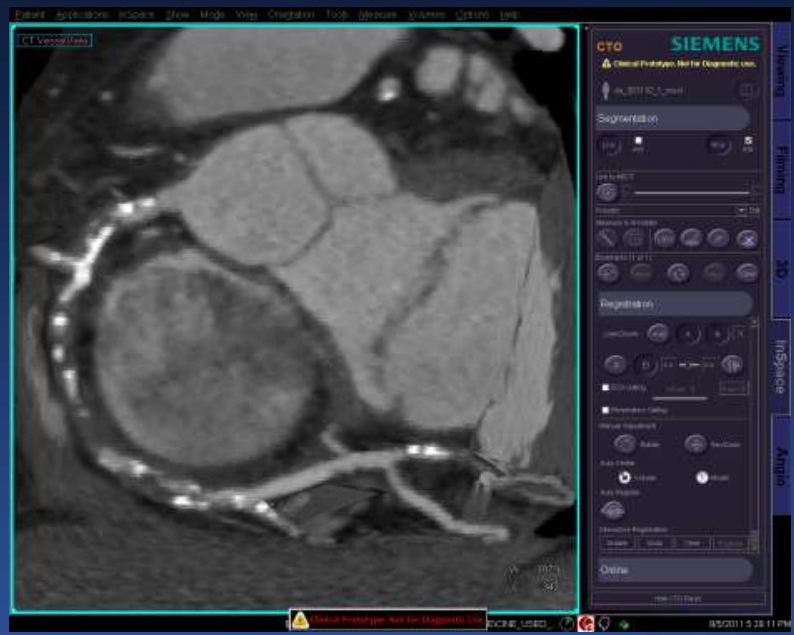
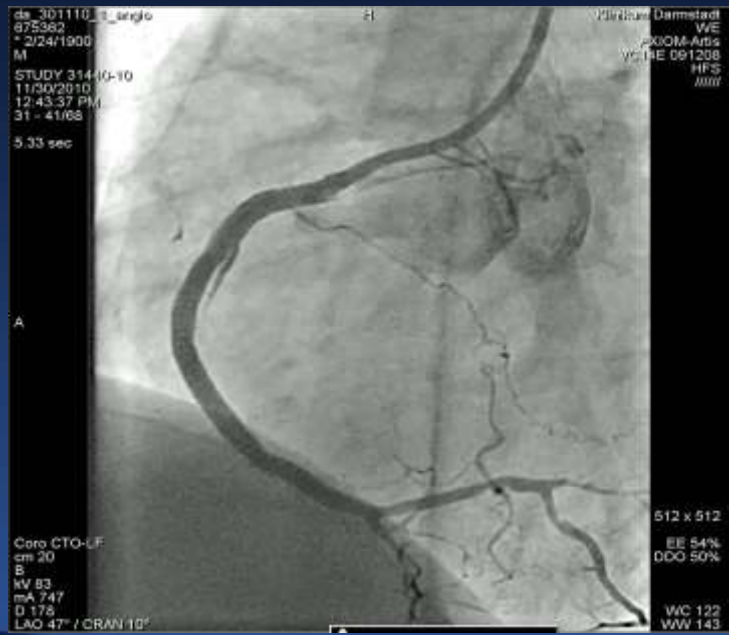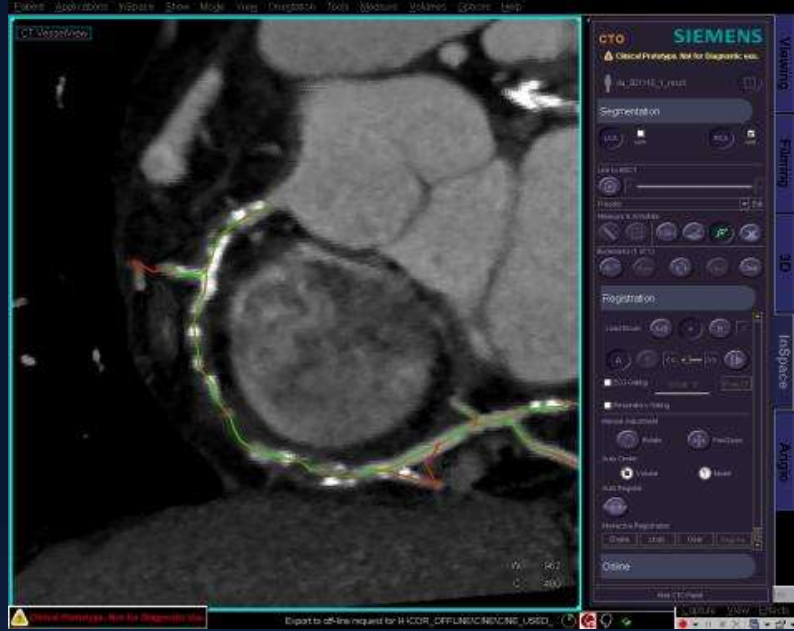
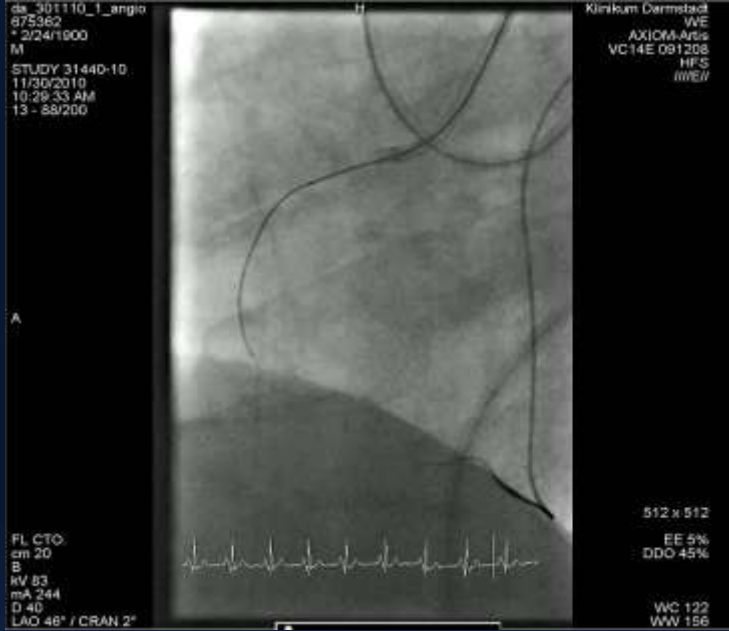
Pullback length: 96mm

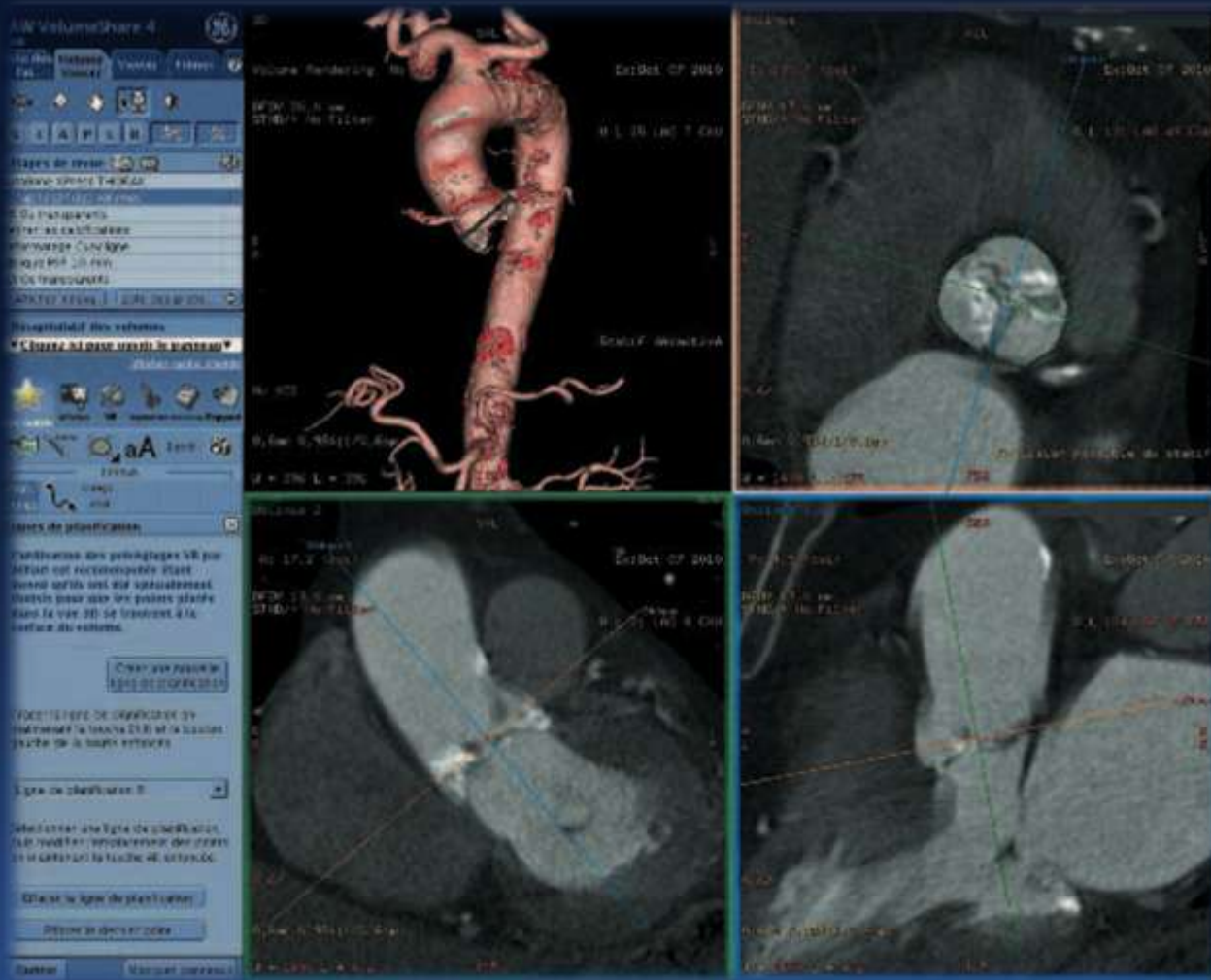Frame spacing: 167 μ m

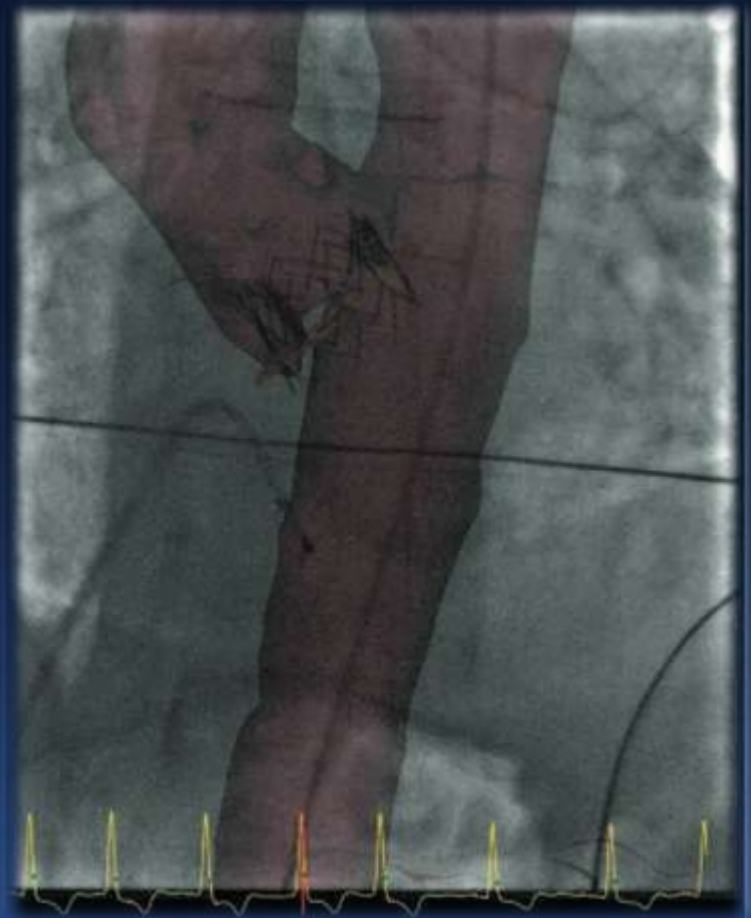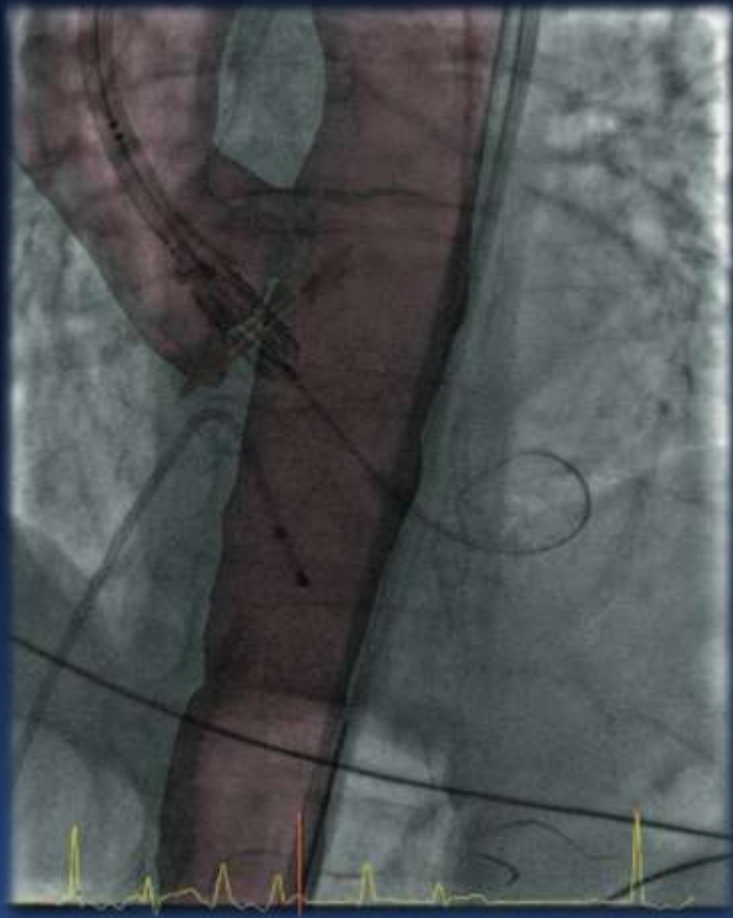15

Co-registration of angio with

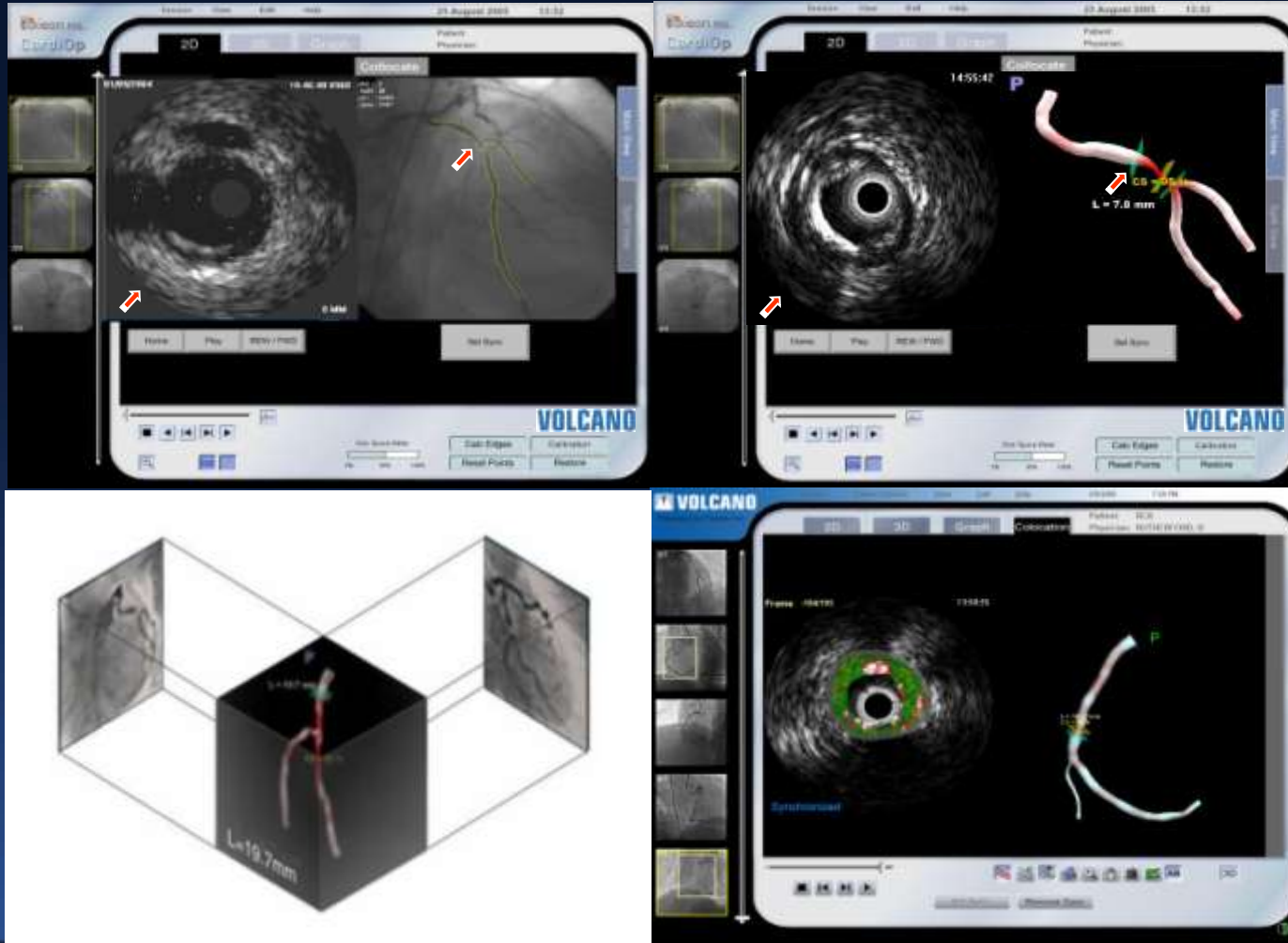
- **MDCT**
 - **Coronary**
 - **Structural**
- **Echo**
- **IVUS**
- **OCT**
- **iFR/FFR**
- **Others**





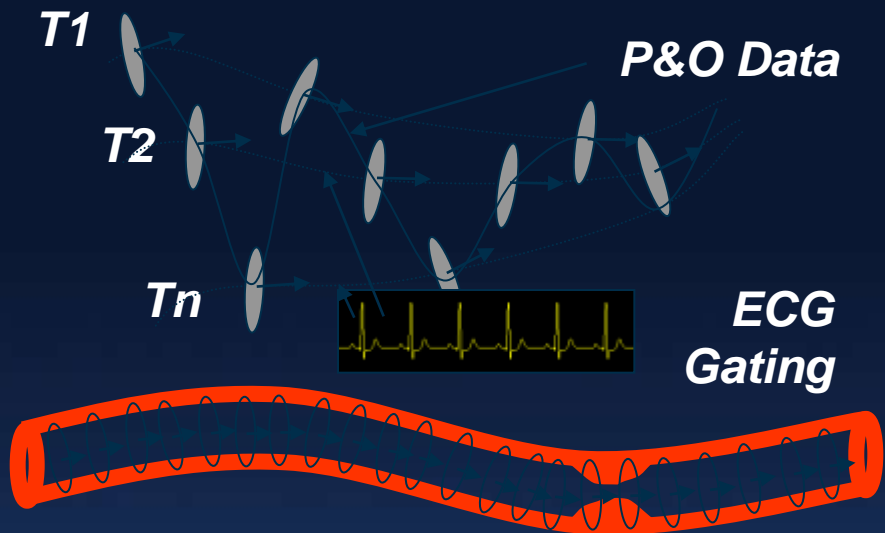
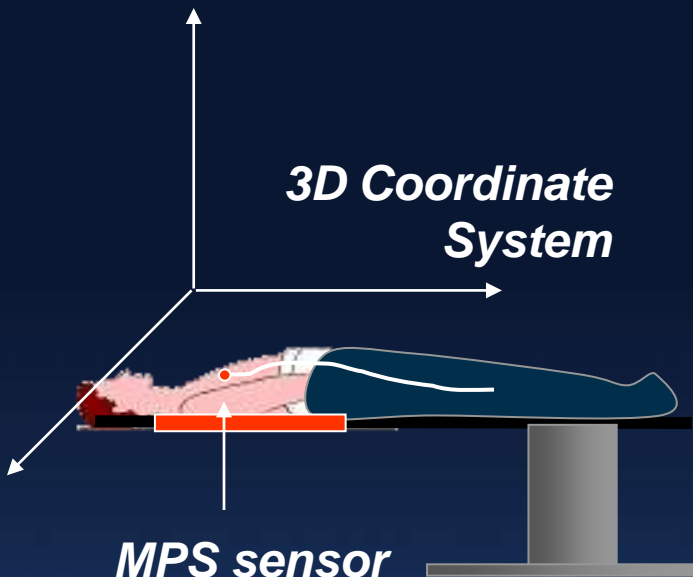


Co-registration of IVUS and Angiography (Paieon)

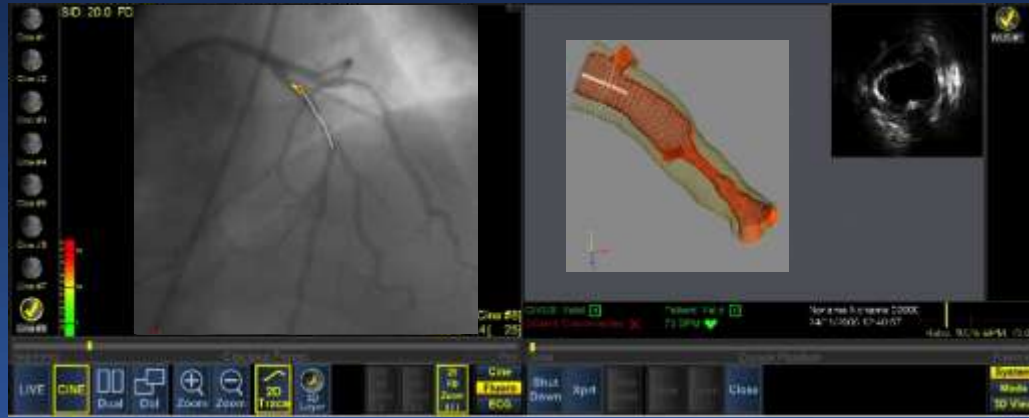

Links angiographic roadmap with corresponding grey-scale and VH-IVUS cross-sections using fiduciary points & interpolated images

Co-registration of IVUS and Angiography (MediGuide, MPS)



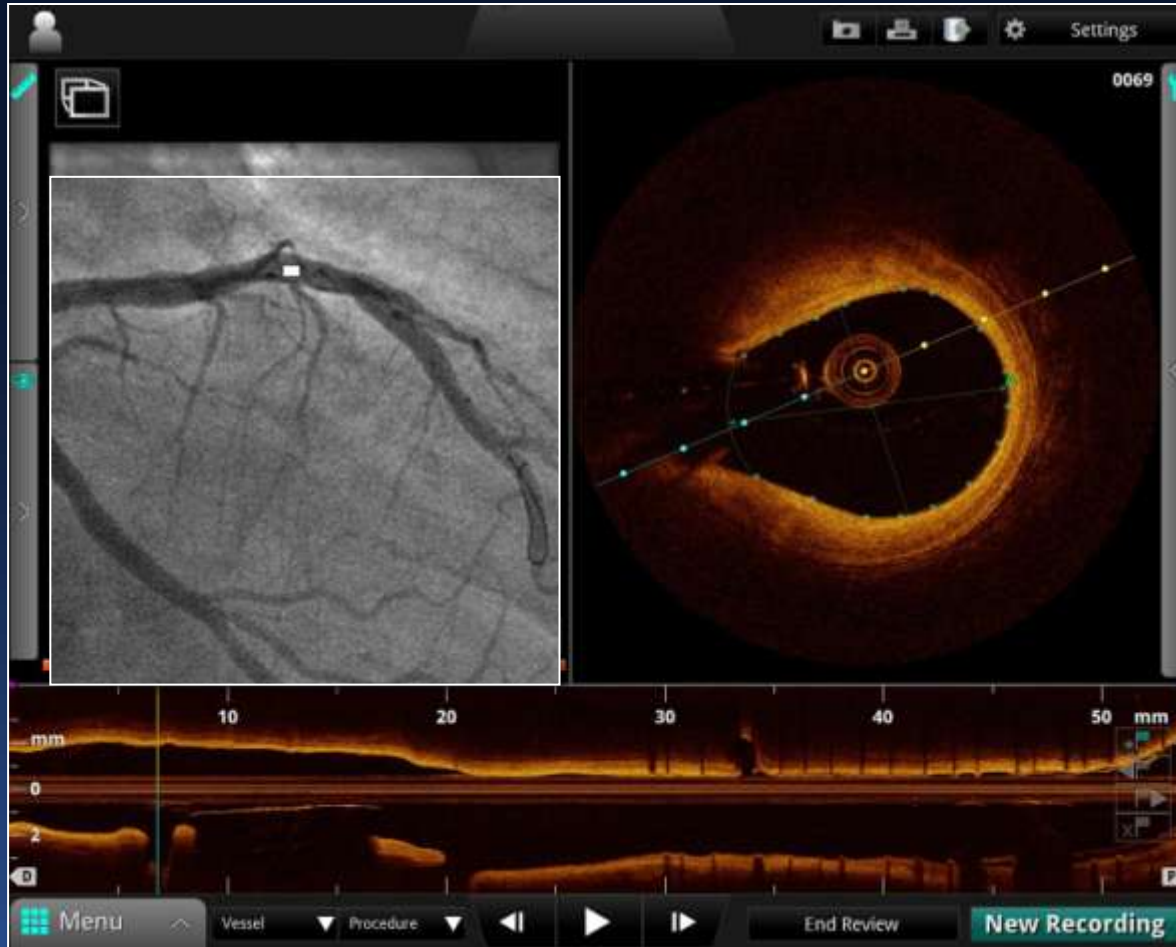
Miniature sensors provide Position and Orientation (P&O) projected on 3D imaging model with an accuracy of $\approx 0.5\text{mm}$



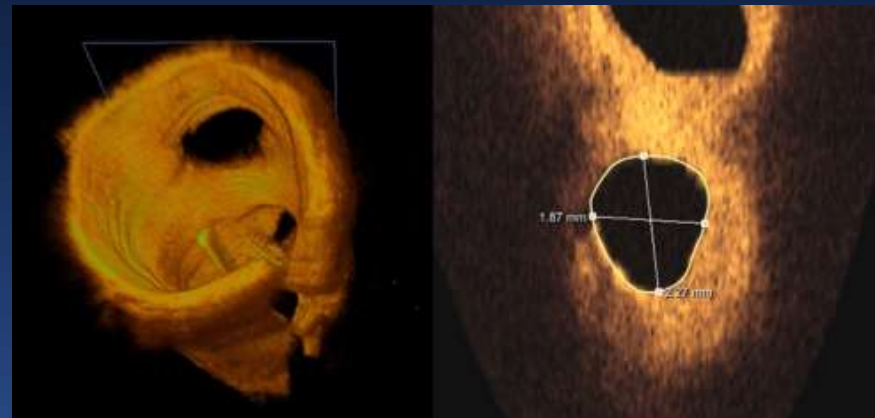
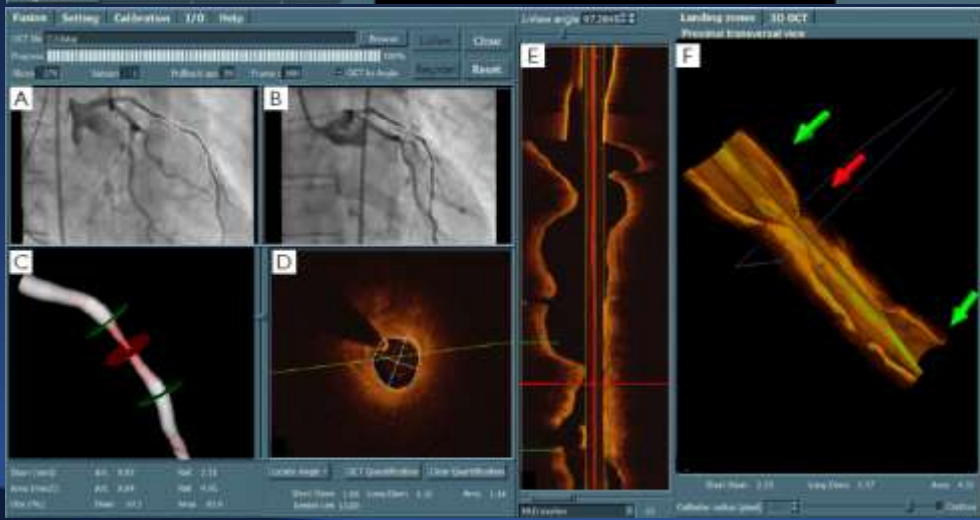
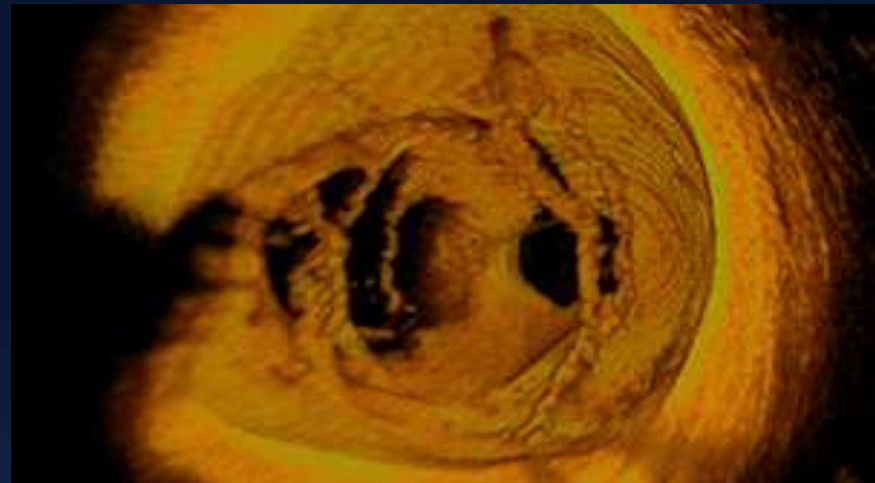
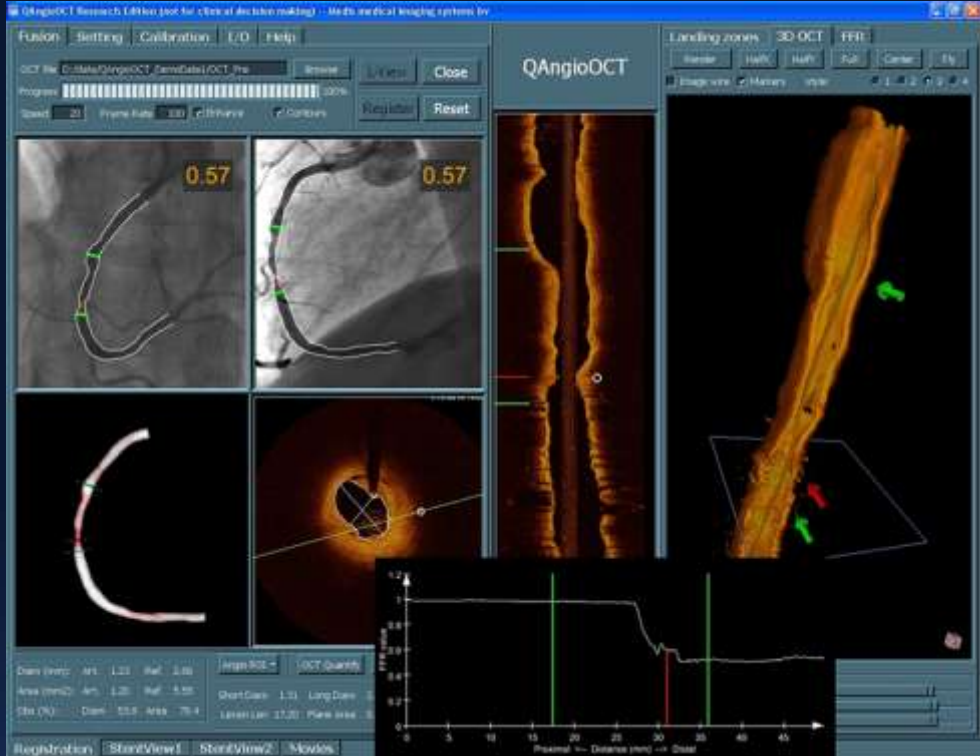
X-ray
 Angio
 QCA & VE
 Deploy.
 Co-reg
 00 mm 10 20 30 40 50
 Image 1/3
 Co-reg
 00:30:05
 Sync-Rx

iFR pullback stenosis mapping





- Directly links OCT and angiography, giving wide-field context to high-resolution pullback
- Enables comprehensive integration of OCT into PCI workflow, both pre- and post-intervention
- Automated software provides coregistration in seconds



3-D OCT

