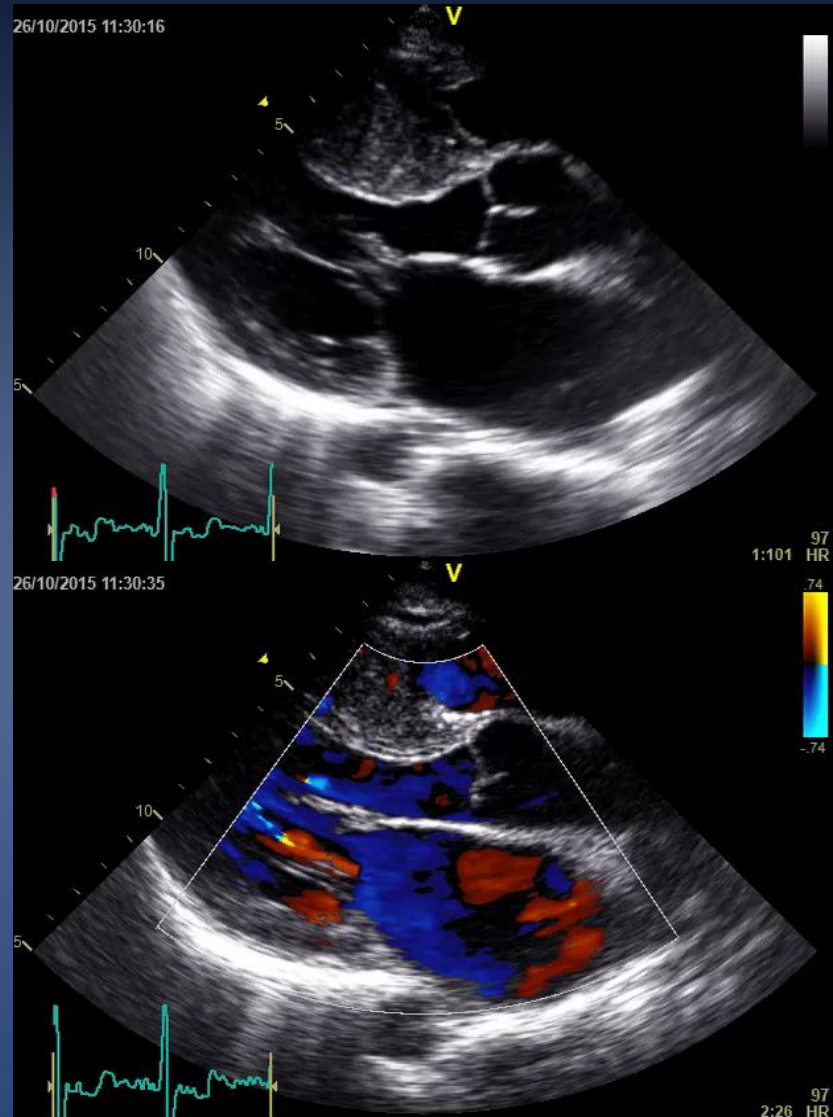


# Alcohol Septal Ablation for HCM : Not as Easy As It Looks

*Dr Chu Chong Mow  
Interventional Cardiologist  
SHC-HQE2*

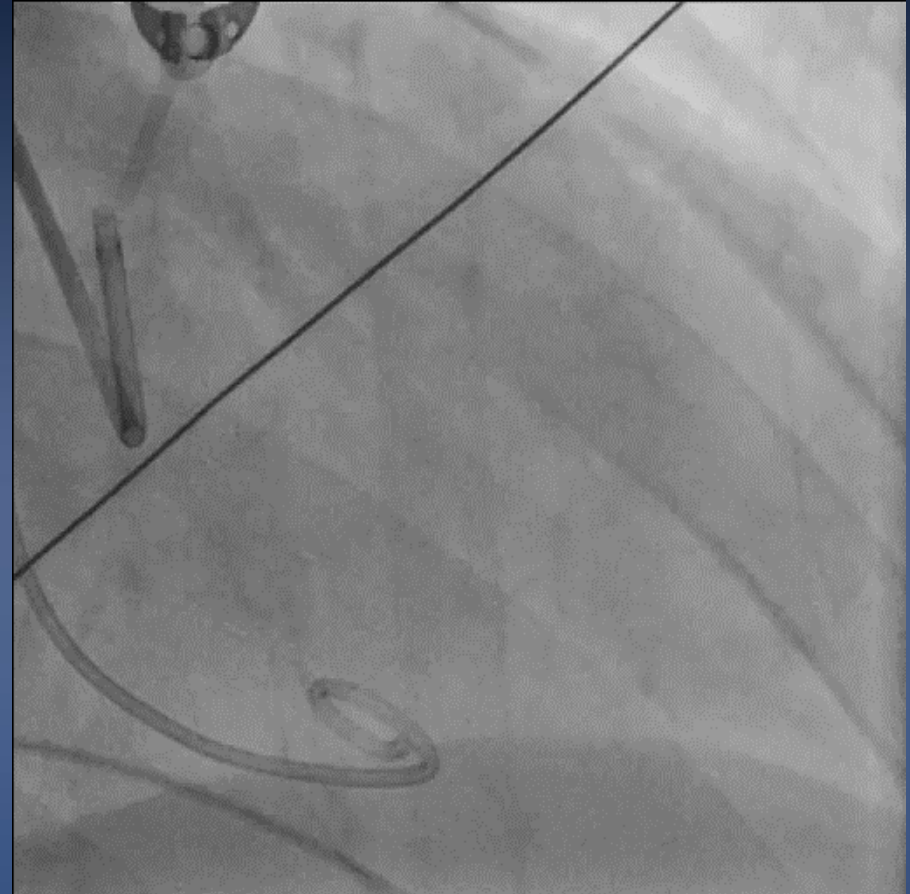
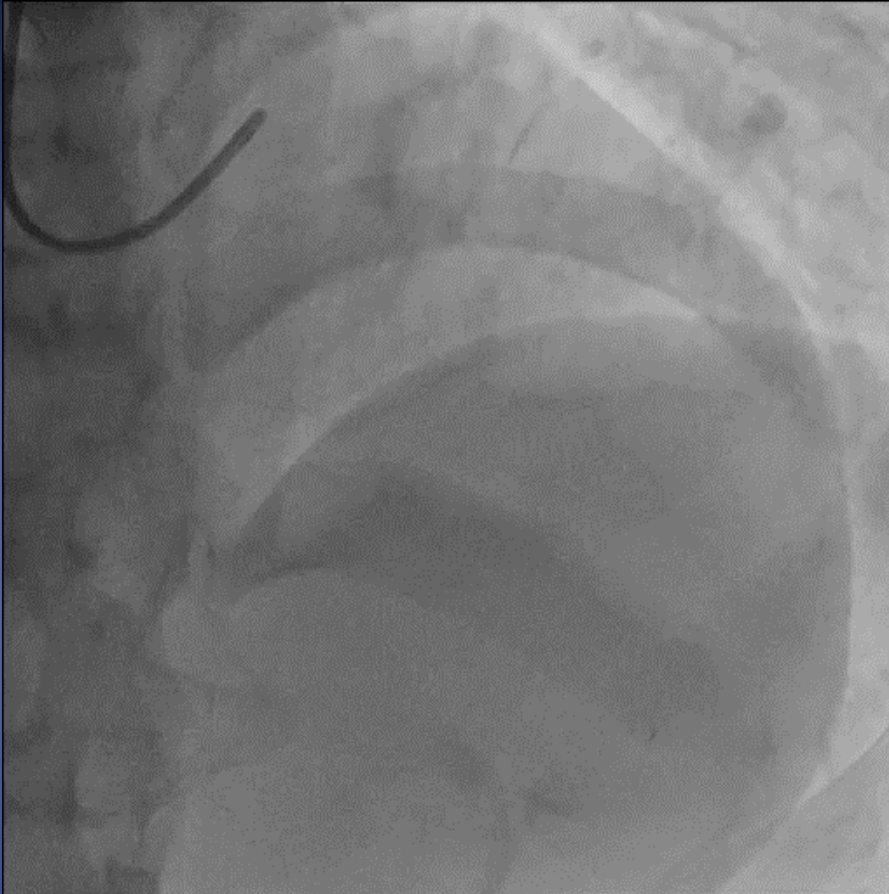
# Mr SR

- 32 male
- FHx of HCM
- Family screening
- Chest discomfort
- ↓ Effort tolerance
- Dyspnea
- Ix
  - EST NAD
  - Holter NAD
  - ECHO
    - Severe ASH
    - LVOT 36mmHg
    - Invasive cath 53mmHg with Valsava



# Diagnostic Angiogram

Right radial 6 Fr, right femoral artery and vein 6Fr  
TPM inserted RV . 6Fr pigtail in LV, EBU 3.5 6Fr



OTW balloon, BMW wire  
Unable to wire the 1<sup>st</sup> septal  
What would you do next?

