Endoleaks: What is the Best Long-Term Surveillance and Management Strategy

John R. Laird, MD
David Del Pizzo, MHA, RVT
UC Davis Vascular Center

UC DAVIS
HEALTH SYSTEM

Endovascular Aneursym Repair

- 600% increase in EVAR procedures since 2000.
- EVAR now accounts for >50% of AAA repairs.
- Significant decrease in deaths from intact and ruptured AAA since EVAR.
- ***Risk of rupture and device failure following EVAR warrants surveillance methods.***



1. Giles K., et al; JVS 2009 Vol49:3
2. Chaikoff E., et al; JVS 2009 Vol 50:85

EVAR Surveillance: Purpose

- Prevent Rupture
  - Evaluate for the presence of endoleak
  - Monitor AAA sac size
- Device Status
  - Migration
  - Structural failure
- Outflow
  - Graft Limbs
  - Distal perfusion
- **Intervention?**

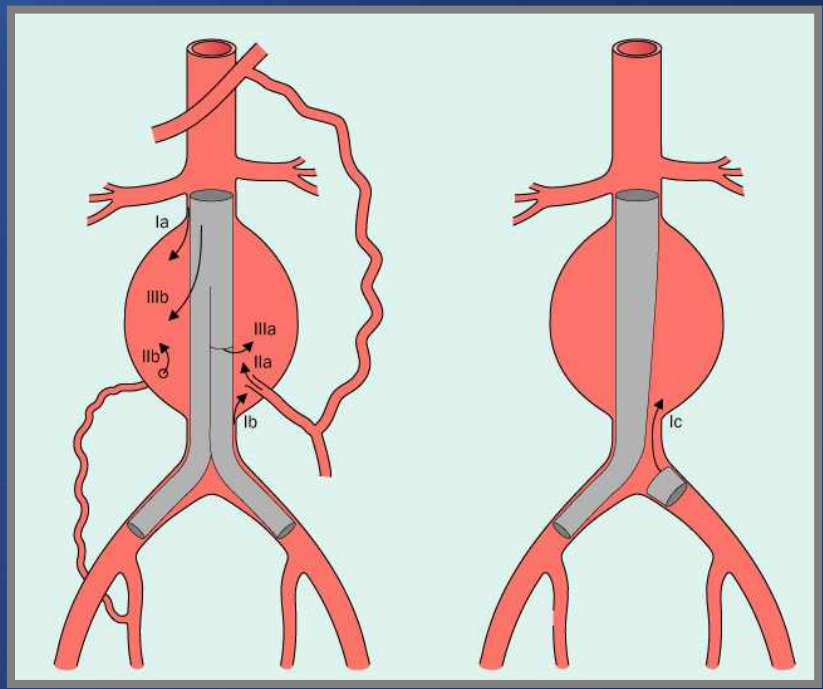

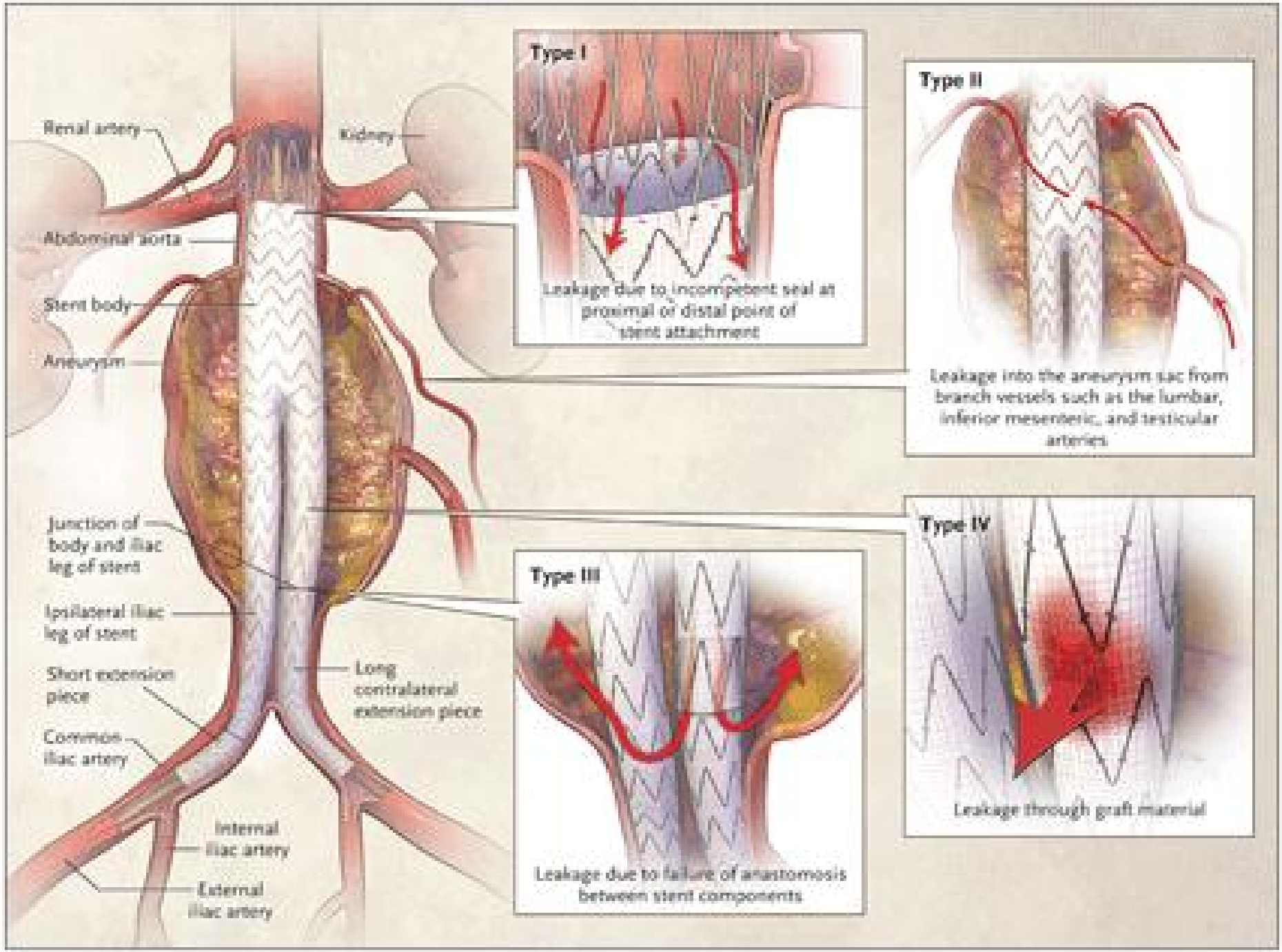
Renal artery
Kidney
Abdominal aorta
Stent body
Aneurysm
Junction of body and iliac leg of stent
Ipsilateral iliac leg of stent
Short extension piece
Common iliac artery
Internal iliac artery
External iliac artery
Long contralateral extension piece
Type I
Leakage due to incompetent seal at proximal or distal point of stent attachment
Type II
Leakage into the aneurysm sac from branch vessels such as the lumbar, inferior mesenteric, and testicular arteries
Type III
Leakage due to failure of anastomosis between stent components
Type IV
Leakage through graft material

EVAR Surveillance: Why is it Necessary?

5-Year US Zenith Trial Results

- 739 patients
- 16.9% had endoleak identified on one-month post EVAR scan
- Even if no early endoleak present, late endoleak will occur in 12-15%
- Treatment of early and late Type II endoleaks accounted for 2/3 of all secondary interventions

UCDAVIS
HEALTH SYSTEM

Endoleak Interventions
Eurostar Registry

- 2846 EVAR patients
- 615 Endoleaks identified
- 120 Endoleak interventions (4.2% of all EVAR cases)
  - Type I – 49 cases
  - Type II – 51 cases
  - Type III – 20 cases

J Vasc Surg 2006;43:896-902

UCDAVIS HEALTH SYSTEM

Type I Endoleak

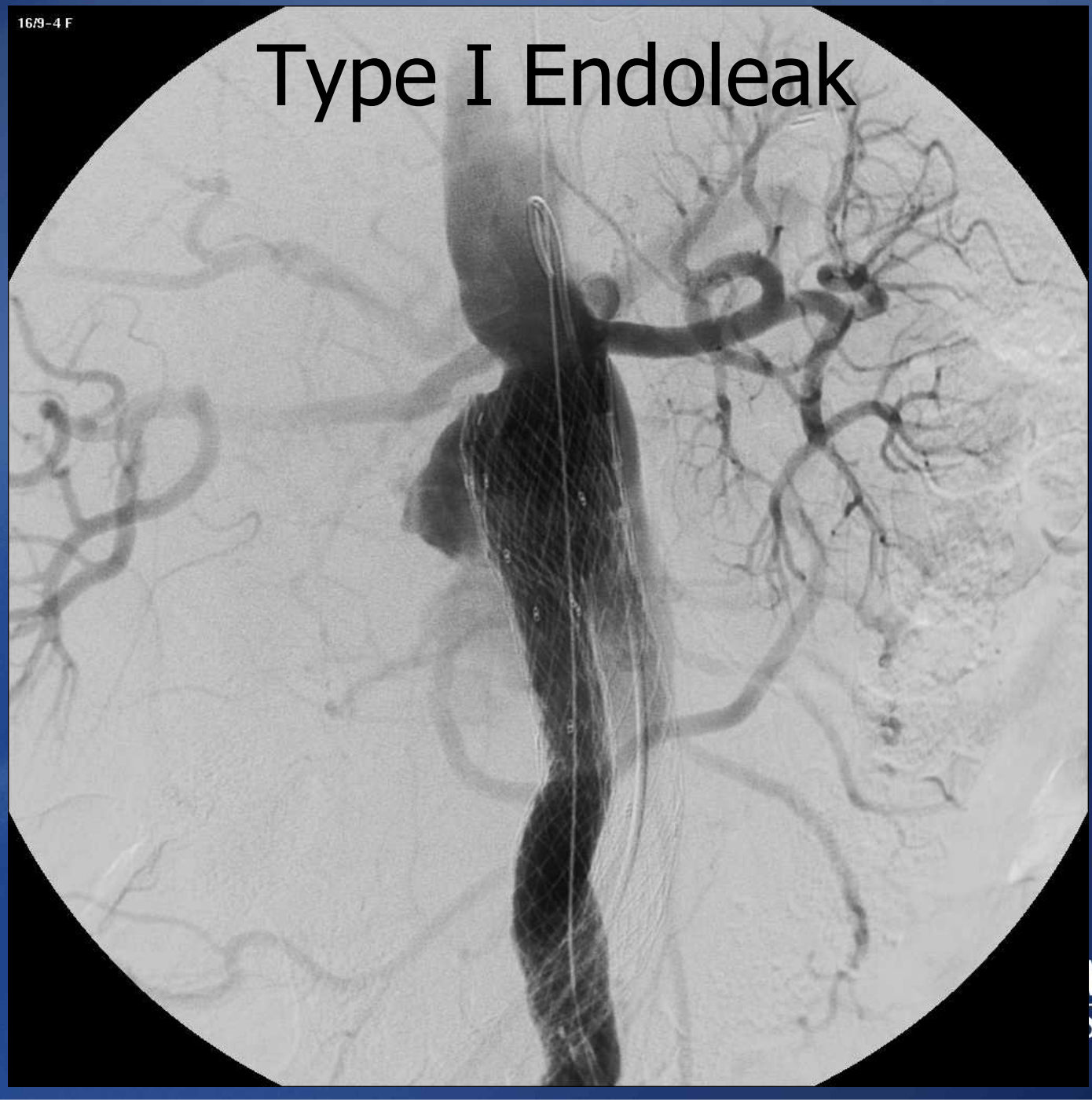

AVIS
SYSTEM

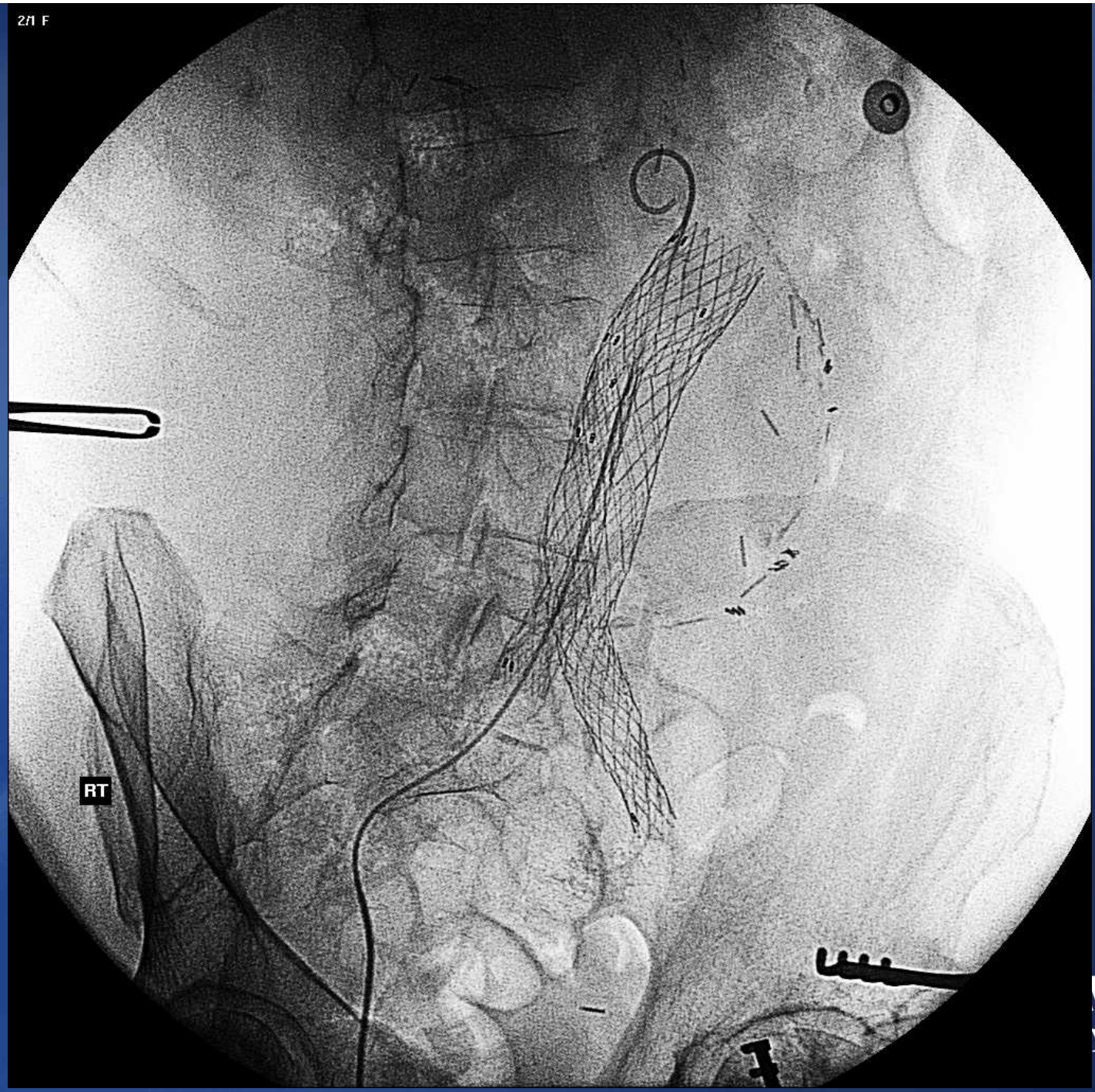

VIS
YSTEM

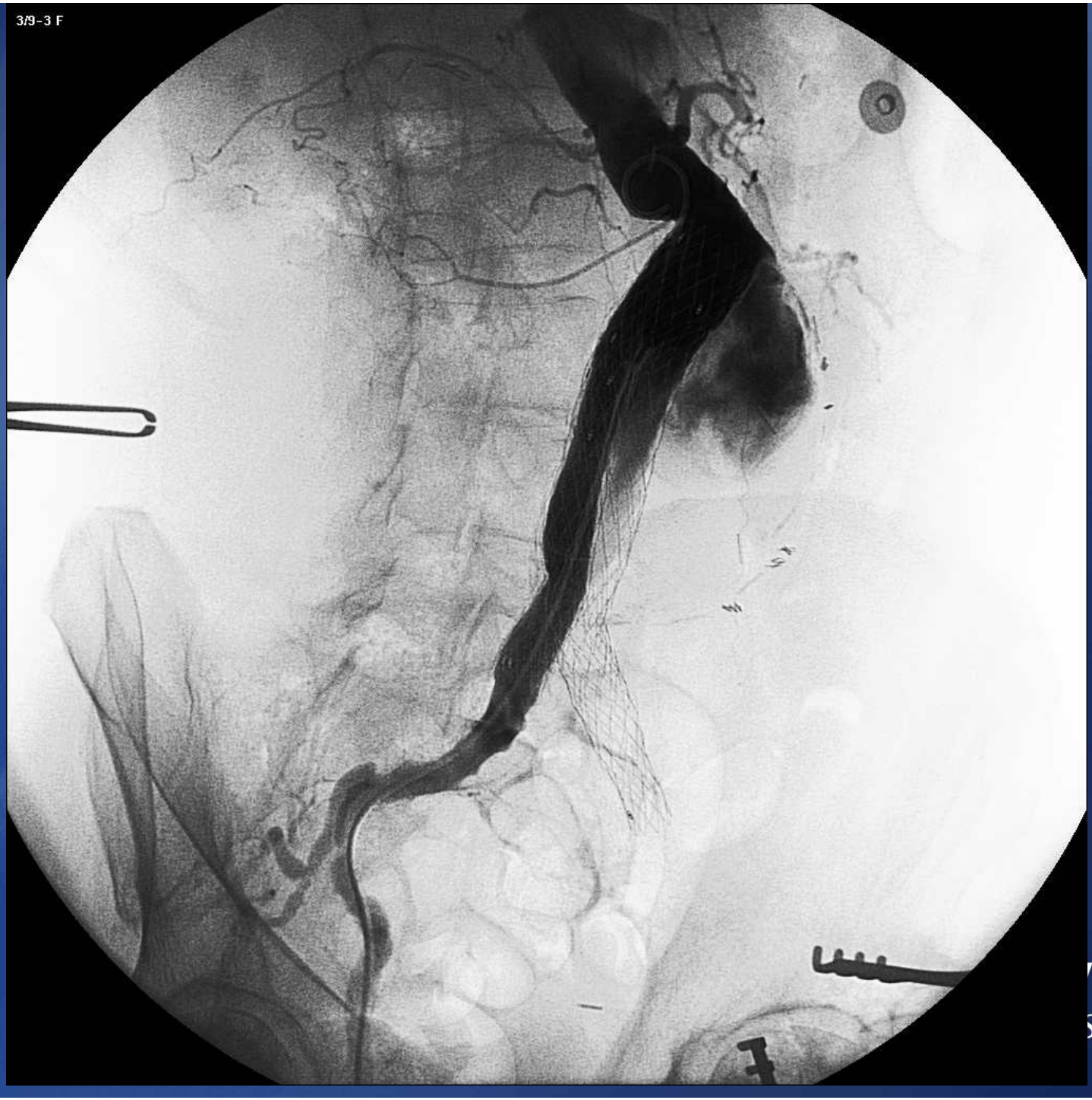

VIS
STEM


12/10-4 F

Late Graft Failure

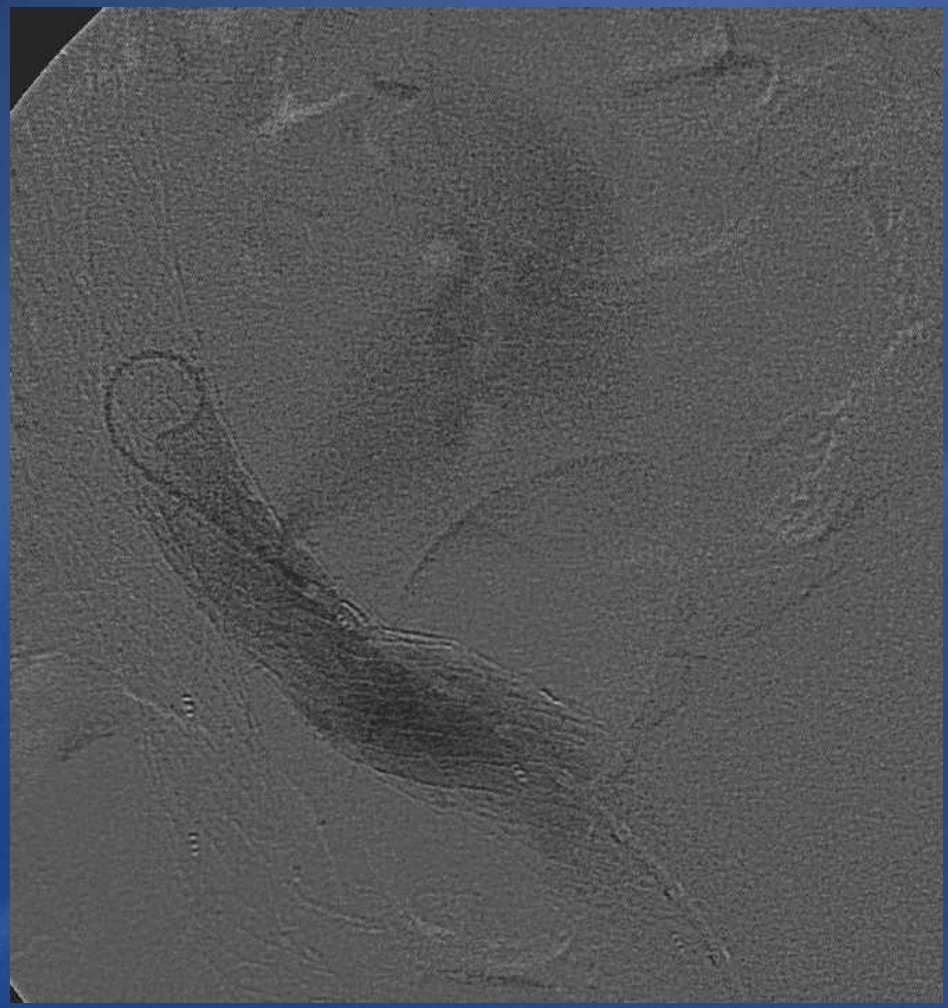

Type III Endoleak

UC DAVIS HEALTH SYSTEM

Endovascular Repair with Iliac Limb

UCDAVIS
HEALTH SYSTEM

Type II Endoleak

"What we call progress is the exchange of one nuisance for another"

Havelock Ellis

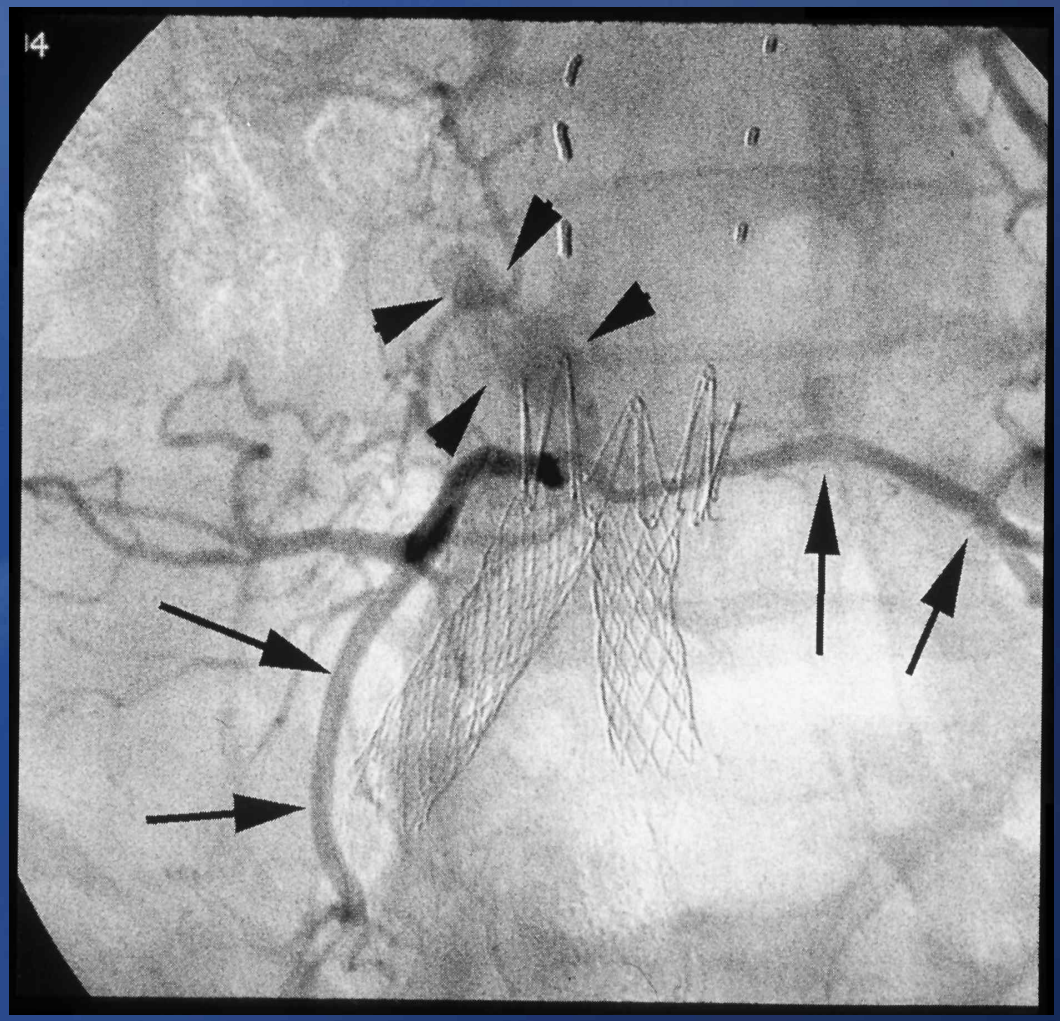

UCDAVIS
HEALTH SYSTEM

EVAR surveillance: SVS Recommendations

The care of patients with an abdominal aortic aneurysm: The Society for Vascular Surgery practice guidelines

Elliot L. Chaikof, MD, PhD,[a] David C. Brewster, MD,[b] Ronald L. Dalman, MD,[c] Michel S. Makaroun, MD,[d] Karl A. Illig, MD,[e] Gregorio A. Sicard, MD,[f] Carlos H. Timaran, MD,[g] Gilbert R. Upchurch Jr, MD,[h] and Frank J. Veith, MD,[i] *Atlanta, Ga, Boston, Mass, Palo Alto, Calif, Pittsburgh, Penn, Rochester, NY, St. Louis, Mo, Dallas, Tex, Ann Arbor, Mich, and Cleveland, Ohio*

	Level of Recommendation	Quality of Evidence
Surveillance at 1 and 12 months should consist of contrast enhanced CT imaging	Strong	High
For type II endoleaks, contrast enhanced CT should be performed at 6month intervals for sac assessment	Strong	High
Color duplex and non-contrast CT are suggested for patients with renal insufficiency	Strong	High
If neither endoleak nor aneurysm growth is documented in the first year then color duplex ultrasound is suggested as an alternate for annual surviellance.	Weak	Low

HEALTH SYSTEM

1. Chaikoff E., et al; JVS 2009 Vol 50:85

SVS Practice Guidelines
EVAR Surveillance



1 month:
CT with contrast

6 month:
IF one month abnormal then CTA

12 months:
CT with contrast

Annual Surveillance

1. If 12 mo Normal: "color flow duplex may be a reasonable alternative to CT for annual surveillance"
2. If abnormal CT every 6 months for diameter change

UCDAVIS HEALTH SYSTEM

1. Chaikoff E., et al; JVS 2009 Vol 50:85

Duplex vs. CT

UCDAVIS
HEALTH SYSTEM

CT – The Gold Standard?

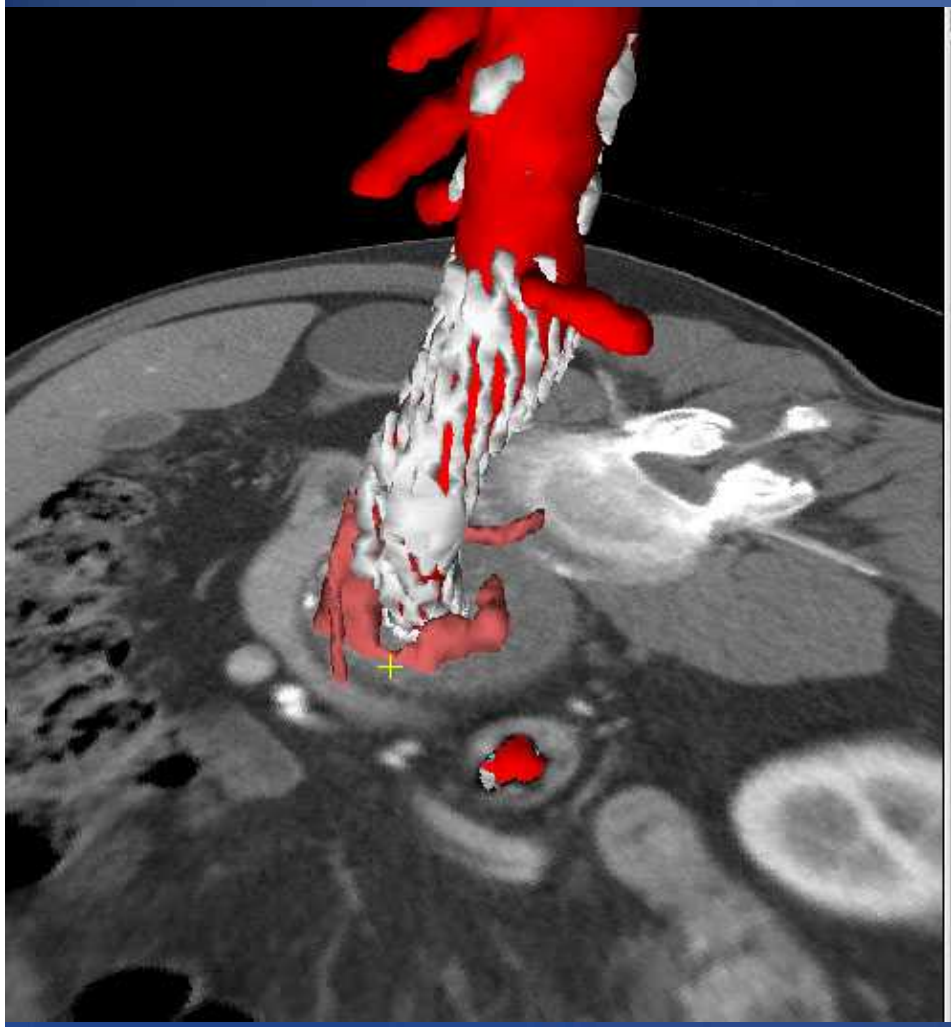

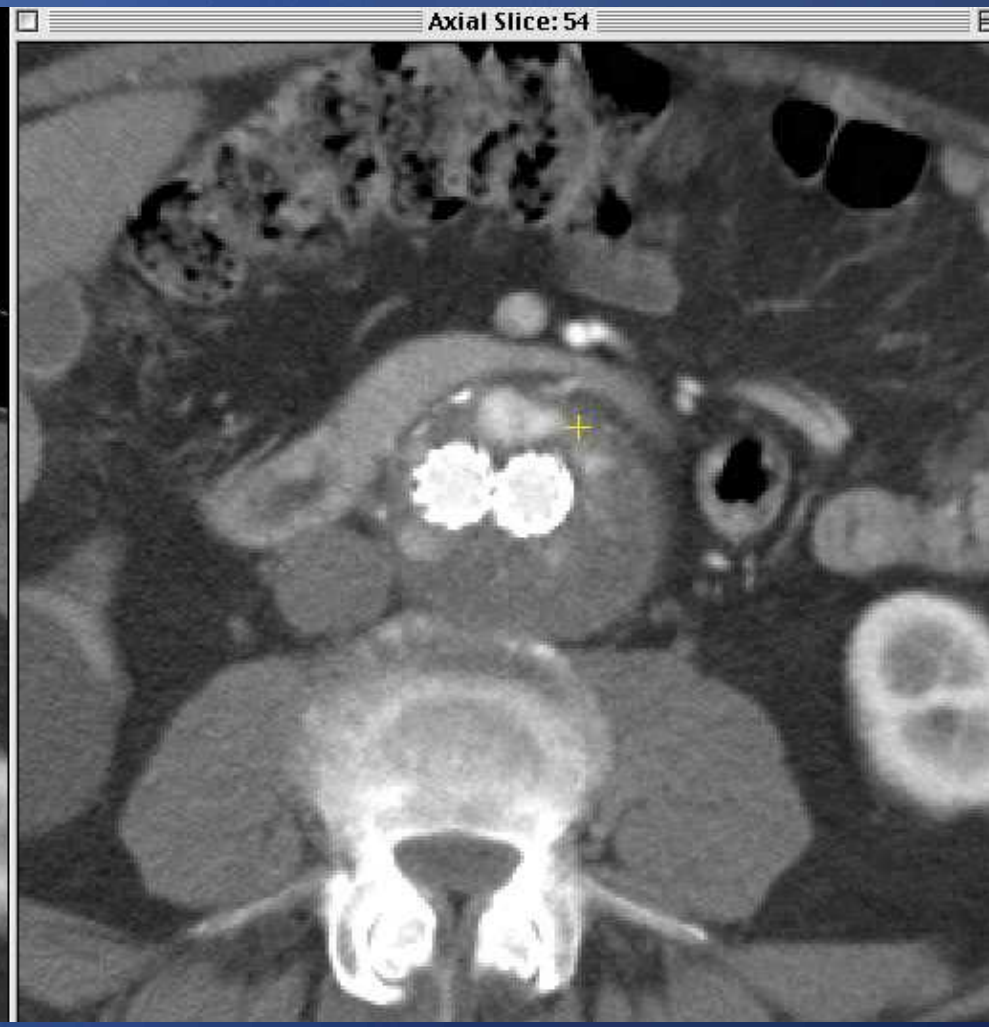

UCDAVIS
HEALTH SYSTEM

CT Risks and Disadvantages

- Contrast induced nephropathy
- Radiation dose equivalent of 300 to 400 chest x-rays
- $16,000 per 3 yr / pt cost increase with CT
- Lacks temporal resolution
- False negatives or Endotension

Beeman et al; Duplex imaging alone is sufficient for midterm endovascular repair. JVS 2009 Nov 50:5

Bendick PJ, Zelinock GB, Rove PG, et al. Duplex ultrasound imaging with an ultrasound contrast agent: The economic alternative to CT angiography for aortic stent graft surveillance. *Vasc Endovascular Surg* 2003;37: 165-170.

The NEW ENGLAND JOURNAL of MEDICINE
N Engl J Med 2007;357:2277-84.

REVIEW ARTICLE

CURRENT CONCEPTS

Computed Tomography — An Increasing Source of Radiation Exposure

David J. Brenner, Ph.D., D.Sc., and Eric J. Hall, D.Phil., D.Sc.

THE ADVENT OF COMPUTED TOMOGRAPHY (CT) HAS REVOLUTIONIZED DIagnostic radiology. Since the inception of CT in the 1970s, its use has increased rapidly. It is estimated that more than 62 million CT scans per year are currently obtained in the United States, including at least 4 million for children.[1]

By its nature, CT involves larger radiation doses than the more common, conventional x-ray imaging procedures (Table 1). We briefly review the nature of CT scanning and its main clinical applications, both in symptomatic patients and, in a more recent development, in the screening of asymptomatic patients. We focus on the increasing number of CT scans being obtained, the associated radiation doses, and the consequent cancer risks in adults and particularly in children. Although the risks for any one person are not large, the increasing exposure to radiation in the population may be a public health issue in the future.

UCDAVIS
HEALTH SYSTEM

Color Duplex Ultrasound

- Advantages
  - Low cost
  - Low risk
  - Portable
  - Static and Dynamic information
  - Well established tool for aneurysm measurements
- Disadvantages
  - Technologist dependent
  - Time consuming, labor intensive protocols
  - Patient size
  - Range of sensitivity; **arbitrarily compared to CTA**

UCDAVIS HEALTH SYSTEM

Duplex Surveillance: Dimensions and Sac characteristics

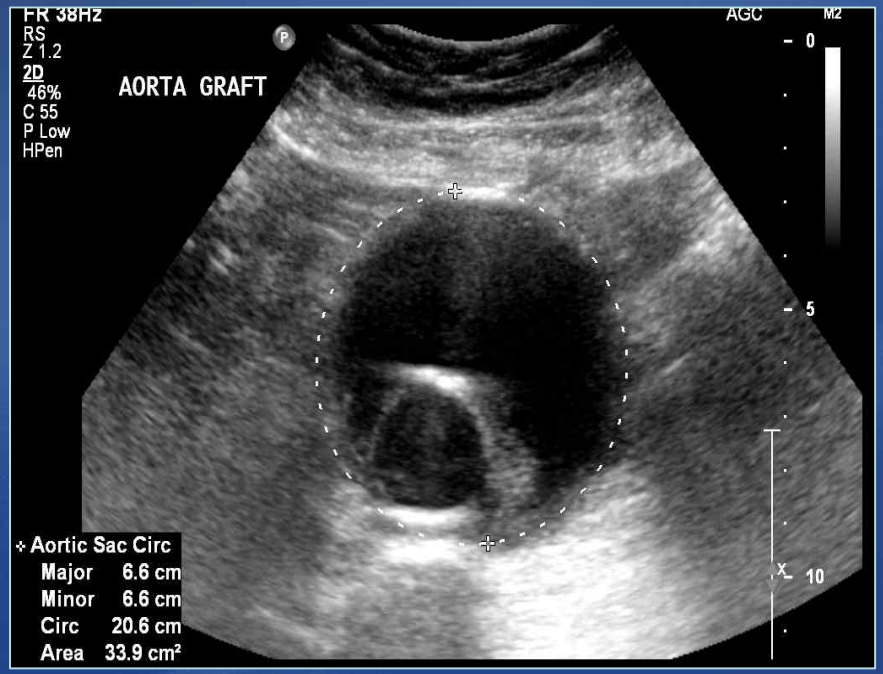

Diameter and circumference measurements

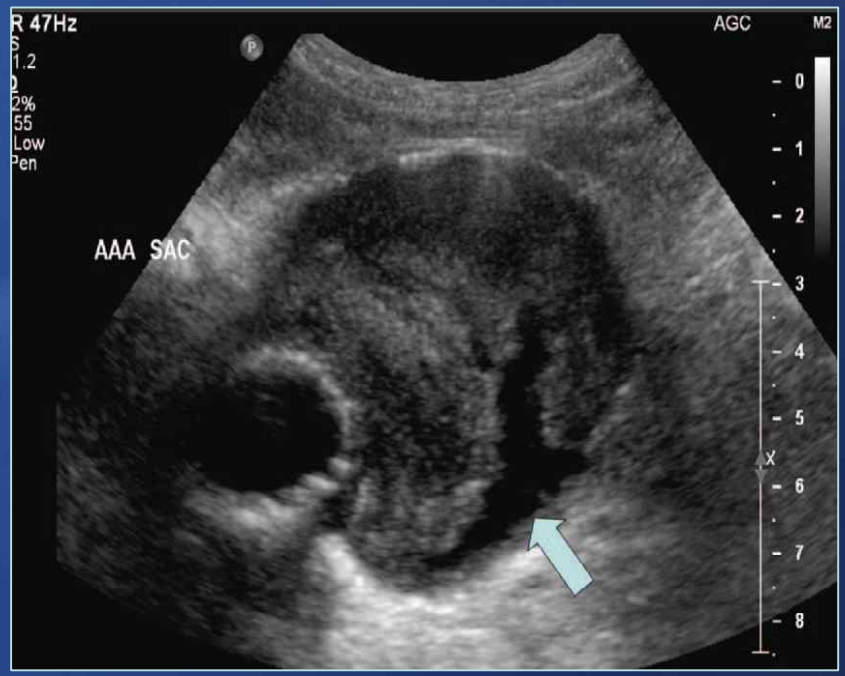

Aortic sac intraluminal echoes characterization

UCDAVIS HEALTH SYSTEM

Preoperative

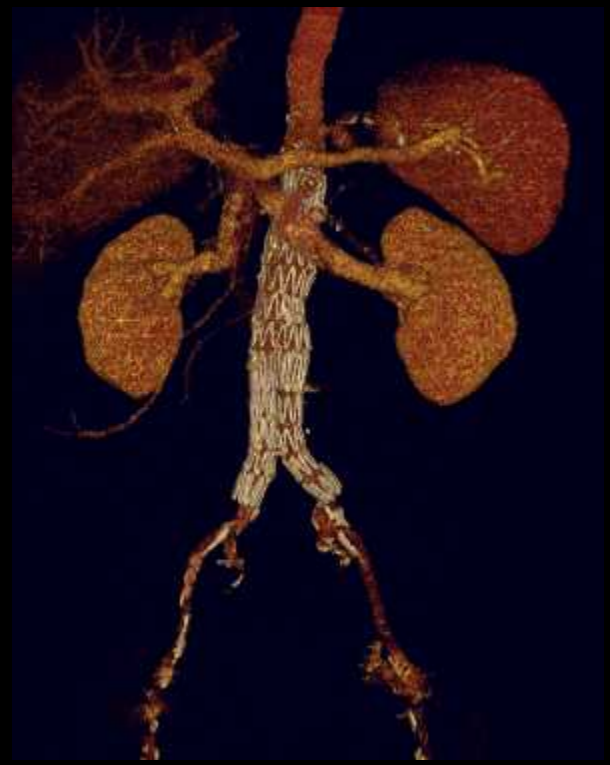

1 month post-EVAR
5.2 cm

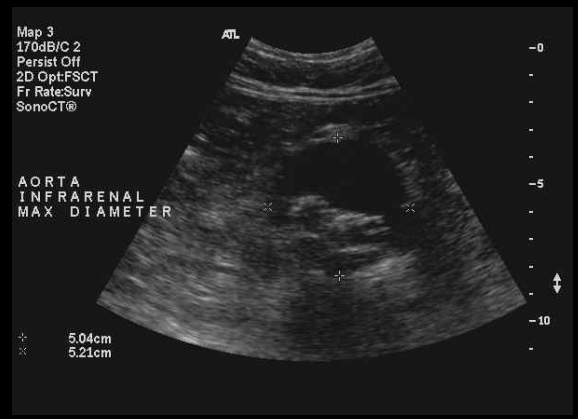

4 months post-EVAR
5.2 cm

7 months post-EVAR
3.7 cm

13 months post-EVAR
2.9 cm

Fixation Sites: Type I

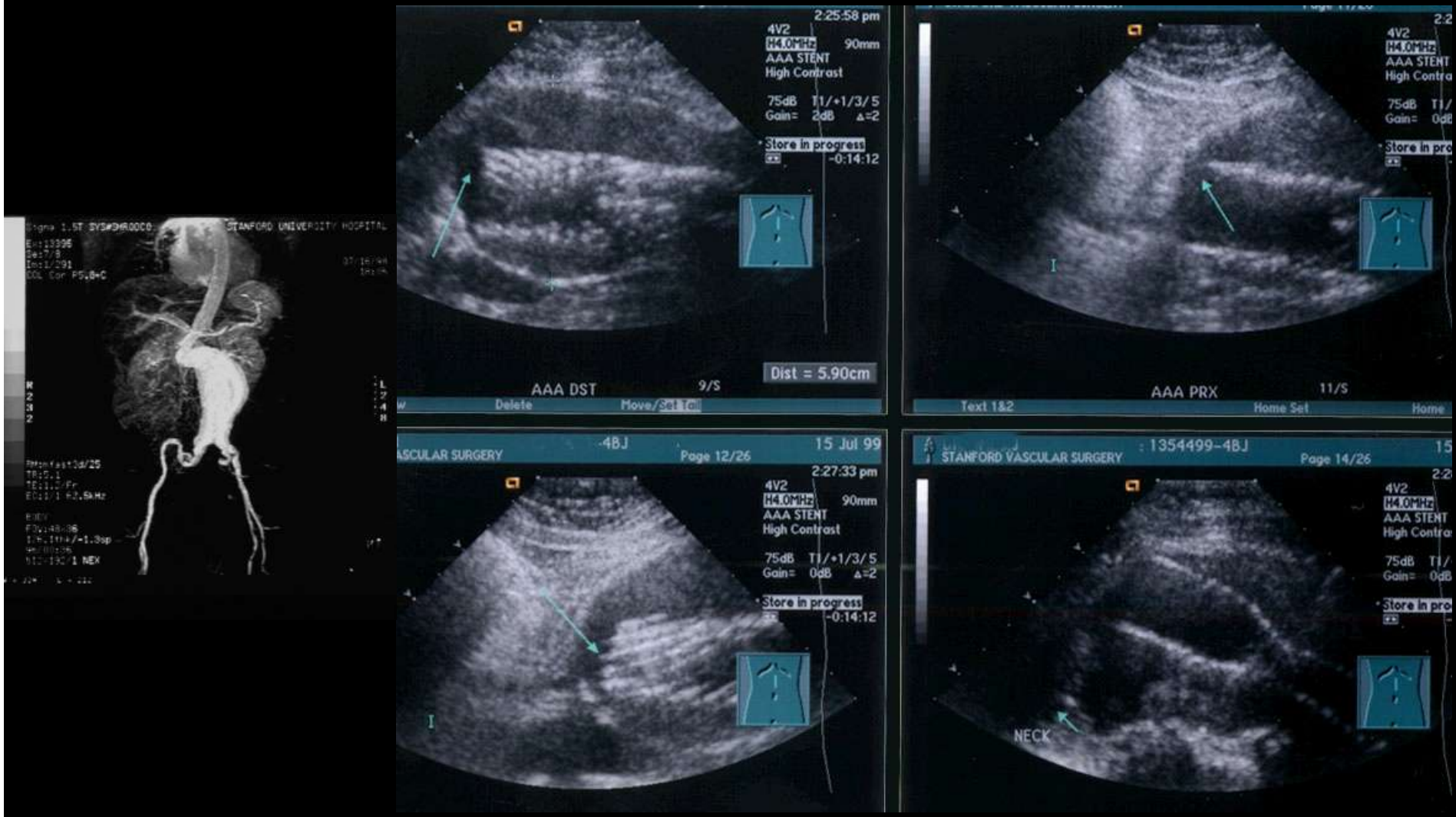

Images: Bonnie Johnson, RVT

Duplex Surveillance: Type II Endoleaks

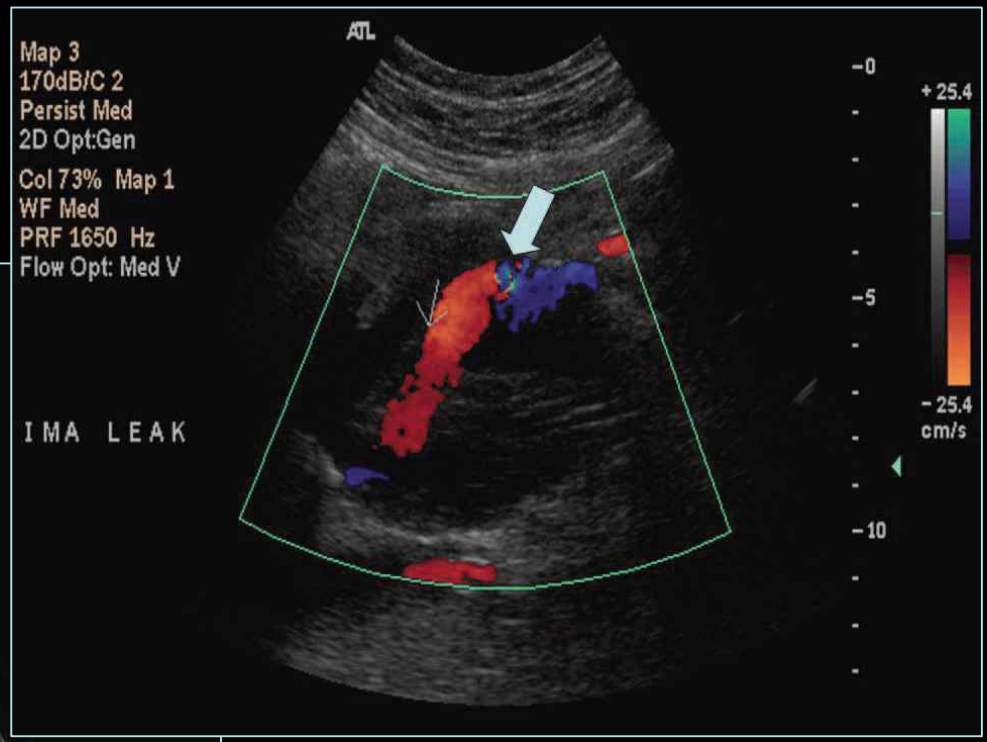

Type IIa: IMA

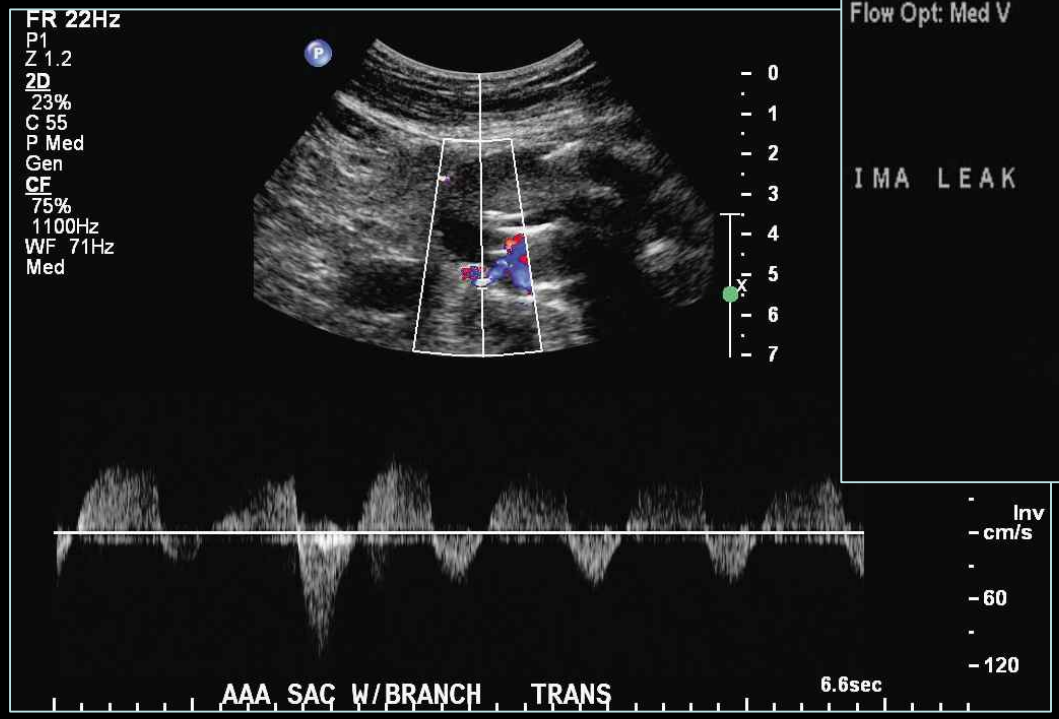

Type IIb: To-fro flow

Device Integrity
Type III

Images: Bonnie Johnson, RVT

Radiographs for migration and strut fracture

Radiation – YES – but less radiation than CT!!!

MS Conners III, WC Sternbergh III, G Carter, et al. J Vasc Surg 2002;36:476-84.)

Endotension

- No endoleak per CT
- Flow detected in sac by duplex
- AAA sac 5.9 to 7.5 cm in 34 months

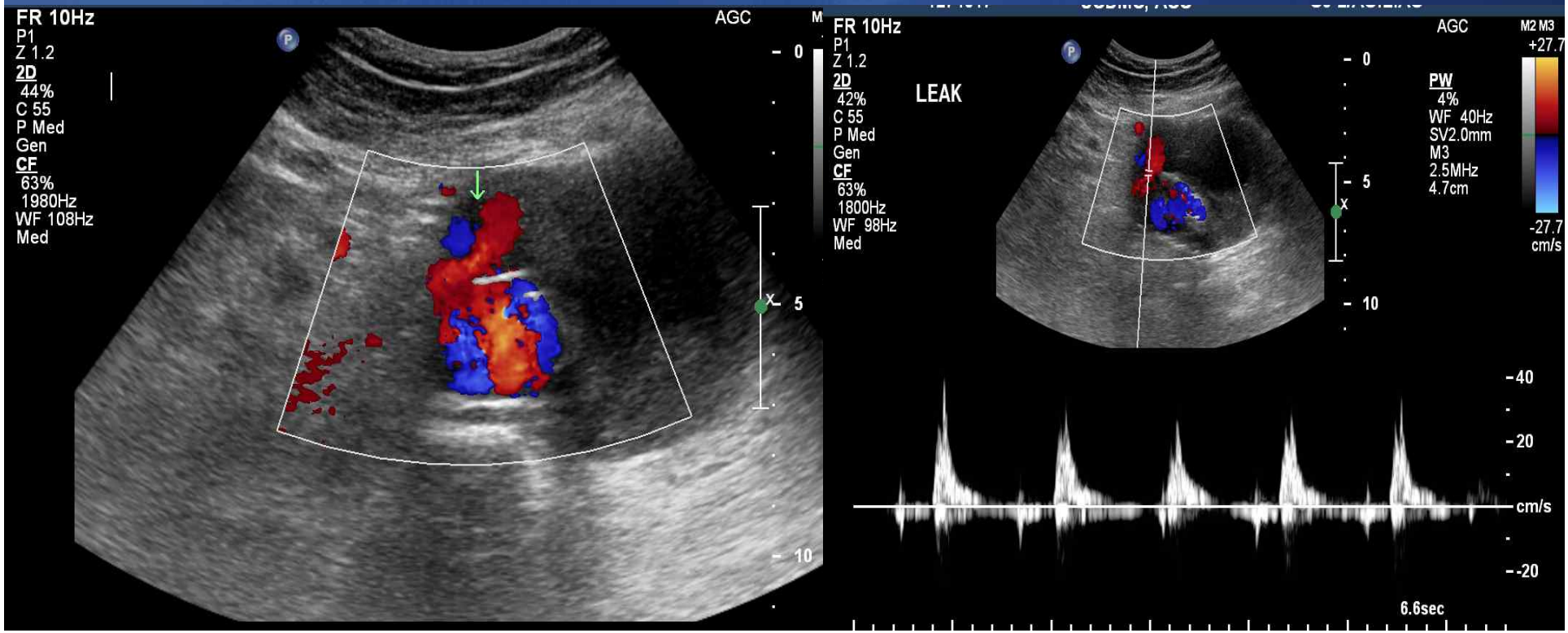

Color Duplex Ultrasound vs CT

Author	Year	n	Sensitivity %	Specificity %	PPV %	NPV %
Sato	1998	79	97	74	66	98
Zannetti	2000	103	91.7	98.4	78.6	99.4
Wolf	2000	100	81	95	94	90
D'Audiffret	2001	89	96	94	89	98
McWilliams	2002	53	12	94	33	81
Raman	2003	281	42.9	96	53.9	93.9
Manning	2009	132	86	67	45	94

UCDAVIS HEALTH SYSTEM

Manning et al; 2009 JVS; Vol49:1

Duplex ultrasound imaging alone is sufficient for midterm endovascular aneurysm repair surveillance: A cost analysis study and prospective comparison with computed tomography scan

Brian R. Beeman, MD, Lynne M. Doctor, BA, Kevin Doerr, RVT, Sandy McAfee-Bennett, RVT, Matthew J. Dougherty, MD, and Keith D. Calligaro, MD, *Philadelphia, Pa*

- CT and CDU comparable for FP and FN (n=199)
  - False Positives = 7 (P=.126):
    - CT: 2 / 199
    - CDU: 5 / 199
  - False Negatives = 16 (P=.253)
    - CT: 11 / 199
    - CDU: 5 / 199
- CDU as accurate for AAA sac size as CT
  - Pearson correlation coefficient of 0.956 (P < .001)
- $1,595 less in charges per year per patient using duplex without CTA
- No adverse outcomes in group with CDU as sole surveillance modality

Beeman et al; JVS Nov 2009 (50:5)

UCDAVIS HEALTH SYSTEM

J Vasc Surg. 2009 Nov;50(5):1012-7; discussion 1017-8.

Endoleak after endovascular aneurysm repair: duplex ultrasound imaging is better than computed tomography at determining the need for intervention.

Schmieder GC, Stout CL, Stokes GK, Parent FN, Panneton JM.

Division of Vascular Surgery, Eastern Virginia Medical School, USA.

- 944 imaging studies retrospectively reviewed
- Common gold standard (Intervention findings n=19)
  - Duplex
    - Identified leak: 89%
    - Type of leak: 74%
  - CT
    - Identified leak: 58% (*Missed 50% of Type I endoleak)
    - Type of leak: 42%

	Sensitivity %	Specificity %	NPV %	PPV %
Duplex	90	81	99	16
CTA	58	87	98	15

UCDAVIS HEALTH SYSTEM

Contrast Enhanced Ultrasound (CEUS)

Microbubbles of Perfluorocarbon gas in a phospholipid shell (Definity, Levovist, Optison)

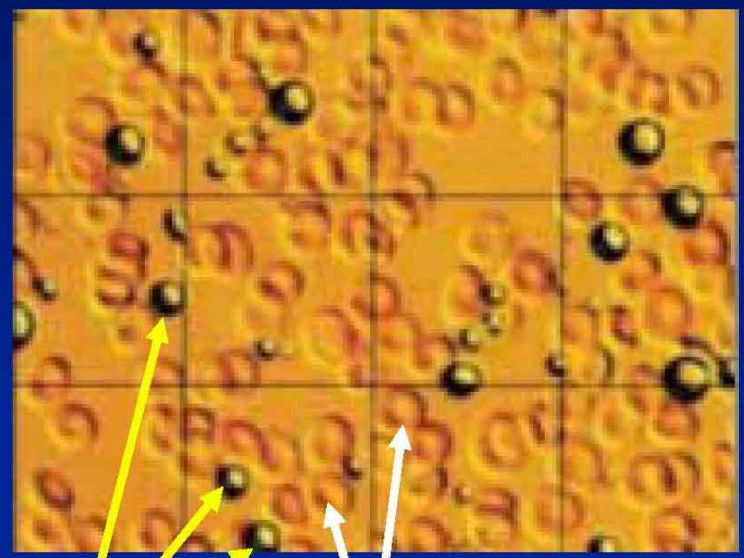

Optison Microbubbles and RBC's (Mallinckrodt Inc/GE Healthcare)

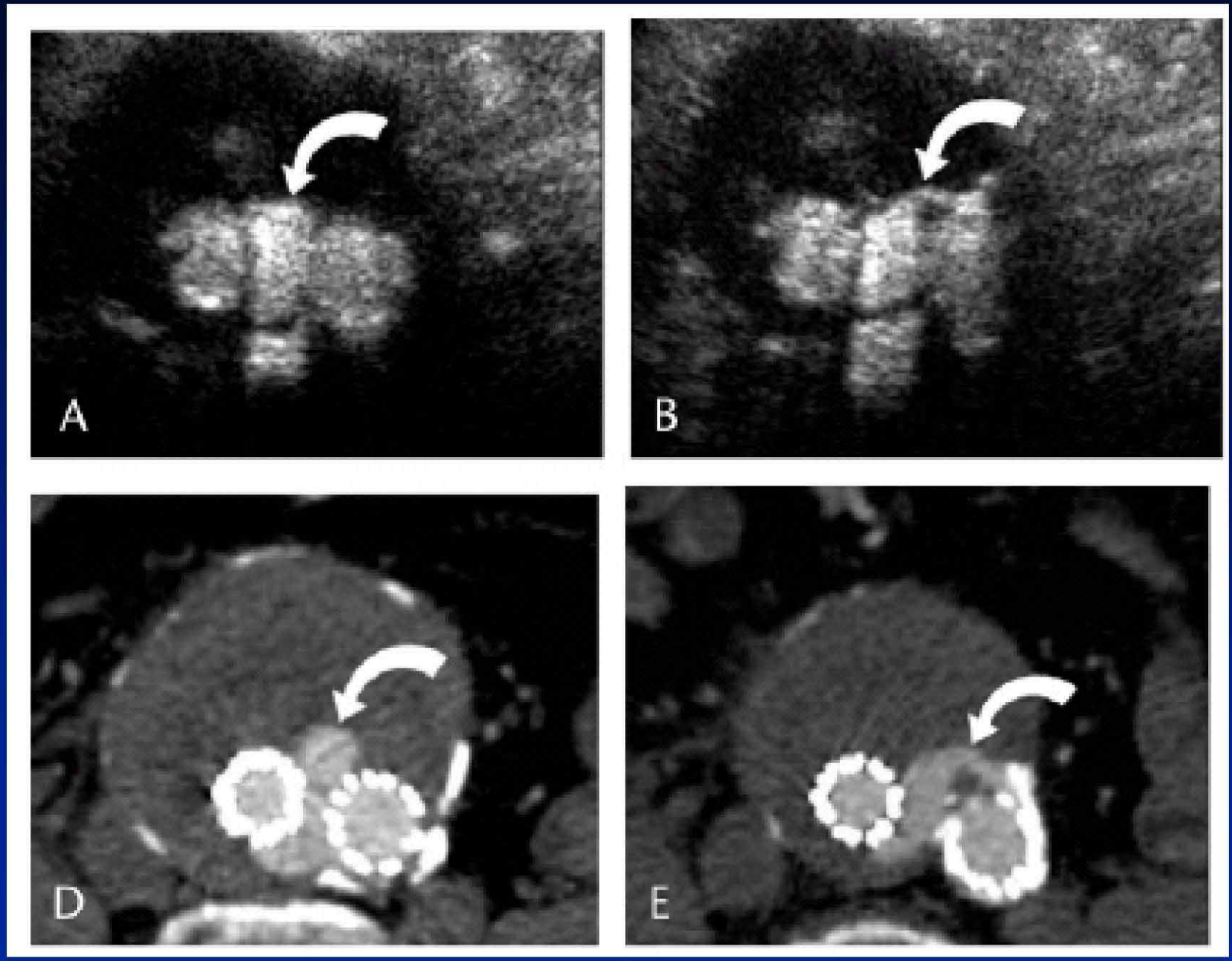

Dill-Mackey MJ. Ultrasound Quarterly 2006;22:49-52

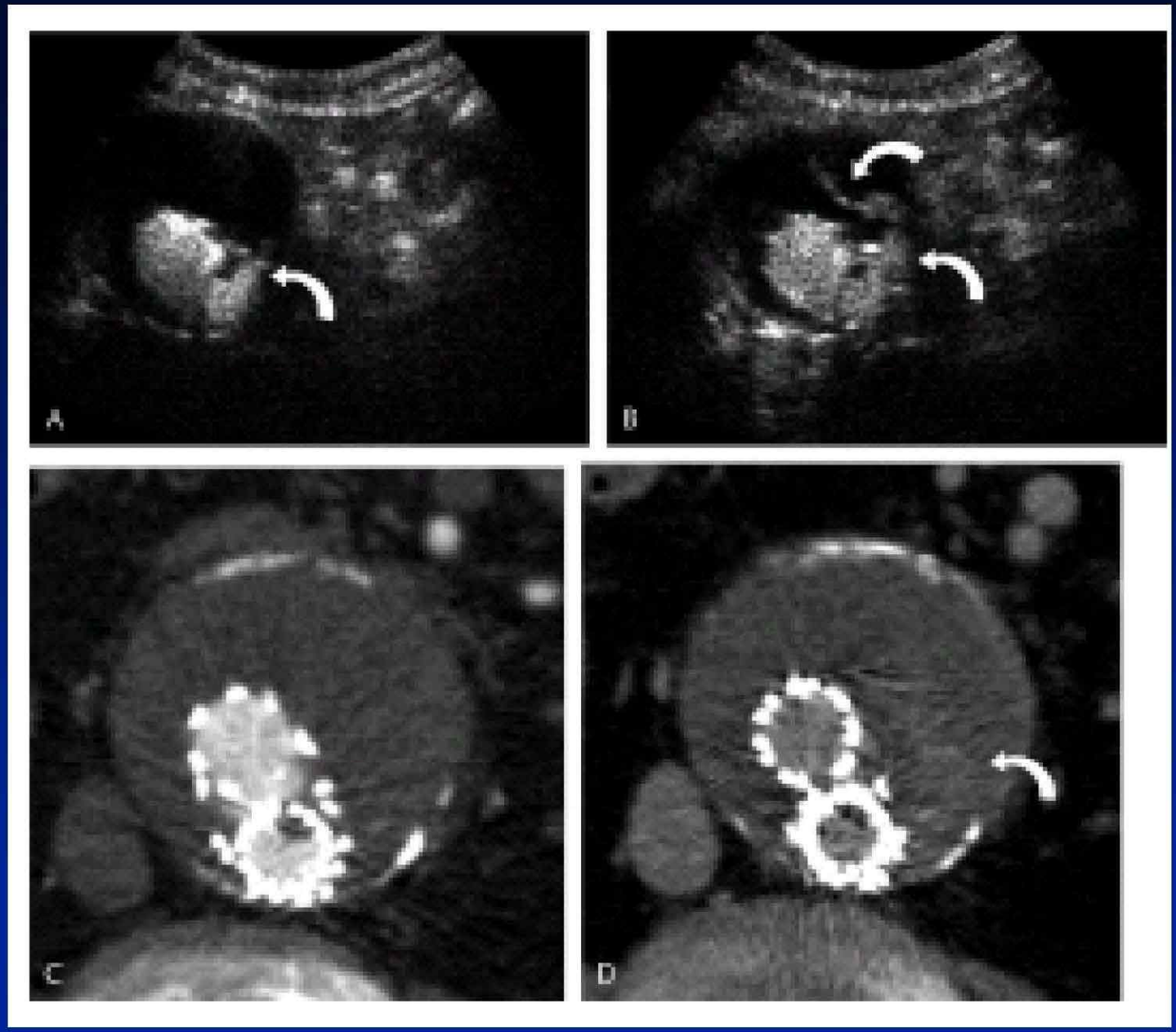

Dill-Mackey MJ. Ultrasound Quarterly 2006;22:49-52

Contrast enhanced ultrasound

- Selective use when clinically indicated
- Contraindications and precautions
- Need RN or MD for injection
- Added time and supplies for continuous infusion
- Added costs currently not reimbursed
- This is still operator dependent

The CardioMEMS EndoSensor™

Implantable Sensor

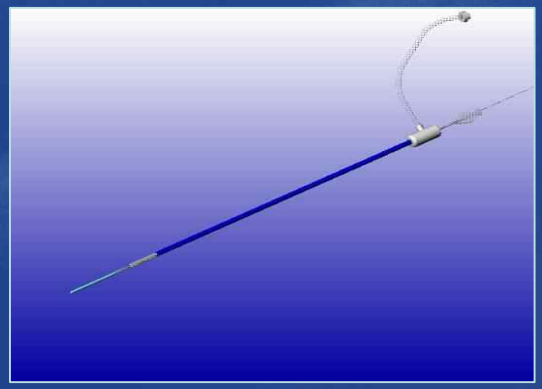

14 Fr Delivery System

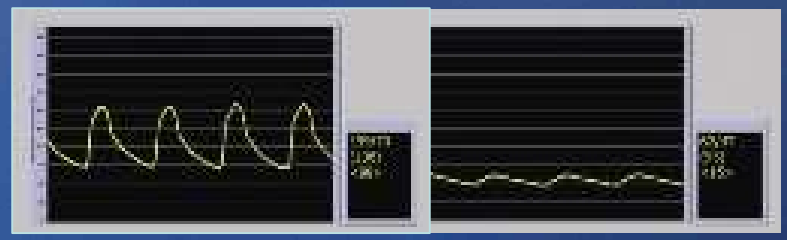

Real-time pressure waveforms Pre- and Post-exclusion

UC DAVIS HEALTH SYSTEM

UC Davis EVAR Surveillance

Intraoperative	▪ Aortogram ▪ Pressure check (if applicable)
Pre-discharge	▪ AP and lateral x-ray
Post-operative (<30 days)	▪ CTA (prior to clinic visit) ▪ Pressure check (if applicable)
6 months	▪ Duplex + ABI ▪ Pressure check (if applicable)
12 months, then annually	▪ AP and lateral x-ray ▪ Duplex + ABI ▪ Pressure check (if applicable
CTA	▪Duplex inadequate, abnormal or diameter increase

UC Davis EVAR Surveillance

Intraoperative	▪ Aortogram ▪ Pressure check (if applicable)
Pre-discharge	▪ AP and lateral x-ray
Post-operative (<30 days)	▪ DUPLEX + ABI ▪ Pressure check (if applicable)
6 months	▪ Duplex + ABI ▪ Pressure check (if applicable)
12 months, then annually	▪ AP and lateral x-ray ▪ Duplex + ABI ▪ Pressure check (if applicable
CTA	▪Duplex inadequate, abnormal or diameter increase

Summary

- EVAR surveillance is currently necessary
- The Type of Endoleak and AAA size are the most important factors influencing secondary intervention
- Color flow Duplex (Lab specific)
  - Duplex comparable to CT in identifying endoleaks
  - Widely accepted modality for AAA sizing
  - Cost effective
  - Avoids some of the downsides of CT
- CT still considered gold standard
  - Inadequate duplex, intervention planning
- Contrast Ultrasound selective basis.
- Plain film utilization for migration – routine.

UCDAVIS
HEALTH SYSTEM