Regional Photodynamic Therapy for Vulnerable Plaque Stabilization: Antrin

Alan C. Yeung, MD

Stanford University School of Medicine

Photodynamic Therapy

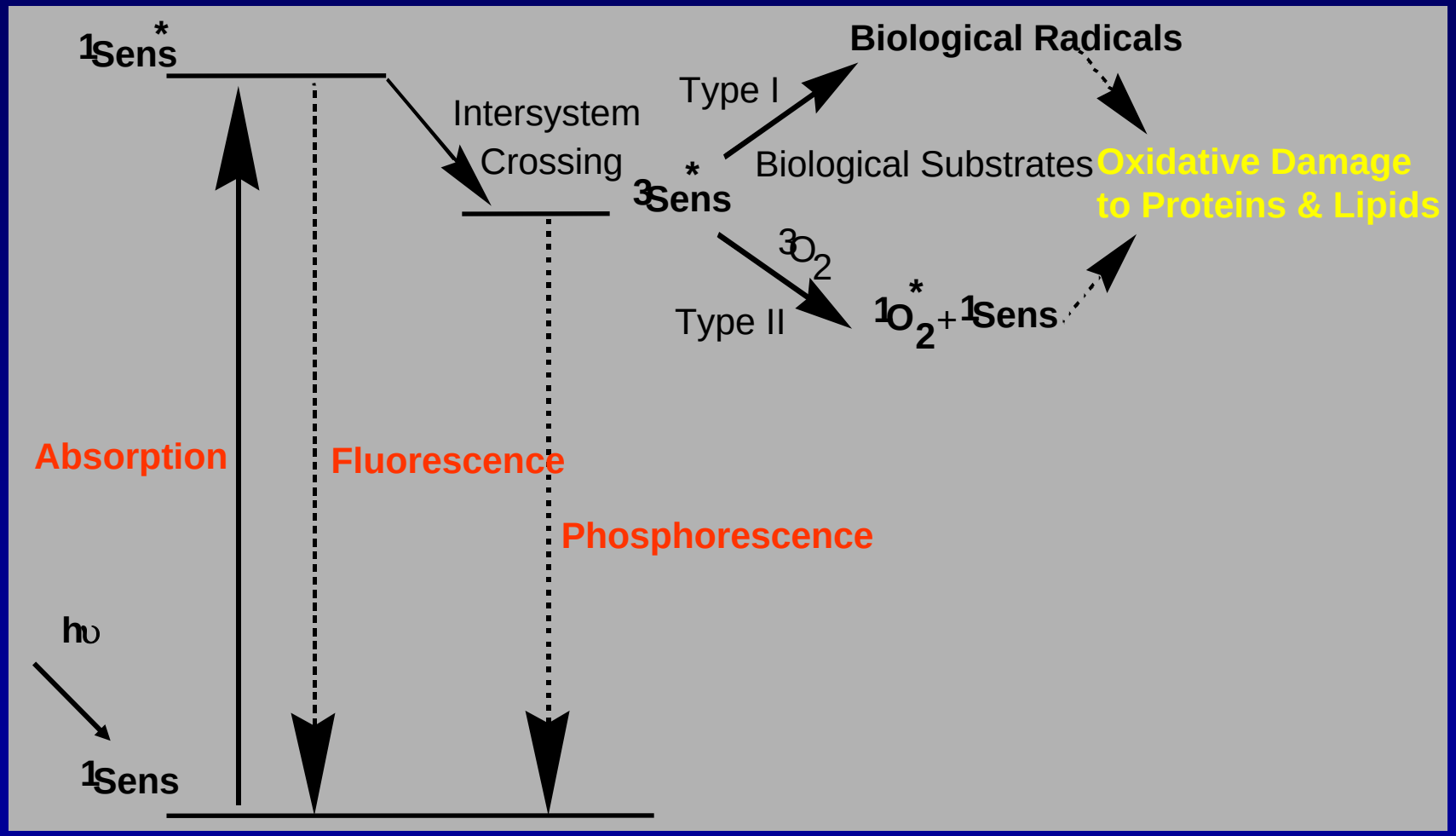

Cell death occurs only if both light and drug present

Antrin® (Motexafin Lutetium)

- Selective accumulation in atherosclerotic plaques
- Rapid clearance from plasma and normal tissues
- Light activation produces singlet O_2 (very short path length) causing cell death
- Activation at 732 nm penetrates blood and tissue better than other photosensitizers in development
- Fluorescence detected at 750 nm with 460-480 nm excitation

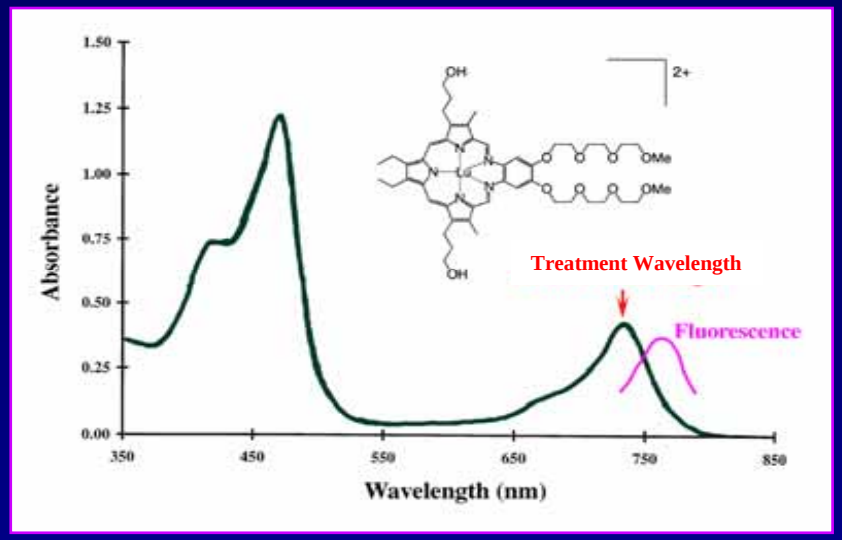

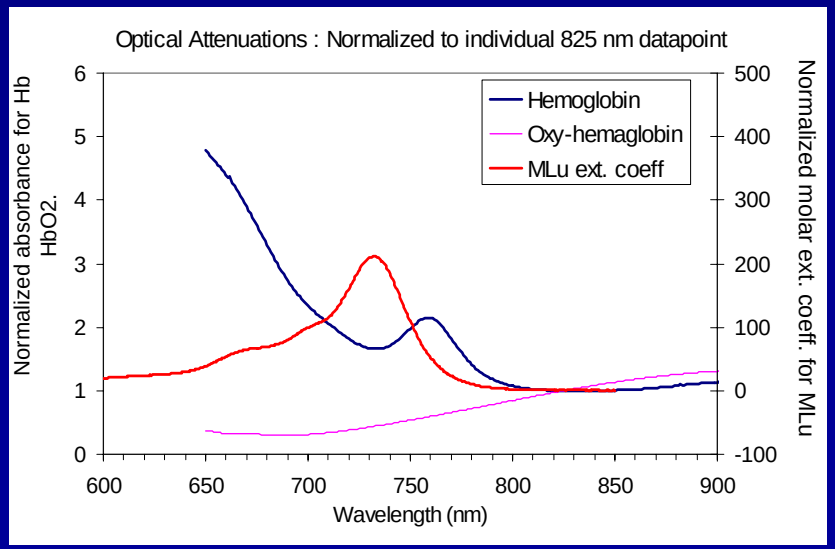

Antrin® Photodynamic Therapy

Antrin (Motexafin Lutetium)

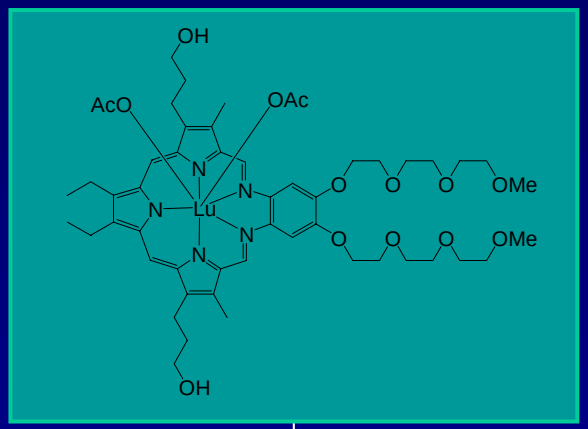

Diode Laser

Diffusing Fiber

IV or Local Delivery

Optical Selectivity

Focal or Regional (multivessel) treatment

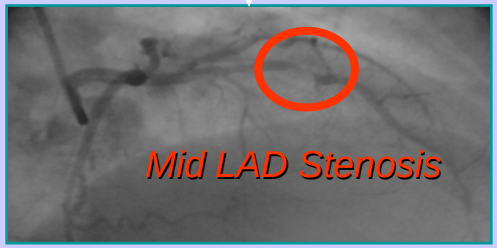



Intracellular Localization of Antrin

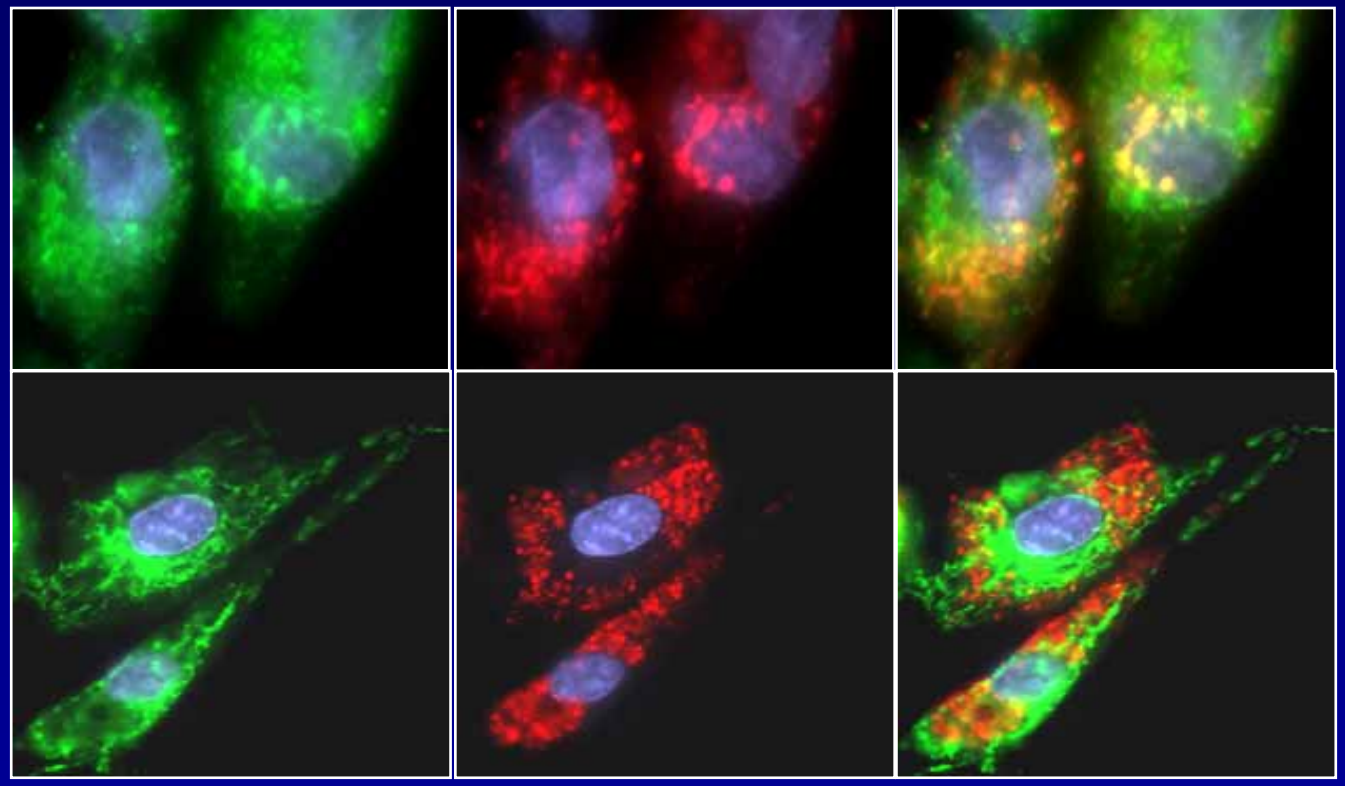

Human Macrophages

HCASMC

Mitochondria (green)

Antrin (red)

Overlay

Woodburn et al., ACC 2002

Lysosomal Instability after Phototherapy

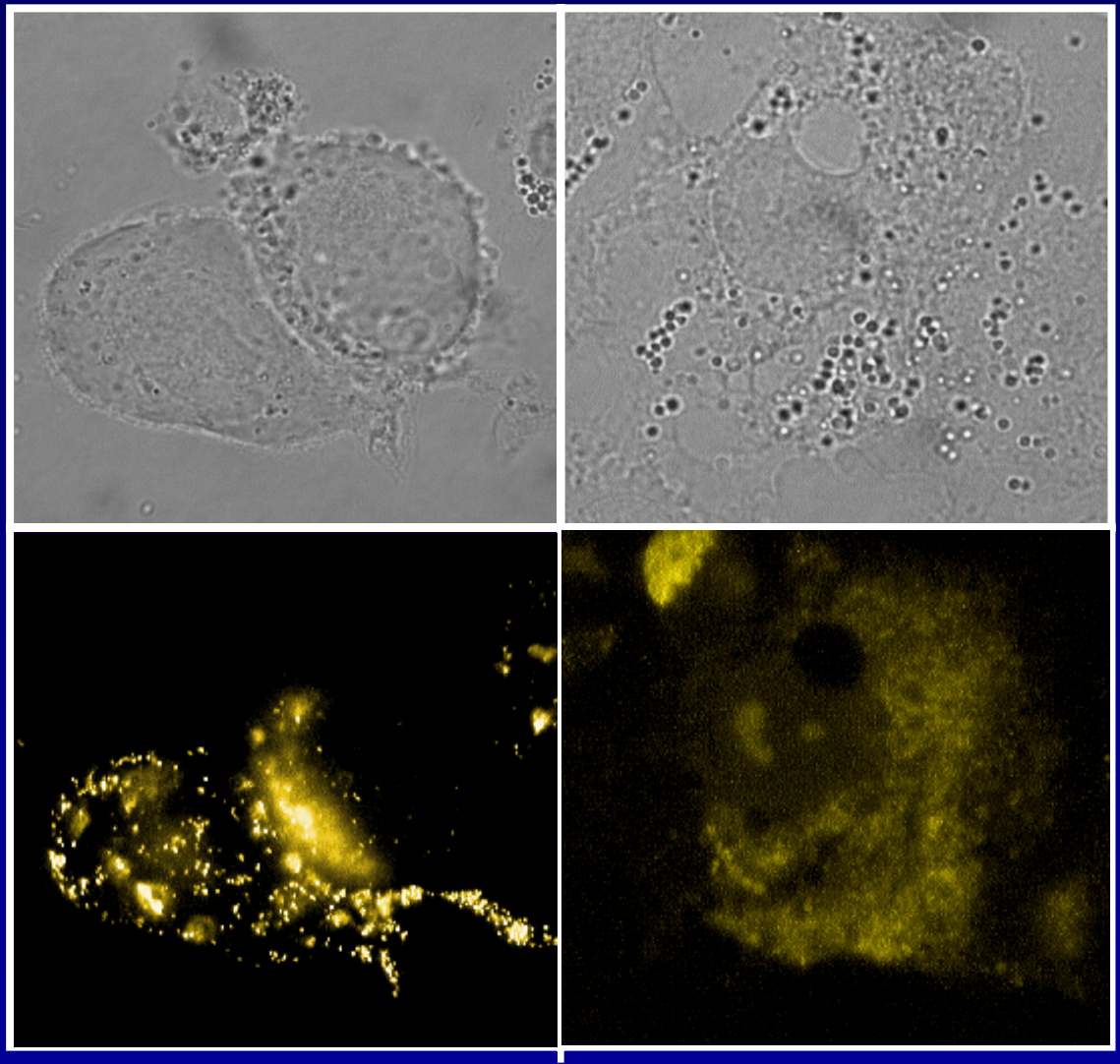

THP-1 Macrophages

THP-1 Macrophages + Acridine Orange

Pre-treatment **Post-PDT @ LD_{50}**

Woodburn et al., ACC 2002

Antrin Phototherapy Induces Apoptosis in Human Macrophages

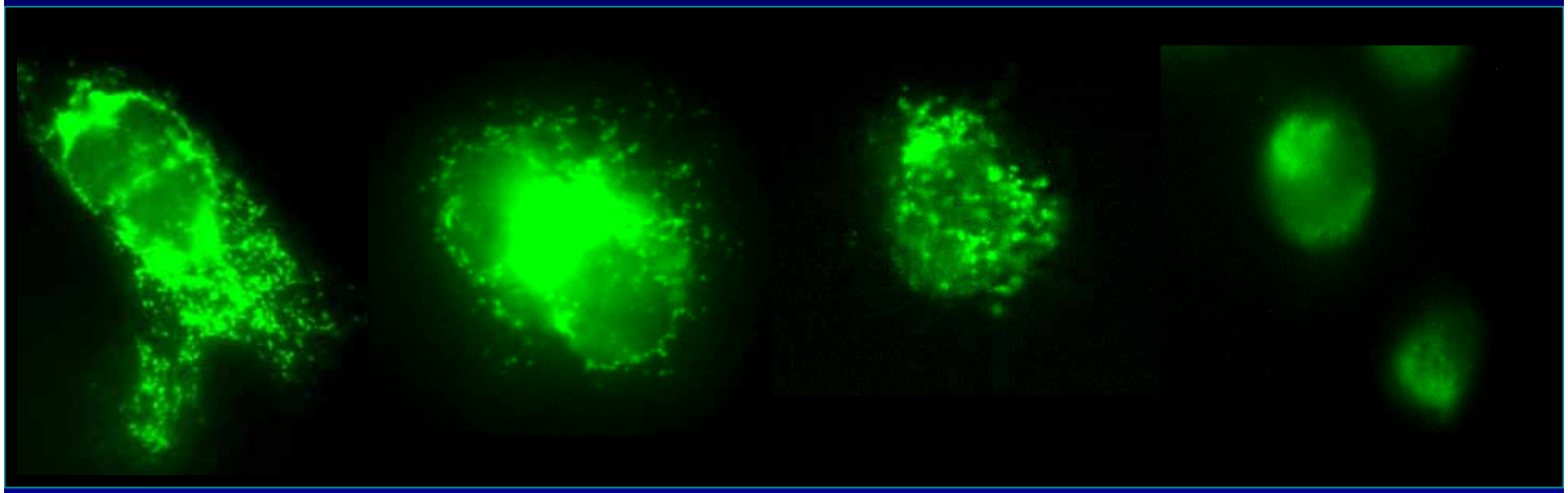

Control	20 ug/ml Antrin	2 J/cm^2 Light	Antrin + Light

Cytochrome C immunoreactivity assay in human THP-1 cells

Woodburn et al., ACC 2002

Antrin Biolocalization in Atheromatous Plaque

NZW Rabbit aorta, 10 mg/kg iv administration, analysis at 24h

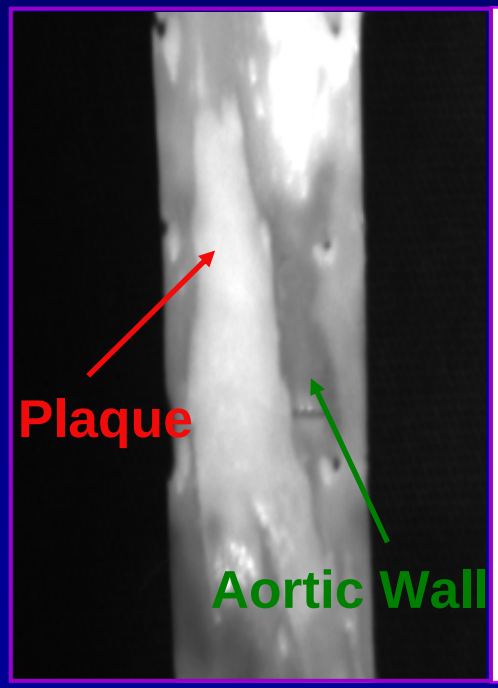

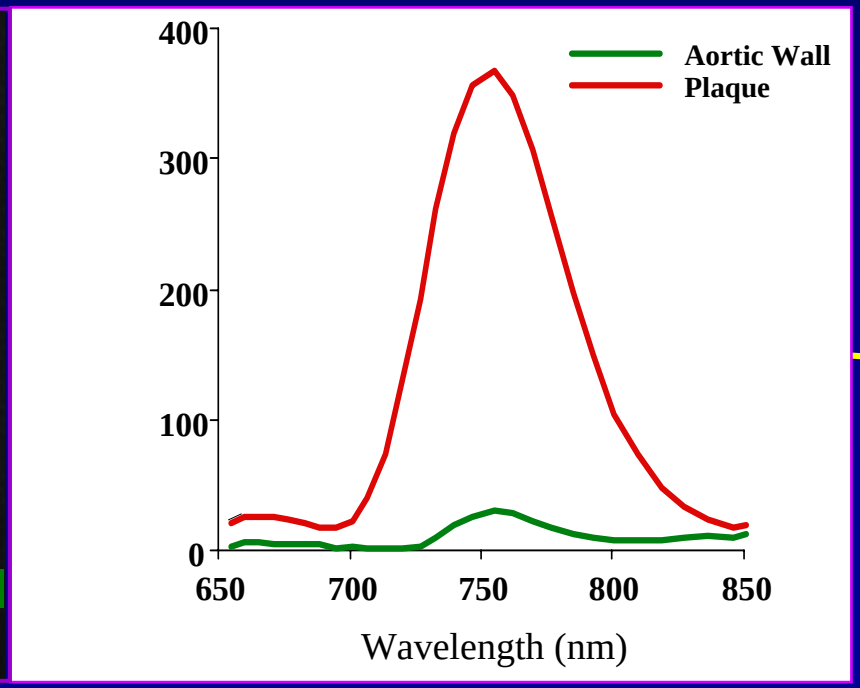

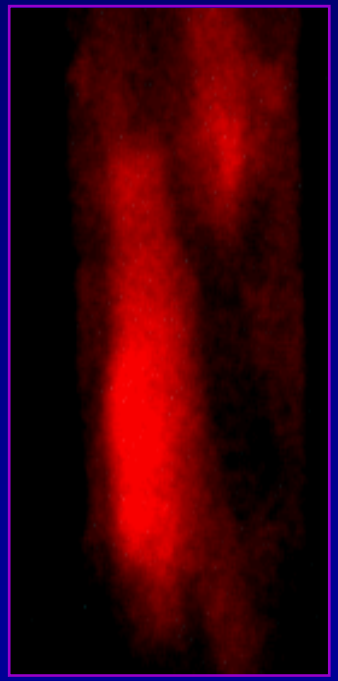

Fluorescent image

Rockson SG et al., Circulation 2000; 102:591-6

Texaphyrin Uptake in Rabbit Atheromas

B/W image **Fluorescence**

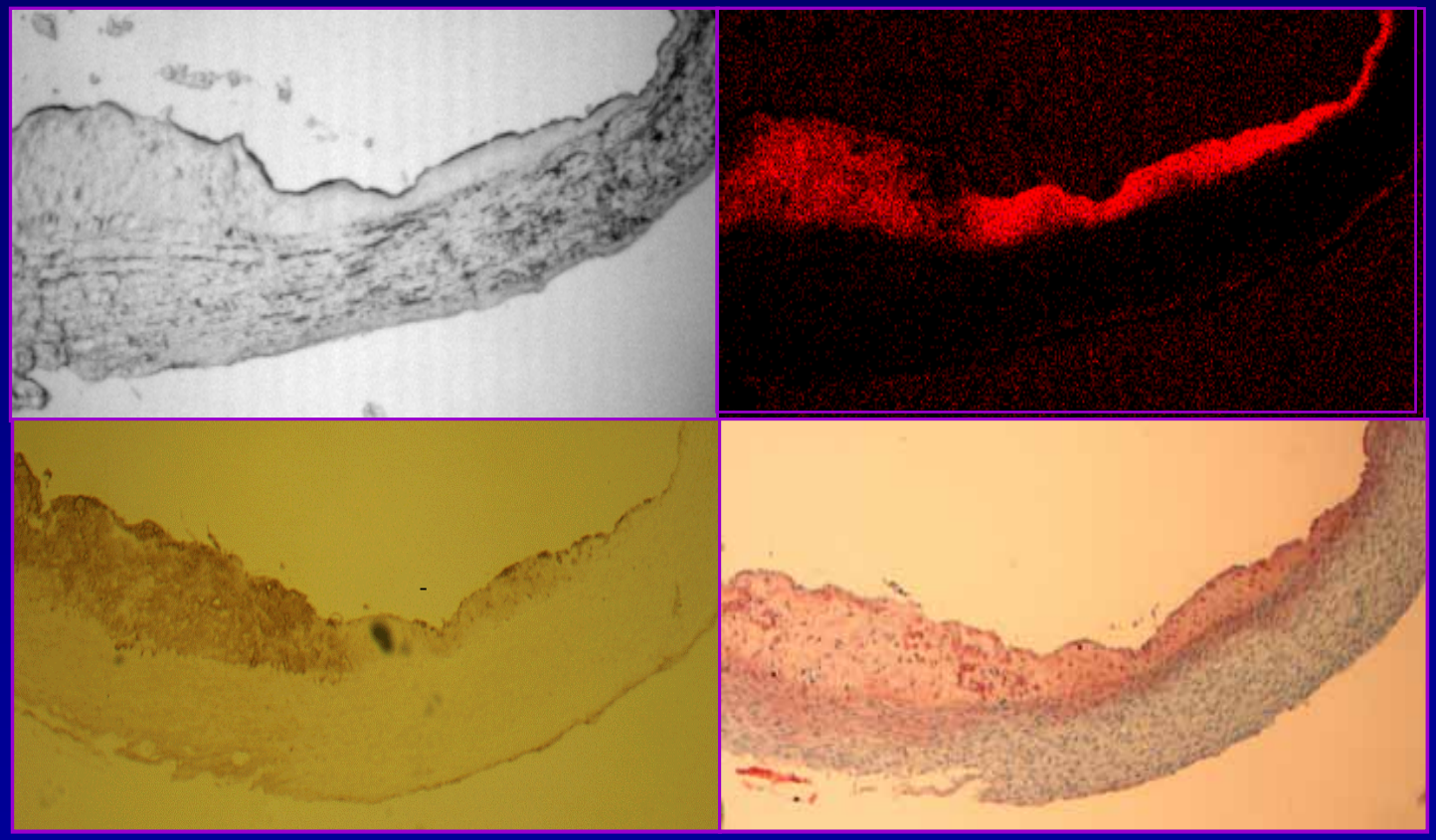

RAM-11 (macrophage) **Oil Red O (neutral lipids)**

Antrin Phototherapy (PT) depletes vascular macrophages in NZW rabbit injury model, local Antrin

Control

Treated

Hayase et al, Cardiovascular Research 2001, 49, 449-455.

Macrophage depletion in Fat-Fed New Zealand White (NZW) Rabbit; iv Antrin

Macrophage Burden as % of total intima and media

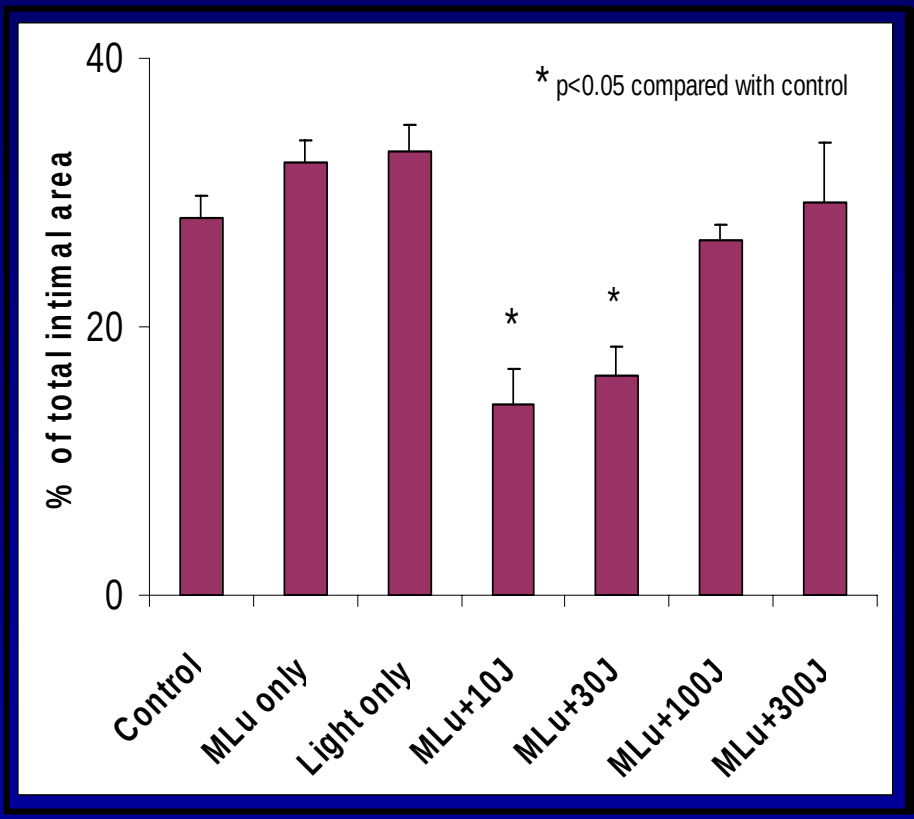

Intraballoon Illumination

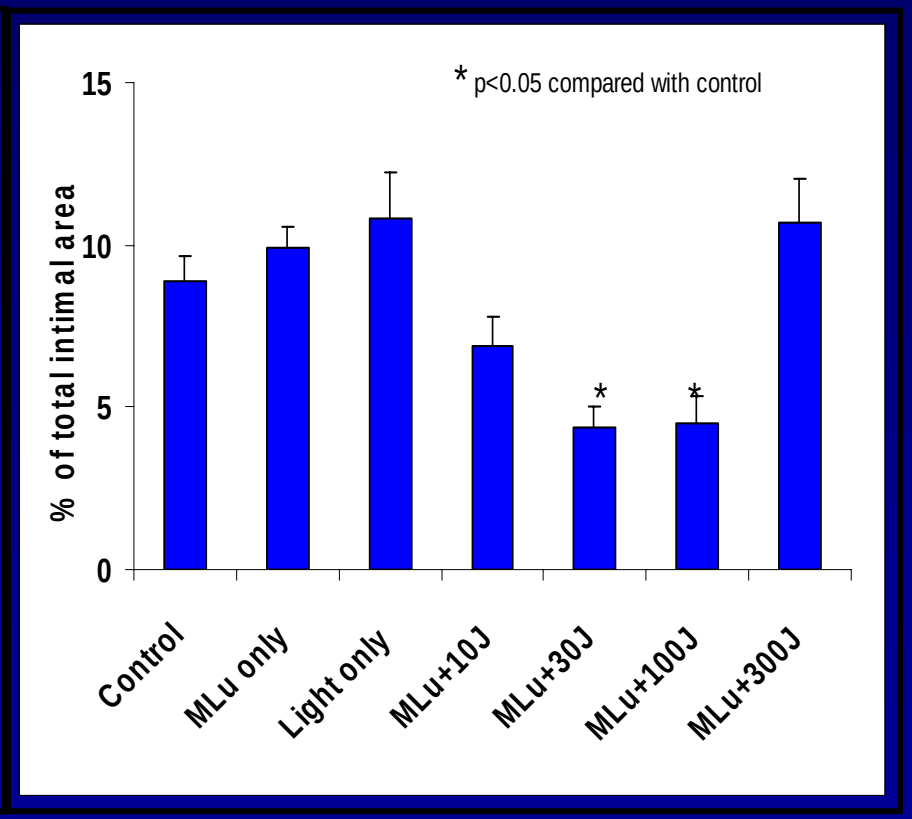

Bare Fiber Illumination

Reduces cell density post-Antrin PT

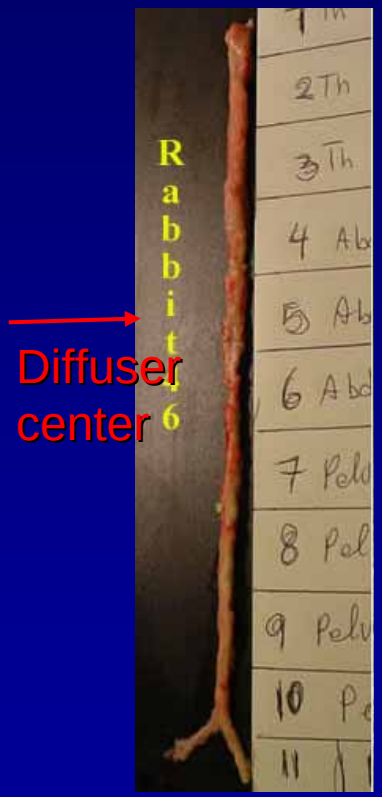

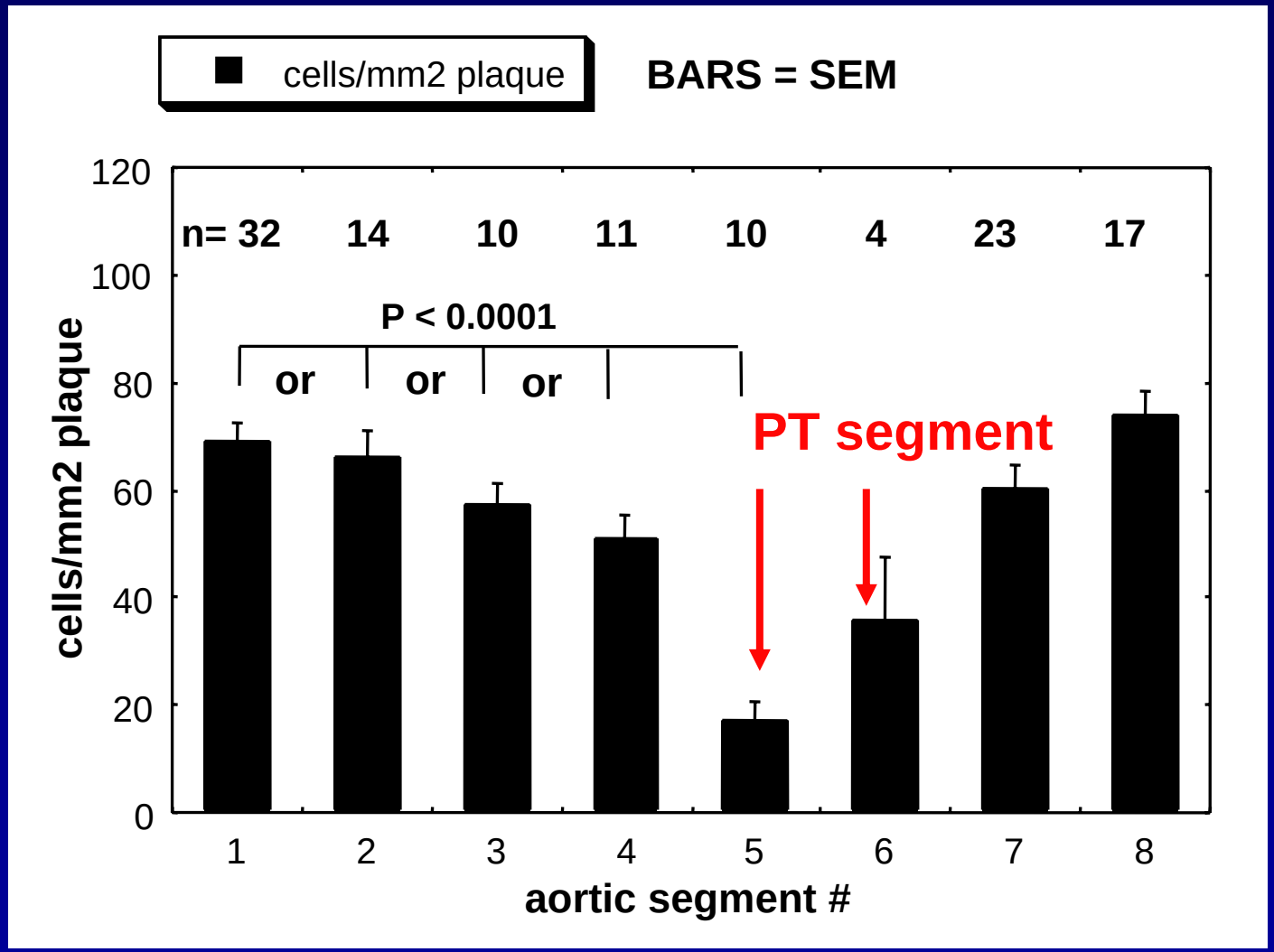

NZW injury model, 7d after PDT

Hamblin, et. al, Wellman Labs, MGH, Boston

Preclinical Findings

- Antrin localizes intracellularly in mitochondria and lysosomes
- Antrin is selective to plaques rich in macrophages and neutral lipids
- Antrin Phototherapy:
  - Reduces macrophages in all rabbit models studied
  - Produces significant plaque accellularity within days post-PT
  - Downregulates cytokines involved in monocyte migration
  - Appears to maintain or increase smooth muscle area
  - Suggests some collagen remodeling of PT lesion
  - Does not traumatize normal vessel walls.
  - Potentially remodels and stabilizes unstable plaque
- Allows both focal and regional treatment of diseased vessels.

Antrin Clinical Development

Peripheral Arterial Disease (PAD)

Phase I: Dose ranging for safety. Completed.
Rockson et. al. Circulation 2000; 102:2322

Phase II: Multi-center, double-blind, randomized trial for prevention of restenosis and treatment of de novo lesion.
Study Completed. No adverse safety signals.

Coronary Arterial Disease (CAD)

Phase I: Drug and light dose escalation in subjects with CAD undergoing PCI with stent placement. Completed. Kereiakes, et. al. Circulation 2003; 103:1310

Antrin Phototherapy

Phase 1 Coronary Artery Disease Angiographic Results

- Enrollment: 79 patients
- Design: Drug and light dose escalation for safety
- Safety: No serious adverse effects
- Results: Optimum regimen identified
- Publication: **Kereiakes, et. al. Circulation 2003; 103:1310**

"The present phase 1 coronary study supports the apparent safety and tolerability of this treatment and materially extends our understanding of this emerging therapy in several ways.

Phase I CAD Participating Investigators & Centers

Dean Kereiakes
The Lindner Center, Cincinnati

Daniel Simon
Brigham and Women's Hospital, Boston

Arthur M. Szyniszewski
Michigan Heart & Vascular, Ann Arbor

Alan Yeung
Stanford Medical Center, Palo Alto

Paul Kramer
Mid-America Heart Institute, Kansas City

Howard Herrmann
Hospital of the University of Pennsylvania

Wendy Shear
Minneapolis VA Medical Center

Jeffry Popma
QCA Core Lab, Boston, MA

Peter Fitzgerald
IVUS Core Lab, Stanford, CA

CAD Phase I Design

Dose-escalation safety trial in subjects with CAD under-going PCI with stent placement

Eligibility: Patients With Coronary Arterial Disease

Design: IV ANTRIN Followed 18-24 Hours Later by Phototherapy.
Drug escalation (0.05 – 4 mg/kg)
Light escalation (100-600 J/cm^{f})

Safety Objectives:

* Extent of restenosis in Antrin PT-treated lesions (QCA, IVUS)
* Pharmacokinetics in this CAD pop.

Primary Outcome Variables

* Dose-limiting toxicities associated with Antrin Injection and/or illumination
* Phototherapy-related procedural adverse events
* Death, Stroke, CK or CK-MB > 3 x ULN

CAD Phase I Design

Secondary Outcome Variables

* Late lumen loss/index (QCA; IVUS) at 6 months
* Angiographic restenosis rate (> 50%)
* TLR, TVR, TVF
* Pharmacokinetics

Inclusion Criteria:

* Target lesion stenosis >50% needing PCI
* Target lesion for PCI ≤ 30 mm long
* Men or women ≥ 18 yrs old
* Give informed consent

Exclusion Criteria:

* Target lesions with previously placed stent
* Target lesions involving left main or ostial left anterior descending arteries

Angiographic Analysis Plan

BWH Angiography Core Lab – J. Popma

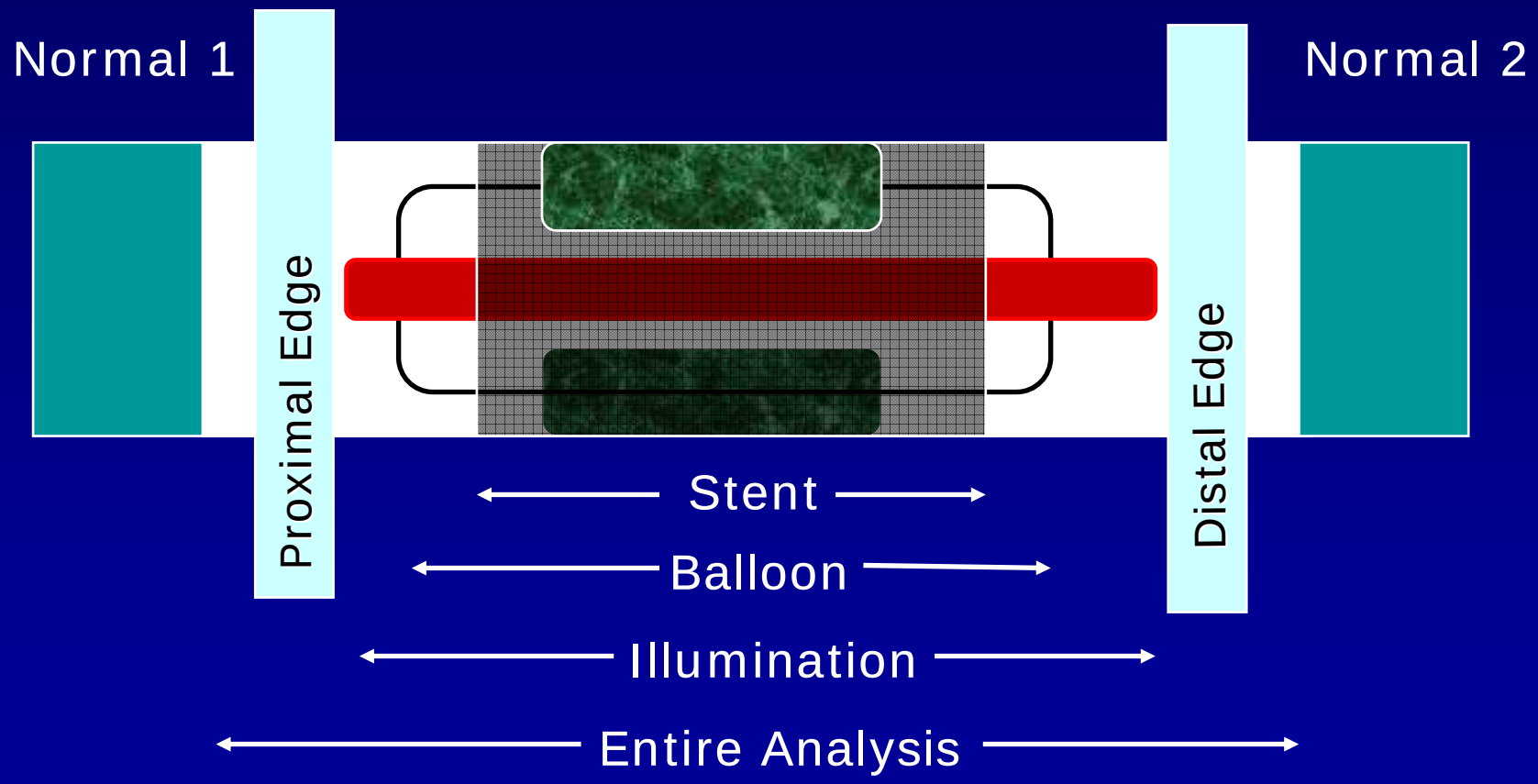

CAD Phase I Study Demographics (n=79)

Median Age, yrs	64.0 (43-85)
Men, %	70.9%
Diabetes, %	20.3%
Prior PCI, %	16.5%
Prior MI, %	51.9%
NYHA Class I, %	31.6%
NYHA Class II, %	68.4%

CAD Phase I Study
Target Vessel Characteristics

Target Vessel, %	
➢ LAD	40 %
➢ LCX	28 %
➢ RCA	32 %
Stent Diameter (mm; mean)	3.33
Stent Length (mm; mean)	19.1

CAD Phase I Study
Procedure and Device Performance

Device Success*	100%
Procedural Success**	96.2%
• Interrupted Illumination	0%
• Fiber could not be delivered	0%
• Bailout procedure [left main disease; angioplasty dissection]	3.8% (n=3)
GP IIb/IIIa Use	51%

**Successful delivery of the illuminating fiber when attempted*

***No in-hospital MACE*

CAD Phase I Study
Preliminary Acute Safety (30 days)

Emergent CABG	0 %
Death	0 %
Stroke	0 %
Total CK Elevation (>3xULN)	1.3 %
Total CK-MB Elevation (>3xULN)	10.3 %
Target vessel revascularization	1.3 %
Stent Thrombosis	0 %

Antrin CAD Phase I Study Infusion Related Events

Dose (mg/kg)	N	Peripheral Paresthesia*	Rash*
0.05	5	1 (20.0%)	0 (0)
0.15	5	0 (0%)	0 (0)
0.5	6	0 (0%)	0 (0)
1	6	1 (16.7%)	1 (16.7)
2	21	10 (47.6%)	3 (14.3)
3	26	14 (53.8%)	5 (19.2)
4	10	6 (60.0%)	3 (30.0)

* Rashes were not phototoxic reactions. Duration of paresthesias and rashes ranged from 0-46 days, and 0-51 days, respectively. All were mild to moderate in severity

Antrin (MLu) Pop Pharmacokinetics Rapid Clearance from Plasma

Across all drug doses: 0.05-4 mg/kg

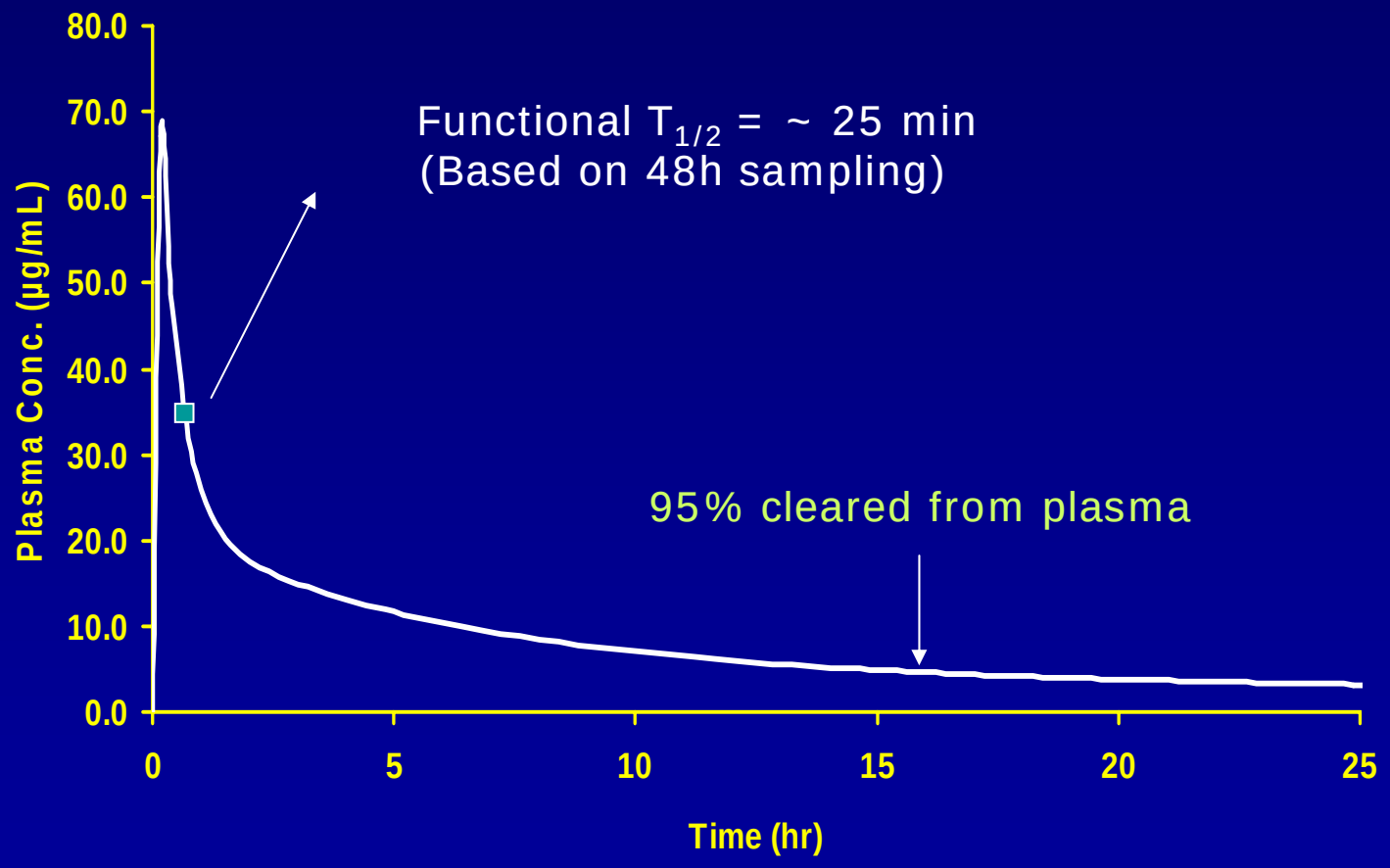

Follow-Up Angiography
Quantitative Results

There were no clinically significant differences between the stent, balloon injury, illumination and analysis segments

	Overall % (95% CI)
Stent Segment (Binary Restenosis)	24/71, 33.8 % (23.0, 46.0)
Stent Segment MLD (mm)	1.75
Stent Segment Late lumen loss (mm)	1.02
Edge segments	2/70 (2.9 %) (0.3, 9.9)
Pre-PCI % stenosis (median)	66.0 %
Post-PCI % stenosis (median)	6.8 %
Pre / Post- ref. vessel diameter (mean)	2.93 / 2.94 mm

Mean (SE) late lumen loss by quantitative coronary angiography stratified by study stage, MLu dose, and light fluence.

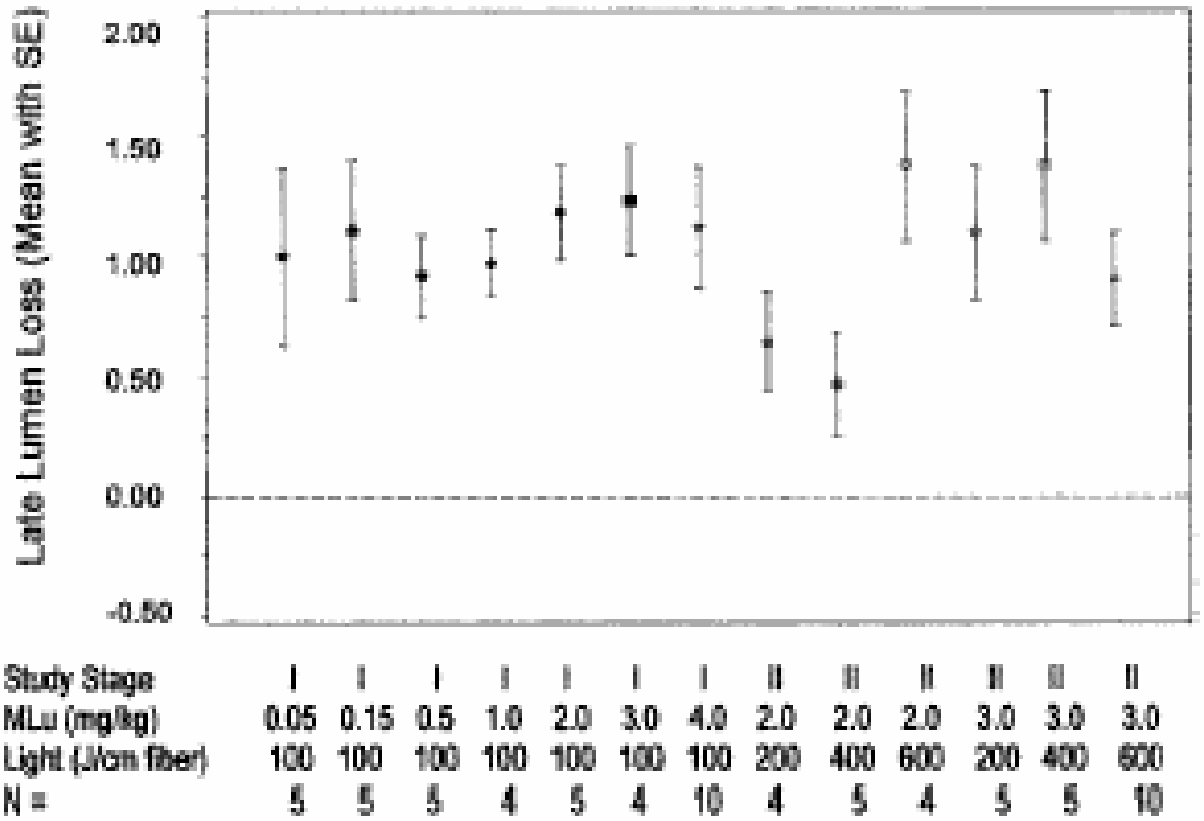

Qualitative Assessment by IVUS (N=39)

- Incomplete apposition

Preserved incomplete apposition:	2
Resolved incomplete apposition:	1
Late incomplete apposition:	0

- Stent edge dissection

Baseline	6-month follow-up
4	0

- Intraluminal thrombus

Baseline	6-month follow-up
0	0

Hongo, et. al., manuscript under preparation

Quantitative Assessment by IVUS (N=39)

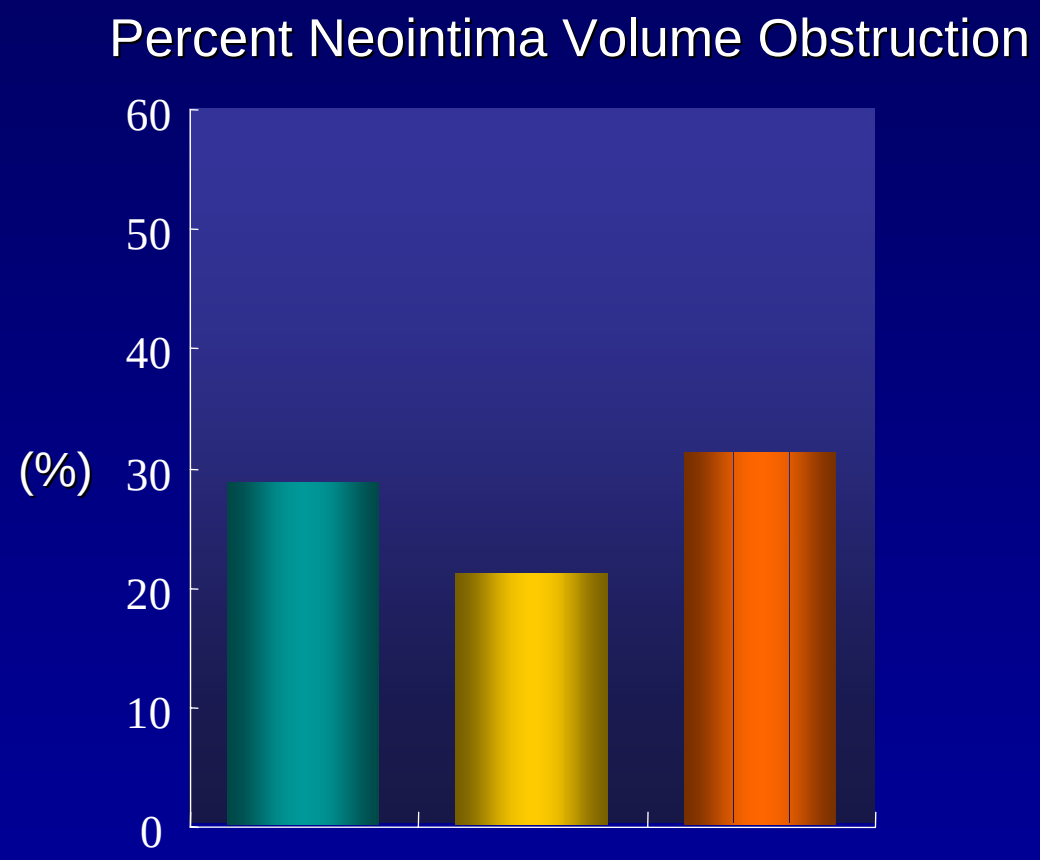

Light (J/cm-fiber)	100	100	200-600
MLu (mg/kg)	0.05-1.0	2.0-4.0	2.0-3.0
N	(9)	(7)	(23)

Hongo, et. al., manuscript under preparation

Quantitative Assessment by IVUS (N=39)

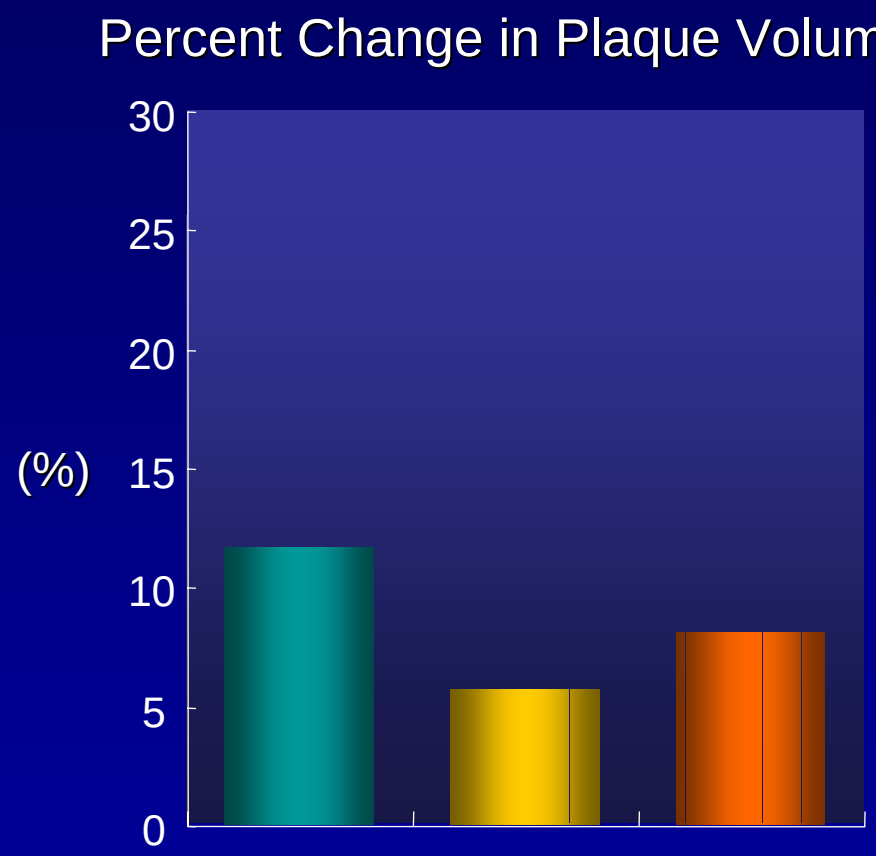

Light (J/cm-fiber)	100	100	200-600
MLu (mg/kg)	0.05-1.0	2.0-4.0	2.0-3.0
N	(9)	(7)	(23)

Hongo, et. al., manuscript under preparation

Safety Summary - CAD

- ANTRIN Phototherapy is feasible, well-tolerated and safe in >250 trial patients to date.
  - **No drug/light dose-limiting toxicities**
  - **Self-limited paresthesias with > 2.0 mg/kg**
  - **Successful and safe intravascular light delivery**
- Absence of late incomplete stent apposition with PT
- Very low incidence of geographical miss
- No evidence of deleterious edge effects
- No reported treatment-related aneurysms
- No observed subacute stent thrombosis or proliferative fibrosis within the reference segment

Vulnerable Plaque

Native CAD vs SVG ?