CENTRO
CUORE
COLUMBUS

ANGIOPLASY SUMMIT 2007
TCT ASIA PACIFIC

Seoul, Korea: 25-27 April 2007

Session: Left mains & bifurcation intervention

An integrated approach to bifurcation lesions: lessons from years of randomized trials, registries, debates and "mature thinking"

15 min

Antonio Colombo

Centro Cuore Columbus Milan, Italy
S. Raffaele Hospital Milan, Italy

CENTRO
CUORE
COLUMBUS

BMS and DES: side branch issue overemphasized

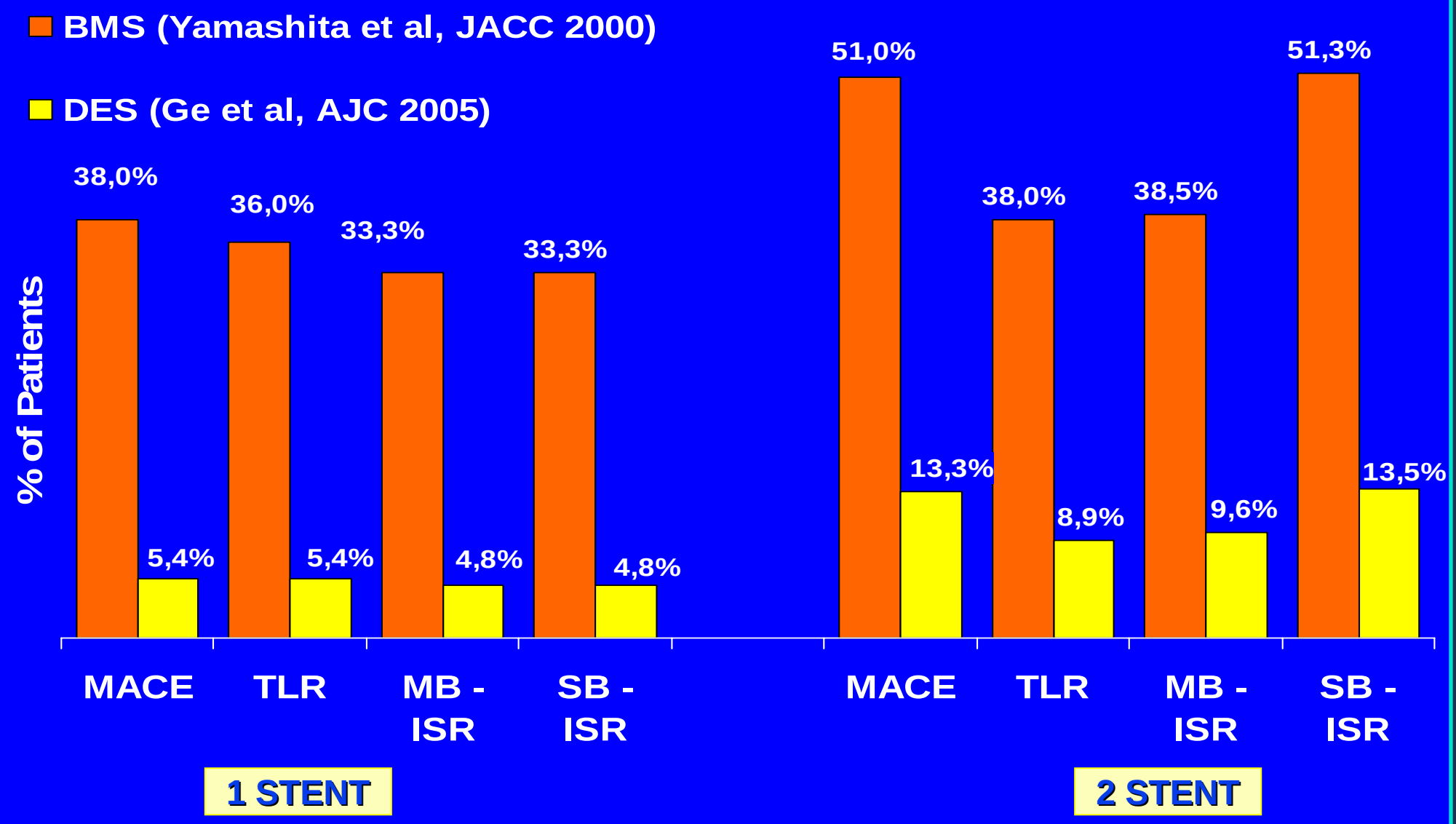

CENTRO
CUORE
COLUMBUS

Studies with DES

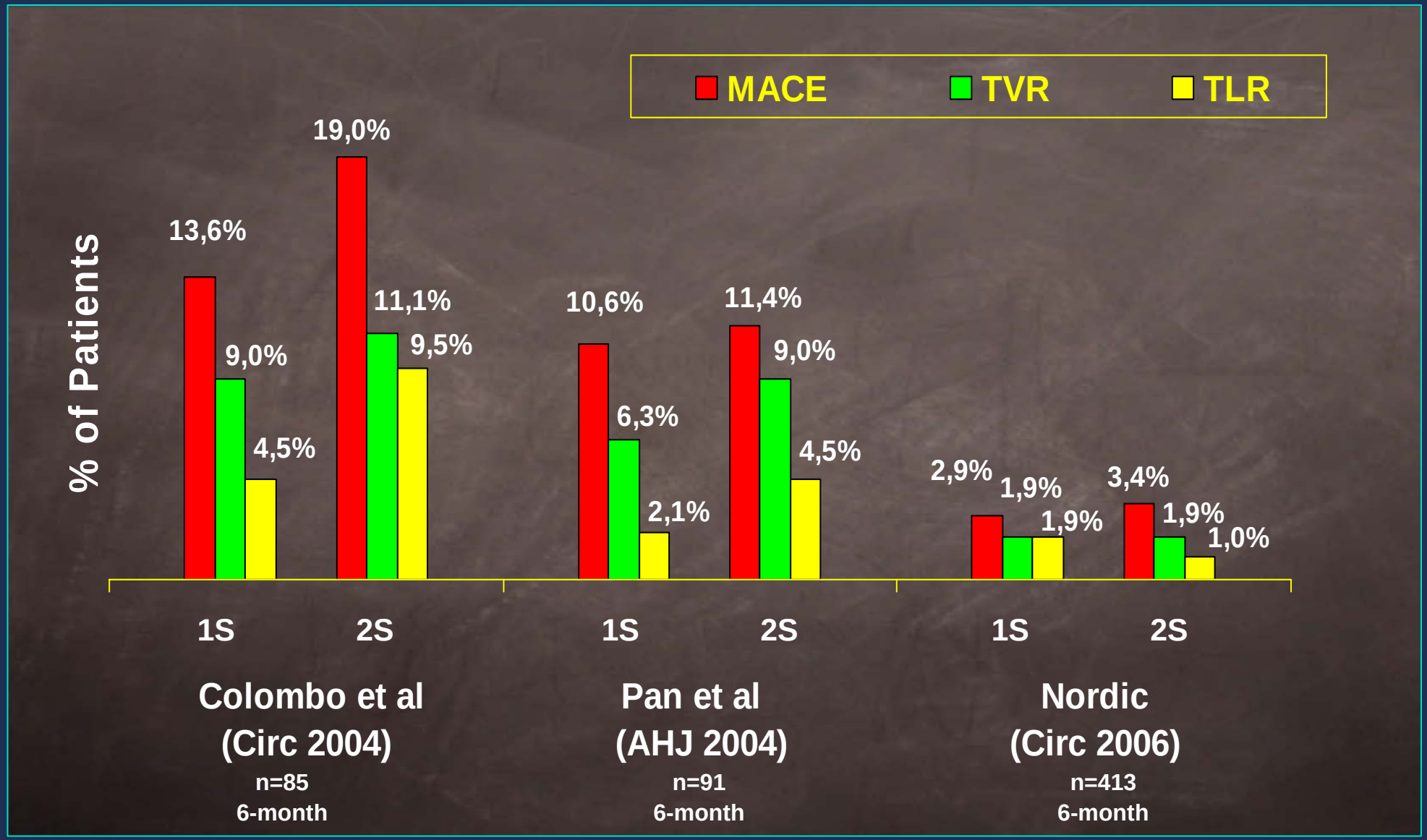

CENTRO
CUORE
COLUMBUS

Angiographic Restenosis

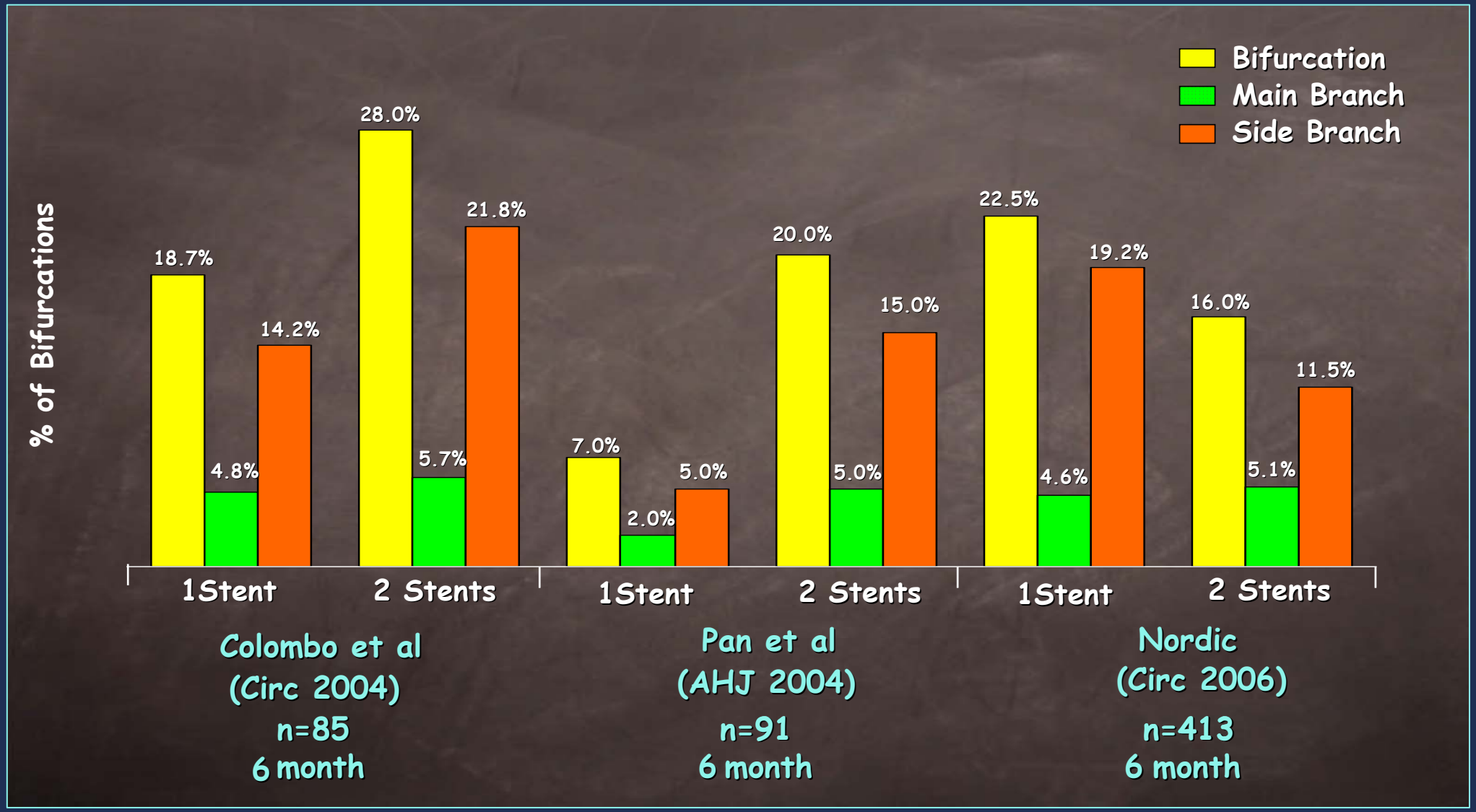

CENTRO
CUORE
COLUMBUS

Thrombosis in bifurcations

CENTRO
CUORE
COLUMBUS

Thrombosis rates

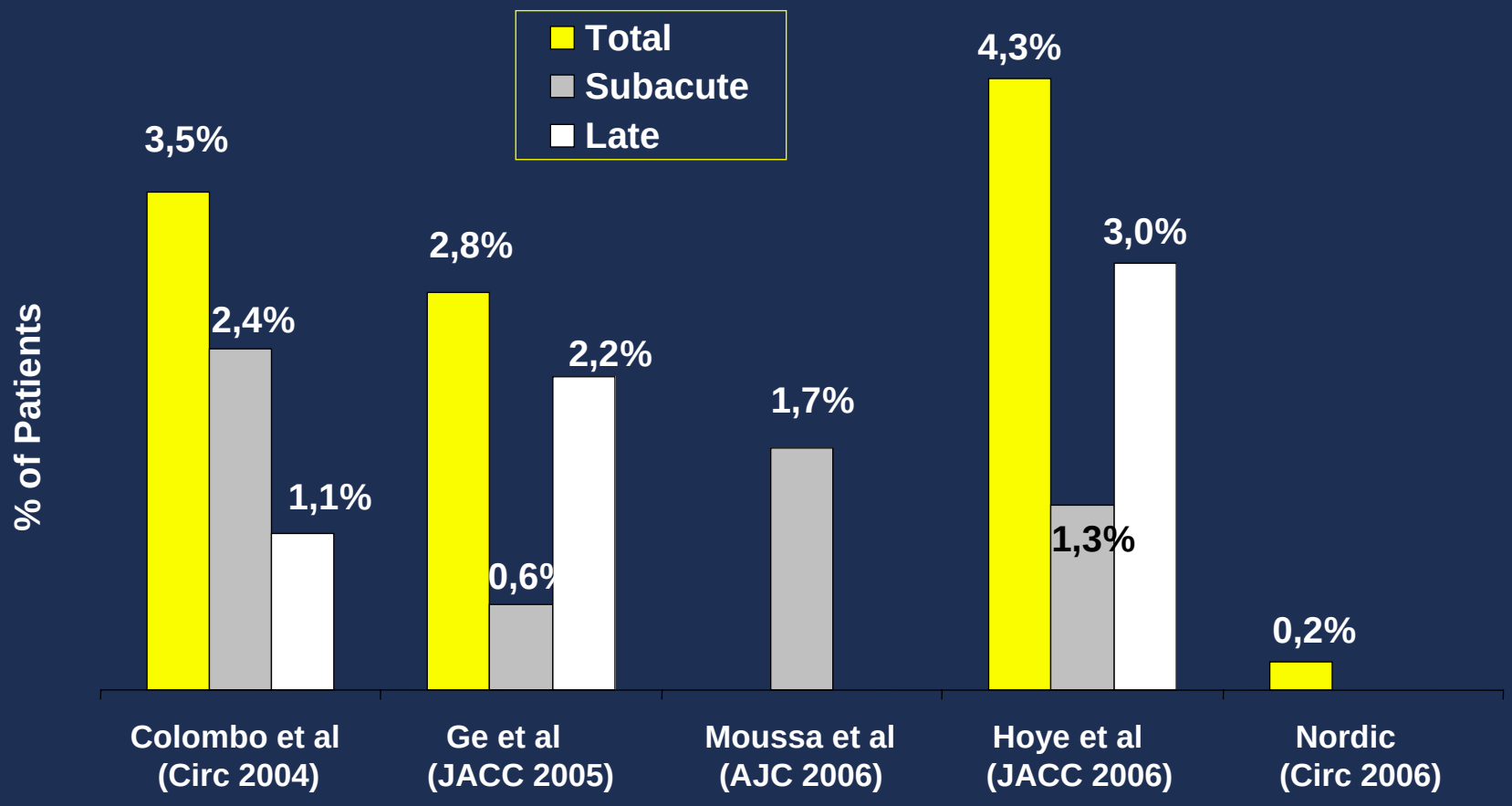

CENTRO
CUORE
COLUMBUS

NORDIC Bifurcation Study

Individual End Points after 6 months

	1 Stent	2 Stents	*P*
Patients	207	206	
Cardiac death	2 (1.0)	2 (1.0)	1.00
Myocardial infarction	0 (0.0)	1 (0.5)	0.31
Stent thrombosis	1 (0.5)	0 (0.0)	0.31

Steigen et al Circulation 2006

CENTRO
CUORE
COLUMBUS

NORDIC Bifurcation Study

2 Stents Techniques Implemented

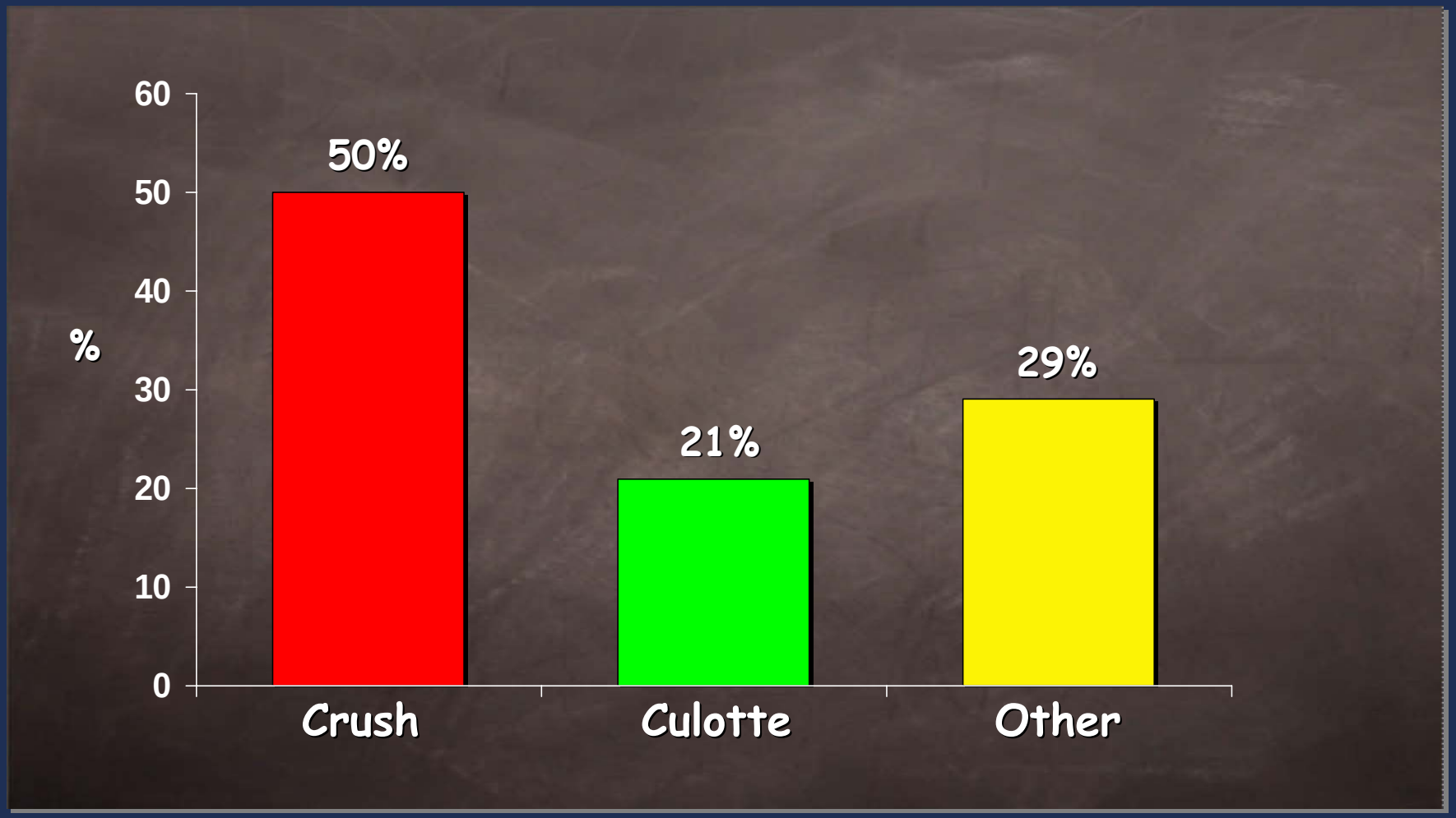

Steigen et al Circulation 2006

CENTRO CUORE COLUMBUS

Predictors of stent thrombosis

Analysis of 2229 pts with 9 m FU Iakovou JAMA 2005



CENTRO
CUORE
COLUMBUS

Bifurcations

1. Provisional
2. Two Stents
3. Keep It Open (KIO)

CENTRO
CUORE
COLUMBUS

Bifurcations

Provisional

When the SB has minimal disease or only at the ostium AND when the SB is suitable for stenting

6 Fr guiding catheter

1. Wire both branches
2. Dilate MB and SB if needed
3. Stent MB leaving a wire in the SB
4. Re-wire SB and then remove jailed wire
5. Kissing balloon inflation
6. Stent SB only if suboptimal result (TAP or reverse crush)

CENTRO
CUORE
COLUMBUS

SB protection

Lesion on LAD-Diag

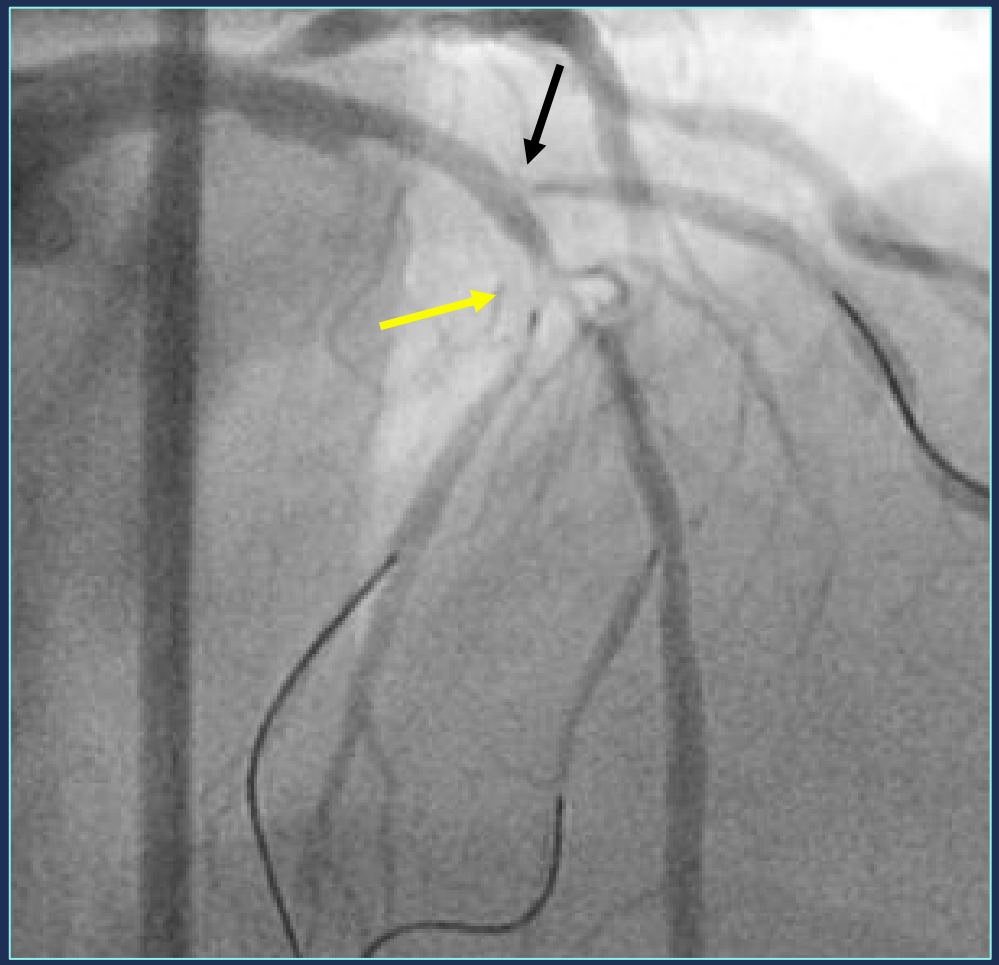

Baseline Angiography

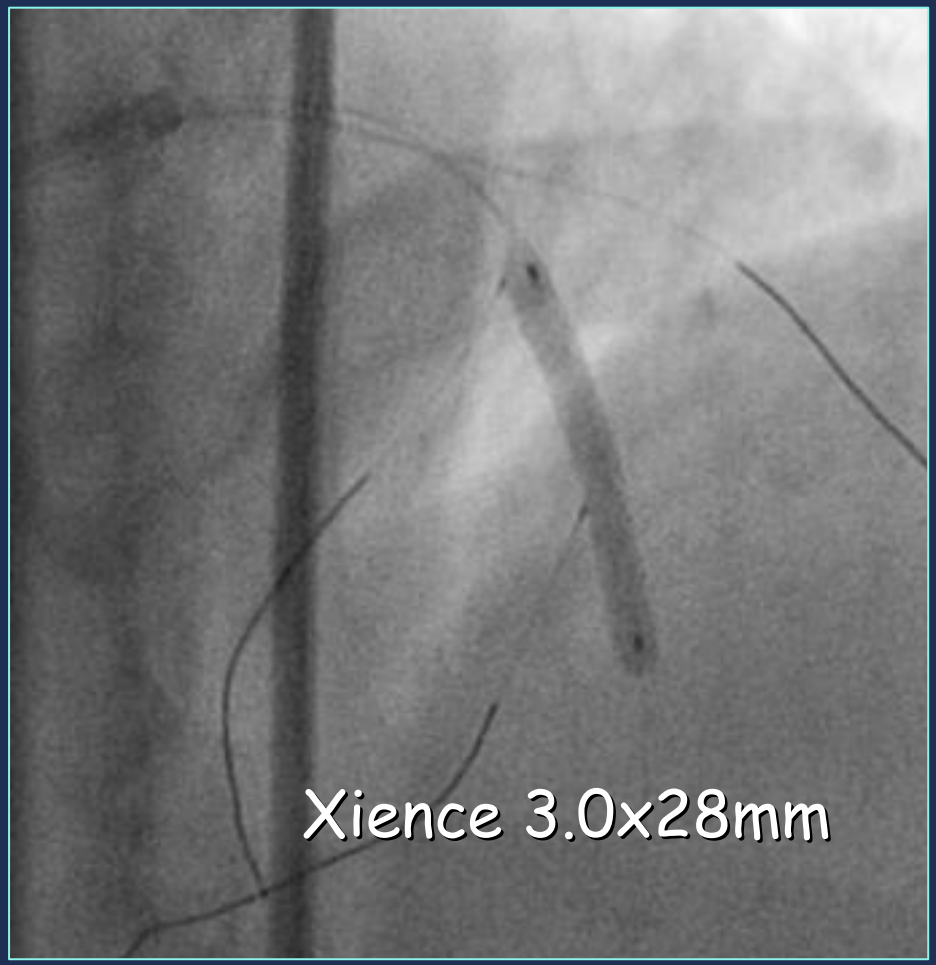

Stent on LAD

26319/07

CENTRO
CUORE
COLUMBUS

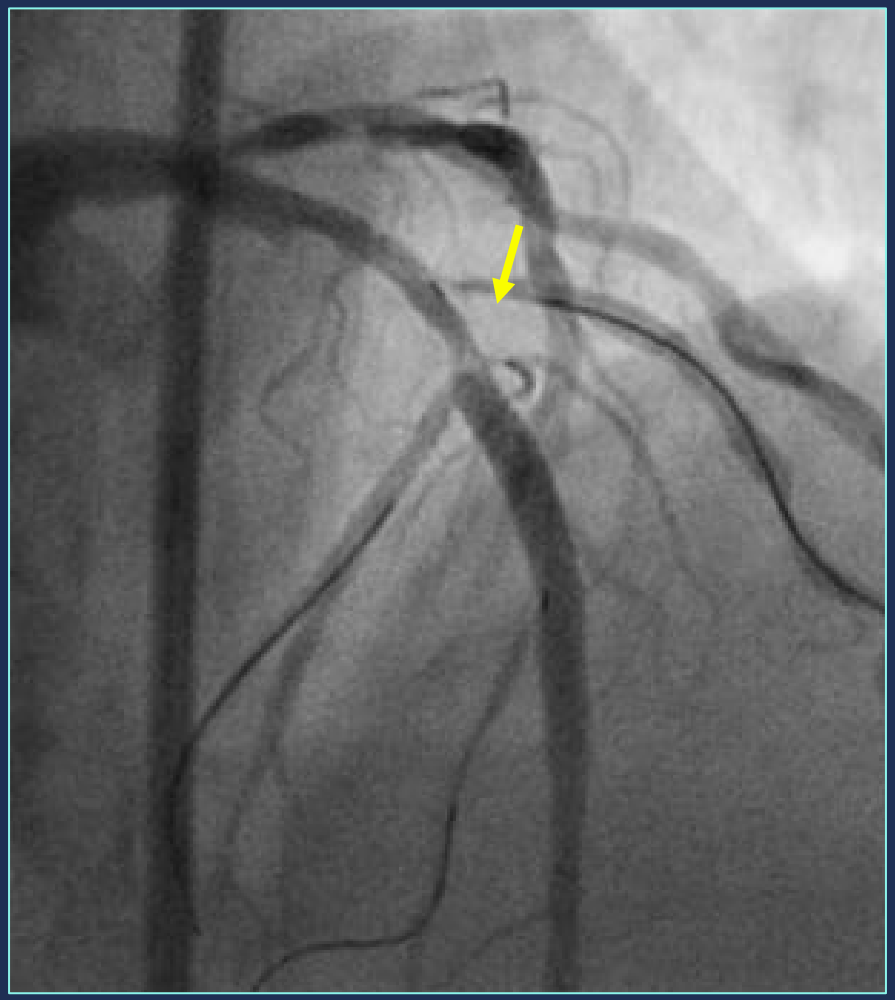

After Stent

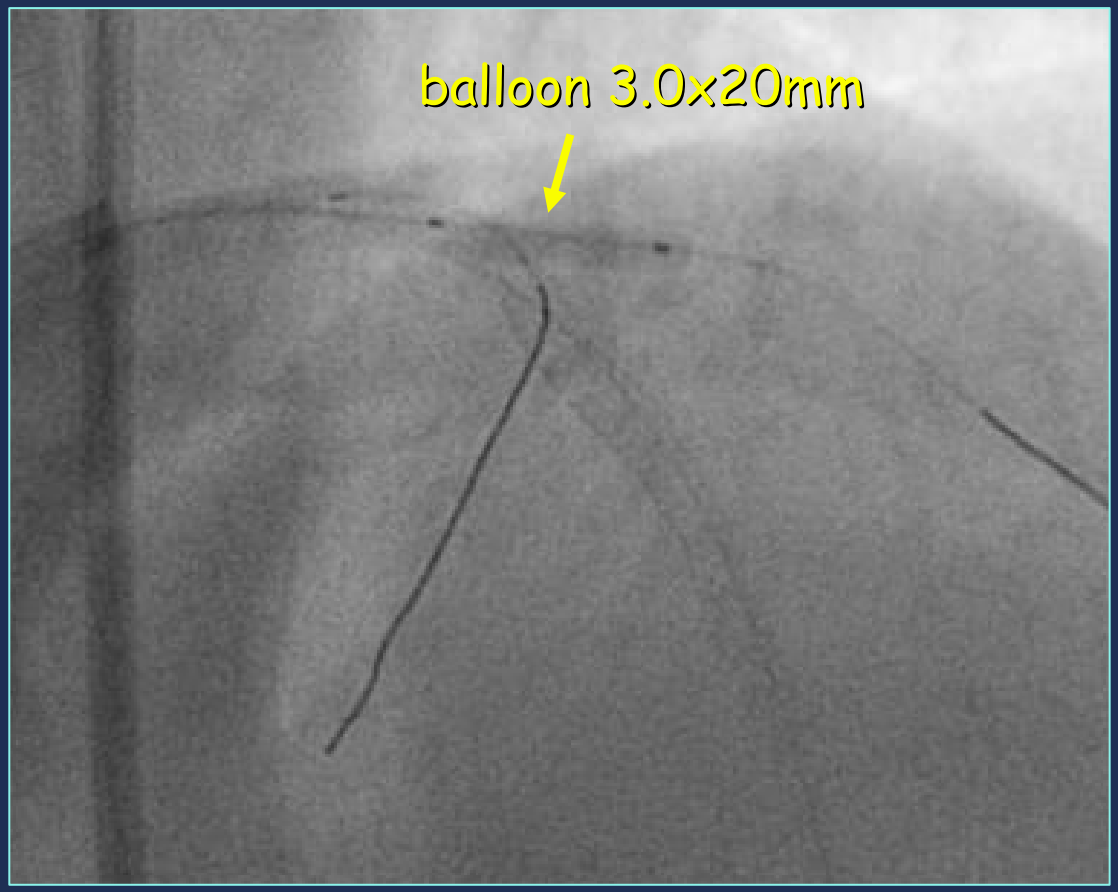

POBA on Diag

26319/07

CENTRO
CUORE
COLUMBUS

Final Result

26319/07

CENTRO
CUORE
COLUMBUS

Bifurcations

Two Stents

When the SB has disease extending beyond its ostium AND when the SB is suitable for stenting

8 Fr guiding catheter

1. Wire both branches
2. Dilate MB and SB if needed
3. Perform crush or V-stent
4. If crush: rewire SB and perform high pressure SB dilatation
5. Kissing balloon inflation

CENTRO
CUORE
COLUMBUS

1 or 2 stents?

A) If the side branch is significantly diseased at its ostium or nearby, it is sufficiently large to be stented, safety and duration of PCI are an issue: 2 stents

B) In all other conditions 1 stents and then evaluate

At present time the most accepted and applied strategy is provisional SB stenting, still there are a number of anatomical settings where the SB is large and diseased to require stenting as intention to treat

CENTRO
CUORE
COLUMBUS

Treatment of Bifurcation Lesion with two stents

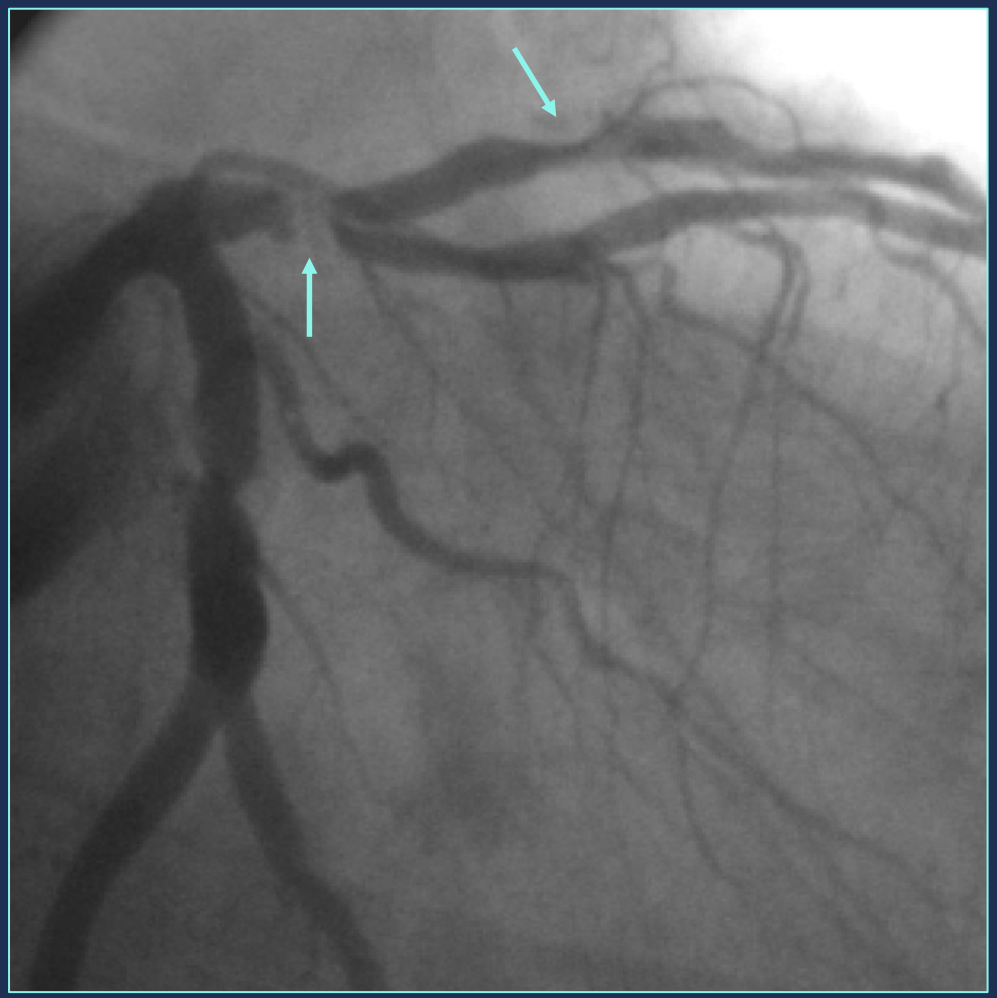

Baseline

Treatment

11162/02

CENTRO
CUORE
COLUMBUS

Treatment of Bifurcation Lesion with two stents

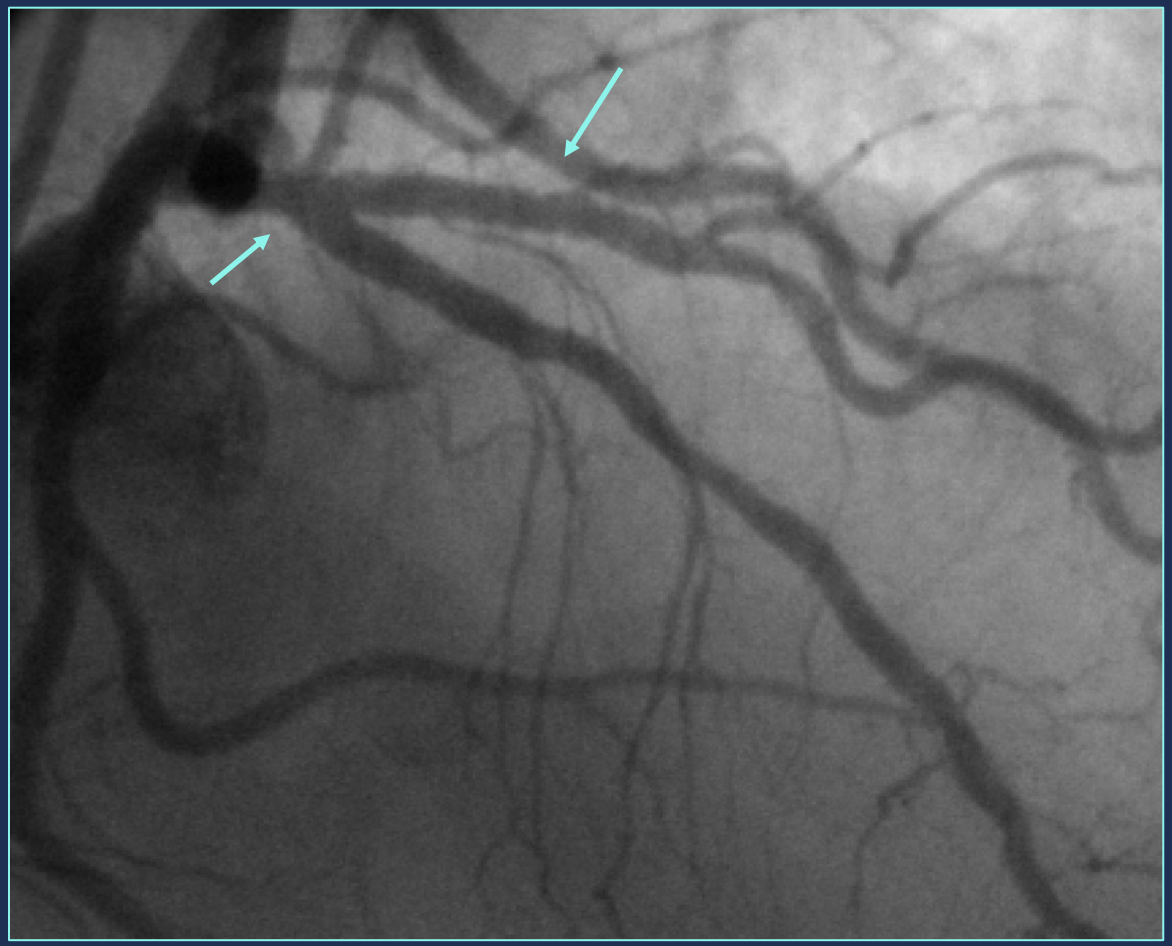

Final Result

11162/02

CENTRO
CUORE
COLUMBUS

A Typical Case for 2 stents

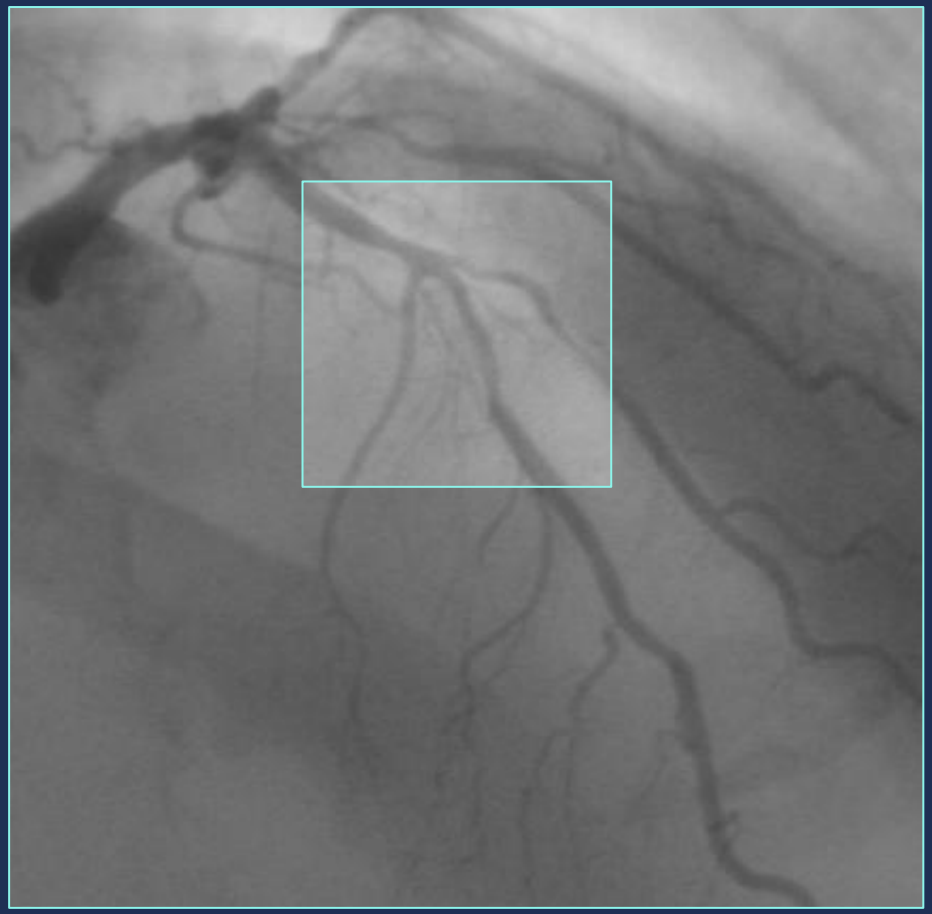

Baseline

Following Crush

12472/05

CENTRO
CUORE
COLUMBUS

2 stents approach when the SB may be difficult to be wired

Baseline

After Stent Implantation

CENTRO
CUORE
COLUMBUS

An approach for bifurcational lesions when using 2 stents as intention to treat

Bifurcational lesion with no disease proximal to the bifurcation or very short left main

V-Stent

Pre Post

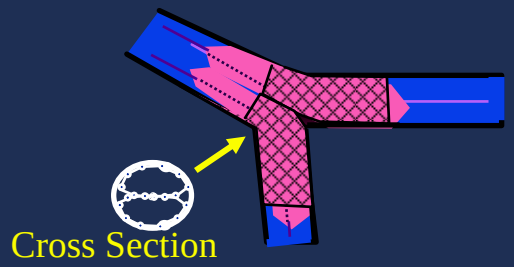

Bifurcational lesion with main branch disease extending proximal to the bifurcation and side branch which has origin with about 90° angle

T-Stent

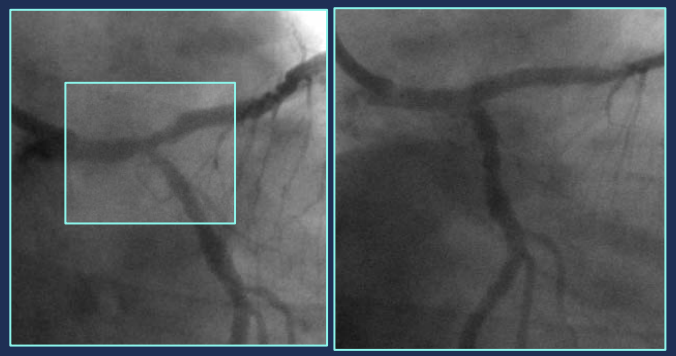

Pre Post

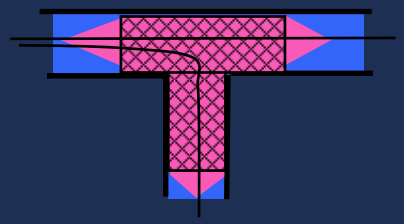

Bifurcational lesion with main branch disease extending proximal to the bifurcation and side branch which ha origin with about 60° angle

Short-Mini Crush

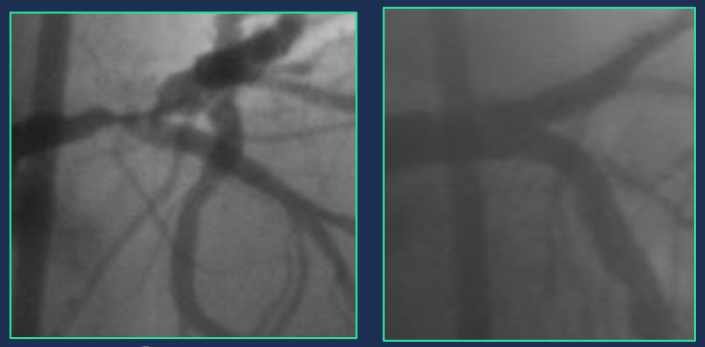

Pre Post

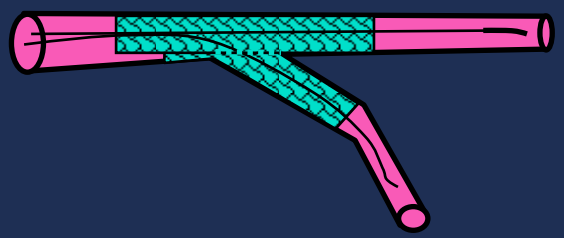

CENTRO
CUORE
COLUMBUS

Bifurcations

Keep It Open (KIO)

When the SB has ostial or diffuse disease AND when the SB is not suitable (too small) for stenting or clinically not relevant

6 Fr guiding catheter

1. Wire both branches
2. Dilate MB if needed
3. Stent MB and leave wire in the SB
4. Perform post-dilatation of the MB with jailed wire in the SB

⇨ Do not re-wire SB or postdilate or predilate SB

CENTRO
CUORE
COLUMBUS

Example of Keep It Open (KIO)

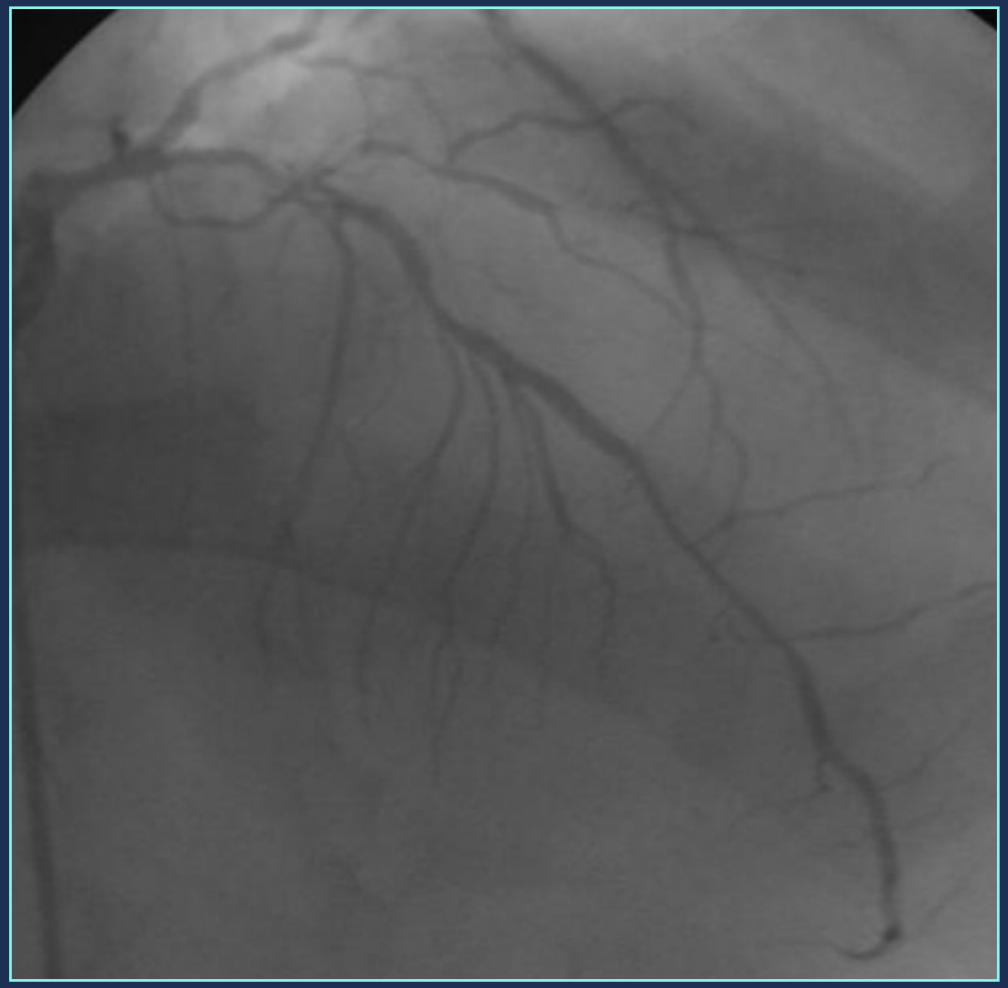

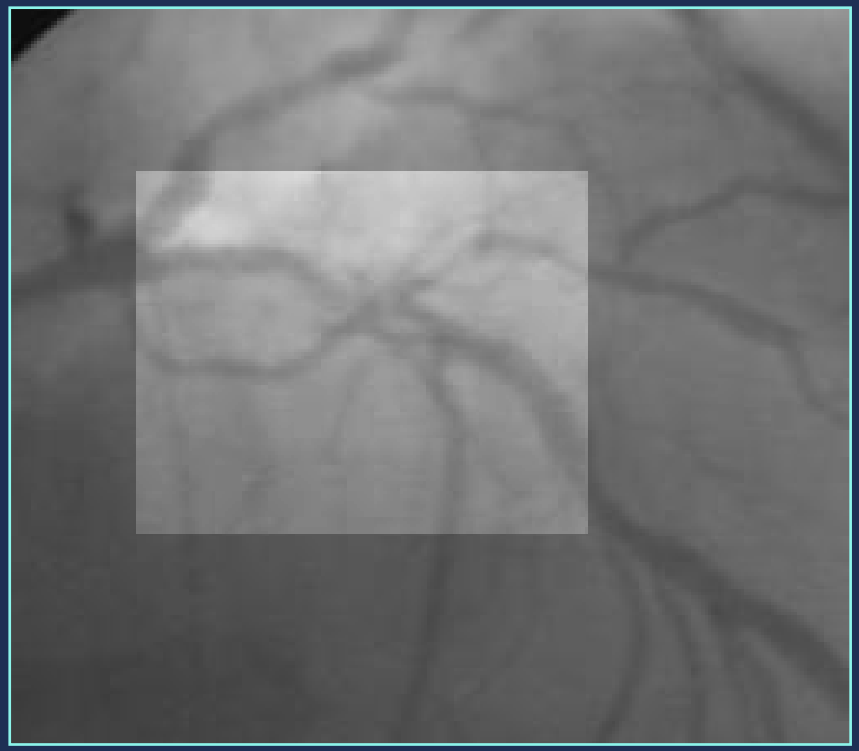

Baseline

CENTRO
CUORE
COLUMBUS

Example of Keep It Open (KIO)

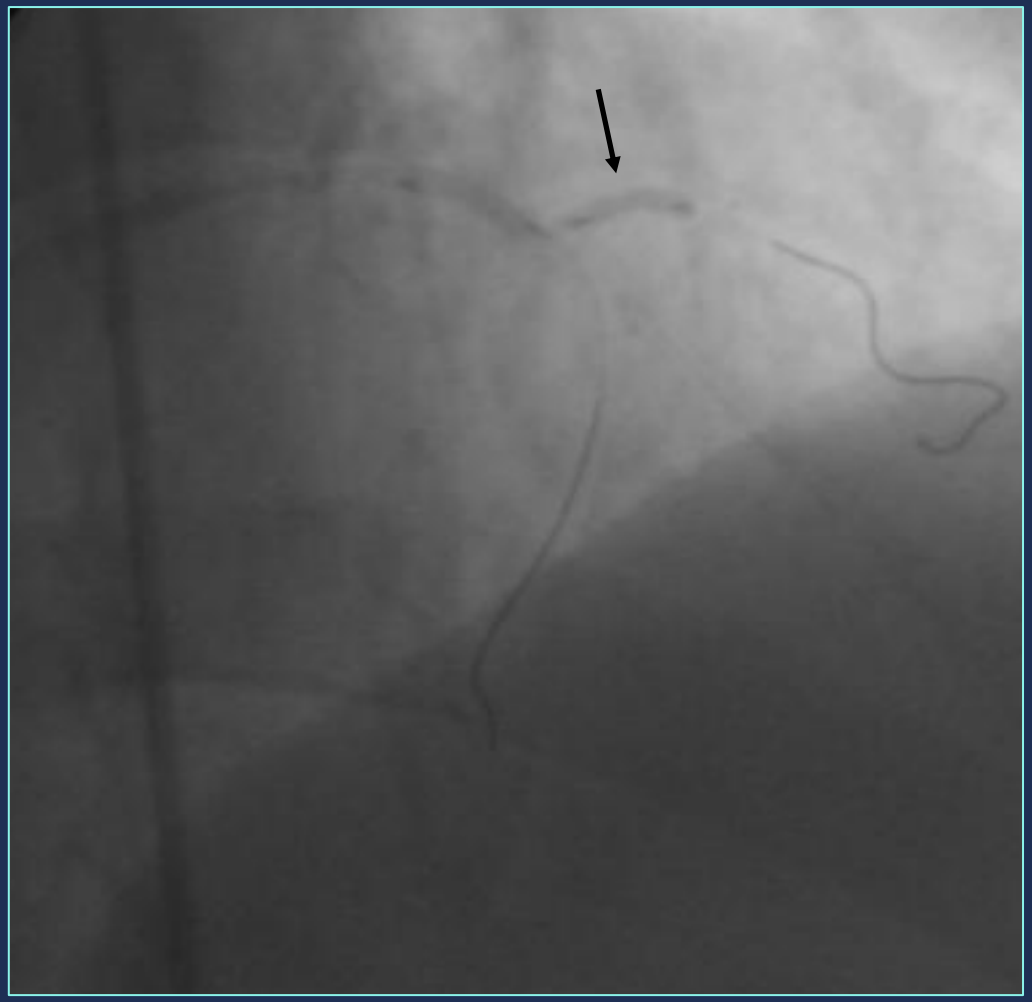

Balloon inflated on SB
(Should not have been done)

Post Balloon inflation on SB

CENTRO
CUORE
COLUMBUS

Example of Keep It Open (KIO)

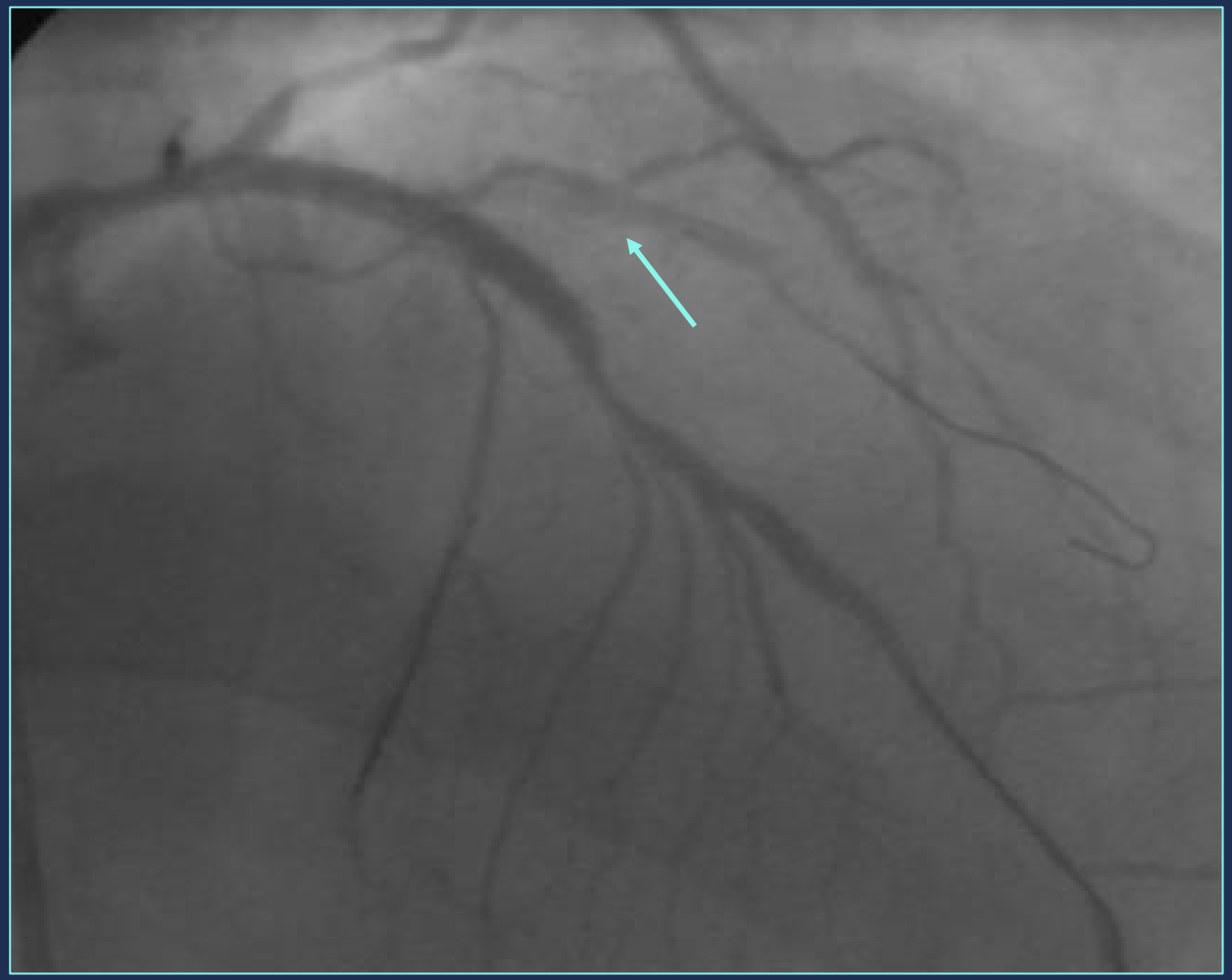

Stenting of MB

Rewiring of SB with large dissection

CENTRO
CUORE
COLUMBUS

Example of Keep It Open (KIO)

Perforation of SB attempting to gain true lumen

Final Result after cover stent on the MB

CENTRO
CUORE
COLUMBUS

Jailed wires for side-branch protection

side branches are selectively wired

Baseline

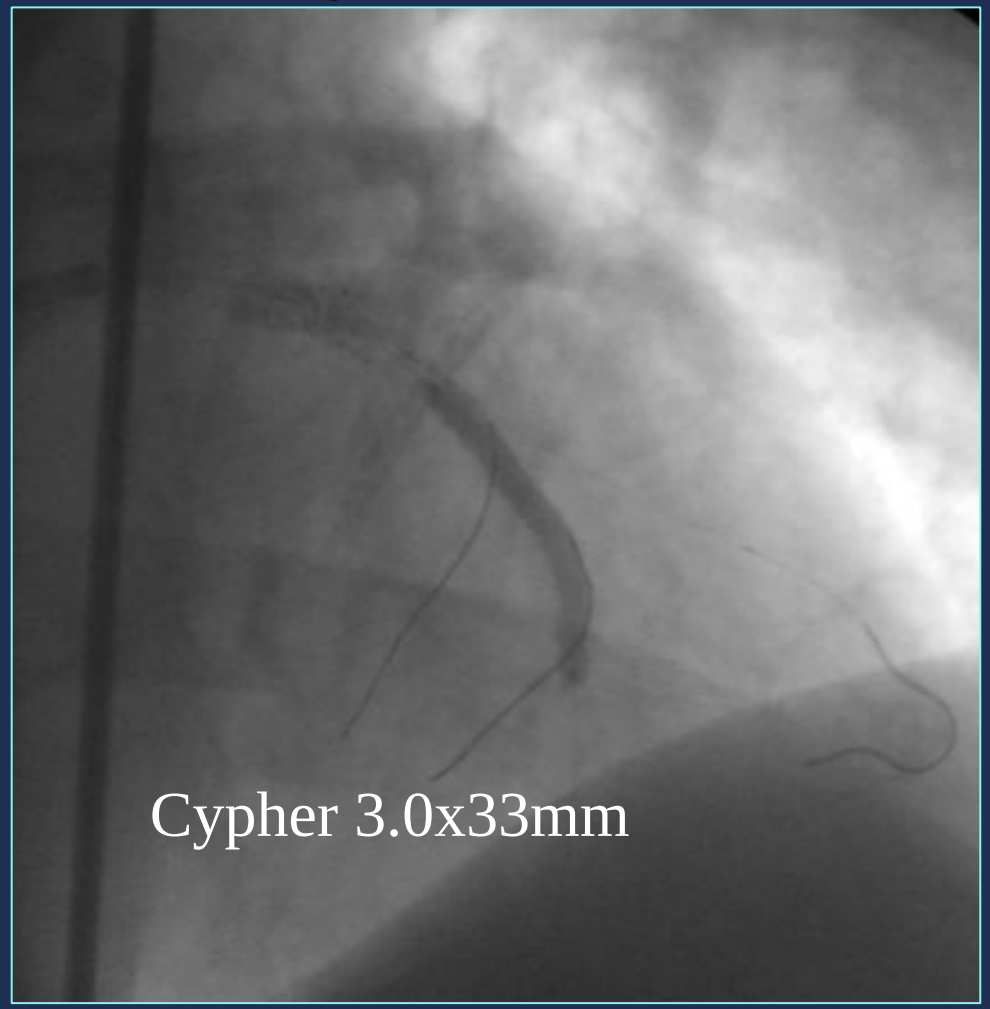

Side-Branch protection

12391/05

CENTRO
CUORE
COLUMBUS

Jailed wires for side-branch protection

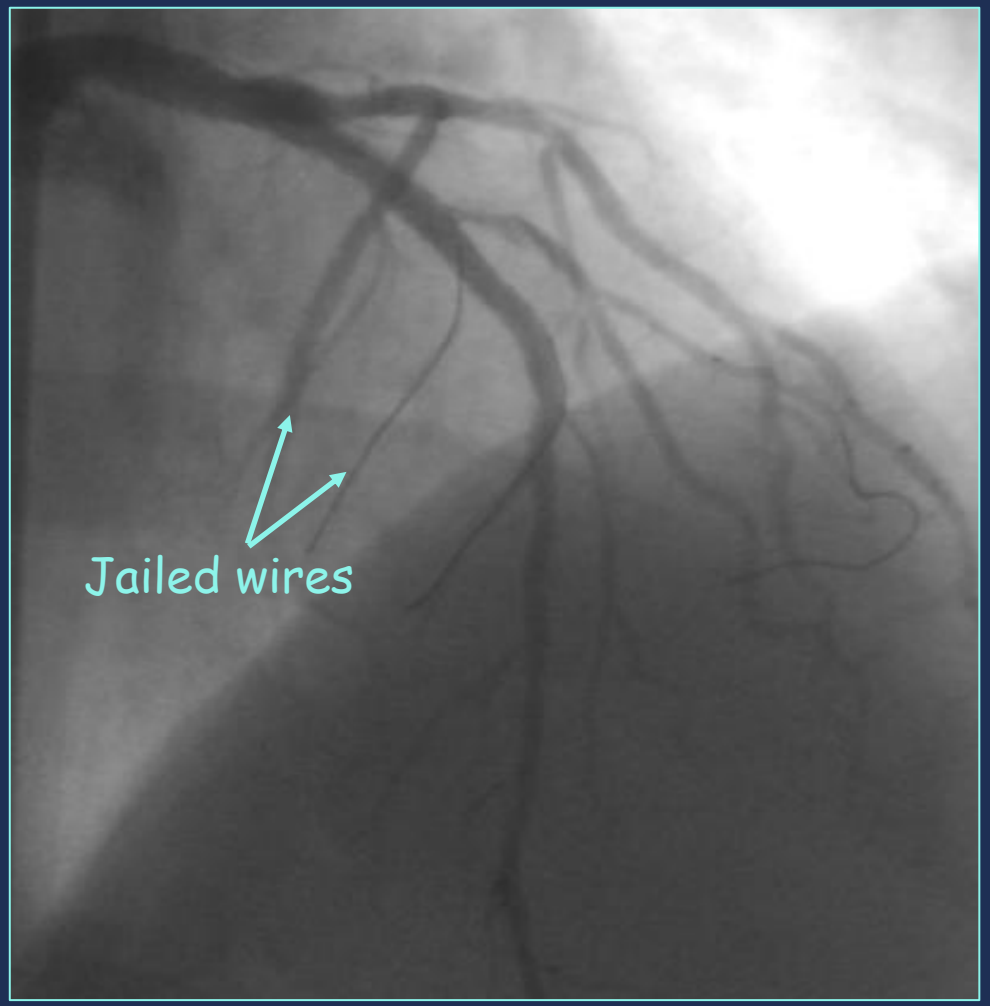

After stent

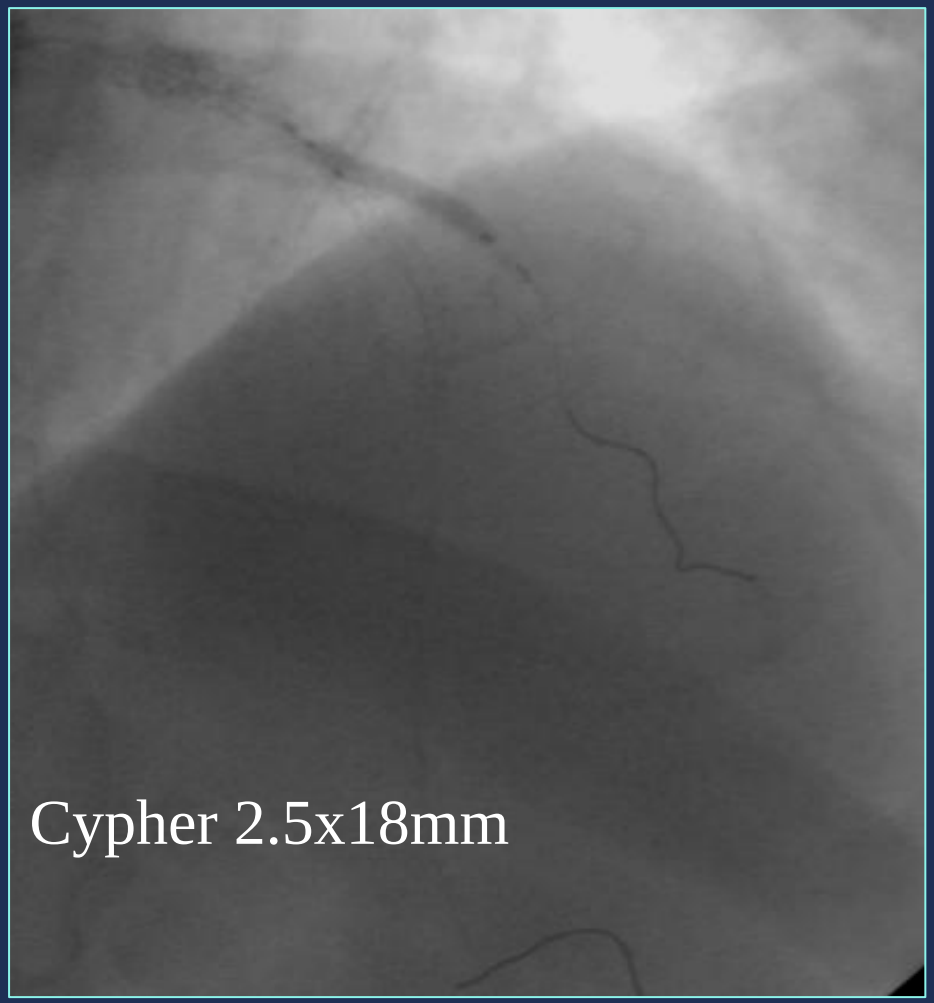

Stent in Diagonal

12391/05

CENTRO
CUORE
COLUMBUS

Jailed wires for side-branch protection

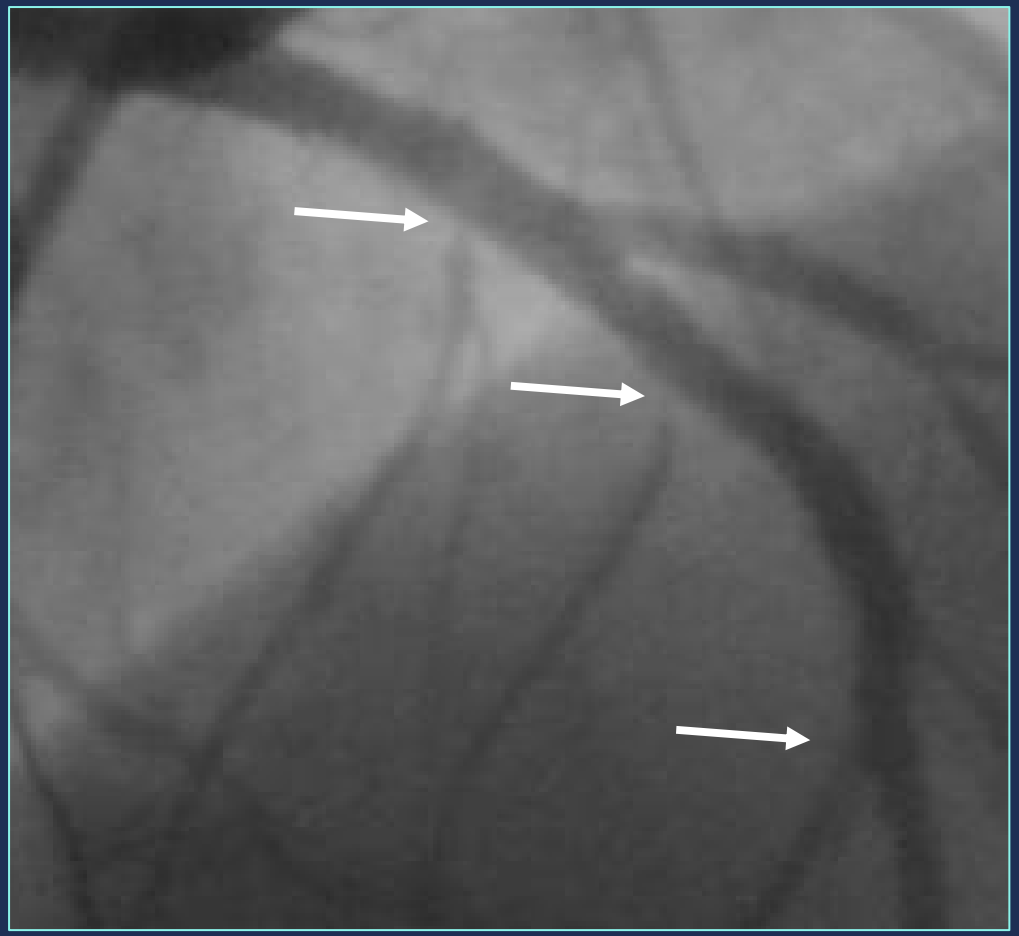

Final Result

12391/05

CENTRO
CUORE
COLUMBUS

Conclusions

- LM bifurcation vs. other bifurcations
- Consider the importance of the SB: not every SB needs treatment and not every SB needs optimal result
- Immediate result is very important when implanting 2 stents