Crossing Strategy for Complex & CTO Lesion
- Cross with Confidence -

Supported by Educational Grant from Johnson & Johnson Medical Korea

Advanced Techniques and Tools to Treat Below the Knee CTO

Kazushi Urasawa, MD, PhD, FJCC
Katsuhiko Sato, MD, PhD, Ryoji Koshida, MD, PhD
Michinao Tan, MD, Yuya Nakagawa, MD

Cardiovascular Center, Tokeidai Memorial Hospital
Sapporo, Japan

Standard setup for BTK intervention

1. Puncture site	ipsi-lateral antegrade
2. Sheath	Sheathless guiding cathe. ex. 4.5F Parent-Plus (Medikit)
3. Guidewire	0.014” guidewire Various products
4. Guidewire buck-up	0.014” compatible micro-cathe. Prominent (Tokai Medical Products) Corsair-PV (Asahi Intec)

Wiring techniques for BTK-CTO

1. Antegrade wiring

2. Bi-directional wiring with distal puncture

   Dorsalis Pedis
   distal ATA
   distal PTA
   distal PA
   Plantar artery
   Digital arteries

3. Bi-directional wiring using collateral channel

   Trans-collateral angioplasty (TCA)

TCA for BTK-CTO : Case 1

Case: 83yo Male

Diagnosis: CLI (Rutherford 5)

Risk factors: Hypertension
Diabetes Mellitus

Control angiography

Tip injection from a Prominent at peroneal trunk

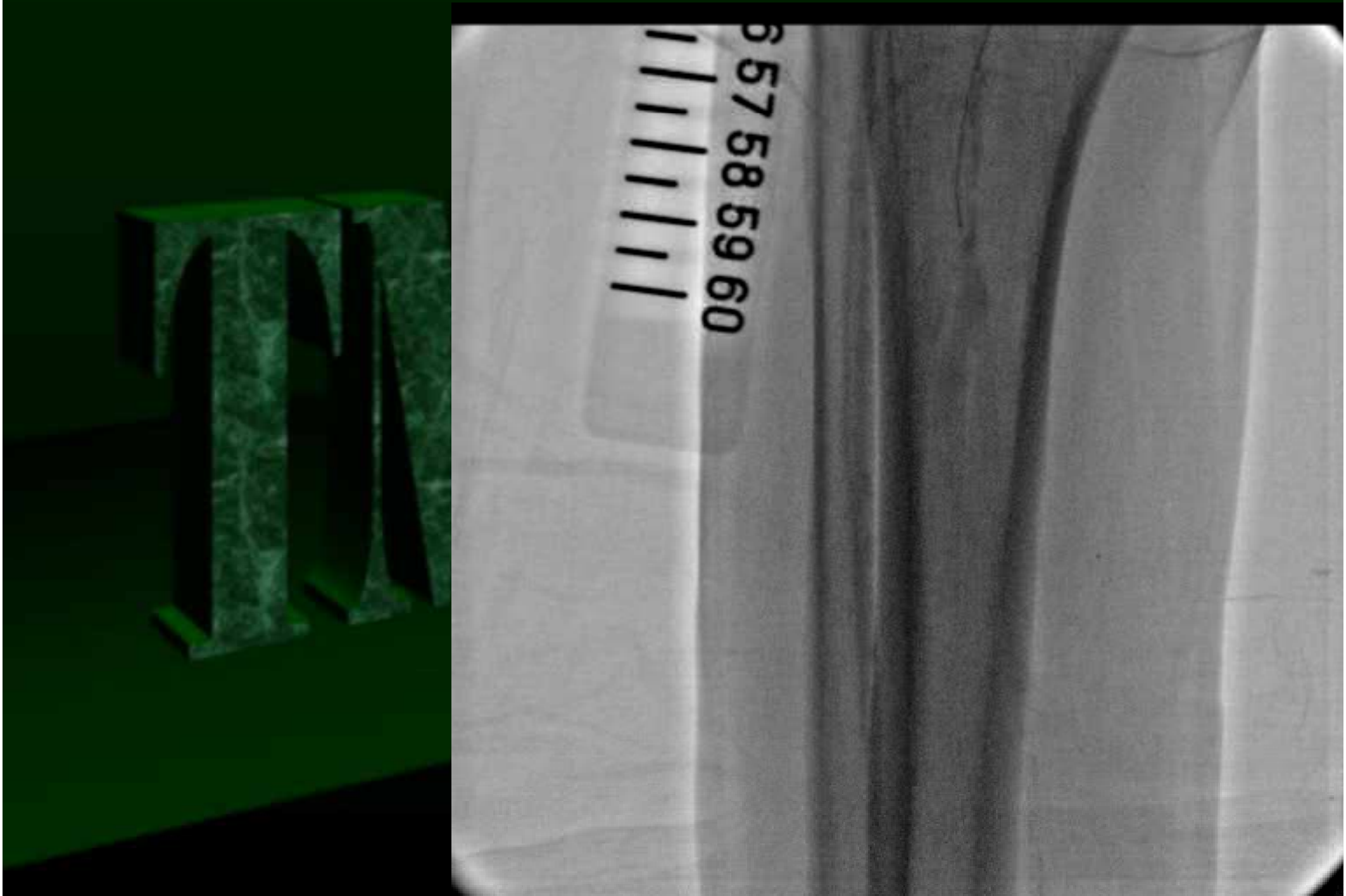

Selective angiography of a collateral channel

Angiogram of a channel connecting to PTA

Prominent was successfully advanced to PTA

Balloon dilatation of PTA

Balloon dilatation of distal PTA and plantar A.

Angiography after balloon angioplasty

TCA for BTK-CTO : Case 2

Case: 71yo Male

Diagnosis: CLI (Rutherford 5)

Risk factors: Hypertension
Diabetes Mellitus
Chronic renal failure (HD)

Control angiography

Wiring to the ATA (Micro Knuckle Method)

Cruise (Neos)
Prominent (Tokai Medical Products)

Angioplasty for the diffuse stenosis of ATA

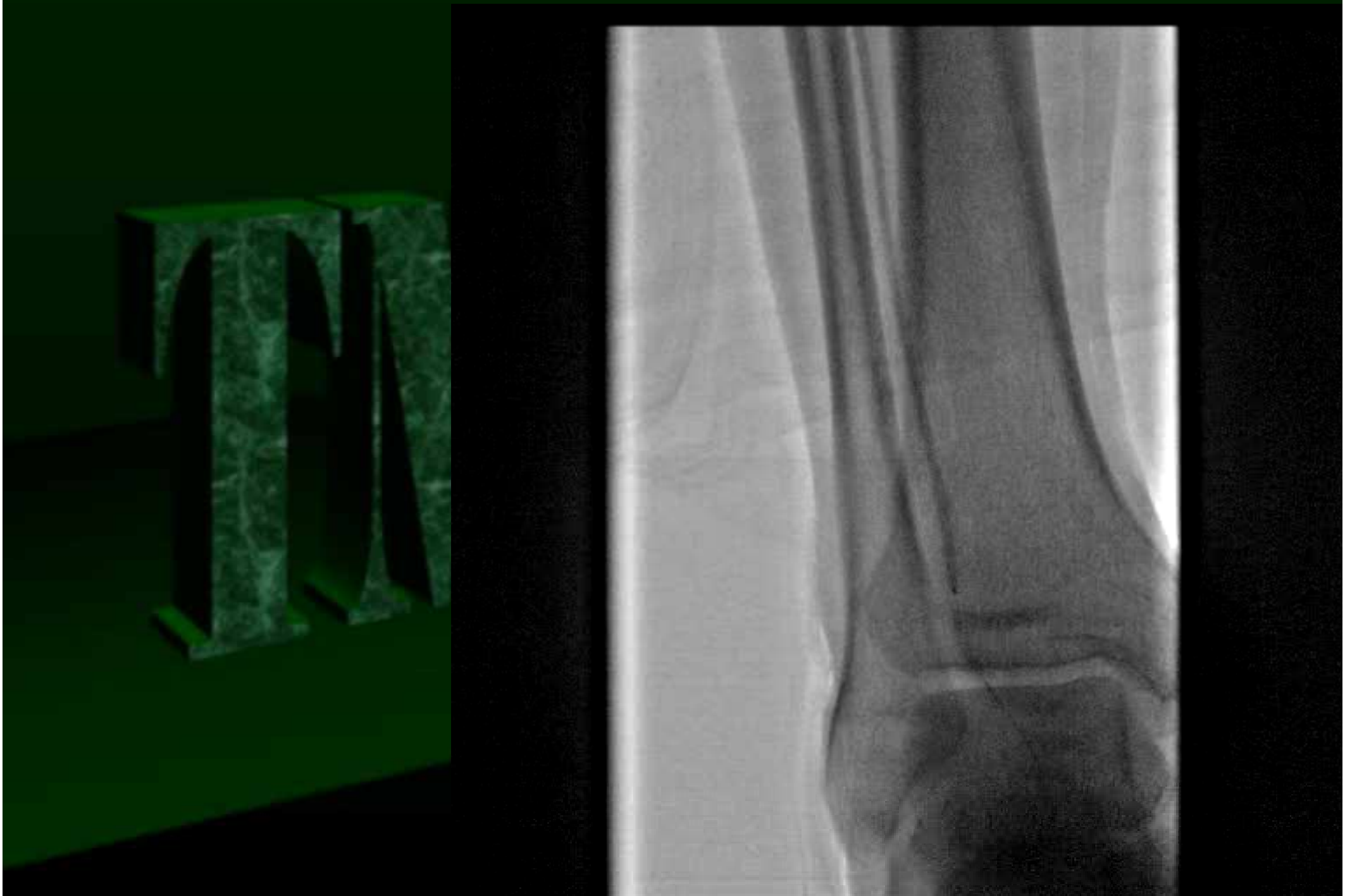

Angiography after balloon angioplasty

Tip injection at DP

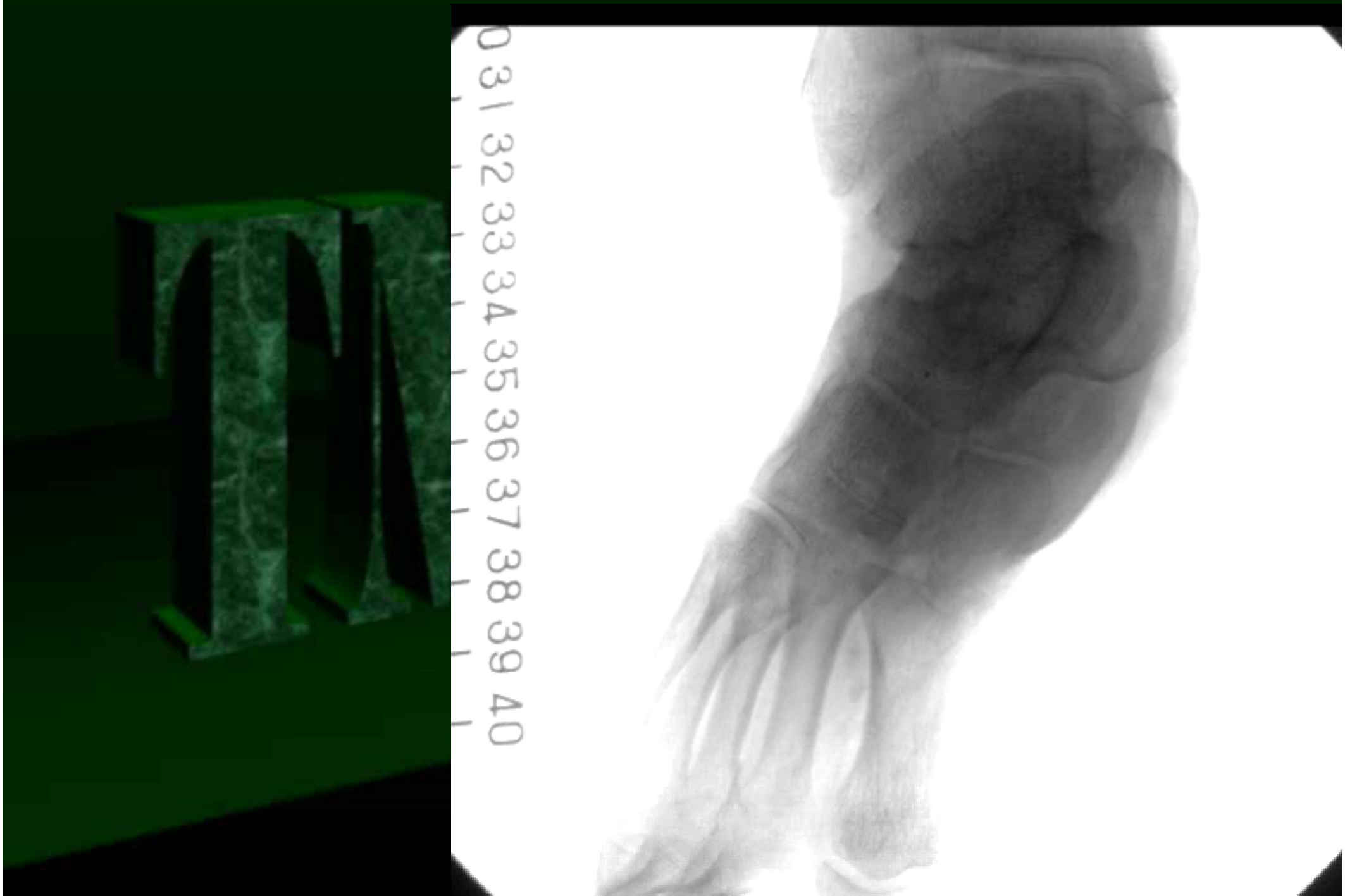

Cruise was advanced to lateral plantar artery

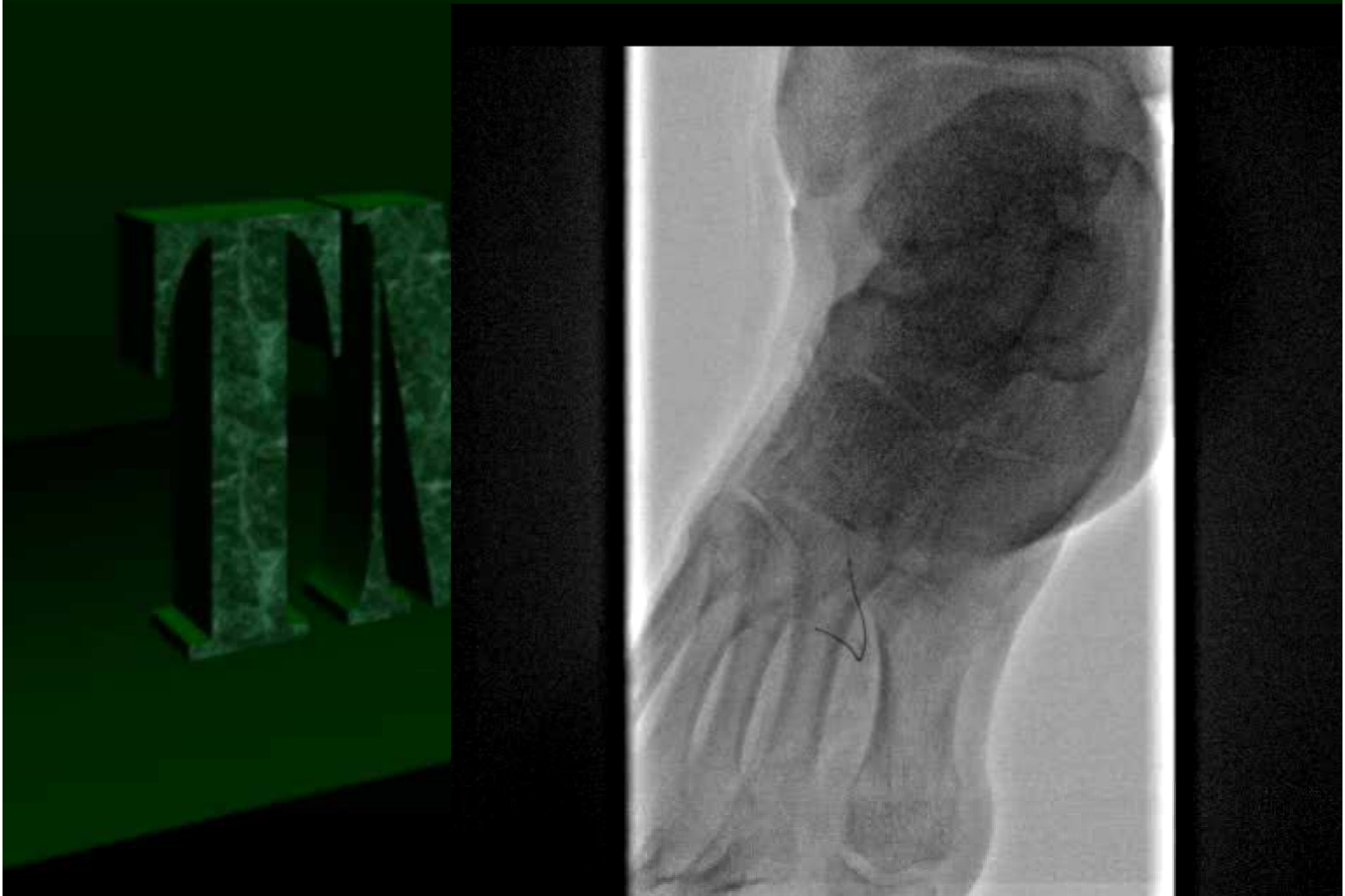

Prominent was advanced through the channel

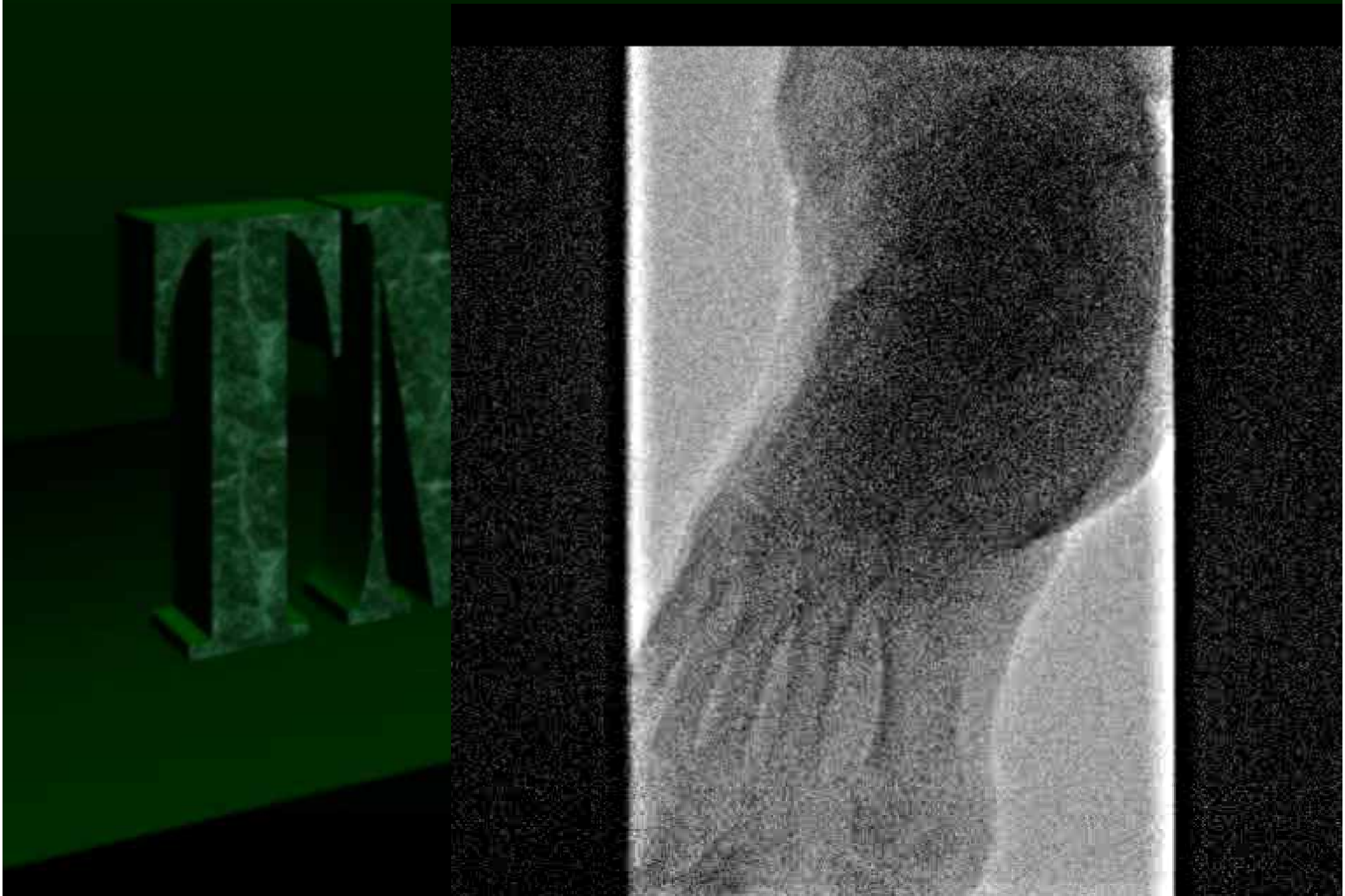

Tip injection at lateral plantar A.

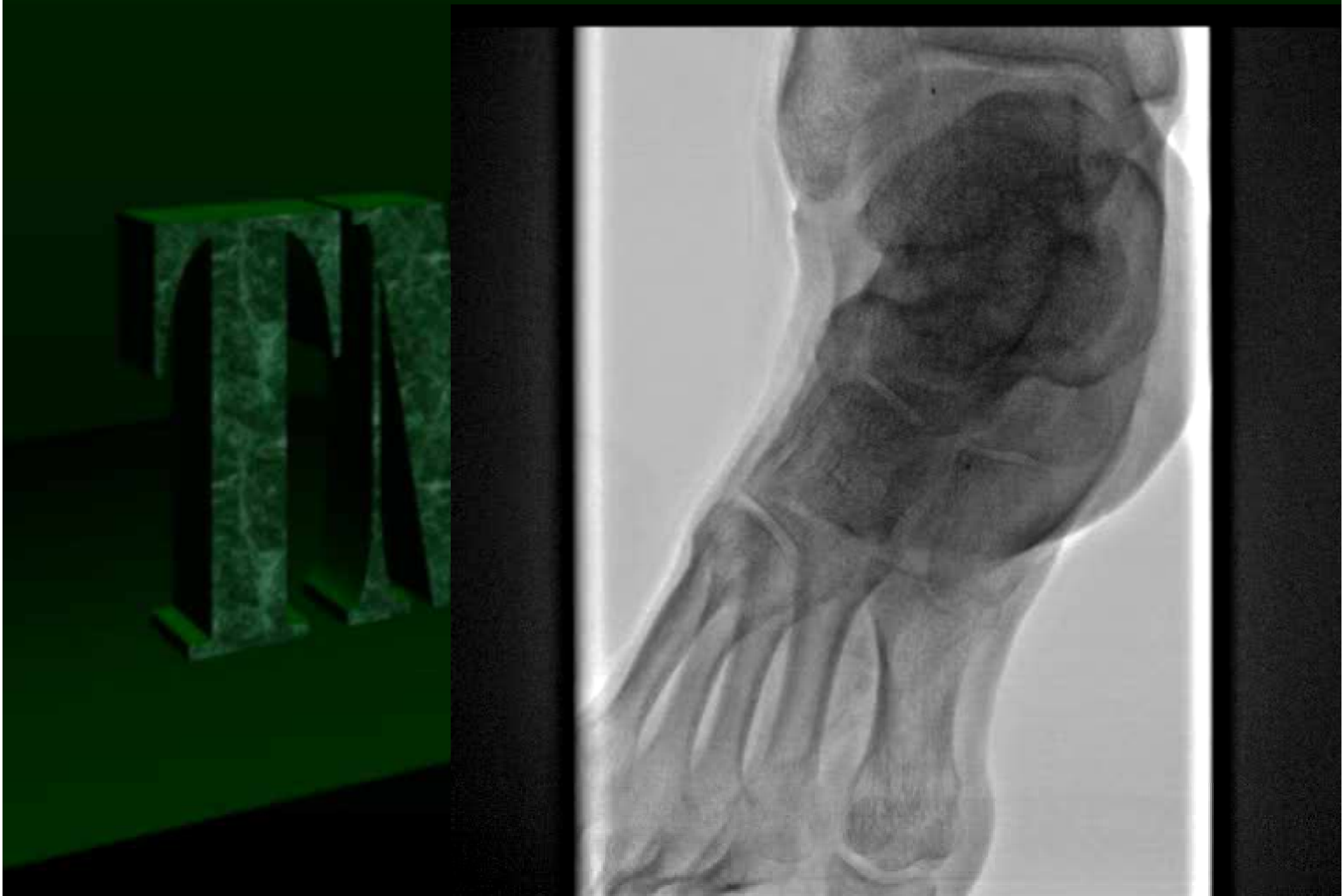

Retrograde wire was advanced to the proximal end of CTO

Chevalier floppy
(JJ Cordis)

Advance an antegrade wire to the PTA

Astato XS9-12
(Asahi Intec)
Corsair-PV
(Asahi Intec)

Wire Rendez-vous at distal PTA

Advance antegrade wire to the plantar A.

Balloon angioplasty of PTA-CTO

Balloon angioplasty of plantar A.

Antegrade wiring to the PA

Balloon angioplasty of PA

Final angiography

Two Key Issues which are essential for successful TCA

1. Technique for safe and secure guidewire navigation within collateral channels.
2. Guidewire and micro-catheter selection

TCA : Tips - 1

Channel selection

Pick up collateral channels suitable for TCA on control angiogram / MDCT

- not too long
- not too tortuous
- not too fine

TCA : Tips - 2

Guidewire selection

Cruise ® (= Fielder / Regalia)
0.014” soft tip wire (Tip weight = 1～ g)
Plastic jacket / Hydrophilic coating
Poor tip-shape memory

As far as we tested, Cruise seems to be the only one guidewire suitable for TCA.
Tapered type guidewires are dangerous, and easily result in wire-induced channel perforation.

TCA : Tips - 3

Microcatheter selection for backup support

Prominent (Tokai Medical Products: TMP)
Prominent-TCA (TMP)
Prominent-BTK (TMP)
Corsair-PV (Asahi Intec)

TCA : Tips - 4

How to pass a guidewire (Cruise) through a collateral channel

1. Shaping of guidewire tip

   Create 45 degree angle at the 1mm from the tip

2. Step by step technique

   Advance guidewire, then advance micro-catheter to straighten the segment.

3. Re-create load-map frequently

   Three dimensional shape of the collateral channel may change dramatically after the passage of guidewire and micro-catheter.

Summary

Trans-collateral approach is extremely useful to set-up bi-directional wiring, and greatly enhances the initial success rate of BTK intervention.

Although TCA is a little bit difficult compared with distal punctures, it is worthwhile to learn the skill of trans-collateral wiring if you want to expand your EVT activity.