Predictors of restenosis and stent thrombosis in bifurcation PCI

Bon-Kwon Koo, MD, PhD, FACC

Seoul National University Hospital, Seoul, Korea

SNUH Cardiovascular Center

Predictors of restenosis and stent thrombosis in bifurcation PCI

- In-stent restenosis: How frequent and Why?
- In-stent restenosis: Stenosis vs. Clinical relevance
- Stent thrombosis in bifurcation PCI
- Stent thrombosis: Lumen vs. Flow

Does restenosis matter in bifurcation lesions?

	One stent Restenosis rate, %	Two stents Restenosis rate,
BMS	27	54

	One stent TVR rate, %	Two stents TVR rate, %
BMS	17.5	38.9

Niccoli, AHA 2005

SIRIUS Bifurcation study

	In-Hospital		6 Months	
	Stent/Stent (63 Patients)	Stent/PTCA (22 Patients)	Stent/Stent (63 Patients)	Stent/PTCA (22 Patients)
Death	0	0	1 (1.6)	0
Q-wave MI	0	1 (4.5)	1 (1.6)	1 (4.5)
Non–Q-wave MI	6 (9.5)	1 (4.5)	6 (9.5)	1 (4.5)
MB restenosis*	. . .	. . .	3/53 (5.7)	1/21 (4.8)
SB restenosis*	. . .	. . .	12/55 (21.8)	3/21 (14.2)
Re-PTCA, TLR	1 (1.6)	0	6 (9.5)	1 (4.5)
Bypass	0	0	1 (1.6)	0
Re-PTCA, TVR	0	1 (4.3)	7 (11.1)	2 (9.0)
TVF	6 (9.5)	2 (9.1)	12 (19.0)	3 (13.6)

Colombo A, et al. Circulation 2004

Does restenosis matter in bifurcation lesions?

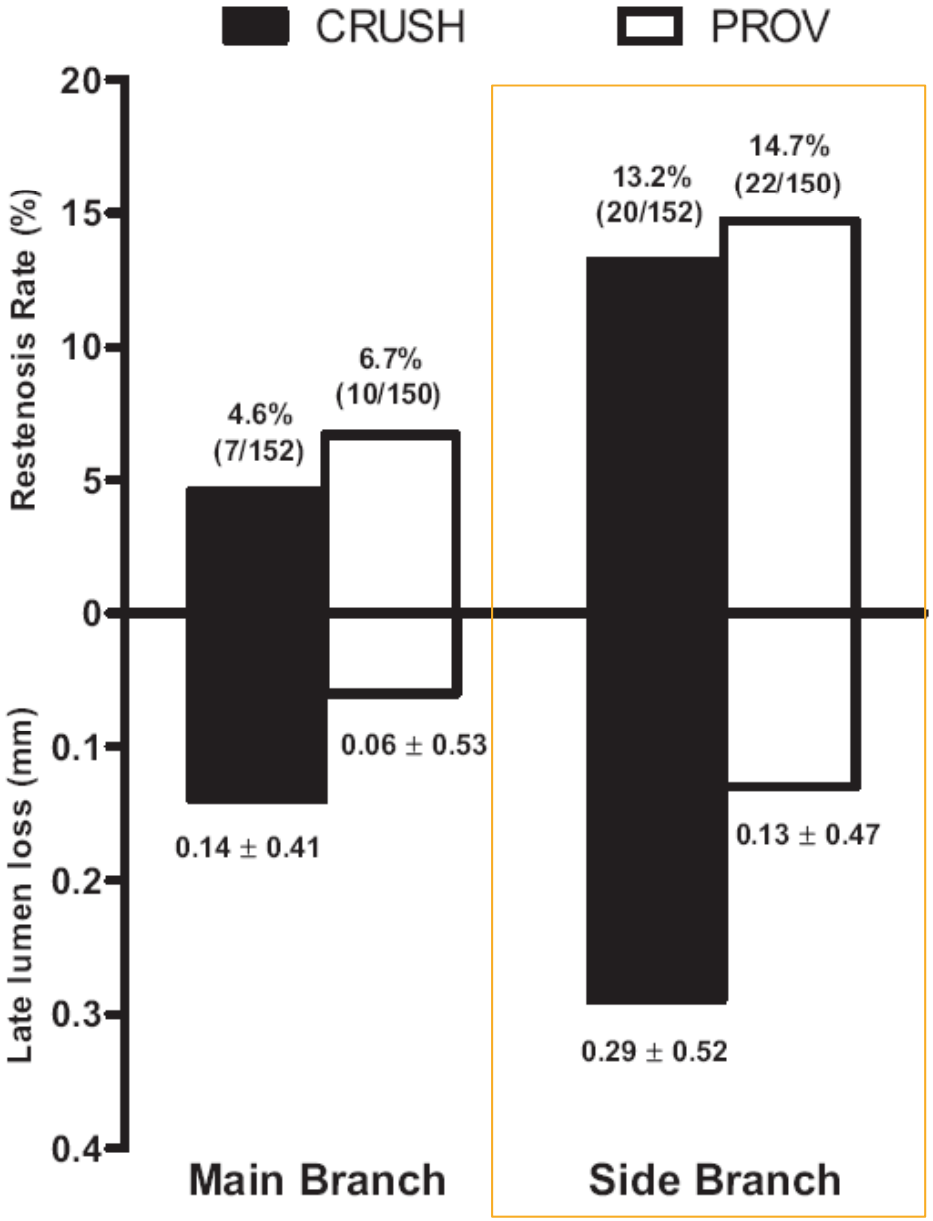

Colombo A, et al. Circulation 2009

Complex disease, complex intervention and high restenosis

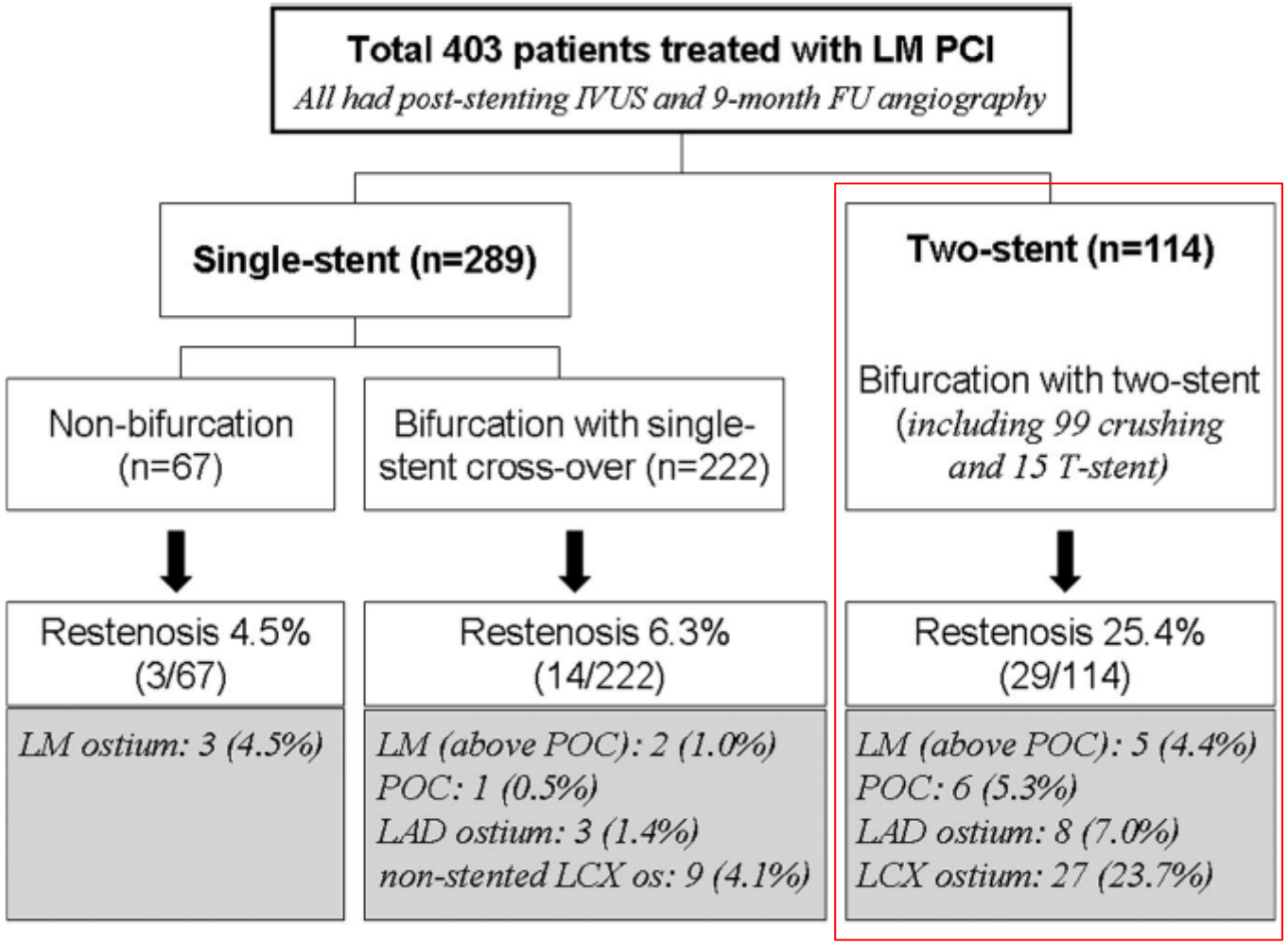

Kang SJ, et al. Circulation CVI 2011

Why more restenosis in side branch ostium?

Unique plaque location, remodeling pattern



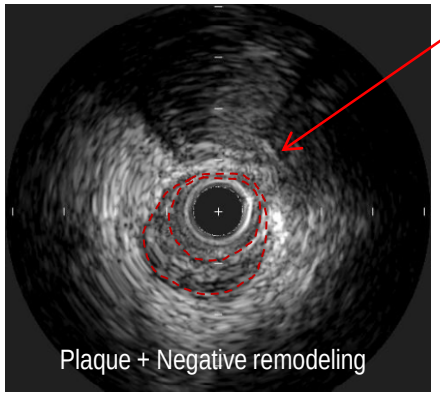

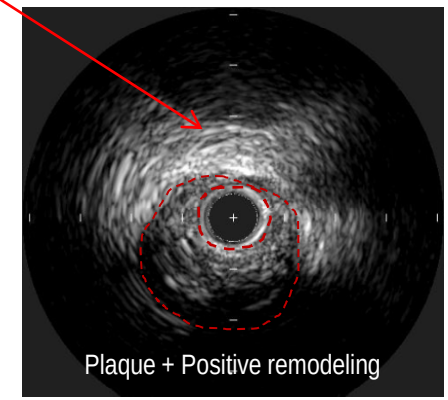

- Eccentric plaque
- Disease free wall at carina
- Negative remodeling

→

- Difficult to achieve enough lumen area
- Easy dissection
- More injury → More tissue reaction

Determinants of restenosis

Serial IVUS study after T stenting

Location of post-procedural minimal stent area

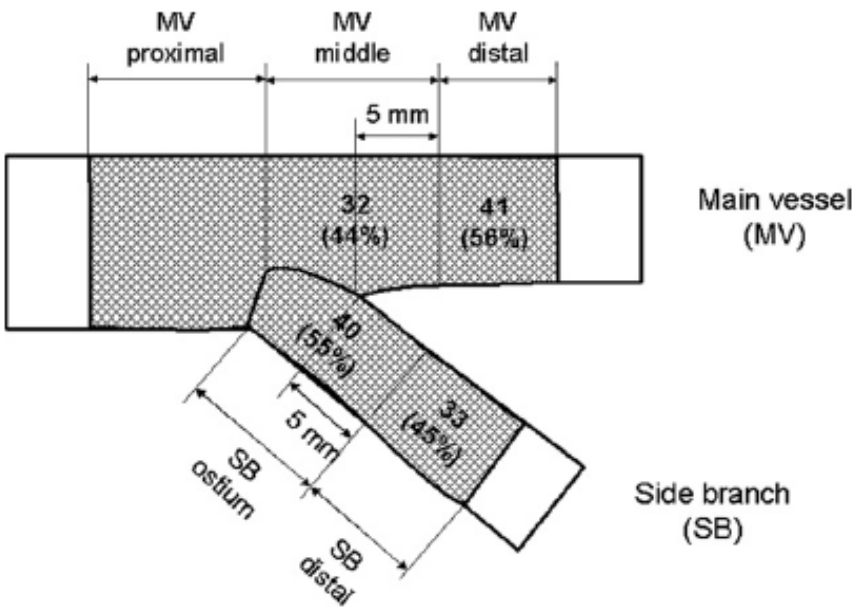

Neointimal hyperplasia at follow-up

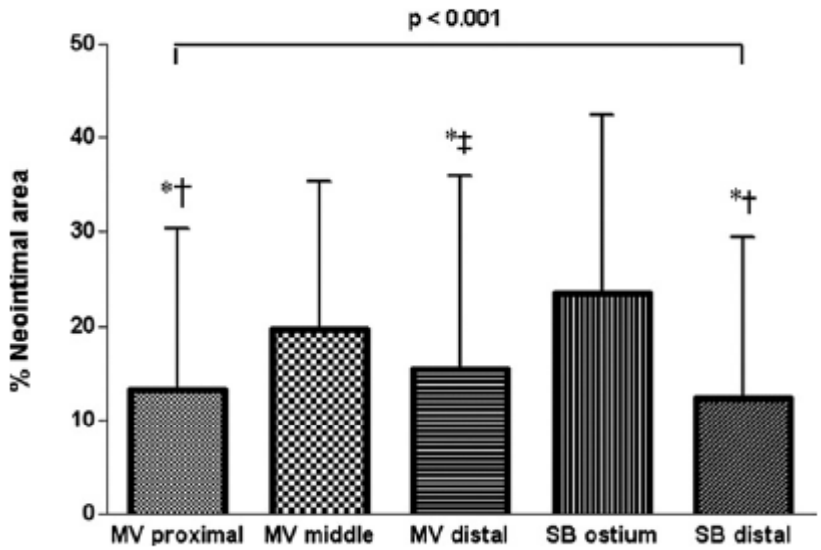

Hahn JY, et al. JACC 2009

Larger post-procedural MSA for larger MLA during follow-up after T-stenting

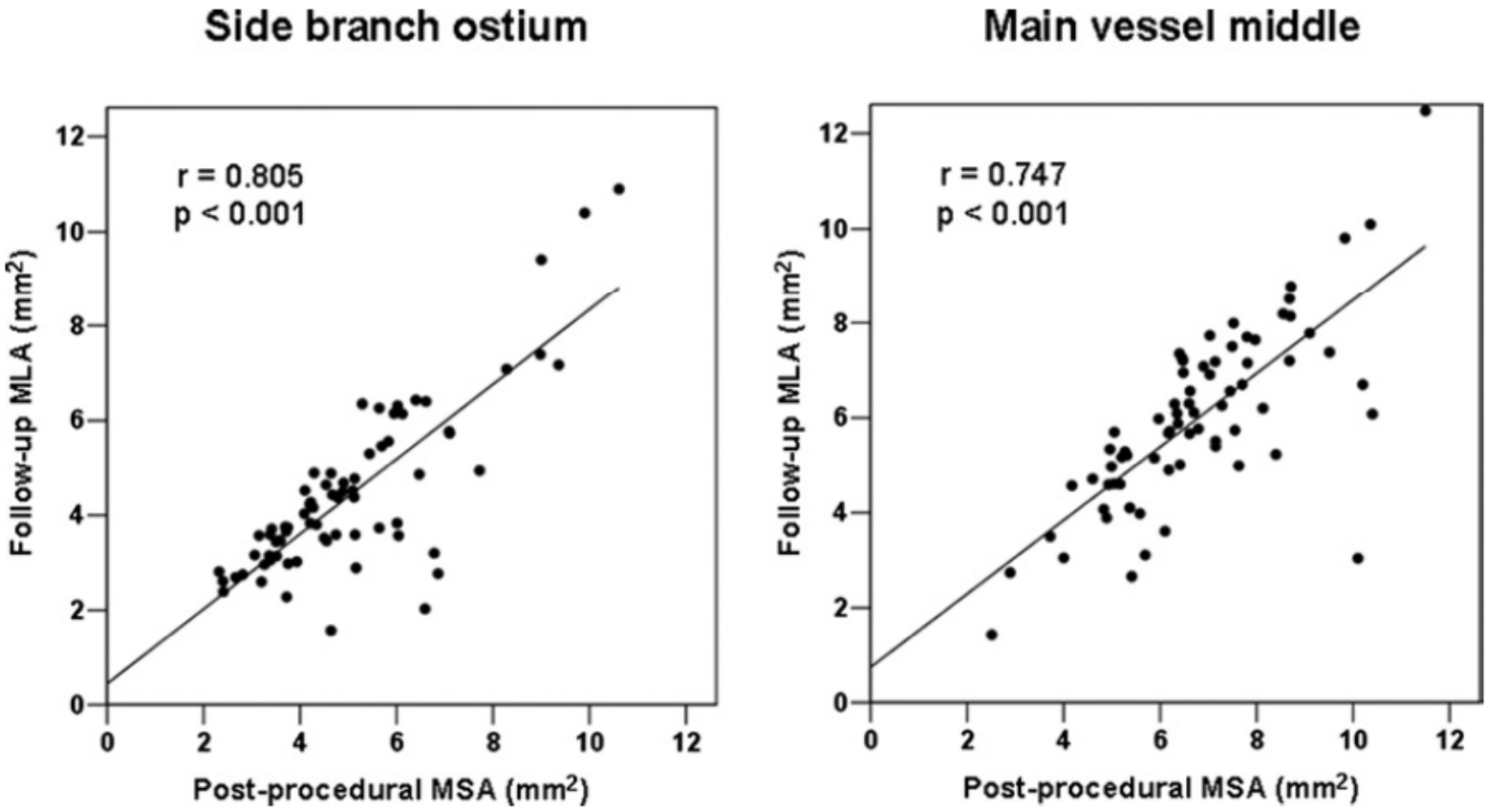

Hahn JY, et al. J Am Coll Cardiol 2009

Small IVUS stent area and under-expansion are the determinants of ISR

Minimal stent area cutoff for ISR

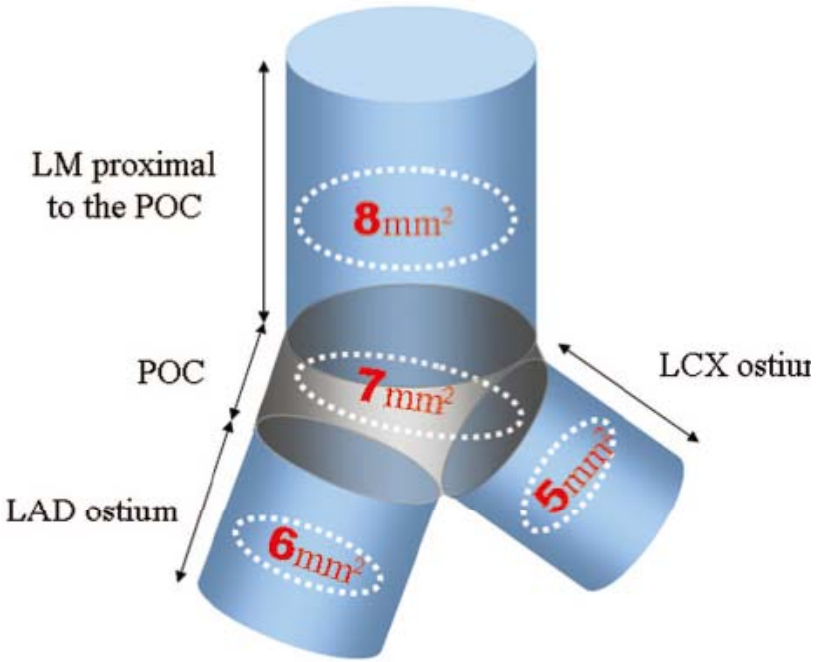

Frequency of under-expansion in 2 stent group

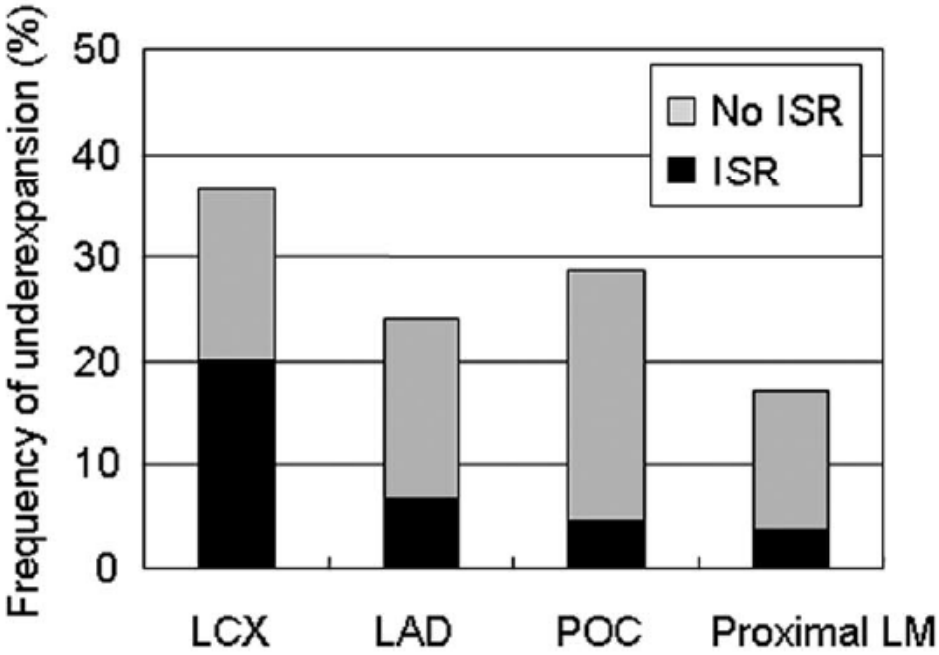

Kang SJ, et al. Circulation CVI 2011

Predictors of restenosis and stent thrombosis in bifurcation PCI

- In-stent restenosis: How frequent and Why?
- In-stent restenosis: Stenosis vs. Clinical relevance
- Stent thrombosis in bifurcation PCI
- Stent thrombosis: Lumen vs. Flow

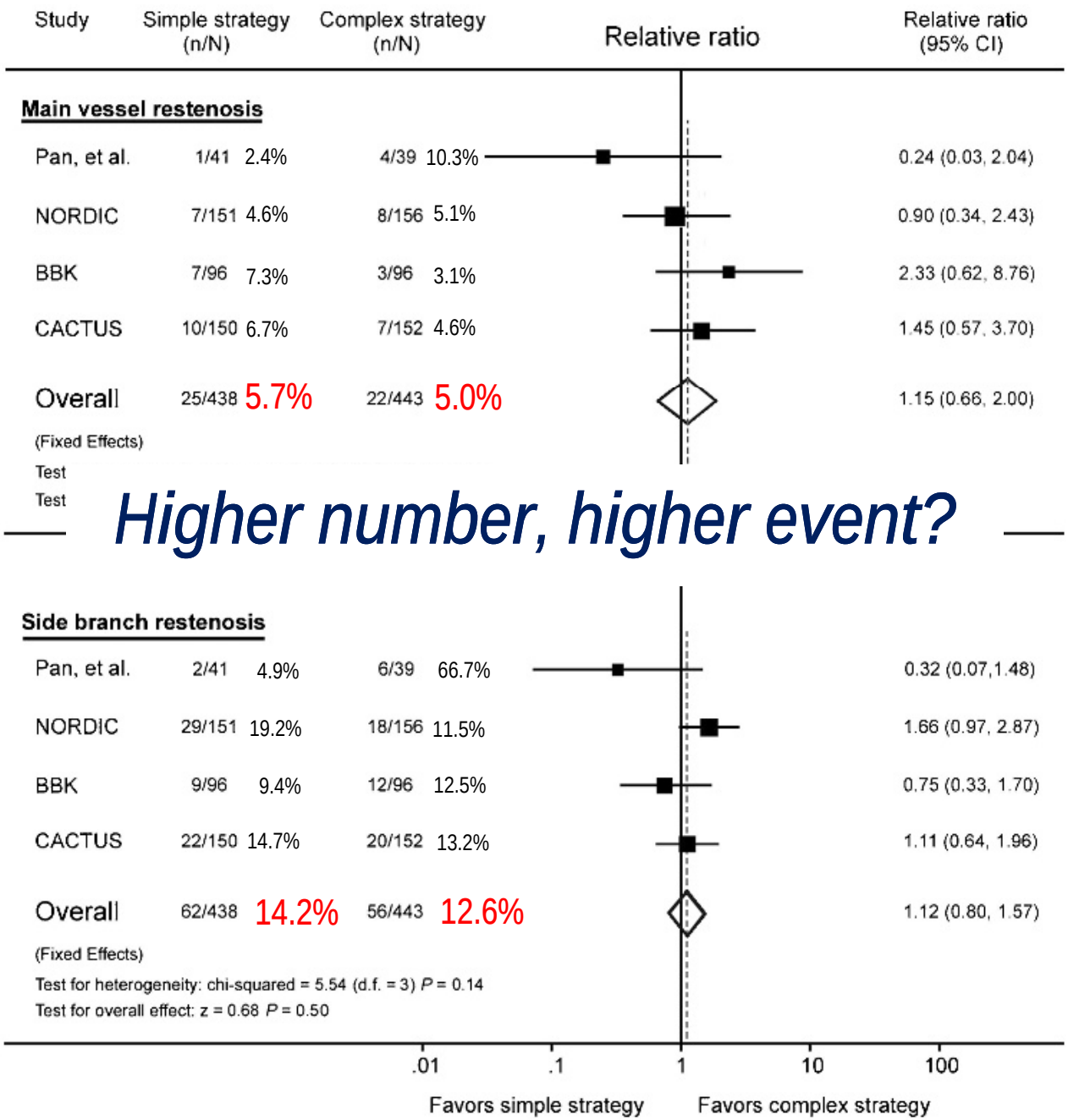

Higher number, higher event?

Zhang, et al. Heart 2009

What is significant restenosis?

TABLE 5. Rate of Significant Stenosis at 8-Month Follow-Up in Bifurcation Segments

	Proximal MV Segment			Distal MV Segment			Side Branch		
Variable	MV	MV+SB	*P*	MV	MV+SB	*P*	MV	MV+SB	*P*
In-stent stenosis, n (%)*	0 (0.0)	1 (0.6)	1.00	4 (2.6)	3 (1.9)	0.72	29 (19.2)	17 (10.9)	0.041
Edge stenosis, n (%)	3 (2.0)	4 (2.6)	1.00	0 (0.0)	2 (1.3)	0.50	11 (7.3)	6 (3.8)	0.20
SB stenosis/occlusion, n (%)	...	...		...	...		29 (19.2)	18 (11.5)	0.062

Steigen, et al. Circulation 2006

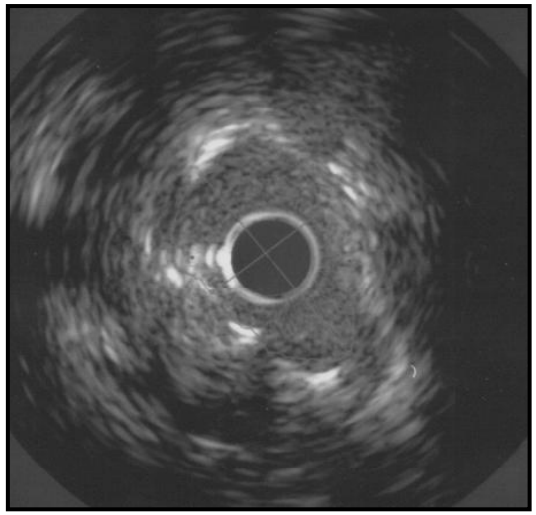

FFR 0.92

Does restenosis (residual stenosis) of a side branch matter?

Angiographic inaccuracy to predict the presence of myocardial ischemia

FFR vs. % diameter stenosis in jailed side branches

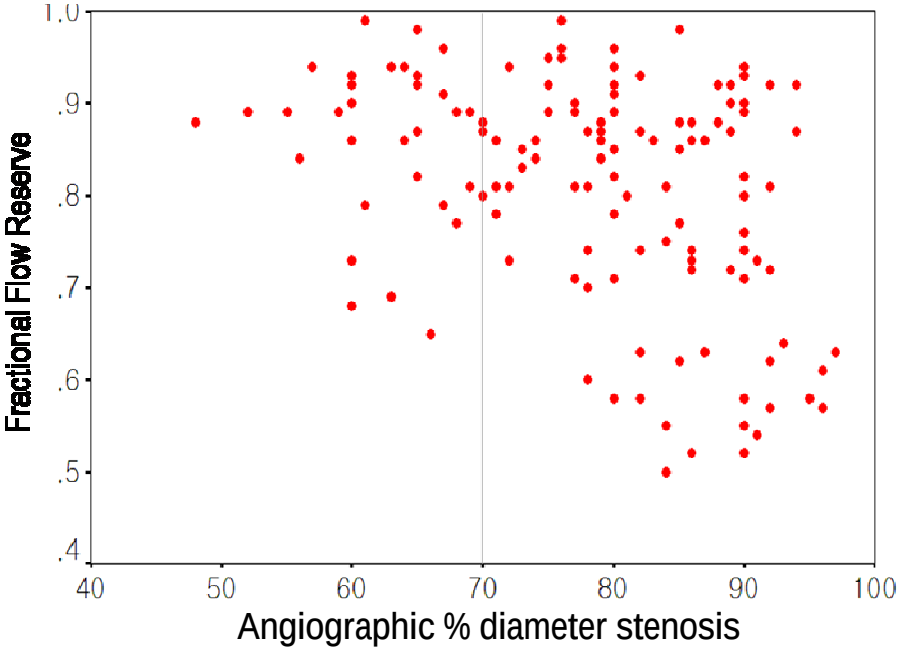

Koo BK, et al JACC 2005, EHJ 2008, Circulation CVI 2010

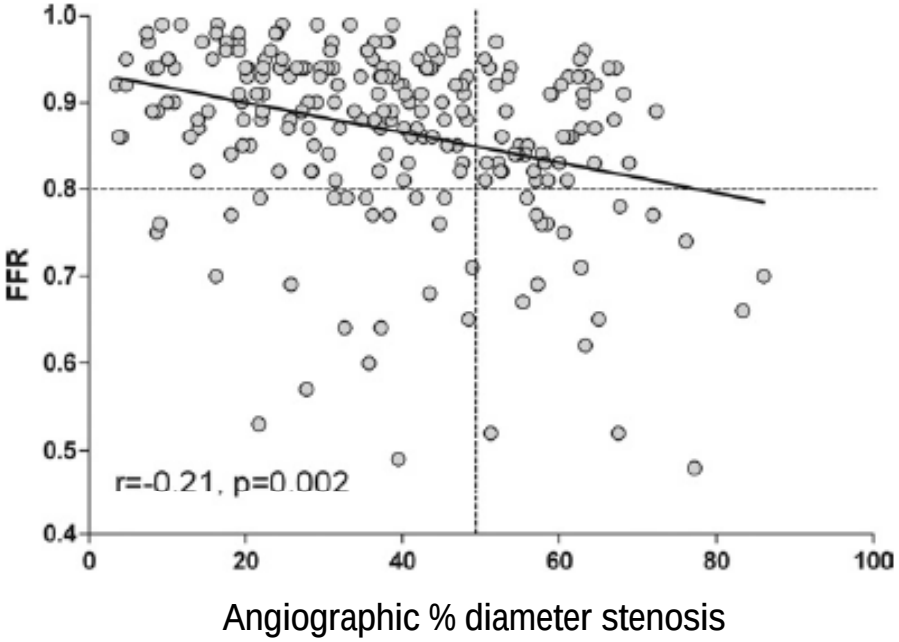

Ahn JM, et al. JACC intv 2012

Does restenosis (residual stenosis) of a side branch matter?

Amount of ischemia is more important than the presence of ischemia

2010 ESC guidelines for revascularization

	Subset of CAD by anatomy	Class[a]	Level[b]
For prognosis	Left main >50%[d]	I	A
	Any proximal LAD >50%[d]	I	A
	2VD or 3VD with impaired LV function[d]	I	B
	Proven large area of ischaemia (>10% LV)	I	B
	Single remaining patent vessel >50% stenosis[d]	I	C
	1VD without proximal LAD and without >10% ischaemia	III	A
For symptoms	Any stenosis >50% with limiting angina or angina equivalent, unresponsive to OMT	I	A
	Dyspnoea/CHF and >10% LV ischaemia/viability supplied by >50% stenotic artery	IIa	B
	No limiting symptoms with OMT	III	C

Comparison of clinical and electrocardiographic relevance between LAD and diagonal branches

	LAD	Diagonal	P value
1 min occlusion of flow			
Pain score	4.1±3.5	2.3±2.7	<0.001
ST elevation +	60 (92%)	24 (37%)	<0.001
QTc segment, msec	413±34	406±30	0.05
QTc dispersion, msec	100±35	84±27	0.001

Koo BK, et al JACC intv, in revision

Predictors of restenosis and stent thrombosis in bifurcation PCI

- In-stent restenosis: How frequent and Why?
- In-stent restenosis: Stenosis vs. Clinical relevance
- Stent thrombosis in bifurcation PCI
- Stent thrombosis: Lumen vs. Flow

Is bifurcation lesion a predictor of stent thrombosis?

Incidence and predictors of coronary stent thrombosis: Evidence from an international collaborative meta-analysis including 30 studies, 221,066 patients, and 4276 thromboses

Most powerful predictors of definite or probable stent thrombosis

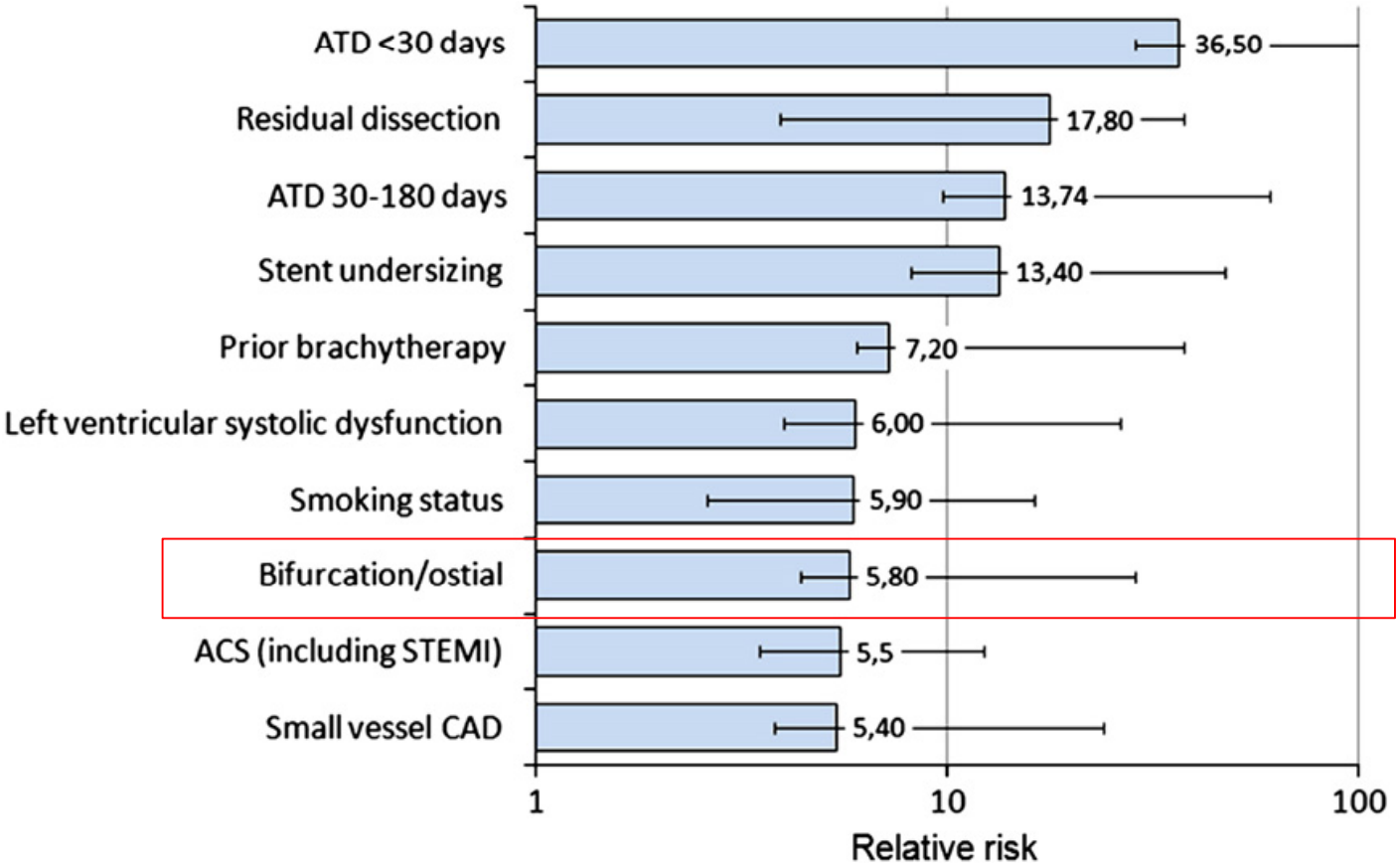

D'Ascenzo F, et al IJCA, in press

Is two stenting a predictor of stent thrombosis?

Stent Thrombosis

- 1 stent vs. 2 stent -

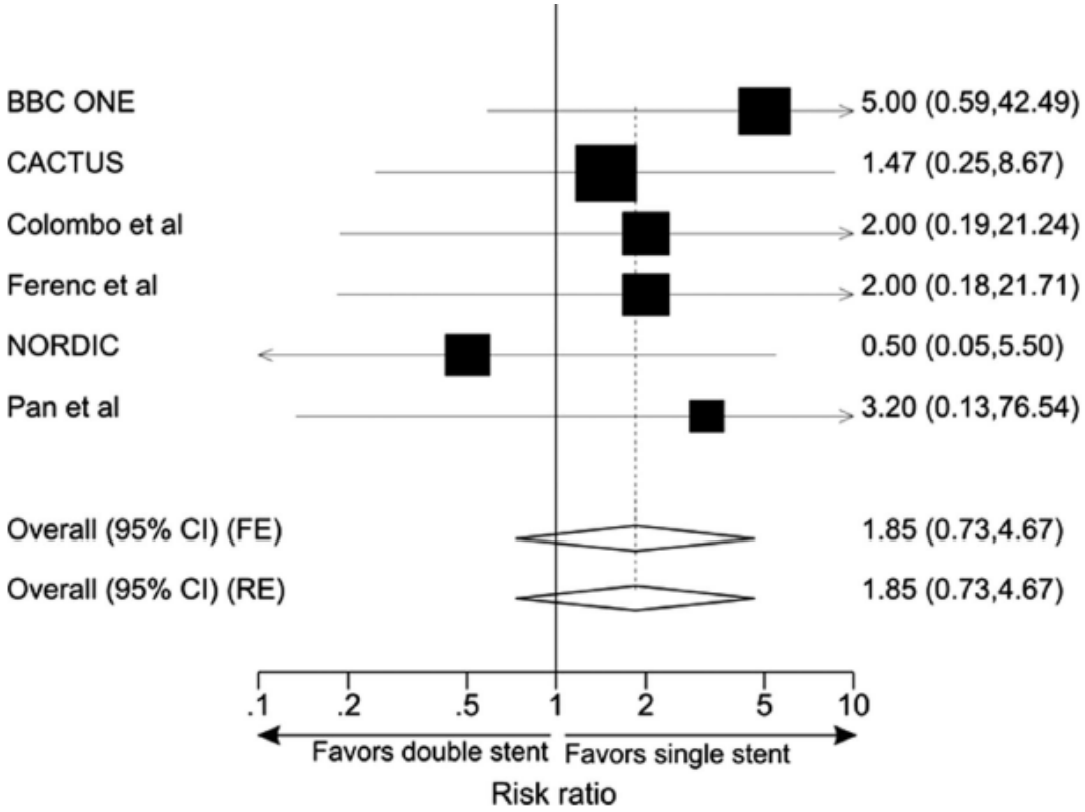

Katritsis, et al. Circ Cardiovasc Interv 2009

Pathologic/IVUS mechanisms of DES ST

- Chronic inflammation
- Stenting along major side branches
- Stenting over major branching points
- Late incomplete apposition
- Post-procedural incomplete apposition with stent underexpansion
- In-stent restenosis
- Strut penetration of necrotic core

Joner, et al. JACC 2006

Fujii, et al. JACC 2005

Okabe, et al. AJC 2007

Excellent results?

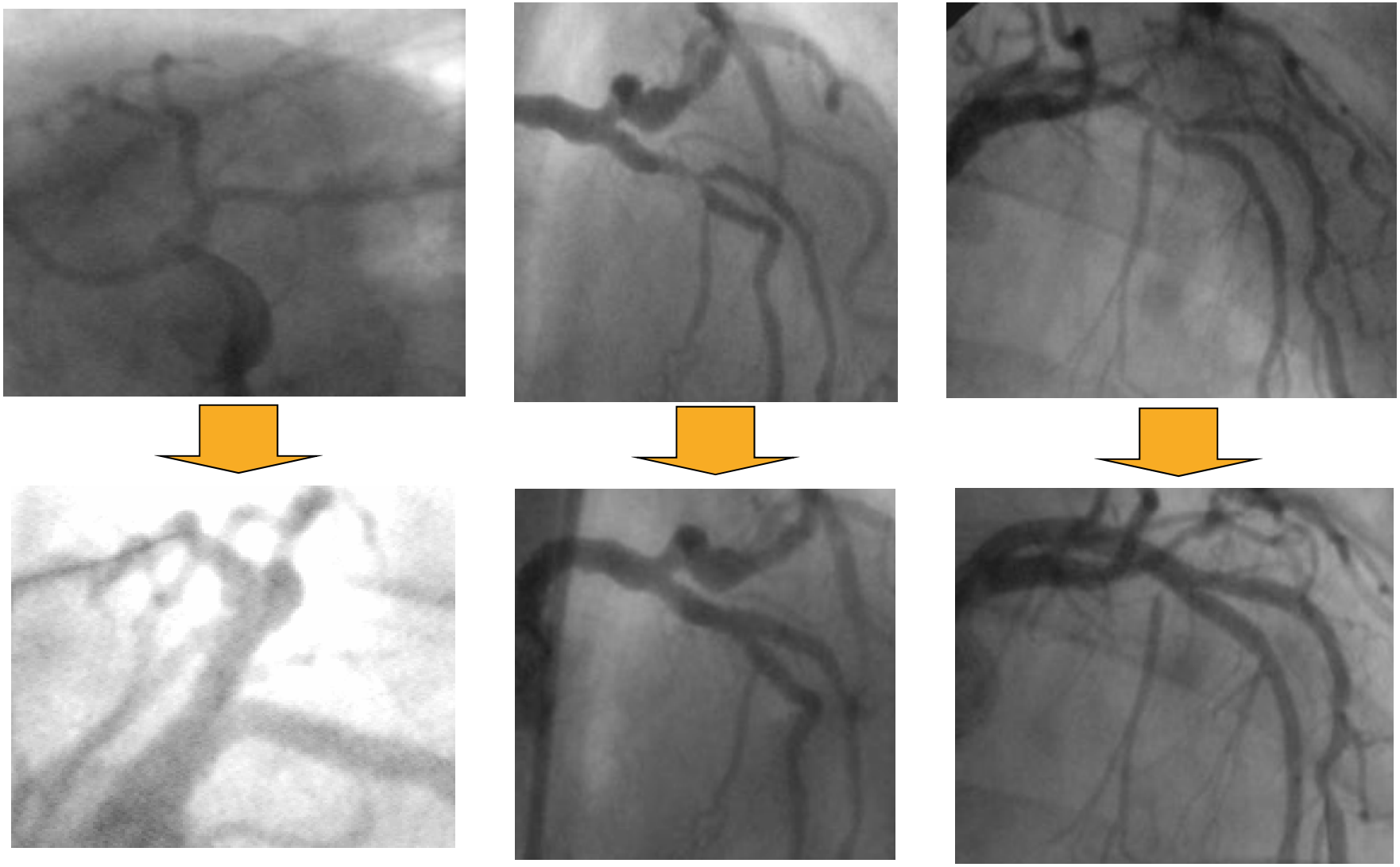

Modified T | Kissing | Crush

Angiographically excellent, but…..

604 Costa *et al.*
Crush Stenting for Bifurcation Lesions

JACC Vol. 46, No. 4, 2005
August 16, 2005:599–605

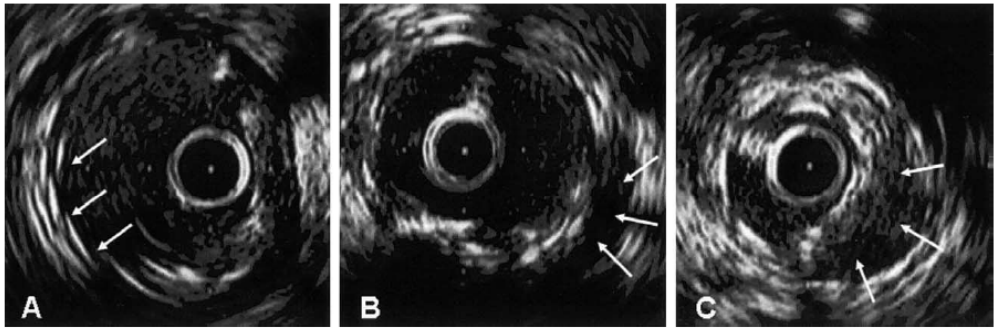

Figure 4. **(A)** Intravascular ultrasound image showing complete crush (apposition) of the side branch (SB) stent; **arrows** indicate the three layers of stent struts. **(B, C)** Intravascular ultrasound images showing incomplete crush (apposition) of the SB stent struts **(arrows)**.

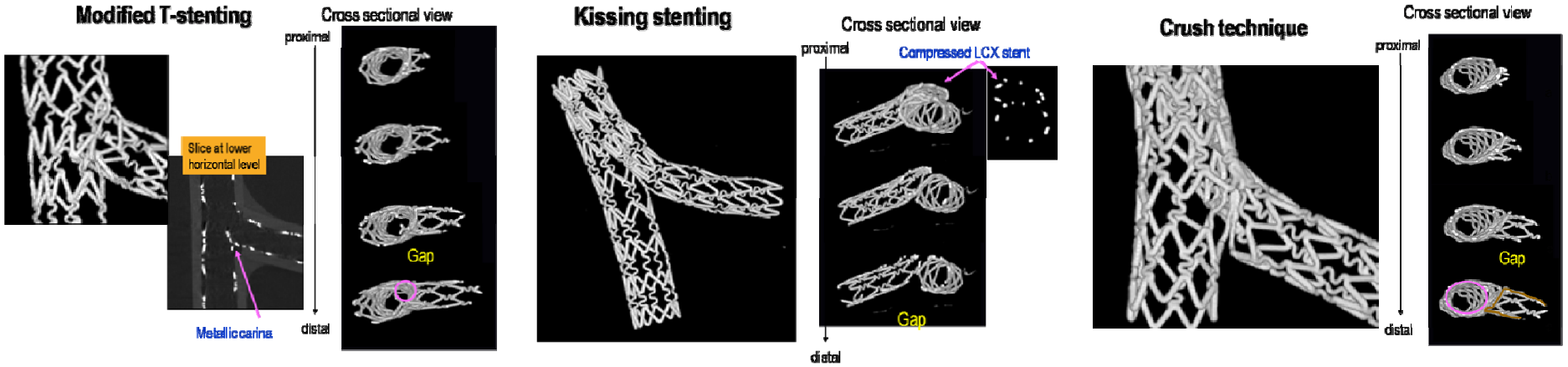

Courtesy of Dr. Murasato, Japan

IVUS-guided PCI for bifurcation lesion may improve outcomes

Long-Term Outcomes of Intravascular Ultrasound-Guided Stenting in Coronary Bifurcation Lesions

Sung-Hwan Kim, MD[a], Young-Hak Kim, MD, PhD[a], Soo-Jin Kang, MD, PhD[a], Duk-Woo Park, MD, PhD[a], Seung-Whan Lee, MD, PhD[a], Cheol Whan Lee, MD, PhD[a], Myeong-Ki Hong, MD, PhD[a], Sang-Sig Cheong, MD, PhD[b], Jae-Joong Kim, MD, PhD[a], Seong-Wook Park, MD, PhD[a], and Seung-Jung Park, MD, PhD[a,*]

Stenting for bifurcation lesions is still challenging, and the effect of intravascular ultrasound (IVUS) guidance on long-term outcomes has not been evaluated. We assessed the long-term outcomes of IVUS-guided stenting in bifurcation lesions. We evaluated 758 patients with de novo nonleft main coronary bifurcation lesions who underwent stent implantation from January 1998 to February 2006. We compared the adverse outcomes (i.e., death, stent thrombosis, and target lesion revascularization) within 4 years, after adjustment using a multivariate Cox proportional hazard model and propensity scoring. IVUS-guided stenting significantly reduced the long-term all-cause mortality (hazard ratio [HR] 0.31, 95% confidence interval [CI] 0.13 to 0.74, p = 0.008) in the total population and in the patients receiving drug-eluting stents (DESs) (HR 0.24, 95% CI 0.06 to 0.86, p = 0.03), but not in the patients receiving bare metal stents (HR 0.41, 95% CI 0.13 to 1.26, p = 0.12). IVUS-guided stenting had no effect on the rate of stent thrombosis (HR 0.48, 95% CI 0.16 to 1.43, p = 0.19) or target lesion revascularization (HR 1.47, 95% CI 0.79 to 2.71, p = 0.21). In patients receiving DESs, however, IVUS guidance reduced the development of very late stent thrombosis (0.4% vs 2.8%, p = 0.03, log-rank test). In conclusion, in patients receiving DESs, IVUS-guided stenting for treatment of bifurcation lesions significantly reduced the 4-year mortality compared to conventional angiographically guided stenting. In addition, IVUS guidance reduced the development of very late stent thrombosis in patients receiving DESs. (Am J Cardiol 2010;106:612–618)

Impact of intravascular ultrasound guidance on long-term clinical outcomes in patients treated with drug-eluting stent for bifurcation lesions: Data from a Korean multicenter bifurcation registry

Jung-Sun Kim, MD, PhD,[a] Myeong-Ki Hong, MD, PhD,[a,1] Young-Guk Ko, MD, PhD,[a] Donghoon Choi, MD, PhD,[a] Jung Han Yoon, MD, PhD,[b] Seung-Hyuk Choi, MD, PhD,[c] Joo-Yong Hahn, MD, PhD,[c] Hyeon-Cheol Gwon, MD, PhD,[c] Myung-Ho Jeong, MD, PhD,[d] Hyo-Soo Kim, MD, PhD,[e] In-Whan Seong, MD, PhD,[f] Joo-Young Yang, MD, PhD,[g] Seung Woon Rha, MD, PhD,[h] Seung-Jea Tahk, MD, PhD,[i] Ki Bae Seung, MD, PhD,[j] Seung-Jung Park, MD, PhD,[k] and Yangsoo Jang, MD, PhD[a,1] *Seoul, Wonju, Gwangju, Daejeon, Goyang, and Suwon, Korea*

Background Although intravascular ultrasound (IVUS) has been widely used for complex lesions during coronary intervention, IVUS for stenting at bifurcation lesions has not been sufficiently assessed. The aim of this study was to investigate the impact of IVUS guidance on long-term clinical outcomes during drug-eluting stent (DES) implantation for bifurcation lesions.

Methods The Korean multicenter bifurcation registry listed 1,668 patients with non-left main de novo bifurcation lesions who underwent DES implantation between January 2004 and June 2006. Using propensity score matching with clinical and angiographic characteristics, 487 patients with IVUS guidance and 487 patients with angiography guidance were selected. The long-term clinical outcomes were compared between the 2 groups.

Results Baseline clinical and angiographic characteristics were well matched and showed no significant differences between the 2 groups. Two-stent technique and final kissing ballooning angioplasty were more frequently performed in the IVUS-guided group. Maximal stent diameters at both the main vessel and the side branch were larger in the IVUS-guided group. Periprocedural creatine kinase–MB elevation (>3 times of upper normal limits) was frequently observed in the angiography-guided group. The incidence of death or myocardial infarction was significantly lower in the IVUS-guided group compared to the angiography-guided group (3.8% vs 7.8%, log rank test $P = .03$, hazard ratio 0.44, 95% CI 0.12-0.96, Cox model $P = .04$).

Conclusions Intravascular ultrasound guidance during DES implantation at bifurcation lesions may be helpful to improve long-term clinical outcomes by reducing the occurrence of death or myocardial infarction. (Am Heart J 2011;161:180-7.)

In conclusion, IVUS-guided stenting for bifurcation lesions significantly reduced the 4-year mortality compared to conventional angiographically guided stenting.

CONCLUSIONS:
IVUS guidance during DES implantation at bifurcation lesions may be helpful to improve long-term clinical outcomes by reducing the occurrence of death or myocardial infarction

IVUS-guided PCI for bifurcation lesion may improve outcomes

Impact of Intravascular Ultrasound Guidance on Long-Term Mortality in Stenting for Unprotected Left Main Coronary Artery Stenosis

Seung-Jung Park, MD, PhD*; Young-Hak Kim, MD, PhD*; Duk-Woo Park, MD, PhD; Seung-Whan Lee, MD, PhD; Won-Jang Kim, MD, PhD; Jon Suh, MD; Sung-Cheol Yun, PhD; Cheol Whan Lee, MD, PhD; Myeong-Ki Hong, MD, PhD; Jae-Hwan Lee, MD, PhD; Seong-Wook Park, MD, PhD; for the MAIN-COMPARE Investigators

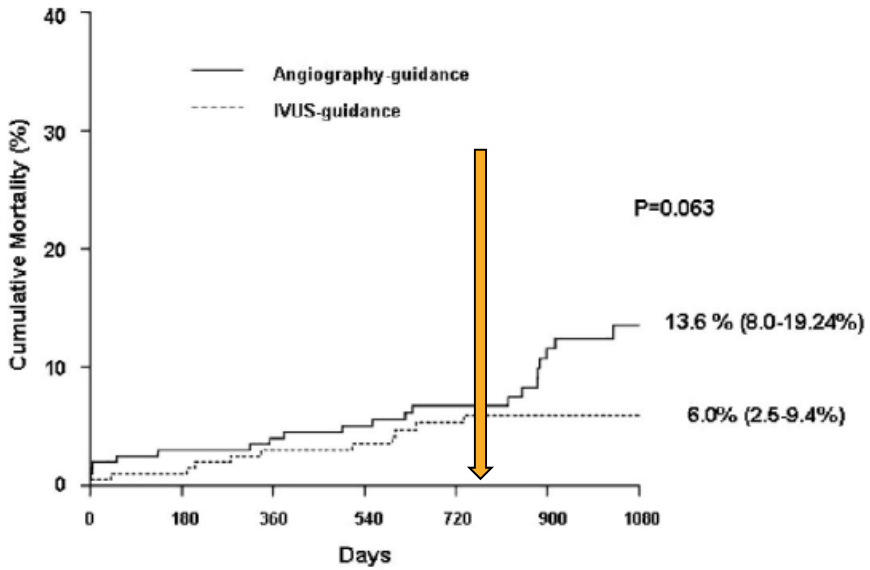

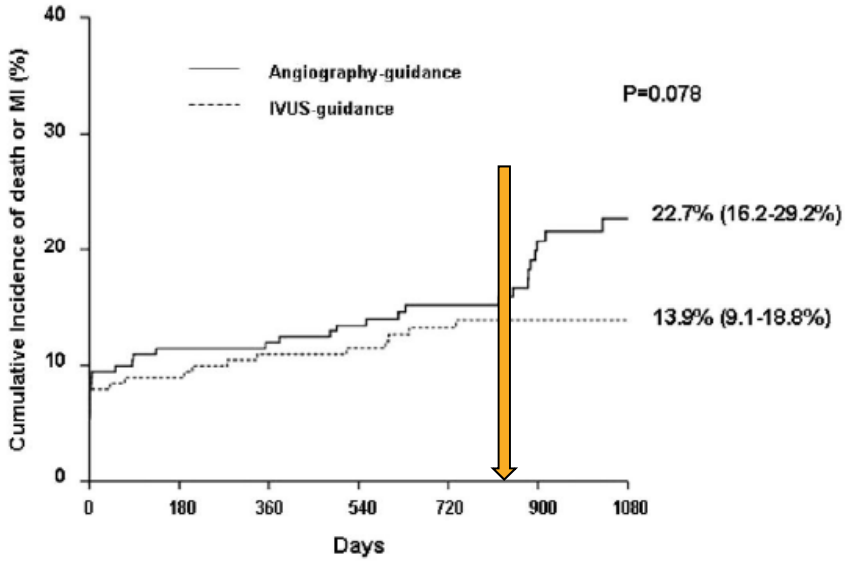

Park SJ, et al. Circ Cardiovasc Interv 2009

Predictors of restenosis and stent thrombosis in bifurcation PCI

- In-stent restenosis: How frequent and Why?
- In-stent restenosis: Stenosis vs. Clinical relevance
- Stent thrombosis in bifurcation PCI
- Stent thrombosis: Lumen vs. Flow

Cardiology Is Flow

Yoram Richter, PhD; Elazer R. Edelman, MD, PhD

Panta rhei. *(Everything flows).*[1]

Cardiology is about flow. The primary purpose of the

rosis. Flow disturbances are therefore ubiquitous; they are a fundamental feature of the vascular system. An entire field of study arose correlating disease with its overlying flow pat-

Circulation 2006

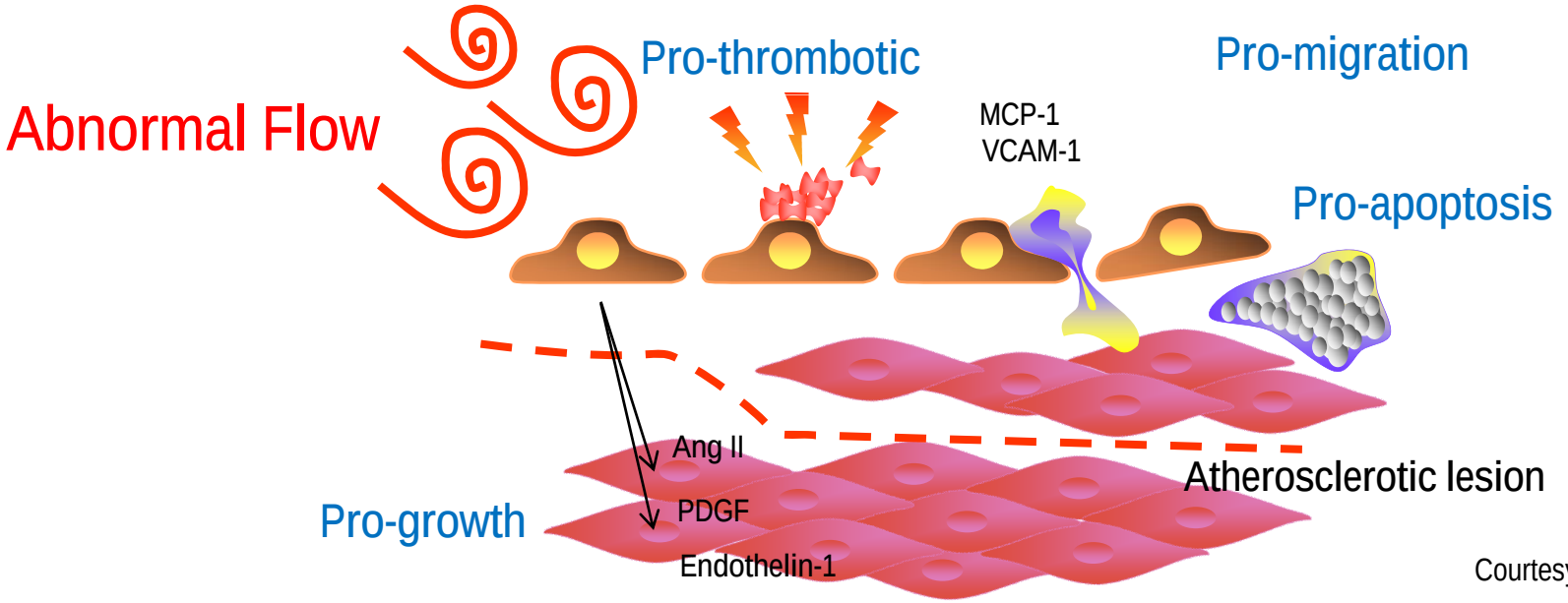

Courtesy of Dr. Finet

Recirculating zone and/or abnormal shear stress → Inflammation, Proliferation, Thrombosis

Keeping the natural laws to minimize the flow disturbance

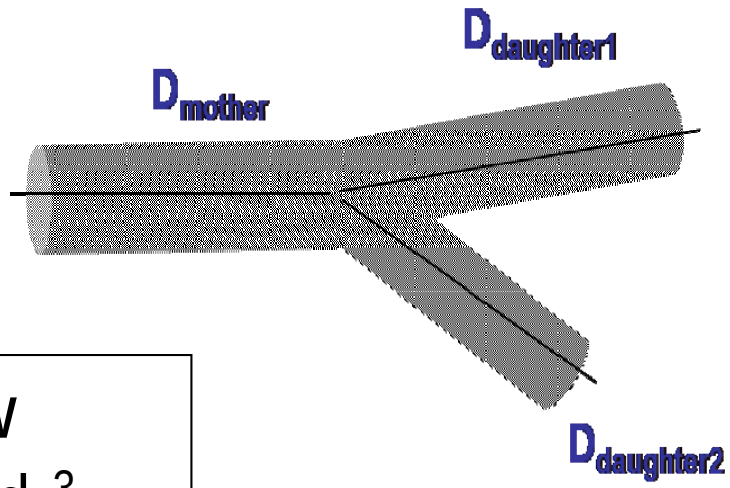

Murray's law

$$D_m^3 = Dd_1^3 + Dd_2^3$$

Kassab's

$$D_m^{2.2} = Dd_1^{2.2} + Dd_2^{2.2}$$

Finet's law

$$D_m = 0.678\,(Dd_1 + Dd_2)$$

Area conservation

$$D_m^2 = Dd_1^2 + Dd_2^2$$

Under-expansion

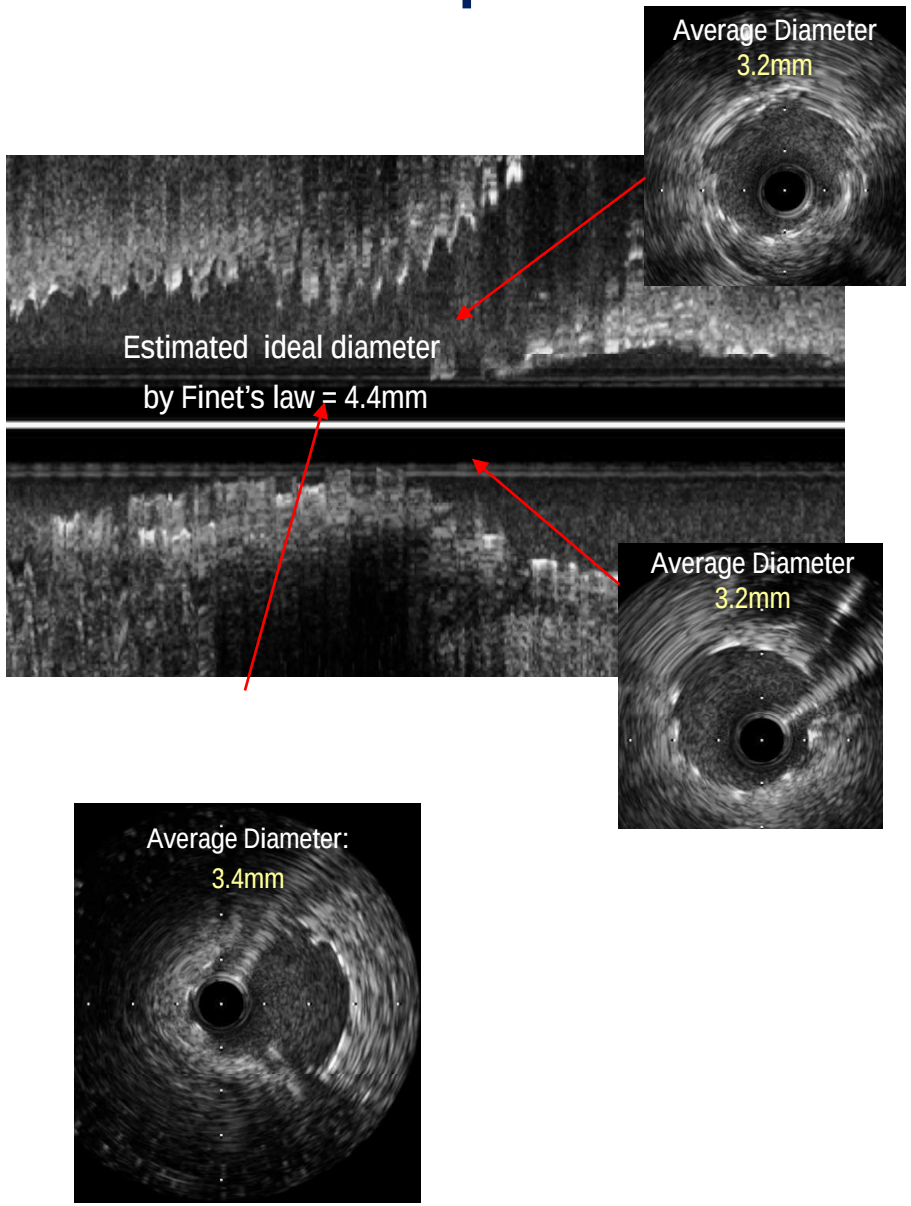

Over-expansion

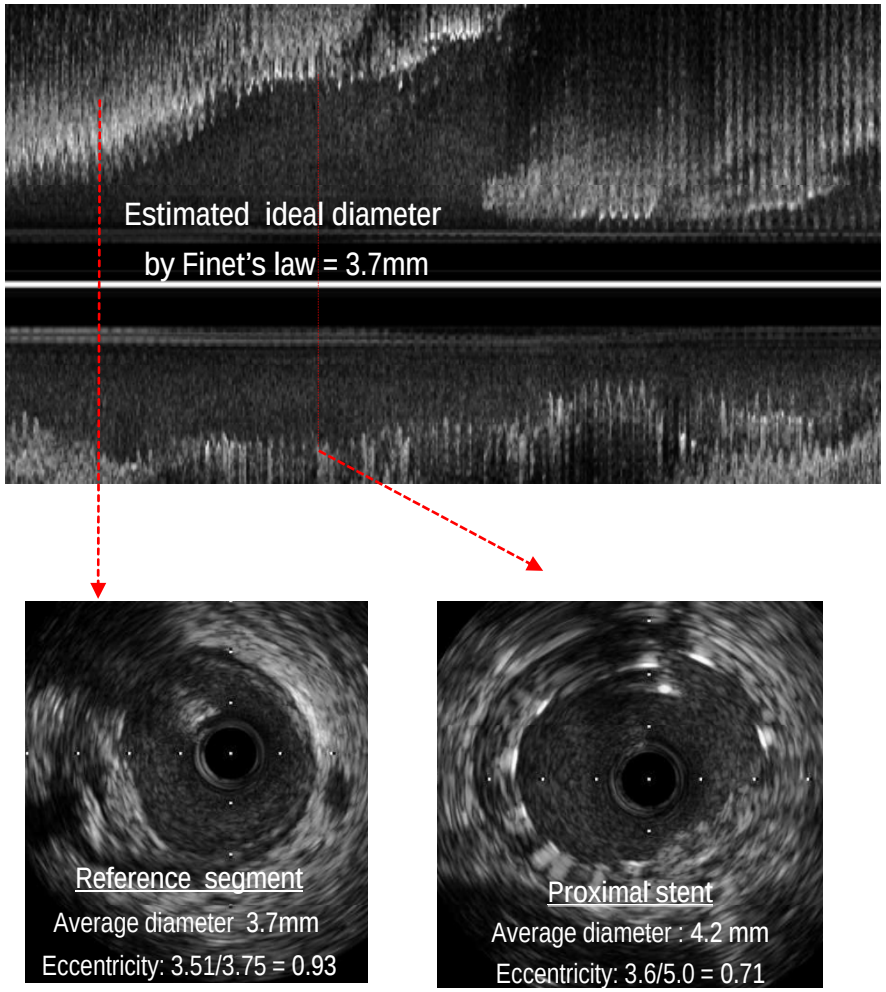

Optimized vs. Non-optimized

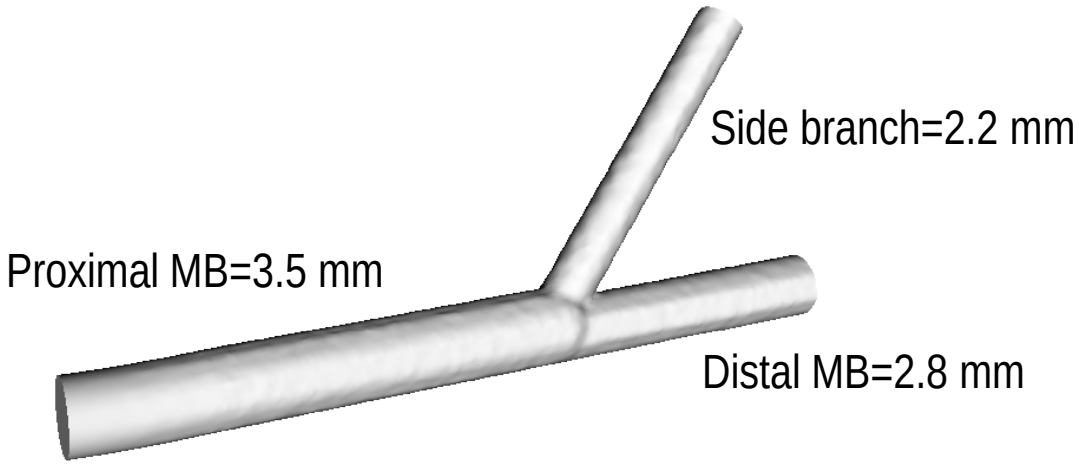

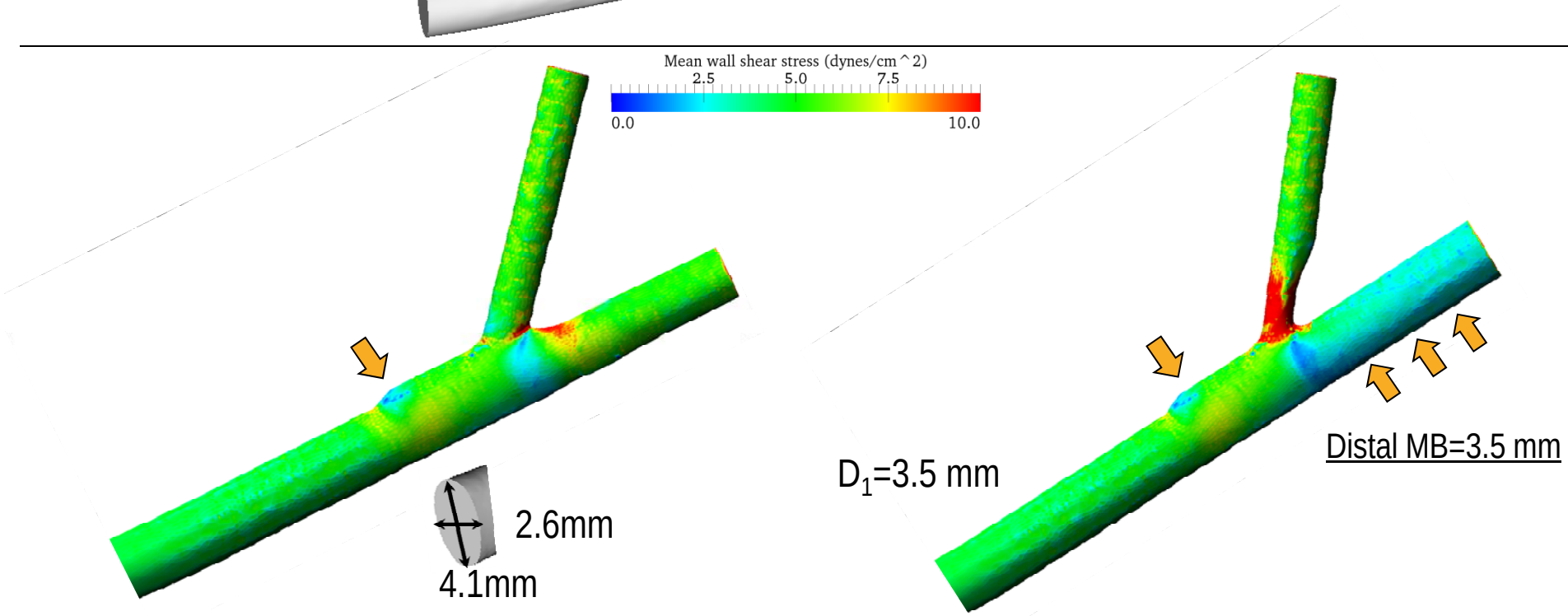

Koo BK and Taylor C. European Bifurcation Club 2010

Restenosis and Stent thrombosis in bifurcations

- Restenosis and stent thrombosis are more frequent in bifurcation lesions.
- Inadequate lumen area, complex procedures and un-natural bifurcation geometry are the main predictors of restenosis and stent thrombosis.
- Understanding the clinical relevance of a stenosis and keeping the "natural bifurcation laws" after PCI may be the key to improve the patients' outcomes.