Debate: Functional Evaluation is Necessary

Yes, We Need a Function-guidance

Bon-Kwon Koo, MD, PhD

Seoul National University Hospital, Seoul, Korea

What is a significant stenosis?

: Anatomy

- Stenosis severity by angiography, IVUS, OCT .....

Same stenosis, same significance ?

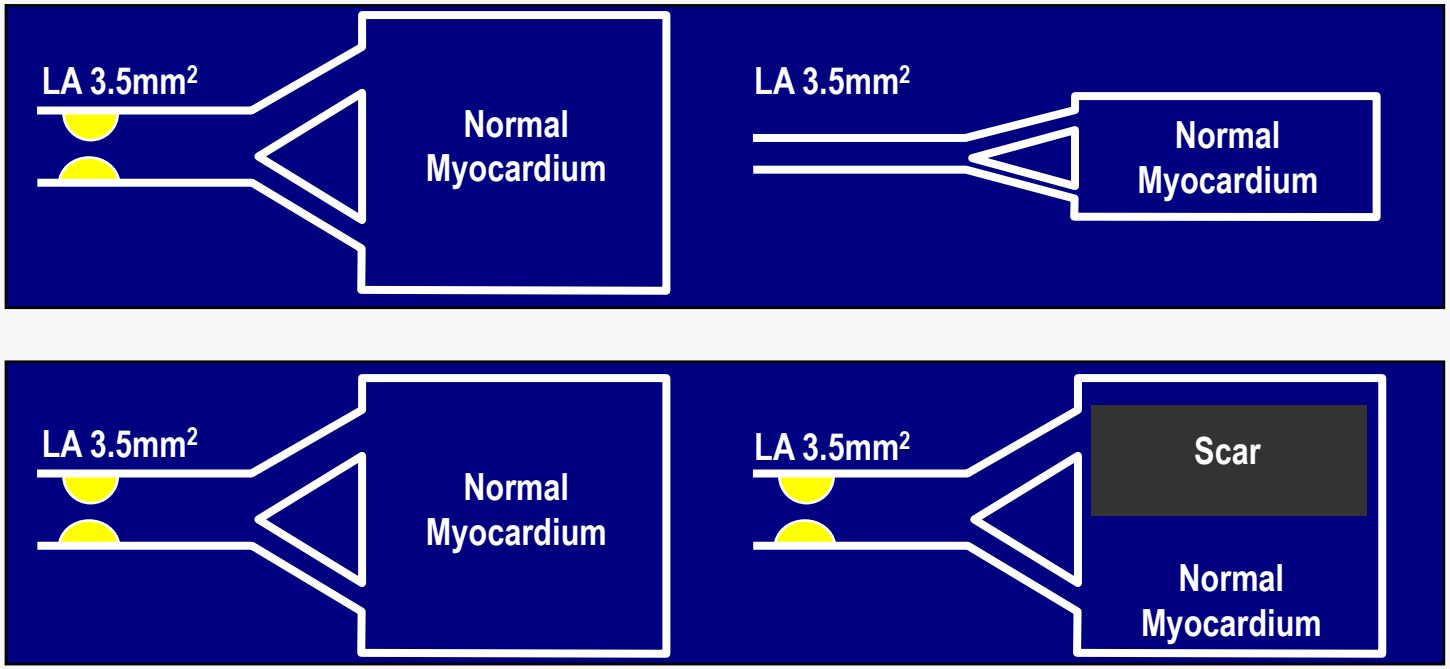

LA: Lumen cross sectional area

Same stenosis can have a different physiological or functional significance according to lesion characteristics.

Same stenosis, same significance ?

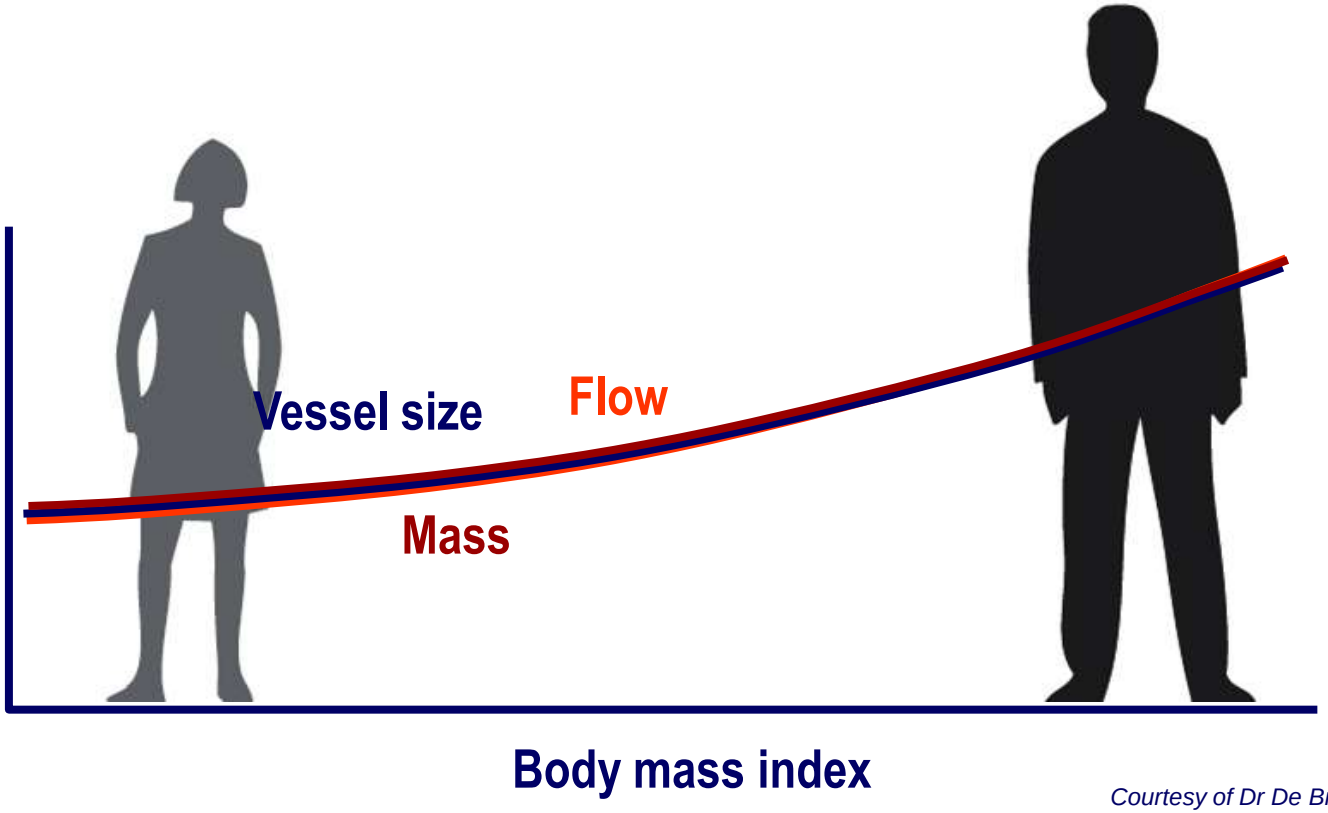

Courtesy of Dr De Bruyne

Same stenosis can have a different physiological or functional significance according to **patient** characteristics.

What is a significant stenosis?

: Anatomy *vs. Ischemia*

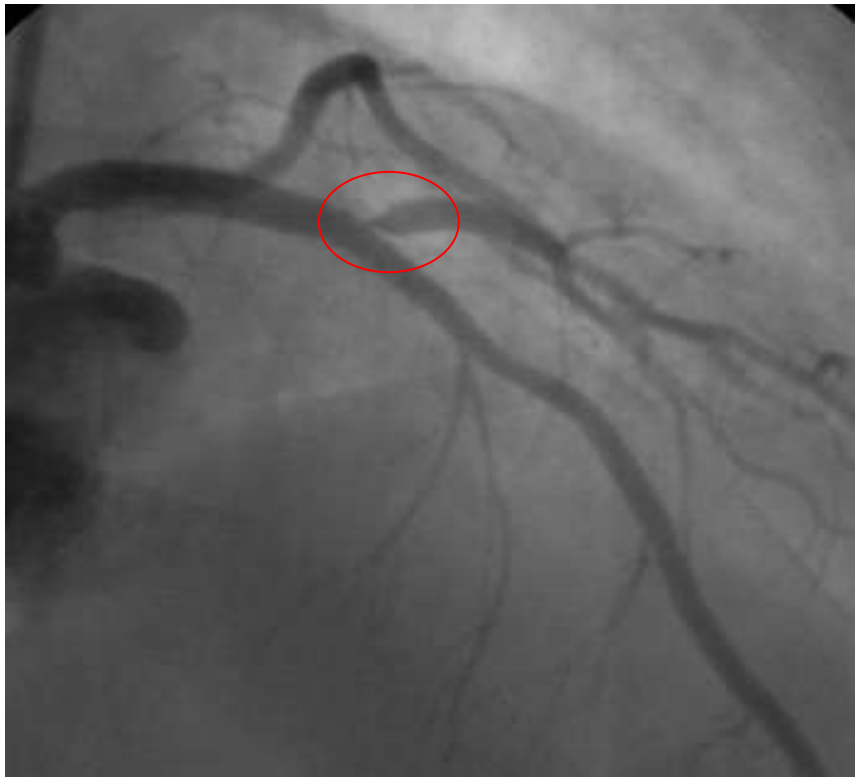

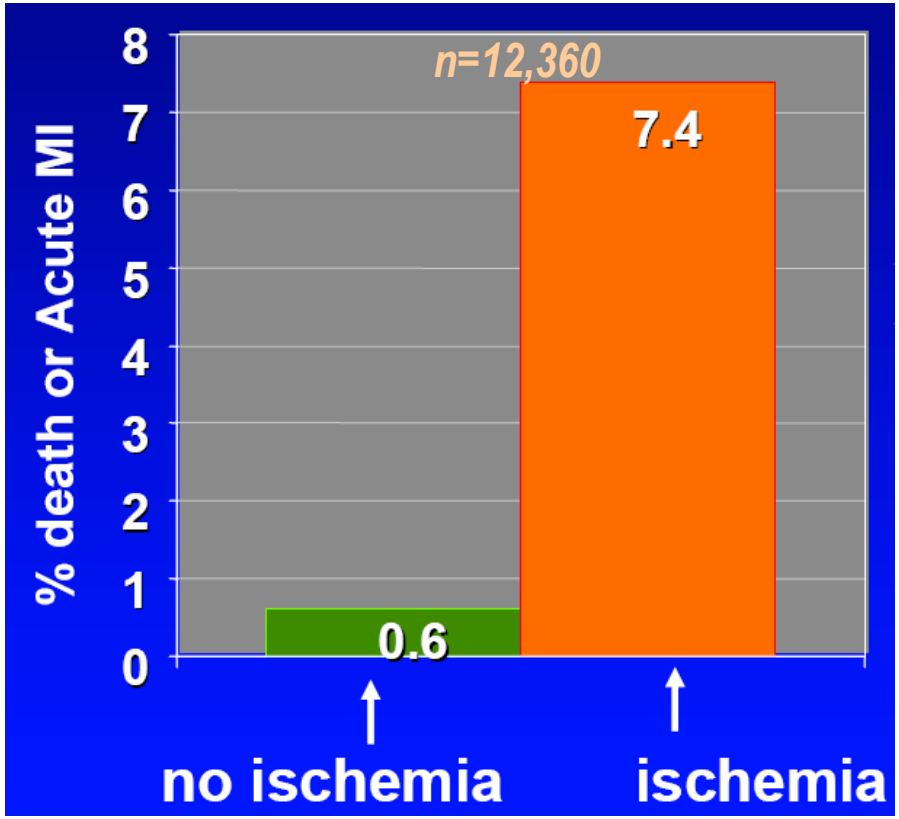

Iskander, et al. JACC 1998

Determinants of a significant stenosis?

: Anatomy ***vs. Ischemia***

- Stenosis severity by angiography, IVUS, OCT, ...
- Extent of the perfusion territory (lesion location, height, weight, gender, age…..)
- Presence of myocardial infarction
- Myocardial blood flow including collaterals
- Microvascular function

→ ***Physiological or functional evaluation***

"Fractional Flow Reserve (FFR)"

- Invasive functional test in a cath lab with very high spatial resolution

$$FFR = \frac{\text{Maximum flow in presence of stenosis}}{\text{Normal maximum flow}} = \frac{Q^{S}_{max}}{Q^{N}_{max}} = \frac{(Pd-Pv)/R}{(Pa-Pv)/R} = \frac{\text{Distal Pr } (P_d)}{\text{Proximal Pr } (P_a)}$$

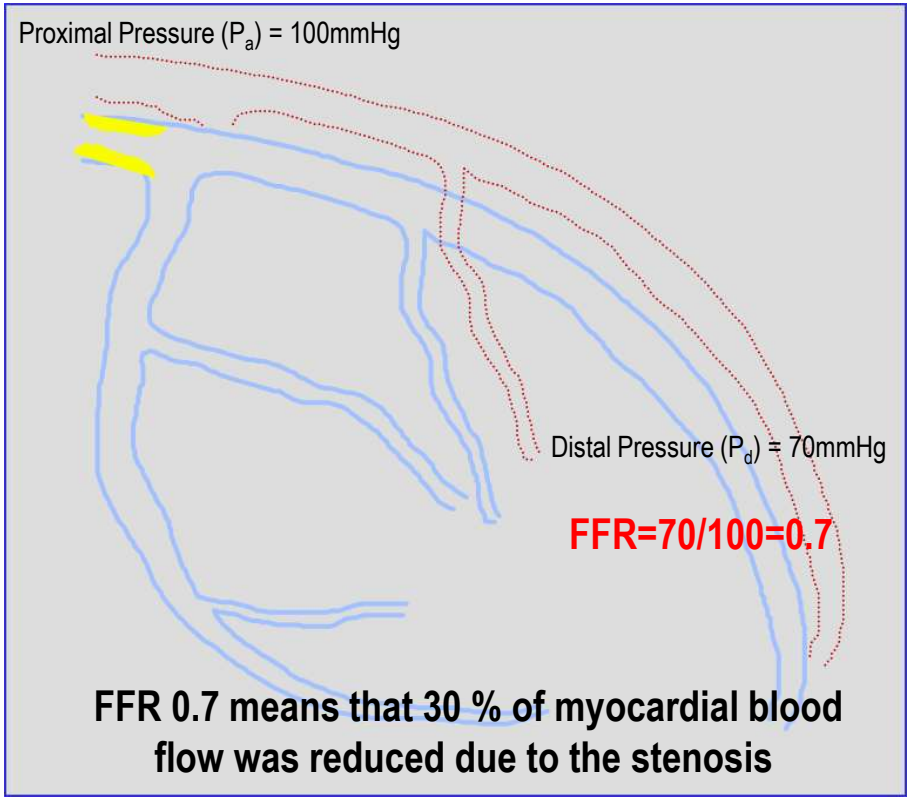

Evidences……

The NEW ENGLAND JOURNAL of MEDICINE

JANUARY 15, 2009

Fractional Flow Reserve versus Angiography for Guiding Percutaneous Coronary Intervention

The NEW ENGLAND JOURNAL of MEDICINE

SEPTEMBER 13, 2012

Fractional Flow Reserve–Guided PCI versus Medical Therapy in Stable Coronary Disease

Journal of the American College of Cardiology
© 2005 by the American College of Cardiology Foundation
Published by Elsevier Inc.

Interventional Cardiol

Long-Term Clinical Outcome After Fractional Flow Reserve-Guided Percutaneous Coronary Intervention in Patients With Multivessel Disease

Alexandre Berger, MD,* Kees-Joost Botman, MD,* Philip A. MacCarthy, MD, PhD, MRCP,* William Wijns, MD, PhD,* Jozef Bartunek, MD, PhD,* Guy R. Heyndrickx, MD, PhD,* Nico H. J. Pijls, MD, PhD,† Bernard De Bruyne, MD, PhD*
Aalst, Belgium; and Eindhoven, the Netherlands

Coronary Pressure Measurement After Stenting Predicts Adverse Events at Follow-Up

A Multicenter Registry

Nico H.J. Pijls, MD, PhD; Volker Klauss, MD; Uwe Siebert, MPh, MSc; Eric Powers, MD; Kenji Takazawa, MD; William F. Fearon, MD; Javier Escaned, MD; Yukio Tsurumi, MD; Takashi Akasaka, MD; Habib Samady, MD; Bernard De Bruyne, MD, PhD; for the Fractional Flow Reserve (FFR) Post-Stent Registry Investigators

Reliability of Pressure-Derived Myocardial Fractional Flow Reserve in Assessing Coronary Artery Stenosis in Patients With Previous Myocardial Infarction

Yasuhiro Usui, MD, Taishiro Chikamori, MD, Hidefumi Yanagisawa, MD, Takayuki Morishima, MD, Satoshi Hida, MD, Nobuhiro Tanaka, MD, Kenji Takazawa, MD, and Akira Yamashina, MD

Clinical Significance of Fractional Flow Reserve for Evaluation of Functional Lesion Severity in Stent Restenosis and Native Coronary Arteries*

Stefan Krüger, MD; Karl-Christian Koch, MD; Ira Kaumanns, MD; Marc W. Merx, MD; Peter Hanrath, MD; and Rainer Hoffmann, MD

Journal of the American College of Cardiology
© 2005 by the American College of Cardiology Foundation
Published by Elsevier Inc.
Vol. 46, No. 4, 2005
ISSN 0735-1097/05/$30.00
doi:10.1016/j.jacc.2005.04.054

Physiologic Assessment of Jailed Side Branch Lesions Using Fractional Flow Reserve

Bon-Kwon Koo, MD, PhD,* Hyun-Jai Kang, MD, PhD,* Tae-Jin Youn, MD, PhD,† In-Ho Chae, MD, PhD,† Dong-Joo Choi, MD, PhD,† Hyo-Soo Kim, MD, PhD,* Dae-Won Sohn, MD, PhD,* Byung-Hee Oh, MD, PhD, FACC,* Myoung-Mook Lee, MD, PhD, FACC,* Young-Bae Park, MD, PhD,* Yun-Shik Choi, MD, PhD,* Seung-Jae Tahk, MD, PhD‡
Seoul, Seongnam, Gyeonggi-

Interventional Cardiology

Clinical outcome in patients with intermediate equivocal left main coronary artery disease a deferral of surgical revascularization on the basis of fractional flow reserve measurements

Michael Lindstaedt, MD,[a] Aydan Yazar, MD,[a] Alfried Germing, MD,[a] Markus K. Fritz, MD,[b] Tim Holland-Letz, MSc,[c] Andreas Mügge, MD,[a] and Waldemar Bojara, MD[a] *Bochum, Germany*

Physiological evaluation of the provisional side-branch intervention strategy for bifurcation lesions using fractional flow reserve

Bon-Kwon Koo[1], Kyung-Woo Park[1], Hyun-Jae Kang[1], Young-Seok Cho[2], Woo-Young Chung[2], Tae-Jin Youn[2], In-Ho Chae[2], Dong-Ju Choi[2], Seung-Jae Tahk[2], Byung-Hee Oh[1], Young-Bae Park[1] and Hyo-Soo Kim[1†]

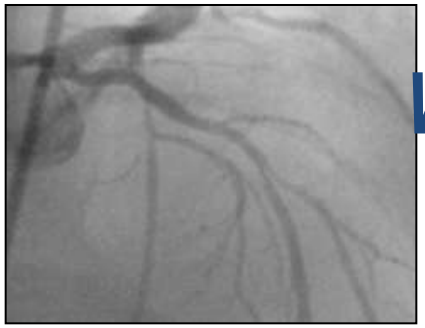

Why FFR in bifurcation lesion?

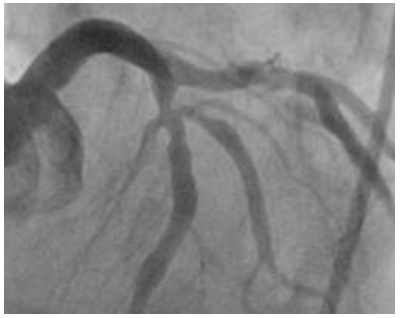

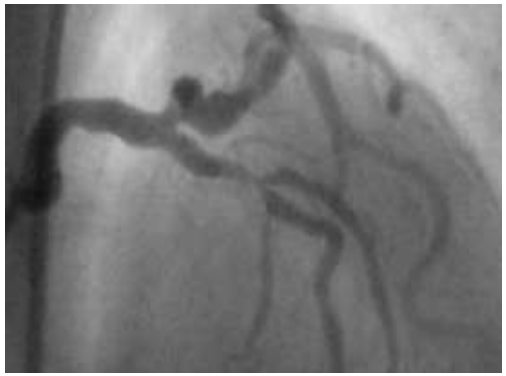

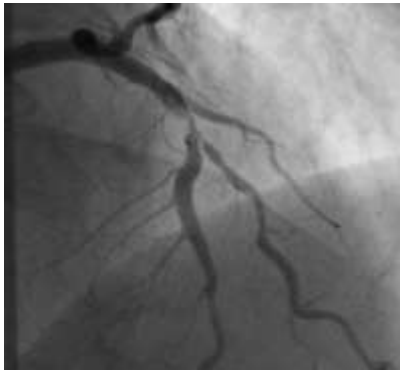

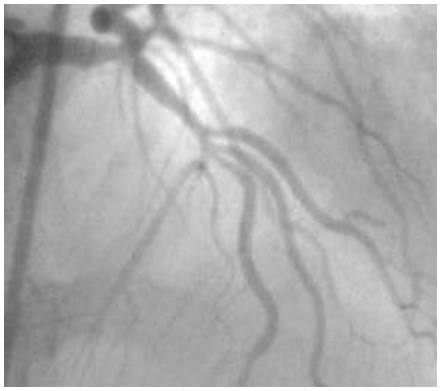

Pitfalls of anatomical evaluation

- Angiography
  - Single directional assessment
  - Variability in stenosis assessment
  - No validated criteria for side branch intervention
  - Not physiologic
- IVUS/OCT
  - Difficult to perform in tight stenosis (ex. Jailed side branch)
  - No validated criteria for side branch intervention
  - Not physiologic

True vs. Pseudo-stenosis

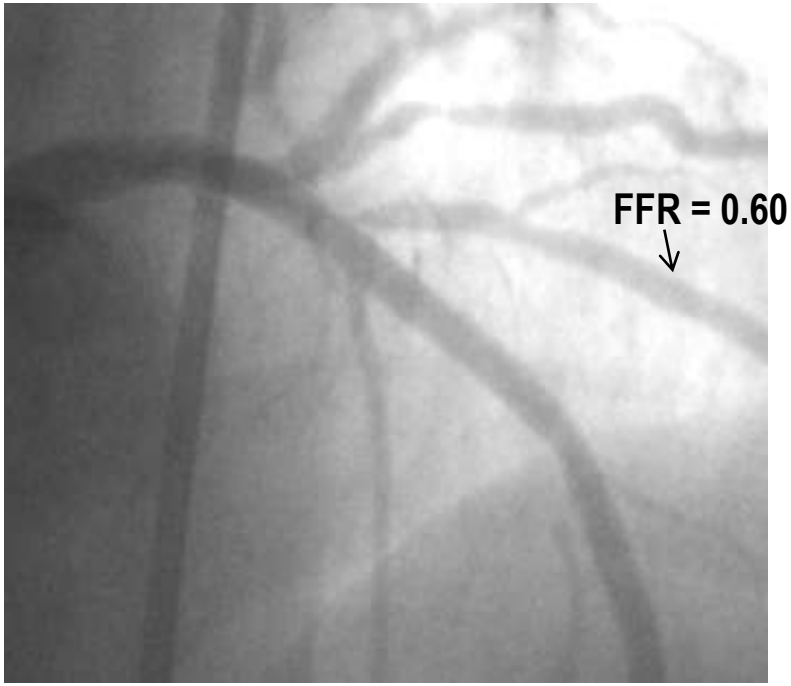

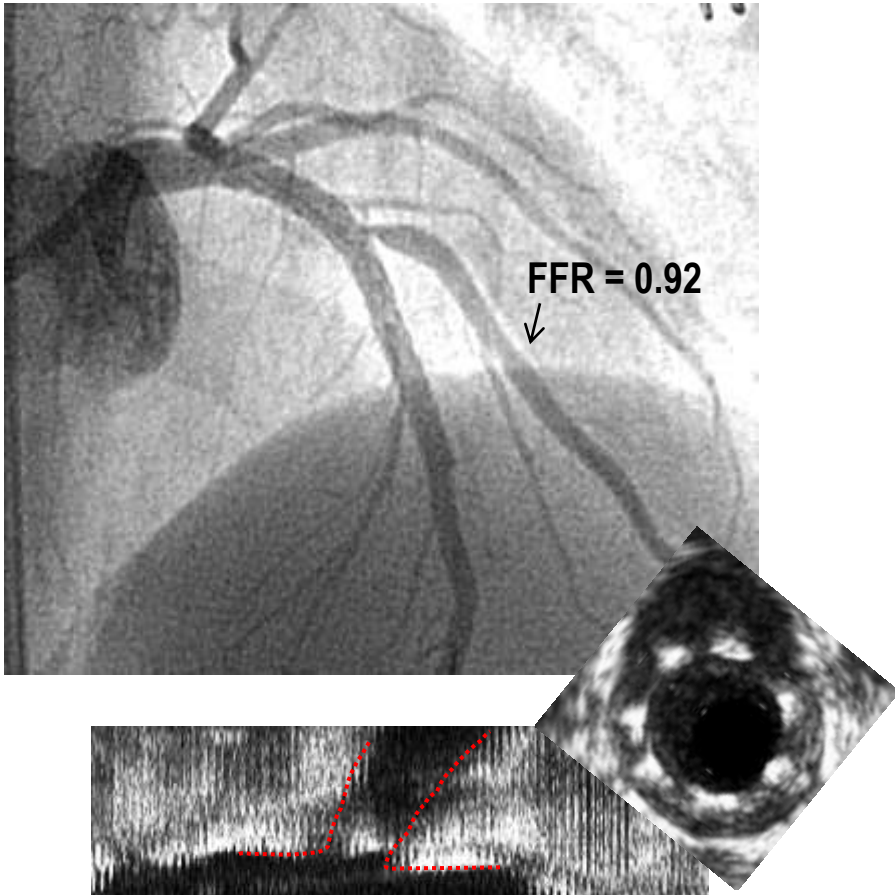

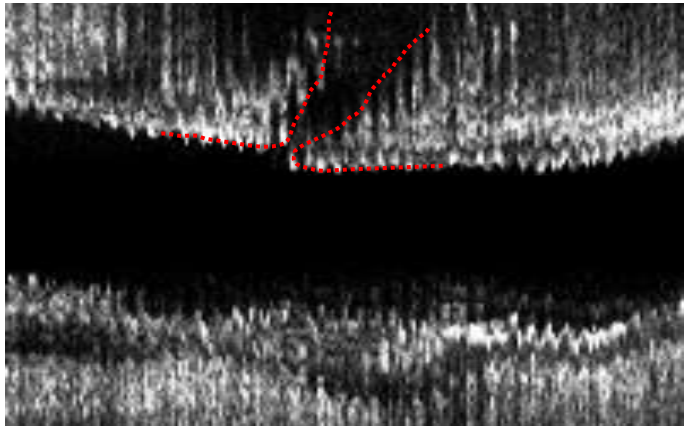

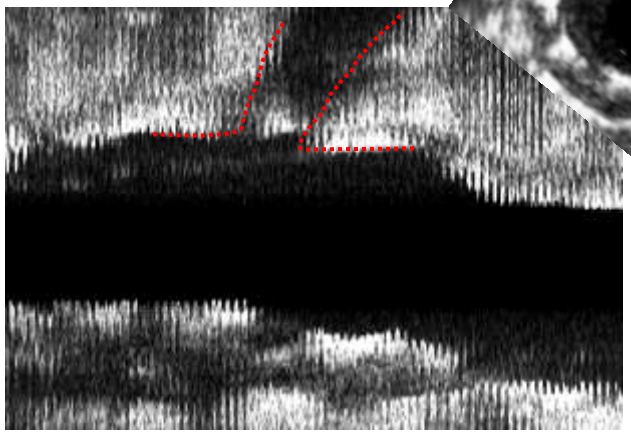

Uniqueness of side branch lesions

- Various size, various amount of supplying myocardium
- Side branch ostial lesion is **unique**
  - Underlying plaque → **Eccentric plaque**
  - Remodeling → **Negative remodeling**
  - Mechanisms of ostial narrowing after main branch stenting

    Carina shift, plaque shift, stent struts, thrombus…..

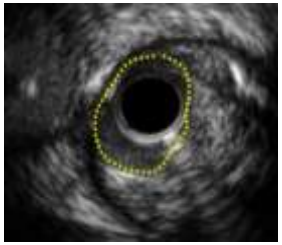

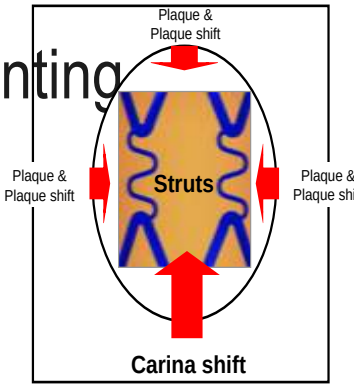

Koo BK. et al, Circ Cardiovasc Interv 2010

Ostial lesions

Angiographic severity ≠ Functional significance

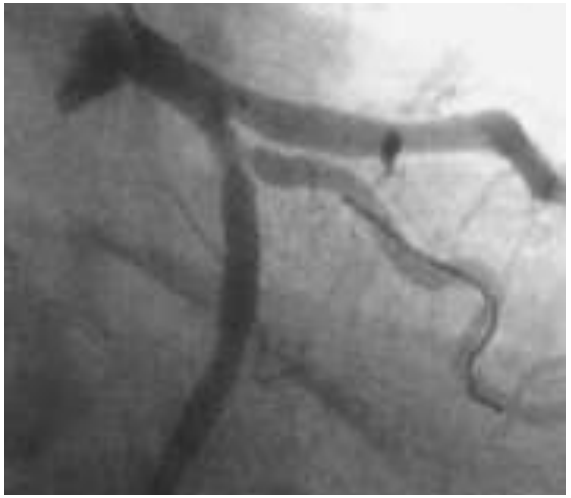

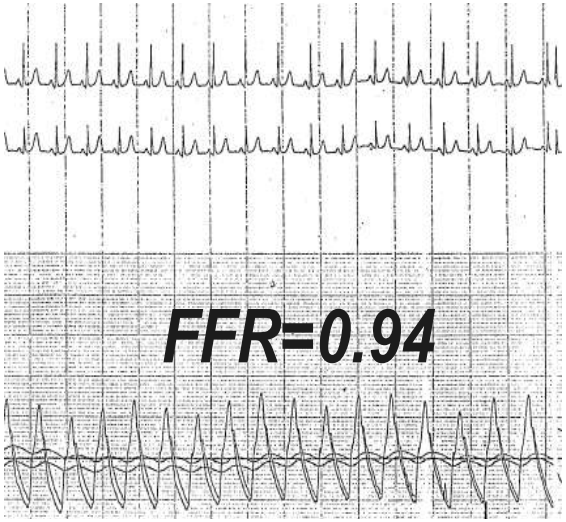

FFR	≥70% Angiographic Stenosis	50%–70% Angiographic Stenosis
≥0.75	20	30
<0.75	5	0

Sensitivity 100%, specificity 55%, and test accuracy 60%.

Ziaee A, et al. AJC 2004

Bifurcation lesion?

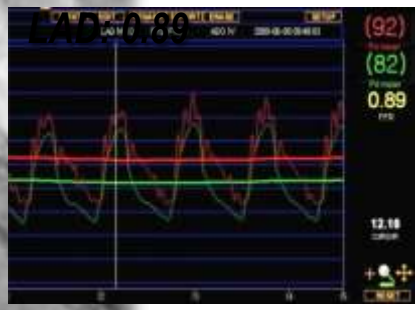

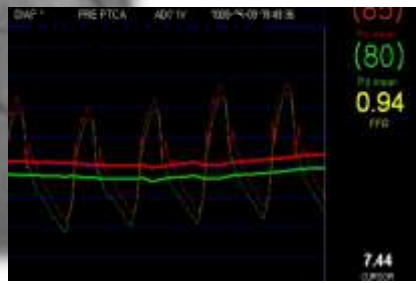

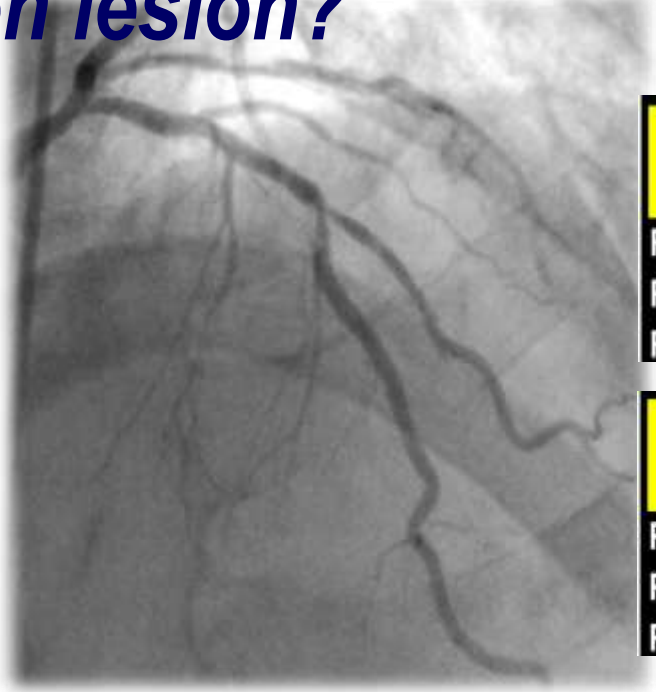

LAD: 0.82	
Pa:iPa	67: 91
Pd:iPd	55: 86
Pd/Pa	0.82

Diag: 0.98	
Pa:iPa	66: 78
Pd:iPd	65: 75
Pd/Pa	0.98

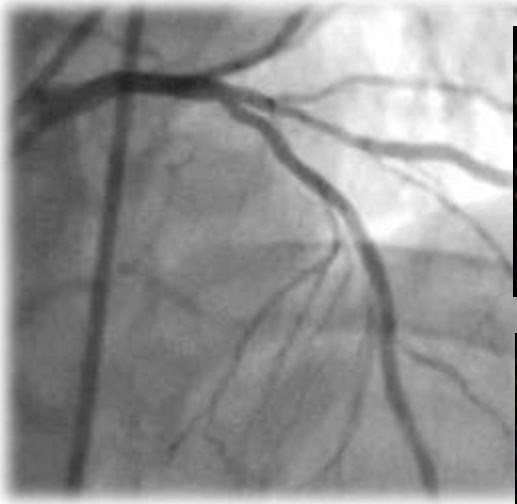

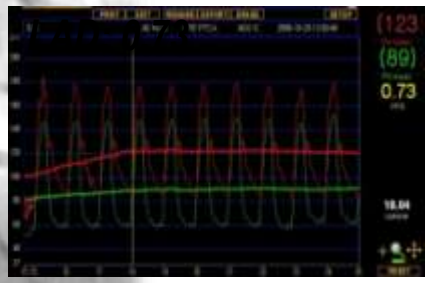

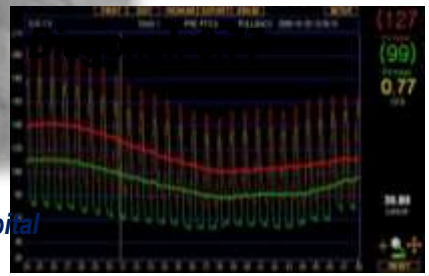

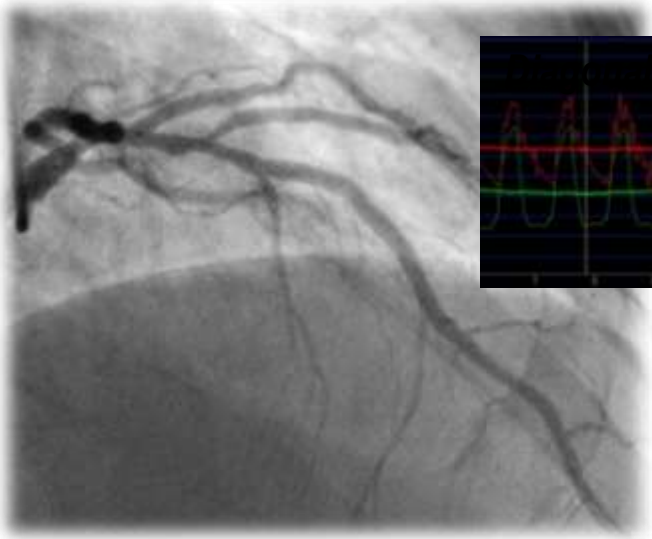

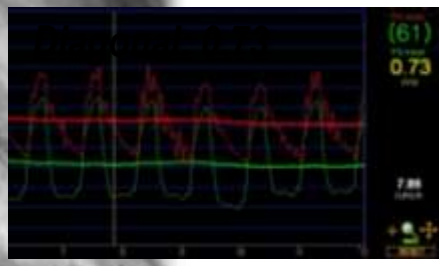

Medina 0,0,1 lesion?

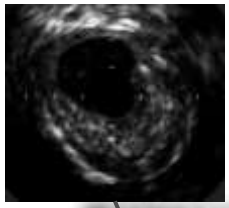

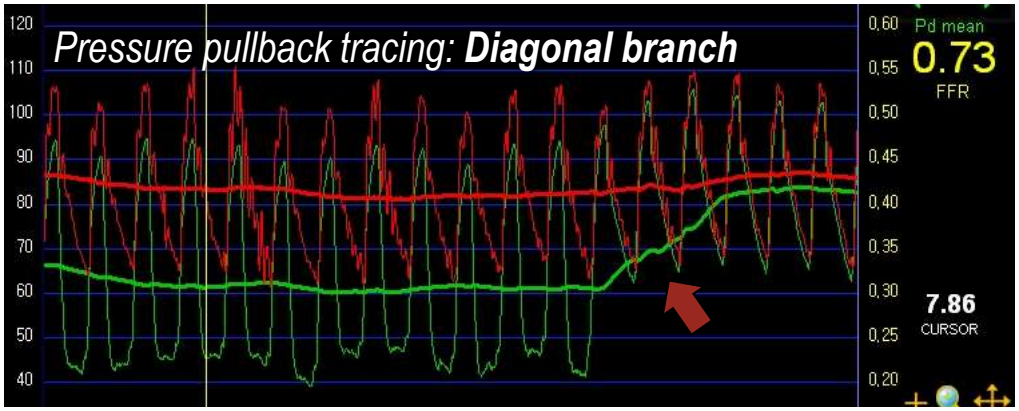

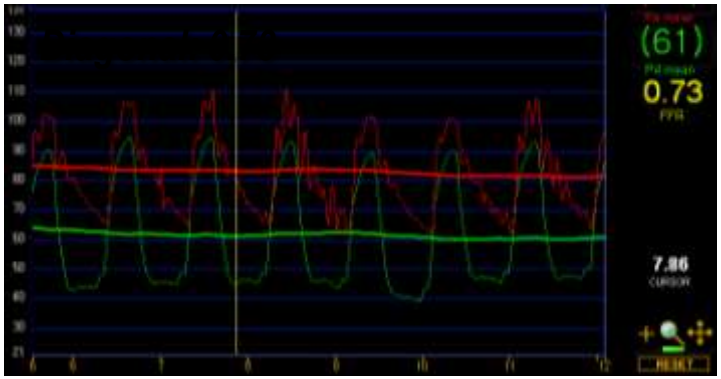

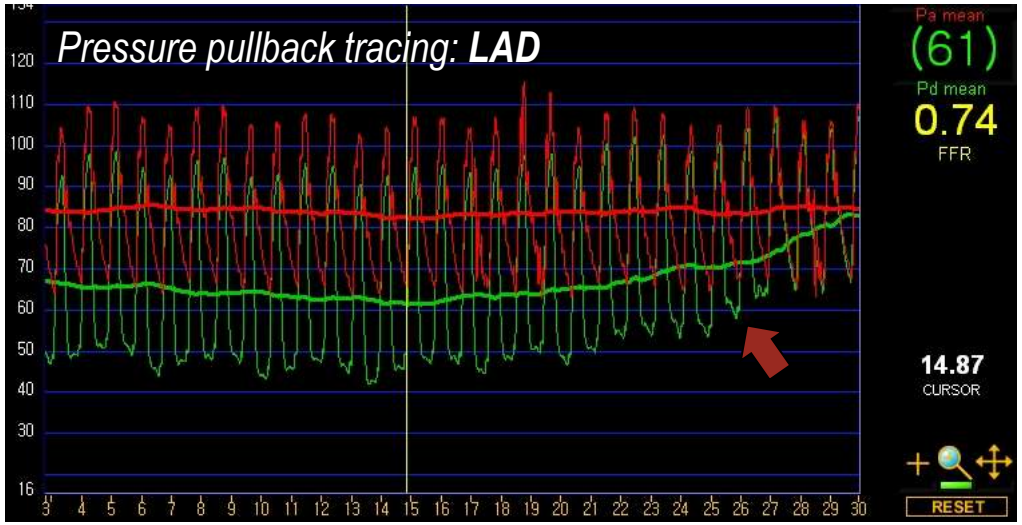

Diagnostic accuracy of angio/IVUS parameters in pure ostial lesions

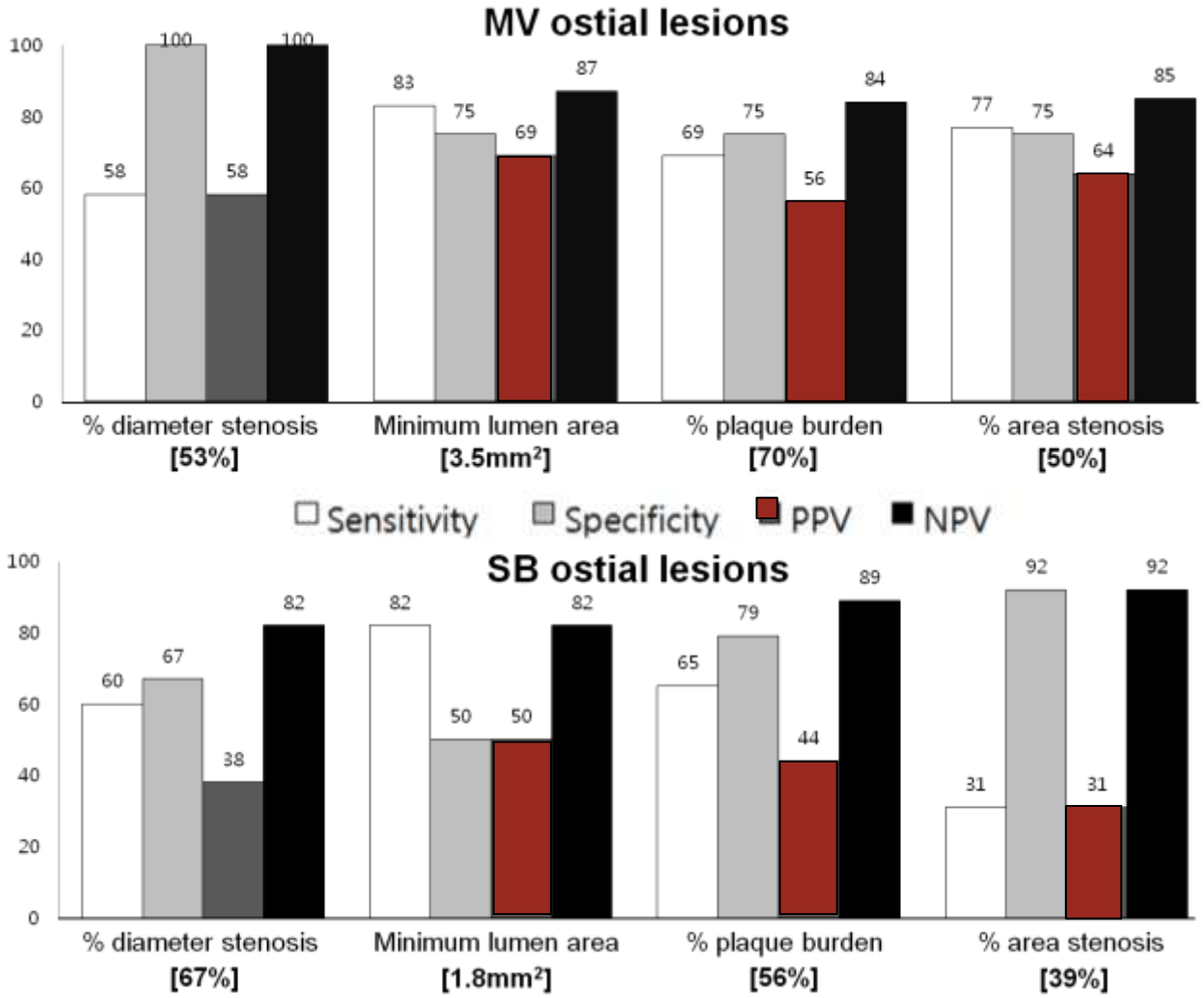

Koh JS, Koo BK, et al., JACC Intv, 2012

Provisional T Stenting

In cases with significant narrowing of side branch after main branch stenting ?

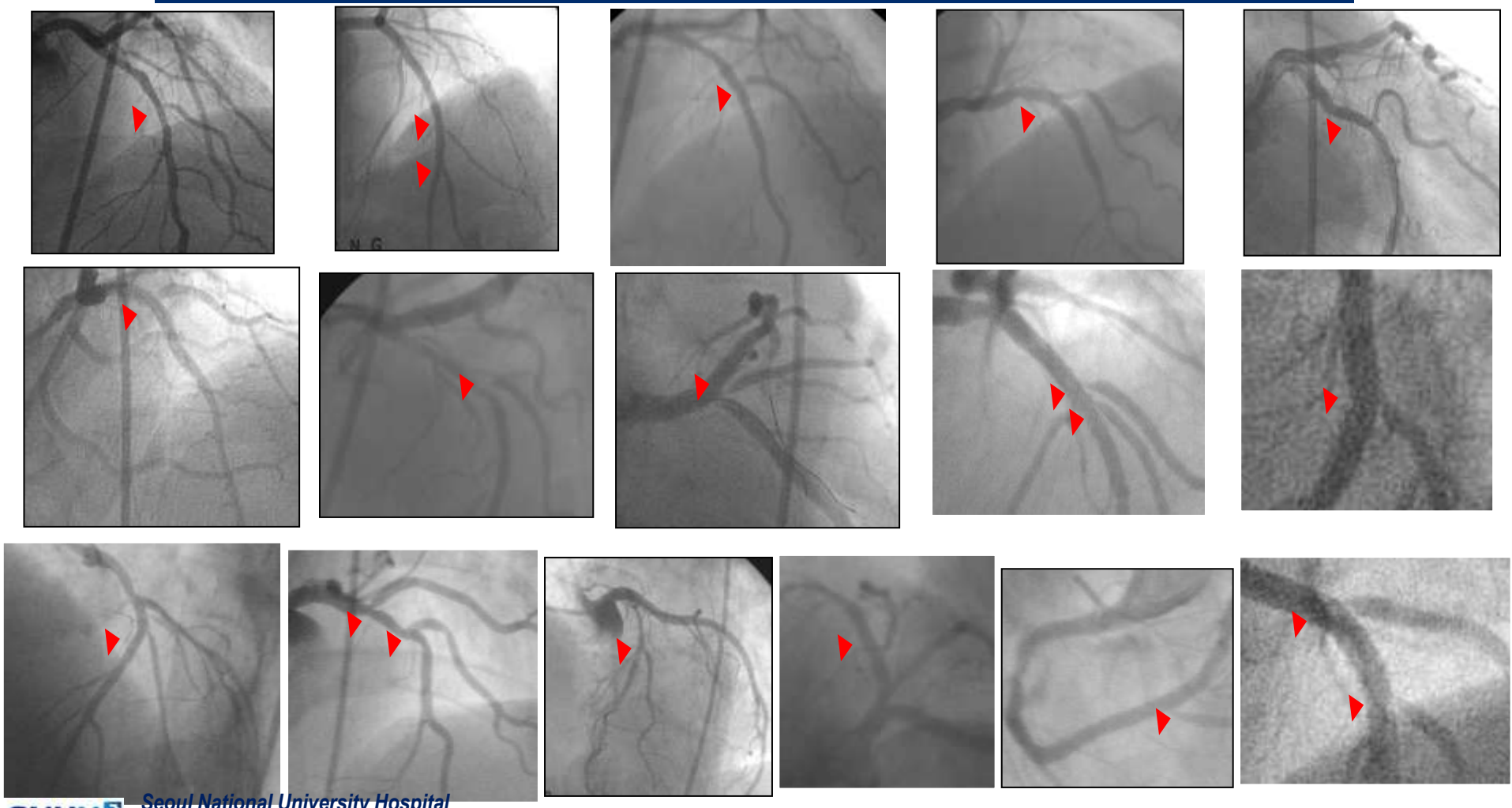

Side branch angioplasty ?

Different criteria in different studies……

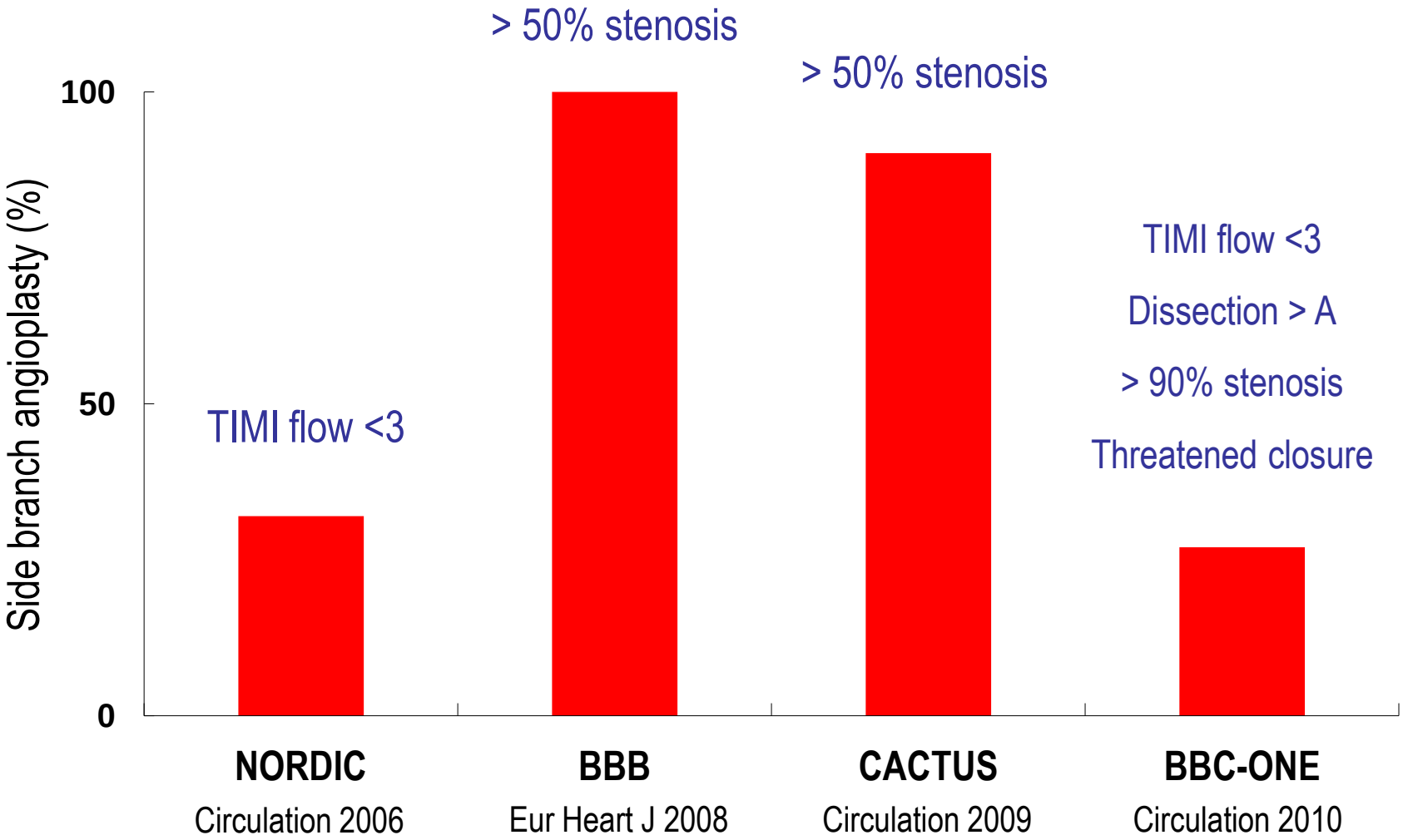

Degree of stenosis?

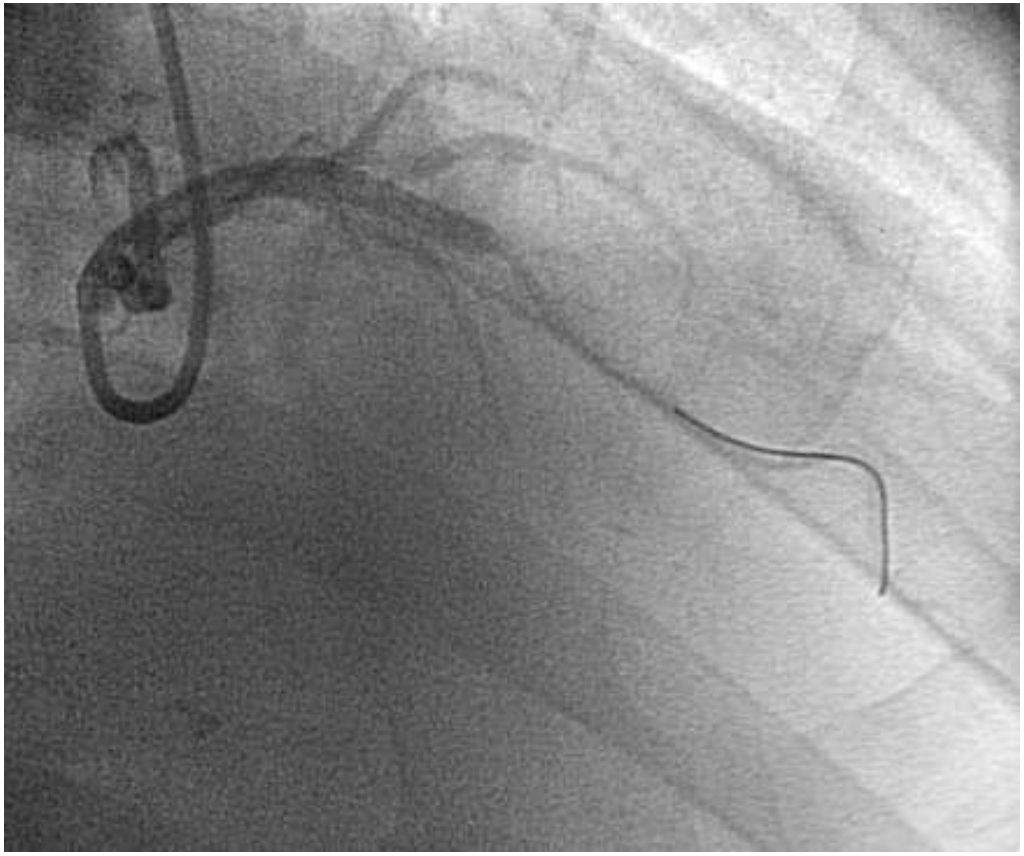

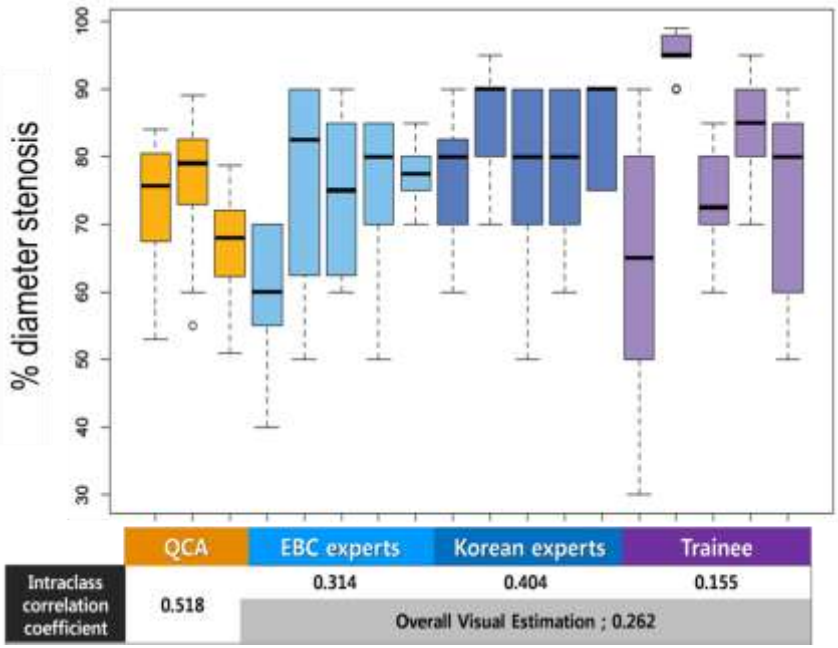

Shin DH, Koo BK, et al. Cath Cardiovasc Interv 2011

Anatomical severity ≠ Physiological significance

% diameter stenosis vs. FFR in Jailed side branches

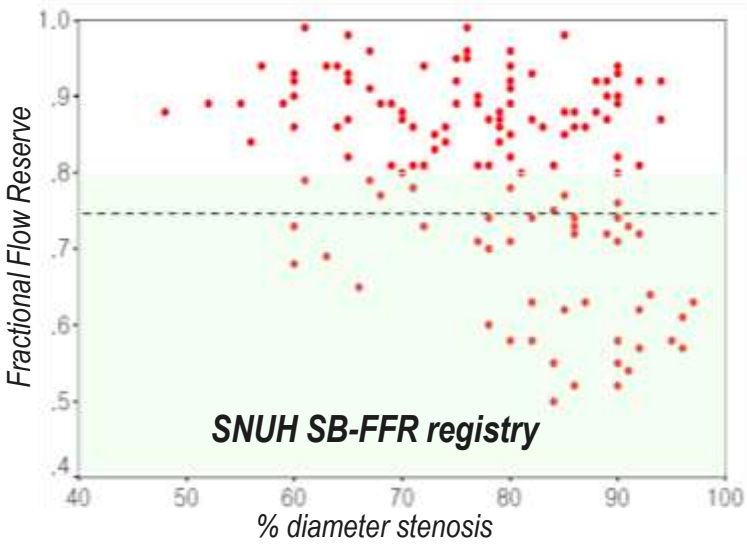

Park SH & Koo BK, J Ger Cardiol 2012

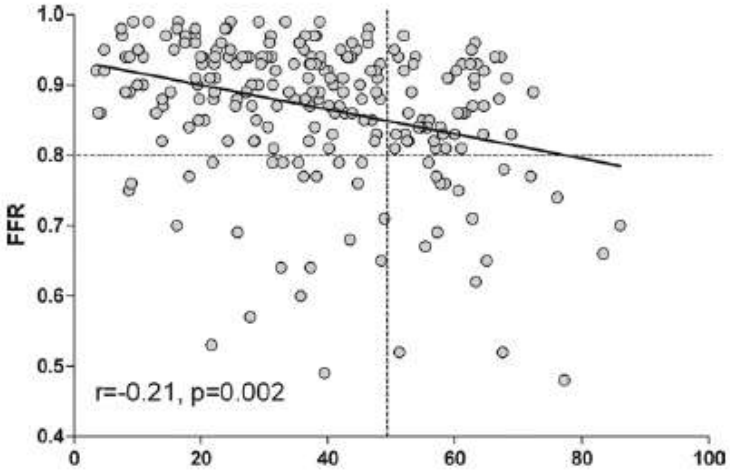

Ahn JM, et al. JACC intv 2012

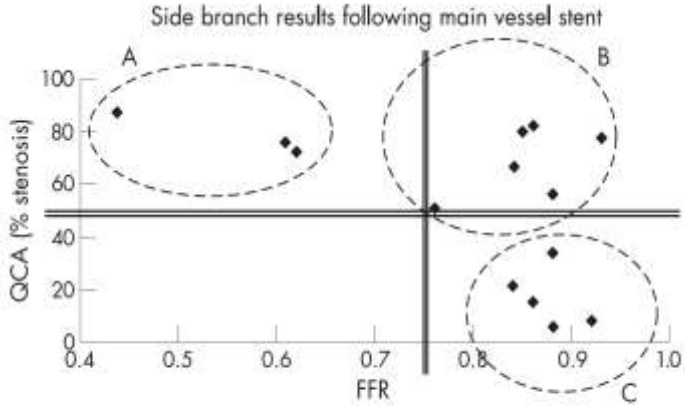

Bellenger, et al. Heart 2007

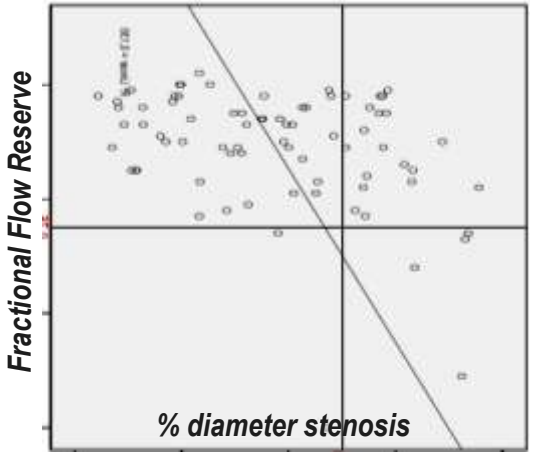

Kumsars I, et al. Eurointervention 2011

Significant stenosis? Needs intervention?

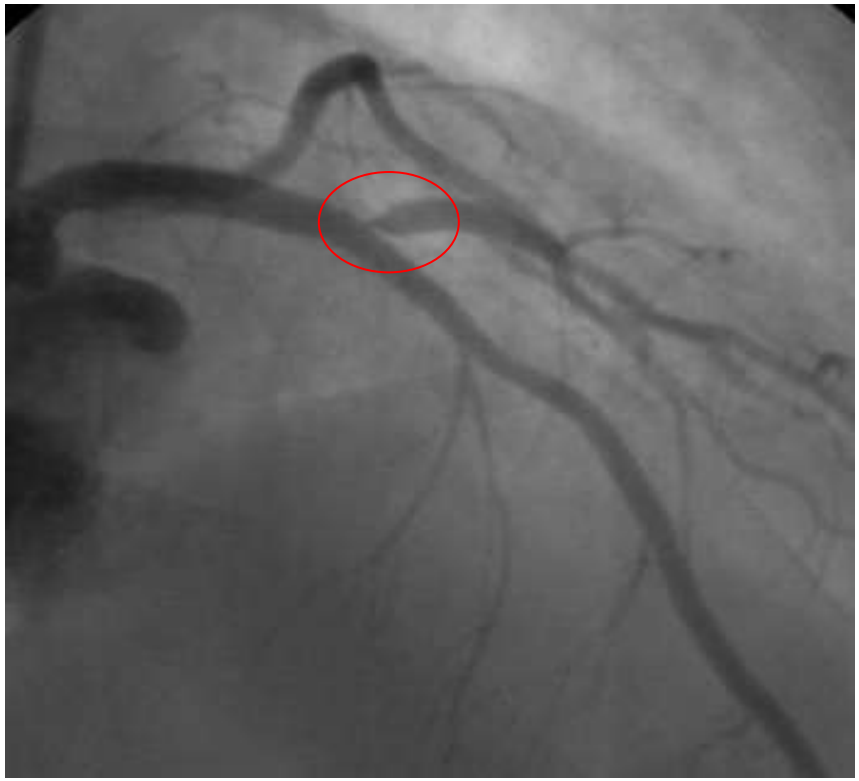

Jailed Diagonal branch FFR 0.81

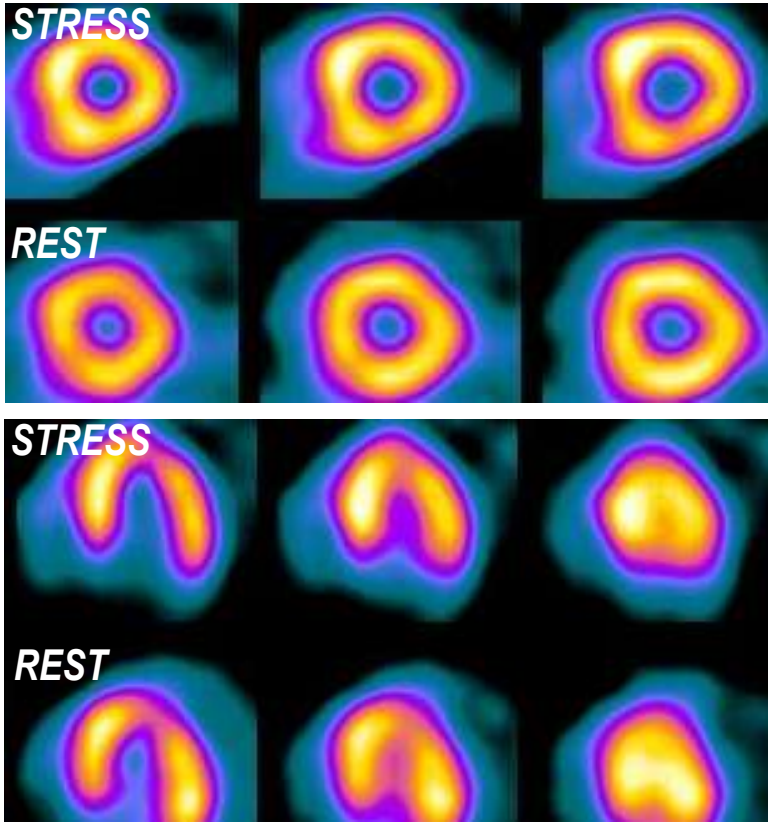

No perfusion defect

Which need(s) additional intervention?

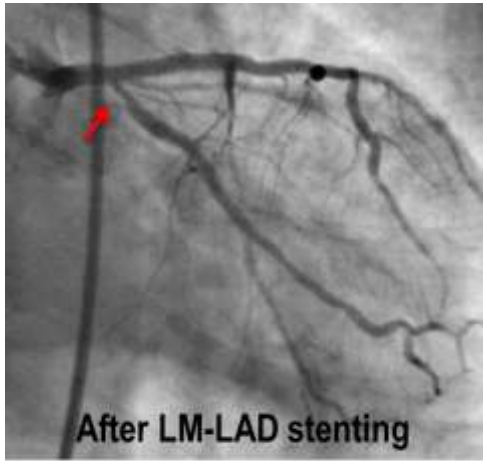

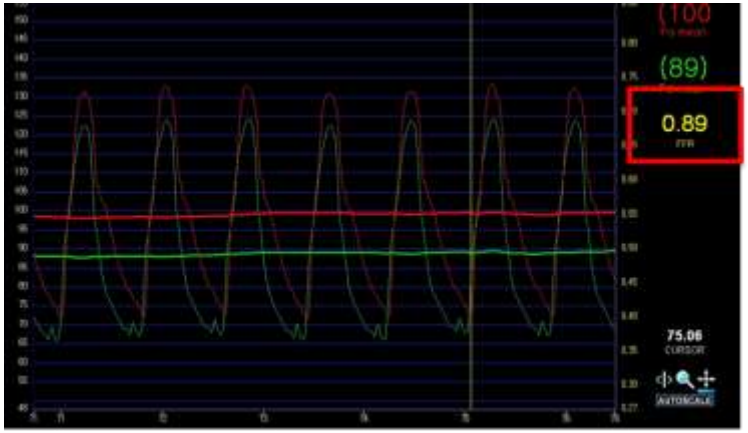

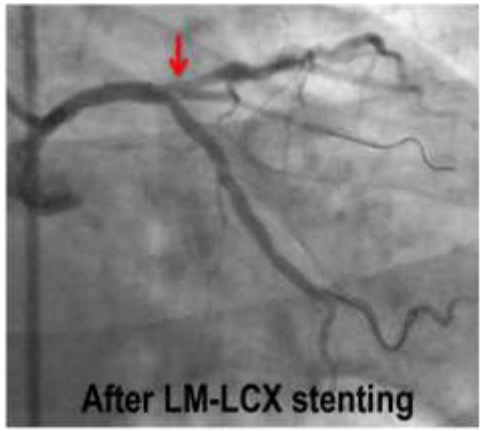

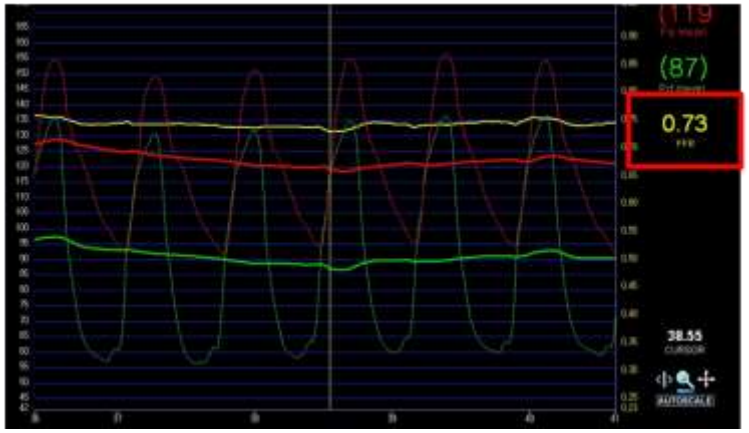

Debate: Is Functional Evaluation Necessary?

- Presence of ischemia is a key prognostic factor in patients with coronary artery stenosis.
- FFR is the gold standard invasive method to define ischemia-causing stenosis.
- In bifurcation lesion, angiography **alone** is inaccurate in the prediction of functional significance.
- High inter-individual variability exists in both visual estimation and QCA.
- IVUS, OCT cannot overcome these limitation.

Yes, We Need a Function-guidance!

(for the main and large side branches)