



TCTAP 2023

A case of intractable stent failure what can OCT help with?

Thinnakrit Sasiprapha, MD

Ramathibodi Hospital, Mahidol University, Bangkok Thailand

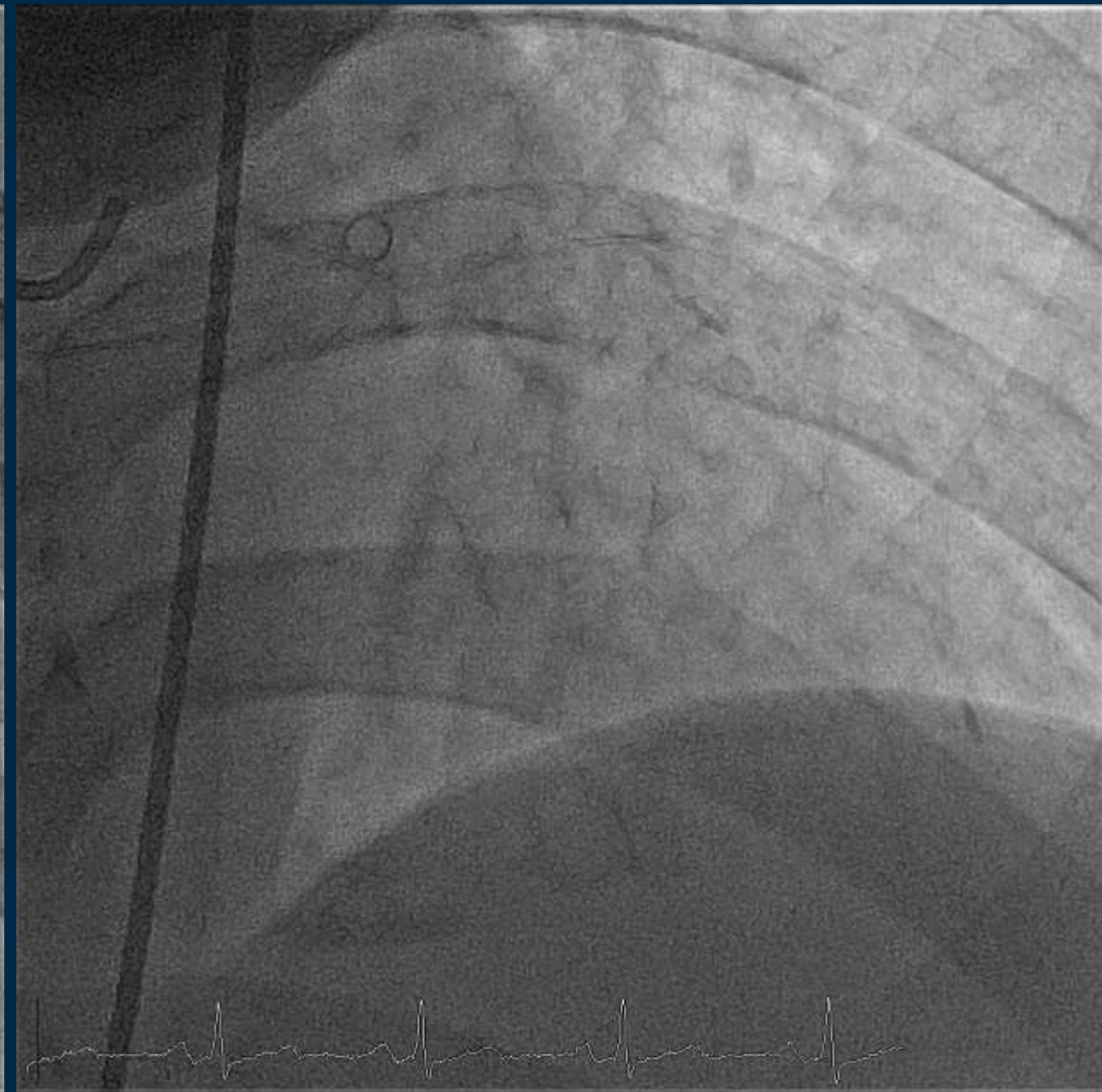
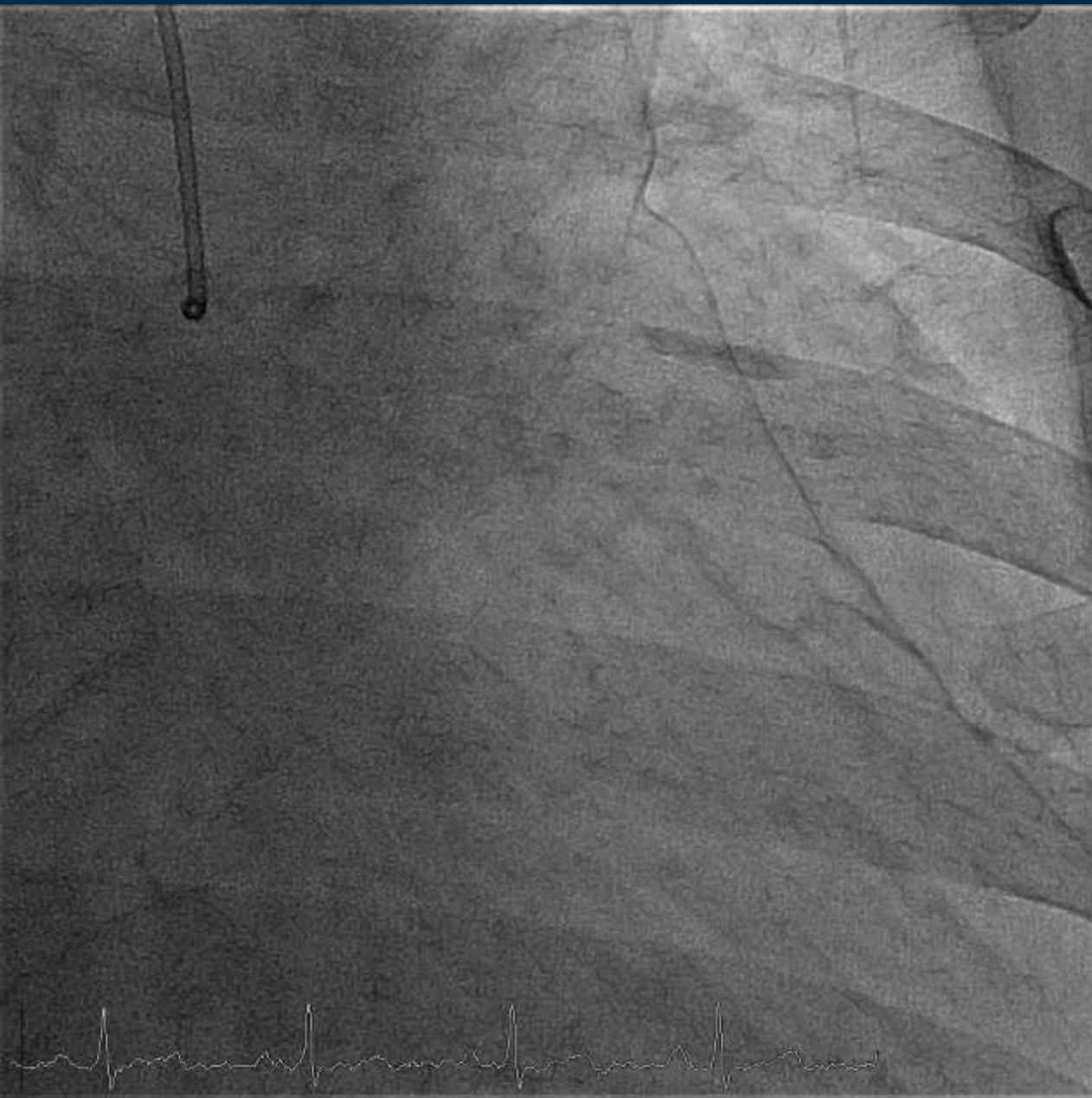
Cardiovascular Intervention Association Thailand (CIAT)

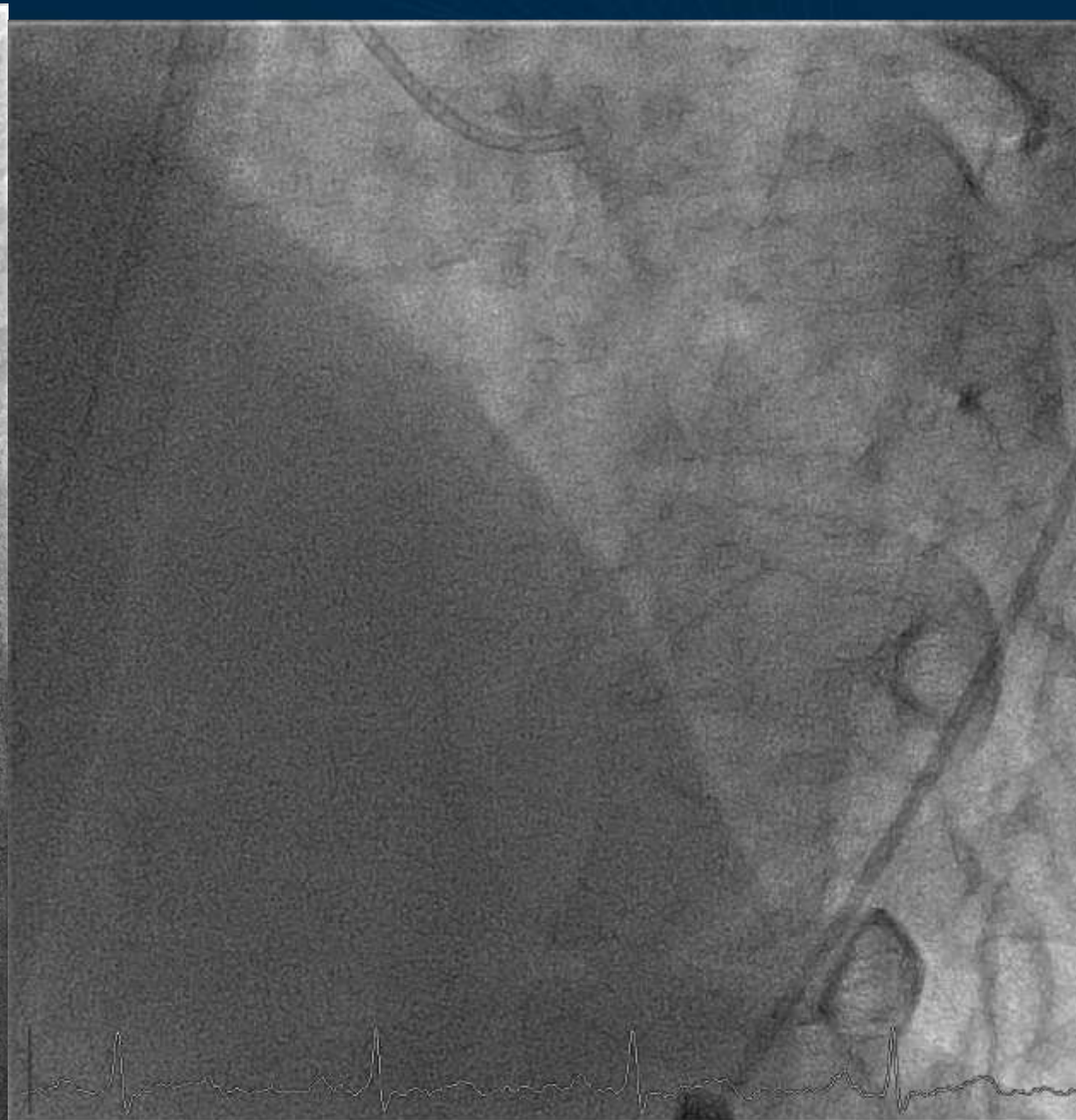
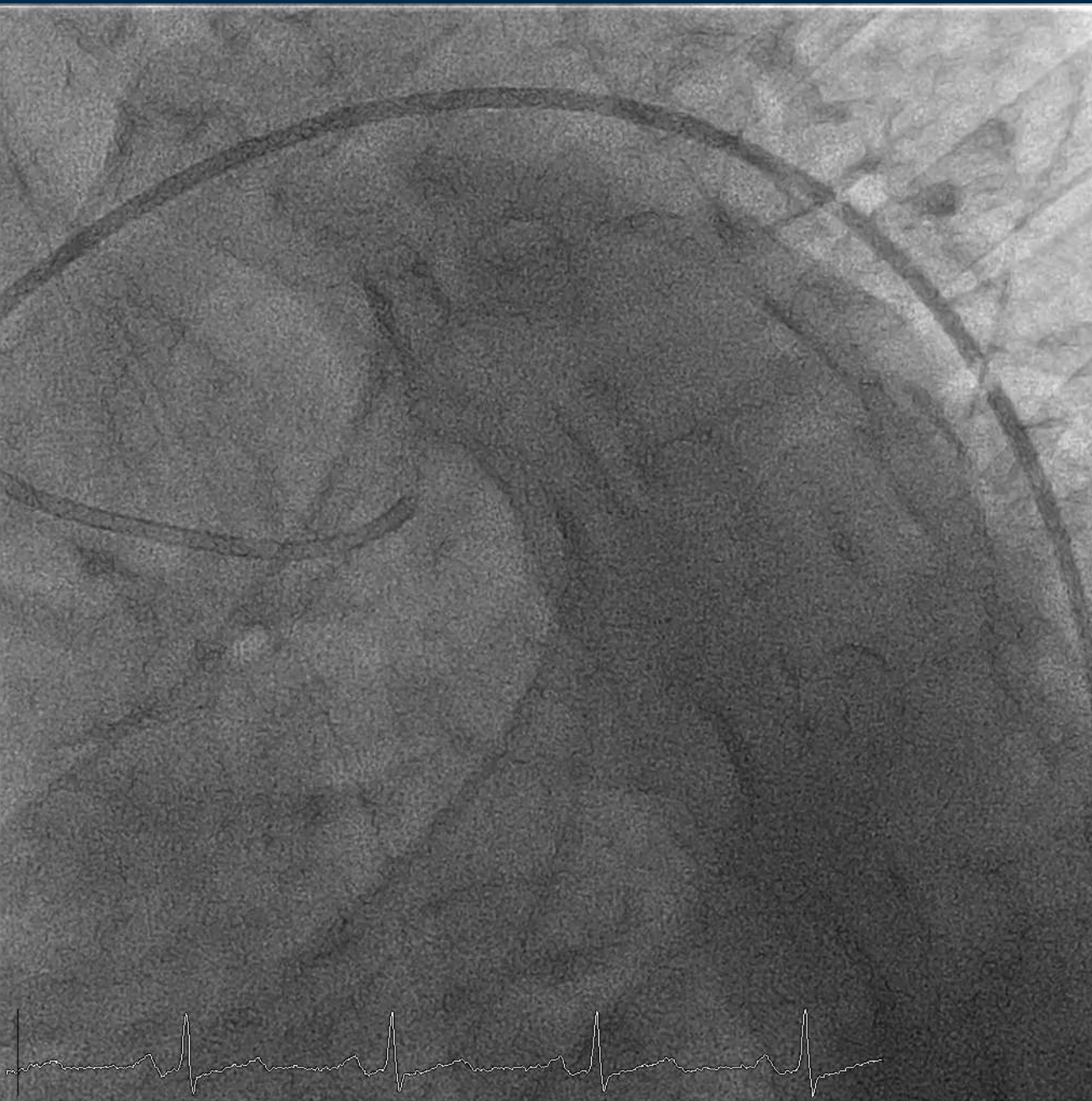Disclosure

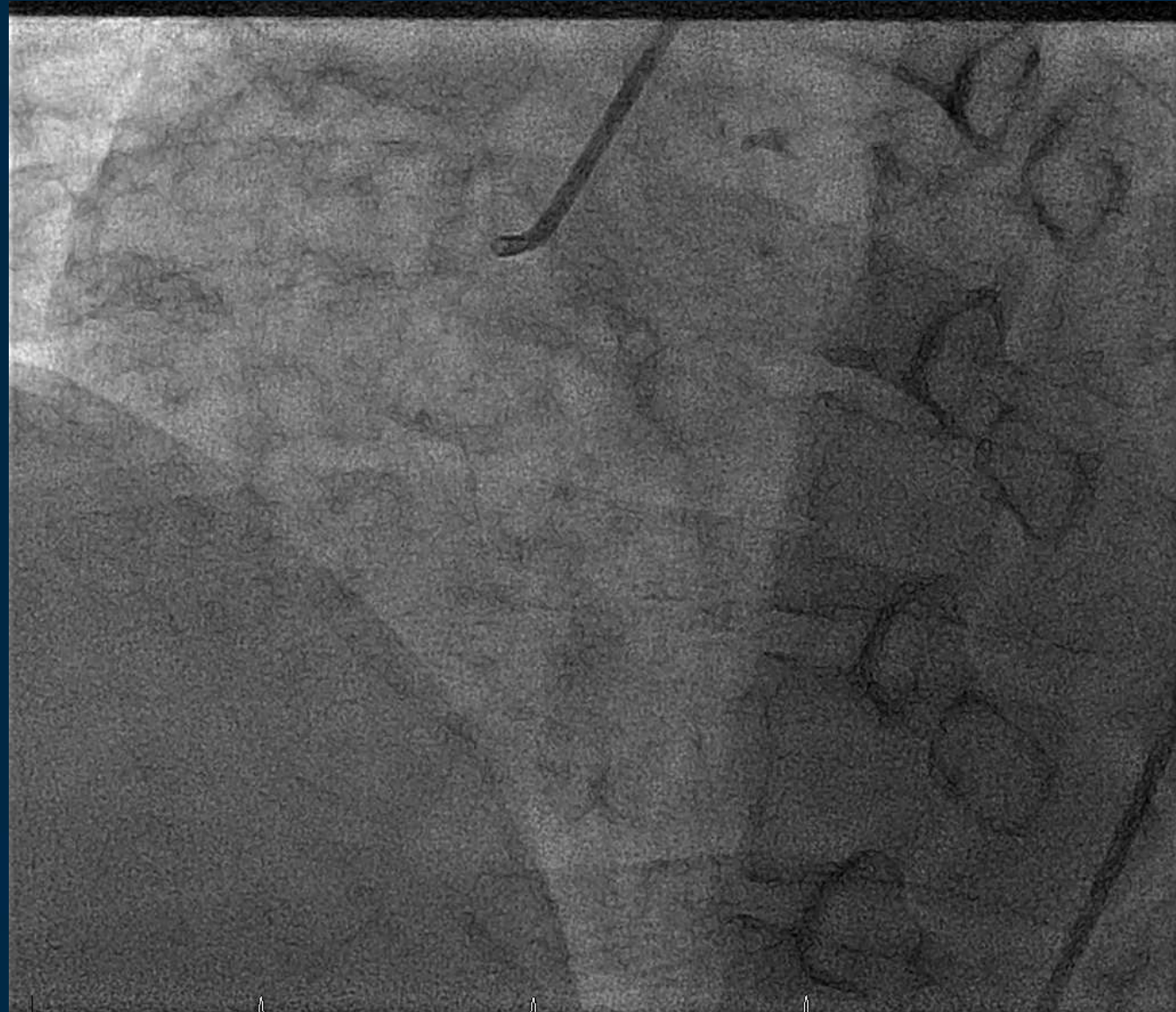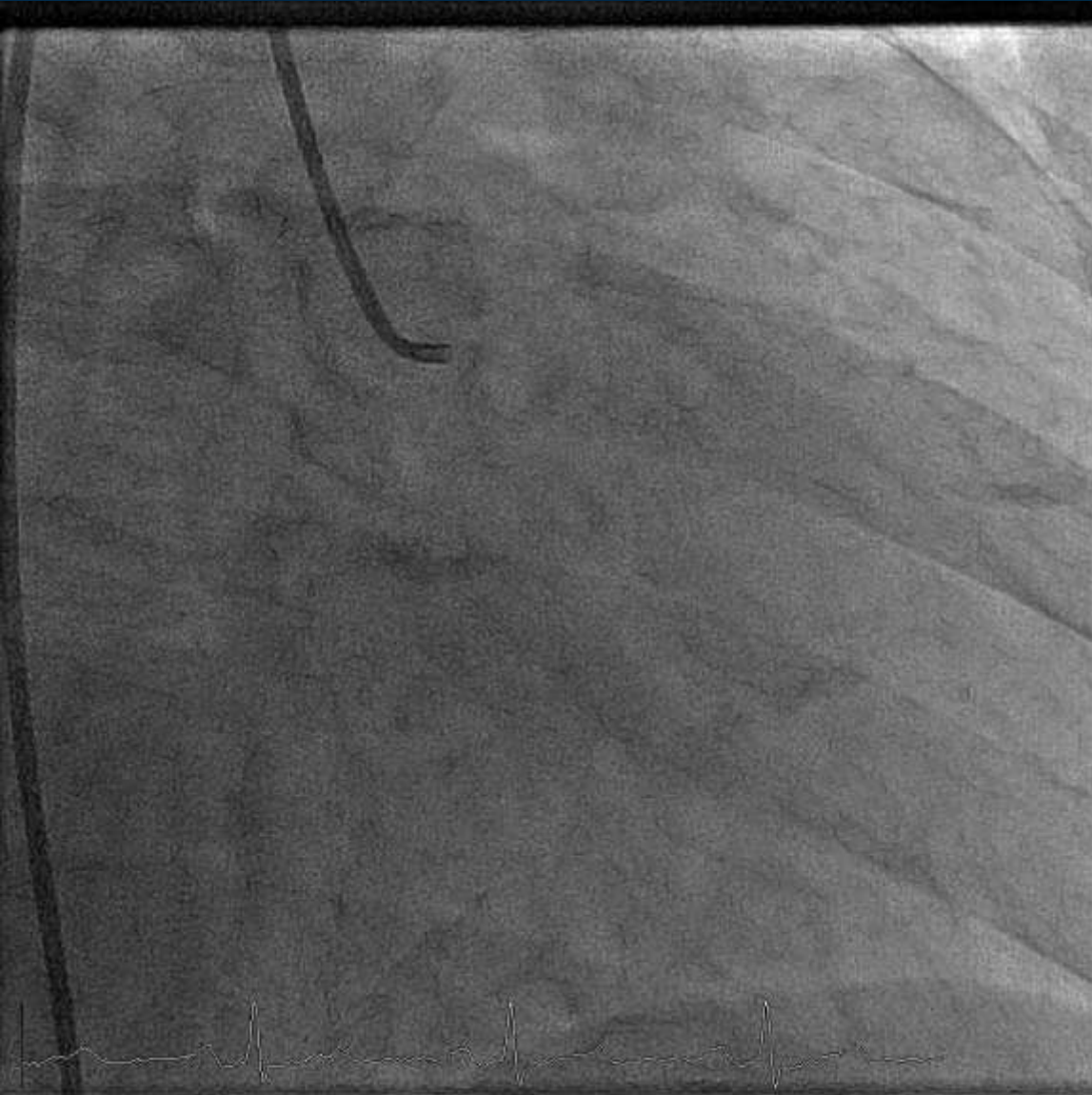
- I have NO financial disclosure or conflicts of interest with the presented material in this presentation

37 years old woman

- Underlying **T1DM, HT, ESRD**, tertiary hyperparathyroid
- Presented with critical limb ischemia ; infected ulcer left ankle S/P PTA with DCB/DES at SFA and debridement
- Consult for pre-op evaluation
 - Angina on exertion
 - Echocardiogram : LVEF 50%, **hypokinesia anterior and inferior wall mid to apex**
- Urgent CAG was scheduled
- Med : Aspirin(81) 1 tab od pc, Clopidogrel(75) 1 tab od pc









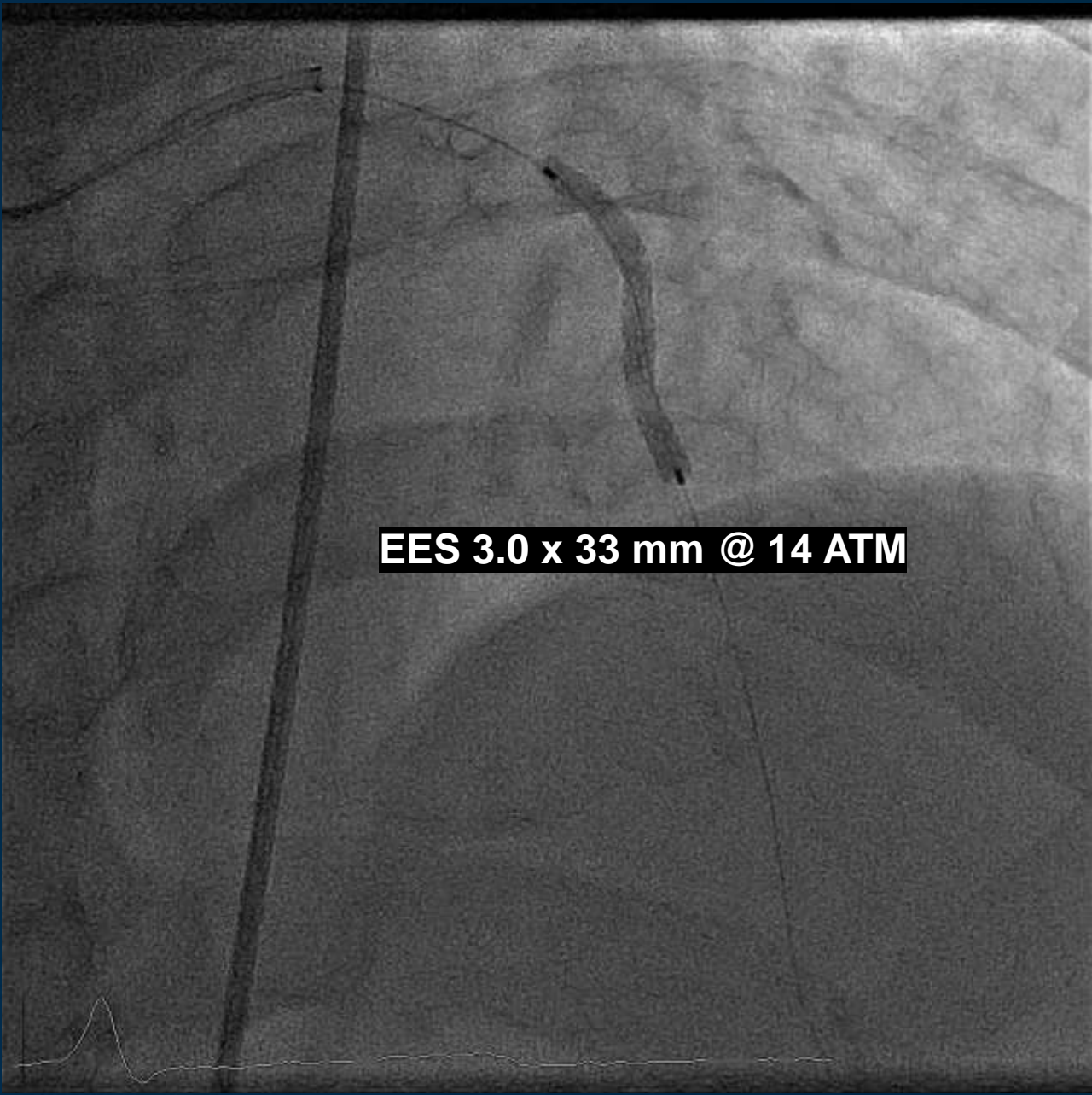
SC balloon 3.0 x 20 mm @ 12 ATM

This is a grayscale angiogram showing a coronary artery with a stent balloon in place. The balloon is inflated, and the underlying vessel lumen is visible through the stent. The image shows the characteristic branching and curvature of the coronary artery system.

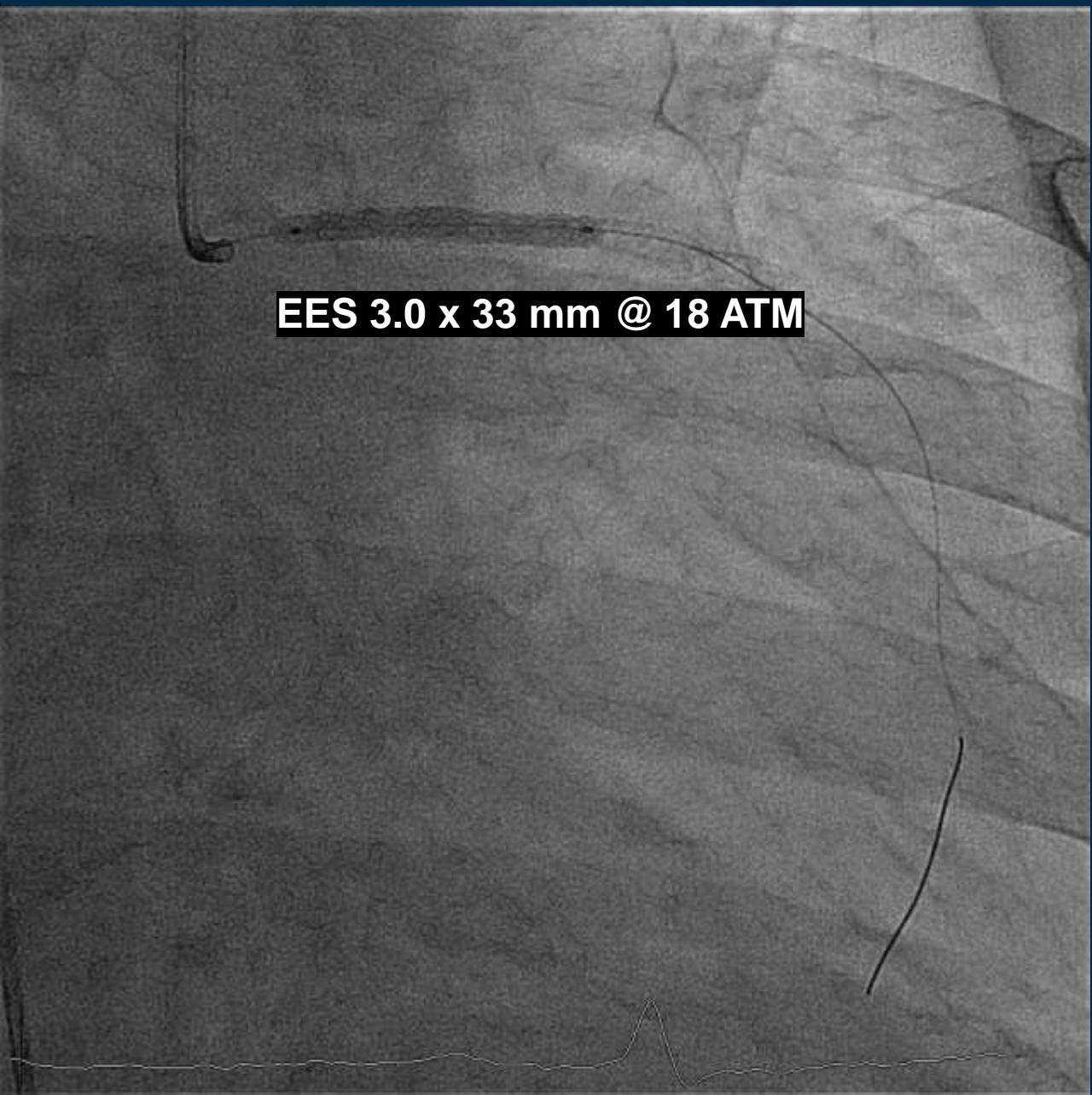


SC balloon 3.0 x 20 mm @ 12 ATM

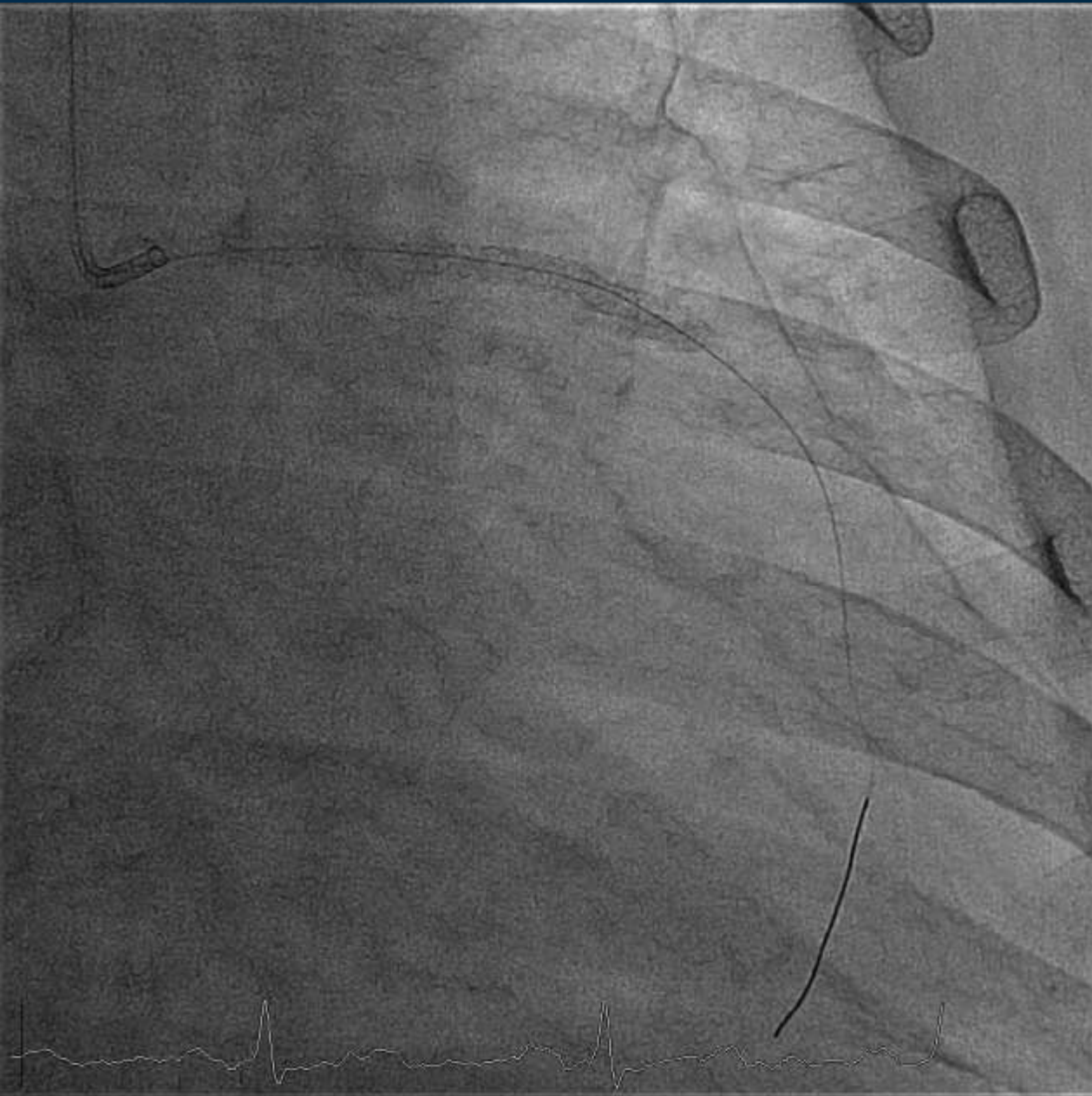
This is a grayscale angiogram showing a coronary artery with a stent balloon in place. The balloon is inflated, and the underlying vessel lumen is visible through the stent. The image shows the characteristic branching and curvature of the coronary artery system.



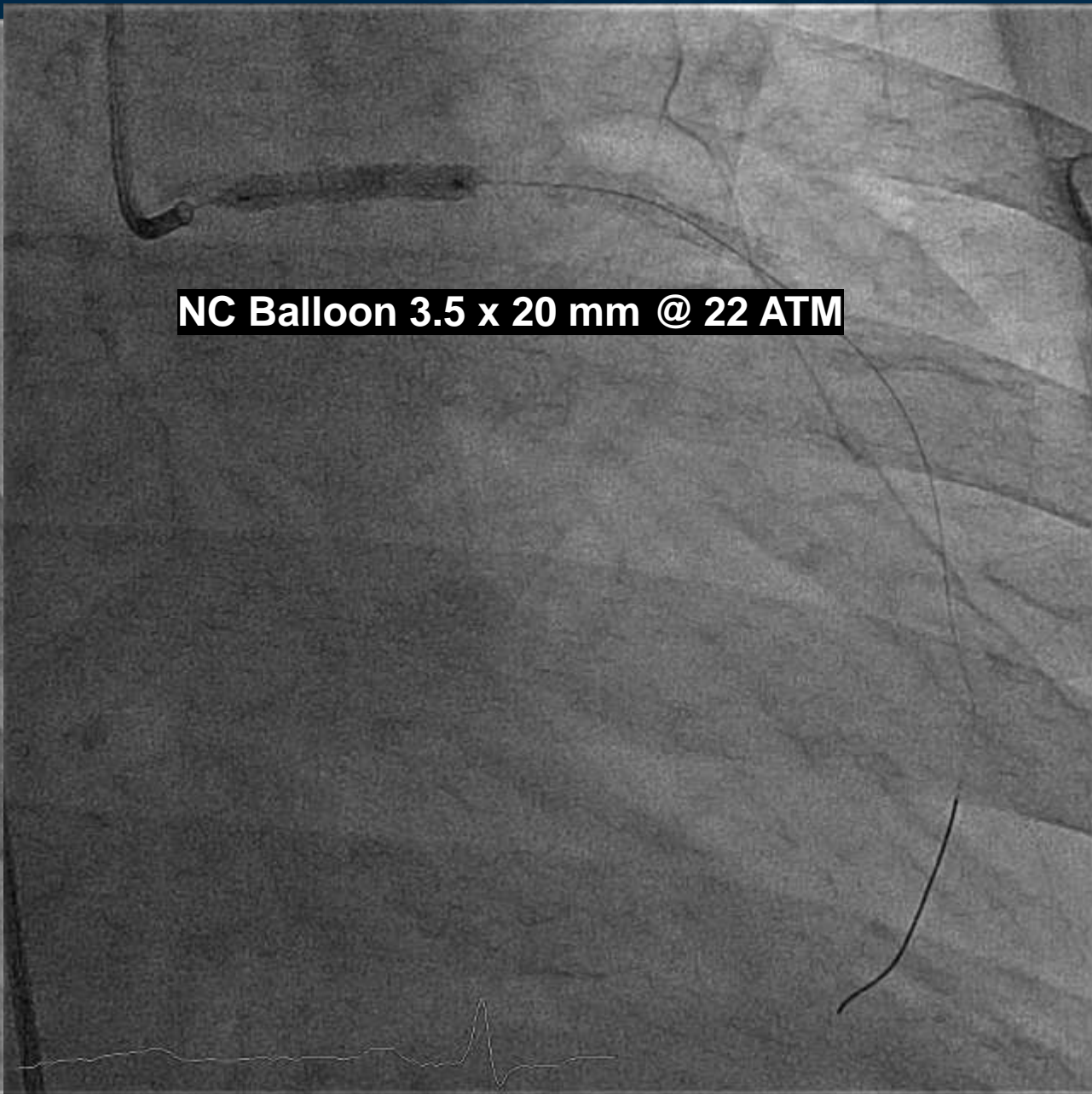
EES 3.0 x 33 mm @ 14 ATM

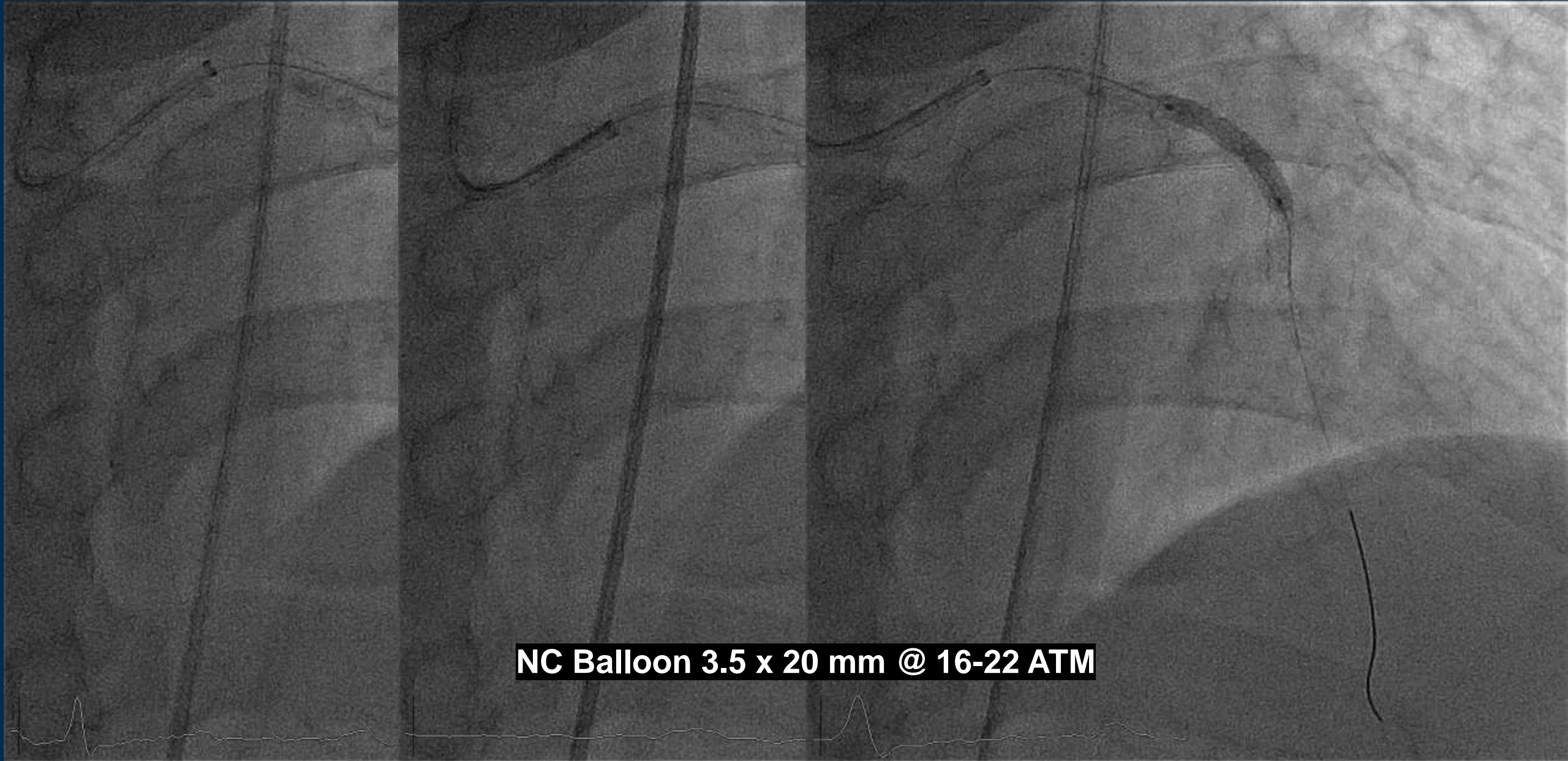

EES 3.0 x 33 mm @ 18 ATM



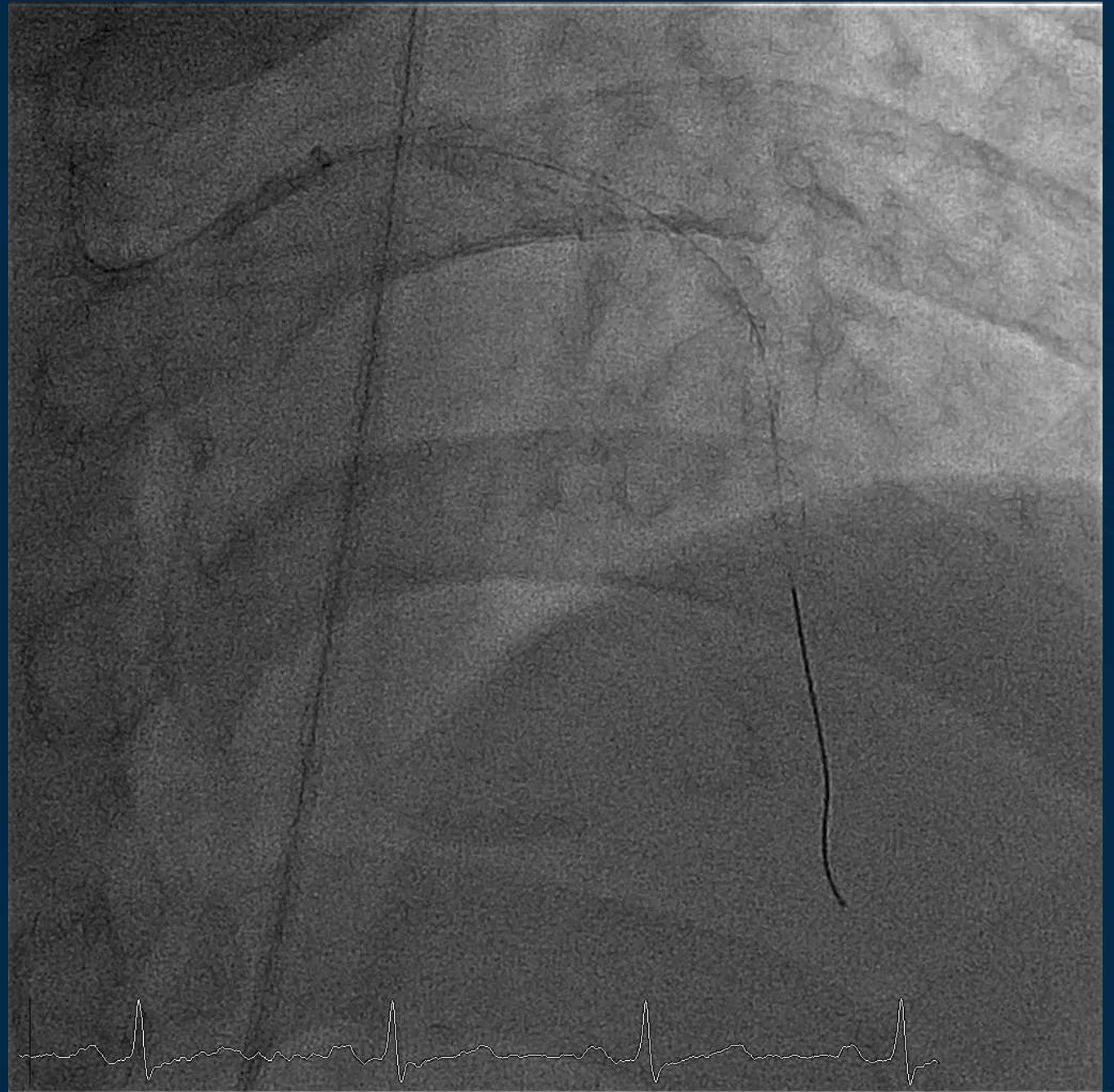
NC Balloon 3.5 x 20 mm @ 22 ATM





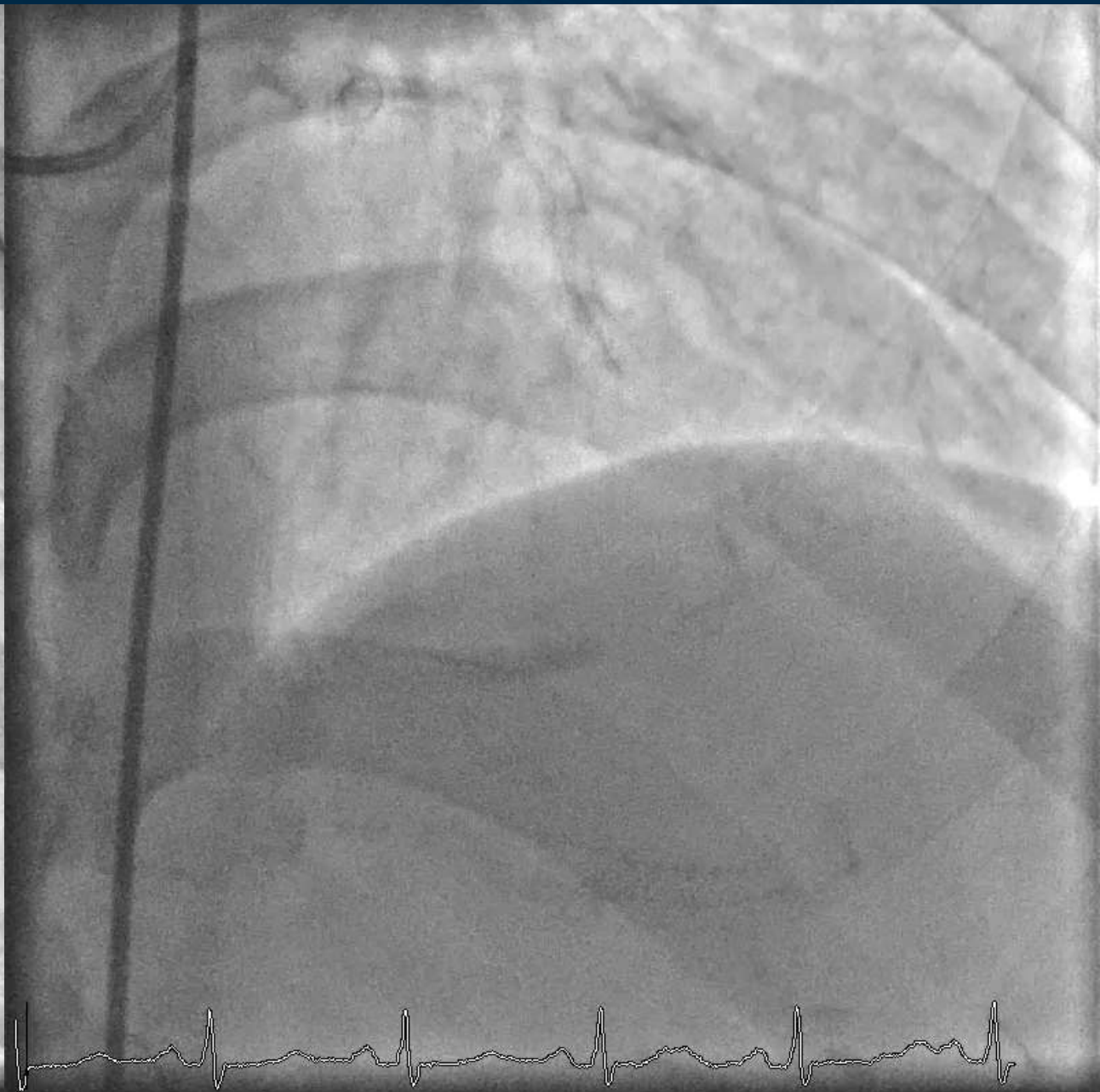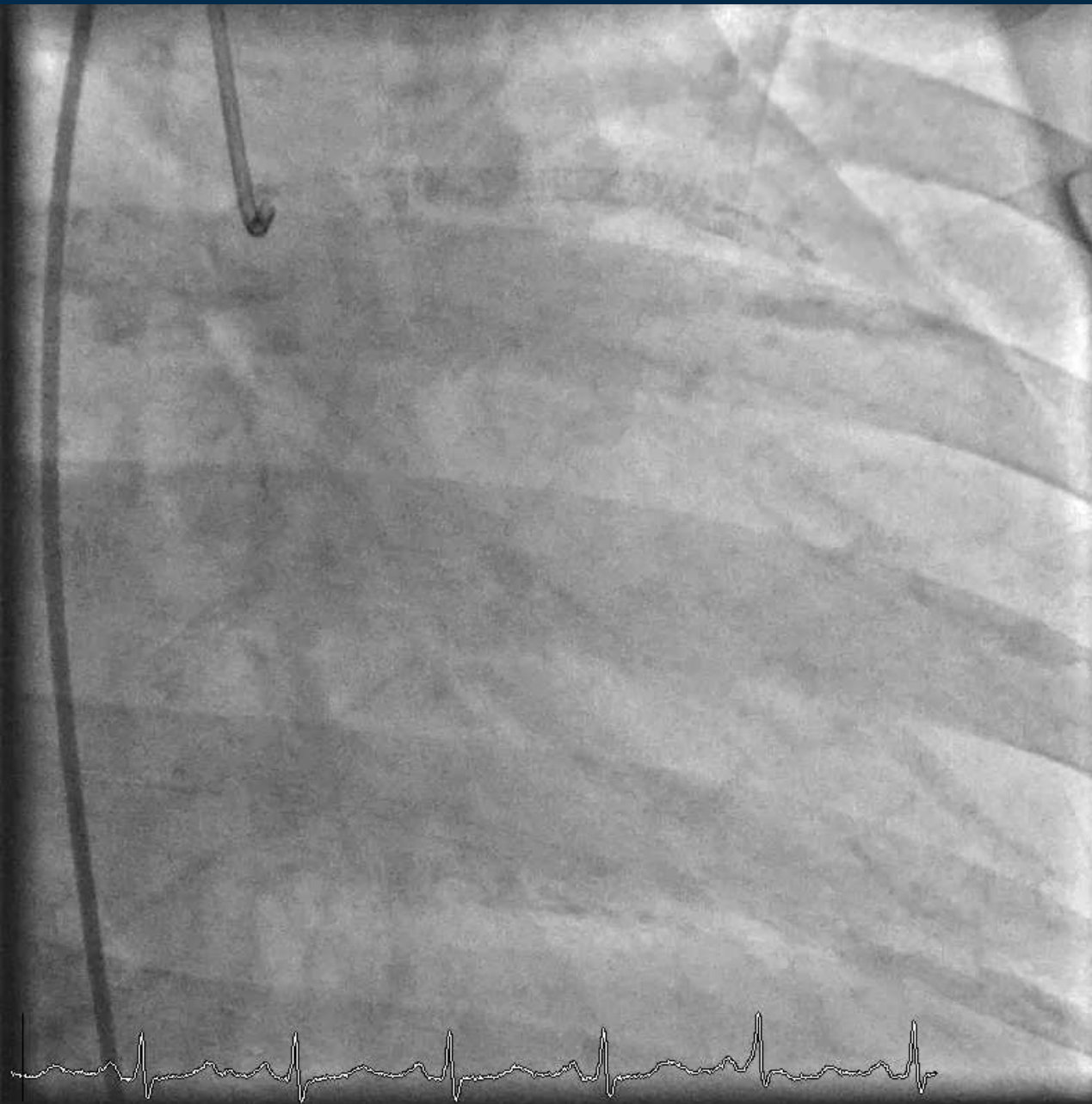NC Balloon 3.5 x 20 mm @ 16-22 ATM

Final angiogram

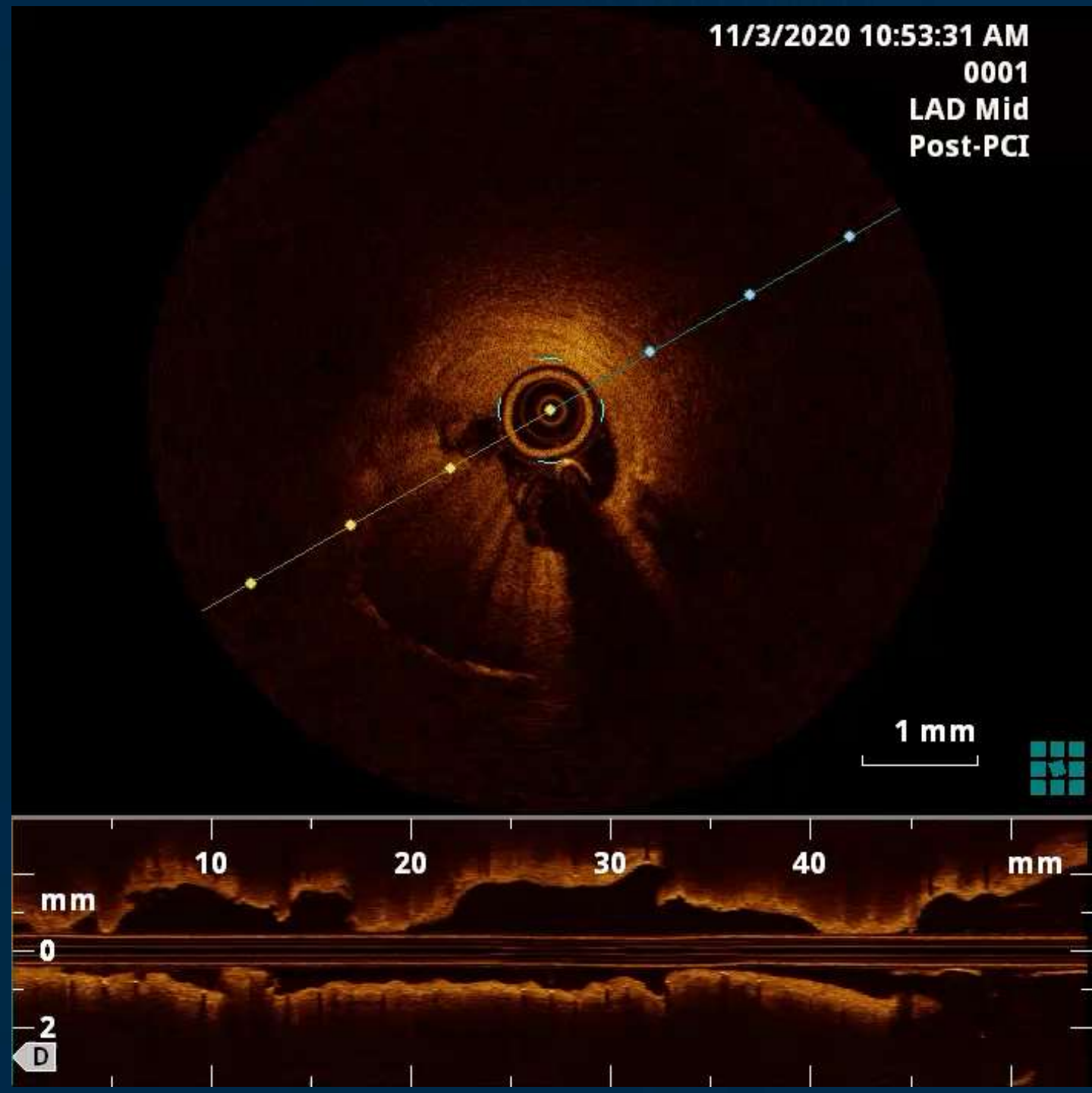


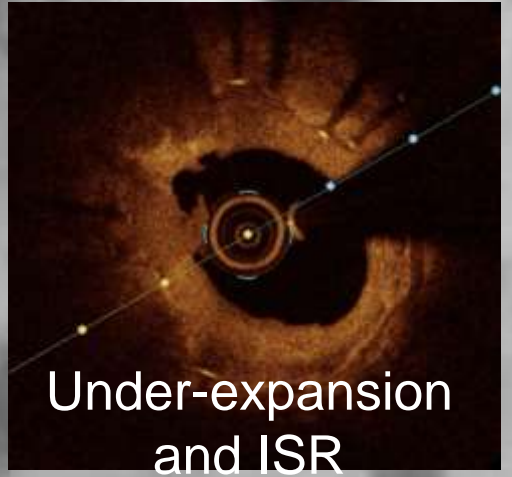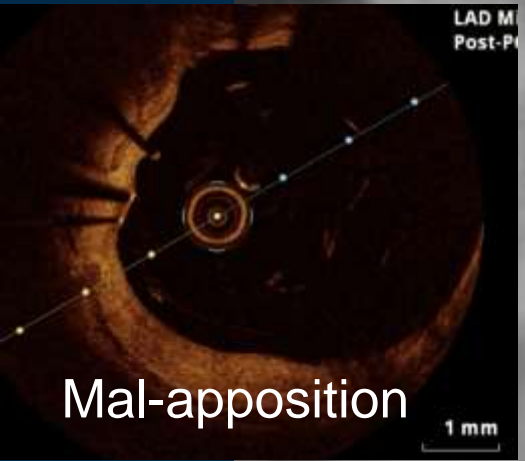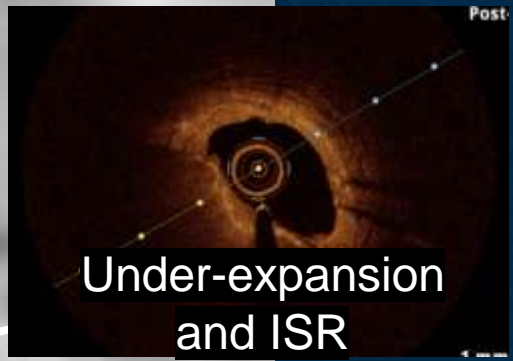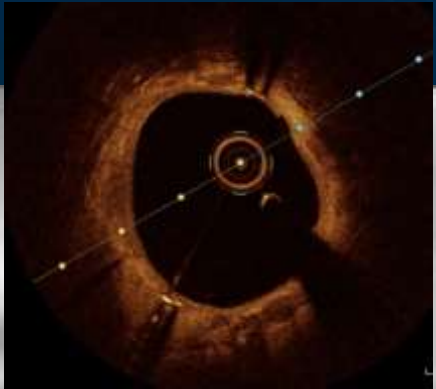
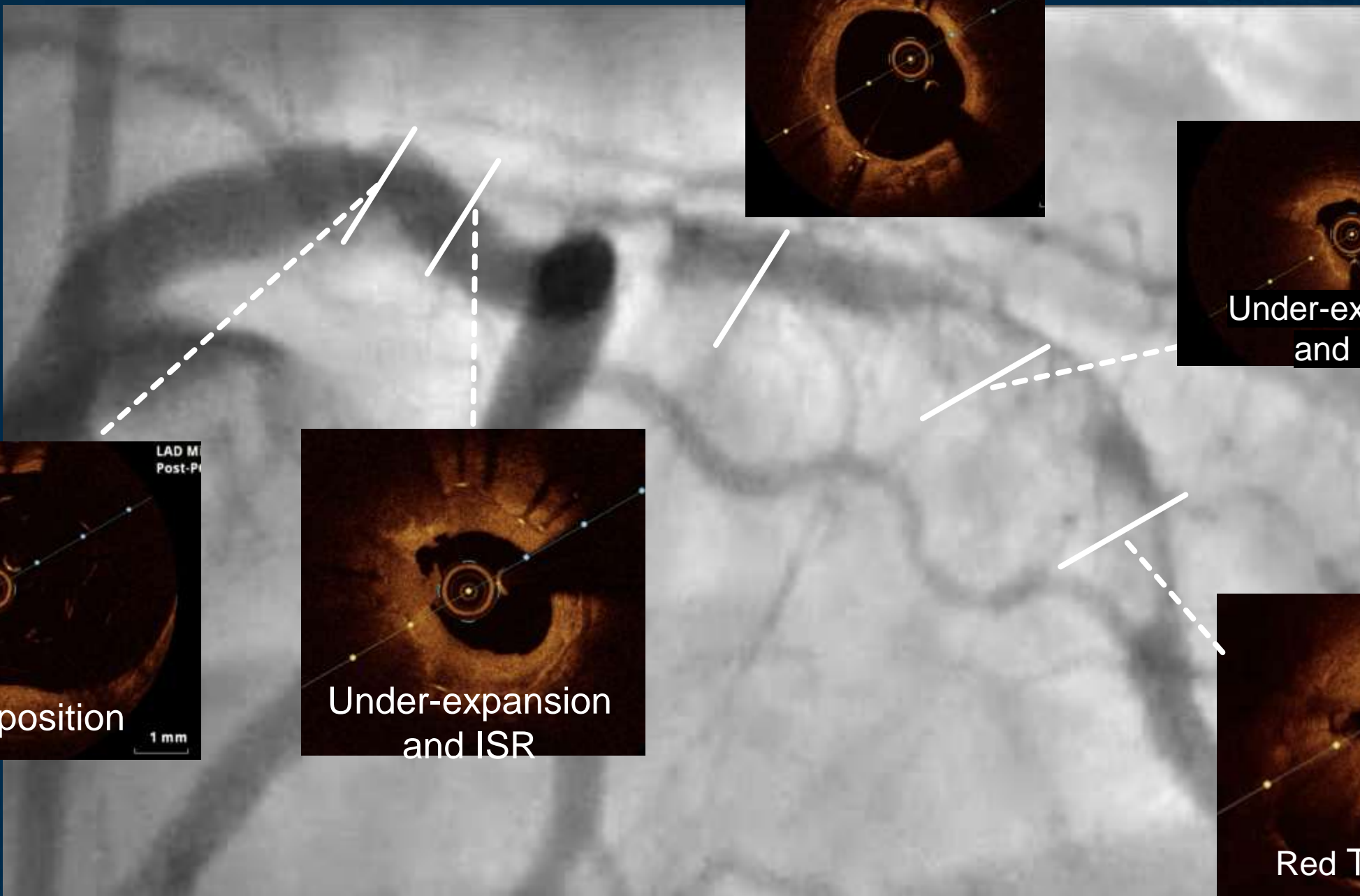
6 months later

- 5 Days PTA ; pain and swelling at right foot > DM foot with cellulitis
- During admission for ATB , she had **acute chest pain**
- Troponin T 100 ng/ml
- Medication : ASA(81) 1 tab od pc, Clopidogrel (75)1 tab od pc, Atorvastatin(40)1 tab od hs
- Lab : LDL 67 mg/dL, PTH 645 pg/ml (15-65), HbA1c 5.7 %



OCT





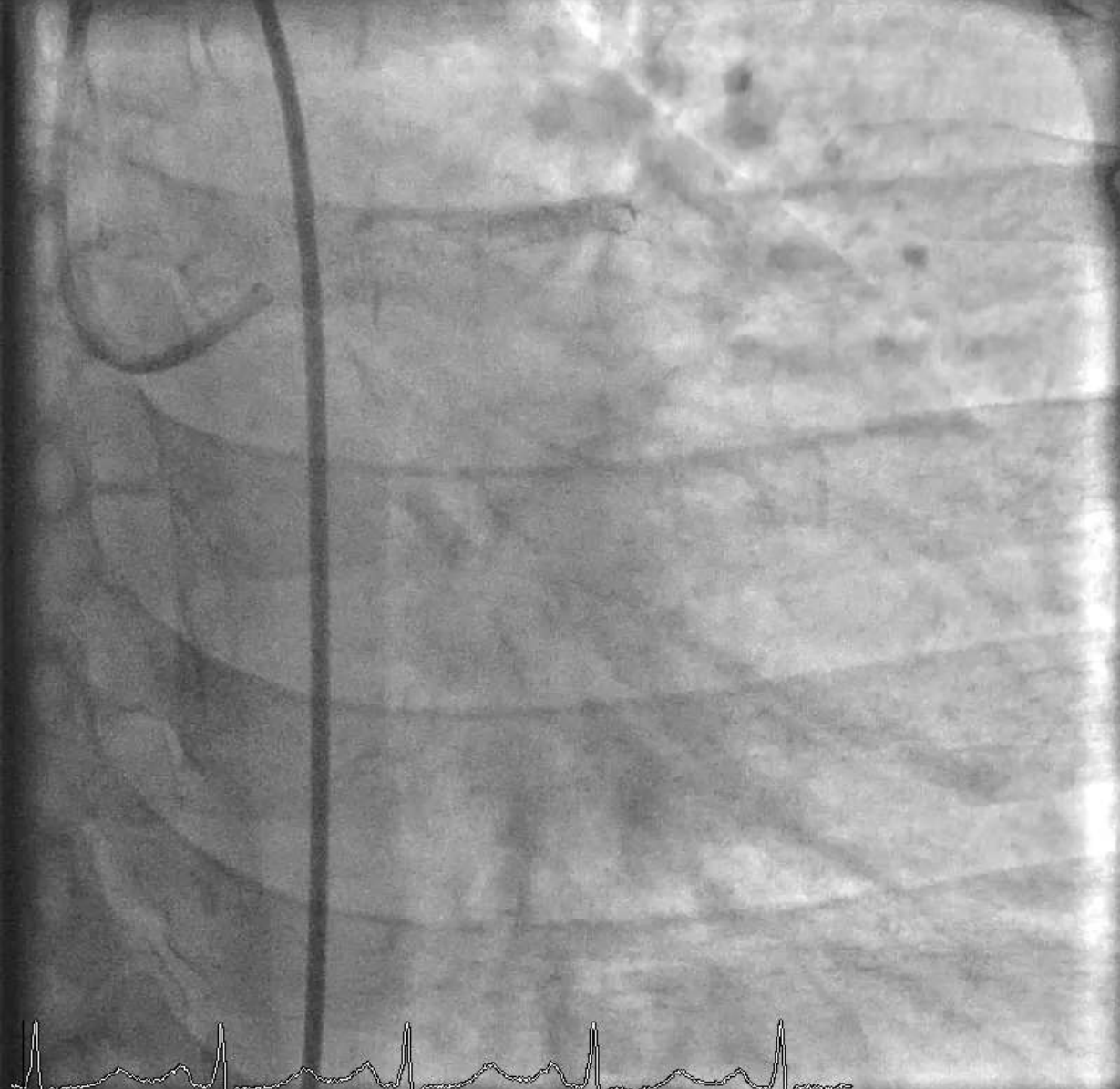
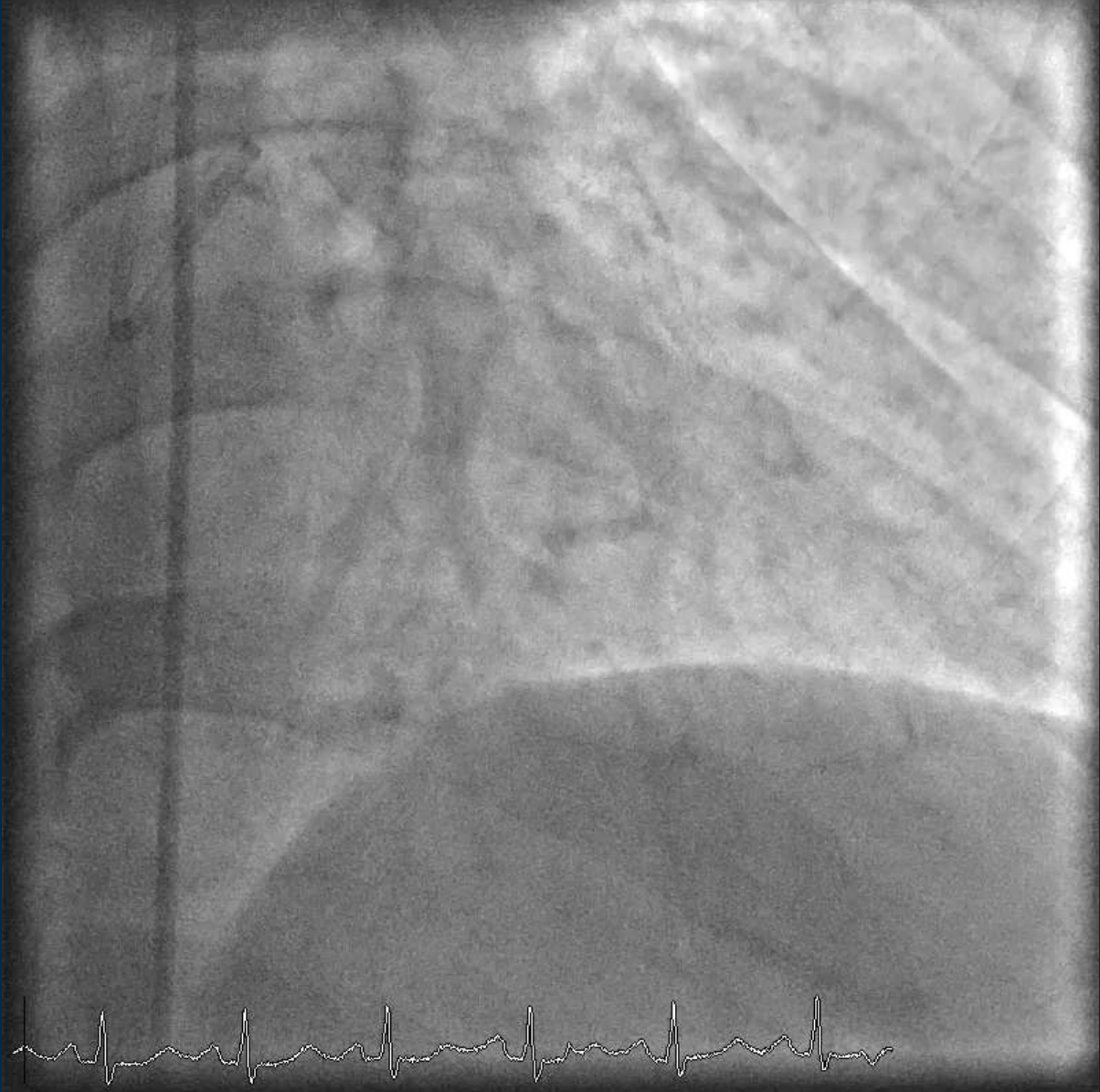

SC Balloon 2.0 x 15 mm 14-16 ATM

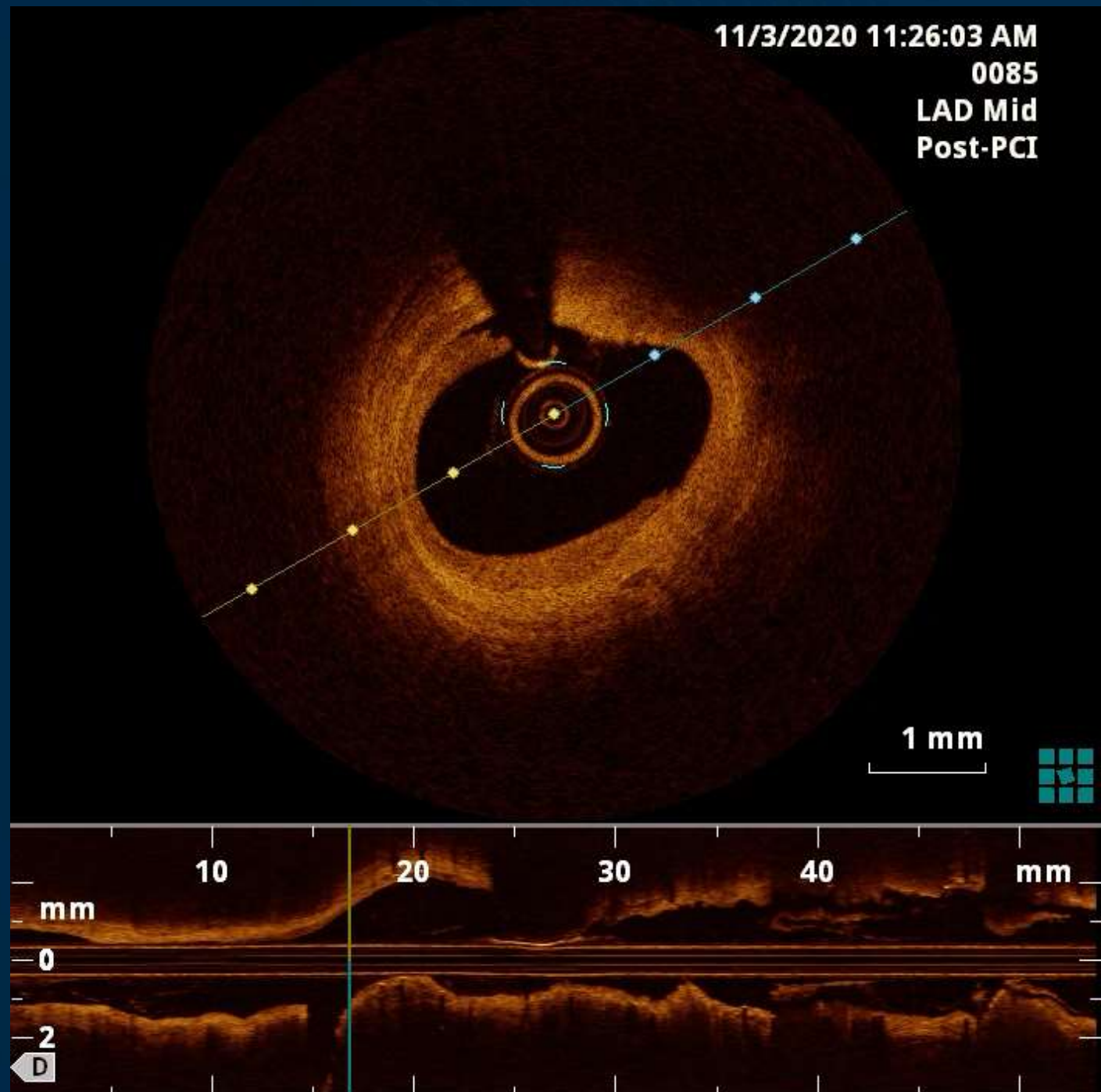
Thrombuster aspiration & sequential balloon dilatation

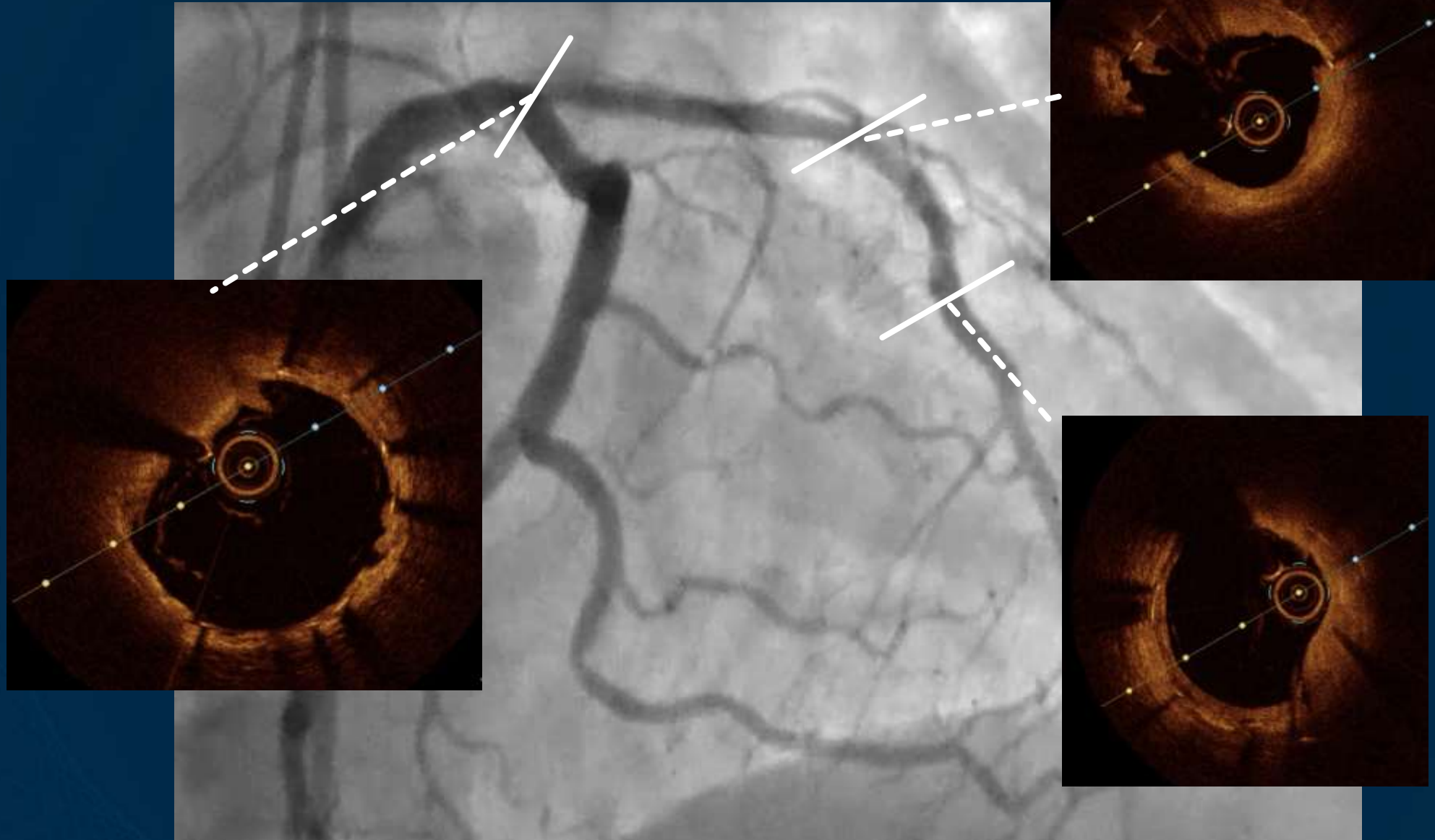
NC Balloon 4.0 x 15 mm 6 ATM

NC Balloon 3.5 x 15 mm 20 ATM



Final OCT

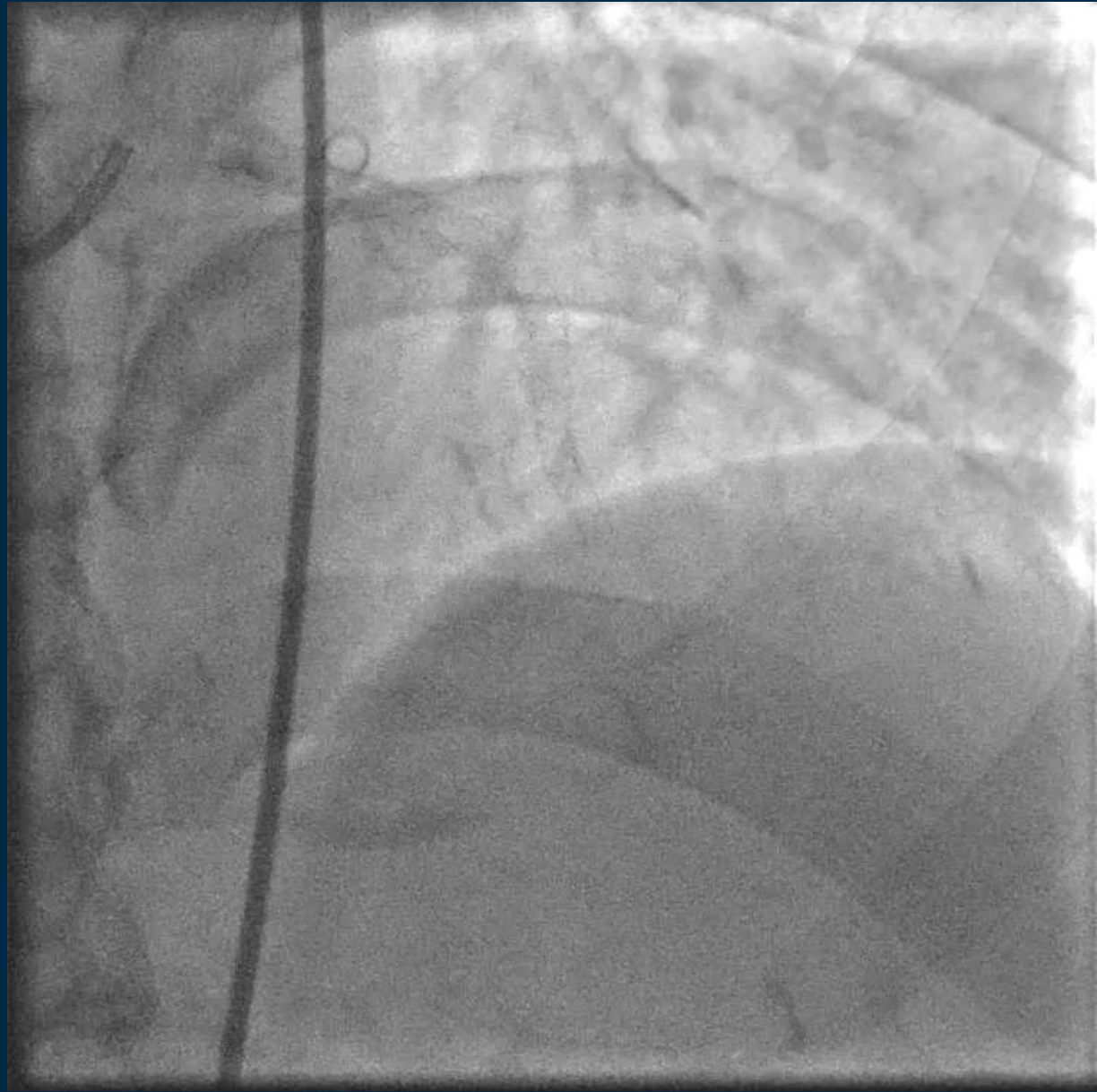
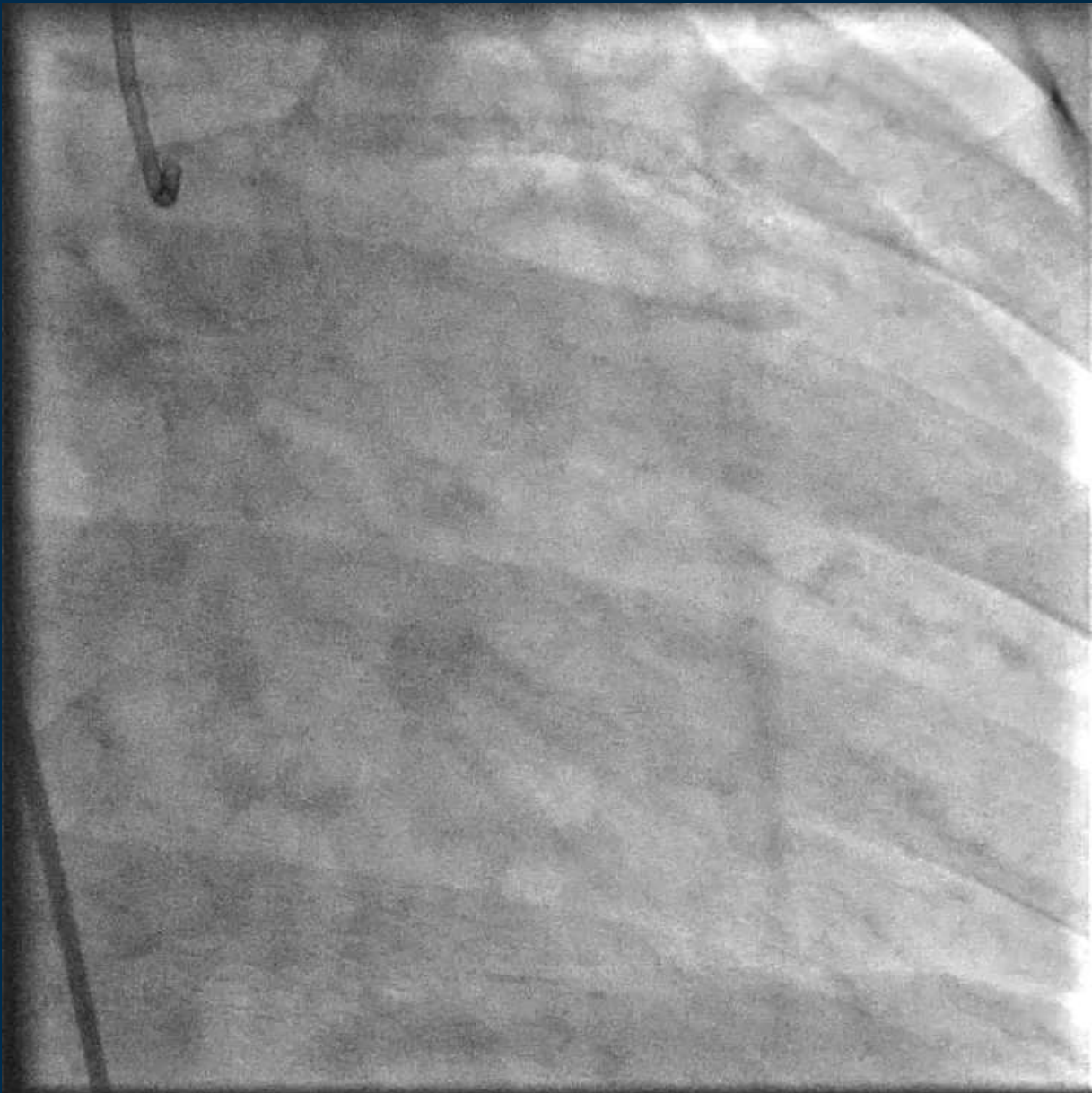


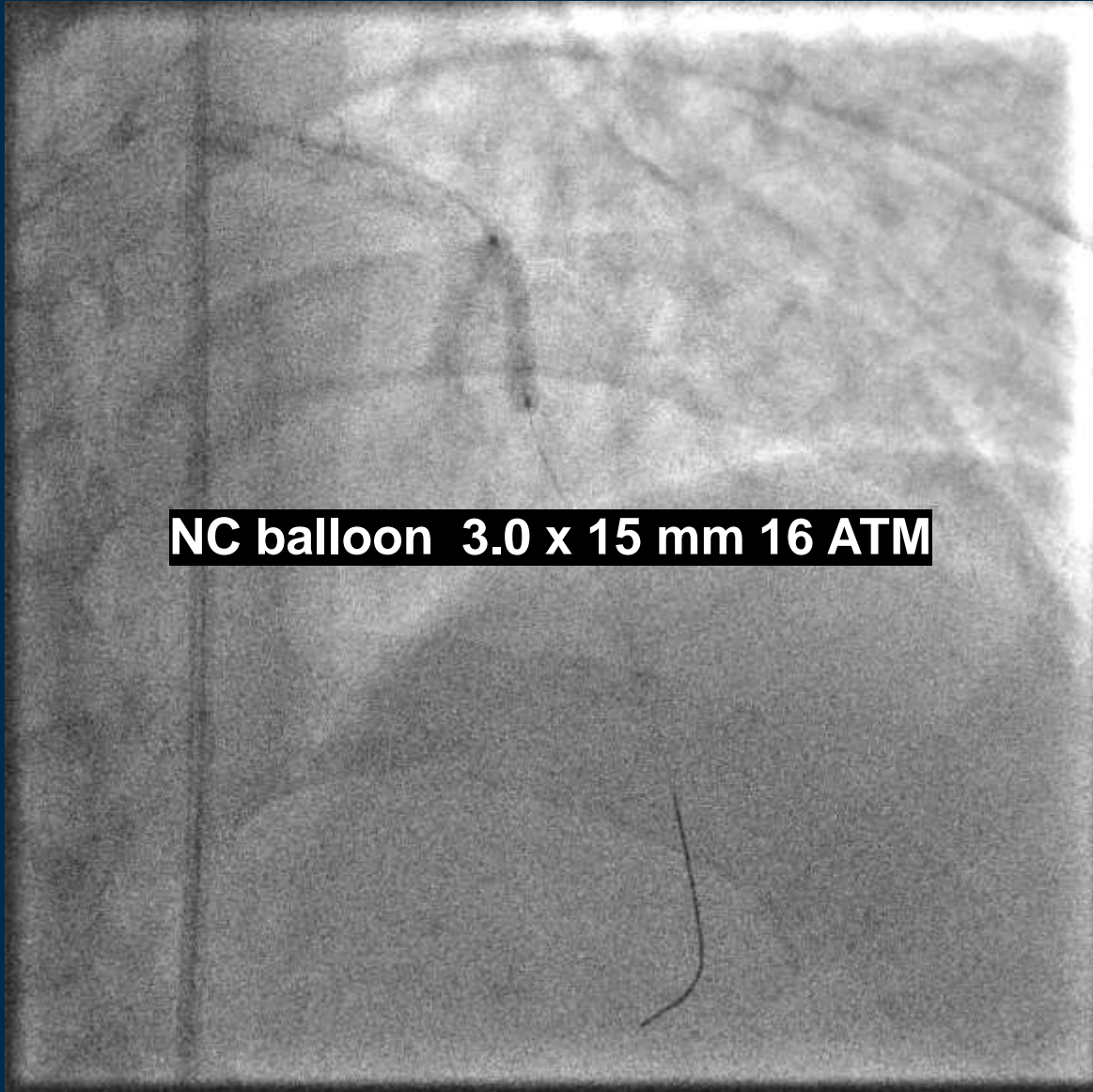


Change from Clopidogrel to Ticagrelor

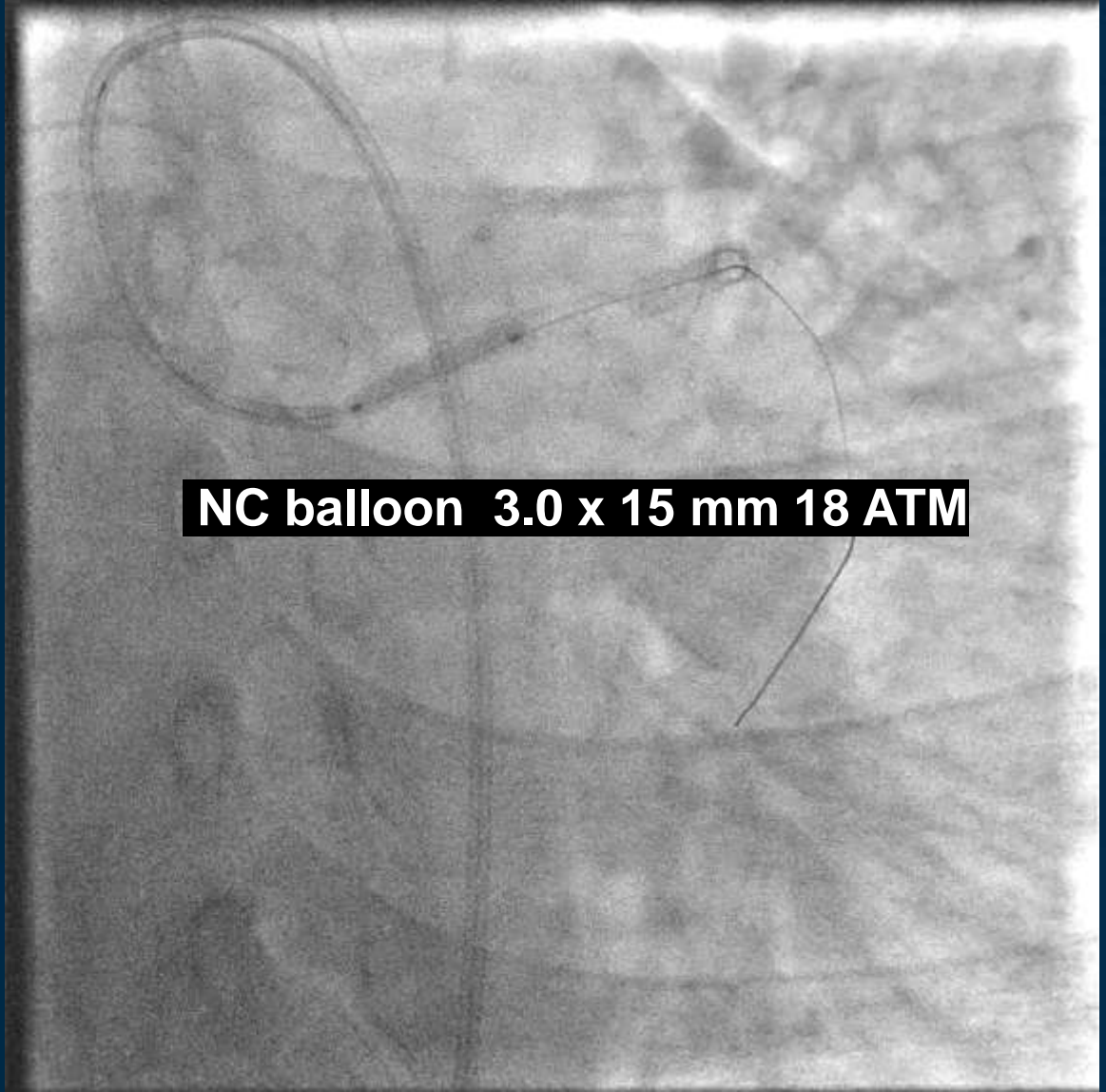
3 months later

- Amputation at left foot was planned
- She had angina on exertion
- Sent for pre-op Coronary angiogram

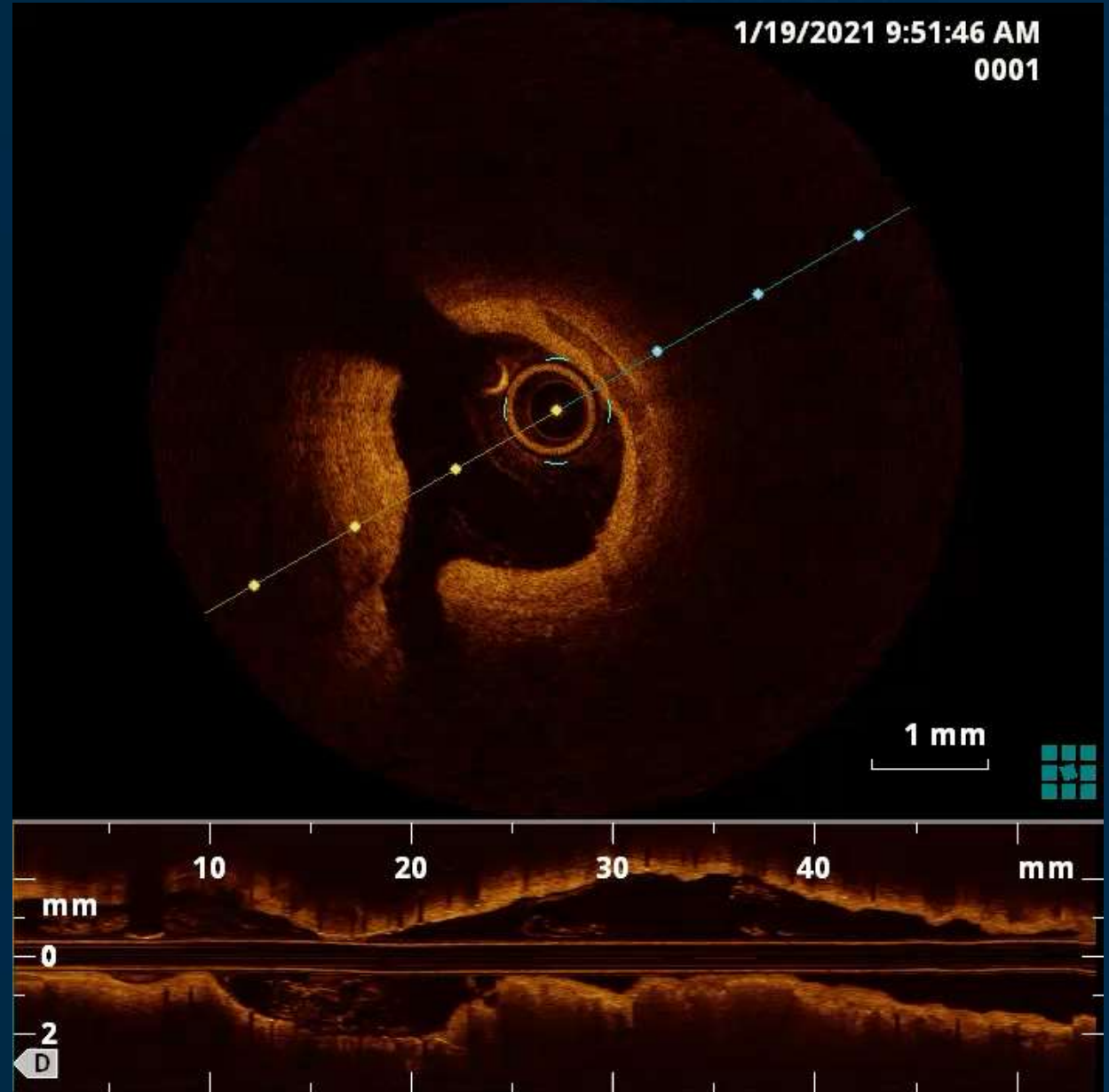
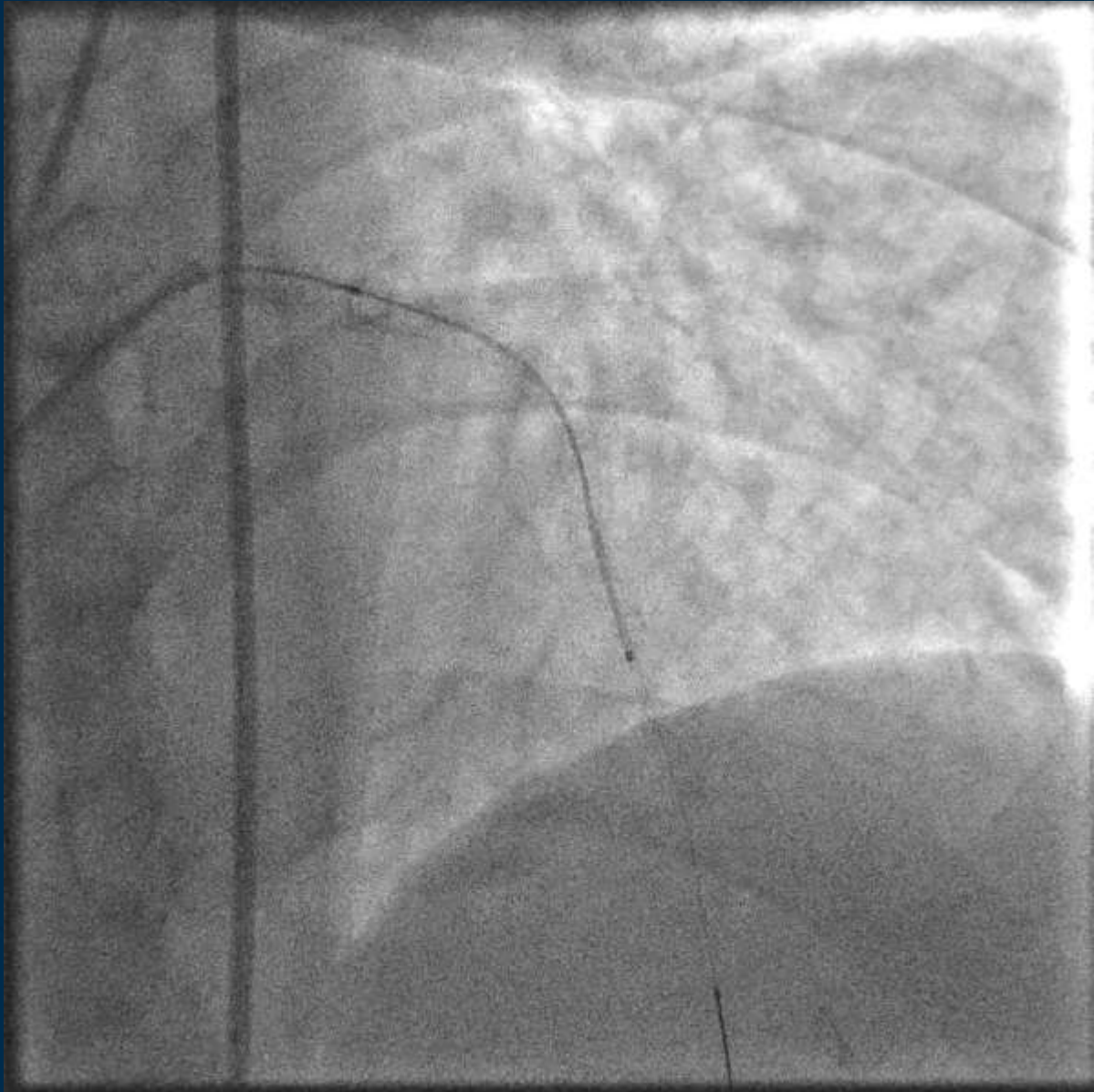


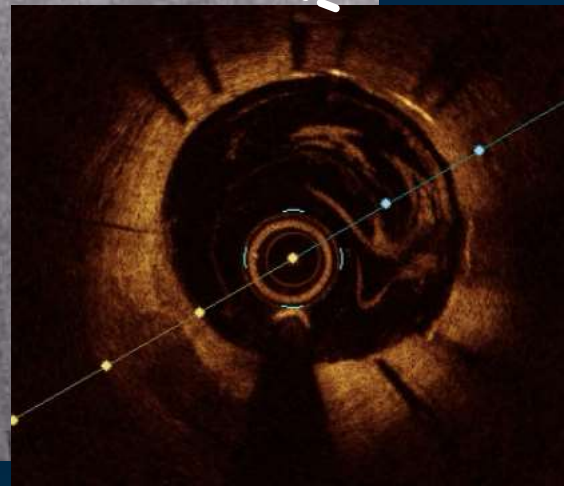
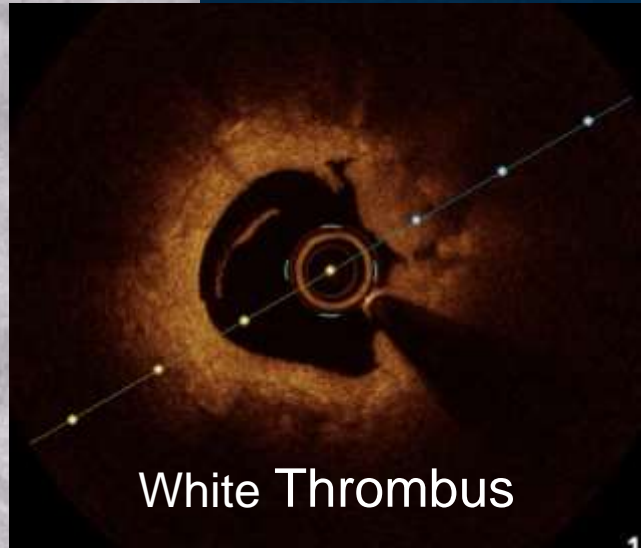
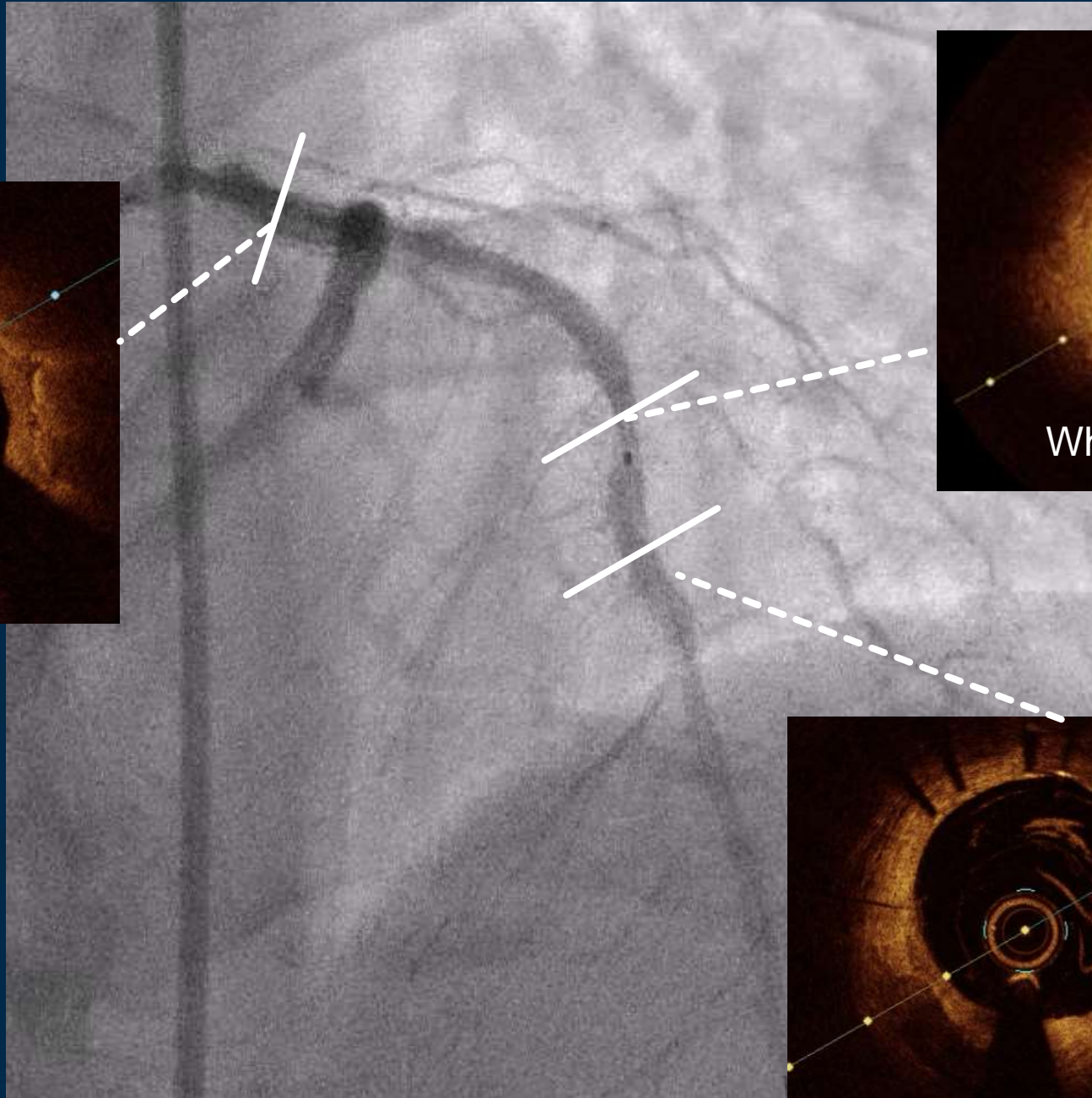
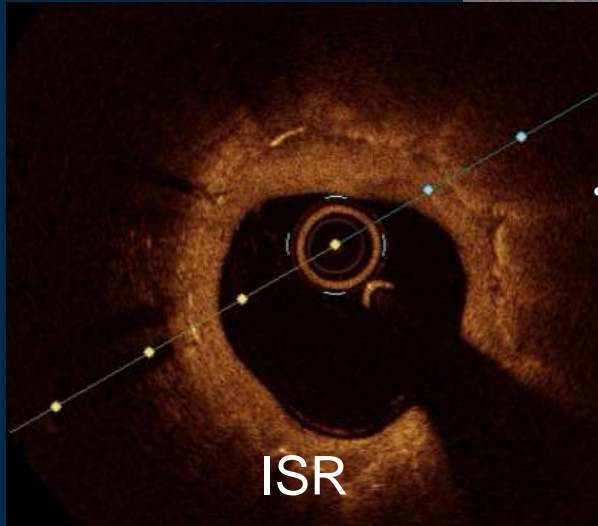


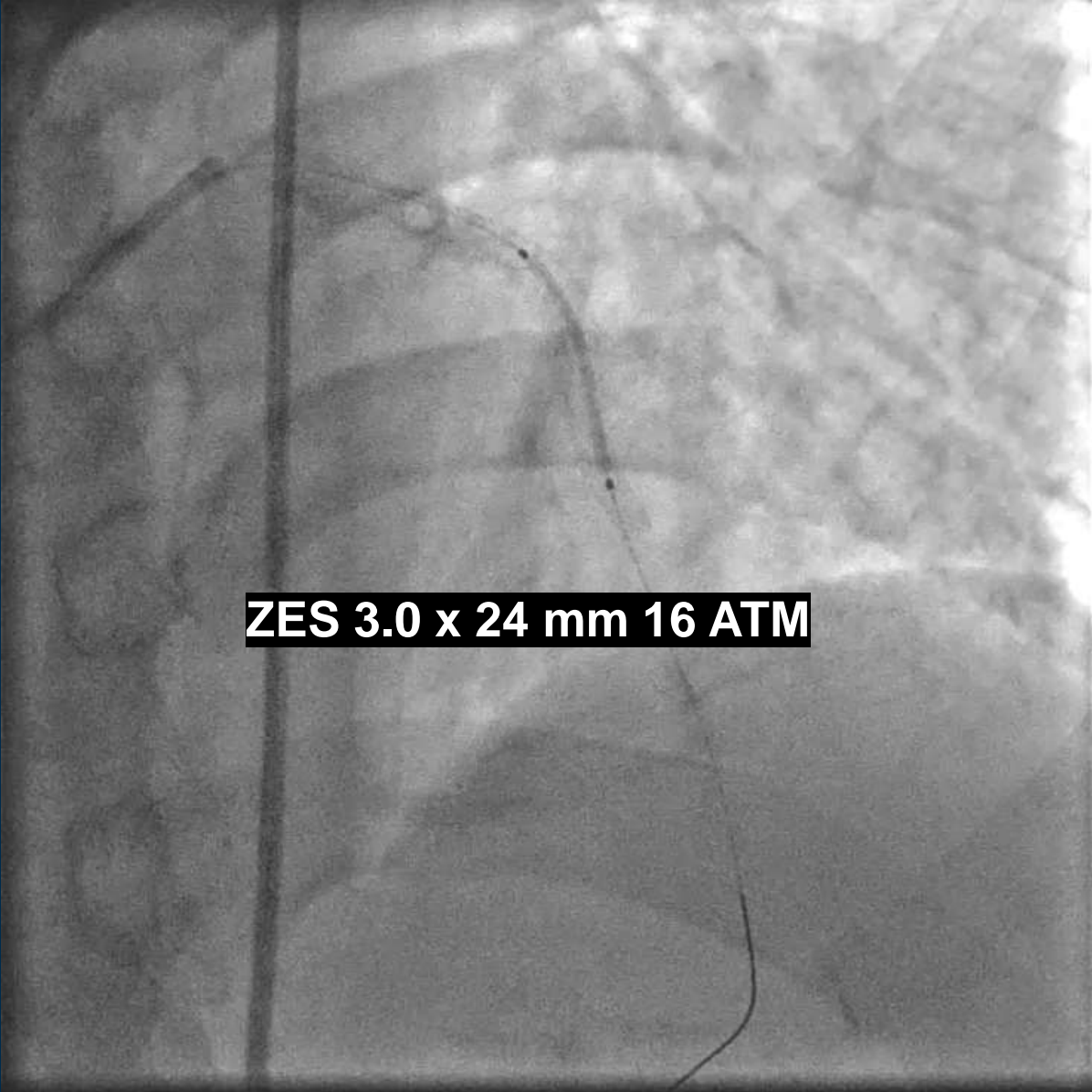
NC balloon 3.0 x 15 mm 16 ATM



NC balloon 3.0 x 15 mm 18 ATM

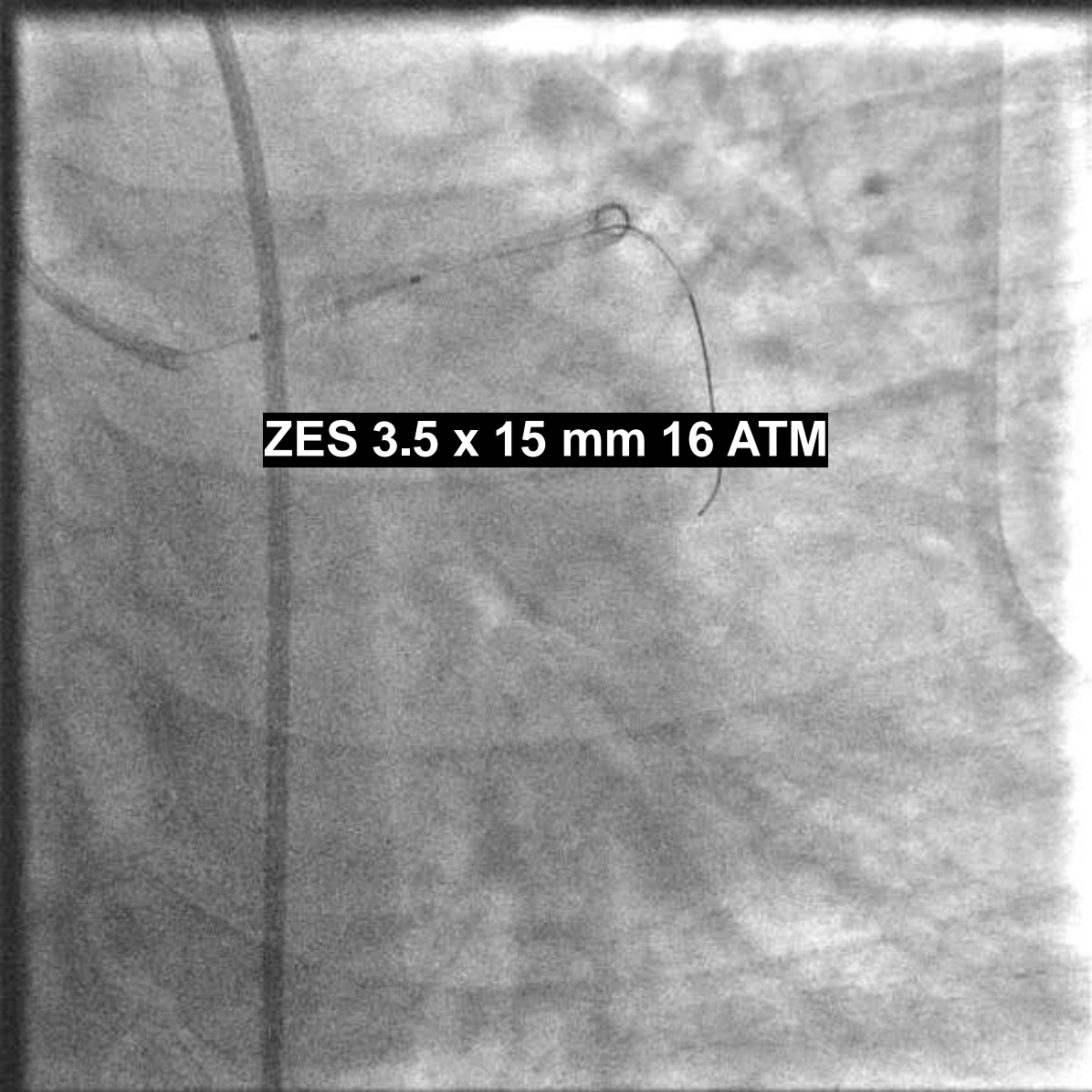






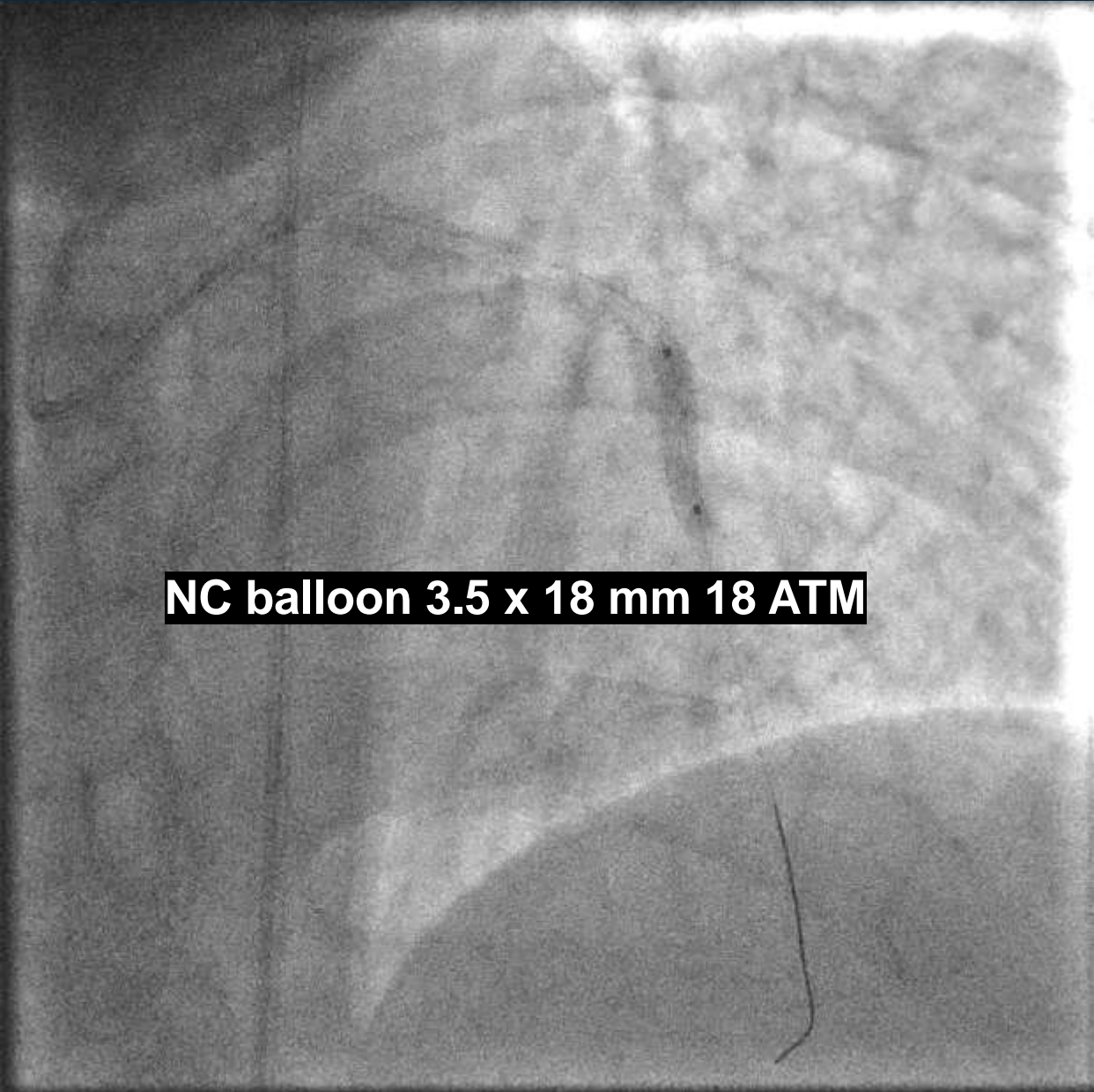
ZES 3.0 x 24 mm 16 ATM

This is a grayscale fluoroscopic image showing a catheter inserted into a blood vessel. The catheter is positioned in the lower portion of the vessel, with its tip curved. The vessel lumen is visible as a lighter area, and the vessel wall is darker. The overall image has a grainy texture.

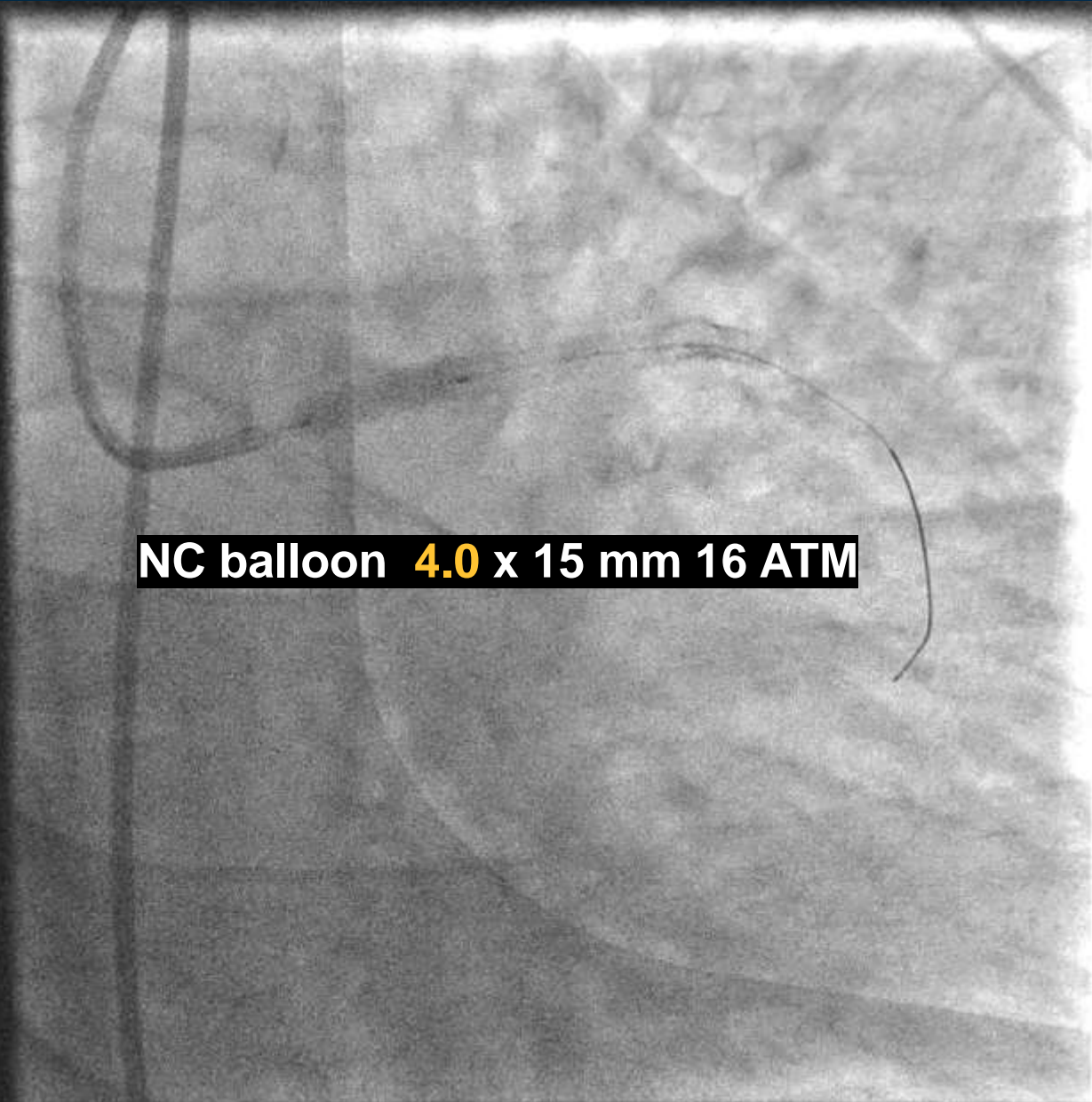


ZES 3.5 x 15 mm 16 ATM

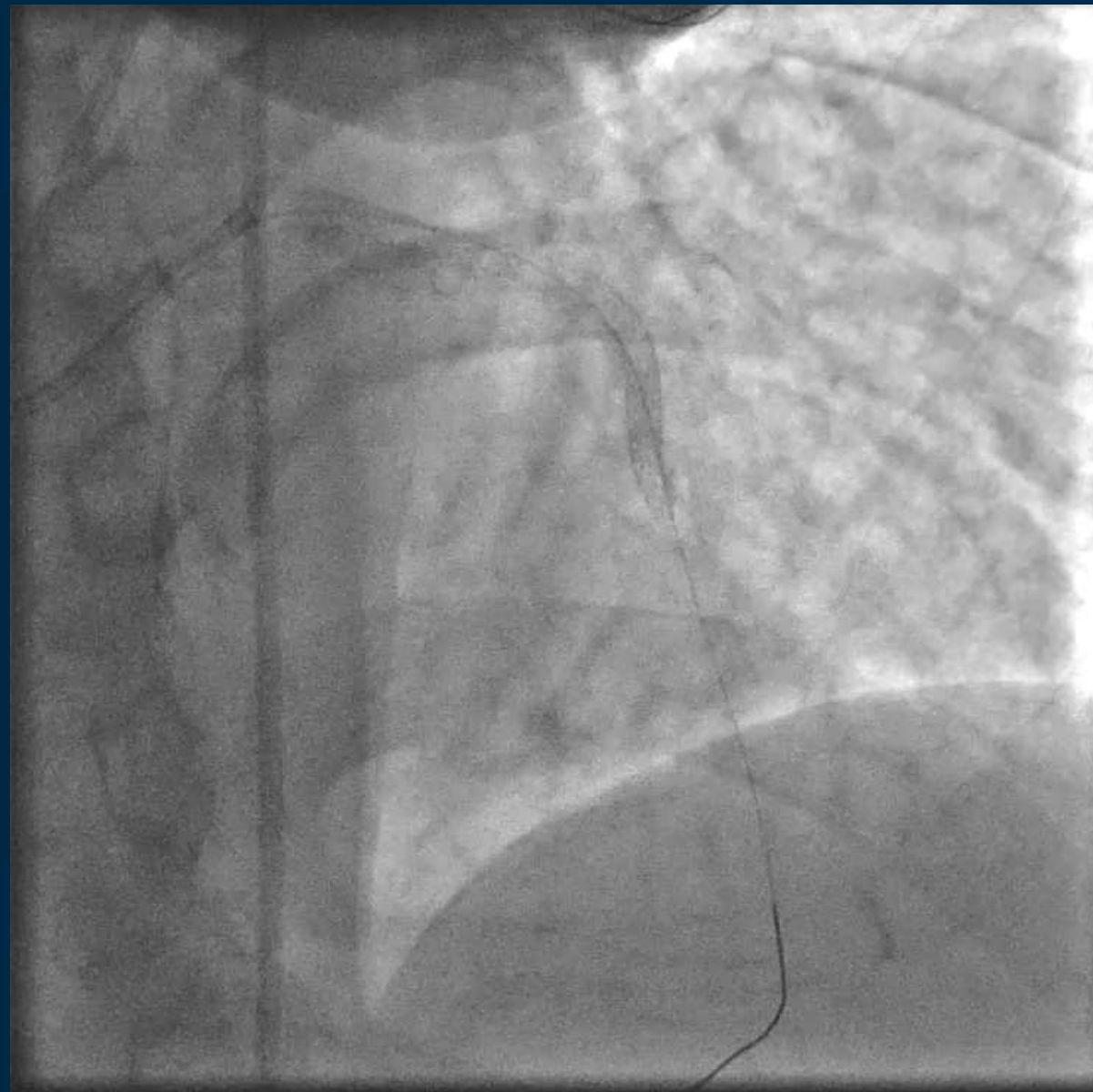
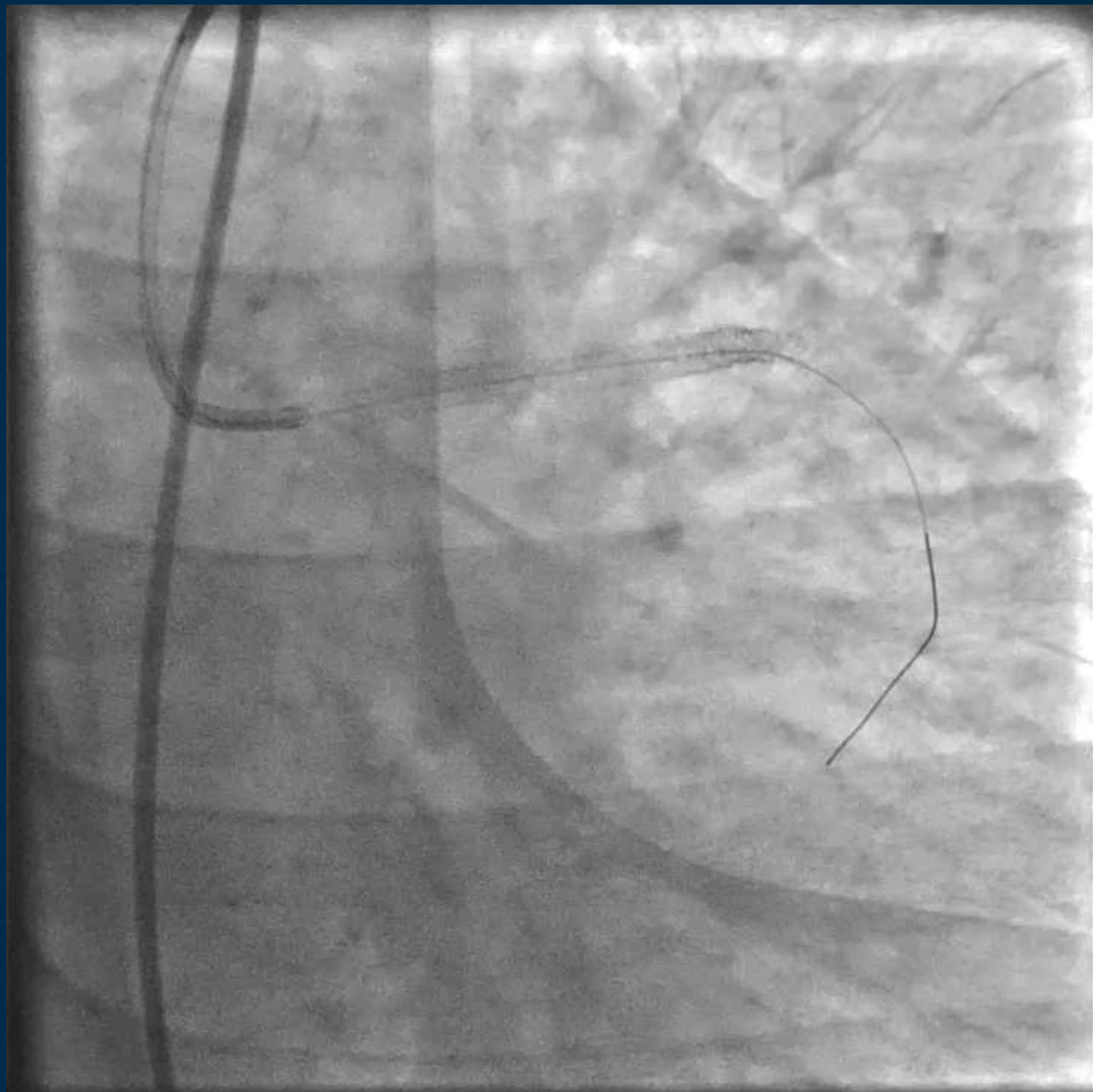
This is a grayscale fluoroscopic image showing a catheter inserted into a blood vessel. The catheter is positioned in the upper portion of the vessel, with its tip curved. The vessel lumen is visible as a lighter area, and the vessel wall is darker. The overall image has a grainy texture.



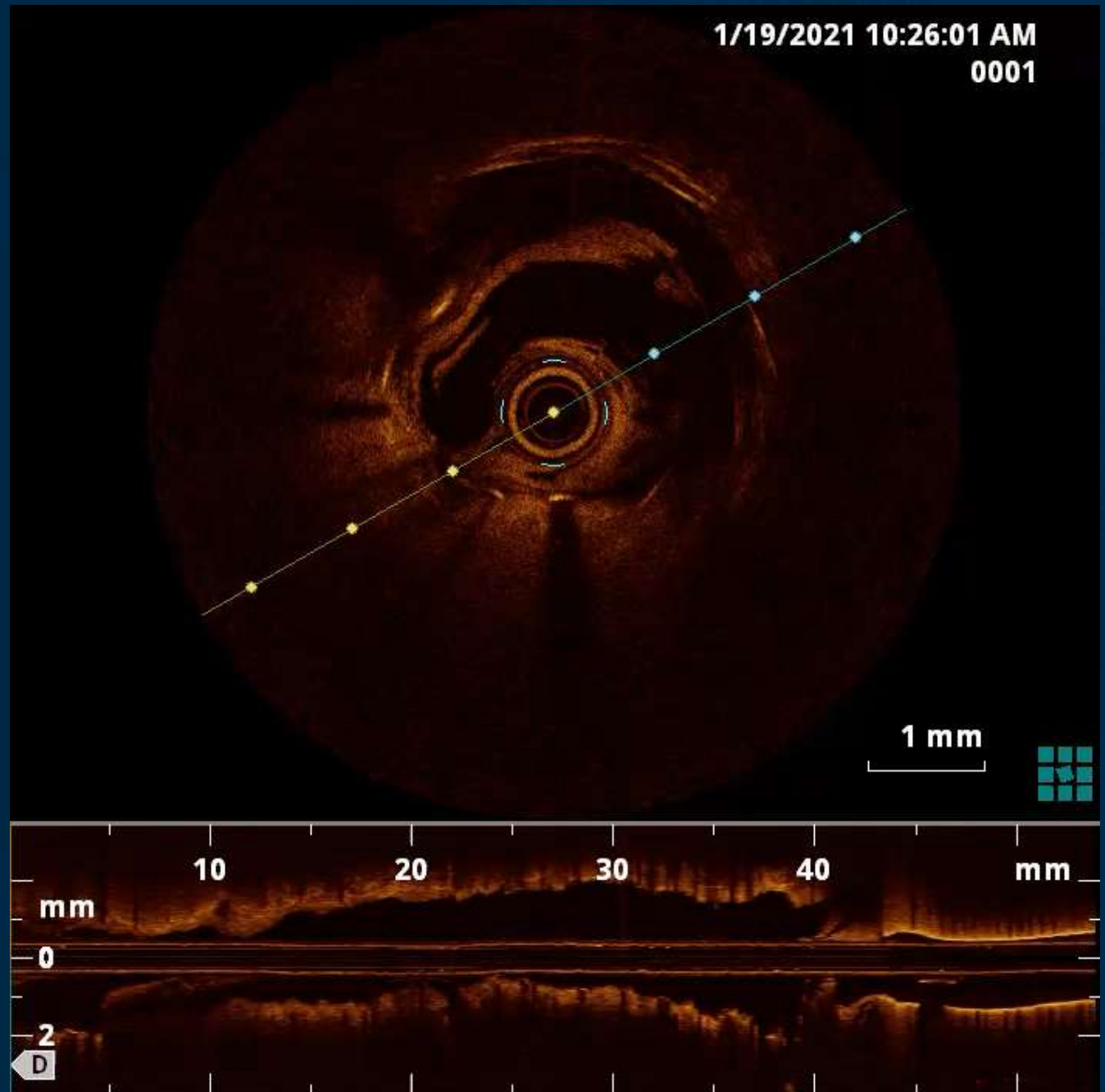
NC balloon 3.5 x 18 mm 18 ATM

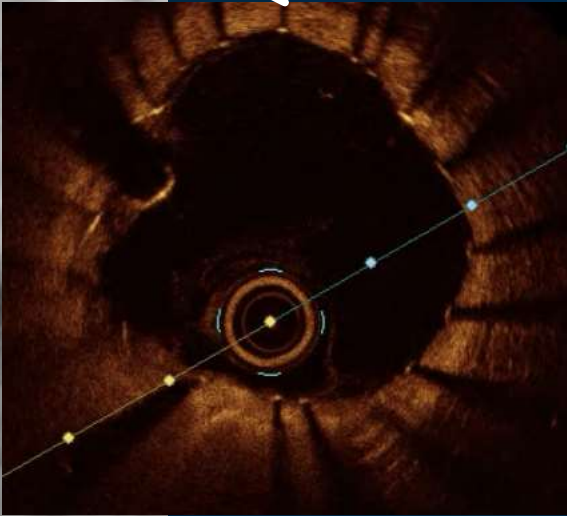
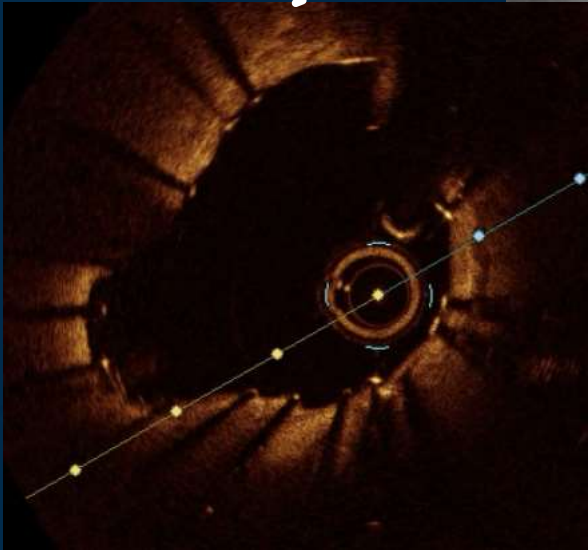
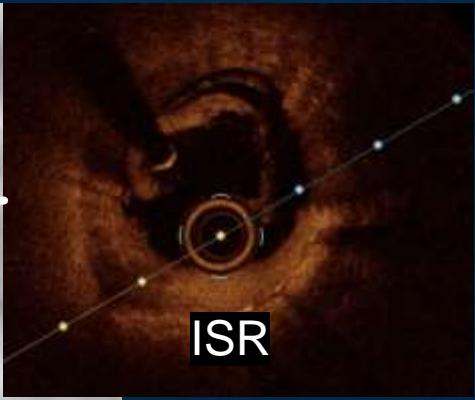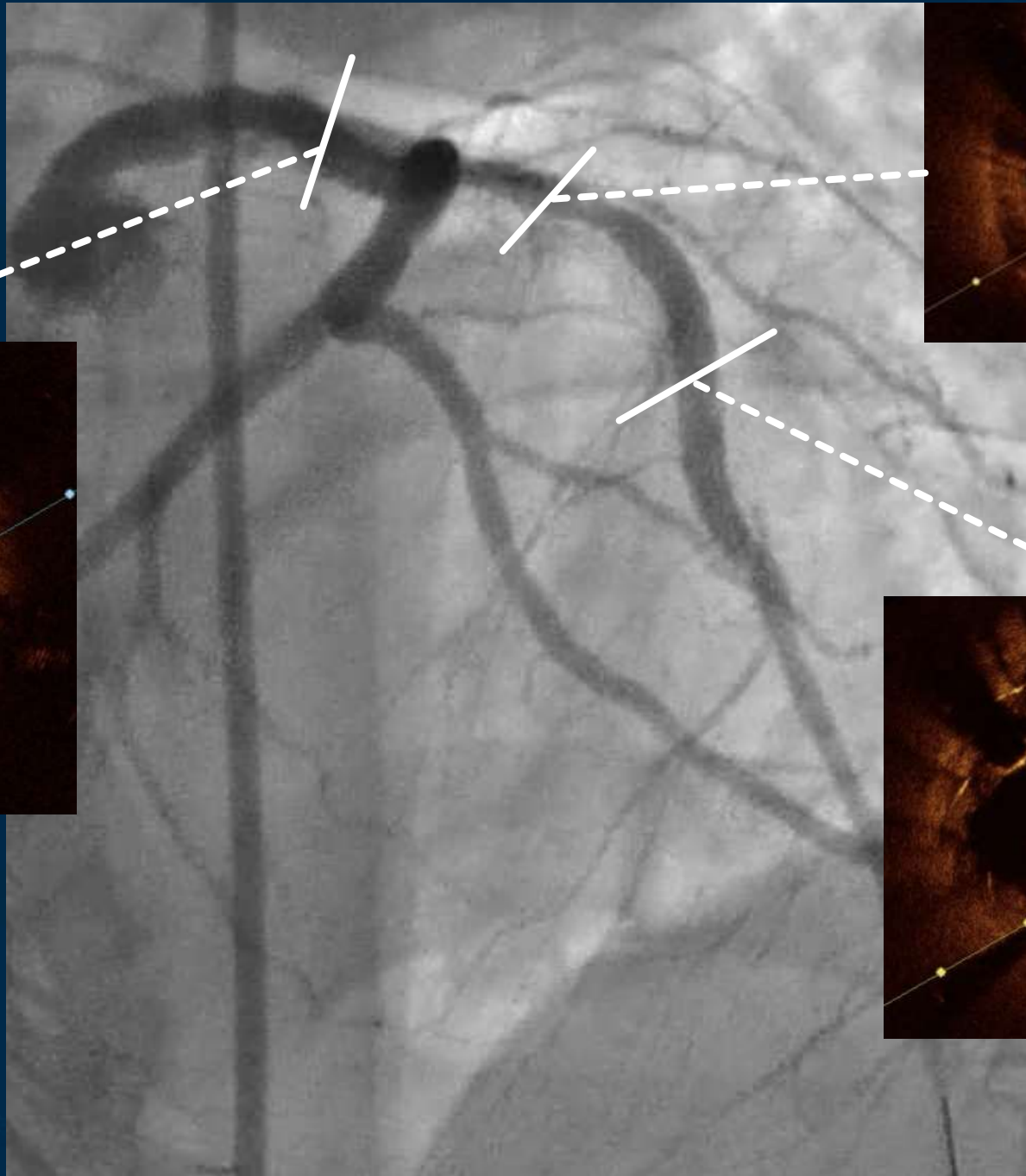


NC balloon 4.0 x 15 mm 16 ATM



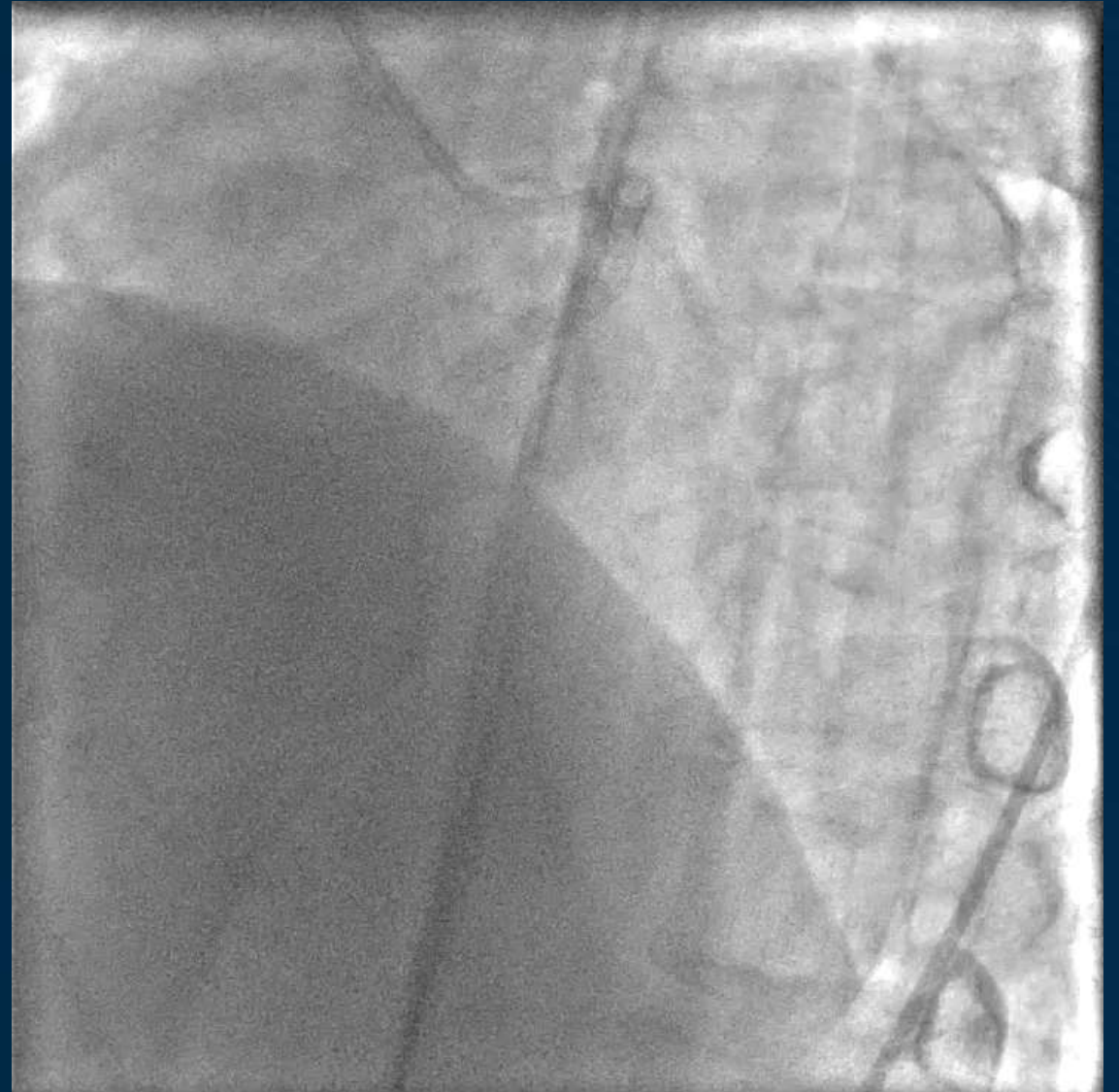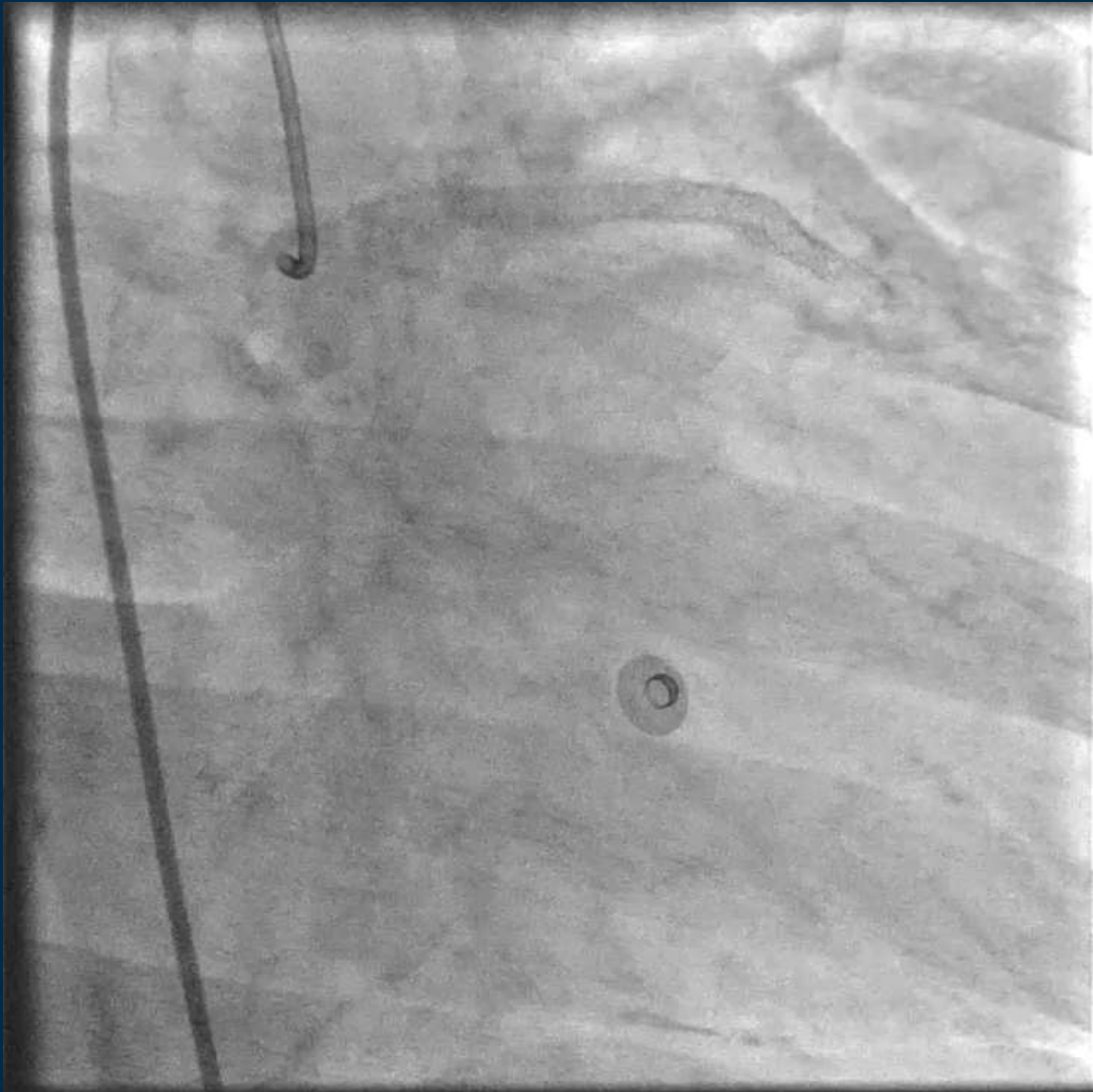
Final OCT

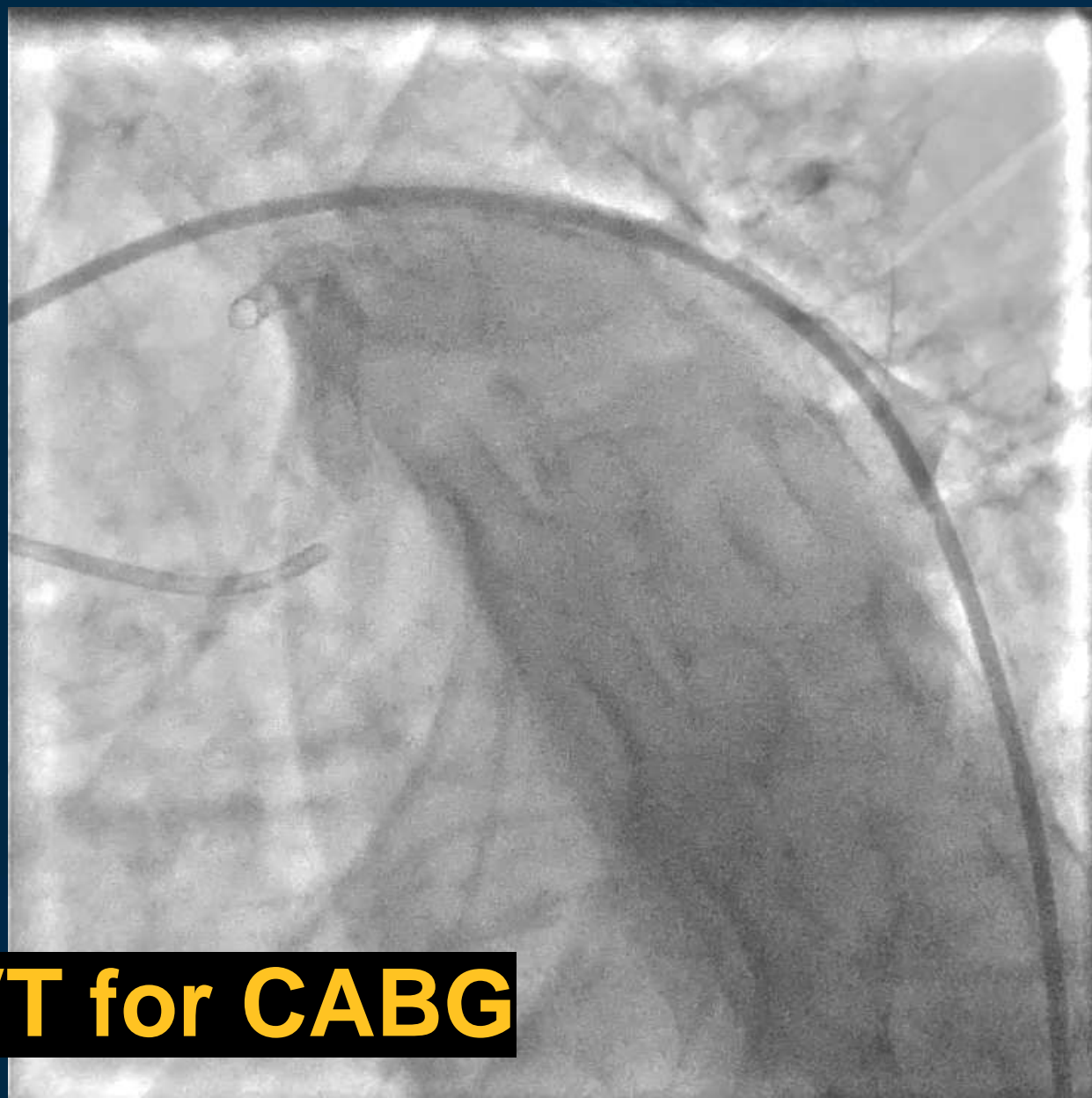
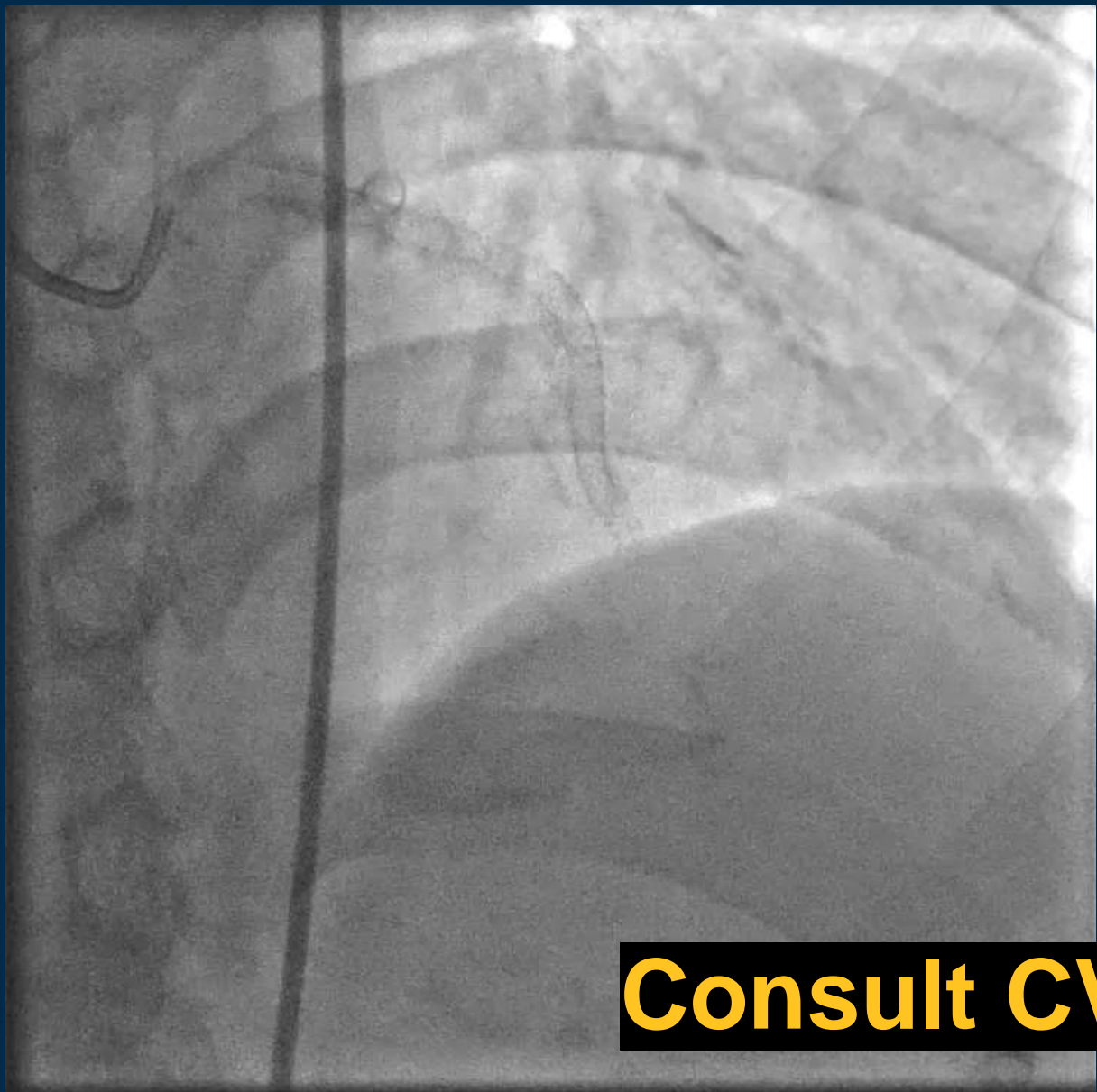




6 months later

- 1 week chest pain radiate to neck and developed intradialysis hypotension
- Troponin 2,916 ng/ml





Consult CVT for CABG

Discussion Points

- What are the OCT findings ?
- What are the mechanisms of recurrent stent failure?
- What interventions could we do to modify the outcome?"

Conclusion

- ESRD is a significant risk factor for stent failure.
- The initial PCI is a critical determinant of the long-term prognosis.
- OCT can identify the underlying cause of stent failure and facilitate stent optimization.