

INTERESTING CASE PRESENTATION

중앙 보훈 병원
김 일 권

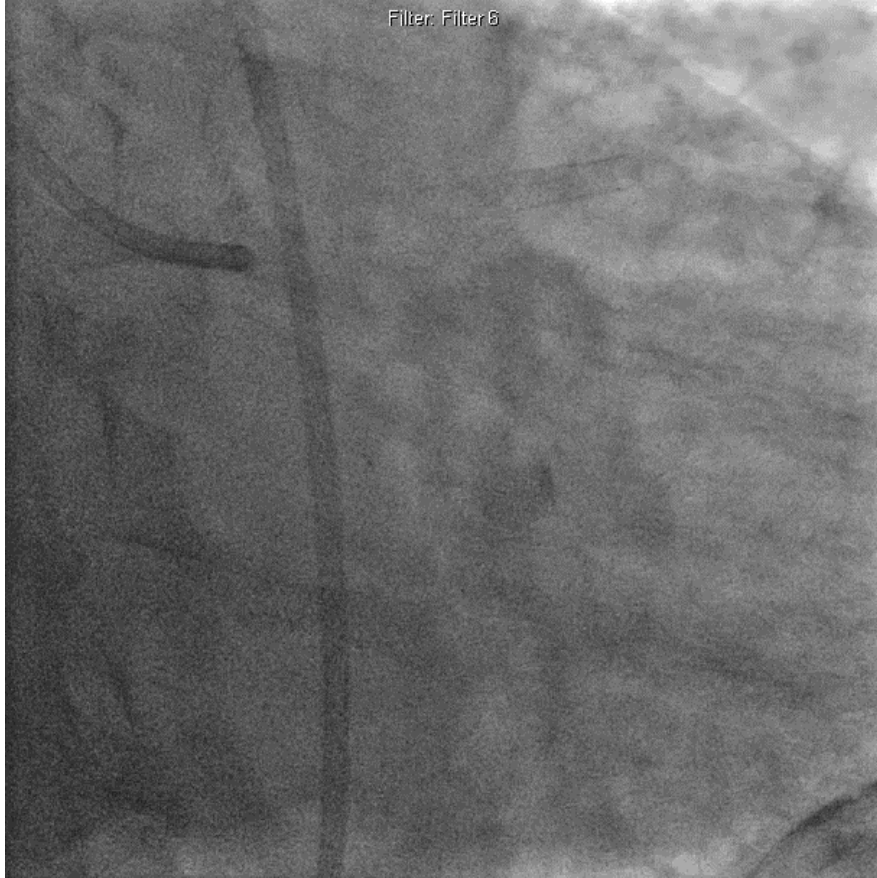
CASE 1

- 72y Male
- 2008 2VD (LAD,RCA), stent insertion on pLAD to mLAD.
- 2010 pLAD ISR, stent insertion on LM to pLAD including ISR.
- 2015 Chest pain 외래 경유 입원.
- TMT positive → CAG

2010년 PCI

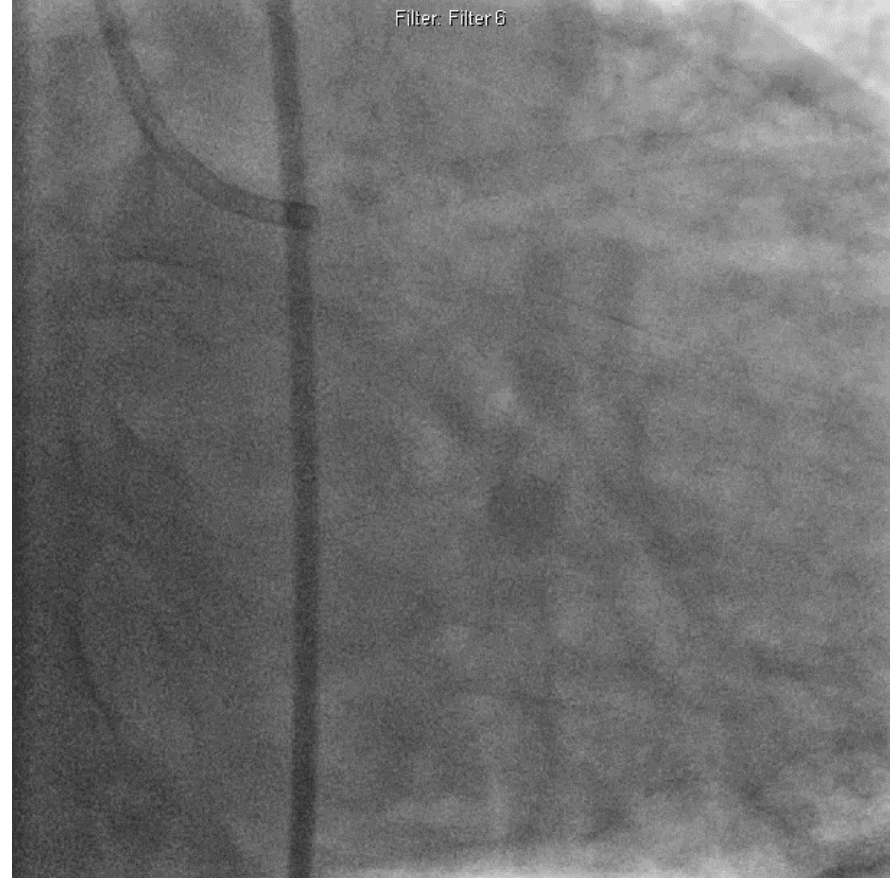
PRE

Filter: Filter6

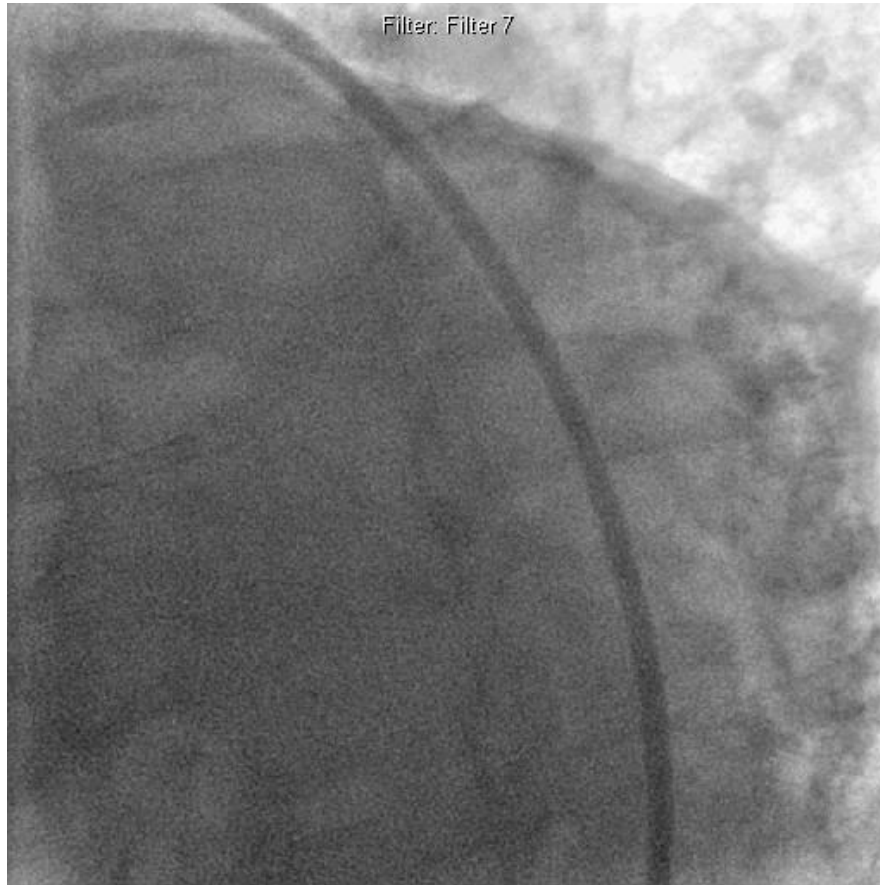

POST

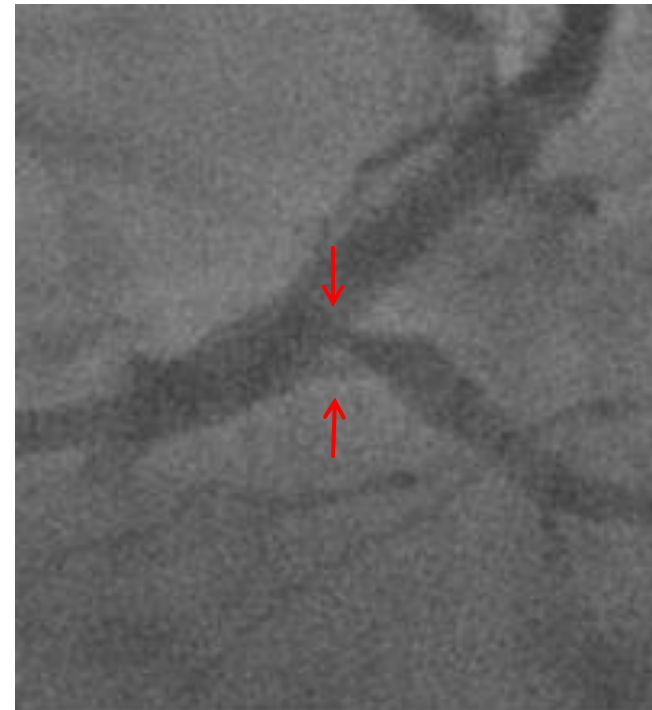Filter: Filter6



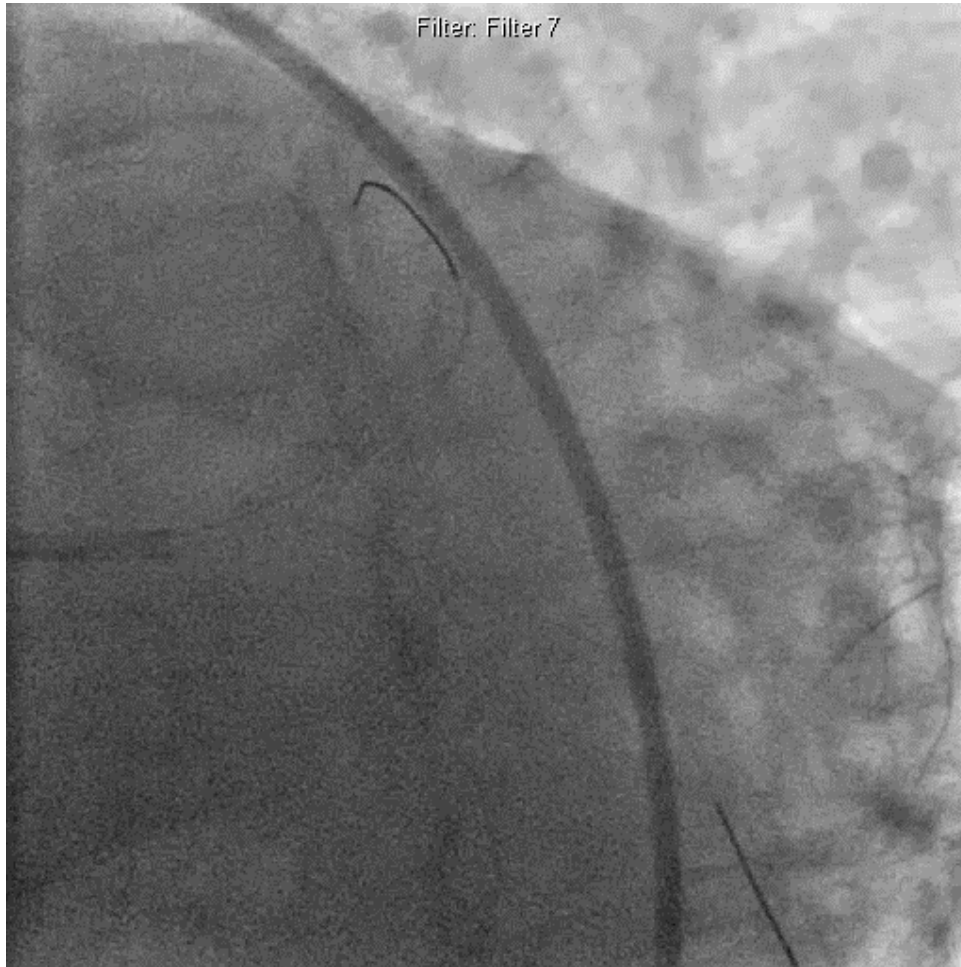
2015 PRE – ANGIO IMAGE



SPIDER VIEW



2015 PRE – ANGIO IMAGE



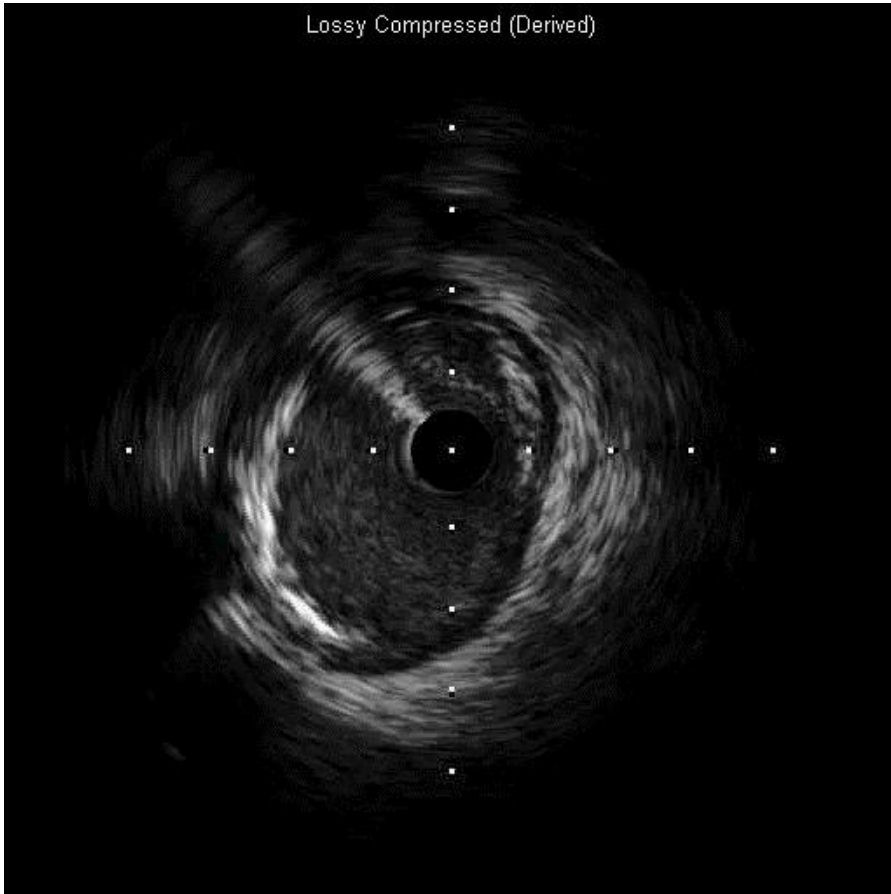
SPIDER VIEW

PASSED WIRE
INTO
LAD & LCX

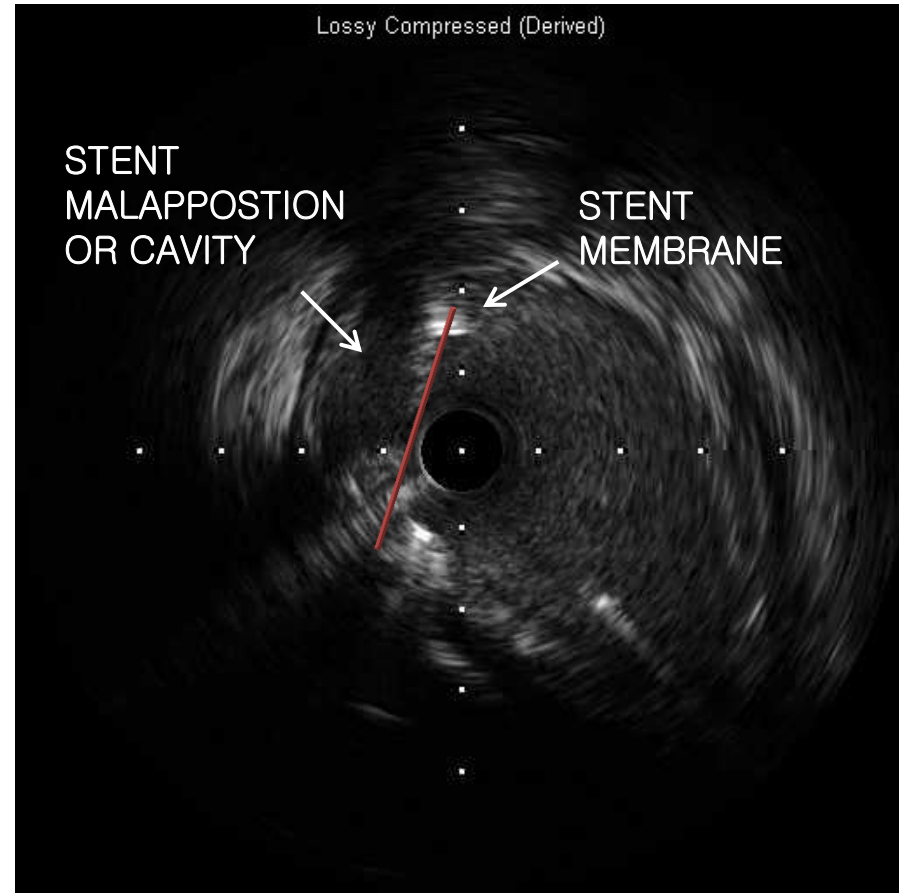
LCX PRE IVUS

LCX to LM

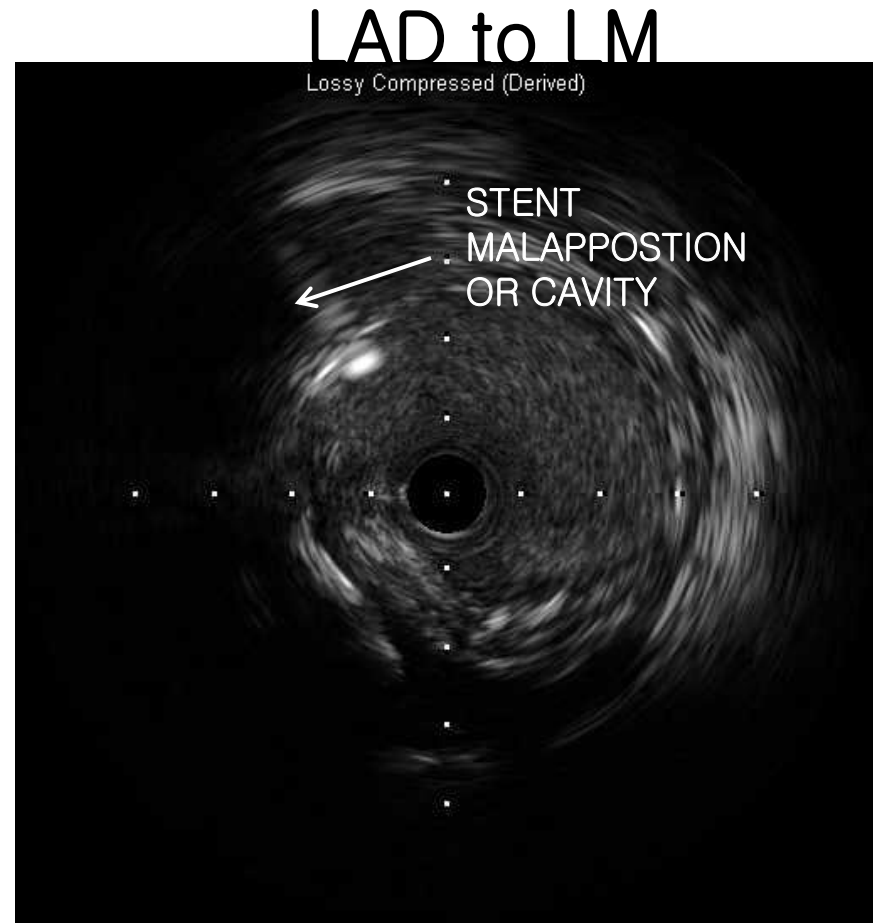
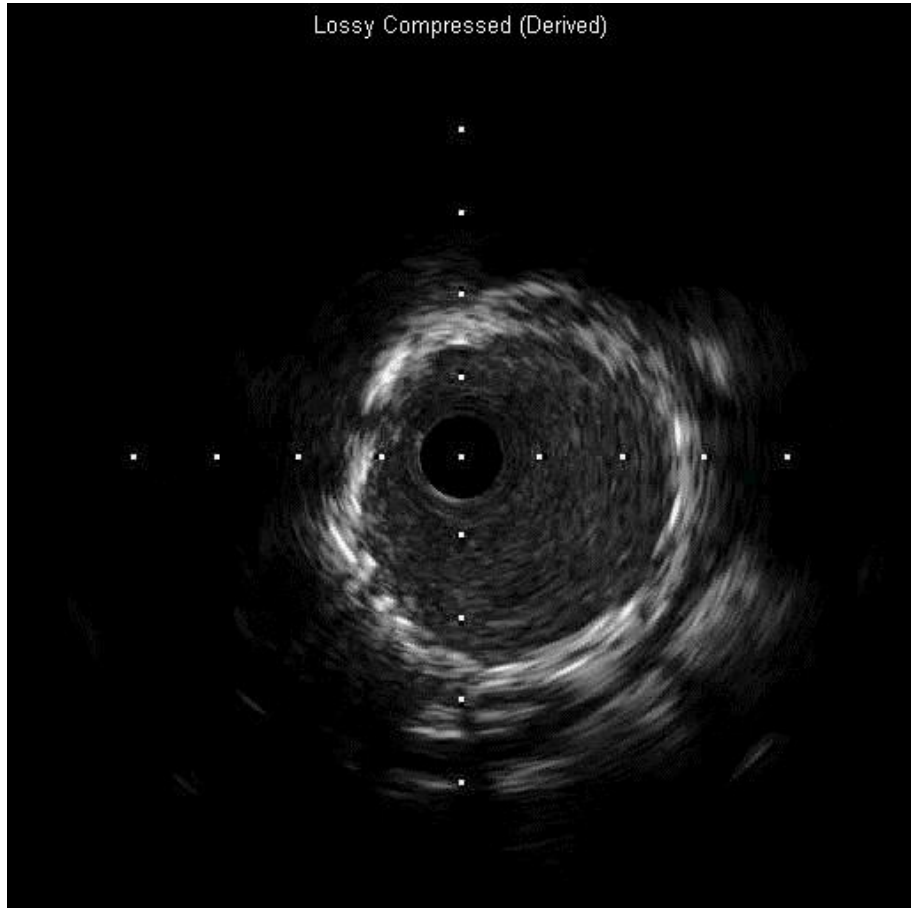
Lossy Compressed (Derived)



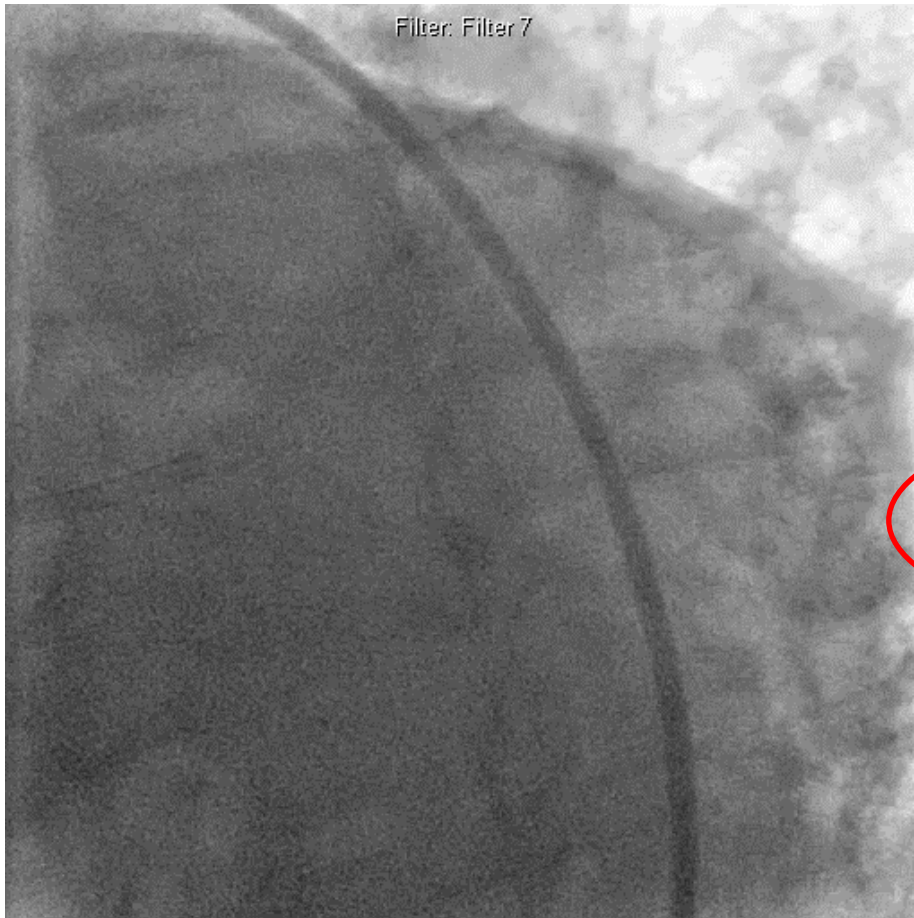
Lossy Compressed (Derived)



LAD PRE IVUS



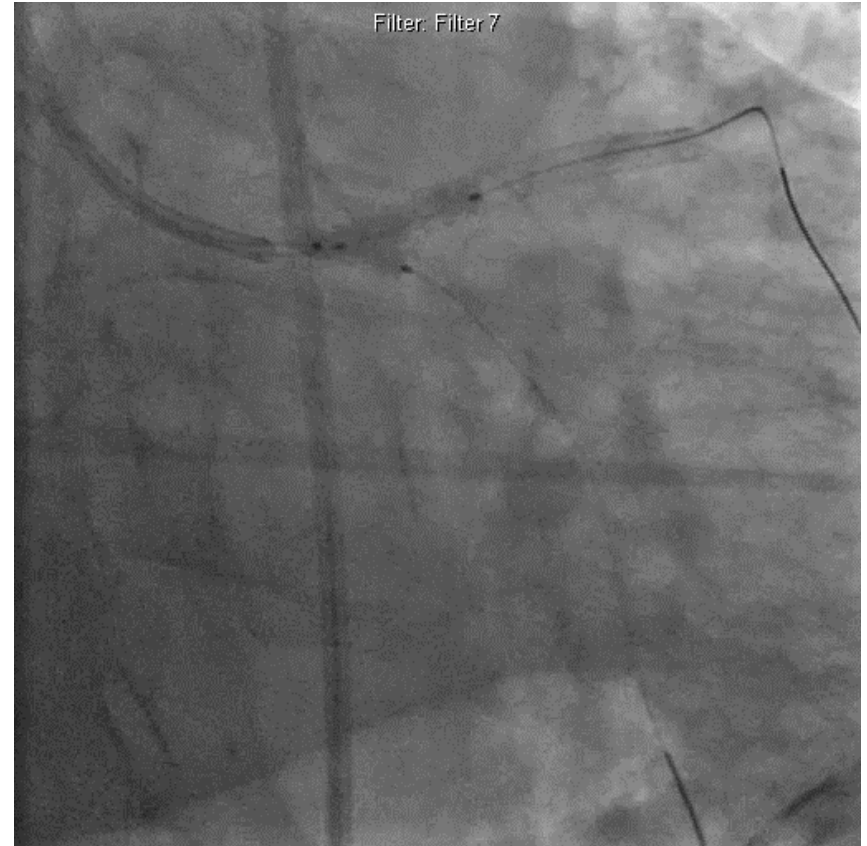
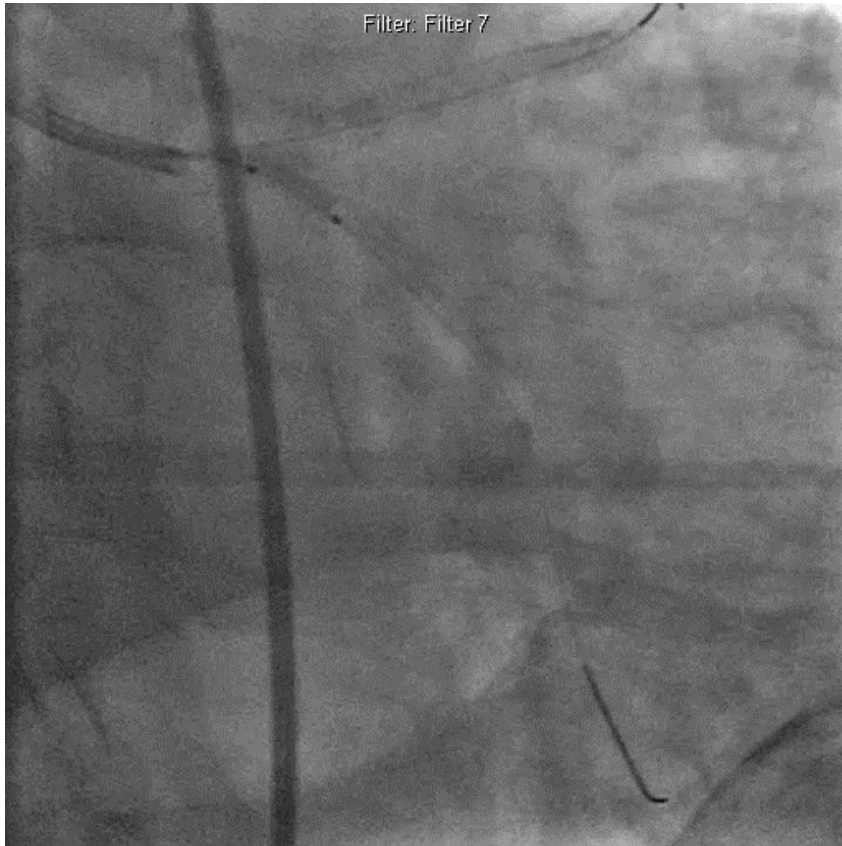
WHAT IS YOUR CHOICE ?



- LET IT BE?
- STENT INSERTION?
- BALLOON OR KISSING BALLOON?
- OTHERS ? FFR ?


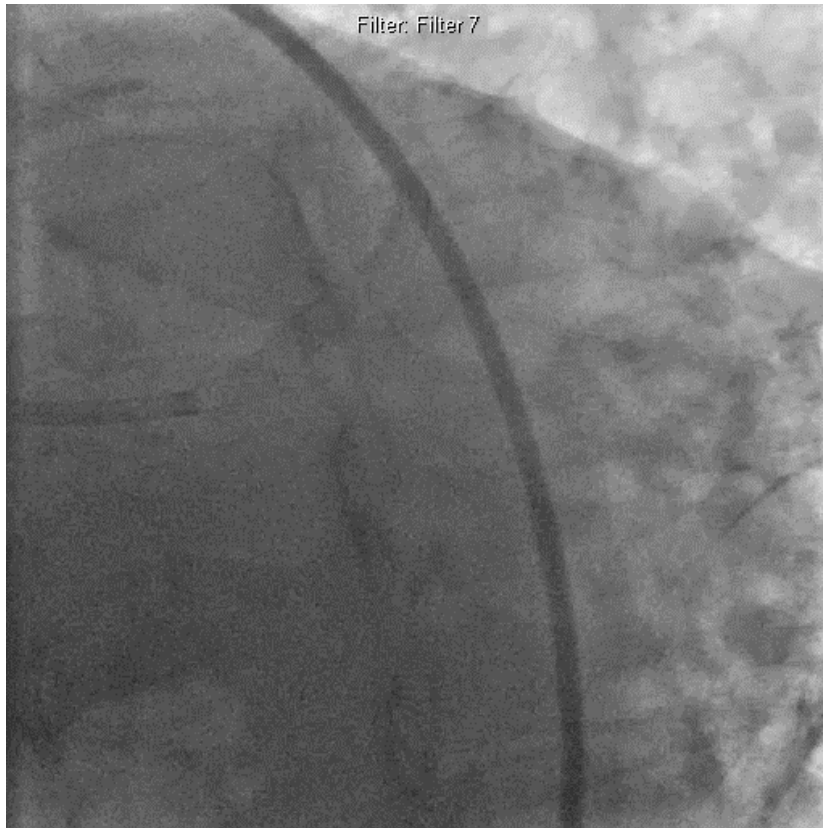
KISSING BALLOON

SPIDER VIEW (TO SHALLOW CAUDAL)



FINAL IMAGE

SPIDER VIEW

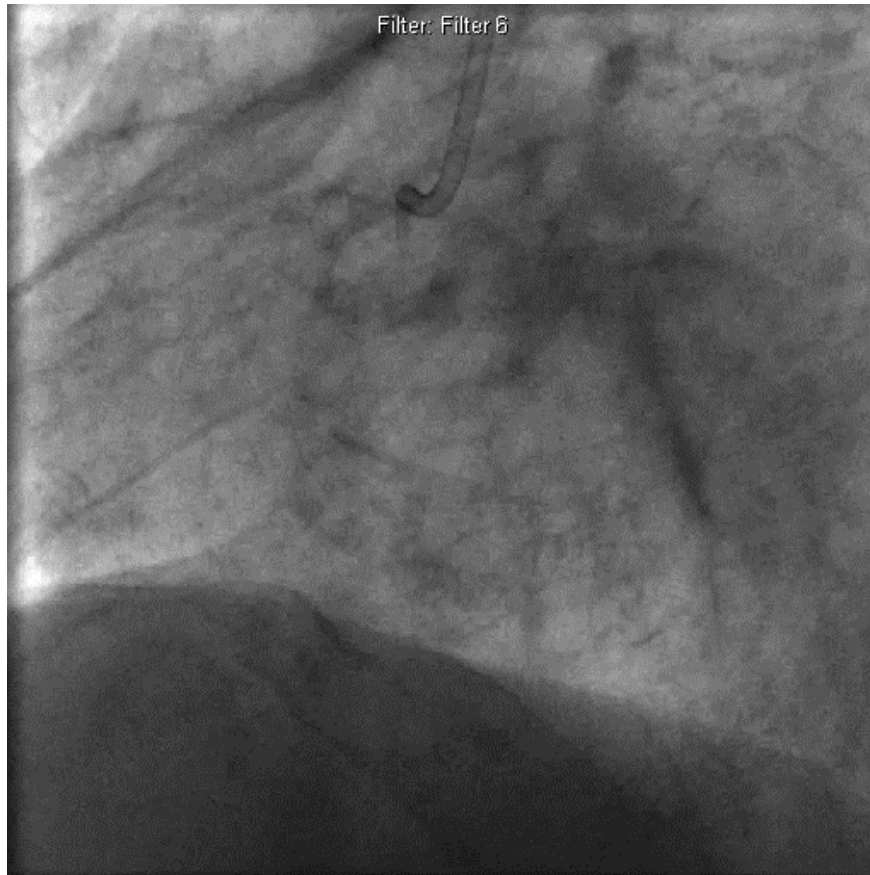


CASE 2

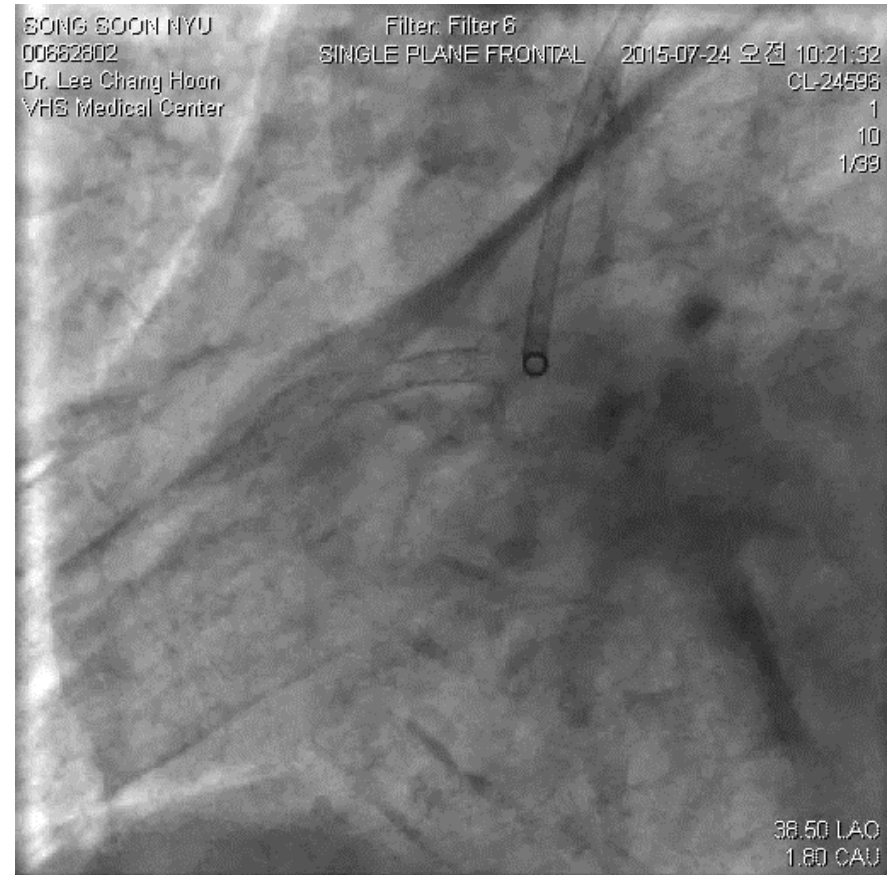- 71y Female
- End Stage Renal Disease (ESRD)
- Hypertension (HTN)
- 핵의학(TL-SCAN)검사에서 Inferior large defect.
- Chest Discomfort 내원 CAG → 3VD PCI

RCA STENT INSERTION

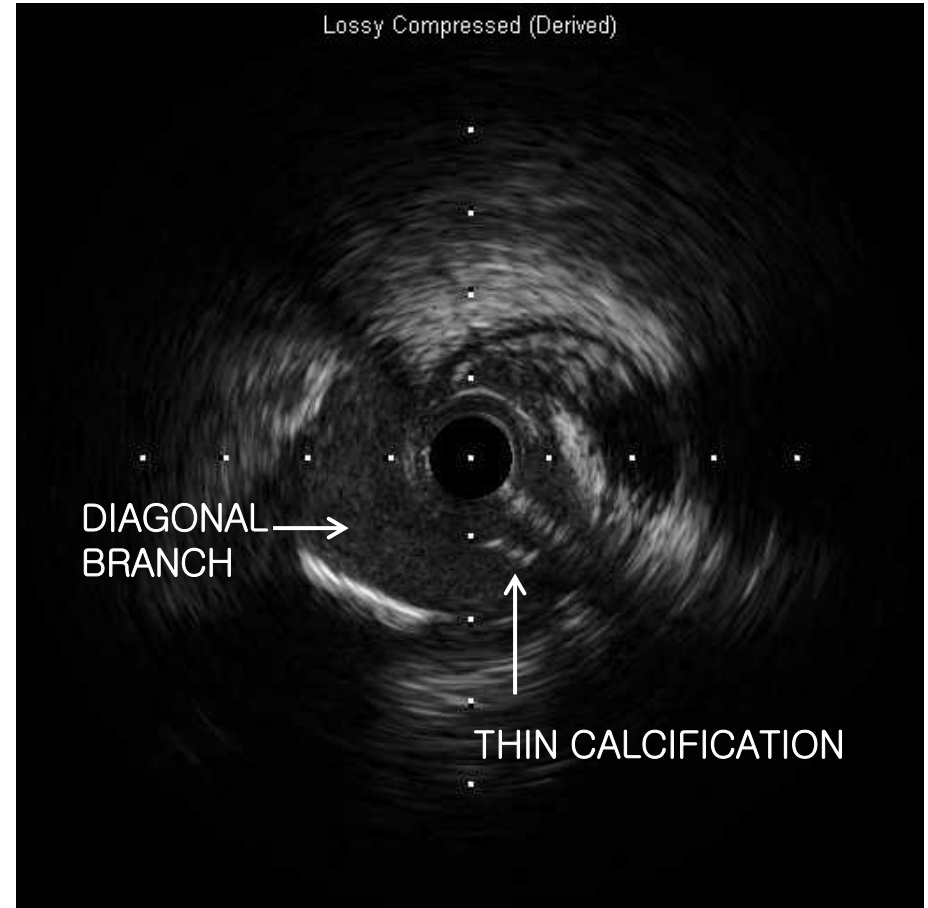
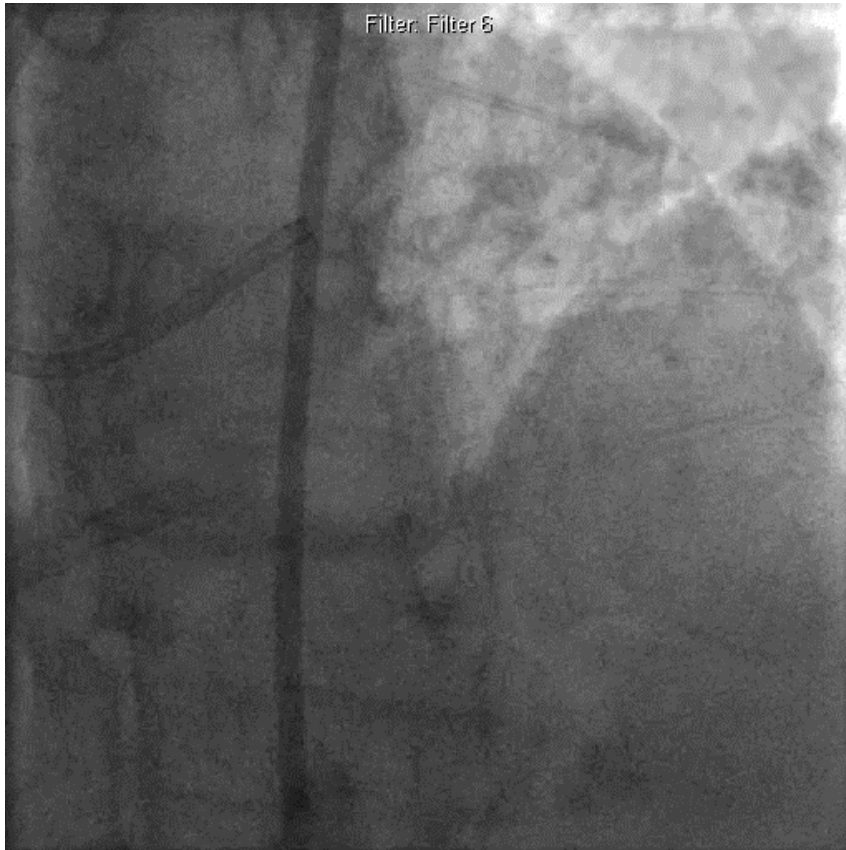LAO VIEW



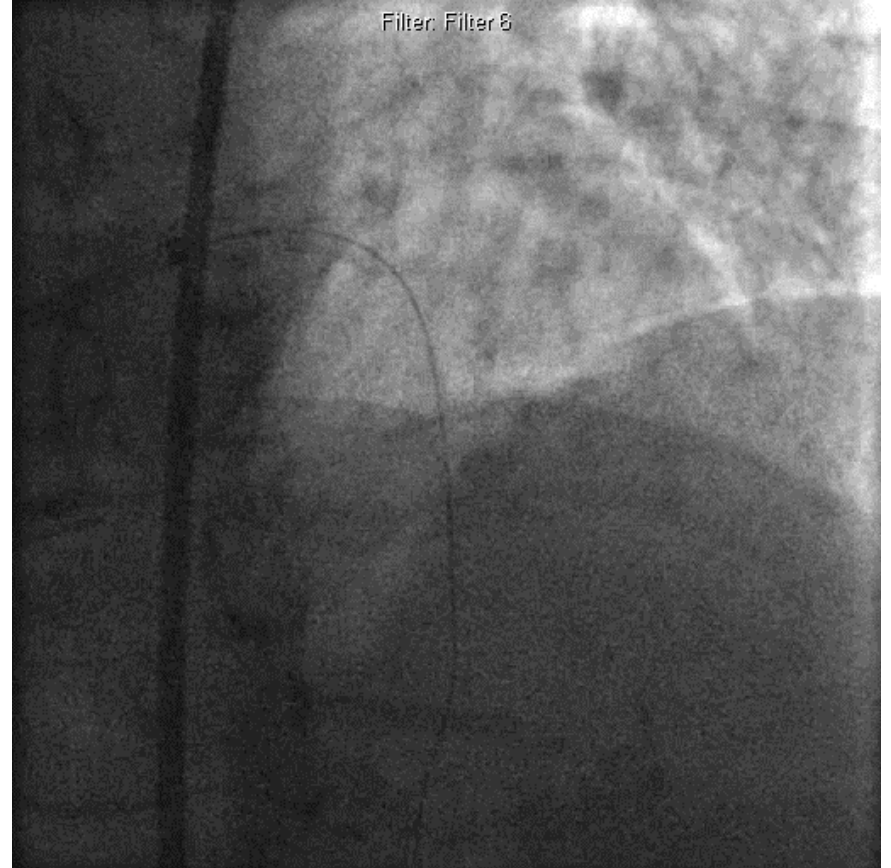
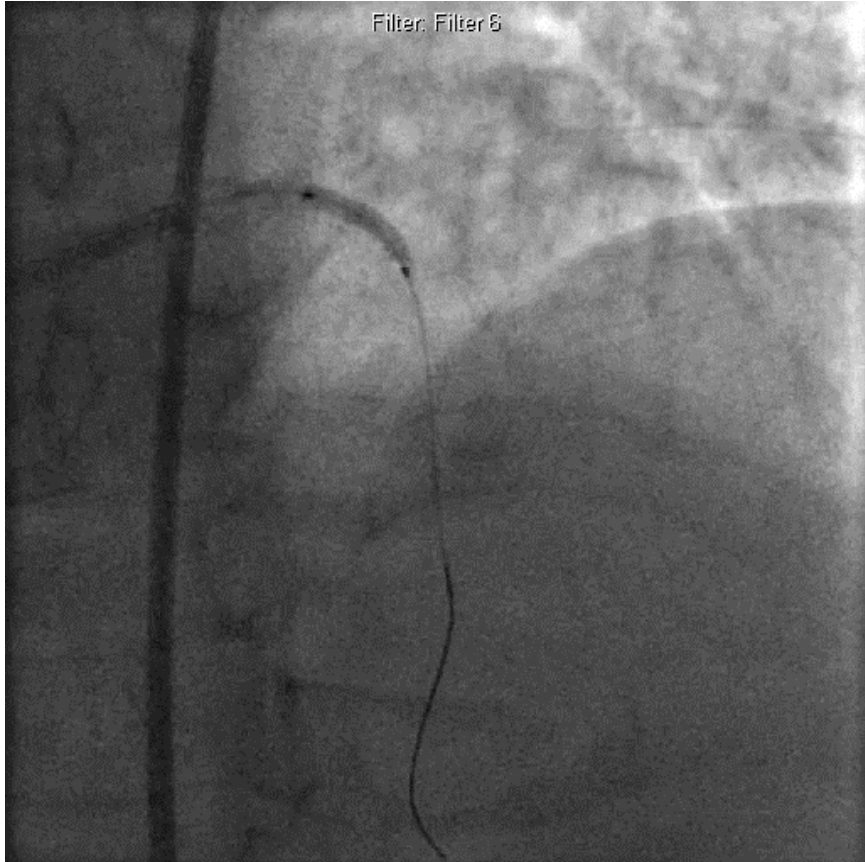
AP VIEW



PRE IMAGE

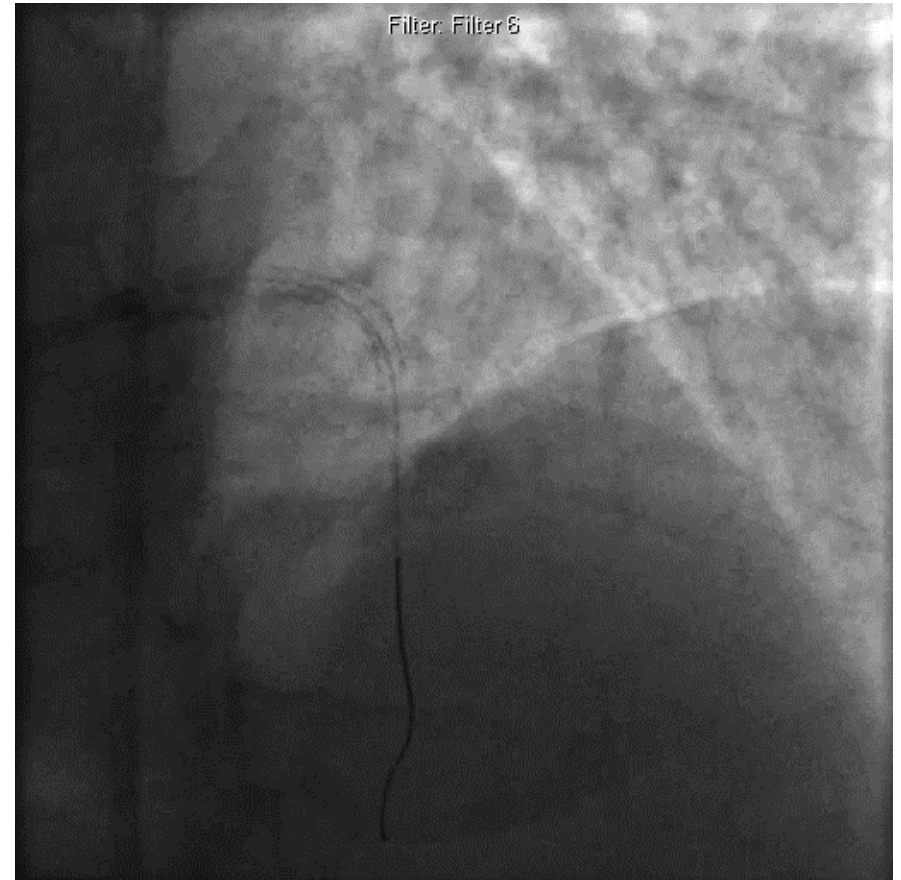
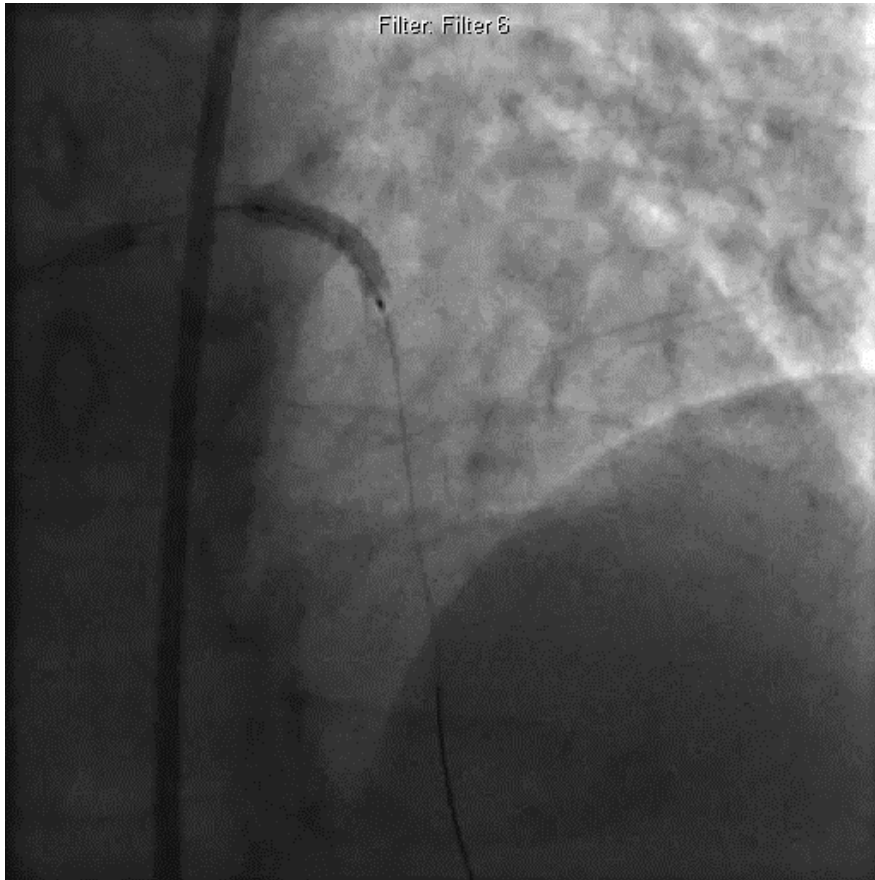


BALLOON

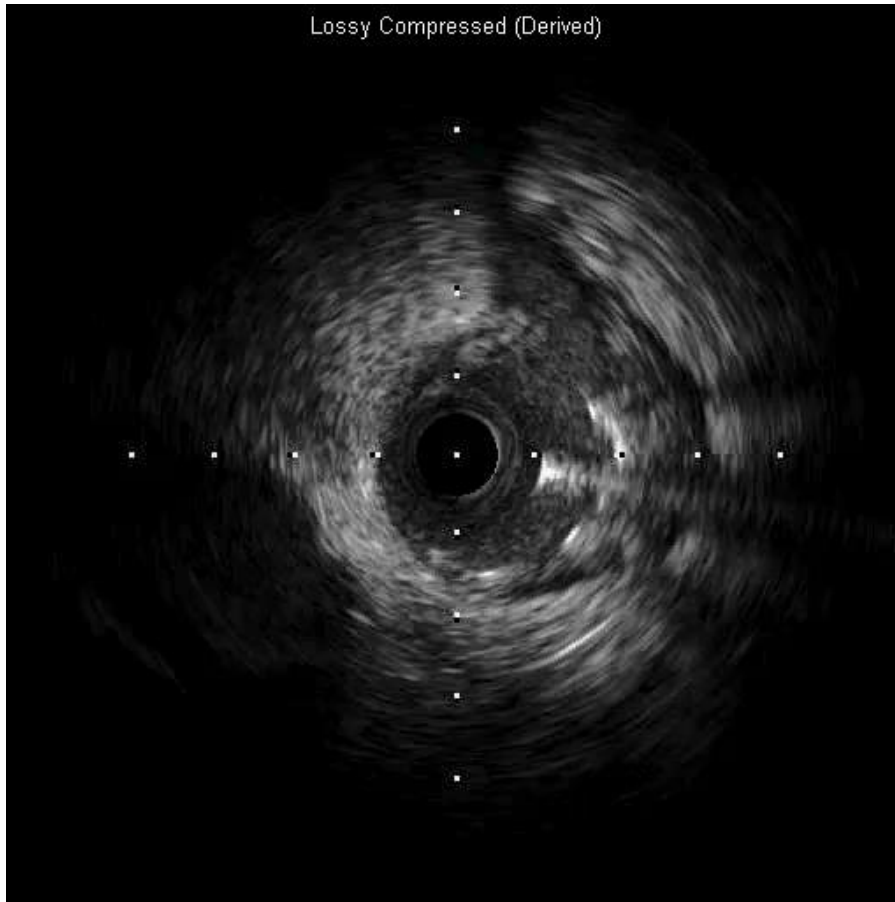


STENT INSERTION

LAO – CRA



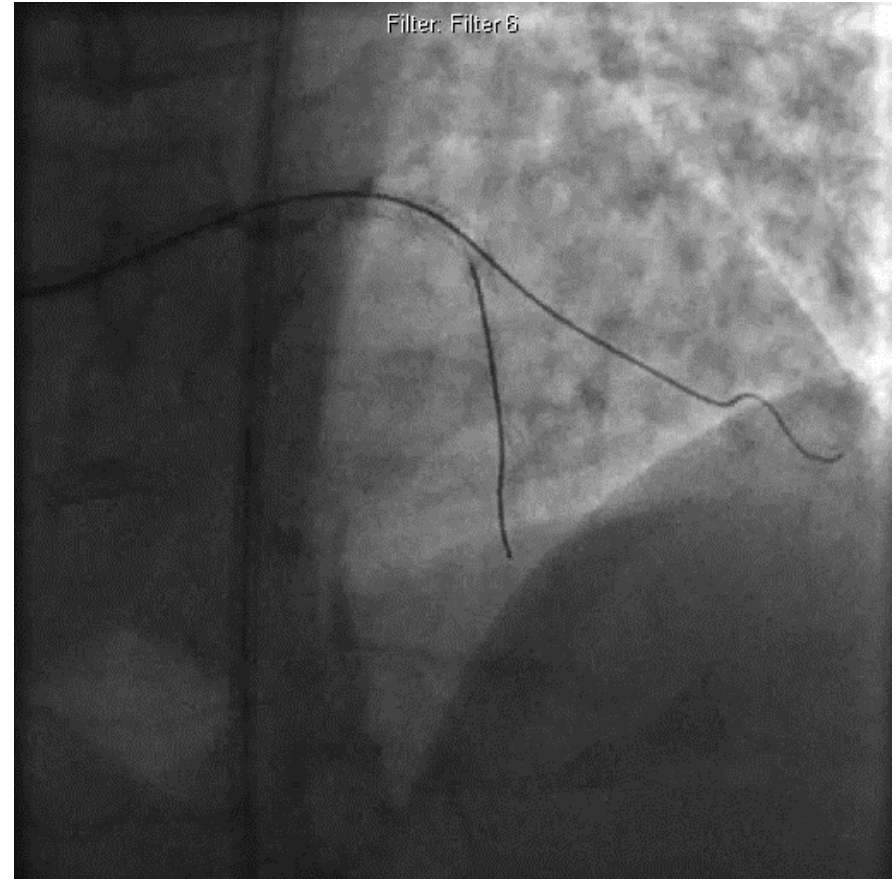
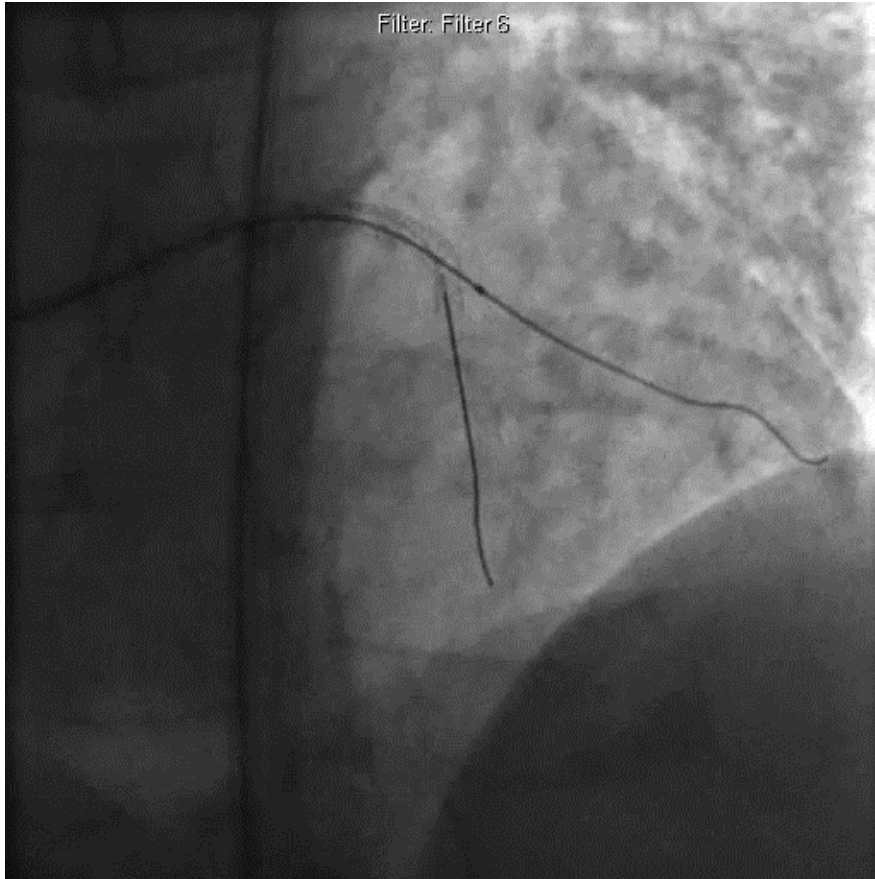
IVUS



COMPROMISED
DIAGONAL
AFTER STENTING
BY
STENT STRUCTURE
+
CALCIFICATION.

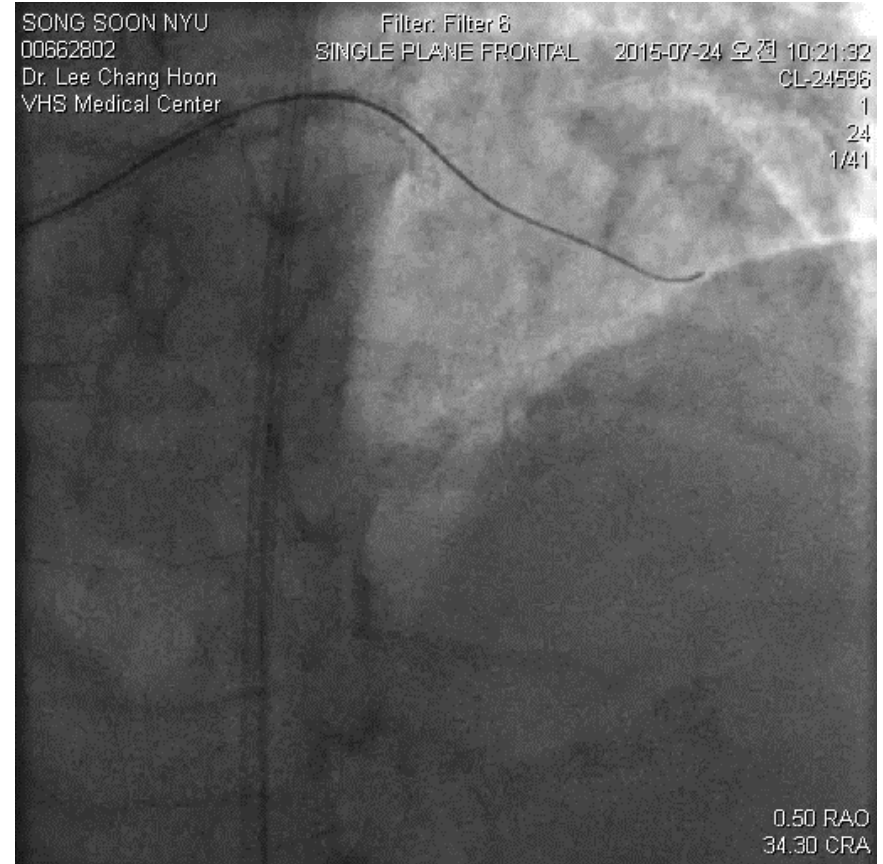
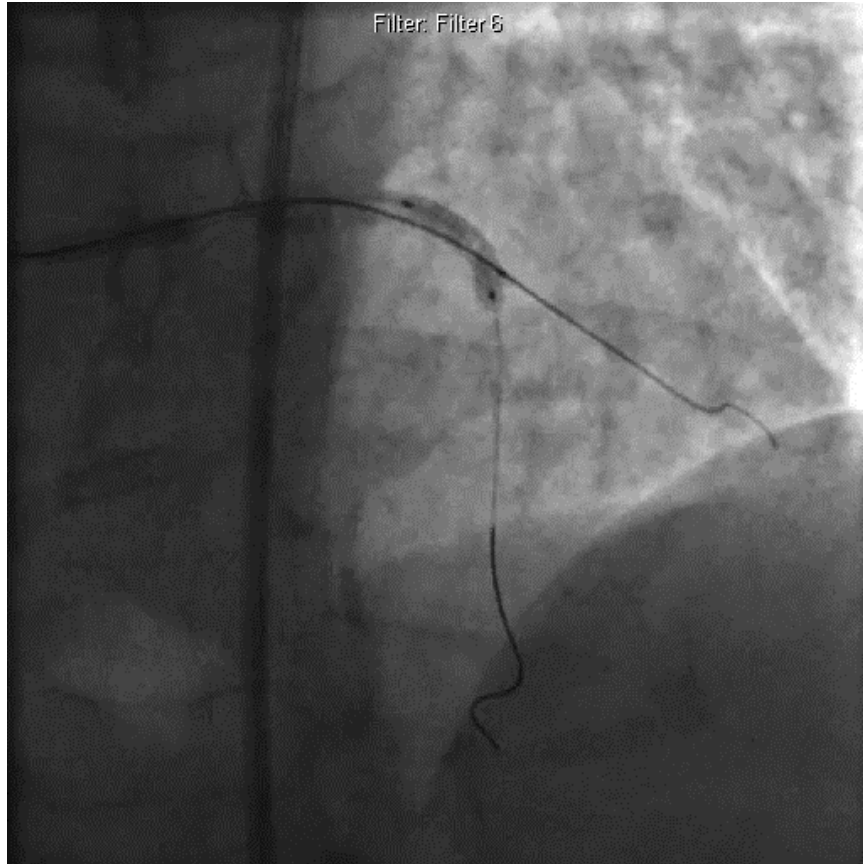
DIAGONAL BALLOON

LAO – CRA



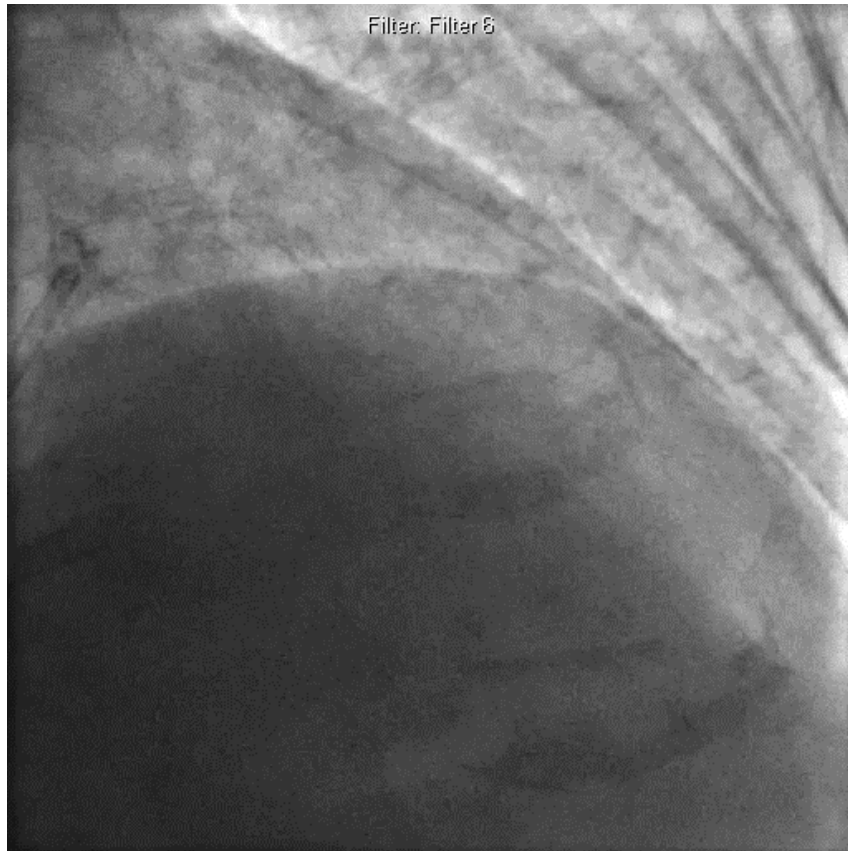KISSING BALLOON

LAO – CRA

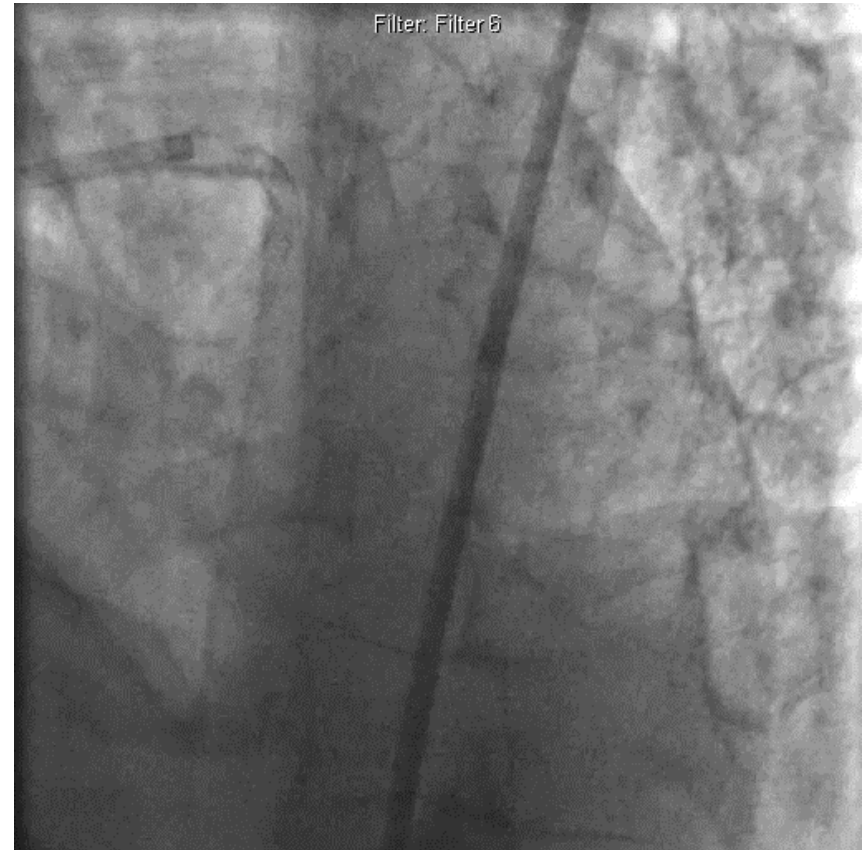


FINAL ANGIO

RAO - CRA



LAO - CRA



Take Home Message

- Bifurcation lesion is not predictable precisely post-procedure result by only angiogram.
- IVUS confirmation in bifurcation lesion is important.
- Even tiny clue of IVUS shouldn't be missed during interpretation.