

# Chinese elements

for the procedure of transcatheter LAA Closure

Shuang Li, Wei Chen, Yawei Xu (the P.I.)

Department of Cardiology  
Shanghai Tenth People's Hospital  
Tongji University School of Medicine






PLAATO




WATCHMAN




ACP

Amulet (ACP 2)



Lefort (China)



L'Ambre (China)


Hemi/spherical devices

Two-disc devices

**LAmbre closer system**



**Implanter**

**Delivery system**




**Single/Double curve:**  
**Delivery sheath: 8~10F**





Nitinol Frame

160 Micron  
Membrane (PET)



10 Active  
Fixation anchors  
(1.2-1.5mm, 45° )

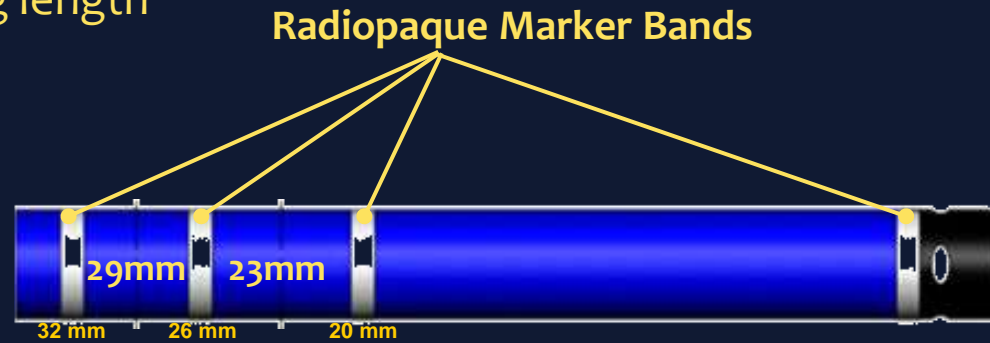
Sizes:  
21, 24, 27, 30, 33 (Φ)  
17, 19, 22, 24, 26 (H)





## Trans-septal Access System

- Double or Single Curve styles
- 1<sup>st</sup> generation: 16F O.D. (5.3mm), 14F I.D. (4.7 mm)
- 2<sup>nd</sup> generation: 14F O.D. (4.7mm), 12F I.D. (4 mm)
- 75 cm working length

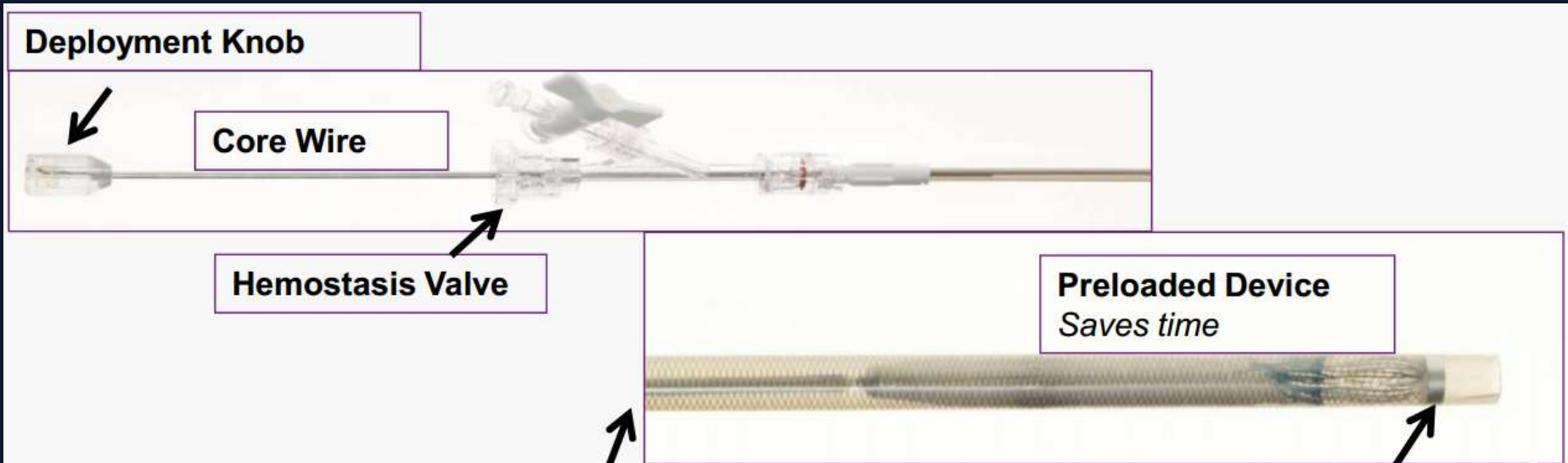


Deployment Knob

Core Wire

Hemostasis Valve

Preloaded Device  
*Saves time*

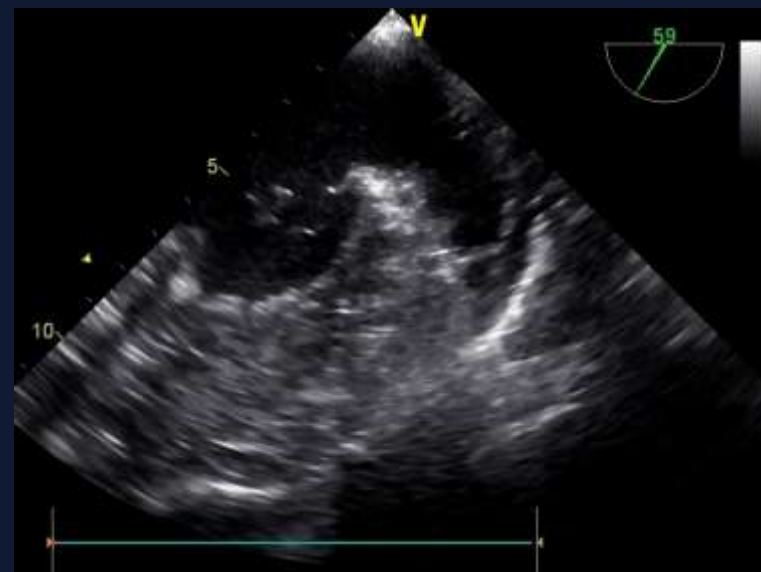

## case 1

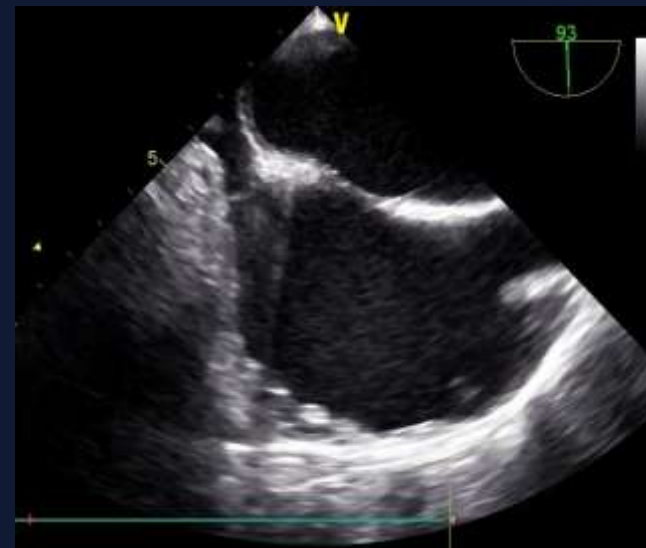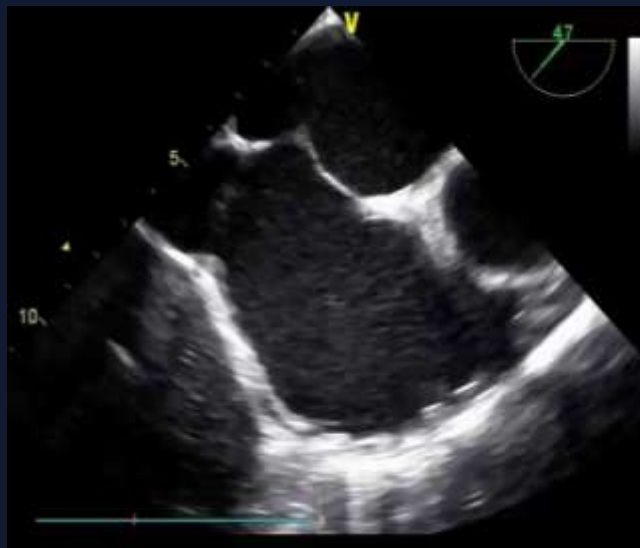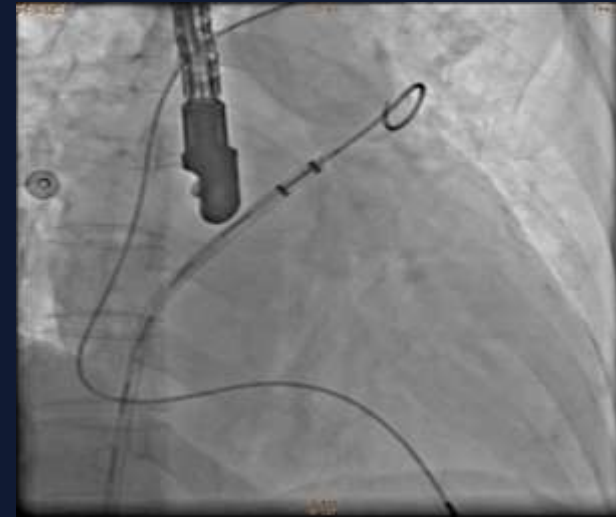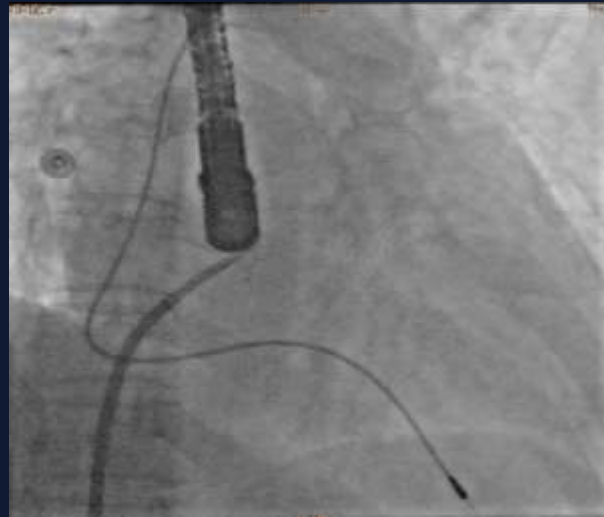
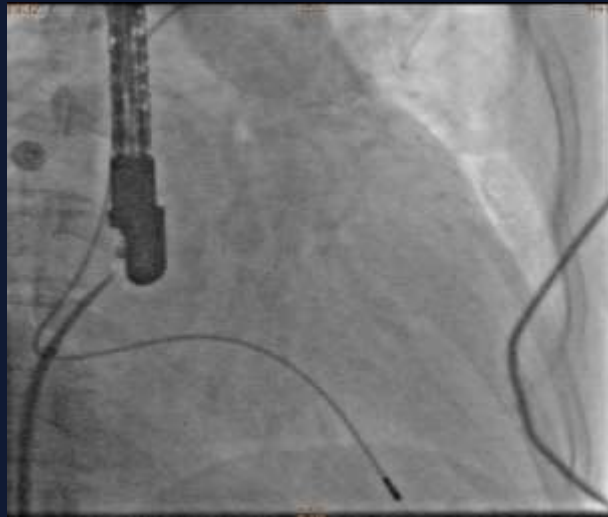A typical case using L'Ambre

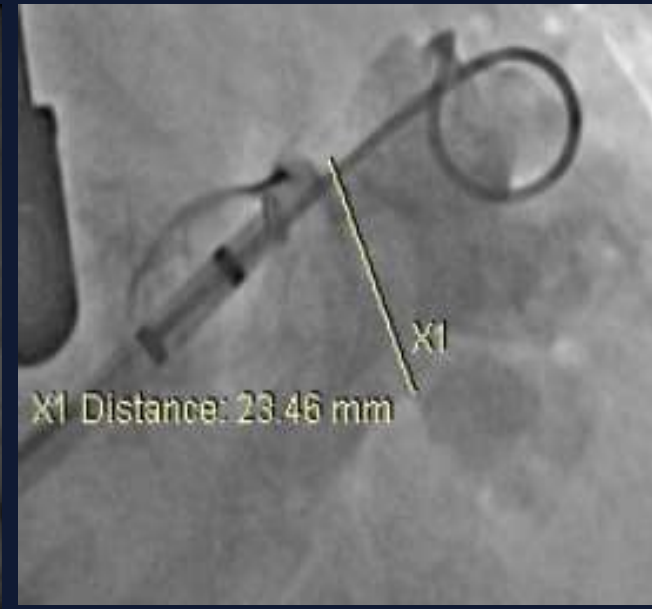
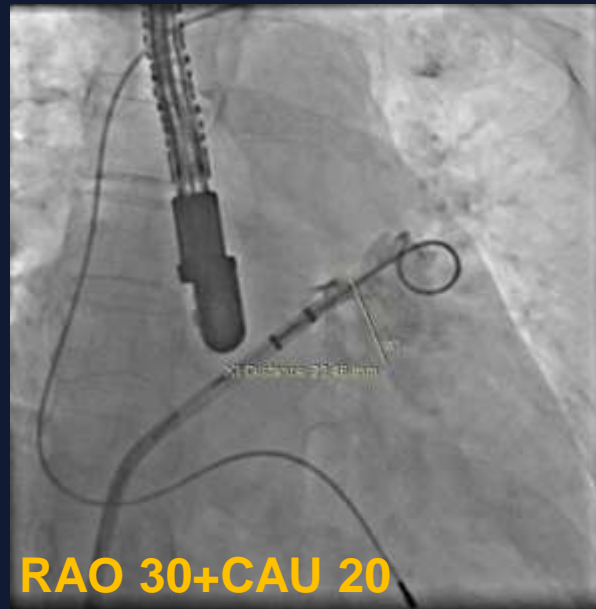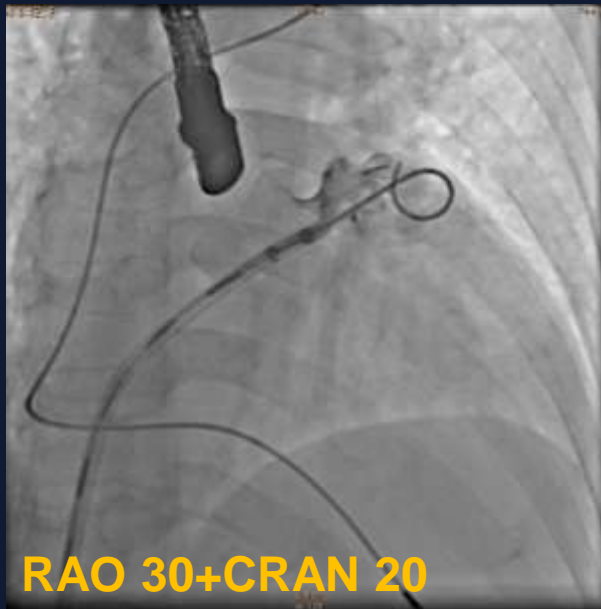


- Xia XX, 61 yrs, female, Palpitation for n yrs
- Pacemaker (VVI), 1 y
- AF, No warfarin as labile INR
- HTN 10 yrs, one event of ischemic stroke
- TTE : LA  $\phi$  48mm, LVEF 58%, slight MR
- TEE : LA  $\phi$  55mm, LAA single-lobe, Orifice: 22mm, Depth: 37mm



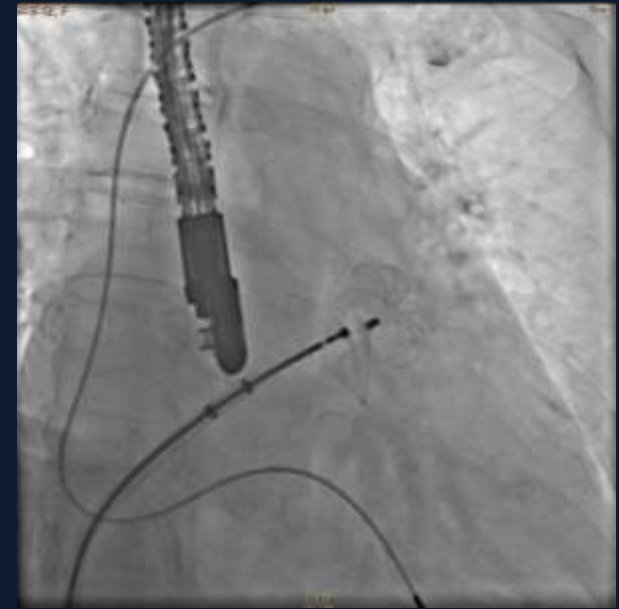
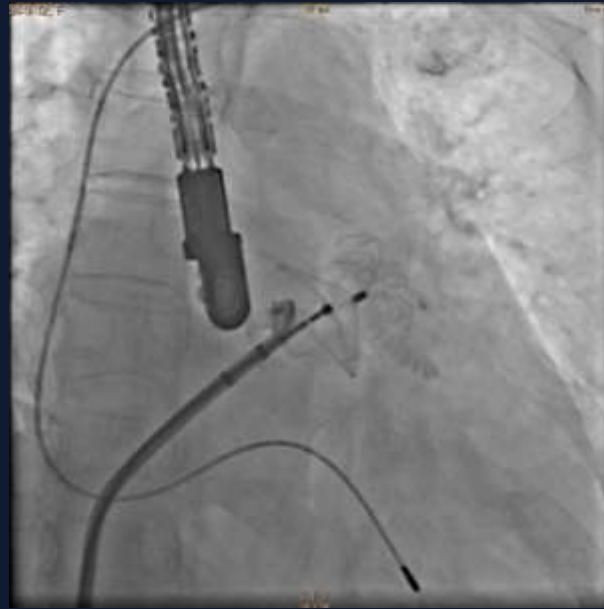
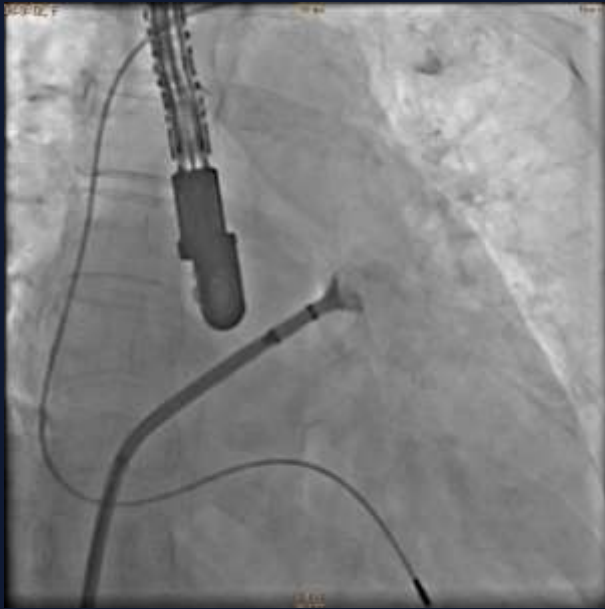





- Angiography : LAA orifice  $\phi$  23.4mm
- TEE 0°, 45°, 60°, 90°, 135°: Orifice  $\phi$  (Max) 22mm, Depth 38mm
- Device:  
**28mm\*34mm (fixed disc  $\phi$  /seal disc  $\phi$ )**

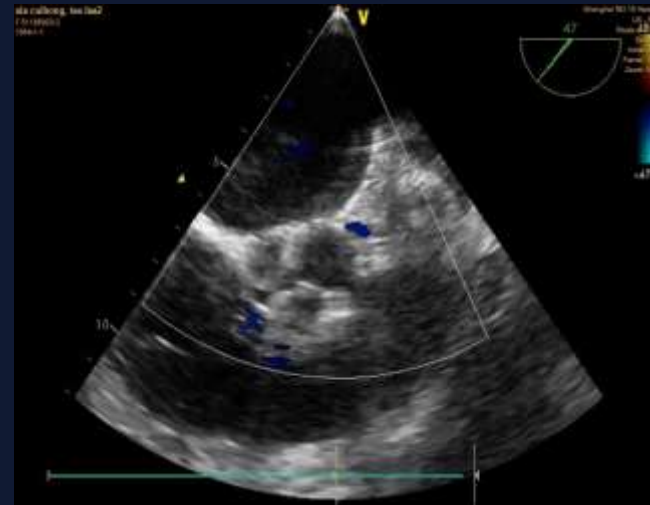



Post-procedural TEE



3-m follow-up TEE



**NO.1/54 LAmbré**



## Case 2

HLC 1834 1-3

ARTICLE IN PRESS

**HOW-TO-DO-IT**

Heart, Lung and Circulation (2015) xx, 1-3  
1443-9506/04/\$36.00  
<http://dx.doi.org/10.1016/j.hlc.2015.03.015>

---

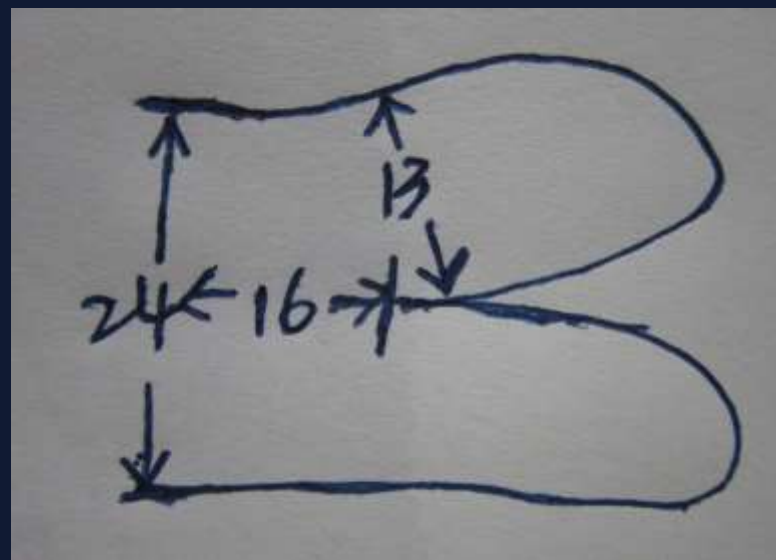
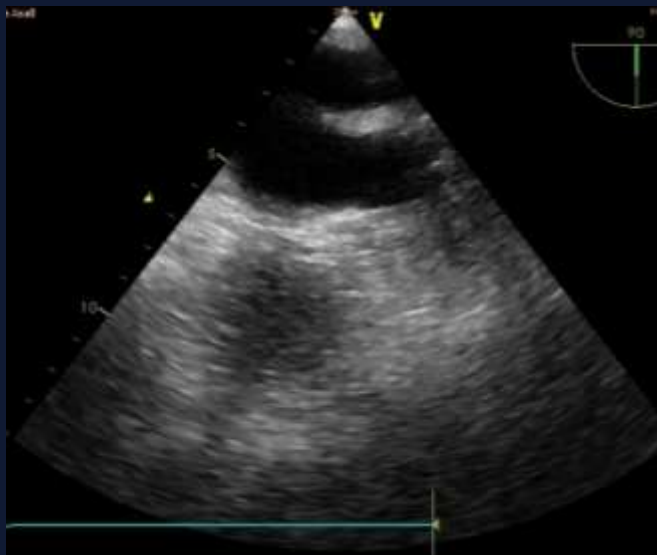# Overlay Technique for Transcatheter Left Atrial Appendage Closure

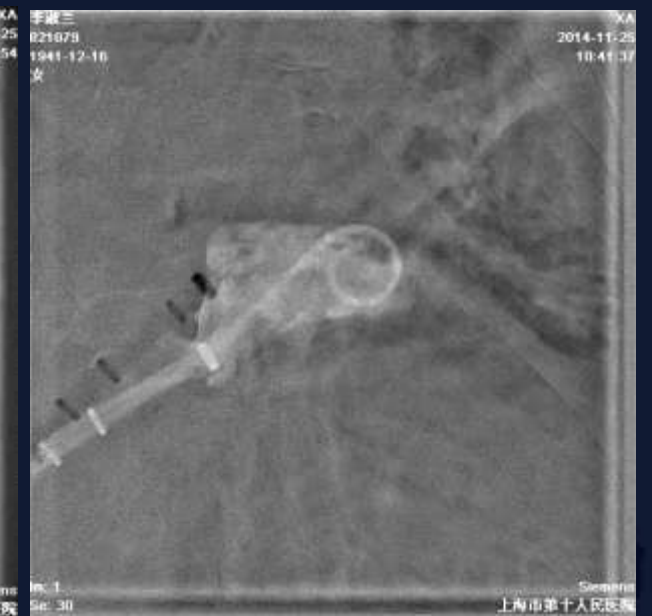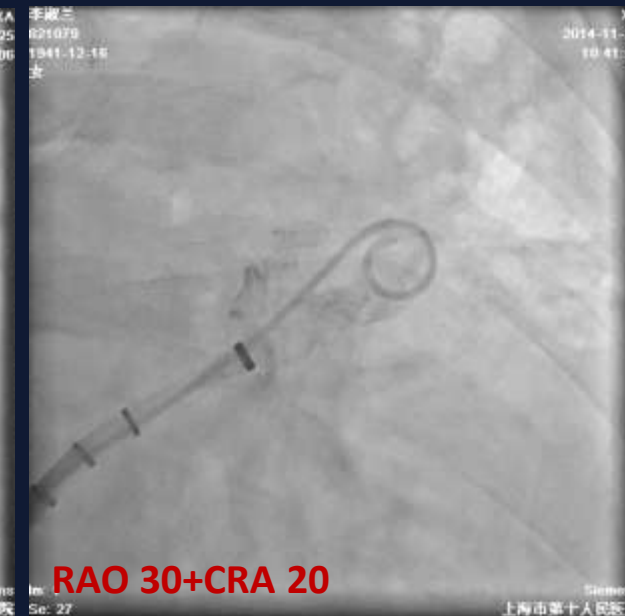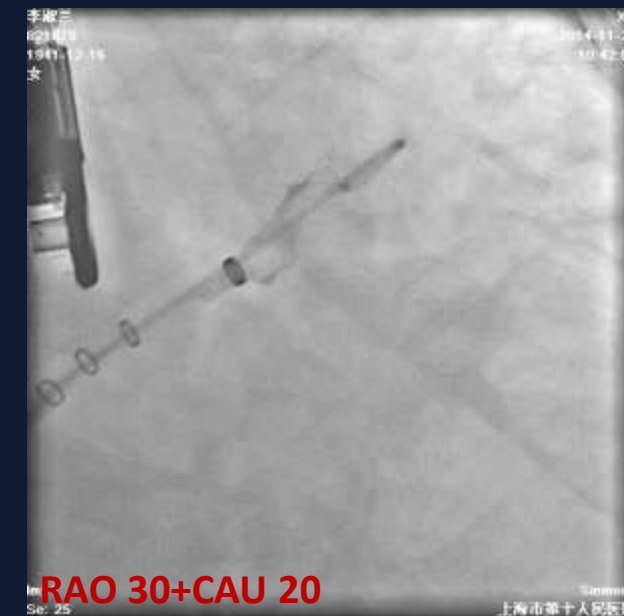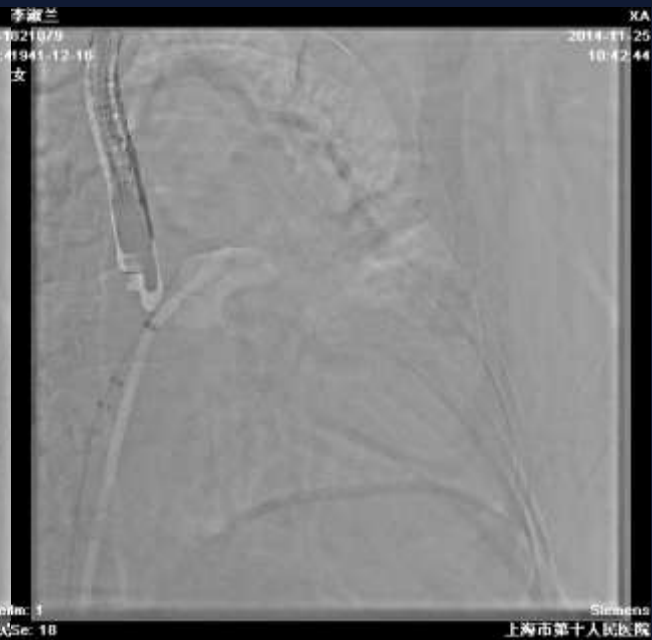
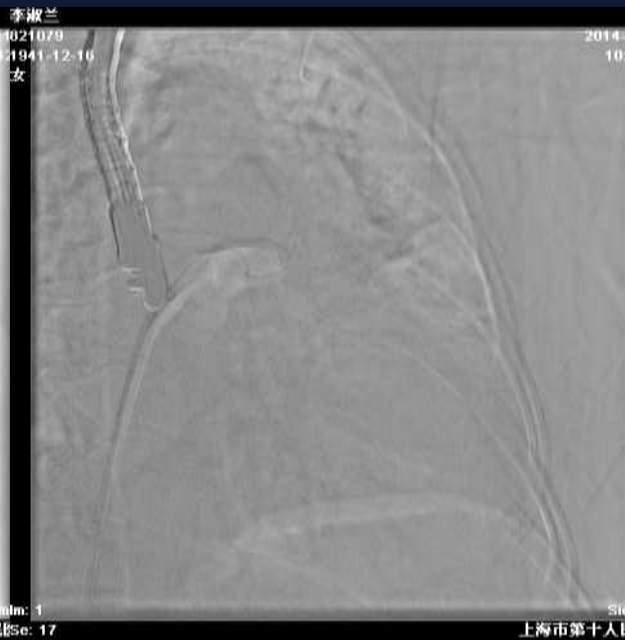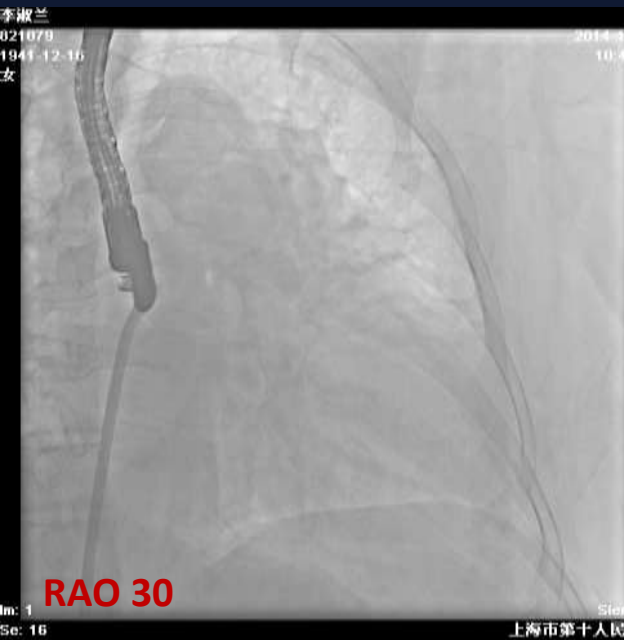**Shuang Li**, MD, Mengyun Zhu, MD,  
Yunlan Lu, MD, Kai Tang, MD, PhD,  
Dongdong Zhao, MD, PhD, Wei Chen, MD, PhD\*,  
**Yawei Xu, MD, PhD, FACC**

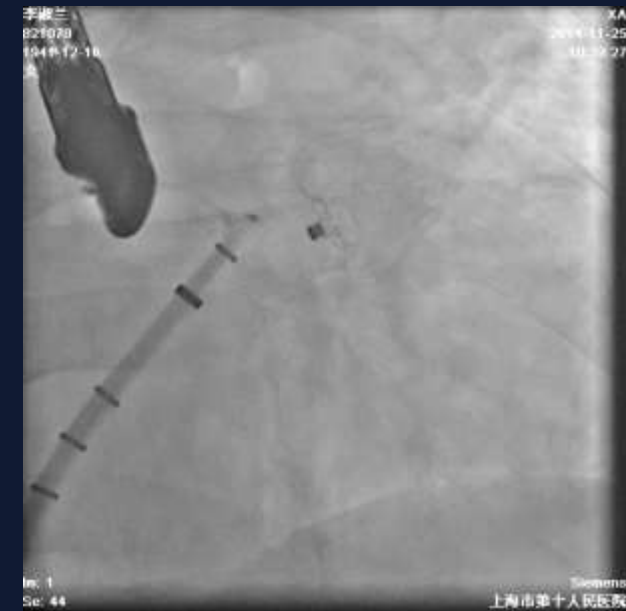
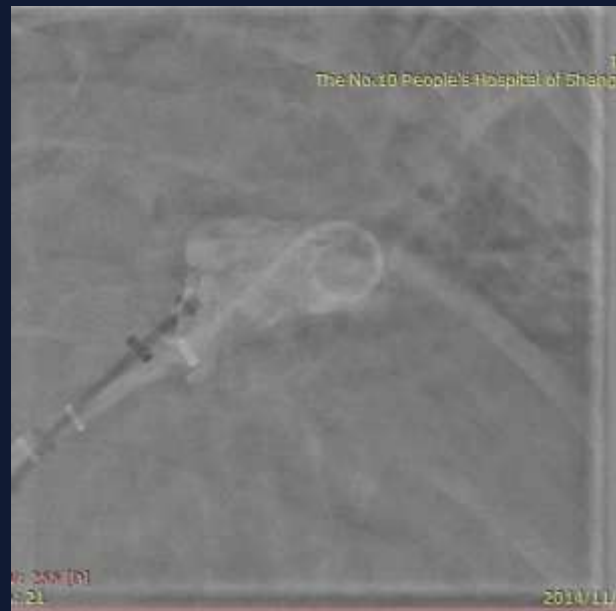
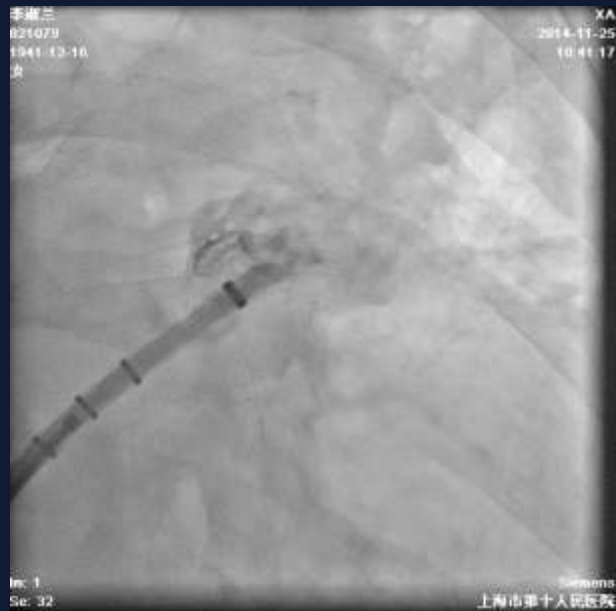- XX Li, Chinese, female, 72 yrs
- AF n yrs, no warfarin
- HTN n yrs, several episodes of TIA
- Pre-procedural TEE:

LA  $\phi$  50 mm, LAA 2 lobes, bifurcated

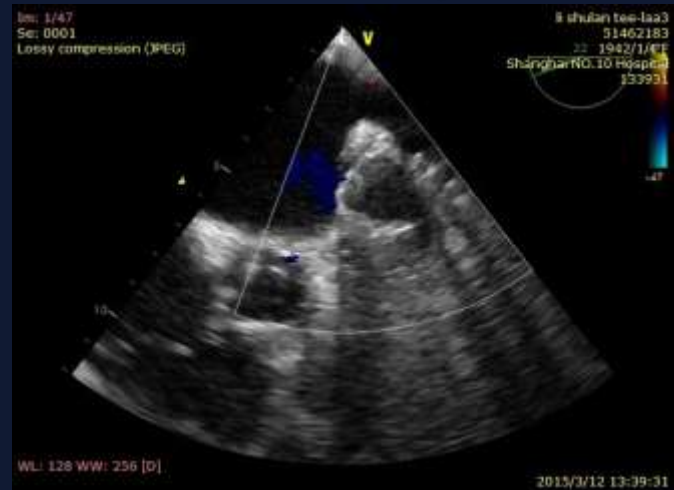
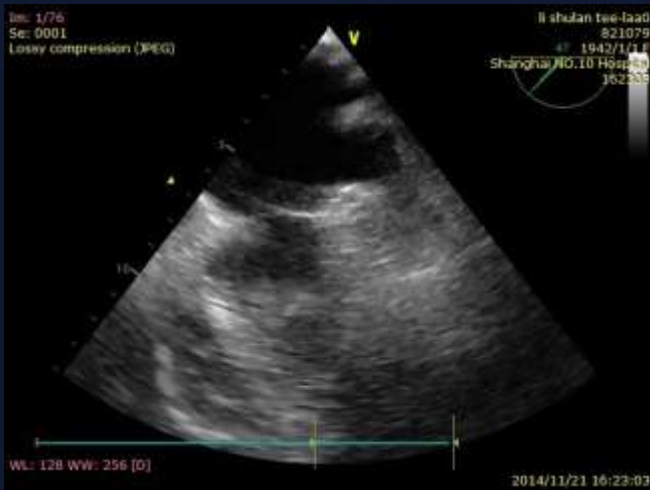




Post-procedural TEE

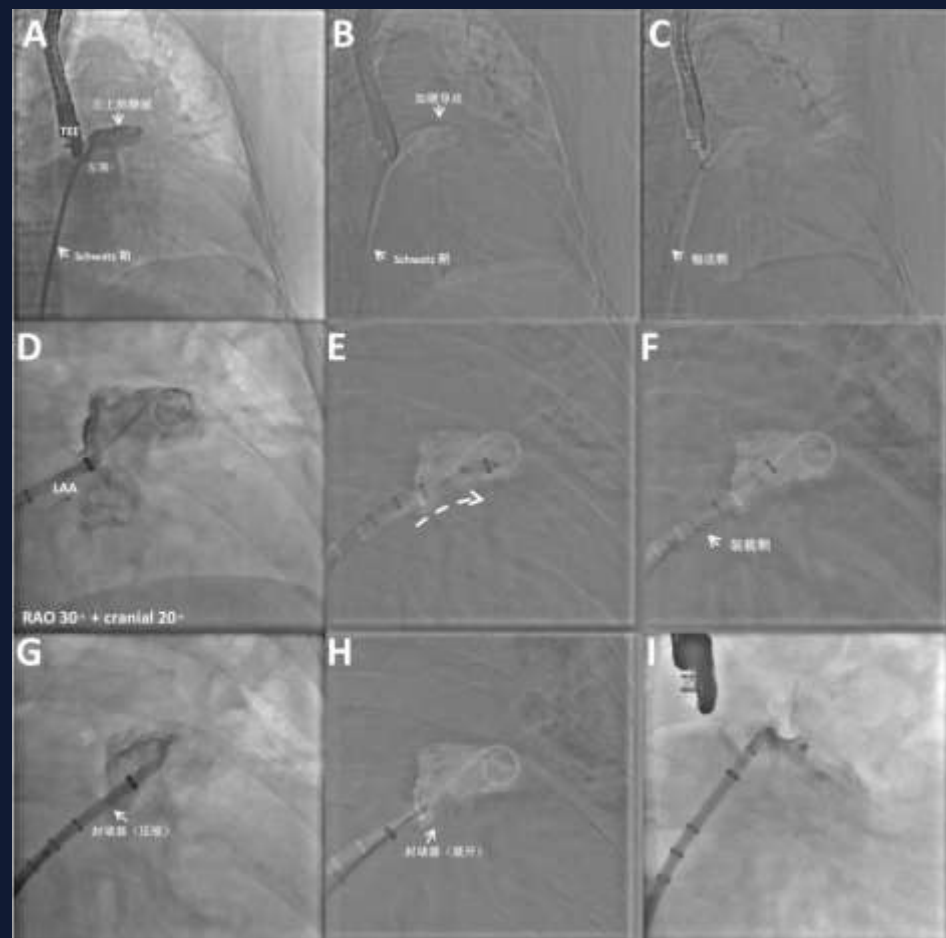
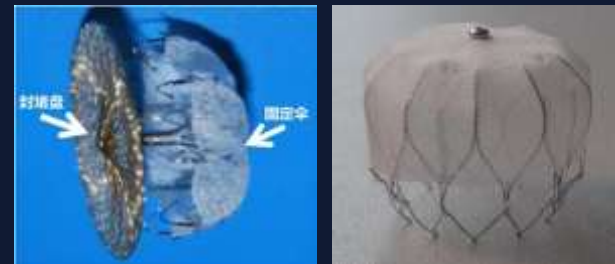3-m follow-up TEE



**NO.2/8 Lefort**  
**NO.1 Overlay**



- **LAmbre, a new two-disc LAA closer**
- **Lefort, a new domestic Watchman-like device**
- **Overlay technique is helpful**





## Welcome to our center



● Our hospital

● LAA team

● Cath/EP "Family"

