

My Challenging Bifurcation PCI Case of the Year

Thierry Lefèvre, Massy, France

Miss K. 90 yrs old, active

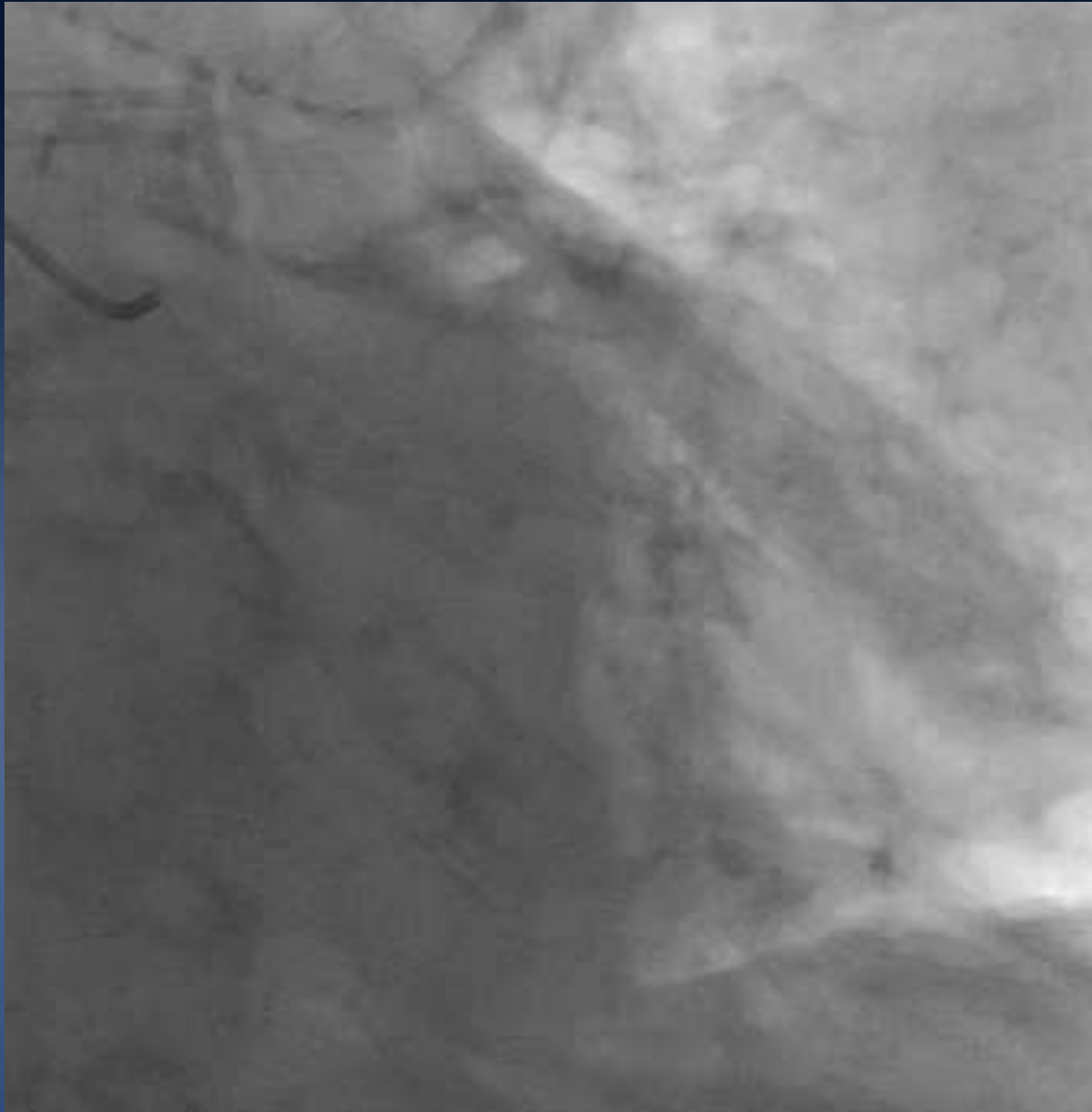
- ✓ Admitted in another hospital for ACS
- ✓ Complicated initially by cardiac failure
- ✓ Severe ST segment depression in anterior leads
- ✓ Cardiogenic shock few hours later
- ✓ Troponine 46 000 ng/l day 1
- ✓ LVEF 30% with anteroseptal and lateral akinesia

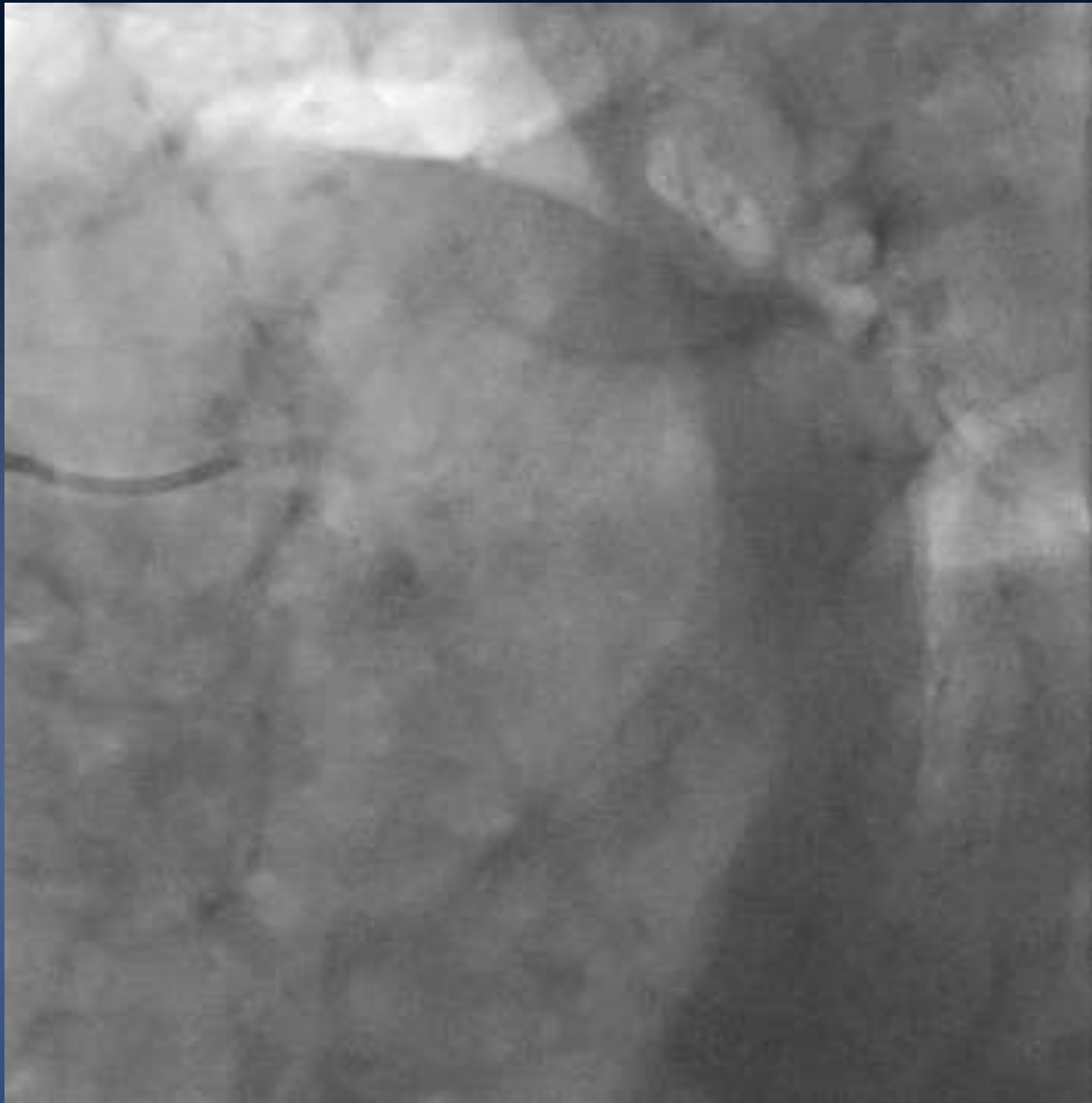
Miss K. 90 yrs old, active

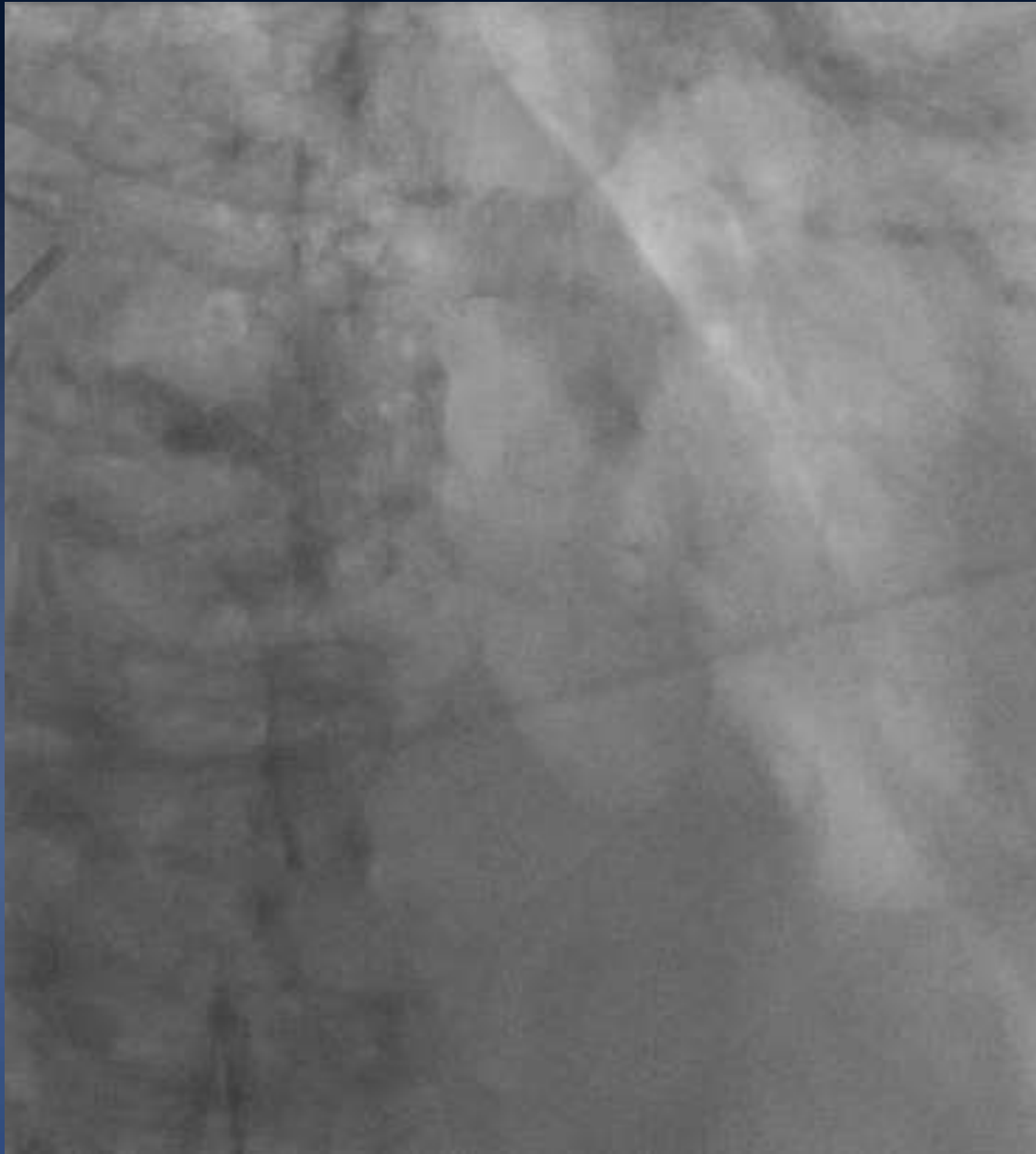
- ✓ Hypertension
- ✓ Dyslipidemia
- ✓ Family history of coronary disease
- ✓ 1m60, 60Kg (IMC 23)
- ✓ Chronic anemia from unknown cause (Hb 9g/dL)
- ✓ Driving his car until recently

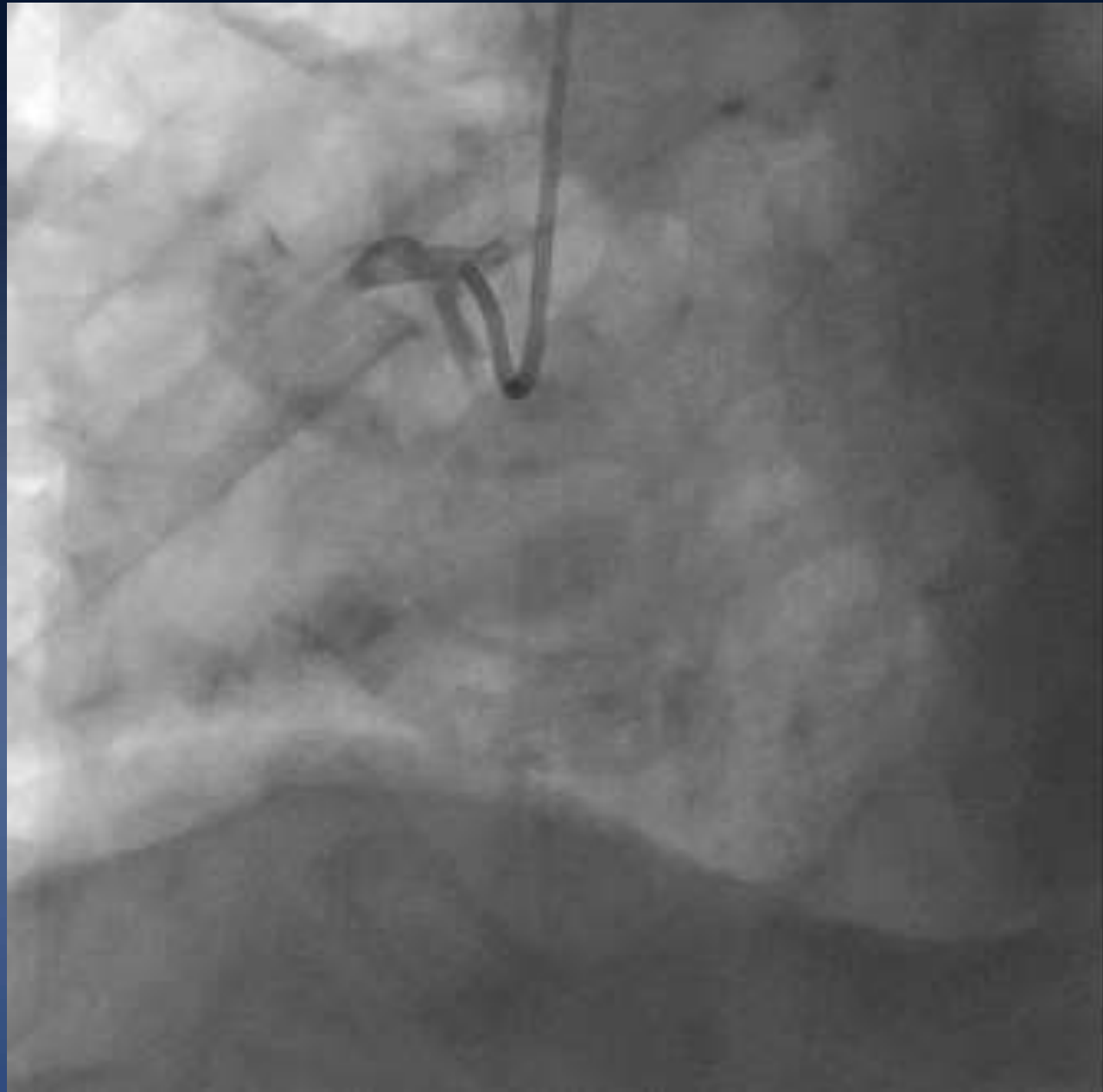
Miss K. 90 yrs old, active

- ✓ Considered initially too high risk for a coronary angiogram
- ✓ On catecholamines and diuretics for 10 days
- ✓ Acute renal failure
- ✓ Slow recovery
- ✓ Coronary angiogram at day 15

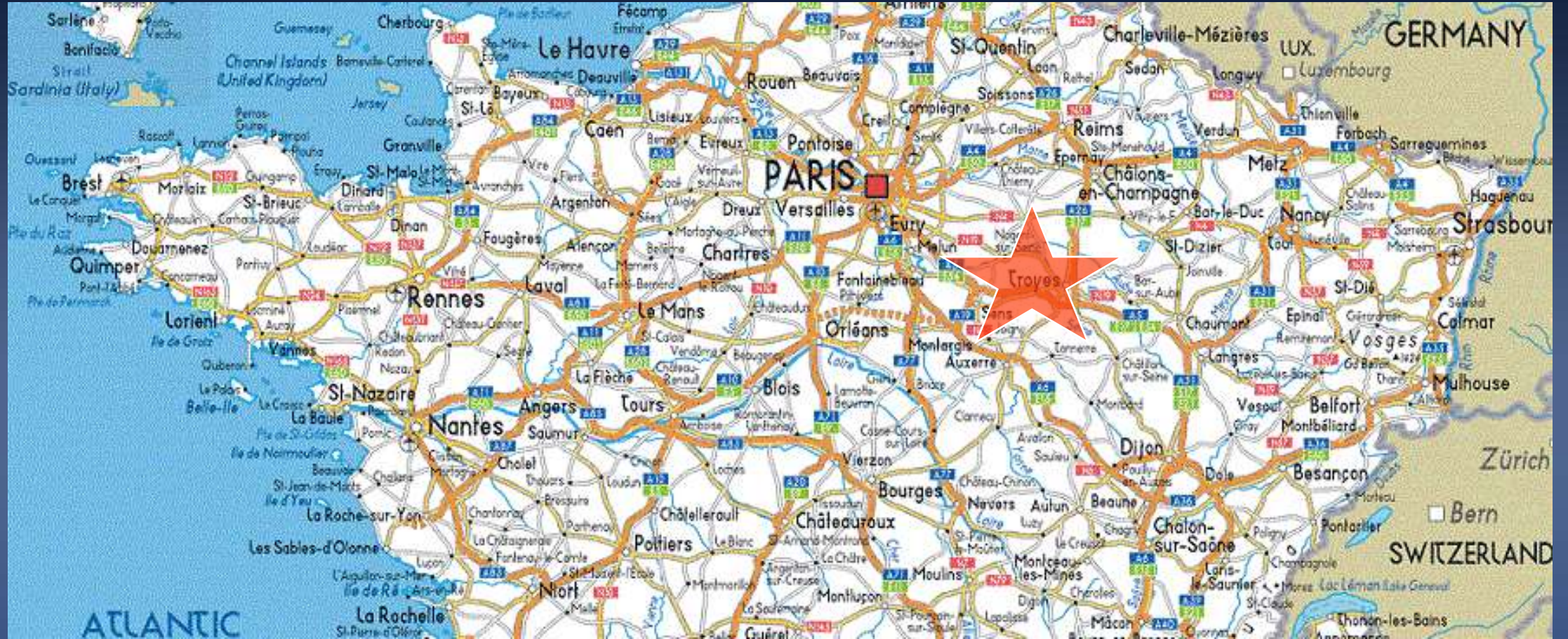




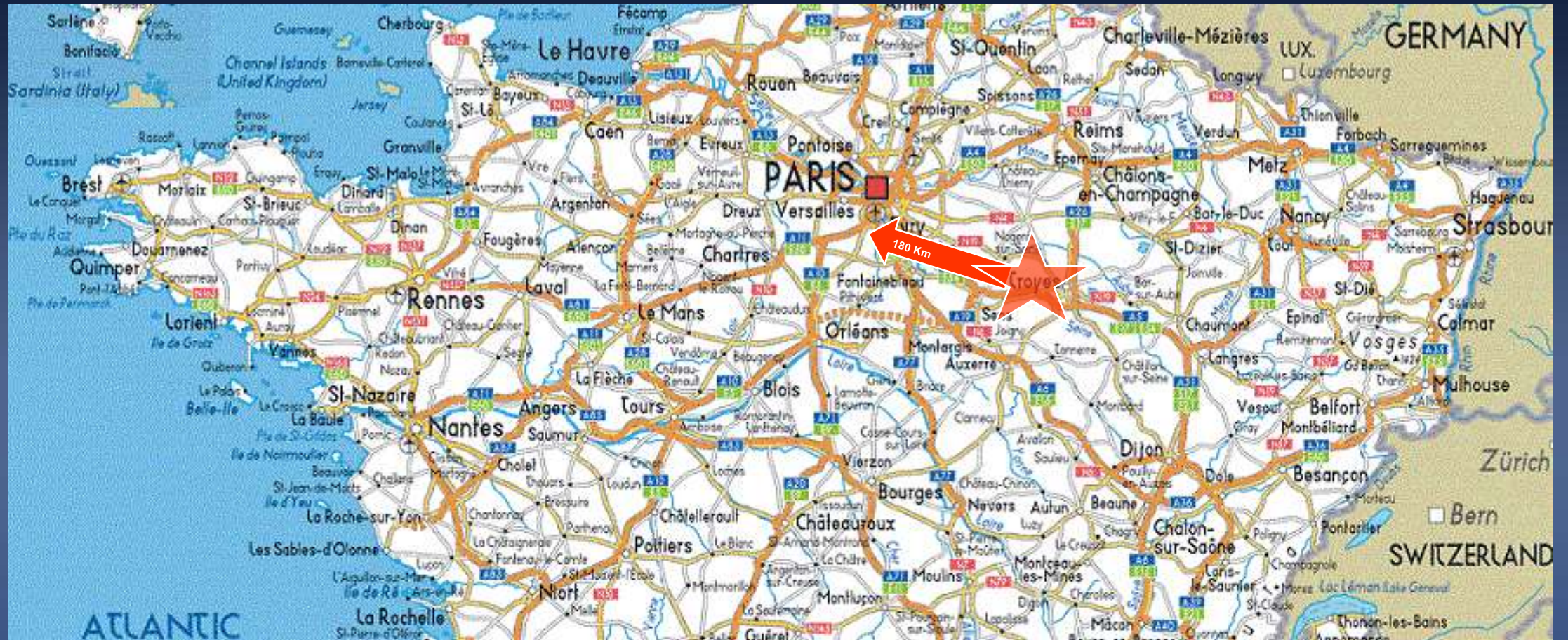


Miss K. 90 yrs old, active

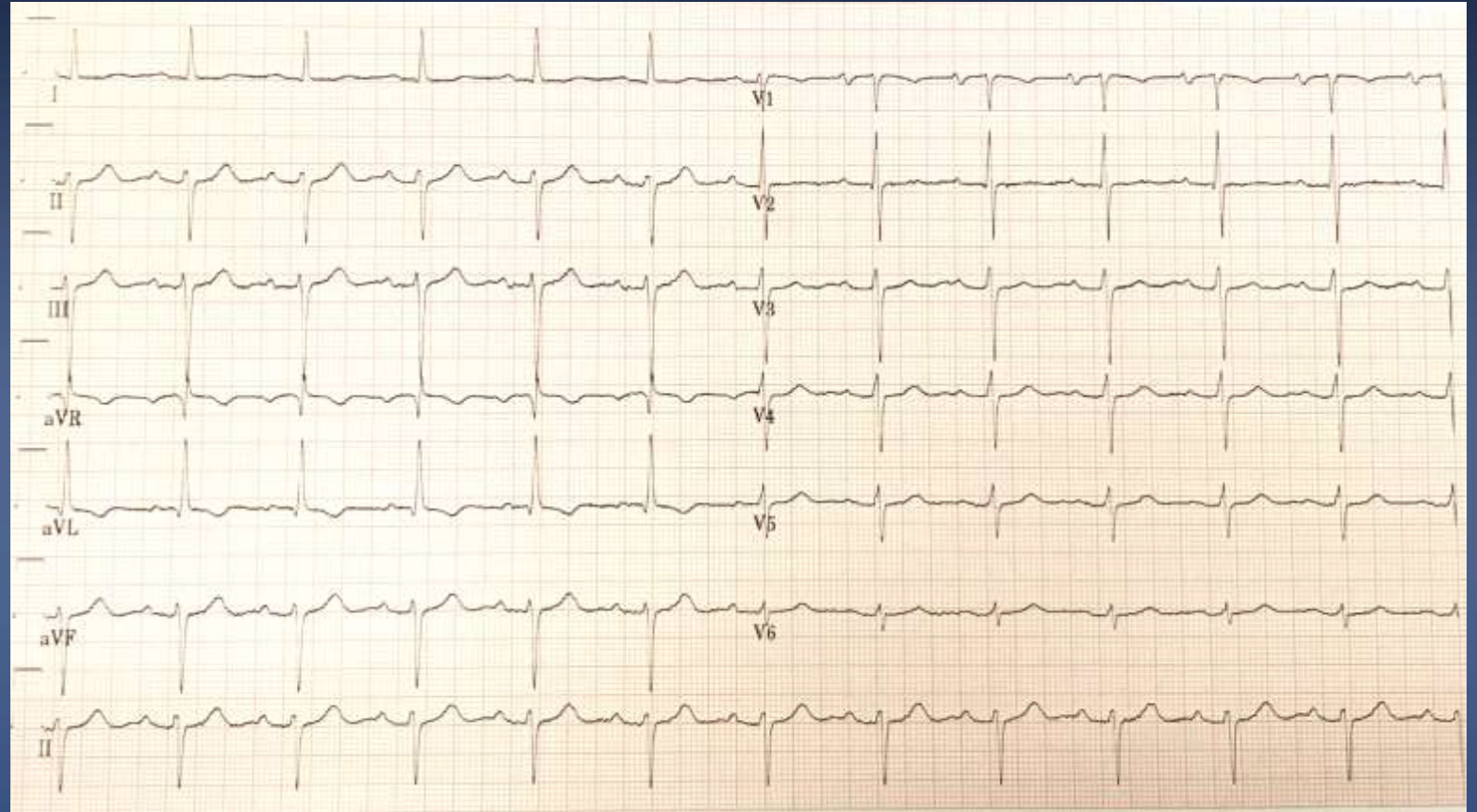


Miss K. 90 yrs old, active

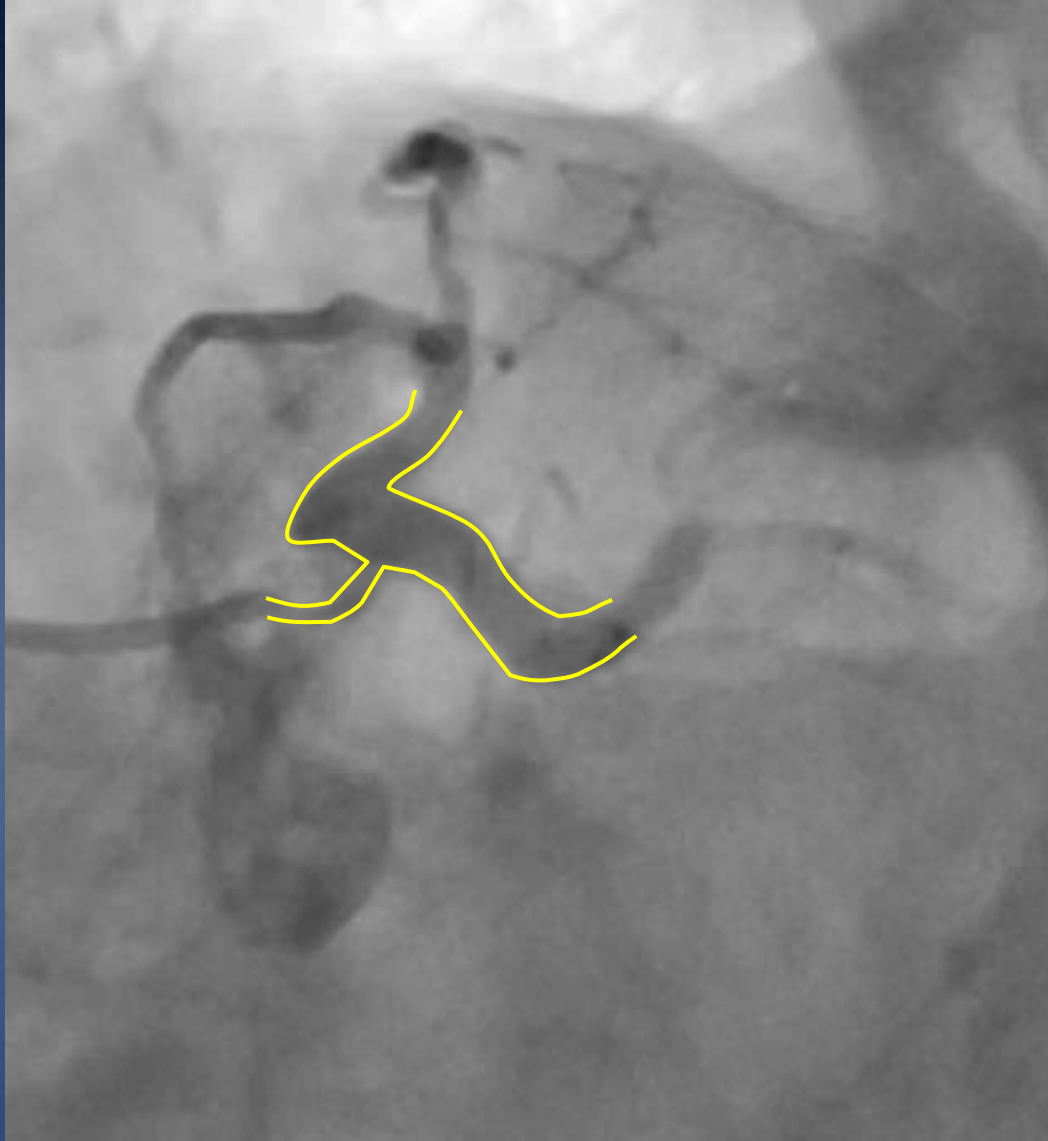


Transferred to Massy at day 16

- ✓ BP 170/80mmHg
- ✓ No pulmonary rales
- ✓ Hb 9,2 g/dL
- ✓ Platelets 248 G/L
- ✓ Creatinine 127 μ M
- ✓ DFG 32mL/min
- ✓ Troponine I HS 76ng/L
- ✓ BNP 1300 ng/L



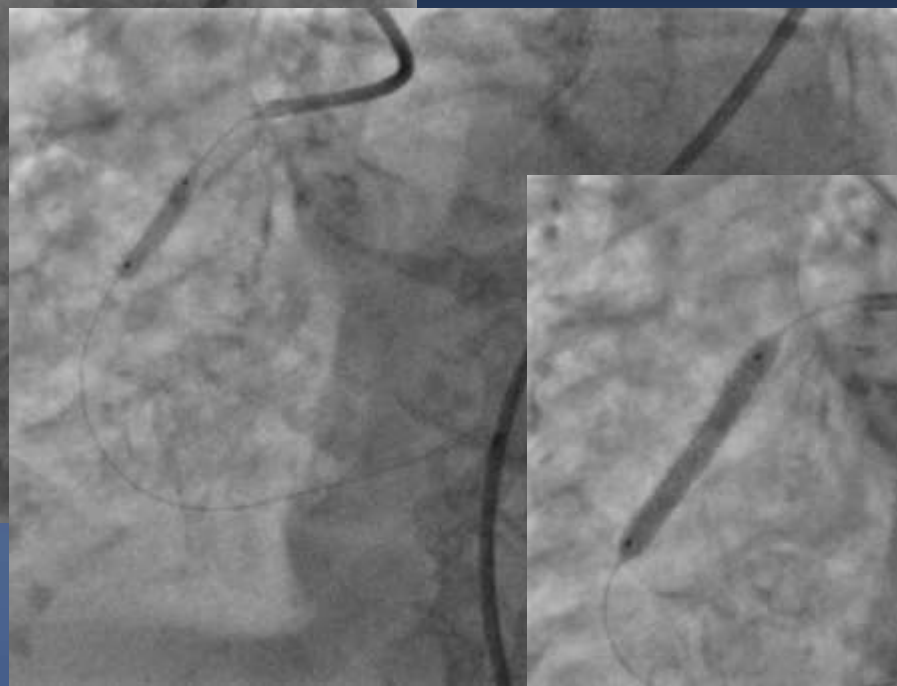
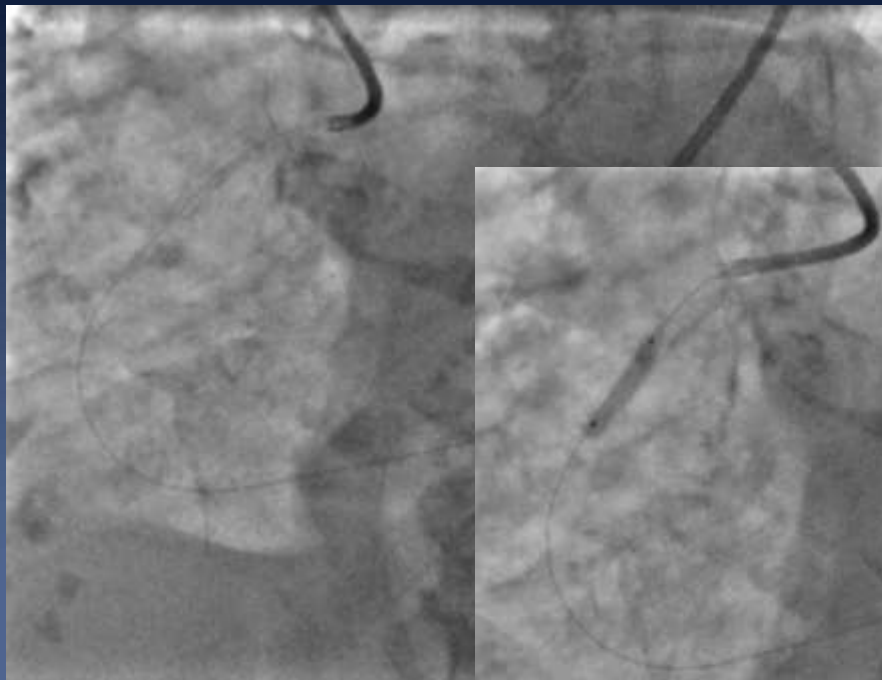
Strategy



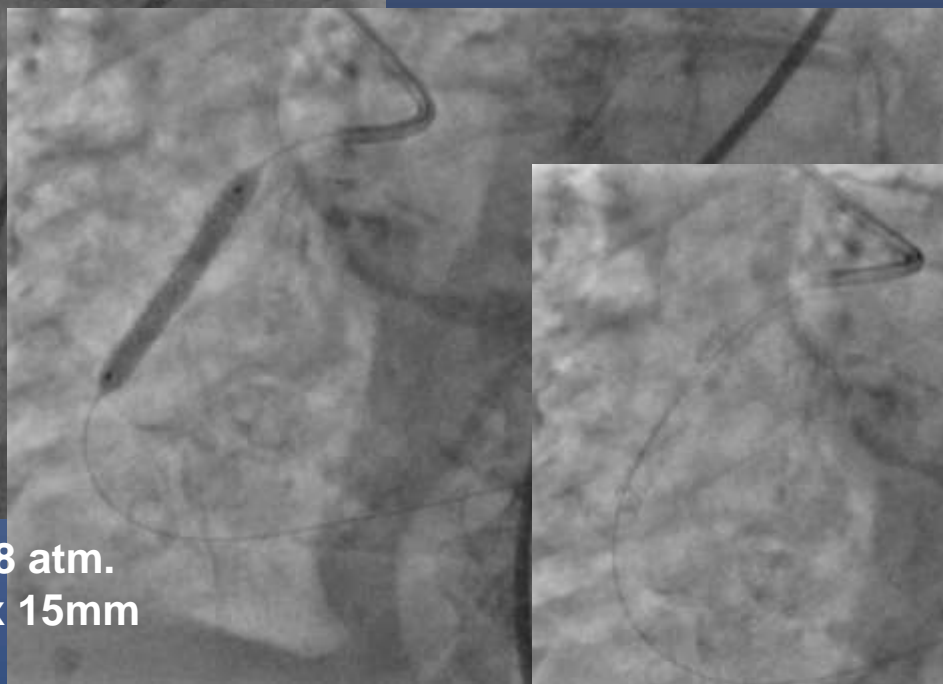
- ✓ HBR
- ✓ IABP
- ✓ RCA first
- ✓ LM Medina 1, 0, 0
- ✓ Provisional SB stenting
- ✓ JL 3.5 6F
- ✓ LAD wiring ?
- ✓ Rotablator ?
- ✓ Stent ?

RCA PCI – Bifémoral approach – IABP

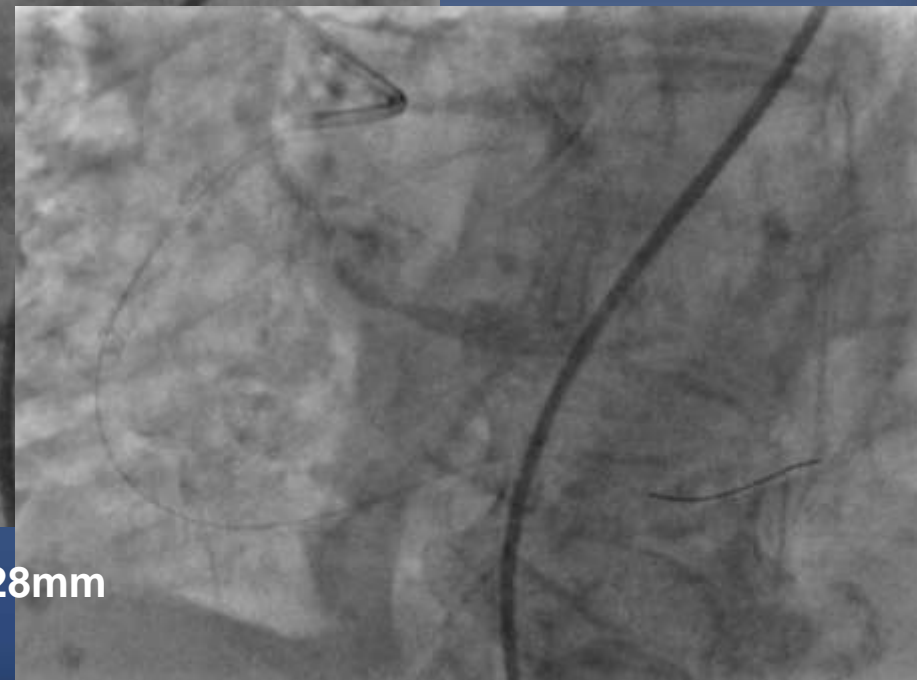
3D Right guide 6F



Predilatation 18 atm.
NC balloon 3.0 x 15mm




DES 3.5x28mm




LM PCI

JL 3.5 guide / 6F




LM PCI
JL 3.5 guide / 6F



Microcather SuperCross 120°

LM PCI JL 3.5 guide / 6F



NC 3.0 balloon 24 atm

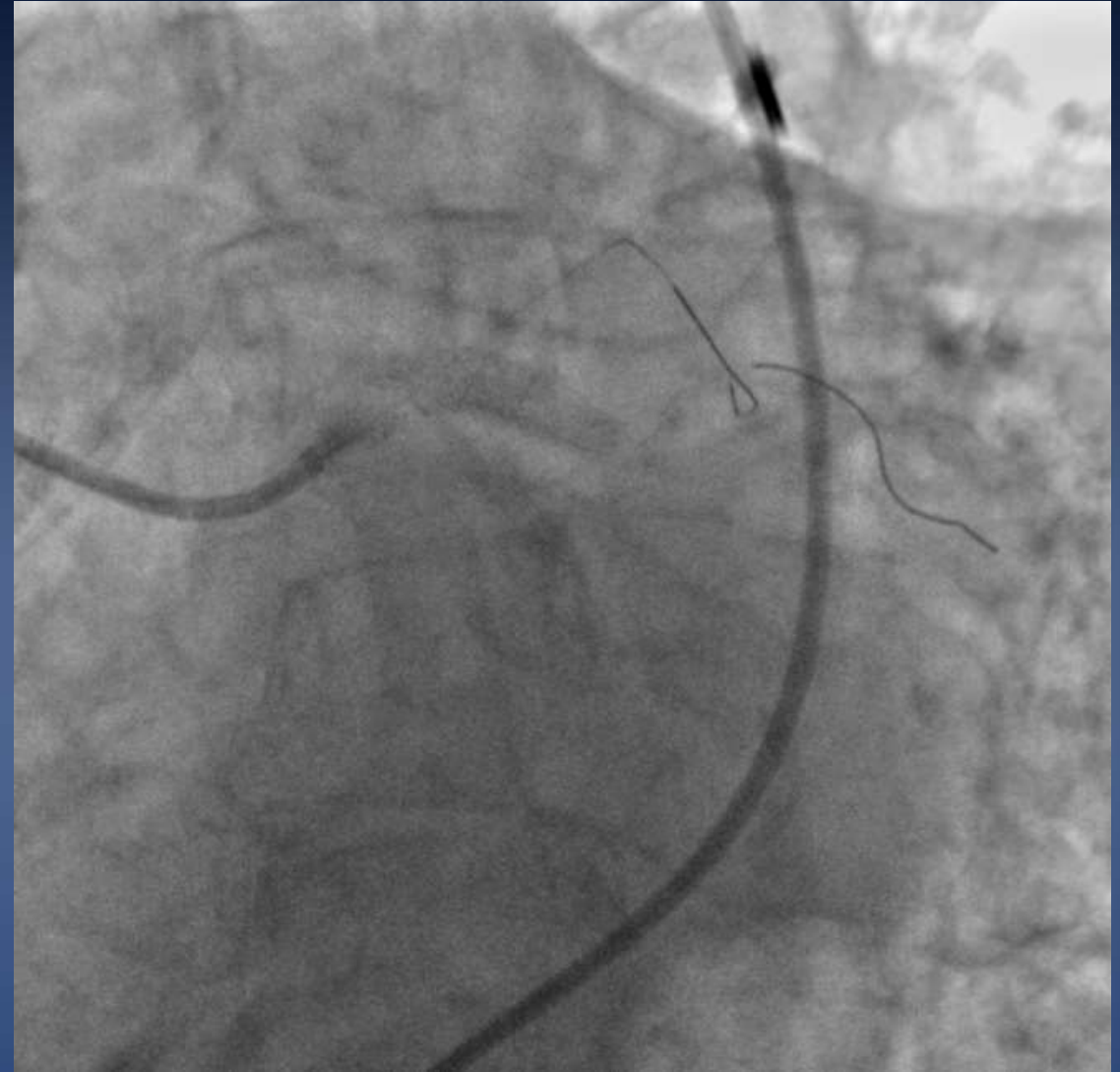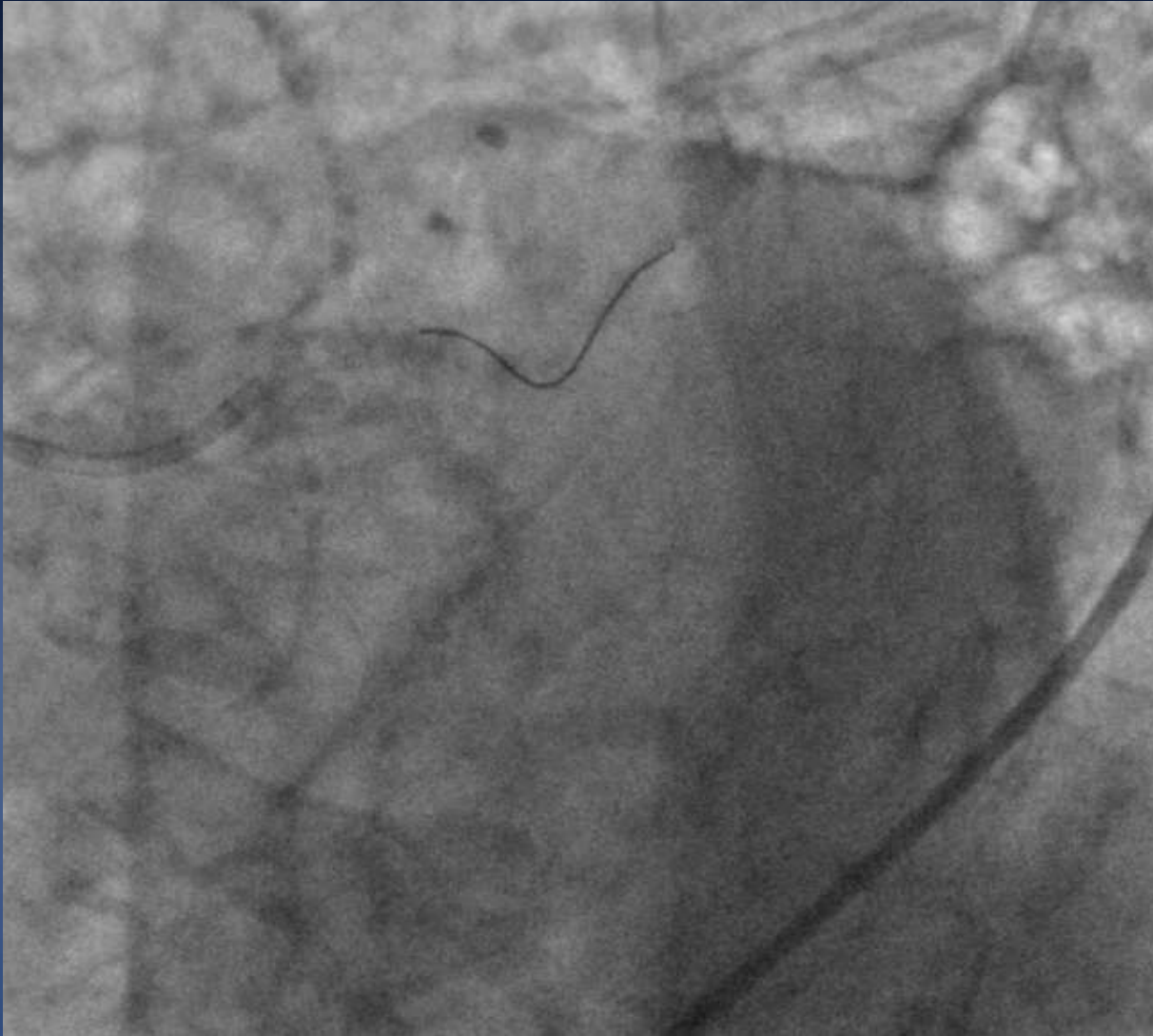
Guidezilla II 6F

SYNERGY megatron 4.5 x 16mm, 8 atm.

POT SC Balloon 5.0 x 15mm

Balloon 3.0 x 15mm
Re POT SC Balloon 5 x 10mm

Final result



In hospital outcome

- ✓ IABP removed on the table
- ✓ Right and Left femoral closure with Proglide
- ✓ No cardiac failure, No acute kidney injury

Echocardiography at day 1

LVEF 58%

Non significant MR

Non significant AR

sPAP 40 mmHg

Discharged at home day 2

- ✓ Aspirin 75mg
- ✓ Clopidogrel 75mg
- ✓ Bisoprolol 1.25mg
- ✓ Pantoprazole 20mg
- ✓ Rosuvastatine 10mg

Take home message

- ✓ **Medical treatment not an option**
- ✓ **Strategy, compagnonage**
- ✓ **Know how to solve difficult branch access**
- ✓ **POT**

The patient 6 months later

The patient is very happy to be back to her normal life

Mme K. [redacted] Christine
Mes remerciements des bons soins
plus mes lui avec [redacted] bague
Je me sens tellement mieux
grâce à l'intervention "détournée"
et réussie par votre dentiste
Avec toute ma reconnaissance.

Mme K. [redacted] Christine
remproplastic du lundi 28/10

French Left Main Registry (BMS)

