TCTAP 2022
Gastro Intestinal Bleeding After Left Main Stenting in Primary PCI

Andi H, MD; A Fauzi Y, MD; Begawan B, MD

St. Borromeus Hospital, Indonesia

Disclosure

- None

Case Illustration

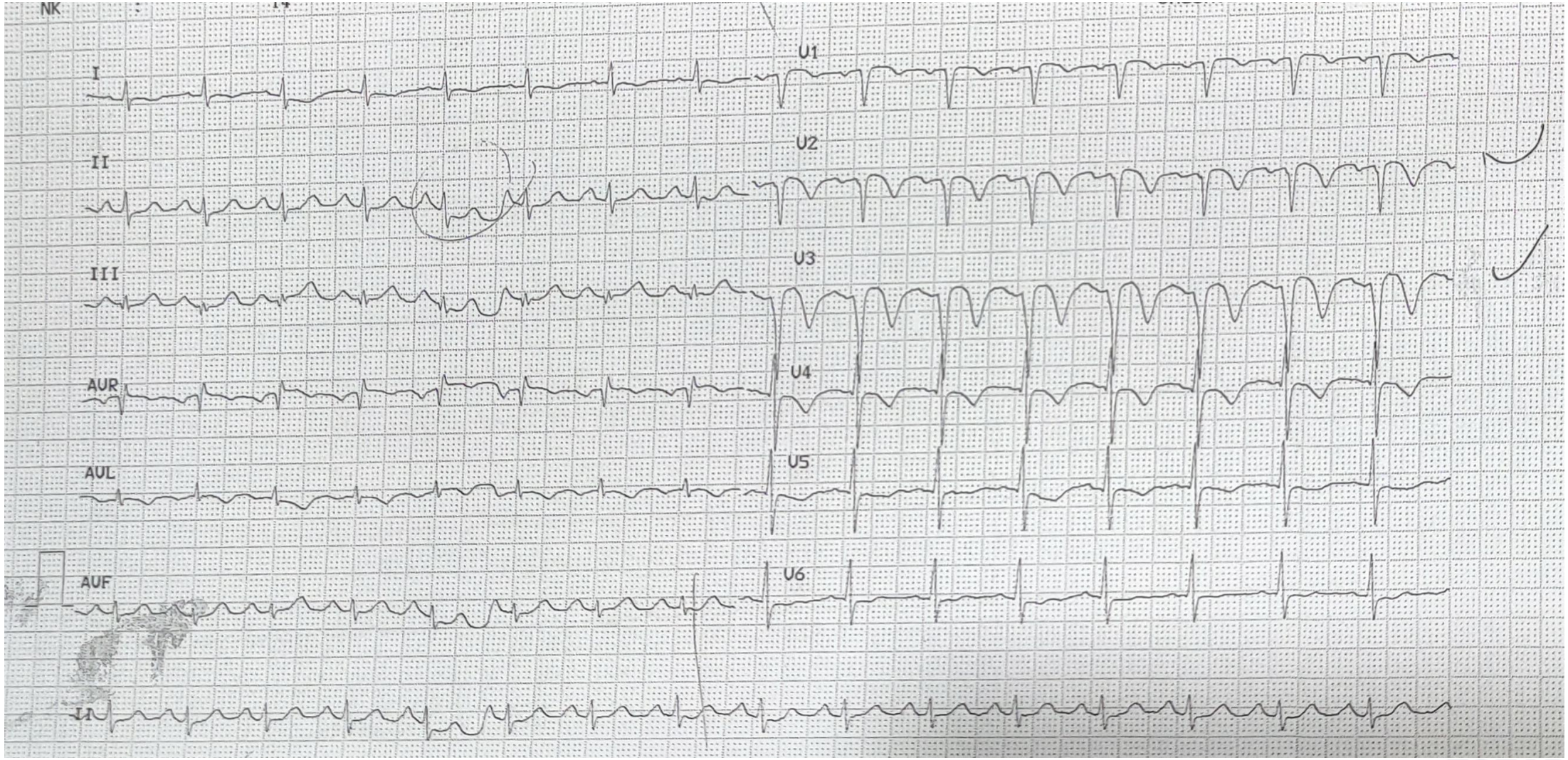

TCTAP 2022

Lab Work

- Elevated cardiac biomarkers
- Normal hematology
- Normal kidney and liver function

→ Primary PCI

Aspirin 320 mg
Clopidogrel 600 mg

LCA

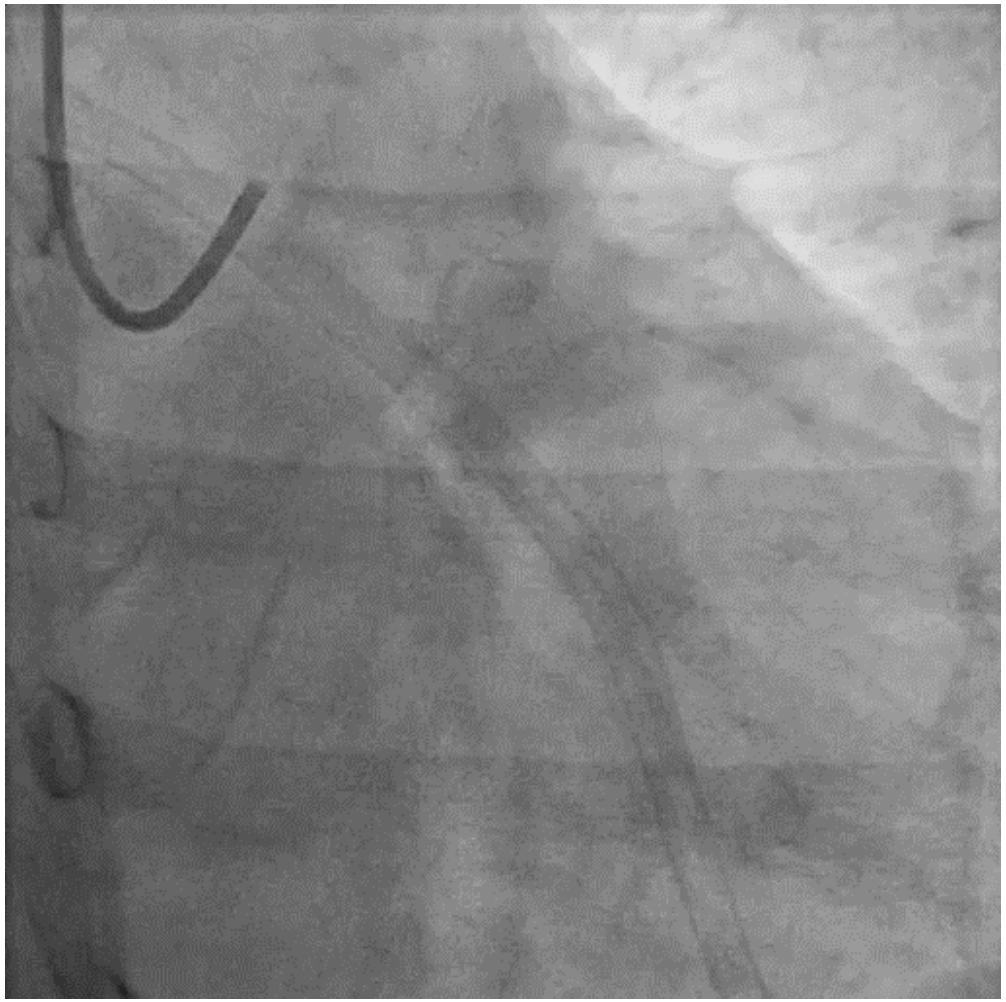

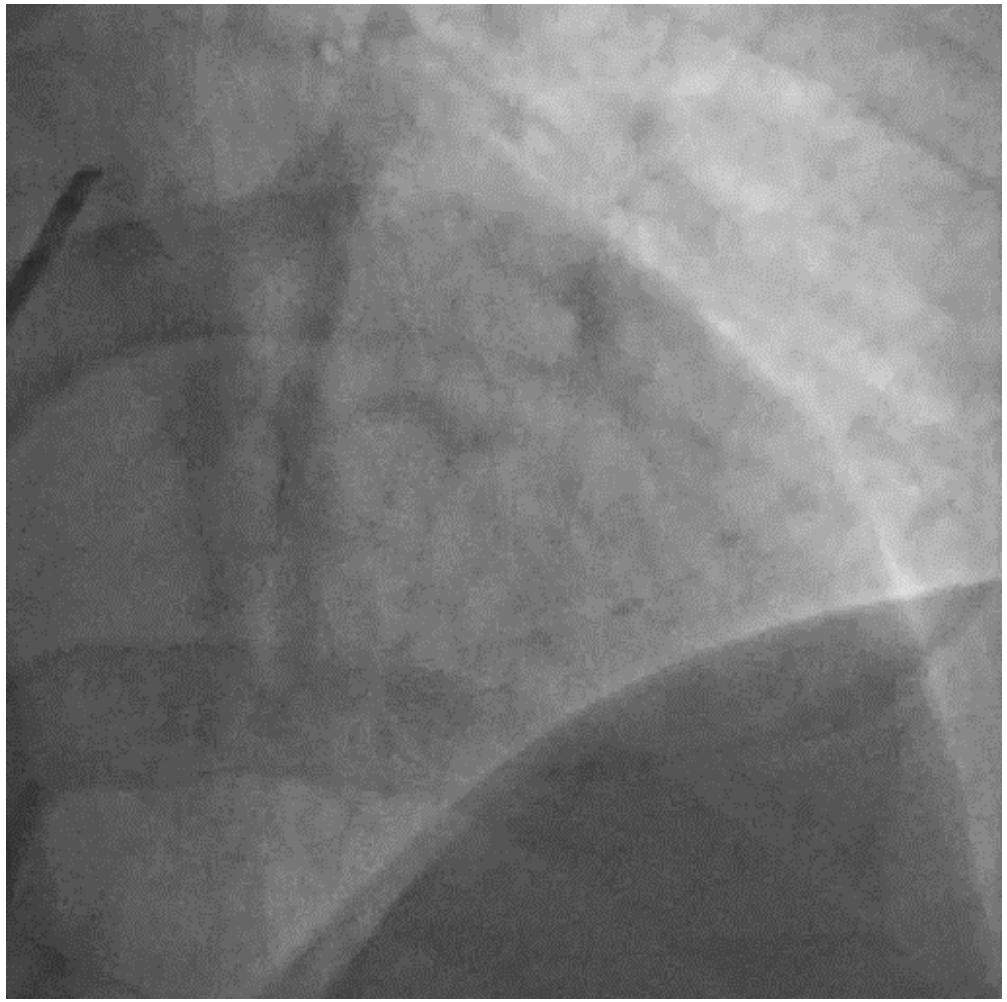

PCI - LAD

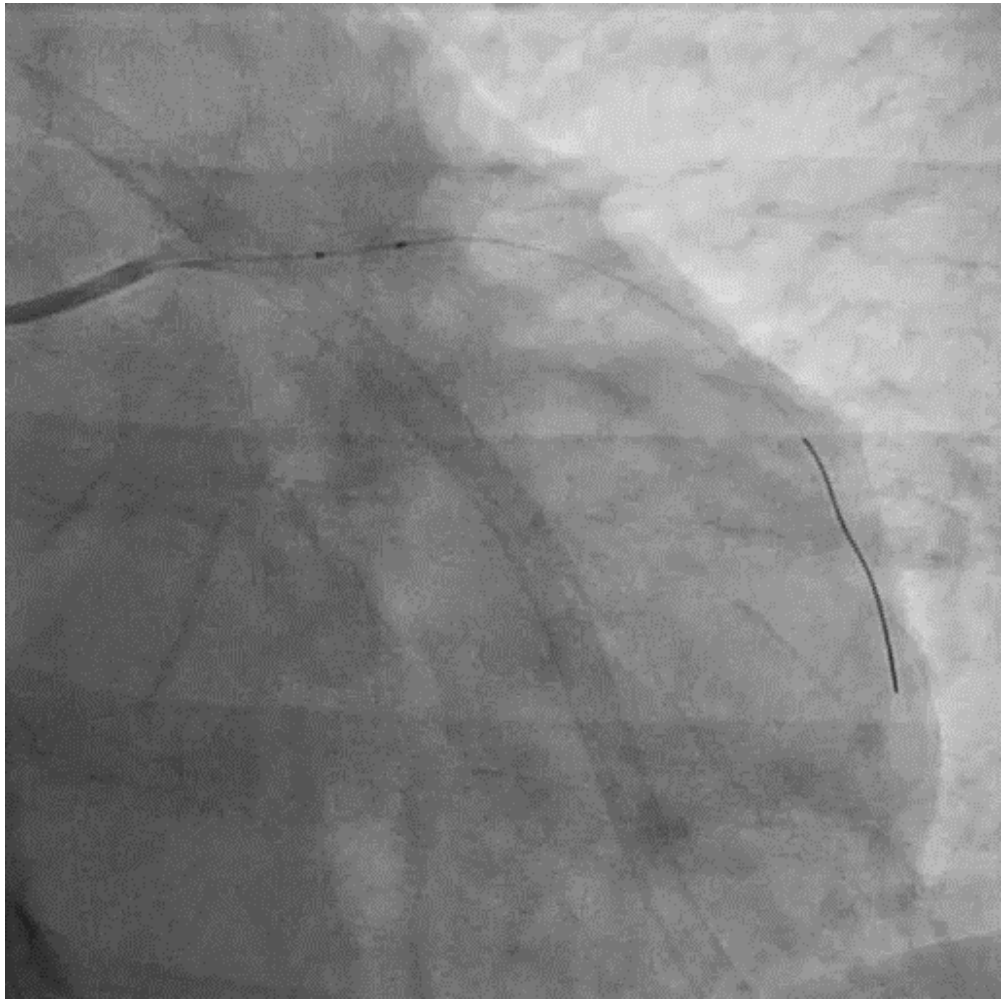

Balloon SC 3.0x10mm

LAD - IVUS

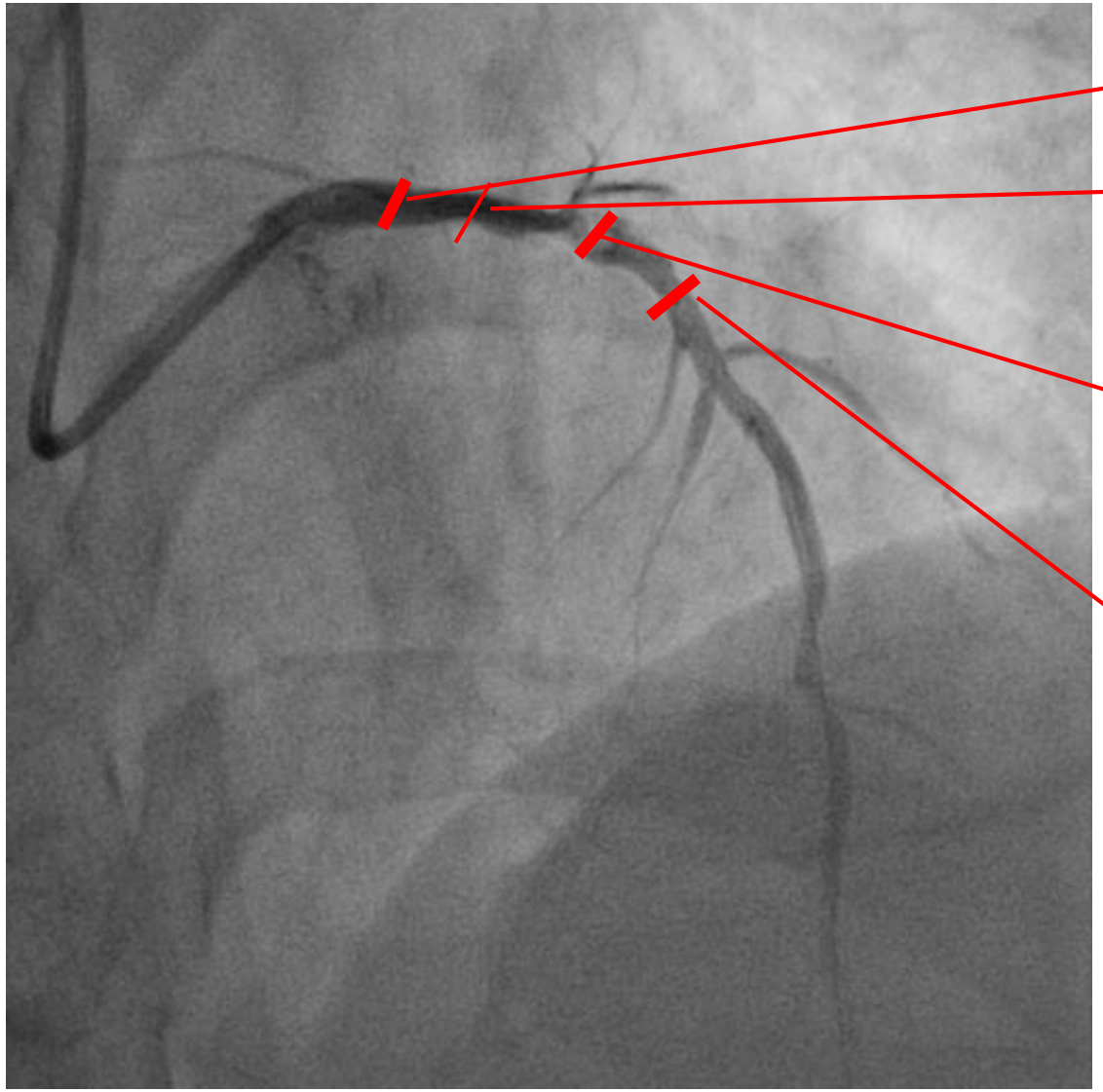

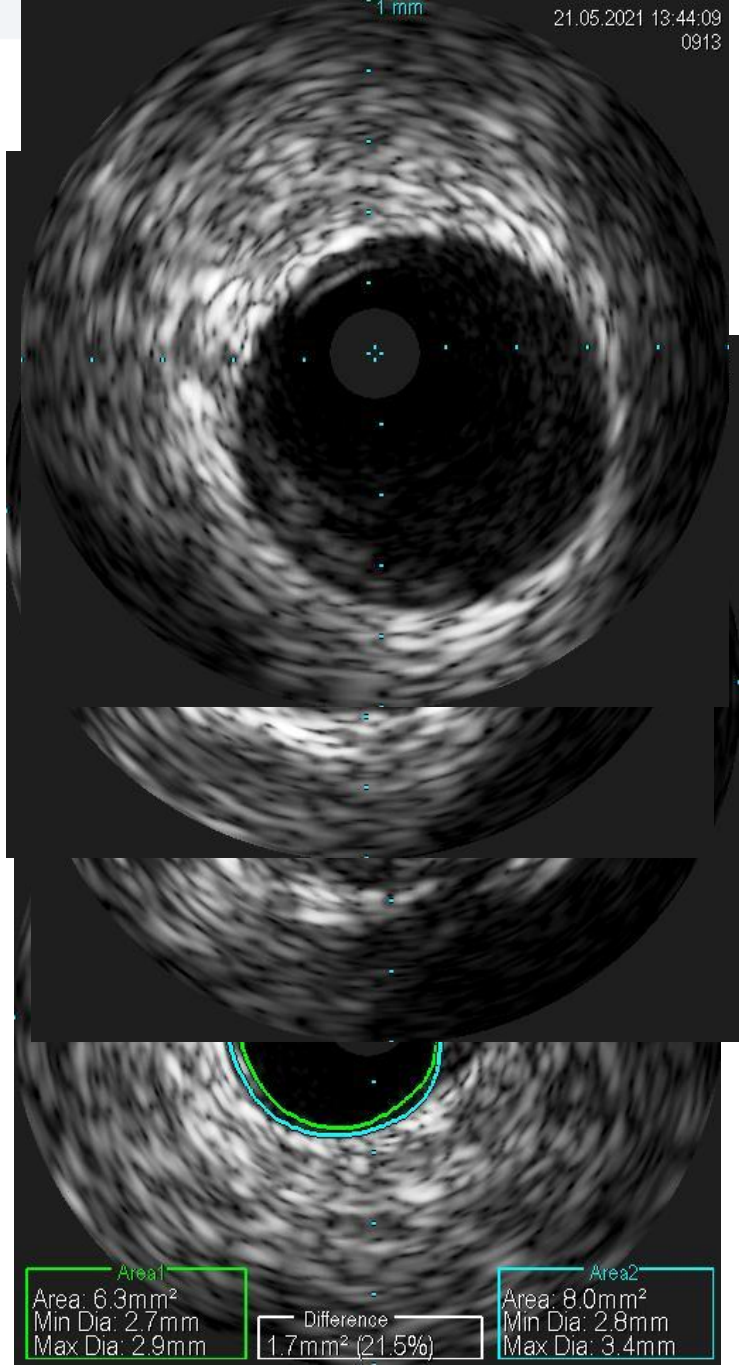
1 mm
21.05.2021 13:44:09
0913
Area1
Area: 6.3mm²
Min Dia: 2.7mm
Max Dia: 2.9mm
Difference
1.7mm² (21.5%)
Area2
Area: 8.0mm²
Min Dia: 2.8mm
Max Dia: 3.4mm

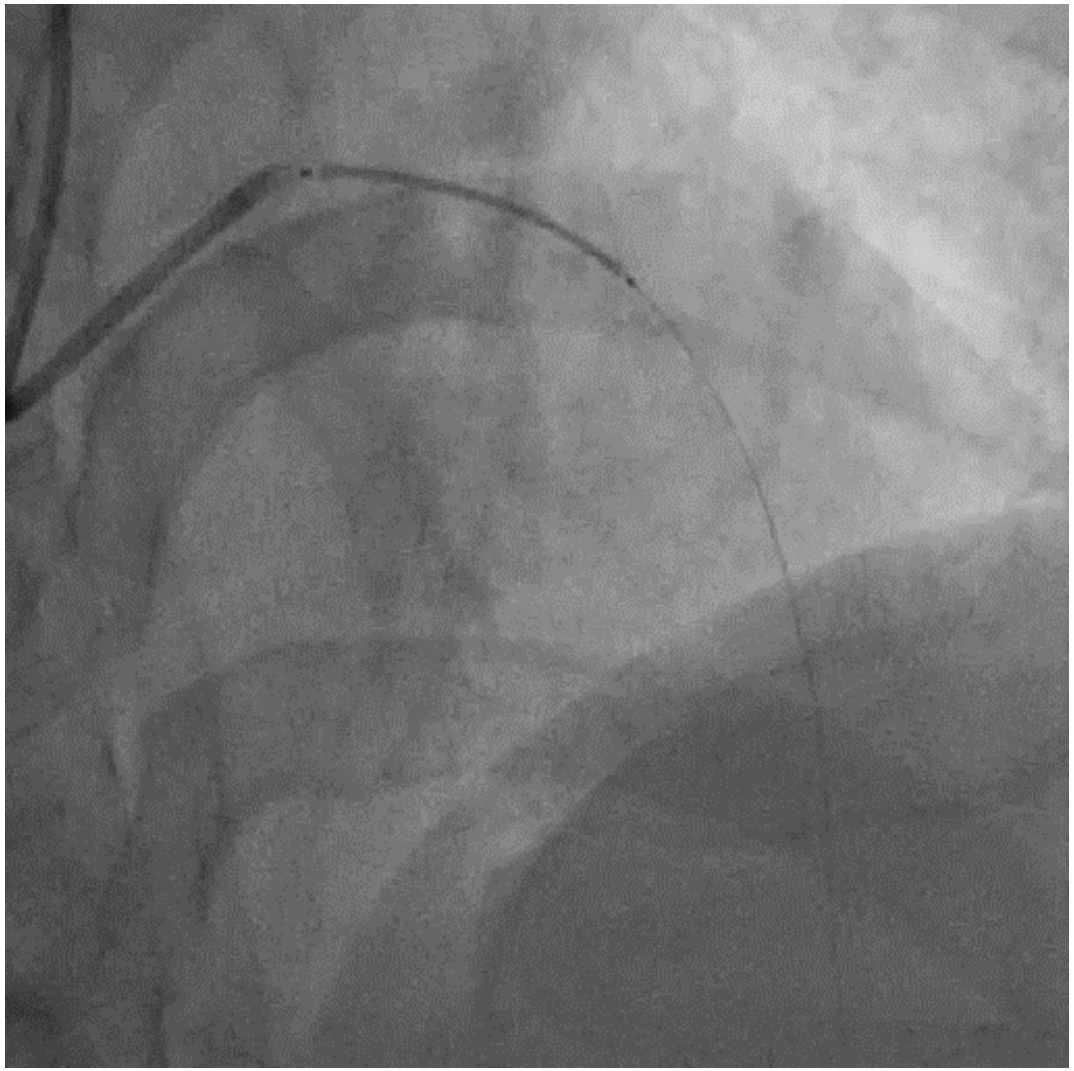

Resolute Onyx 3.5 x 30 mm

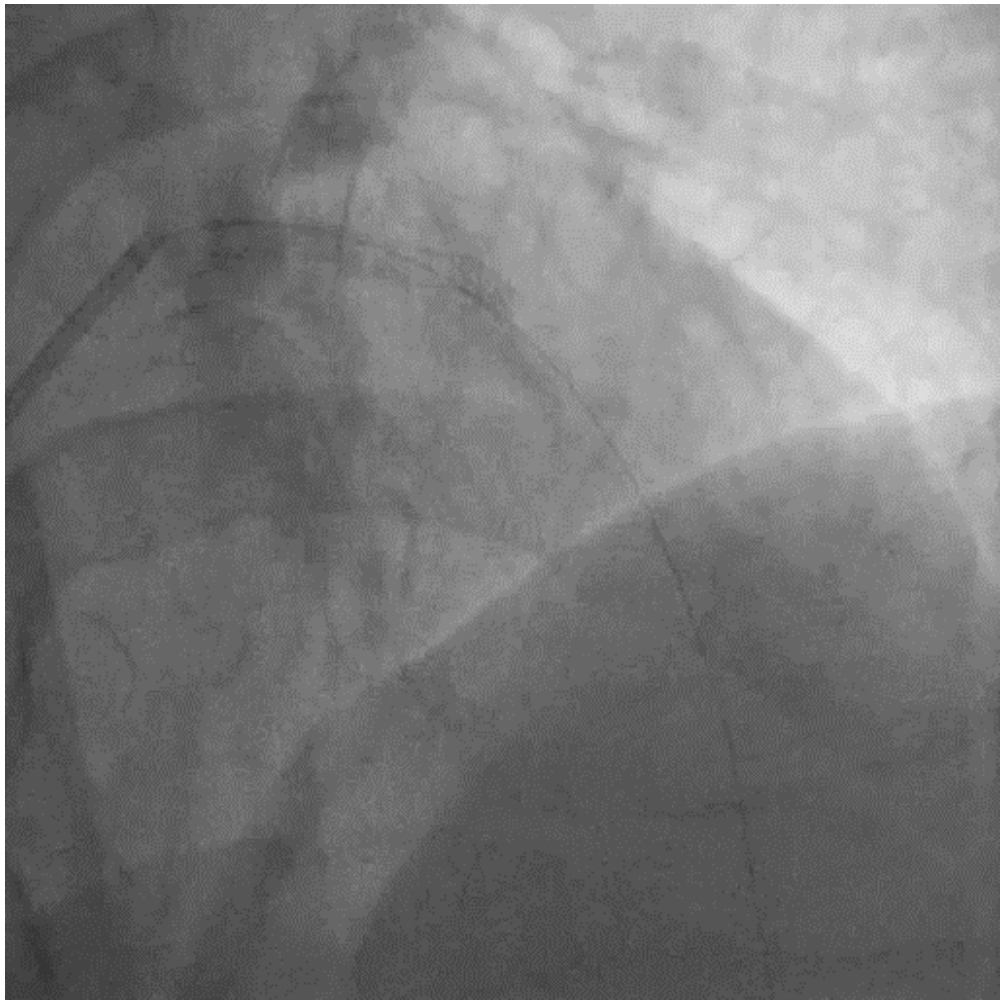

Post Dilatation

NC balloon 3.5 x 12 mm

POT

NC balloon 5.0 x 12 mm

TCTAP 2022

Final result

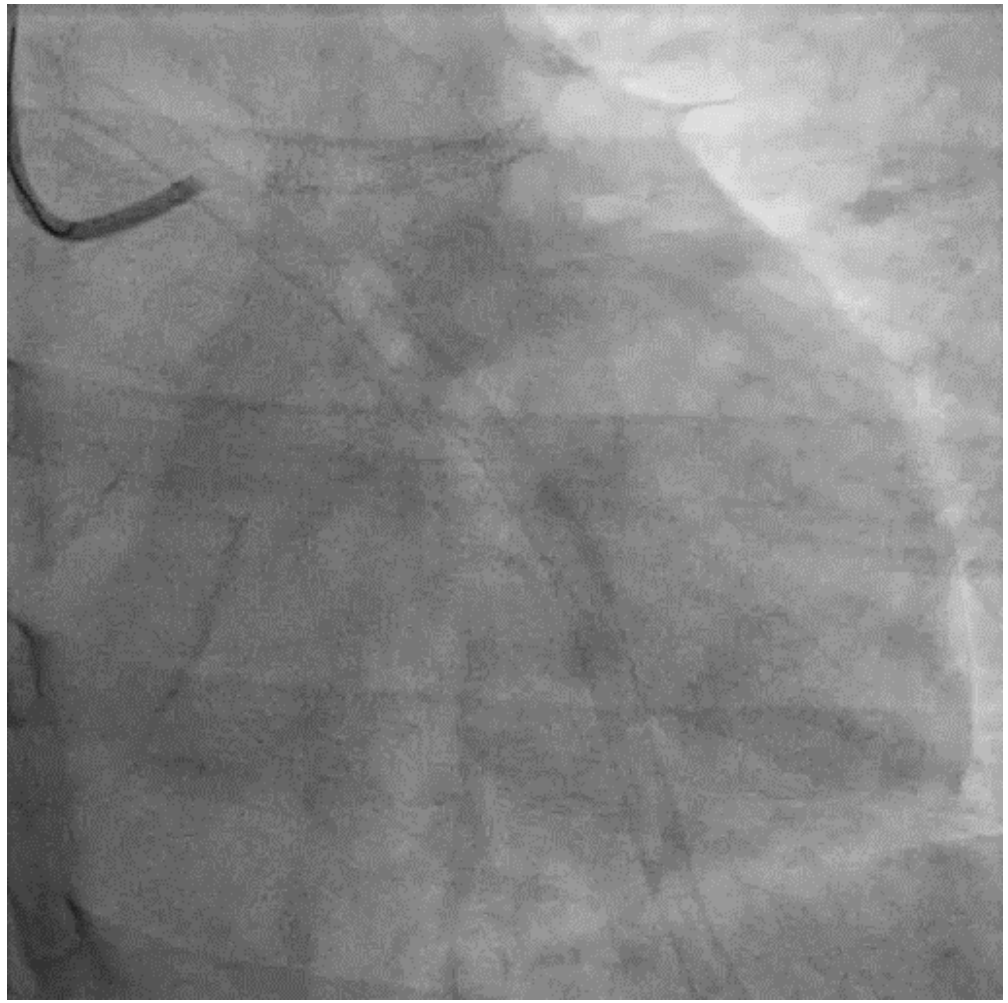

DAPT

3rd day

- Hematemesis
- Hb 16 → 14 g/dL
- NGT → fresh blood
- BARC 2

Figure 1: PRECISE–DAPT Score

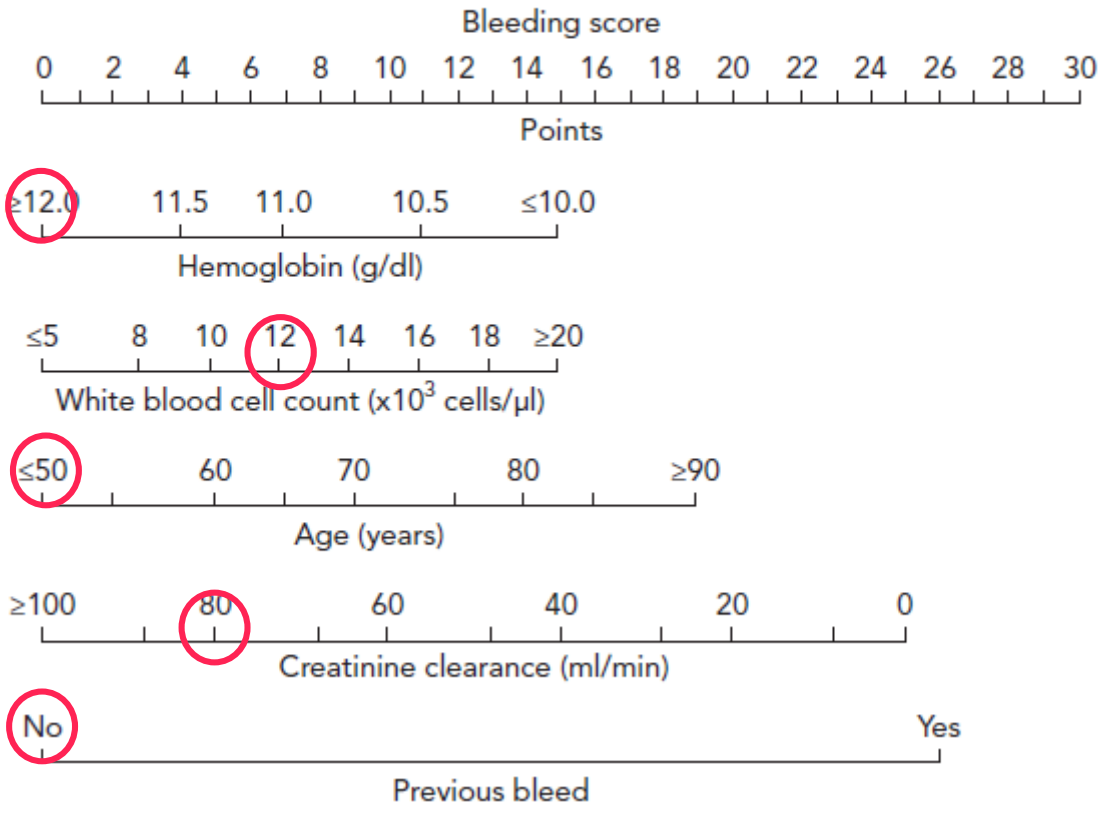

RESULT:

Cluster of risk:

Low

Score Calculated

14

12 months risk of TIMI major or minor Bleeding

0.8%

12 months risk of TIMI Major Bleeding

0.5%

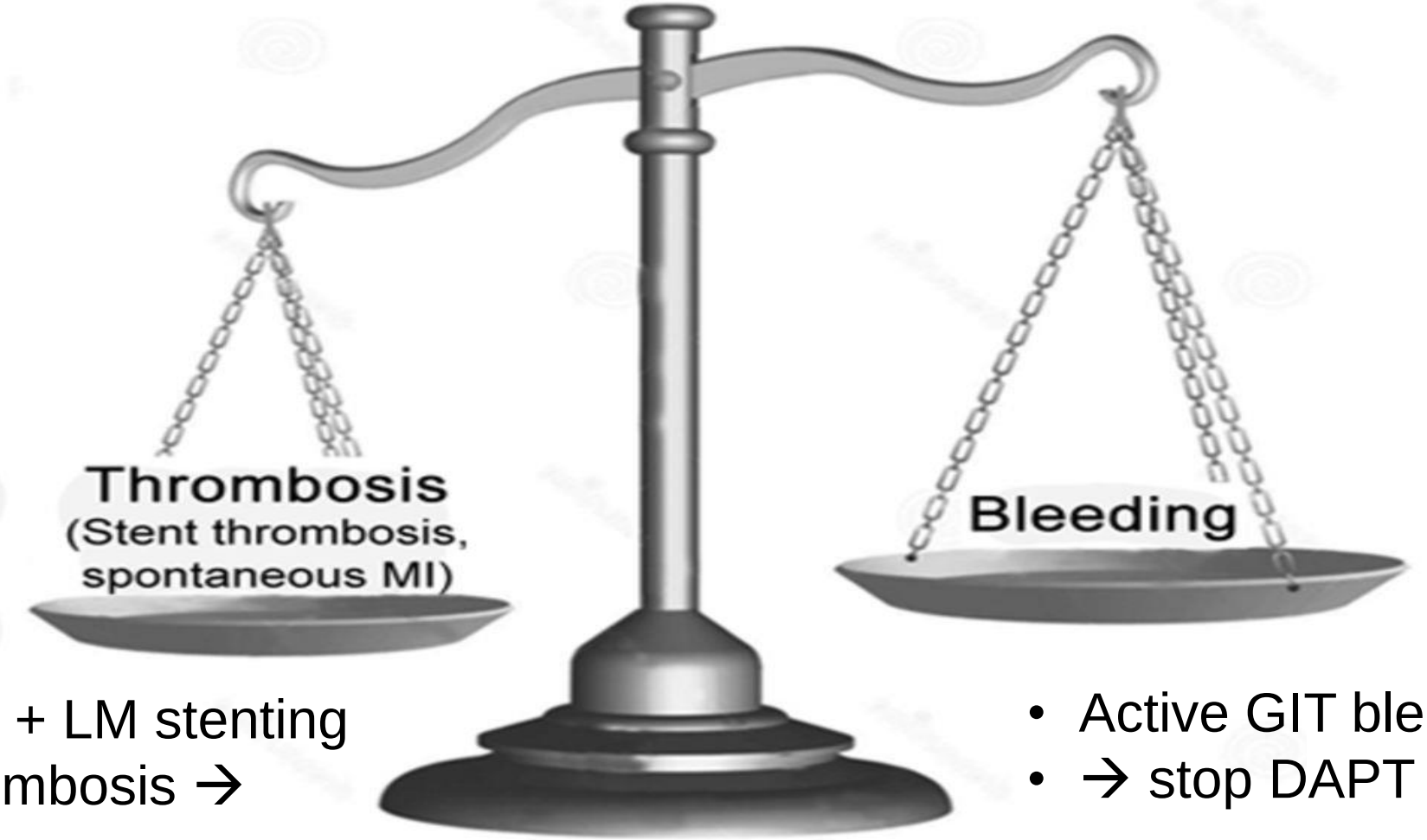

- Primary PCI + LM stenting
- → stent thrombosis → hazardous!!

LMWH (enoxaparin) → 1x60 mg SC

- Active GIT bleeding
- → stop DAPT

Call Gastroenterologist !!
→Urgent Endoscopy

Endoscopy

- Gastroesophageal junction → mucosal break > 5 mm
- Gastric – duodenal bulb → erosive, hyperemic, erythematous, and bleeding almost in every mucose
- Hemostasis → argon plasma coagulation

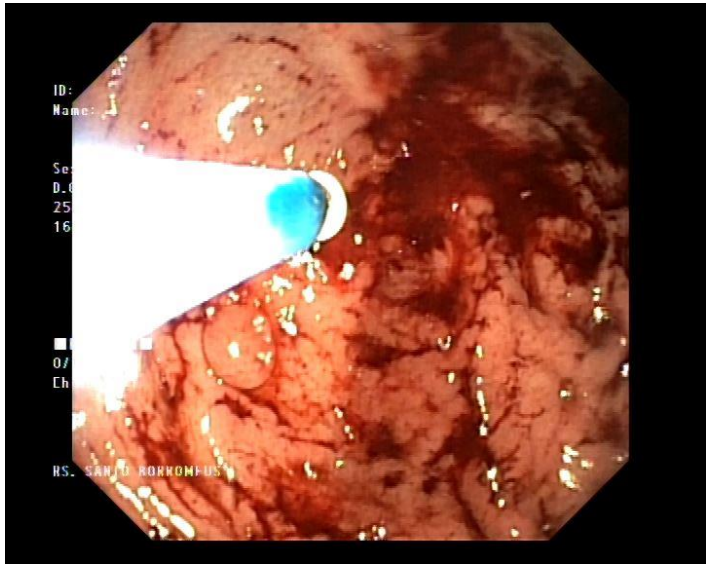

(A

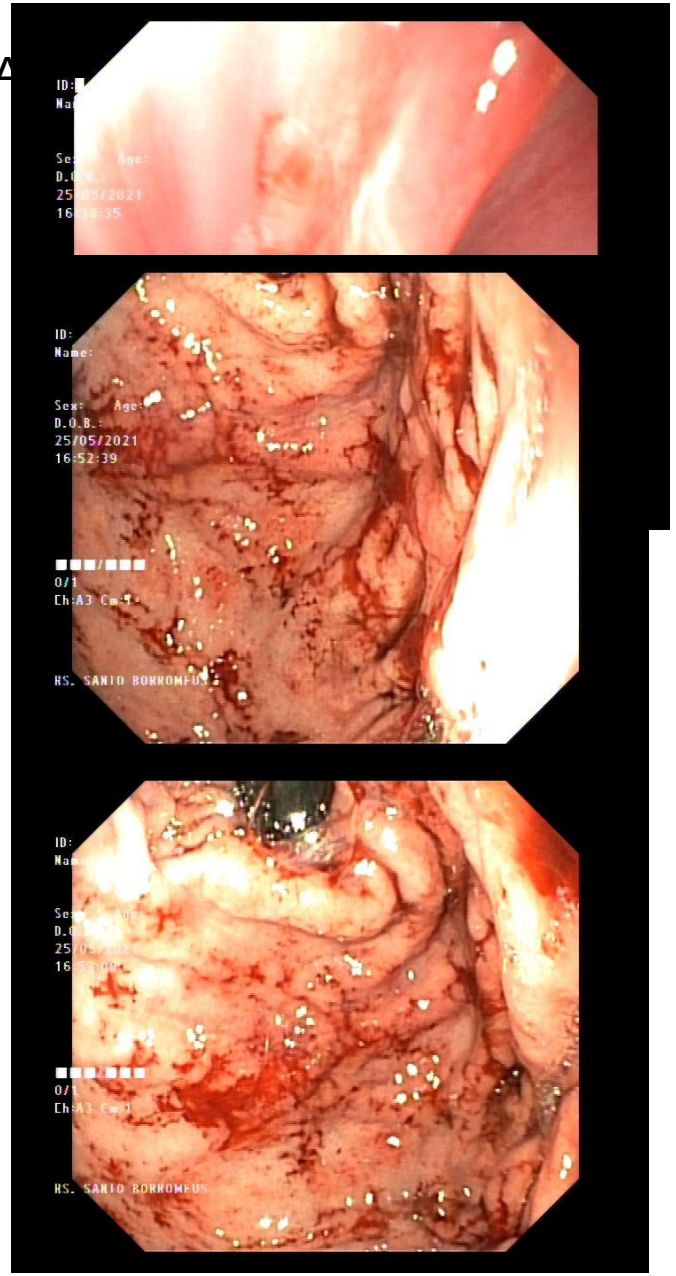

Next Day

- Hematemesis (-)
- NGT → no blood
- Test feeding → Liquid food → no residual
- Still on LMWH

TCTAP 2022

2nd day

- Hematemesis (-)
- Loading dose → clopidogrel 600 mg
- LMWH stop

↓

- Hematemesis (-)
- NGT → no blood
- No residual

TCTAP 2022

3rd day

- Continue DAPT(aspirin 80 mg qd, clopidogrel 75 mg qd)

- Hematemesis (-)
- NGT → no blood
- No residual

- Angina (-)
- Stable vital sign
- ECG → changes (-)
- Hb 14.5 g/dL

- Discharged with DAPT (7th day)

TCTAP 2022

Take home message

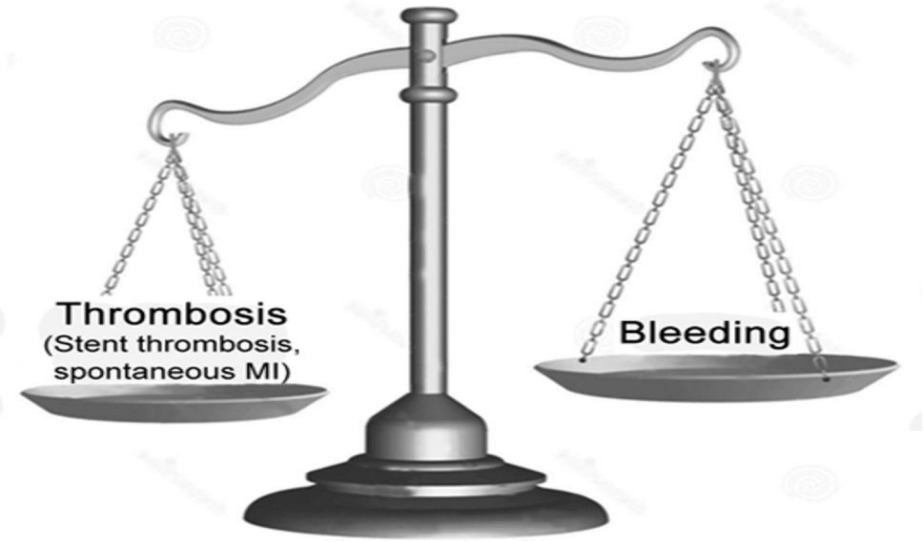

- Important
- Even in low risk patients

BALANCE in every patients

Team Work !!!