

***“VT blotted out everything
except a stent”***

Tae Woo Kim, RT

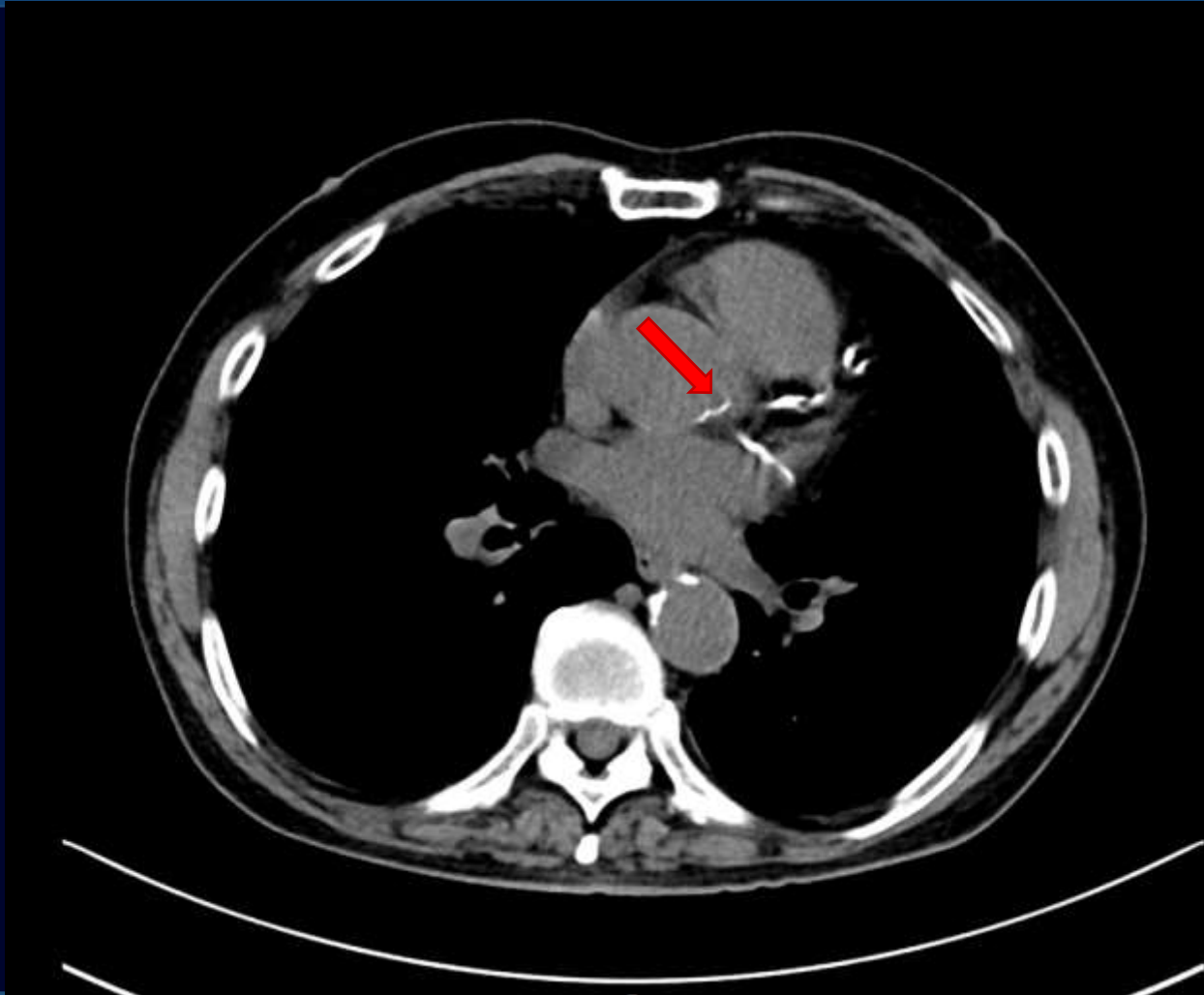
The Catholic University of Korea

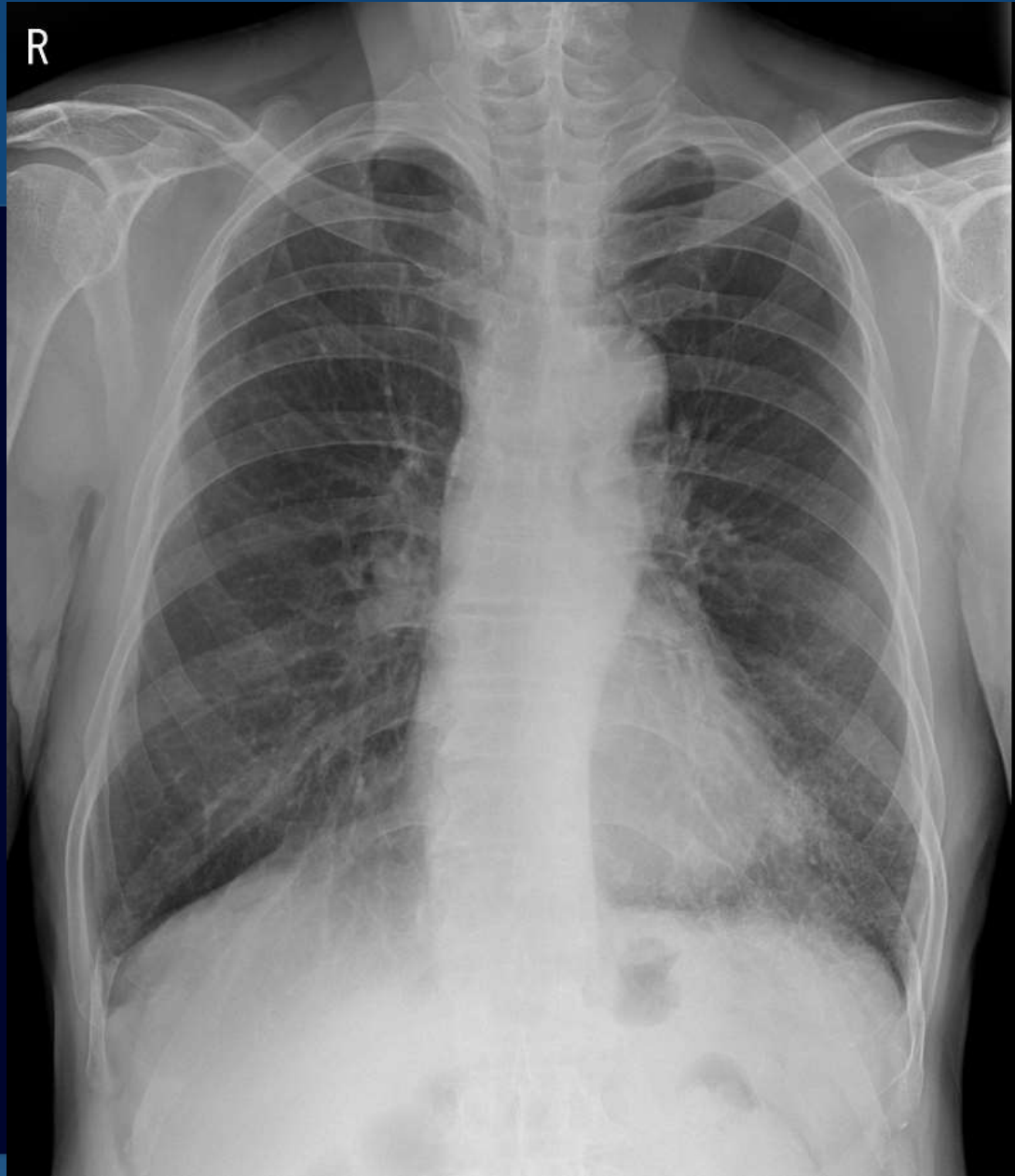Eunpyeong St. Mary's Hospital

77/M severe calcification on chest CT

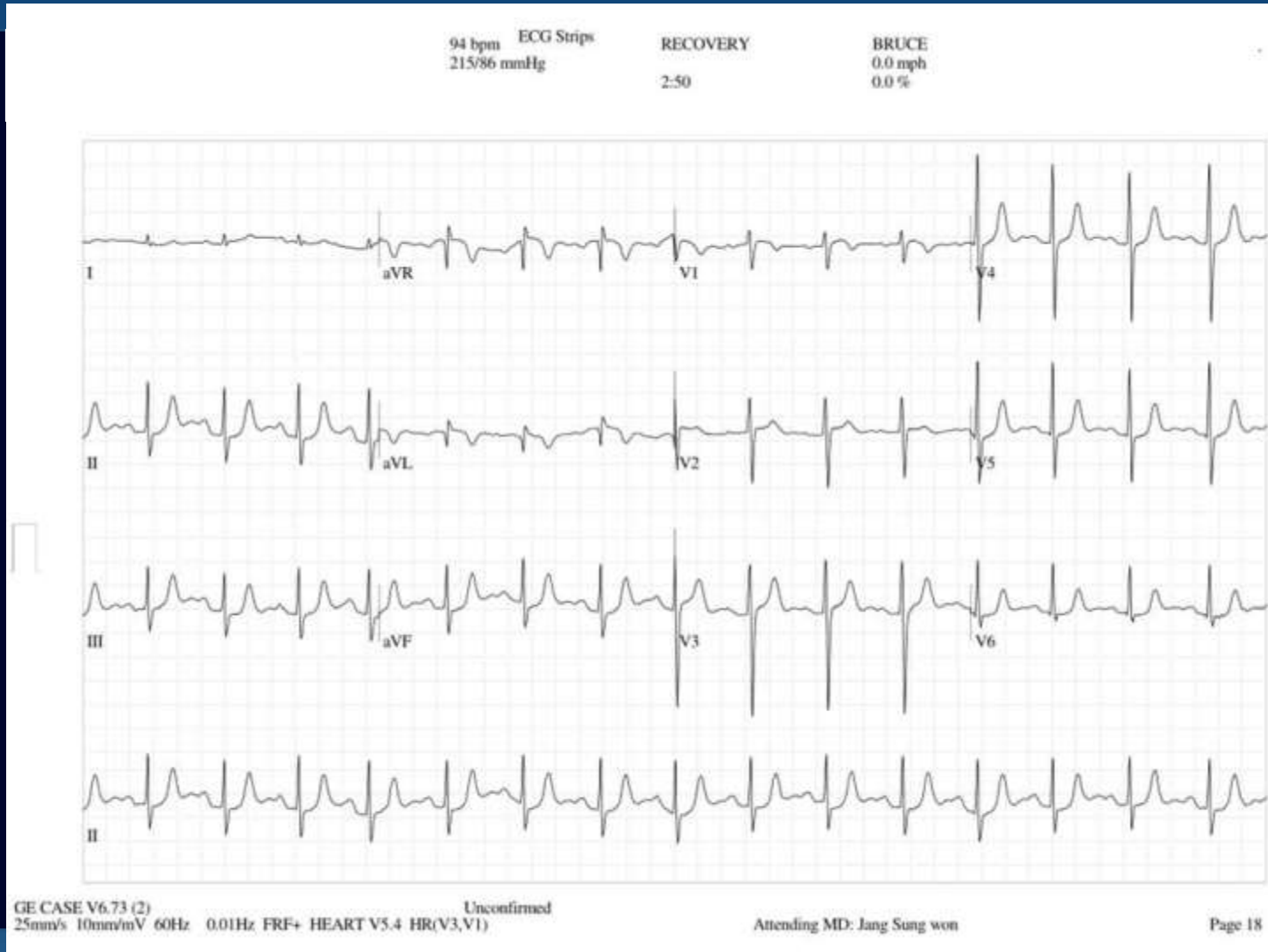
- 77/M, 167/63 (BMI 26.8)
- C/C: consulted for calcification on chest CT and DOE
- PMH
 - Emphysema
 - Current smoker

Chest CT

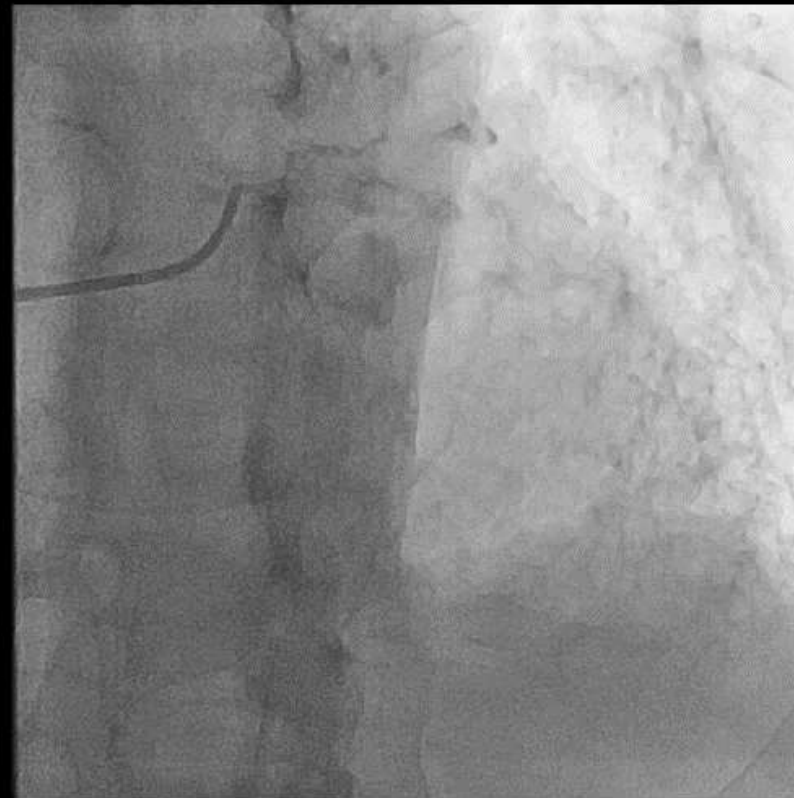
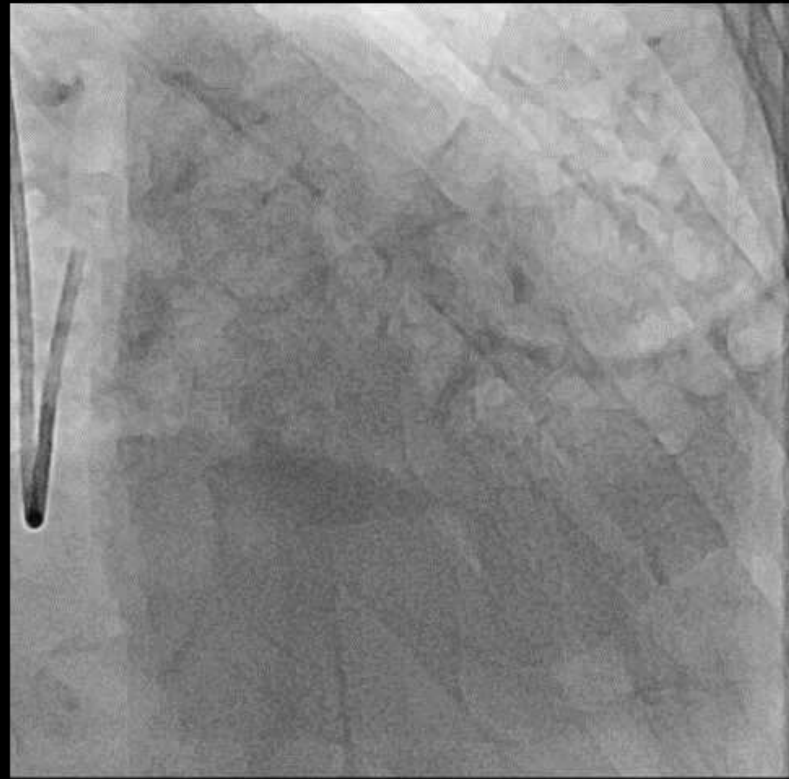




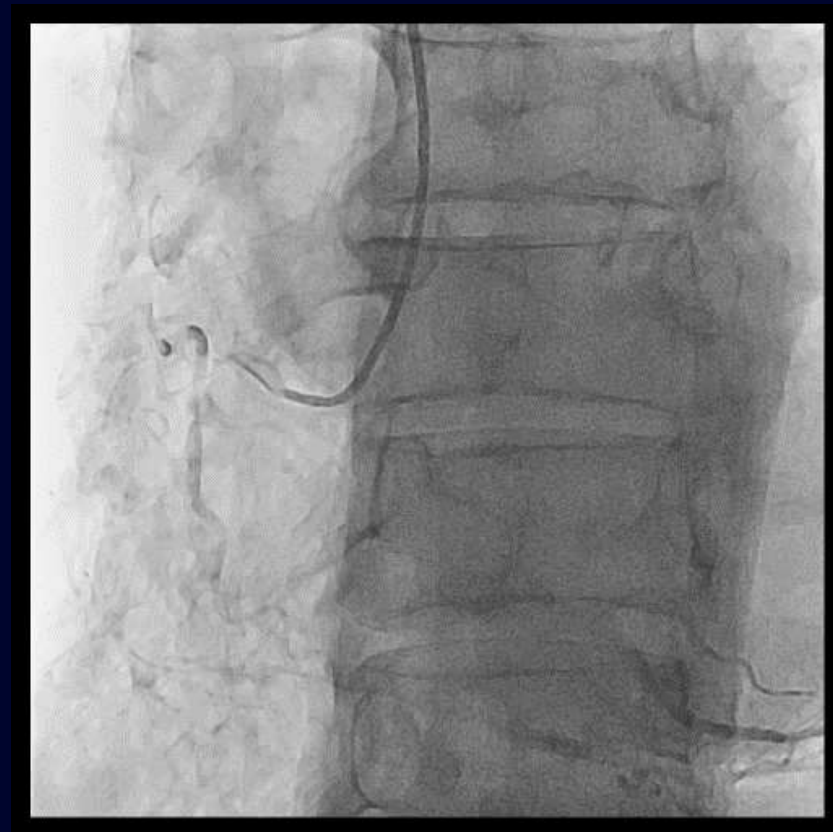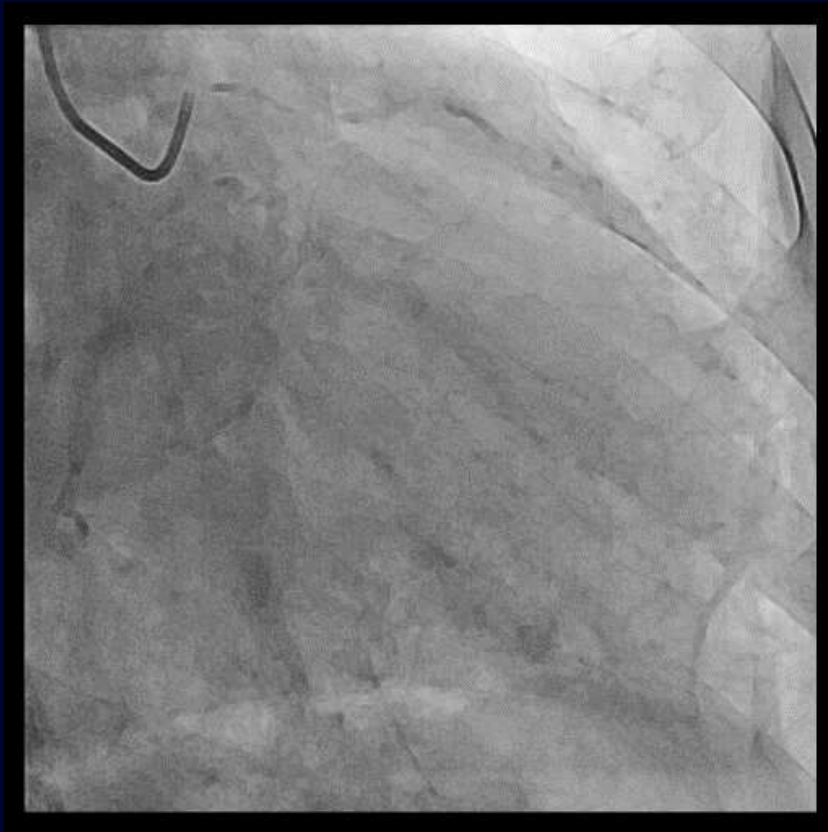TMT



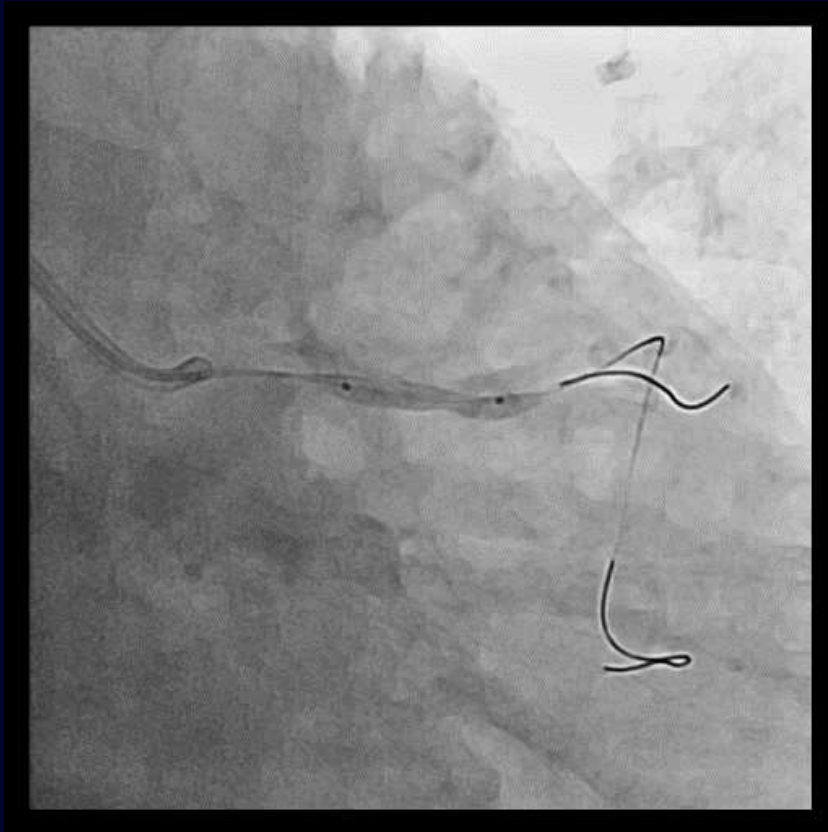
LAD and LCX disease



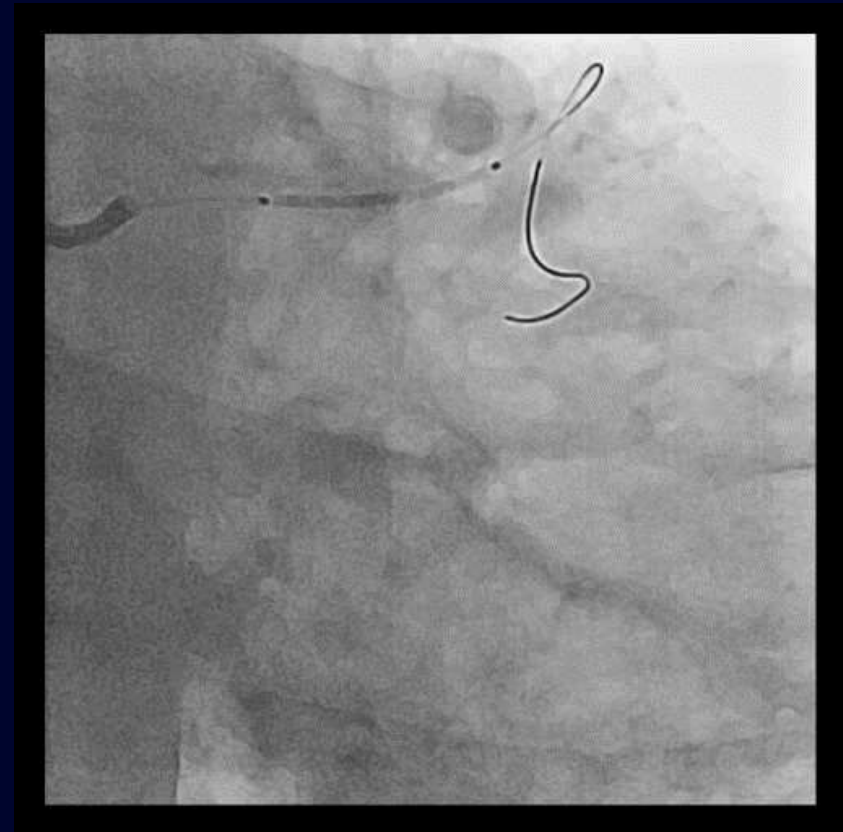
LAD FFR 0.90 -> 0.76



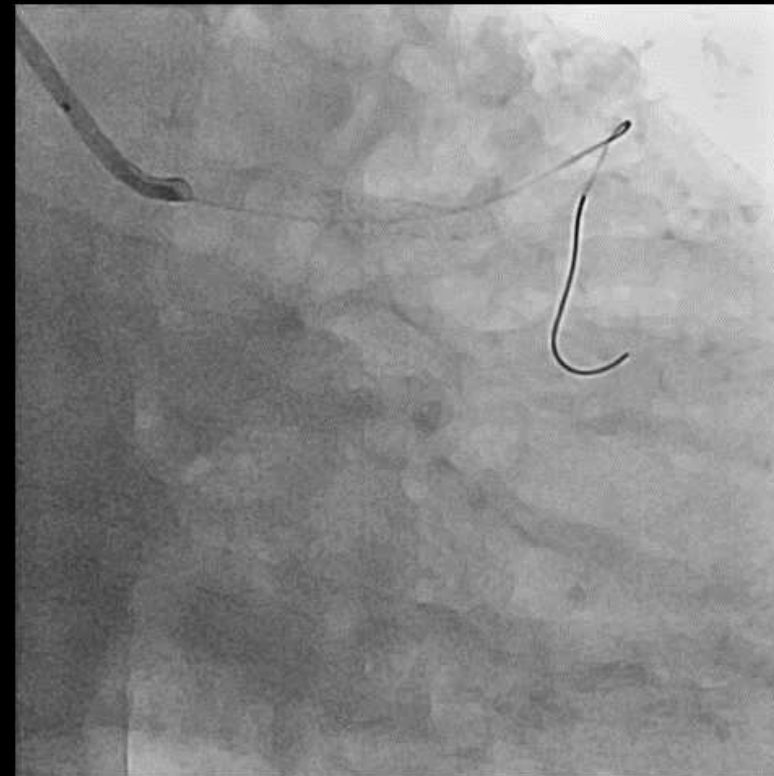
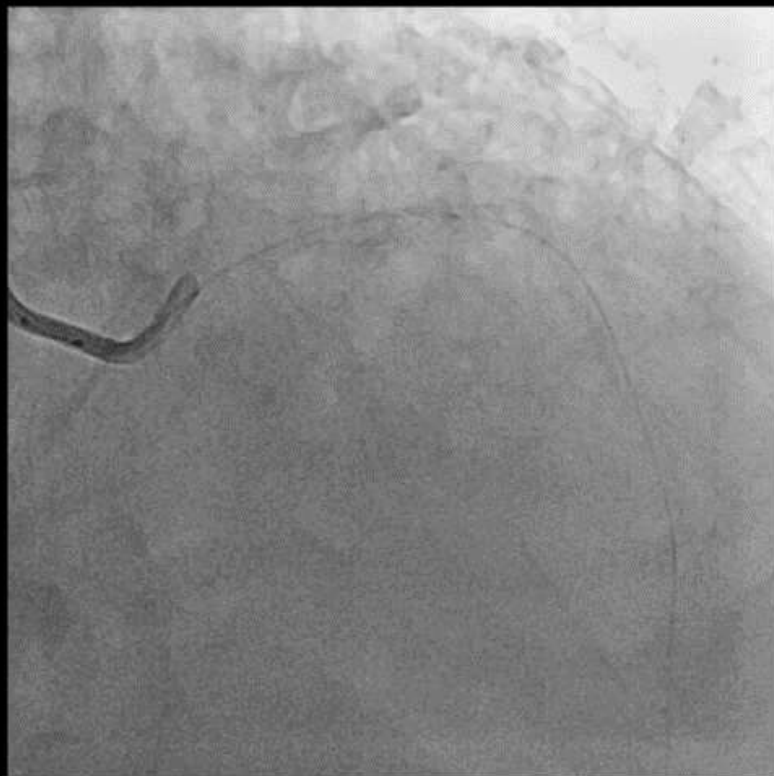LAD PCI



Compliant balloon 2.5/15

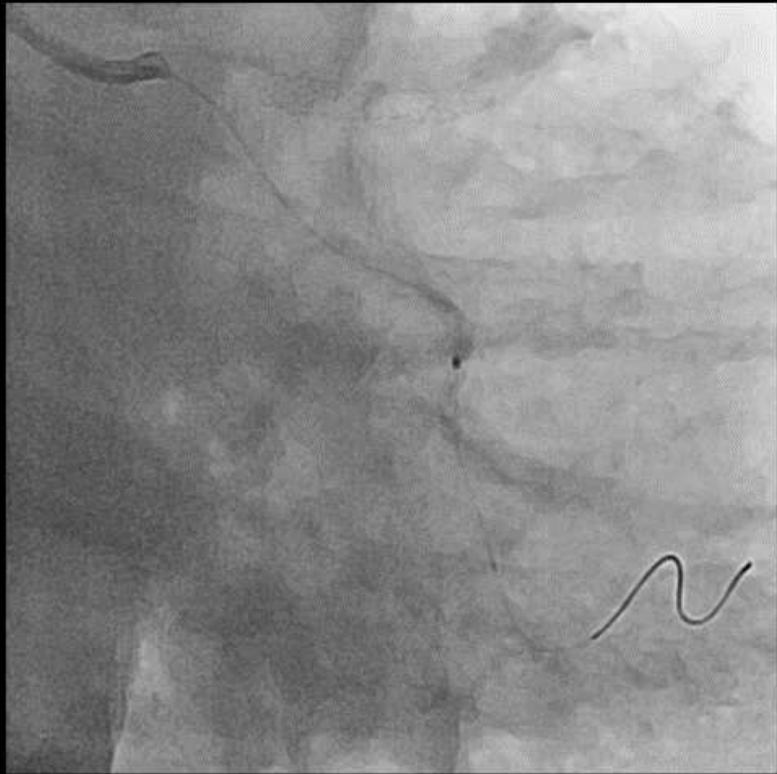

PtCr-DES 3.0/20

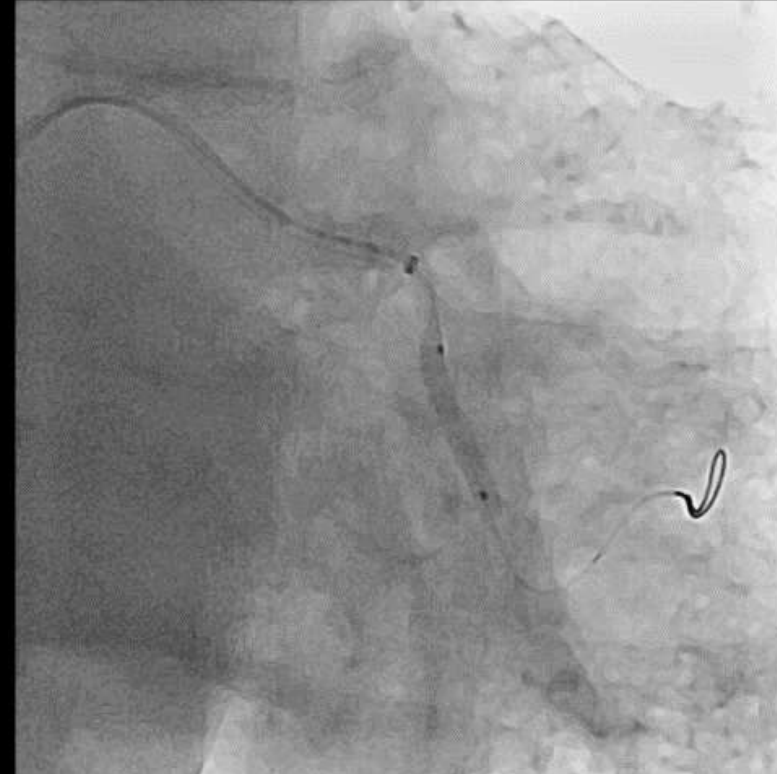

After NC balloon 3.25/15

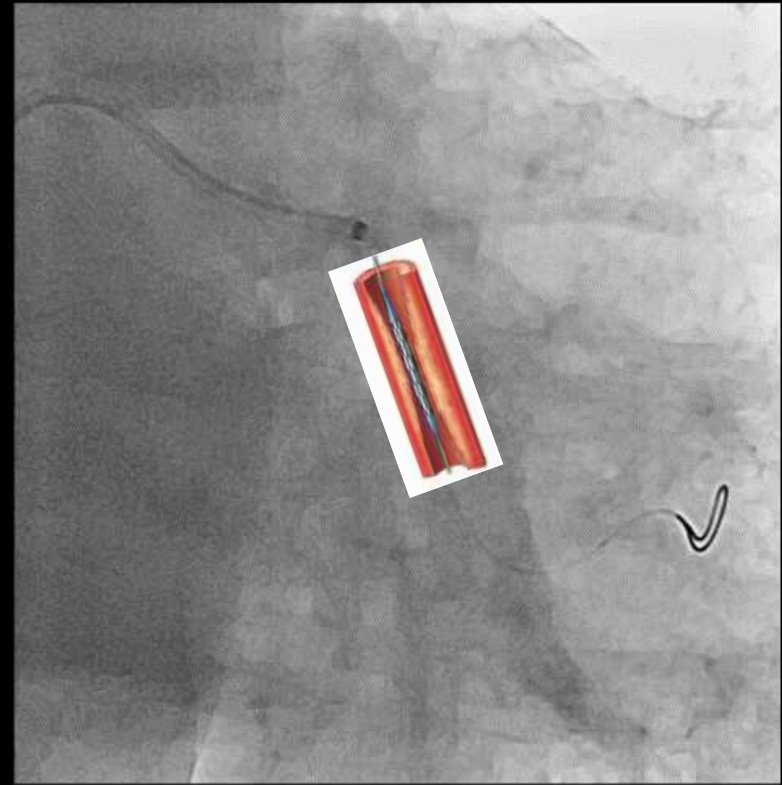
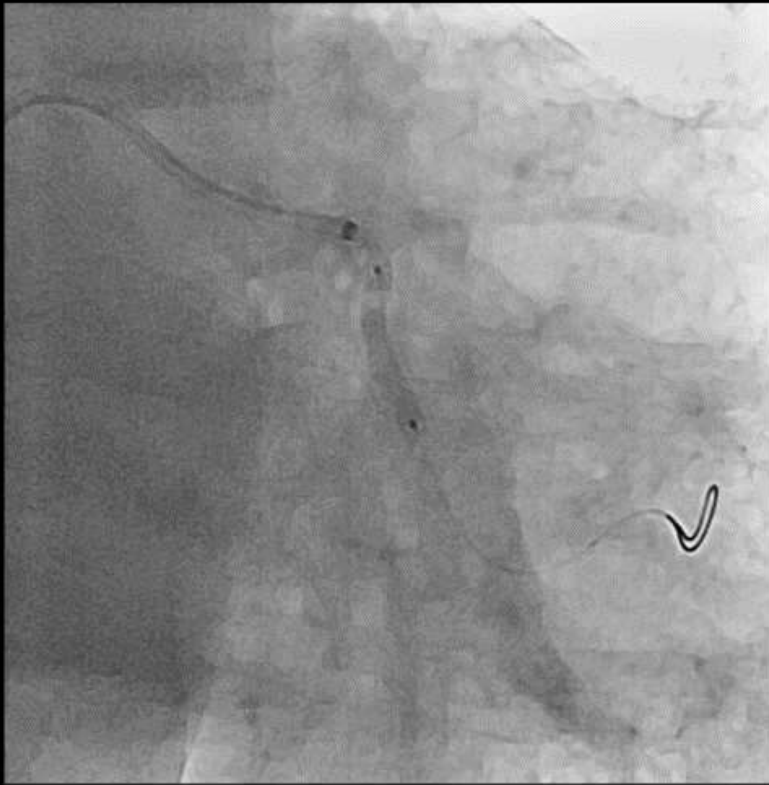LCX PCI



Compliant balloon 1.5/15
Compliant balloon 2.5/15

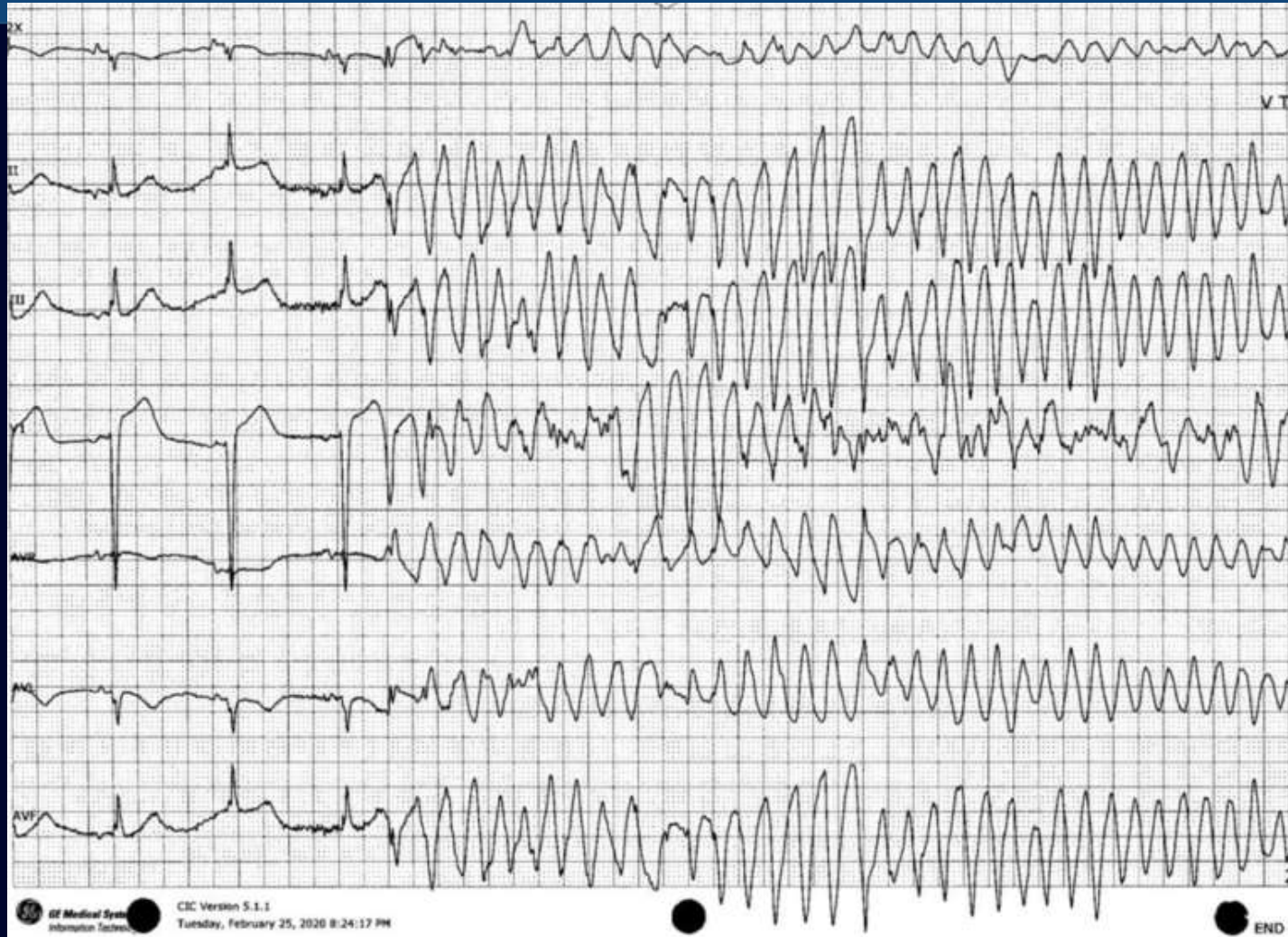


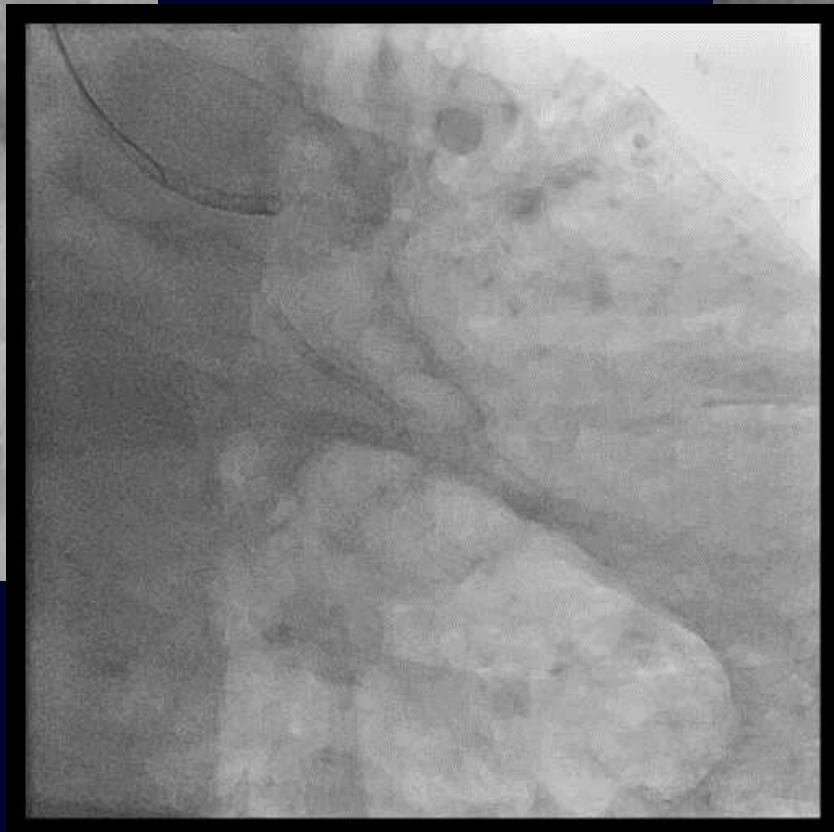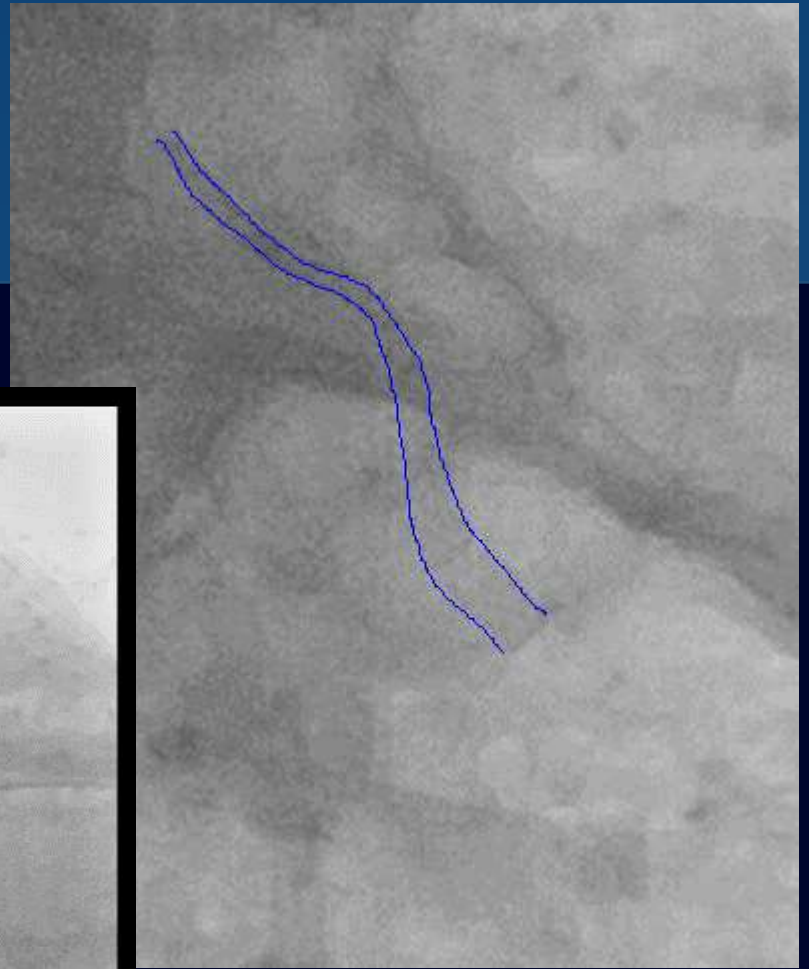
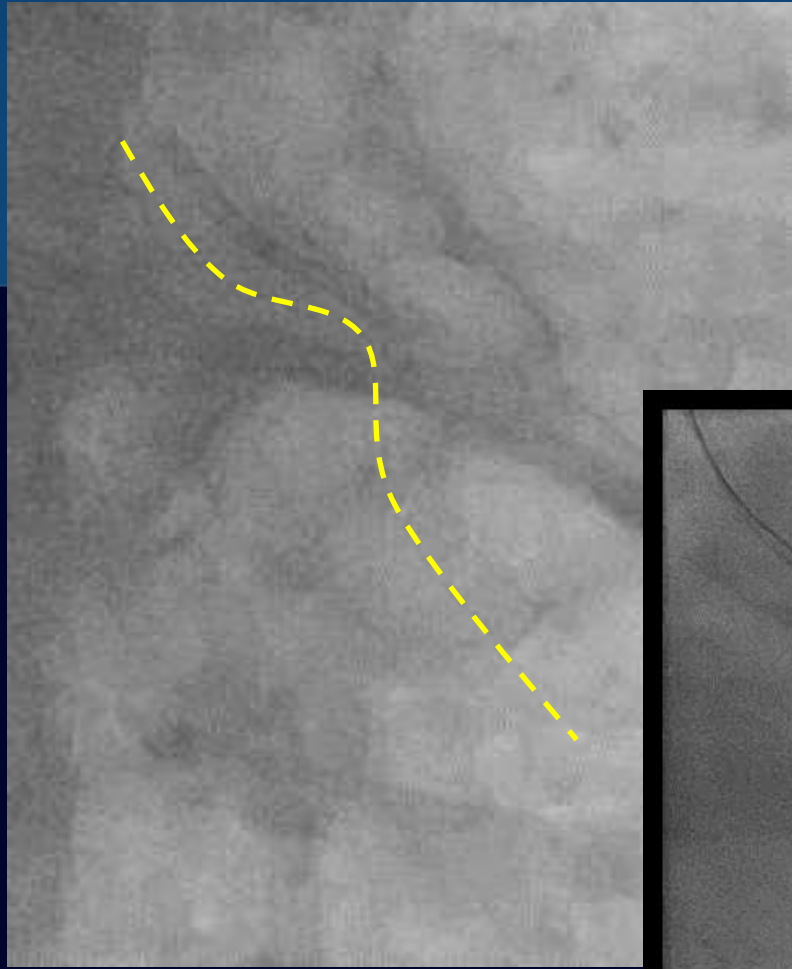
NC balloon 3.0/15 within
Guidezilla and XB 3.5



PtCr-DES 3.0/38

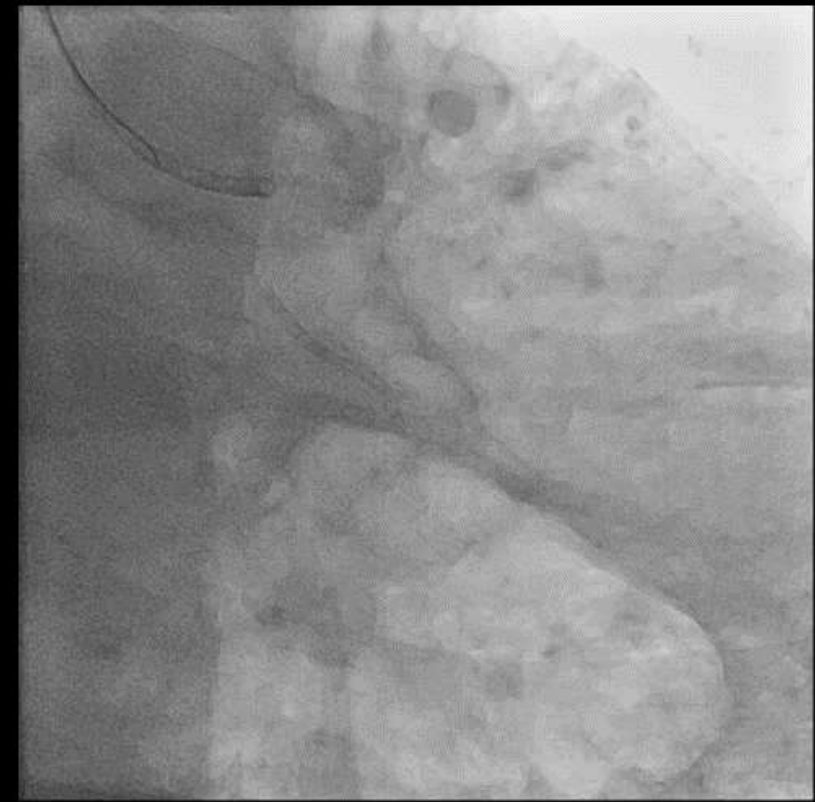VT arrest developed





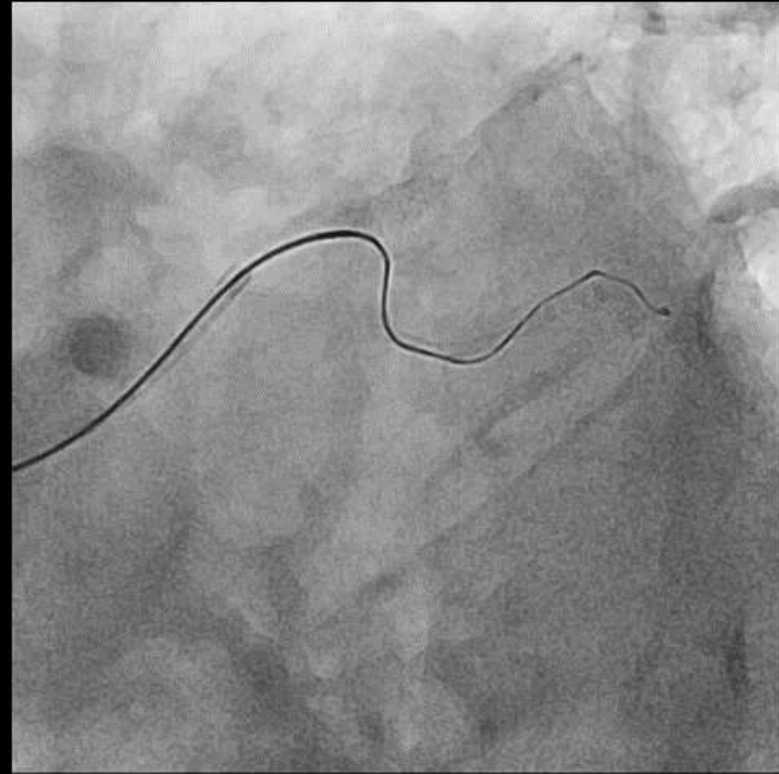
Everyone was not on the same page



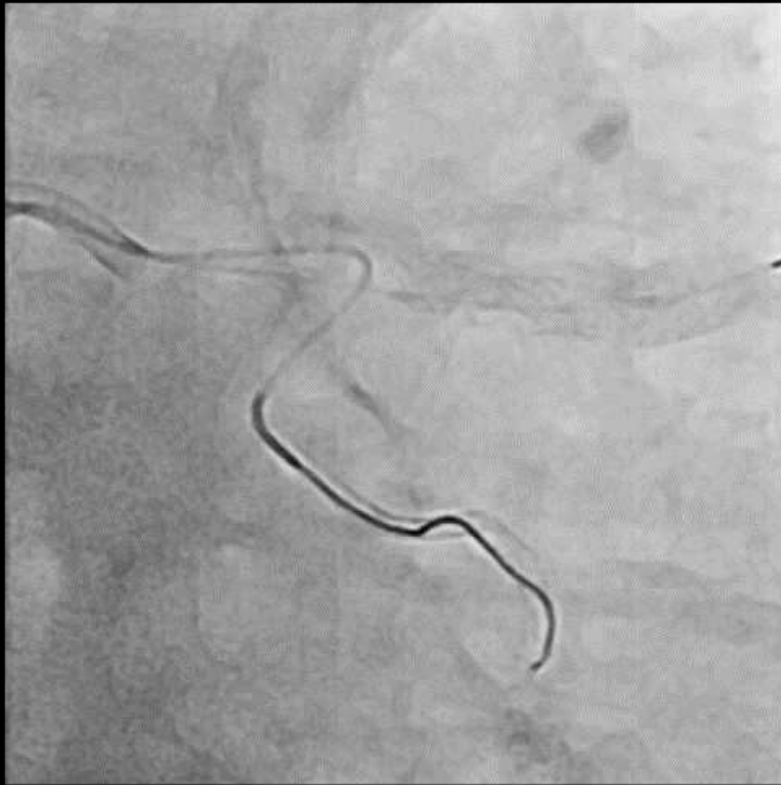




경주이야기
기우의
가정 이야기

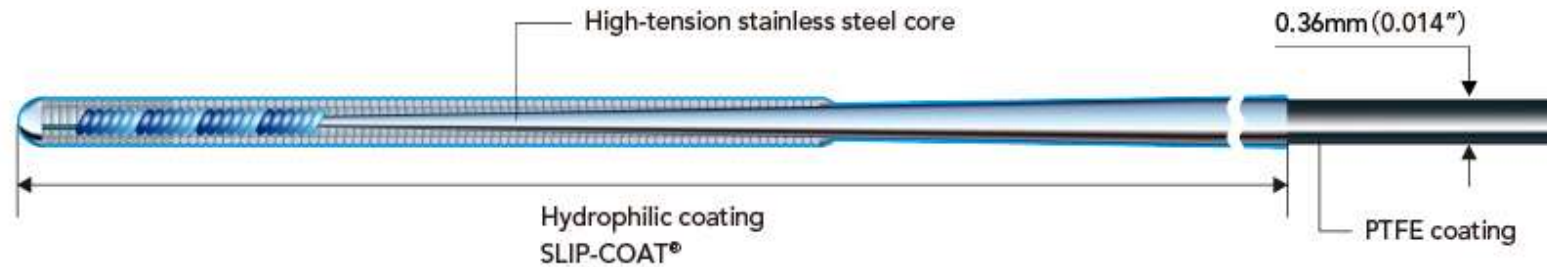


Fielder XT-R, XT-A, and
Gaia 1st within Corsair

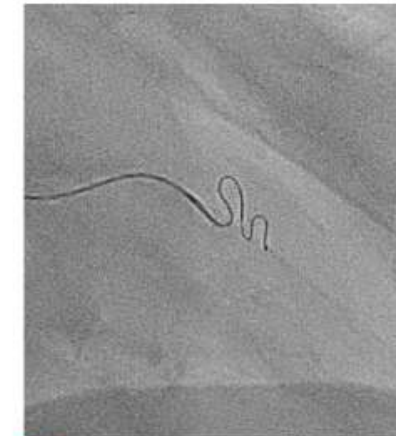
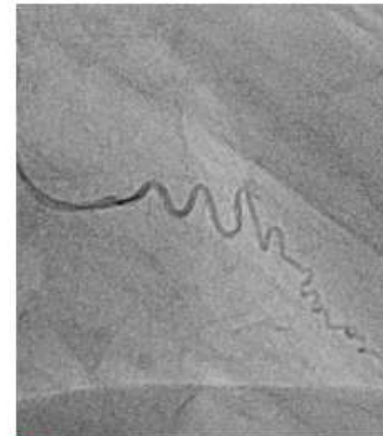

Soft rather than hard with SUOH 3

Structure & ordering information



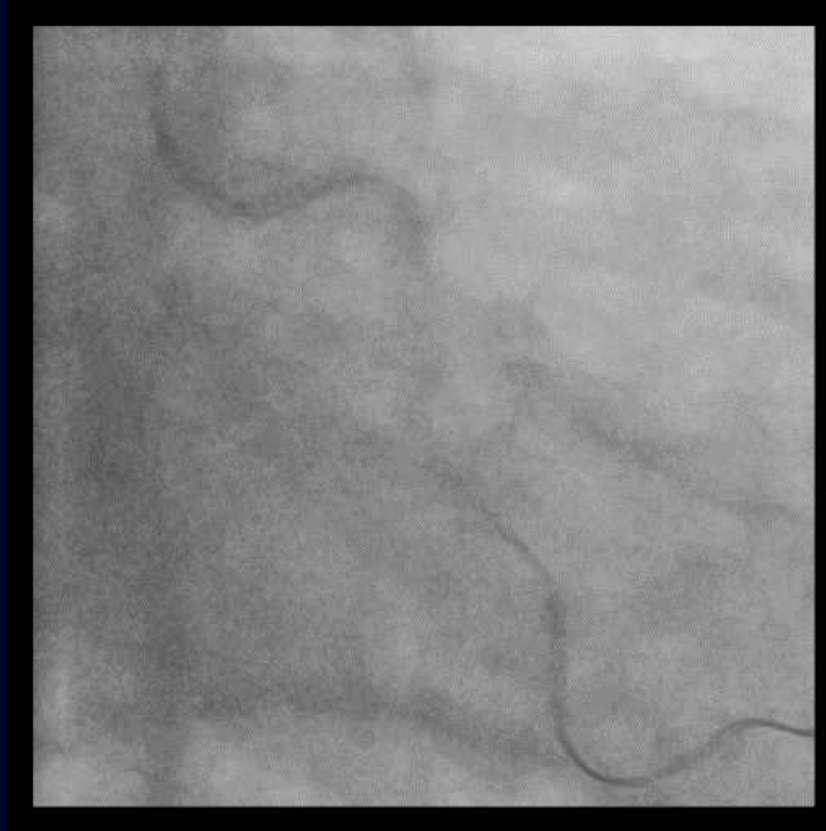
- **0.3 gf Tip load**
 - Softest available tip load at 0.3 gf
 - Improved shaft design allows superb trackability and crossability in severely tortuous vessels.
- **Flexibility and maneuverability**
 - gives highly effective torque transmission and flexibility.



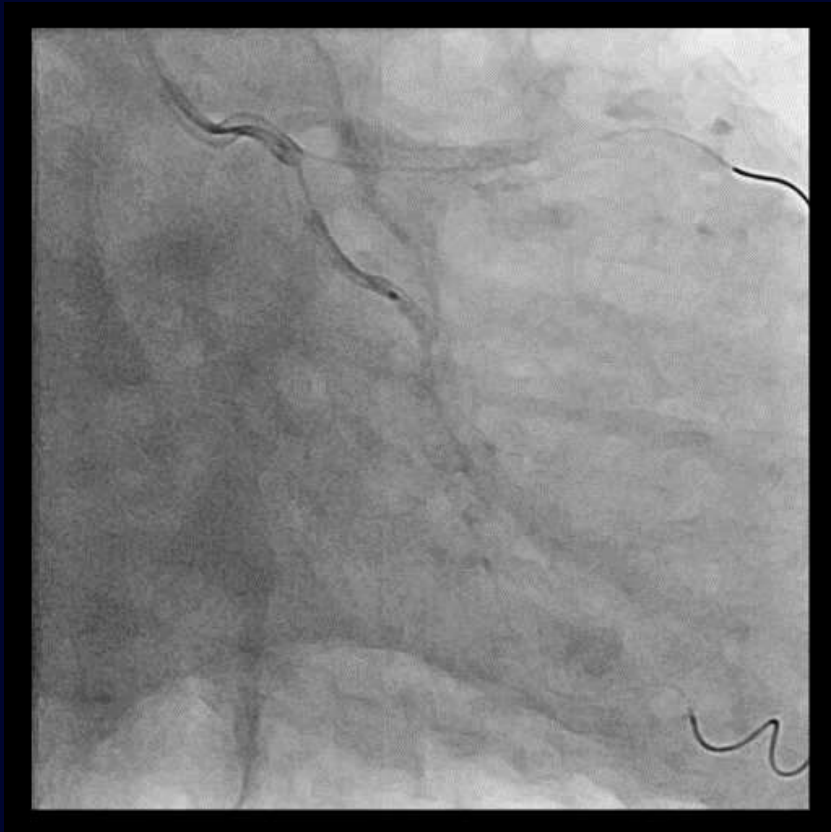■ Angiogram by tip injection

■ SUOH 03 Wiring

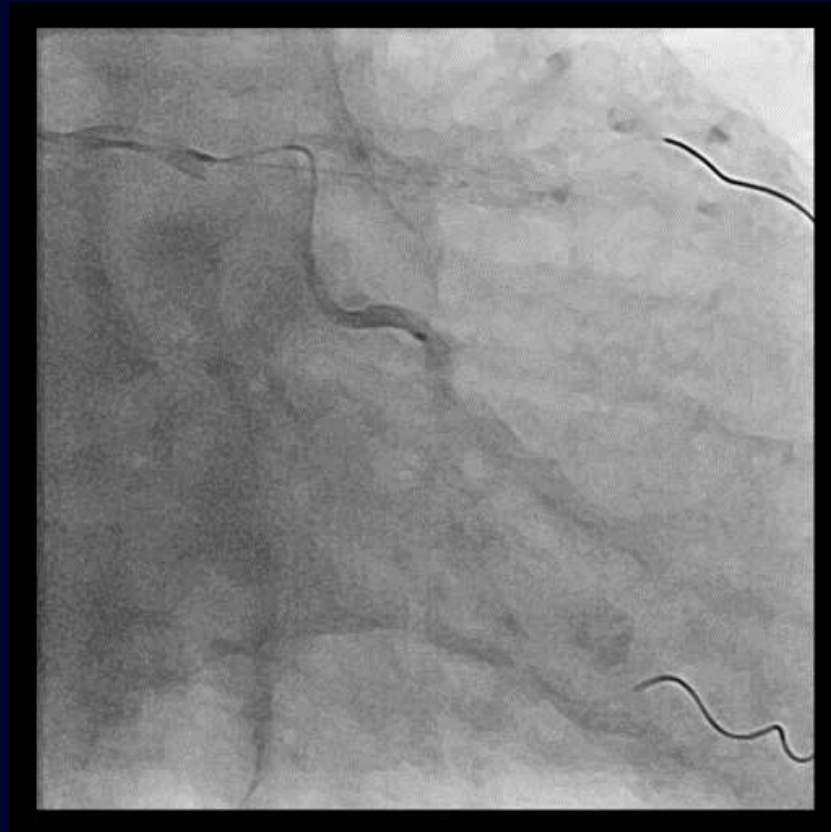SUOH 3 saved everyone



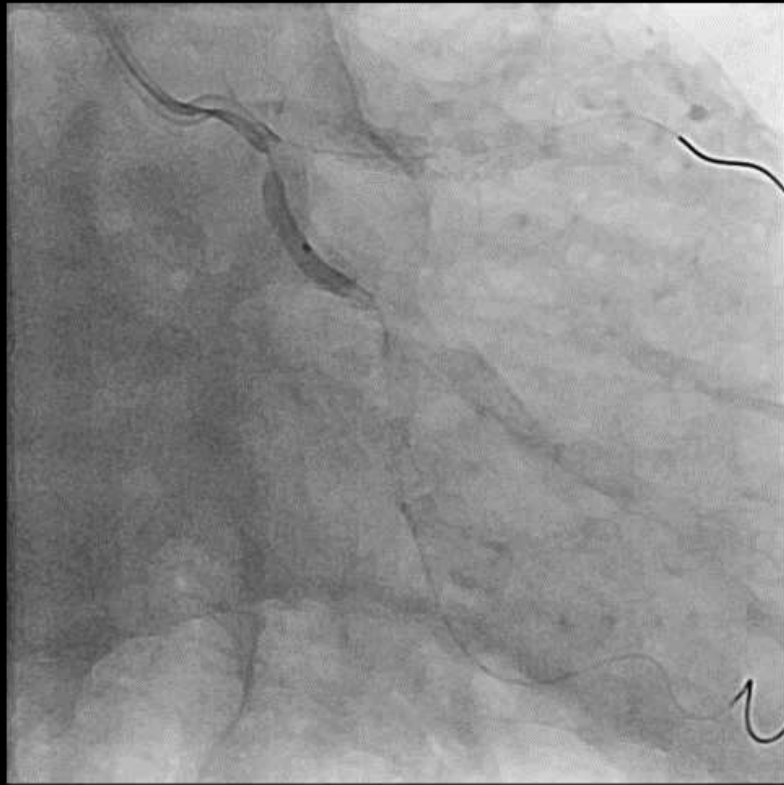
SUOH3 within Corsair



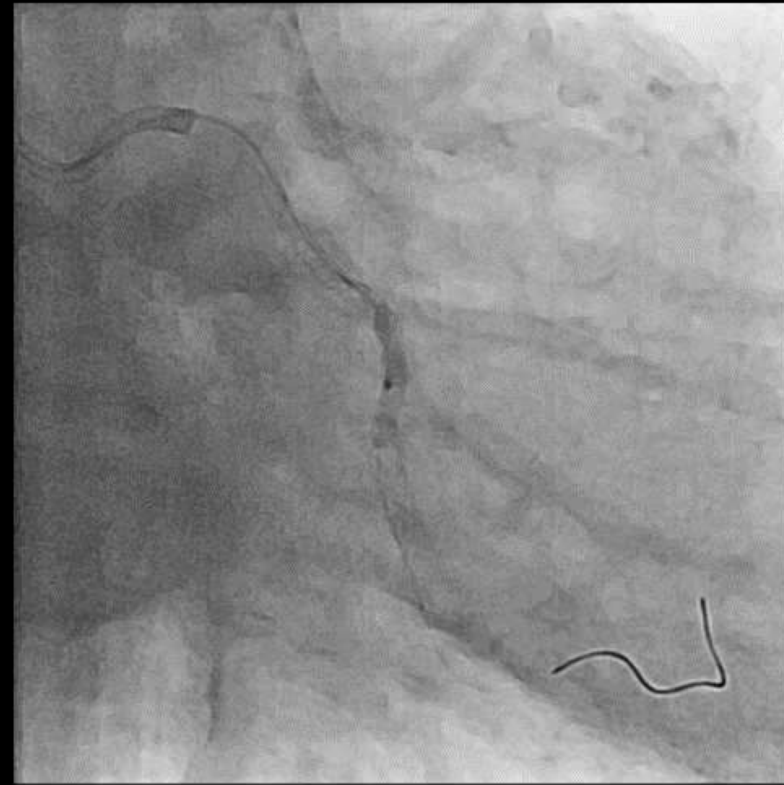
Compliant balloon 1.5/10



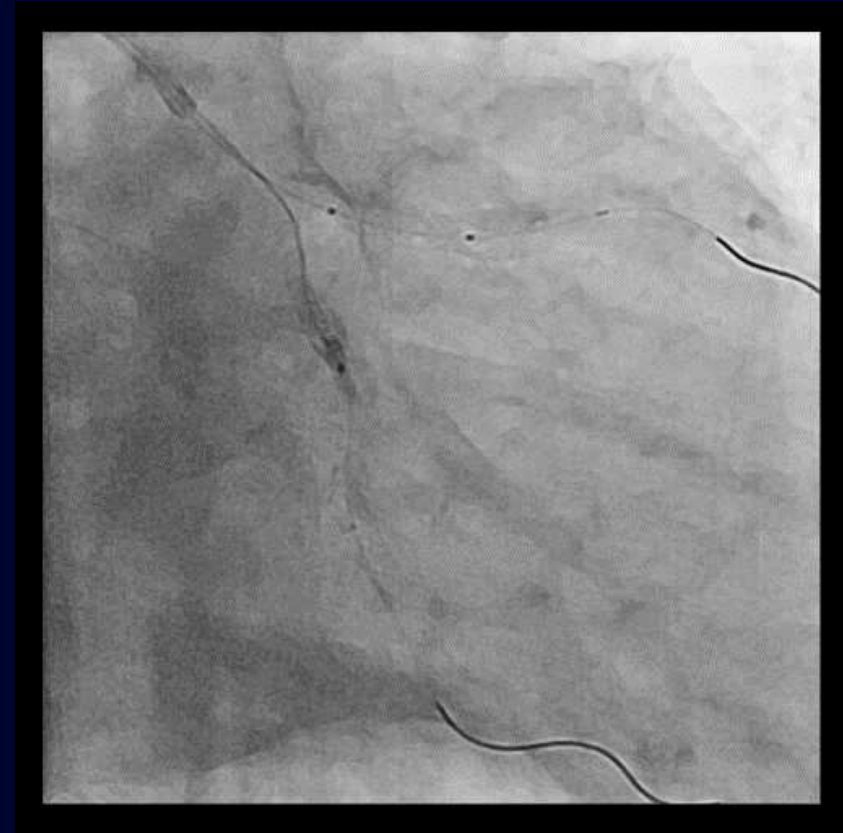
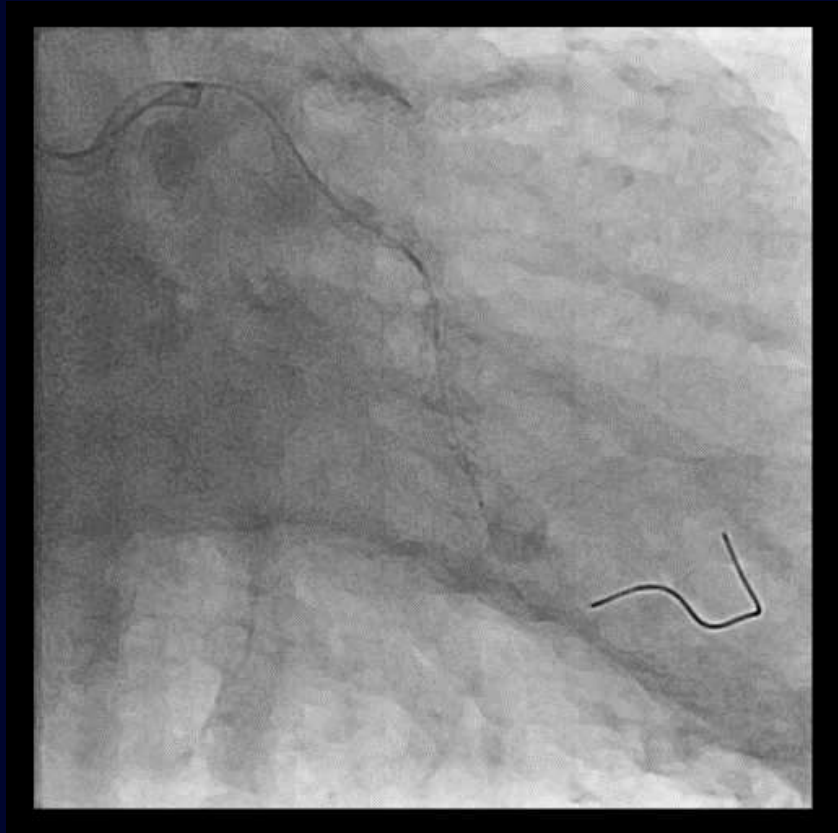
Compliant balloon 1.5/10



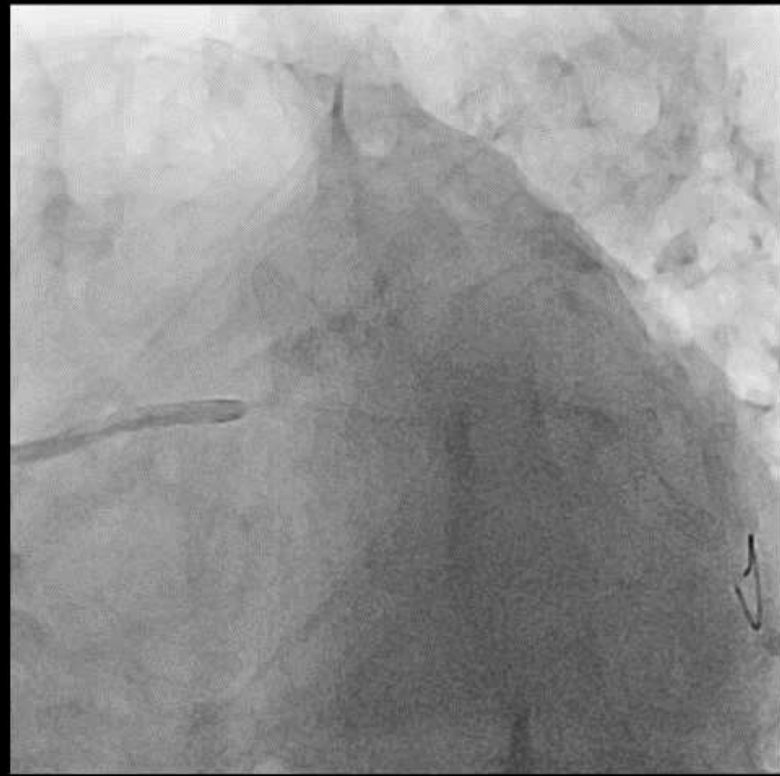
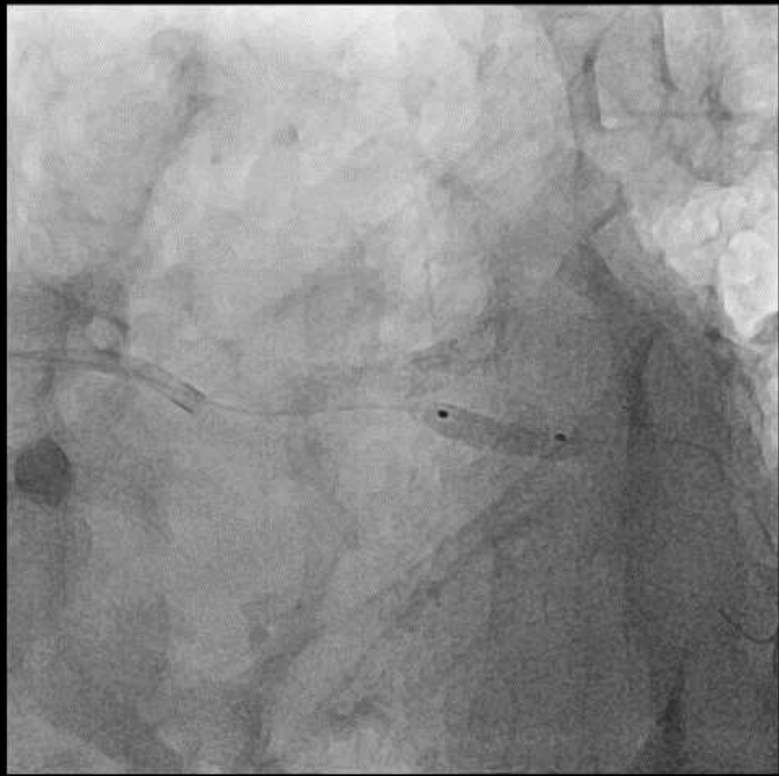NC balloon 2.0/10



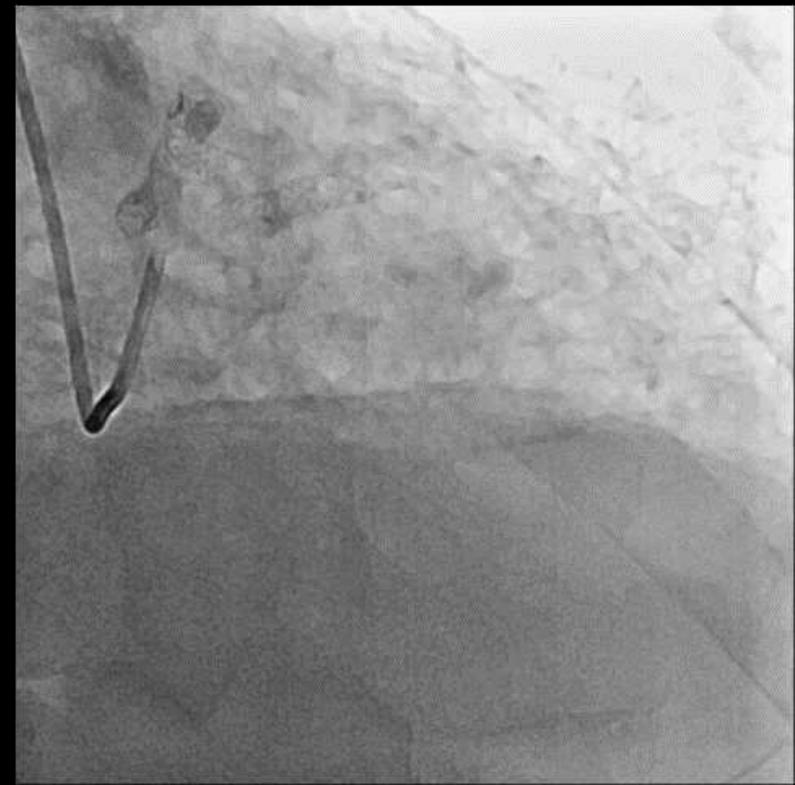
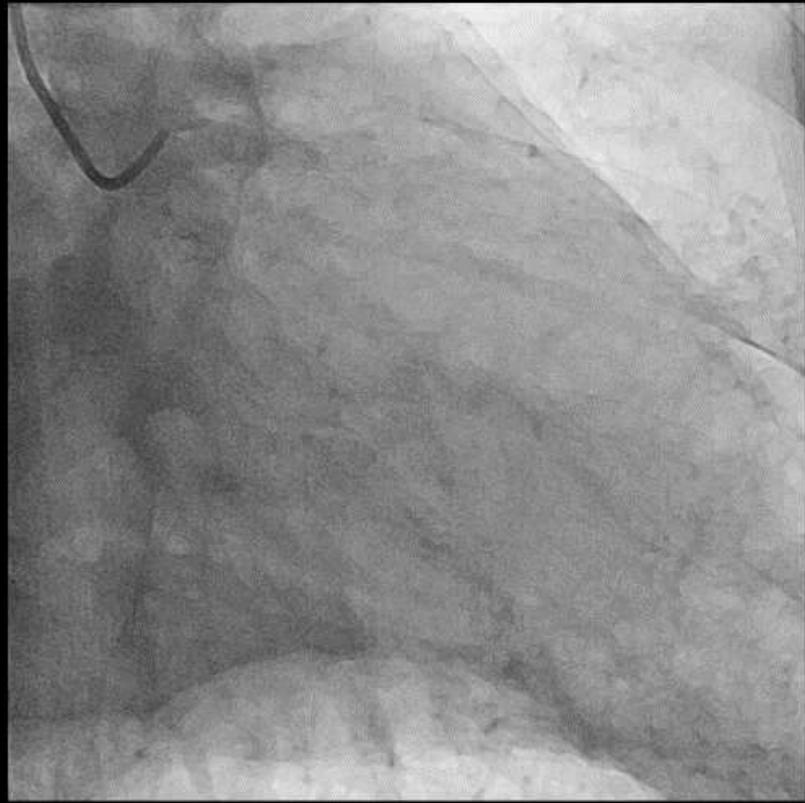
NC balloon 2.0/10



NC balloon 3.0/10



NC balloon 3.0/10



Summary

- Guidezilla has complications such as pressure dampening, coronary artery ischemia.
- Everyone should be on the same page.
- Keep calm and carry on!
- Any other options or techniques?