

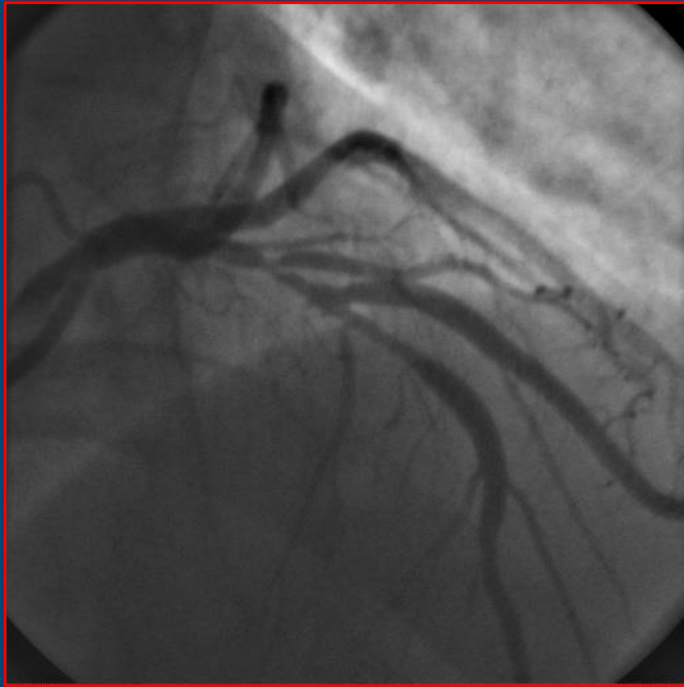
Bifurcation PCI: Contemporary Practical Approach

Jung-Min Ahn, MD

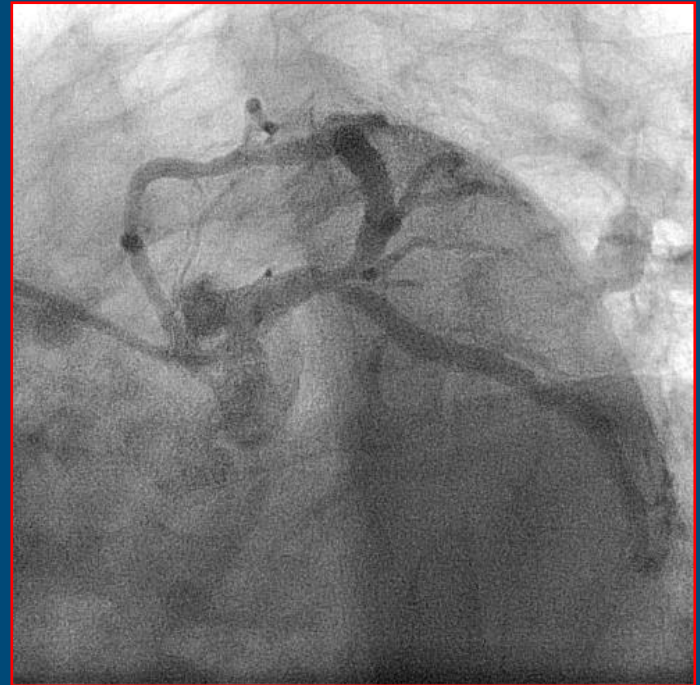
Heart Institute, Asan Medical Center, Ulsan University
College of Medicine, Seoul, Korea

Bifurcation

Non-Left Main



Left Main



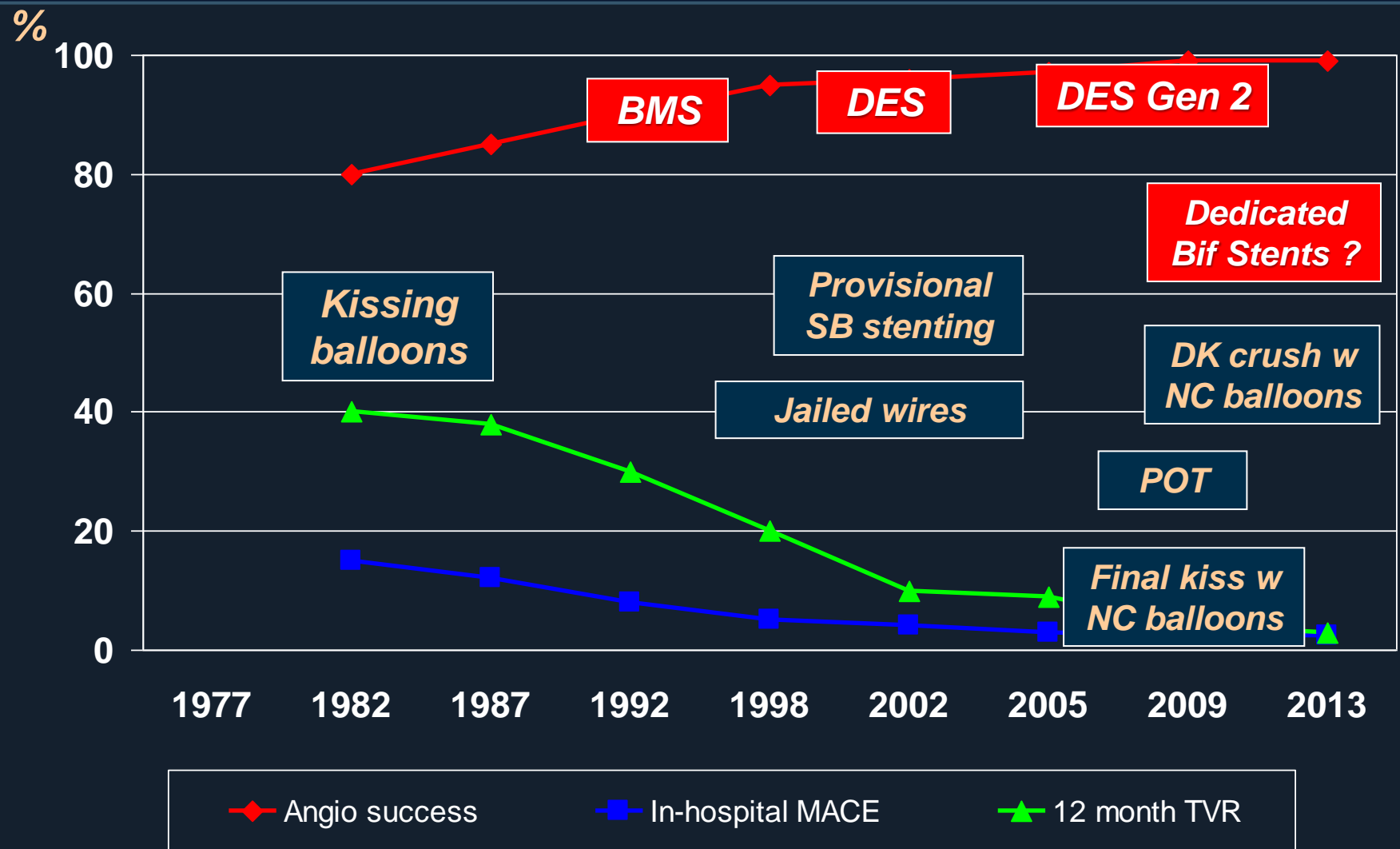
Bifurcation

Non-Left Main



- Simple Cross Over?
- Two Stent Technique?
- Side Branch Protection?

Evolution of Bifurcation Therapy



Meta-Analysis of 12 Major Studies, 6961 Pts

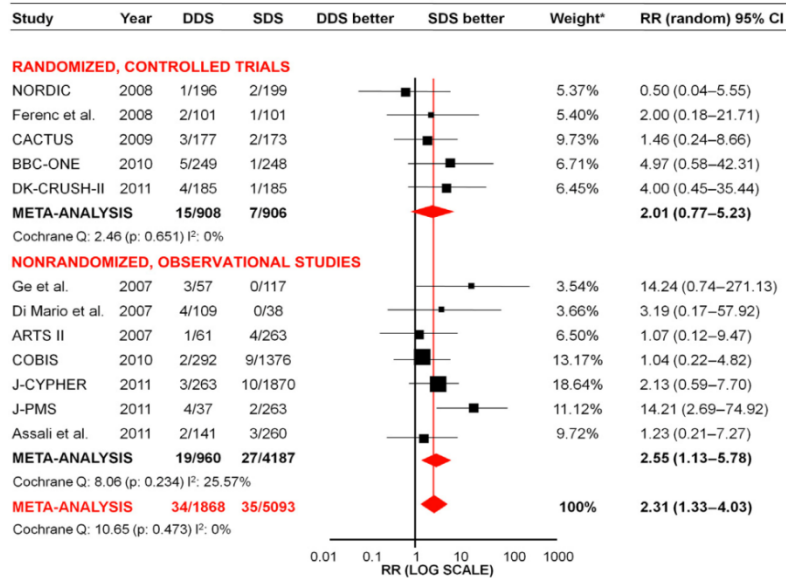
Provisional Single-Stenting is Better !

DES Thrombosis

Myocardial Infarction

A

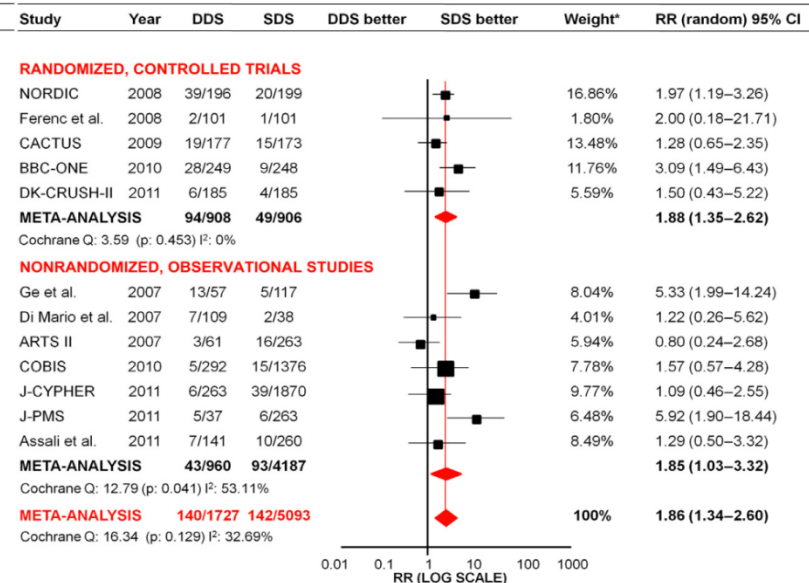
DES THROMBOSIS



Single-stent Two-stent

C

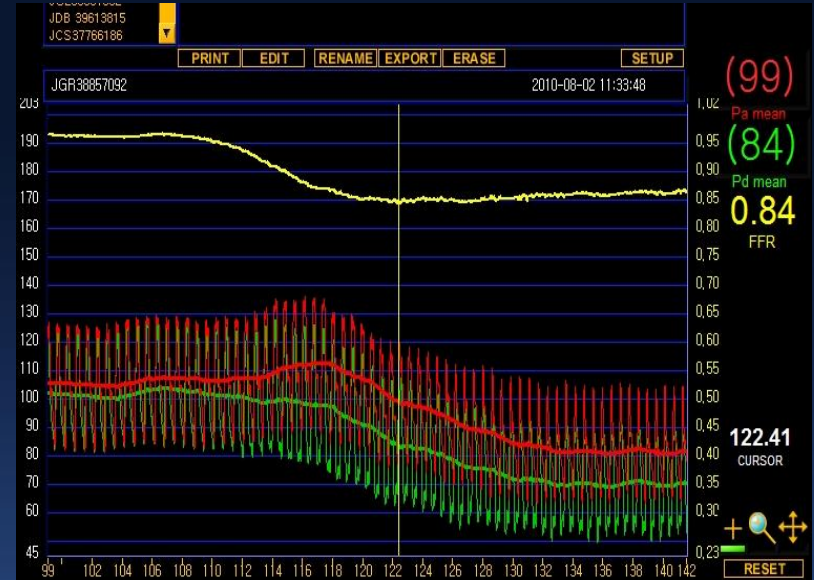
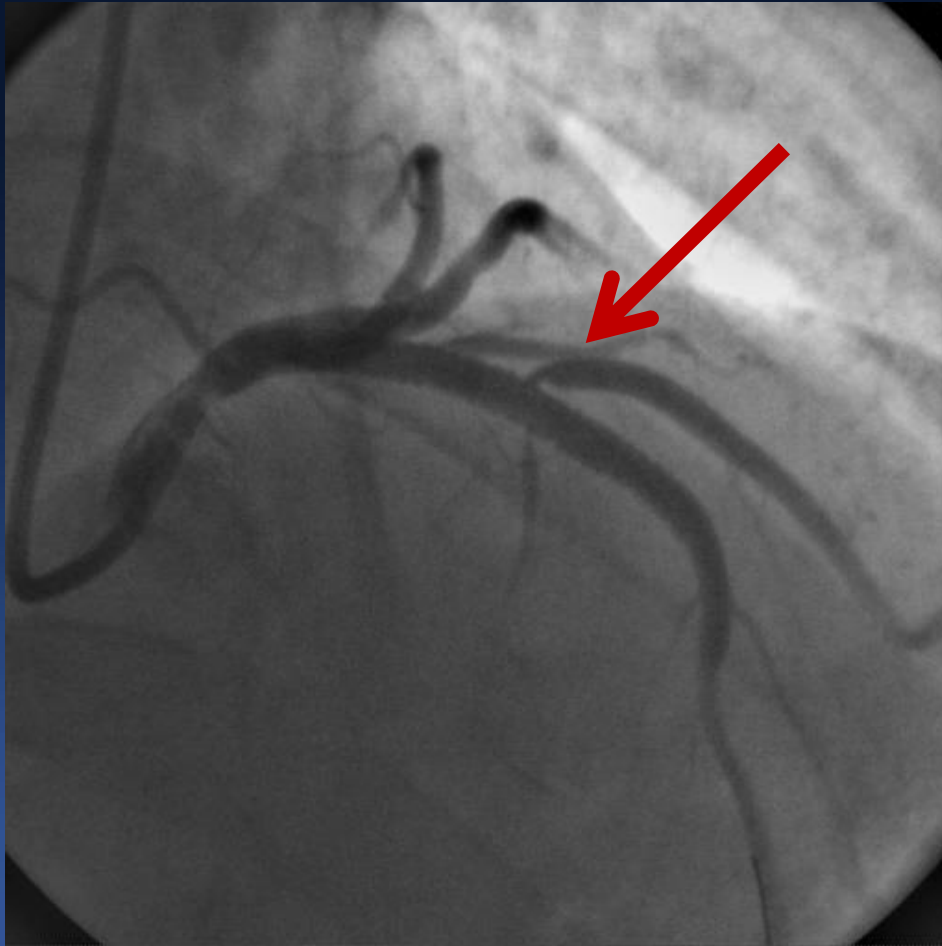
MYOCARDIAL INFARCTION



Single-stent Two-stent

- No randomized trials had shown that two-stenting was superior to single-stenting.
- Provisional one stent cross over with jailed wire has been a standard strategy to treat non-LM bifurcation, even true bifurcation.

After Stenting at Main Vessel

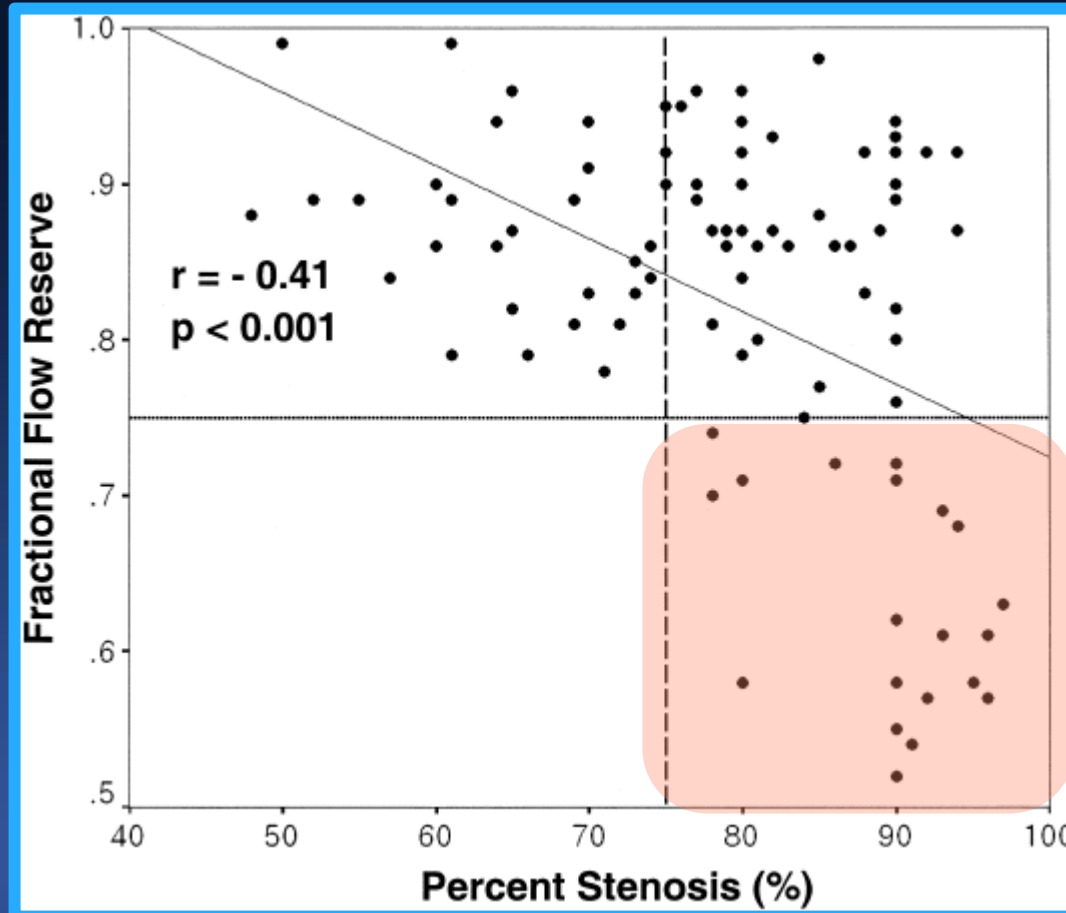


FFR 0.84

Leave it alone.

FFR of the Jailed Side Branch

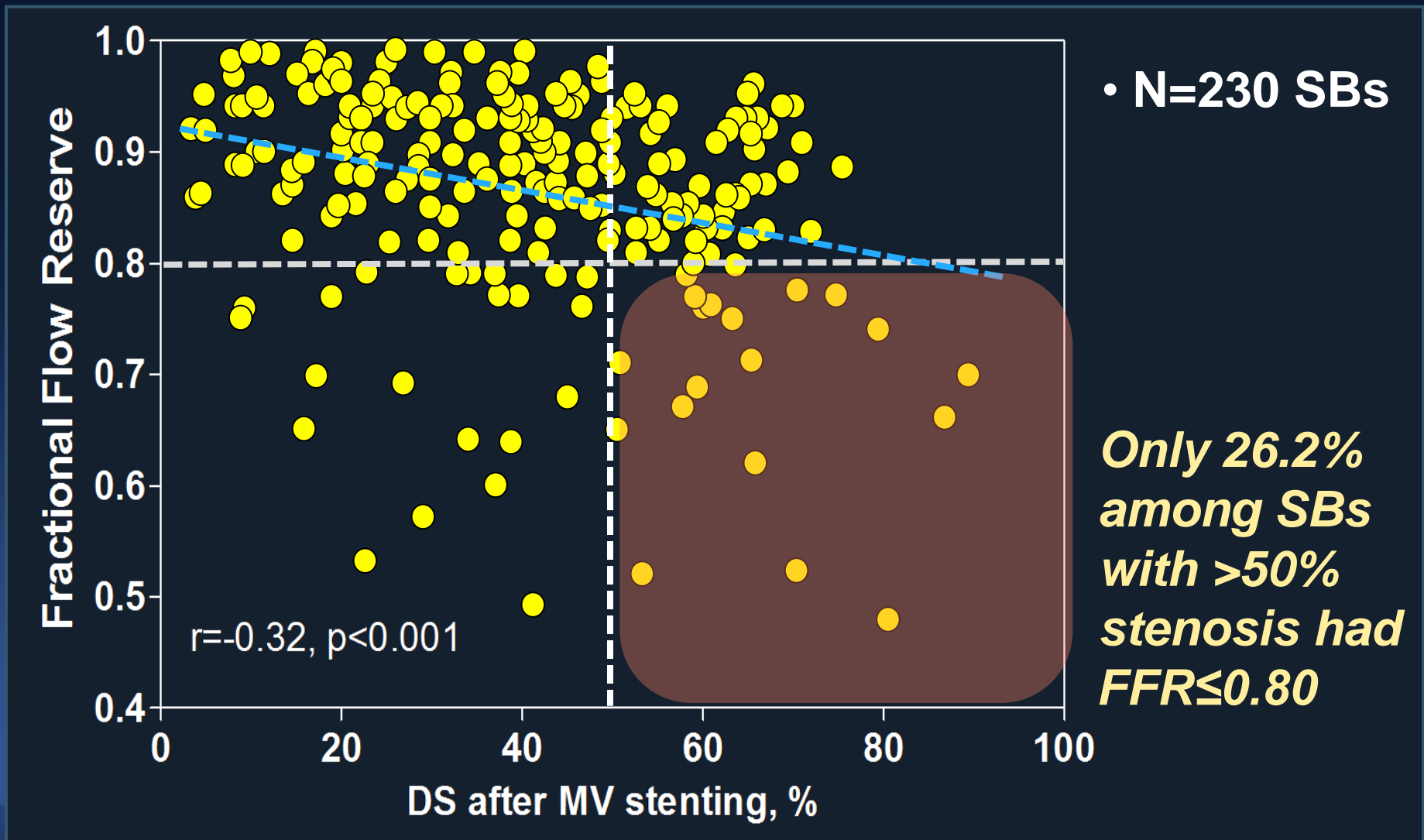
Among angiographic jailed side branches, functionally significant stenosis is not common.



Koo BK et al. J Am Coll Cardiol 2005;46:633–7.

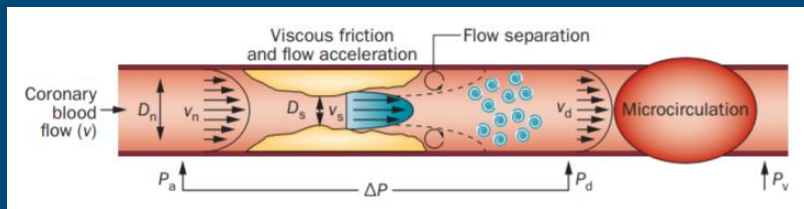
FFR of the Jailed Side Branch

By Using Dedicated Bifurcation QCA



Why? Determinants of FFR

Stenosis

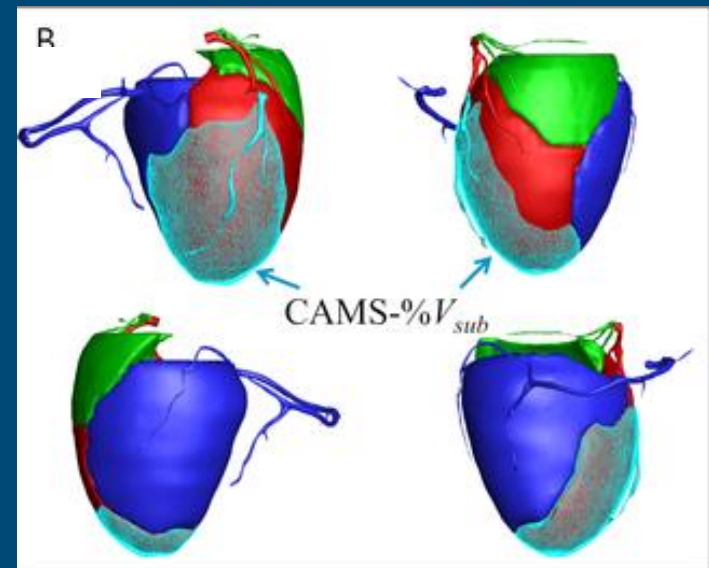


The pressure gradient across a stenosis is determined by the sum of viscous and separation losses.

$$\Delta P = A v + B v^2$$

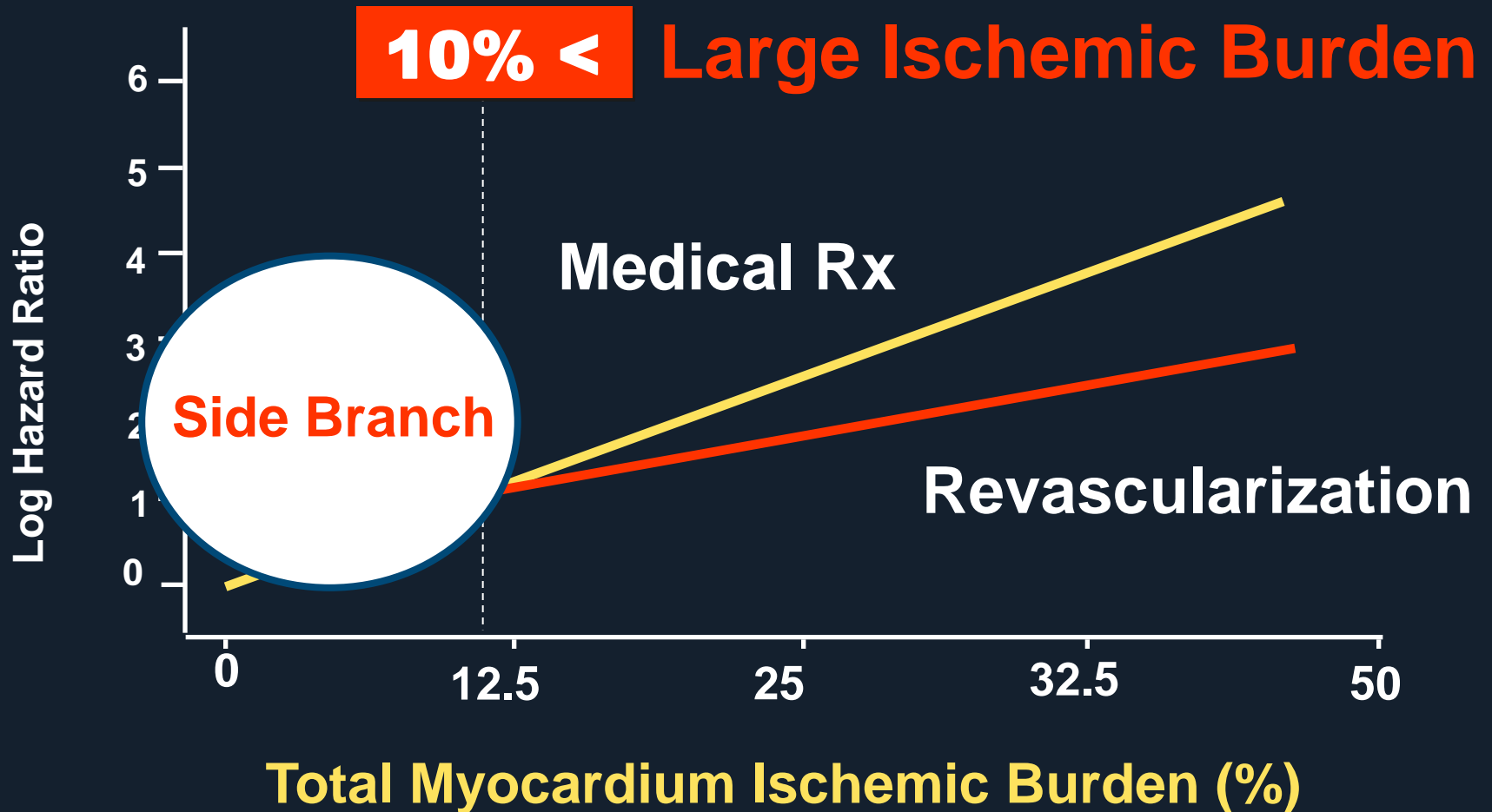
The most-important geometric parameter is the minimum diameter of the stenosis

Myocardium



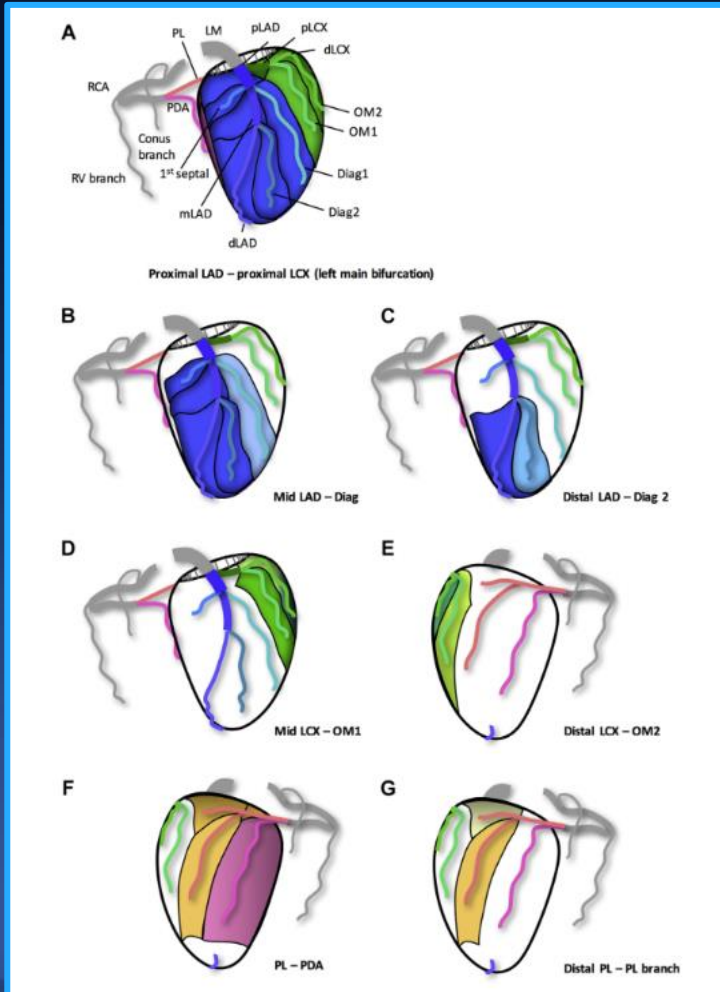
- Vascular territory on the FFR value
- Any given stenosis,
Vascular territory \uparrow FFR \downarrow
Vascular territory \downarrow FFR \uparrow

Survival Benefit of Revascularization



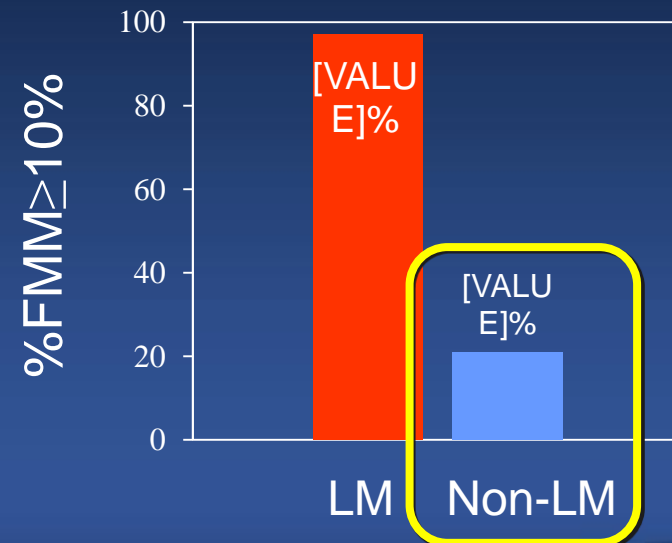
Myocardial Mass Supplied by Side Branch

Fractional Myocardial Mass (FMM)
Based on CT



Predictors of %FMM \geq 10%

- Side branch length \geq 73mm
- Left main bifurcation



Simple Calculation

Ischemia Extent: %FMM>10% in SB: 21%

Ischemia Severity: FFR \leq 0.80 in SB: 26%



Clinically (Prognostically) Important SB is
Only 5.5%

Peri-Procedural MI: Angiographic Complications

Side branch occlusion is not associated with long-term survival but main branch occlusion is associated with long-term survival after PCI.

Angiographic mechanism (N=1367)

Major vessel complication†	186 (1.1)	21 (12.8)		1.84 (1.19-2.87)	0.007
Side branch occlusion	775 (4.5)	61 (9.2)		1.09 (0.83-1.43)	0.55
Unknown cause	406 (2.4)	30 (8.4)		1.22 (0.84-1.76)	0.29

3-5 X URL	663 (3.9)	42 (7.6)		0.98 (0.71-1.34)	0.89
< 3 X URL	15515 (90.7)	802 (6.5)	1 (reference)	1 (reference)	3.9

Symptomatically Important Side Branch

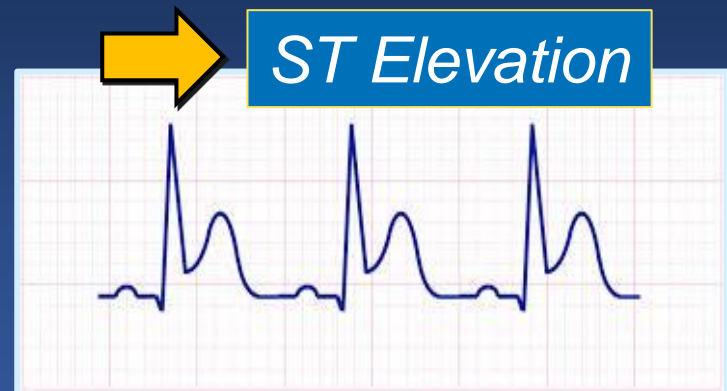- Angina
- EKG change
- Arrhythmogenic potential

Balloon Occlusion

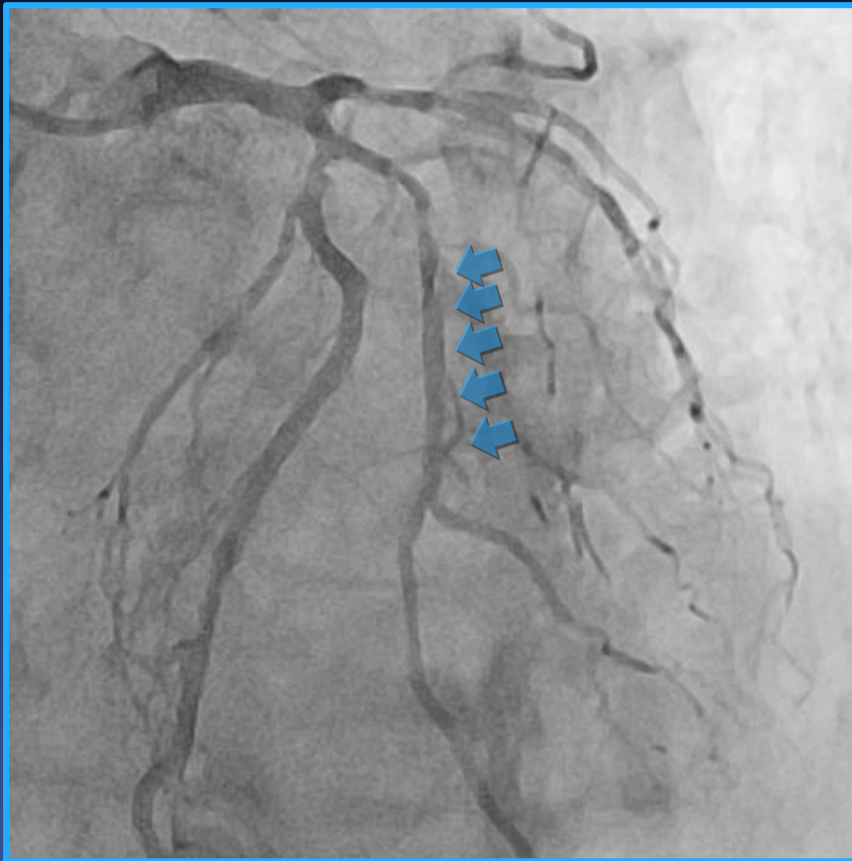
	LAD	Diagonal	p Value
Chest pain and ECG parameters, n = 65			
VAS pain score	5 (0-7)	2 (0-4)	<0.0001
ST-segment elevation ≥ 1 mm	60 (92.3)	23 (35.4)	0.001
QTc interval, ms	454.0 \pm 45.4	440.4 \pm 35.7	0.07
QTc dispersion, ms	83.8 \pm 39.2	70.7 \pm 28.5	<0.0001
Coronary hemodynamic parameters, n = 47			
Pre-intervention FFR	0.67 \pm 0.10	0.71 \pm 0.11	0.02
Pw, mm Hg	21.0 \pm 6.5	26.7 \pm 9.4	<0.0001
Pw/Pa	0.22 \pm 0.07	0.27 \pm 0.08	0.001

Diagonal Br. Scoring

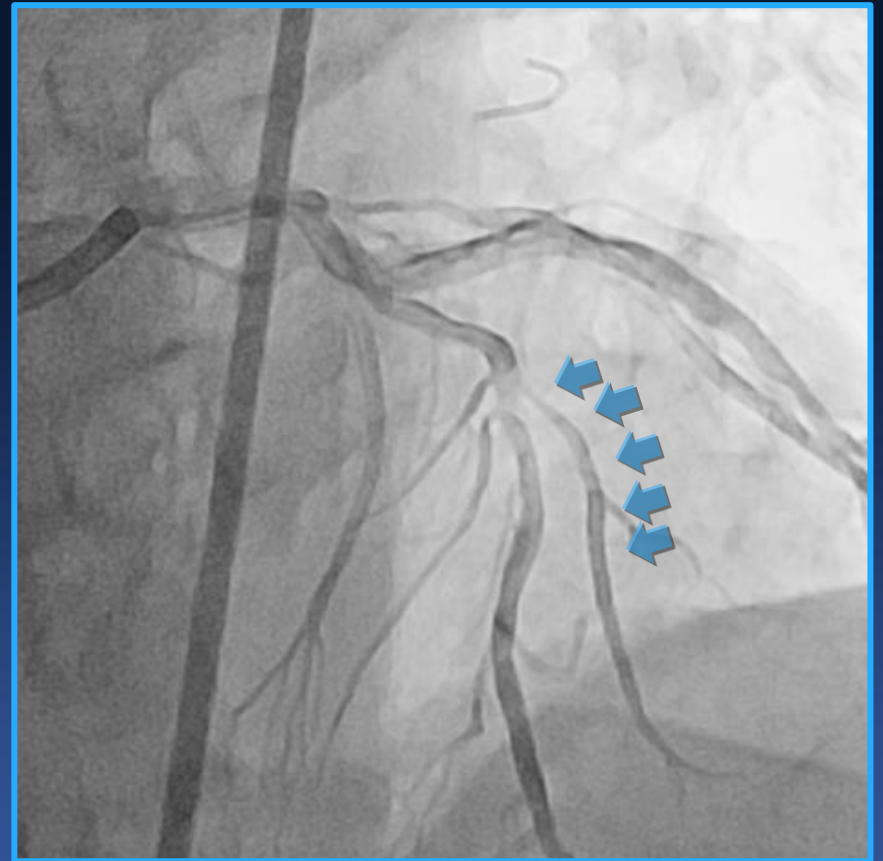
- Vessel Size ≥ 2.5 mm
- No. of Dia. Br. ≤ 2
- No Br. Below



Important



Less Important

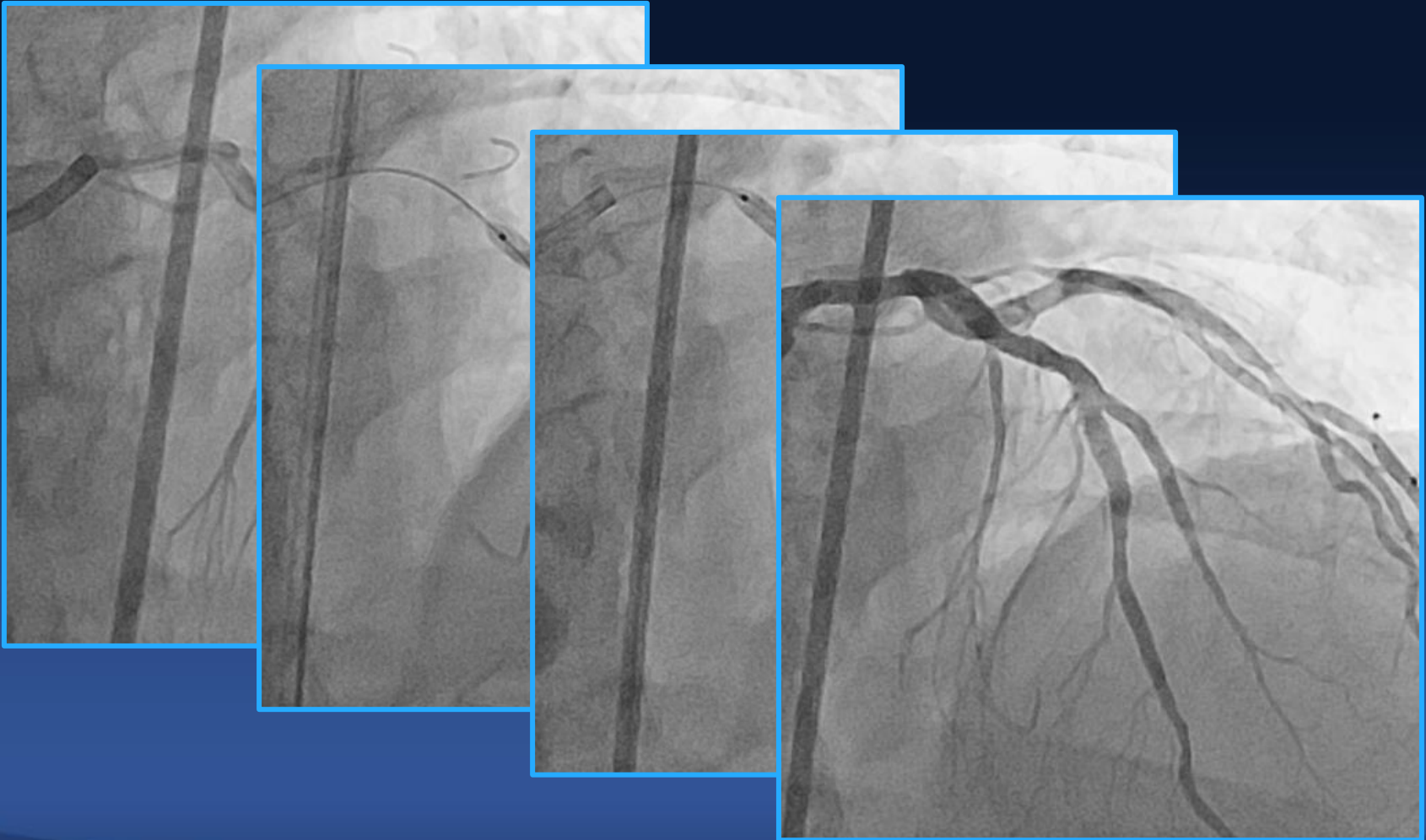

When We Do Initial Two Stenting?

Big SB, Hard to Re-Wire, to Avoid **Pain**

(>2.5mm)

(Very tight, acute angle, calcification etc)

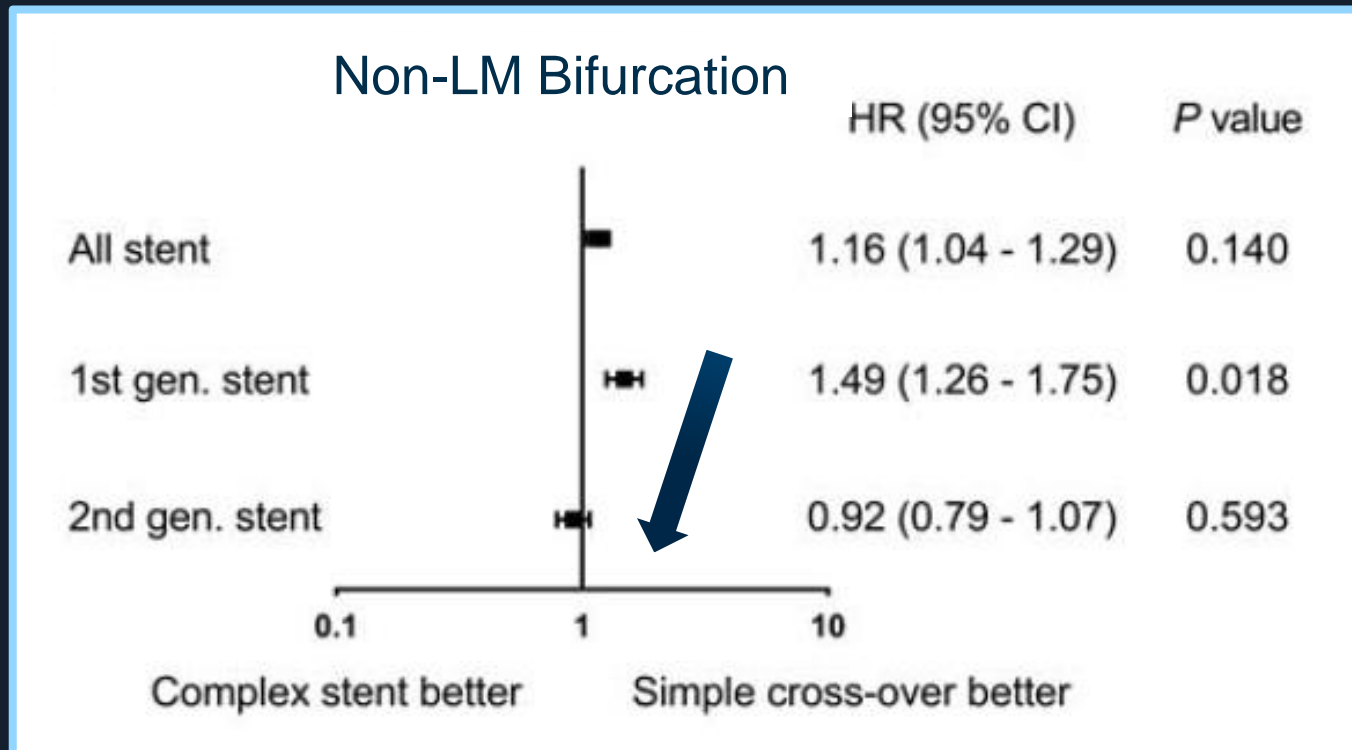


Not For Better Prognosis But For No Pain during PCI

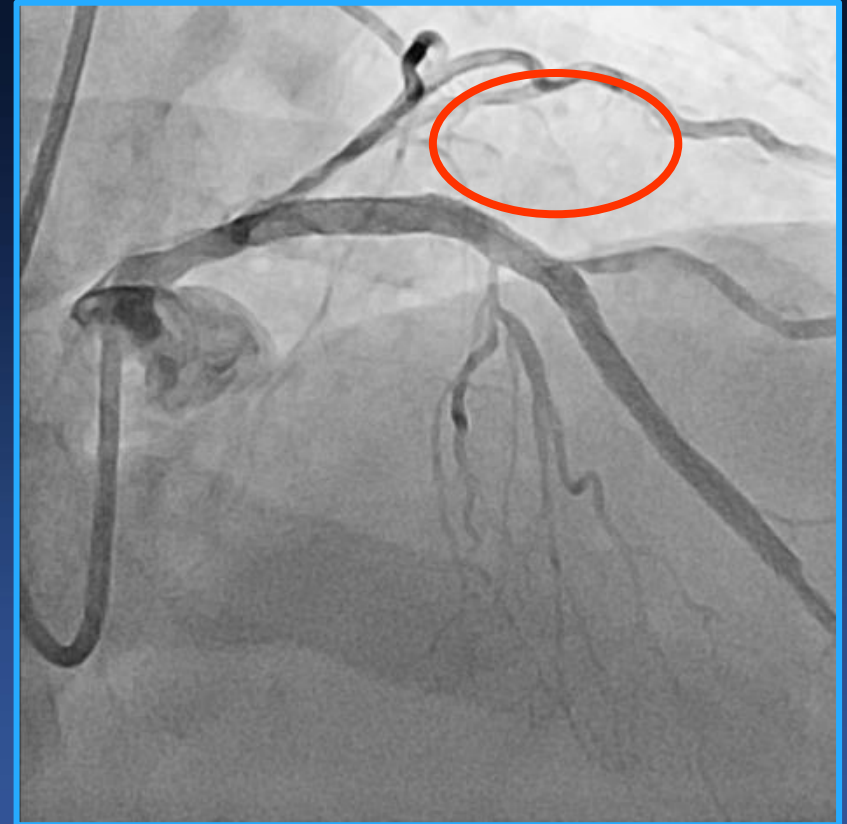
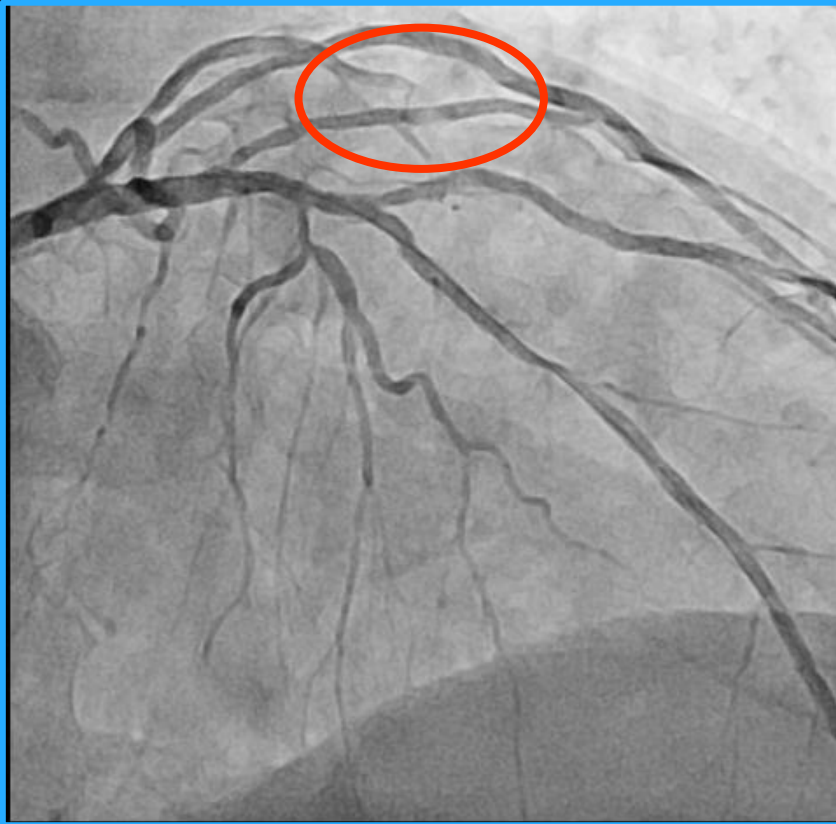
Temporal Changes in Non-LM Bifurcation PCI Data from IRIS-DES and LM Registry

The Outcome of 2-Stenting Has Improved

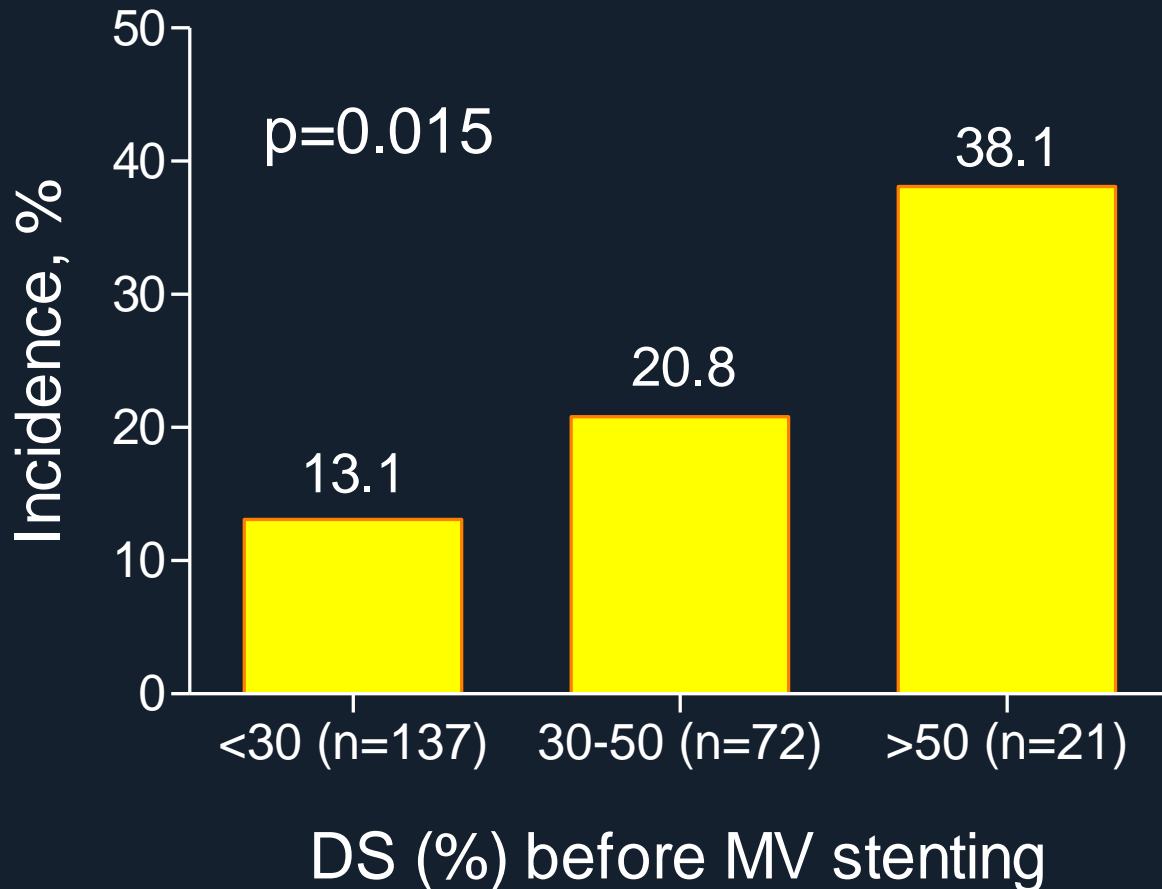
Target-Vessel Failure



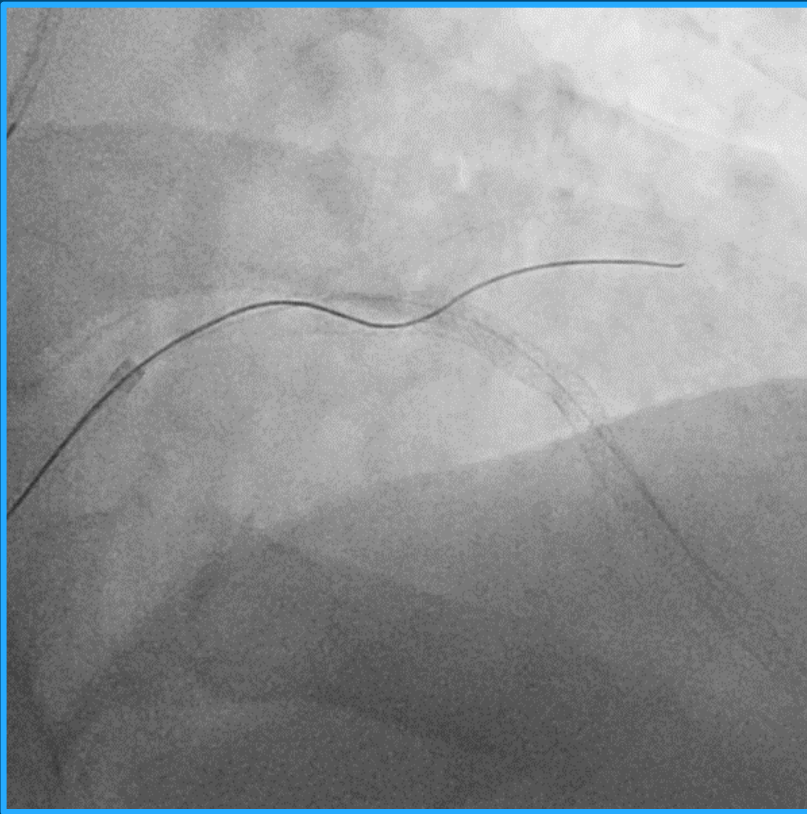
Diagonal Branch Disappeared after Stenting



Pre-Stenting DS vs. Post-Stenting FFR of Side Branches



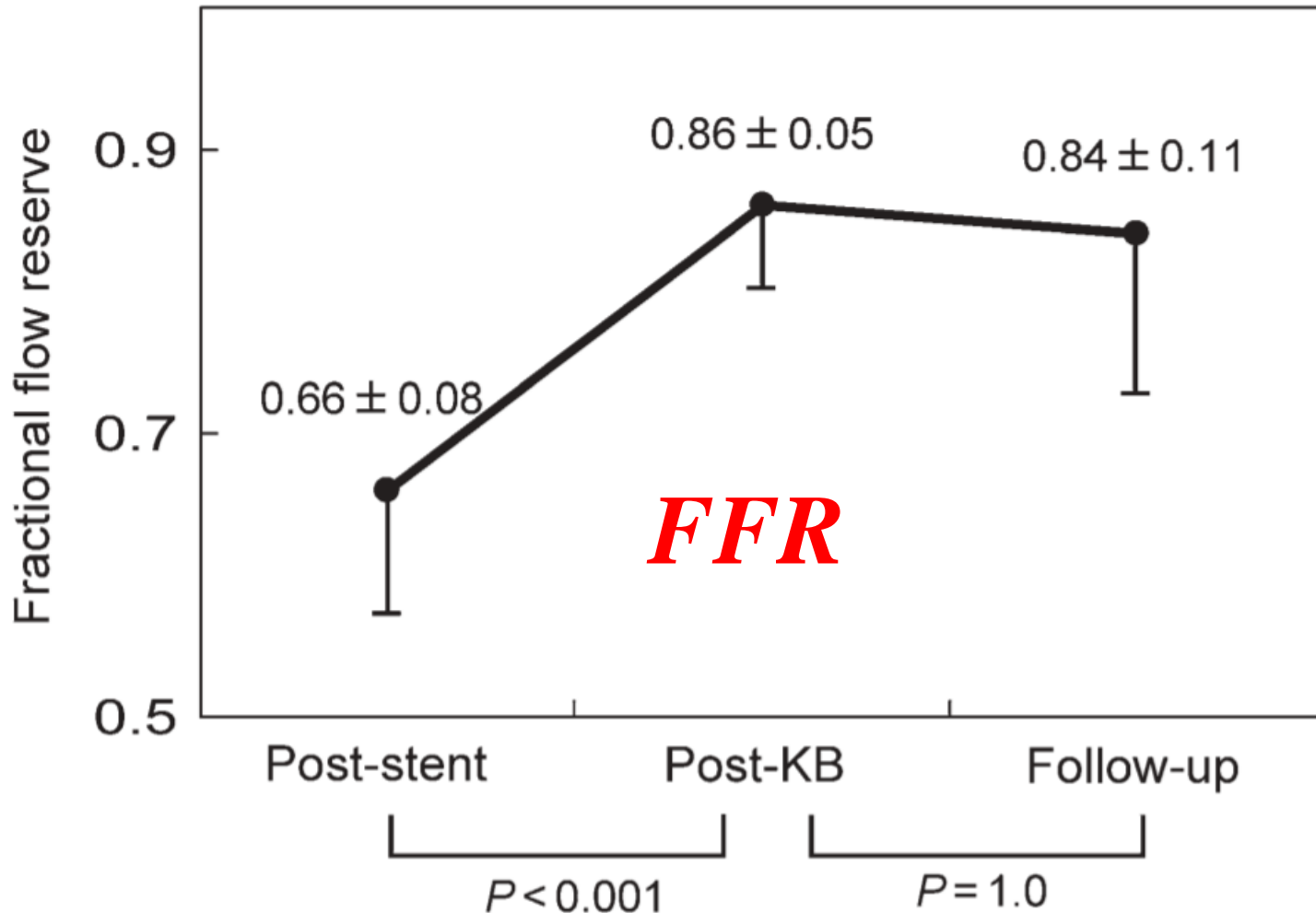
Diagonal Branch Disappeared after Stenting



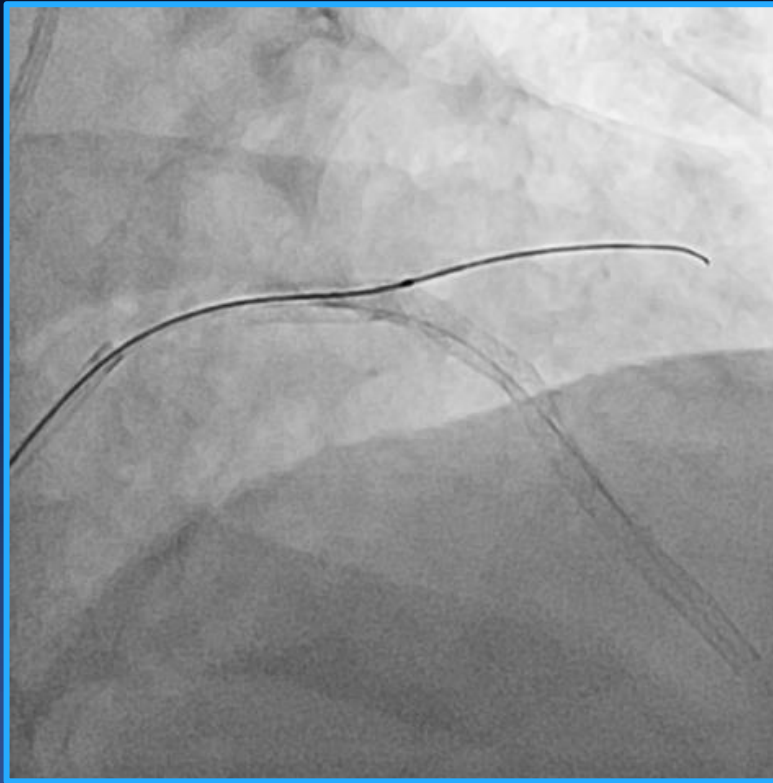
- Provisional Stenting?
- Kissing Balloon?
- Keep It Open?

Kissing Balloon:

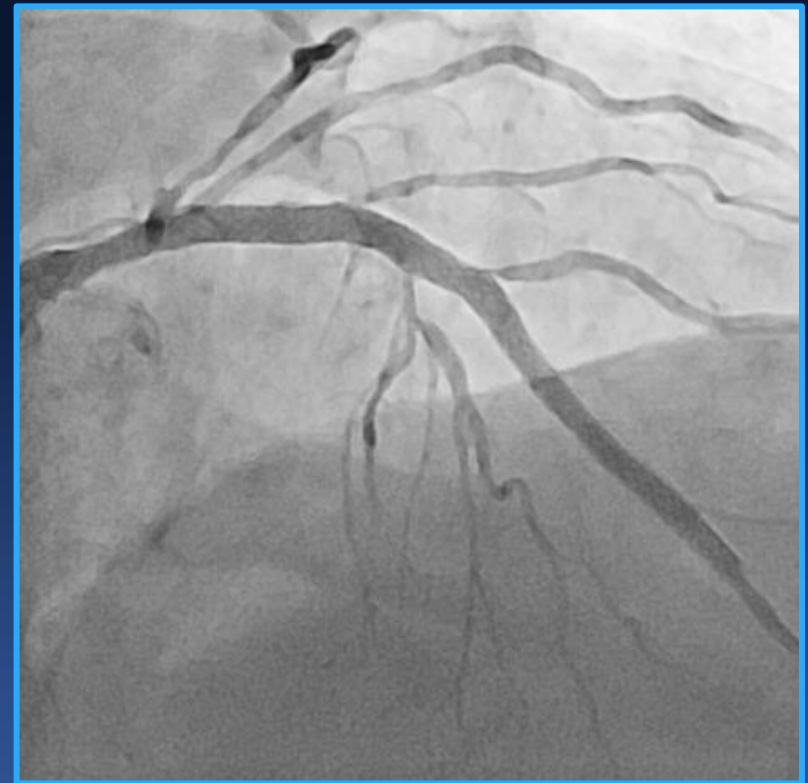
Keep It Open With Small Balloon



Keep It Open Using Small Balloon



Tazuna 1.5(15)mm



TIMI 3 flow

Contemporary Practical Approach for Non-LM Bifurcation PCI

**Provisional Stenting
Is Always Enough**

Any 2 Stent Technique

- Jailing Side Branch ?
- How to Treat ?

It Would Be OK !

With Simple Technique ; POT, Sequential HP Inflation on Both Branches, and Finally Kissing !

Key Message of Non-LM Side Branch PCI

*(FFR) Concept is More
Important than Technique*