

19yr / M

- C.C. : Chest pain (1 hr ago)
- Past history: DOE Fc class II (1 yr)
- Erythema, both feet

19 yr
Male

Vent. rate 124 BPM
PR interval 120 ms
QRS duration 86 ms
QT/QTc 356/511 ms
P-R-T axes 66 263 72

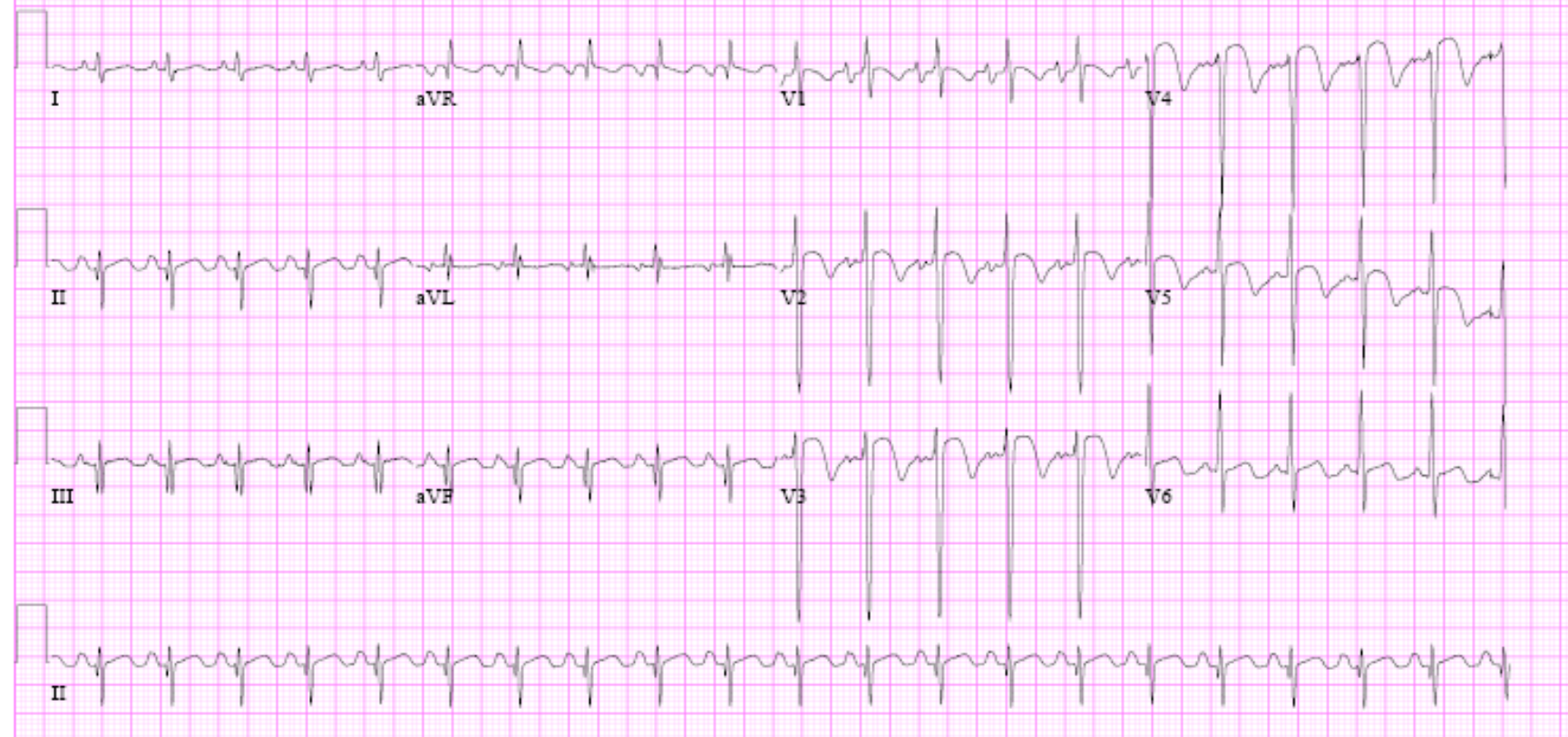
Sinus tachycardia
Left atrial enlargement
Right superior axis deviation
Right ventricular hypertrophy with repolarization abnormality
Inferior infarct , age undetermined
Anterior injury pattern
***** ACUTE MI *****
Abnormal ECG

Loc:43

Technician: PMK
Test ind:31461

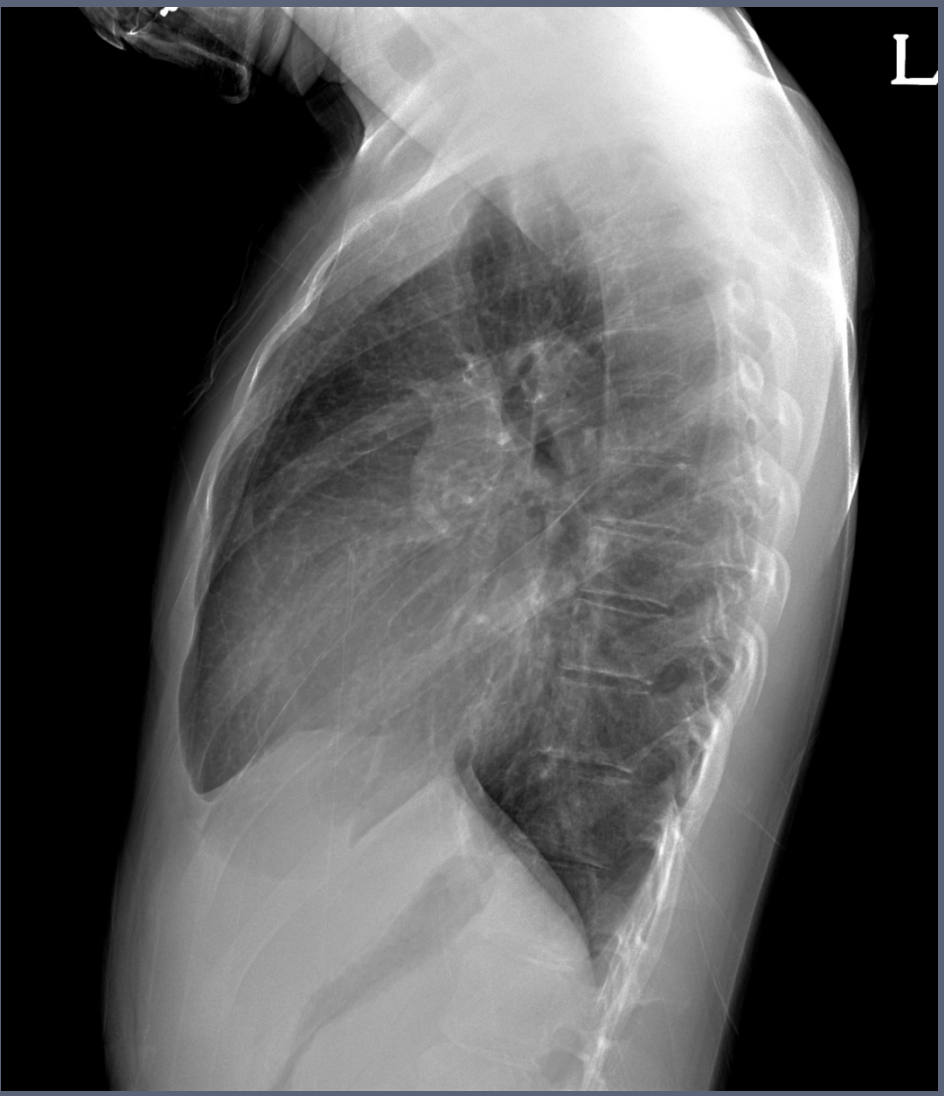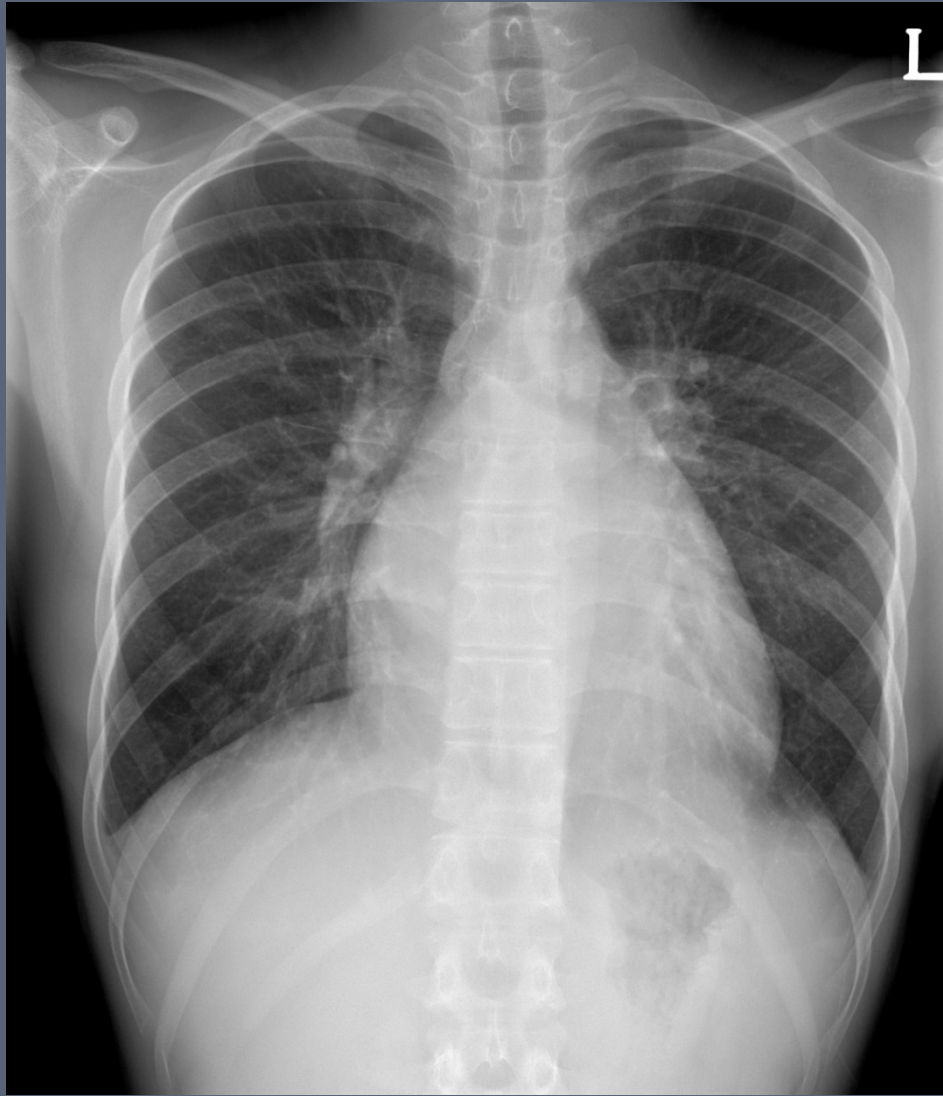
Referred by: 143W CV

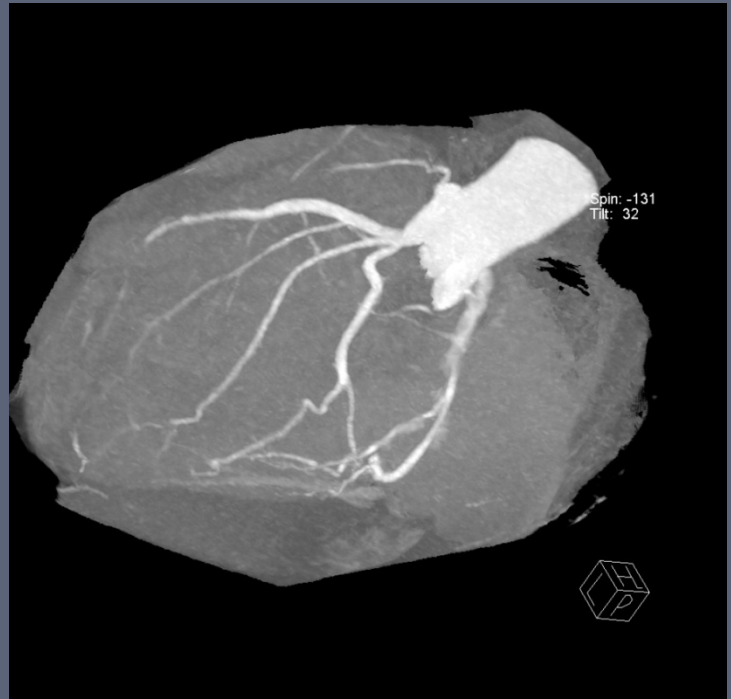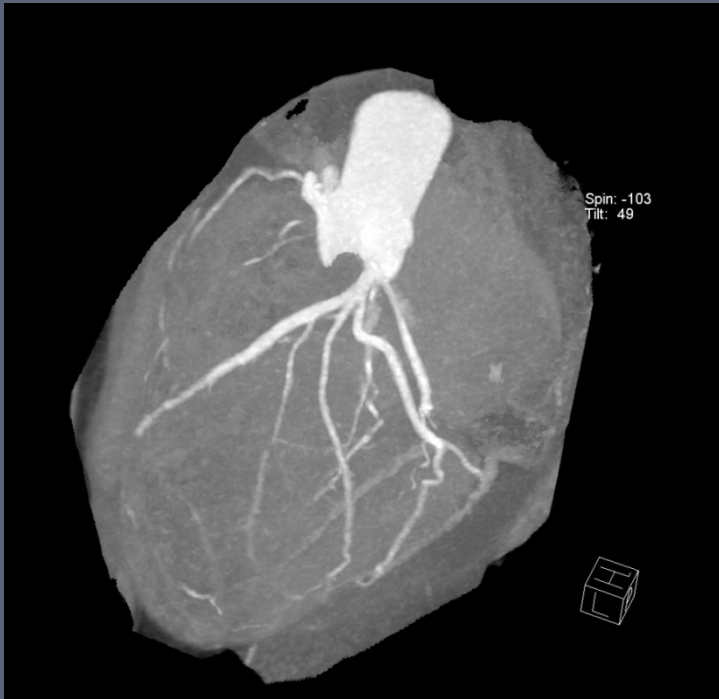
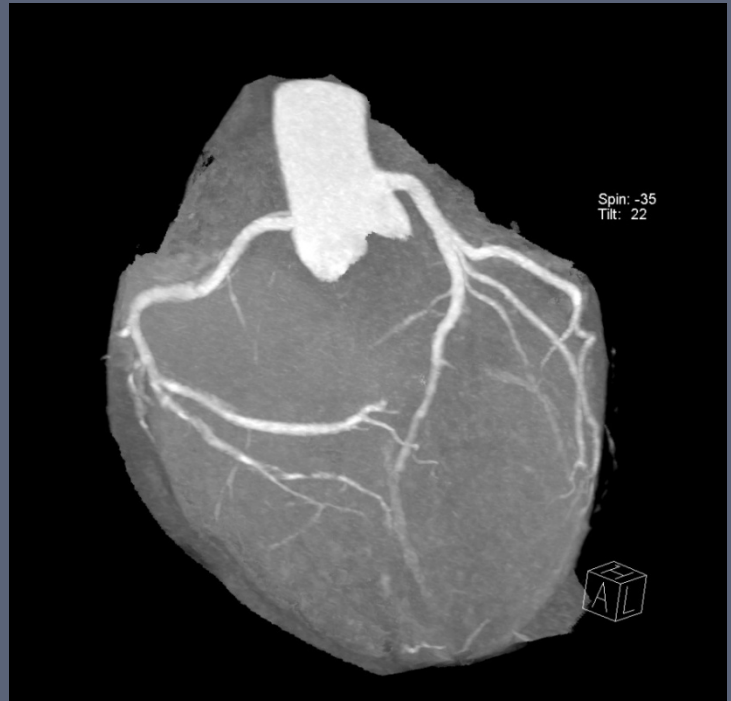
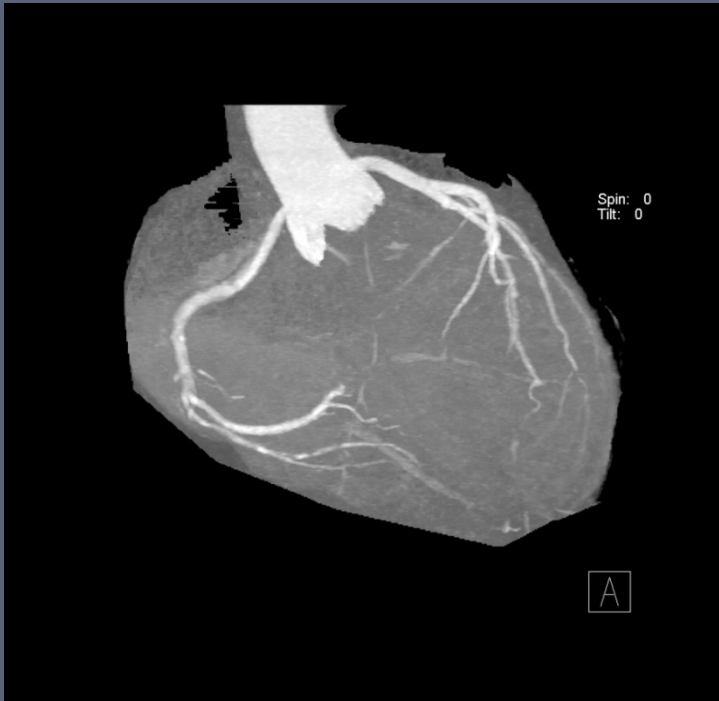Unconfirmed

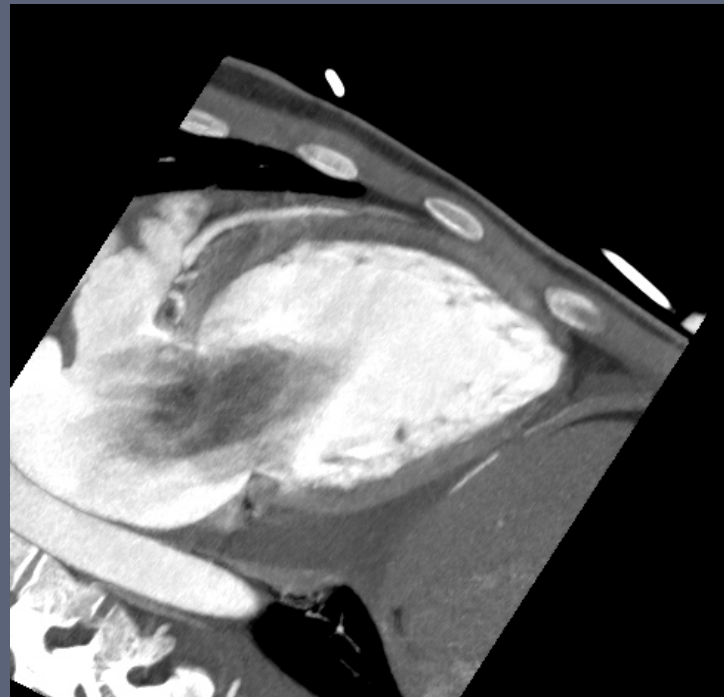
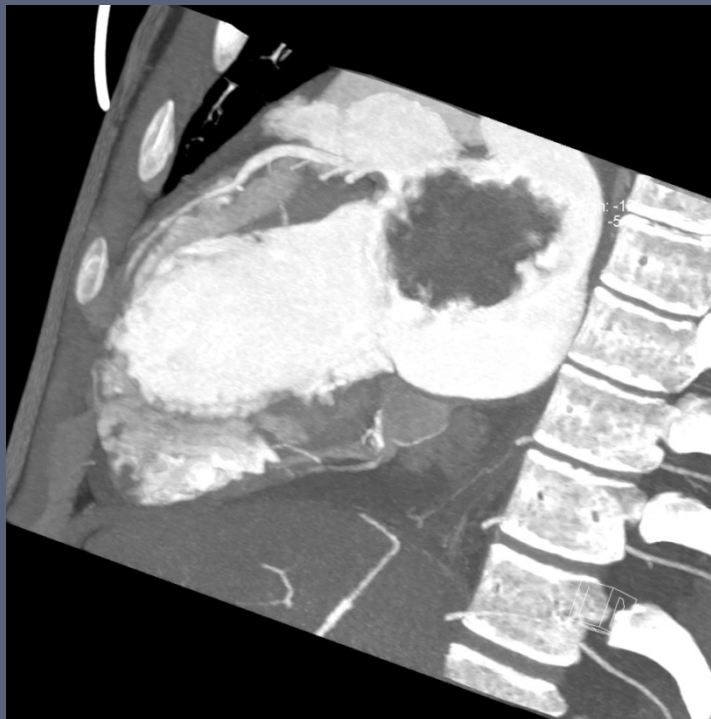
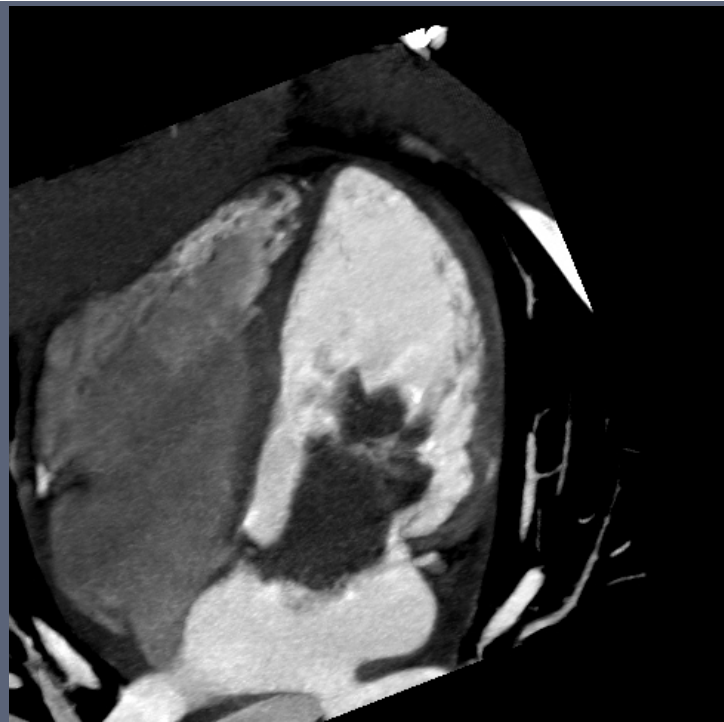
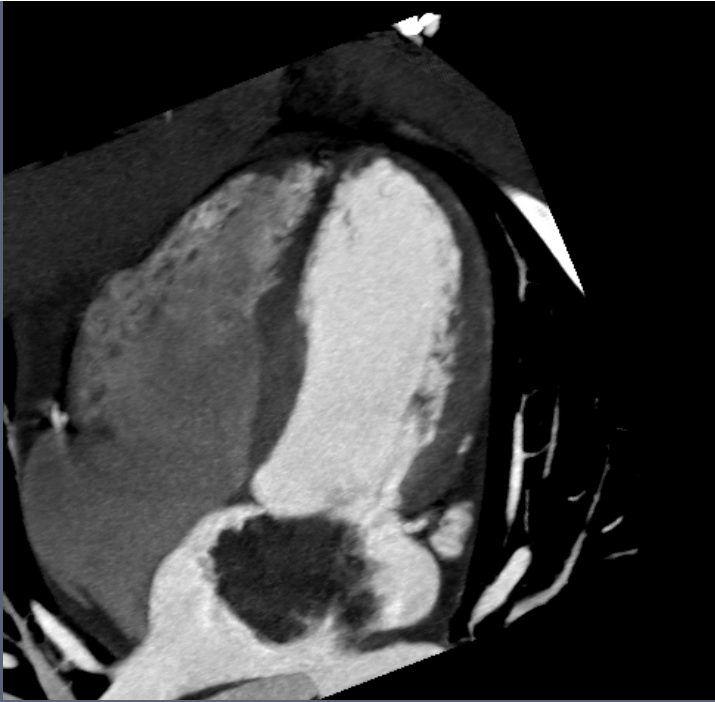


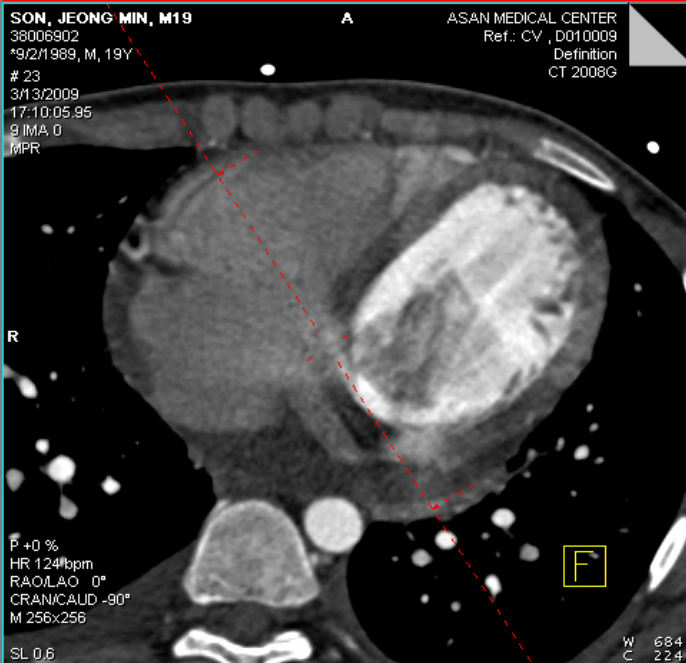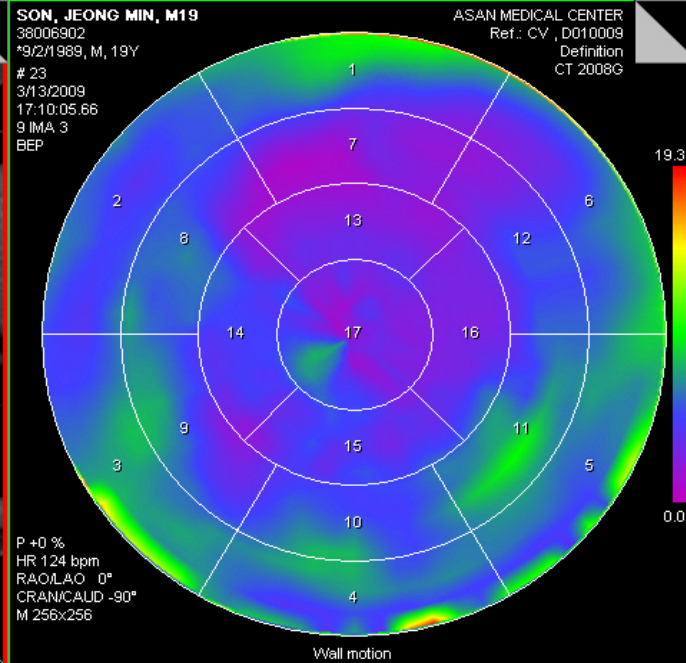
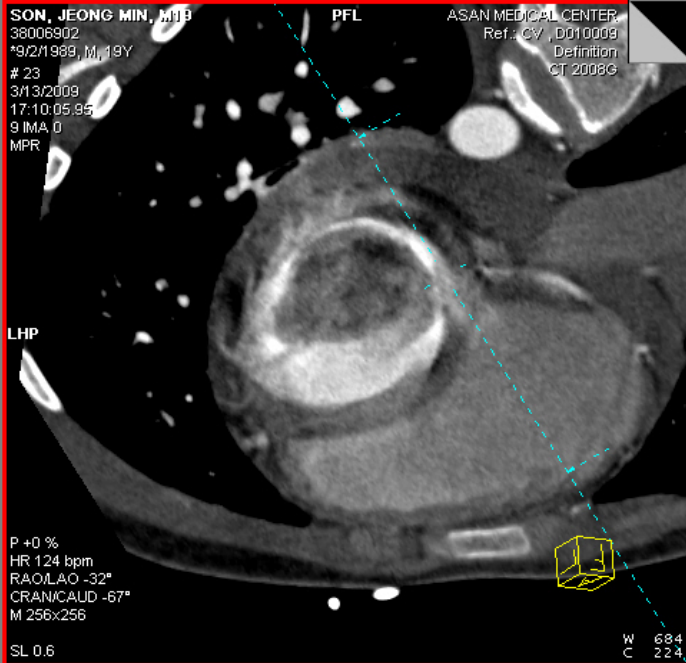
25mm/s 10mm/mV 150Hz 005E 12SL 235 CID: 1

EID:Unconfirmed EDT: ORDER:









LVA Evaluation

previous [left arrow] [down arrow] [right arrow] next [print icon]

- Wall Thick. ES
- Wall Thick. ED 0.0 mm 19.3 mm
- Wall Thickening [color scale bar]
- Wall Motion Current Pointer Value [mm] [input field]

Motion normokinetic [dropdown]

Location unspecified [dropdown]

EF [%]	38.00	ES Volume [ml]	116.00
Myo. Mass ED [g]	197.00	ED Volume [ml]	186.00
Cardiac Output [l/min]	8.68	Stroke Vol. [ml]	70.00

Coronary Overlay [checkbox]

[grid icons]

Advanced Finish [ED] [ES] Cancel Help

SON, JEONG MIN



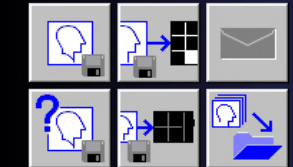
Type	Image	Orien...
[icon]	[icon]	
[icon]	[icon]	
[icon]	[icon]	

Navig... Setti... Tools

[map icon]

[left arrow] 0% [right arrow]

[ES] [ED] [ES] [ED]



Viewing
 Filming
 3D
 CaScoring
 Neuro DSA
 Circulation

Myxoma

