

Endovascular Session II Below the Knee Intervention

Latest Recanalization Technique for Challenging Tibial CTO

Kazushi Urasawa, MD, PhD, FJCC

Katsuhiko Sato, MD, PhD, Ryoji Koshida, MD, PhD

Michinao Tan, MD, Yuya Nakagawa, MD

**Cardiovascular Center, Tokeidai Memorial Hospital
Sapporo, Japan**

Standard setup for BTK intervention

1. Puncture site ipsi-lateral antegrade
2. Sheath Sheathless guiding cathe.
ex. 4.5F Parent-Plus (Medikit)
3. Guidewire 0.014" guidewire
Various products
4. Guidewire buck-up 0.014" compatible micro-cathe.
Prominent (Tokai Medical Products)
Corsair-PV (Asahi Intec)

Wiring techniques for BTK-CTO

1. Antegrade wiring

2. Bi-directional wiring with distal puncture

Dorsalis Pedis

distal ATA

distal PTA

distal PA

Digital arteries

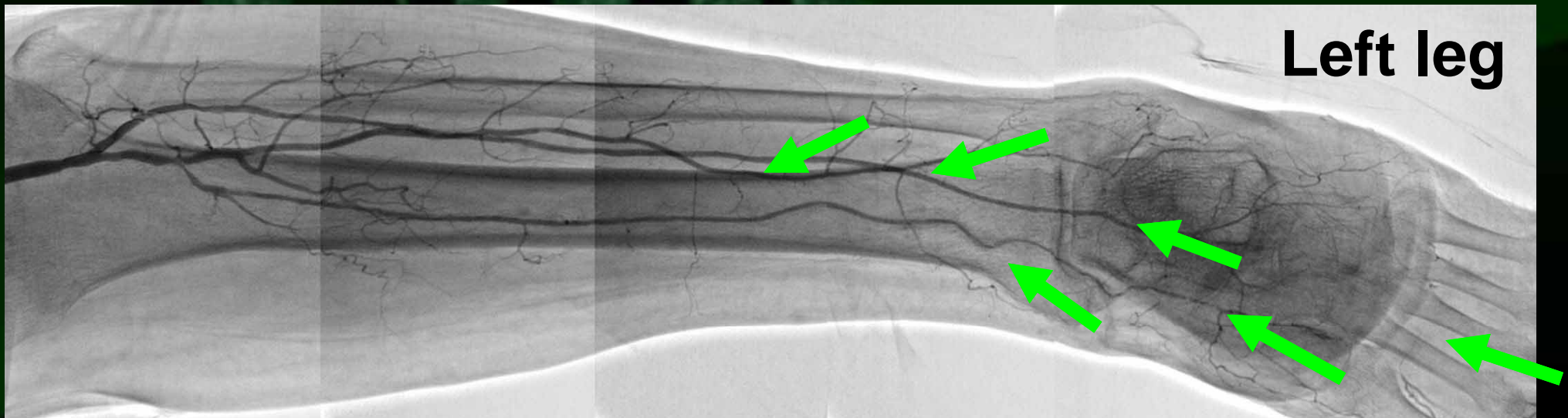Plantar artery

3. Bi-directional wiring using collateral channel

Trans-collateral angioplasty (TCA)

Puncture point and view of angiography

1. Dorsalis pedis (AP cranial)
2. Distal anterior tibial artery (Ipsi-lateral ob.)
3. Distal posterior tibial artery (Contra-lateral ob.)
4. Distal peroneal artery (Ipsi-lateral ob.)
5. Digital arteries (AP cranial)
6. Planter arteries (AP cranial)

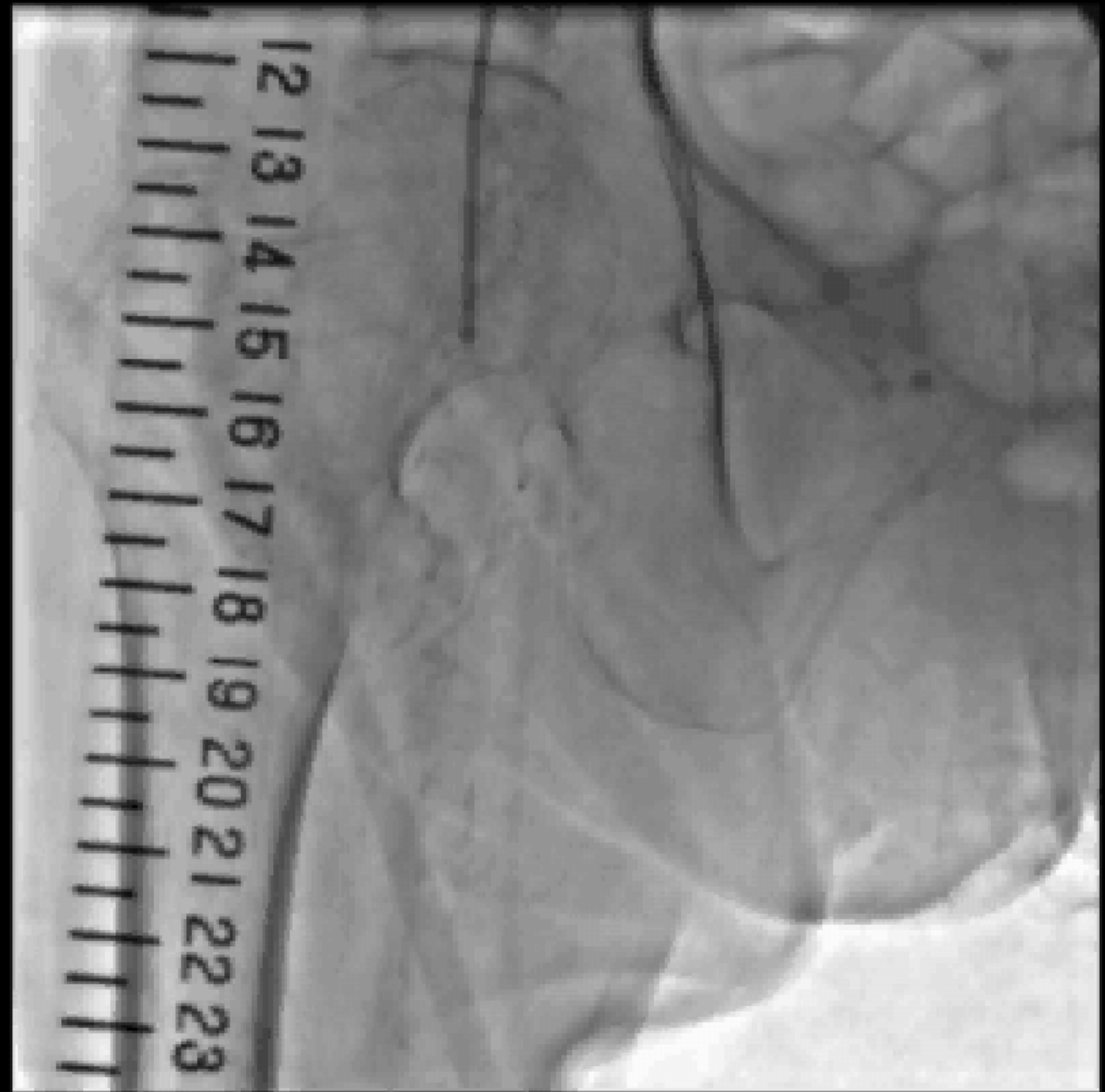

Case: distal peroneal puncture

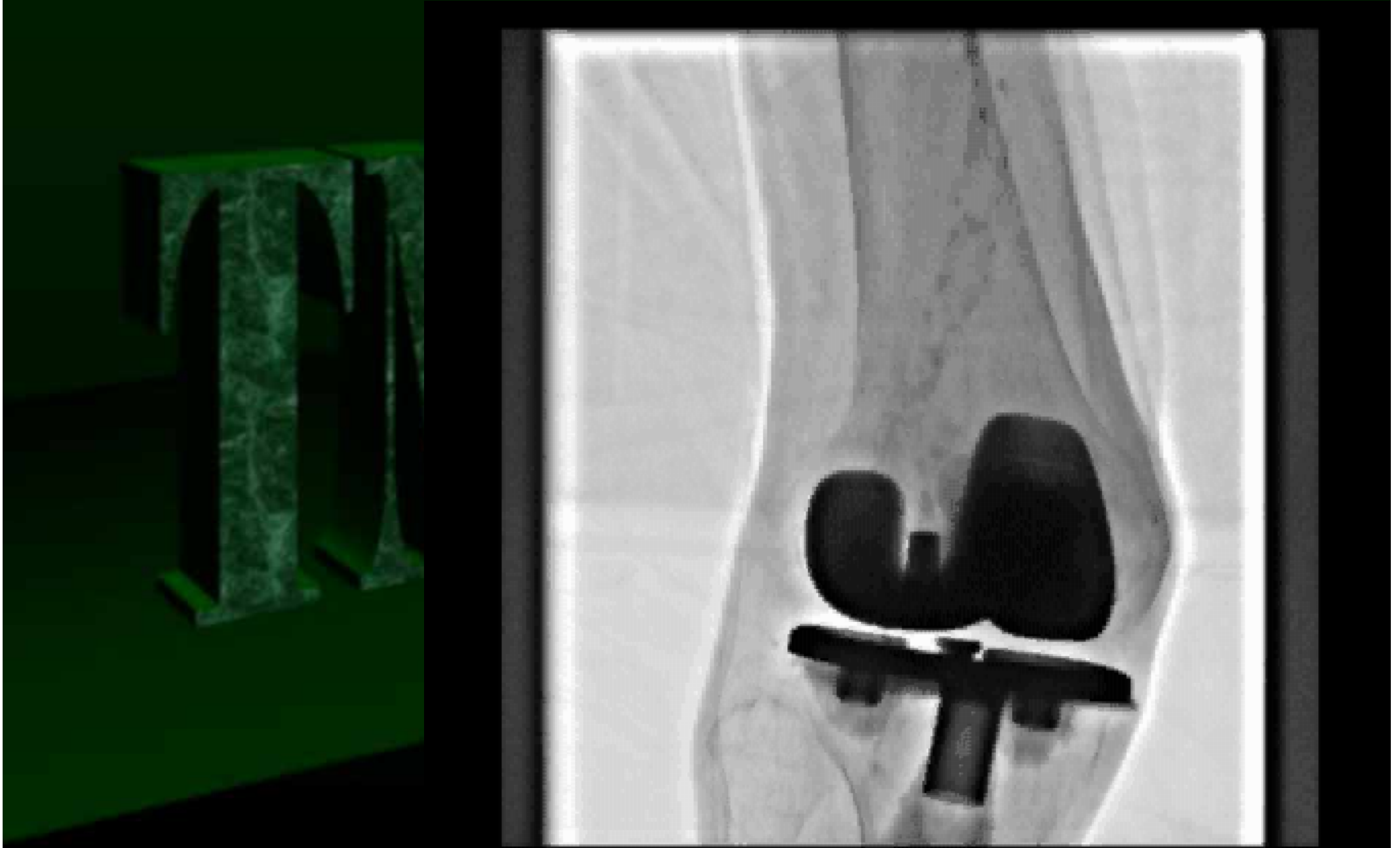Case	94F
Diagnosis	PAD(CLI), DM, HT
Severity	Fontain IV, Rutherford 5
Target	BTK
Lesion type	CTO
Date of EVT	2011.7.12

Control Angiography

Ipsi-lateral puncture
4.5F Parent-Plus
(Medikit)

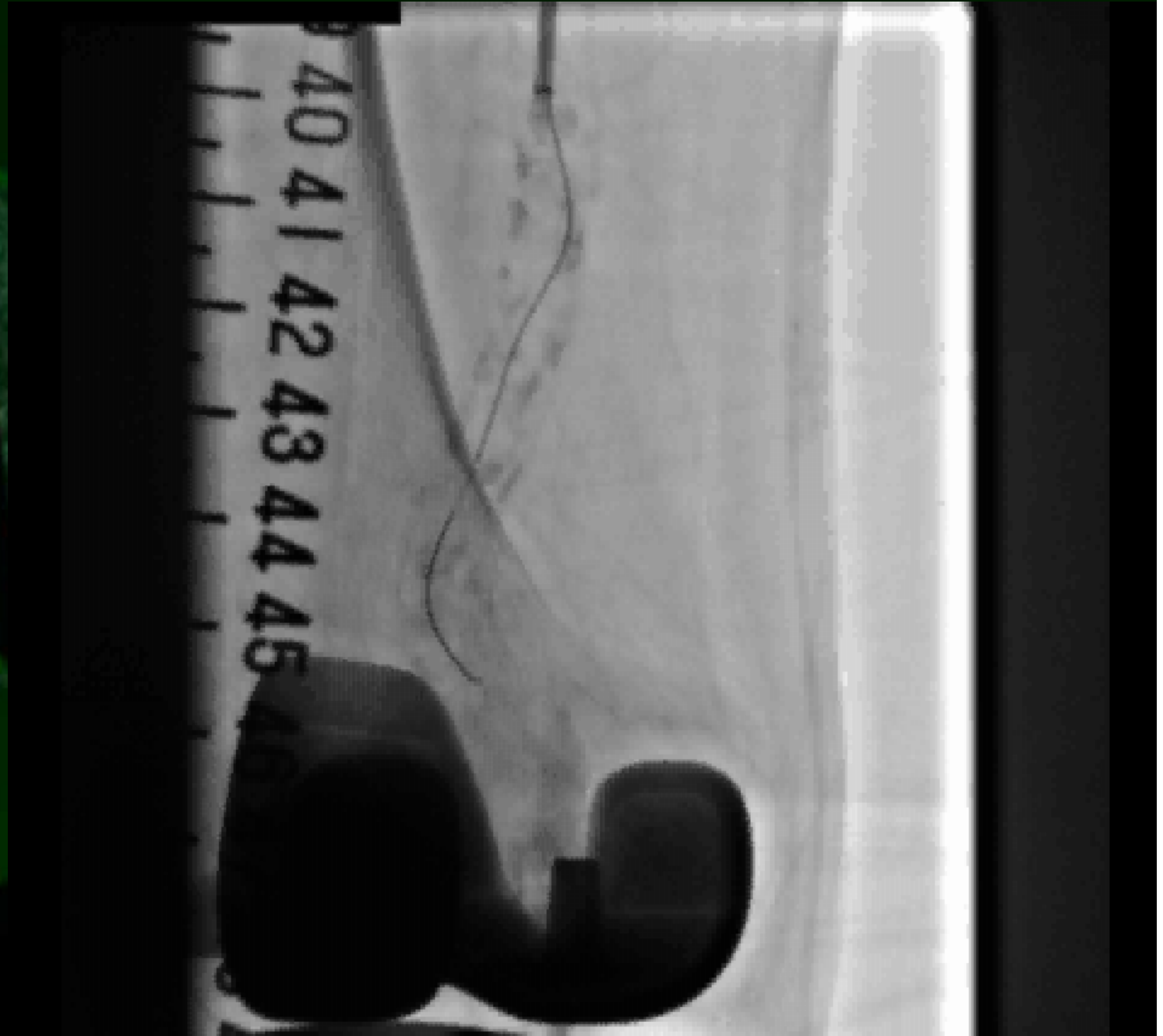



Control angiography (around knee joint)



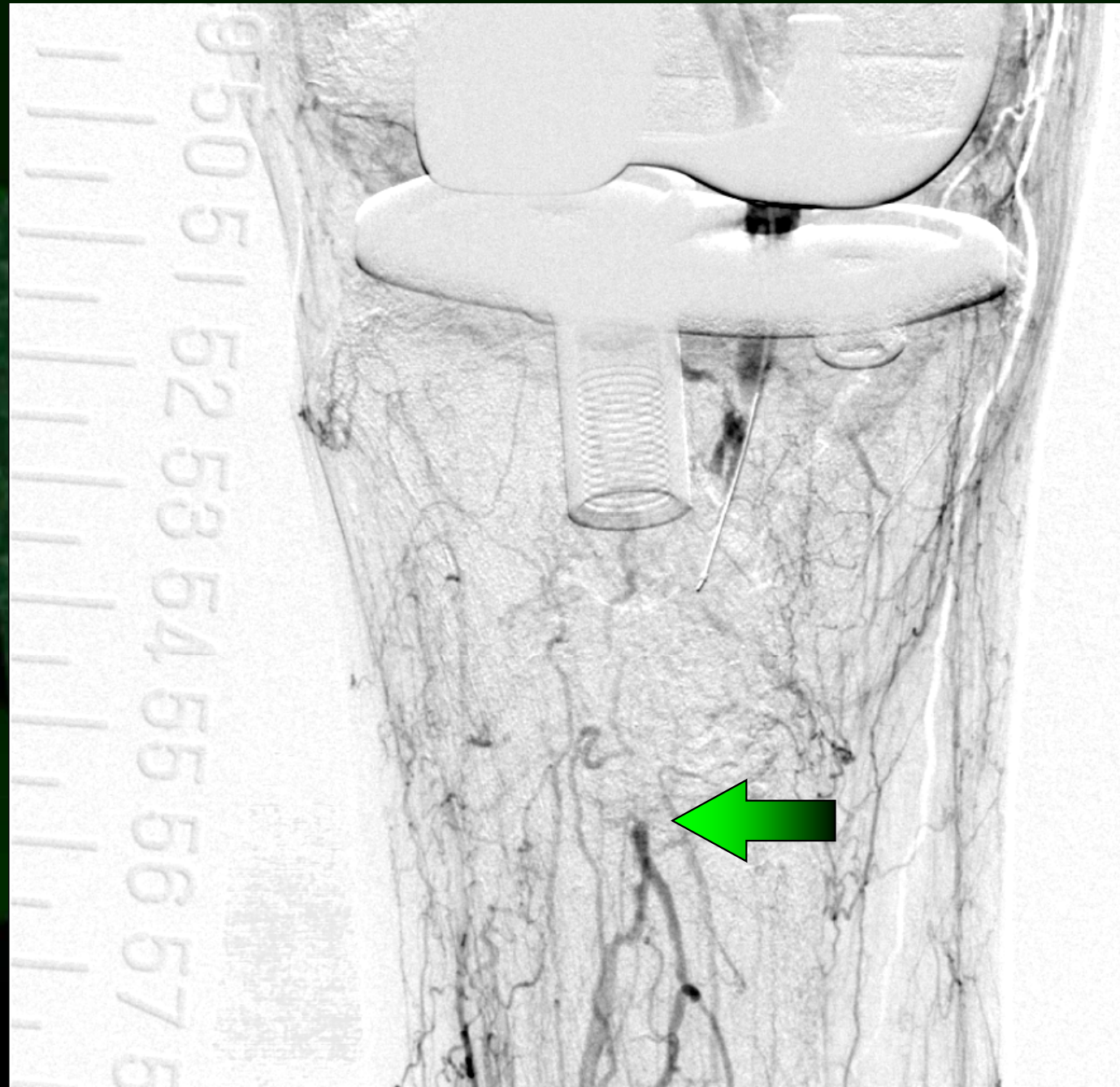
Antegrade wiring to the POP lesion

Ruby hard (Kaneka)
Prominent (Tokai
Medical Products)



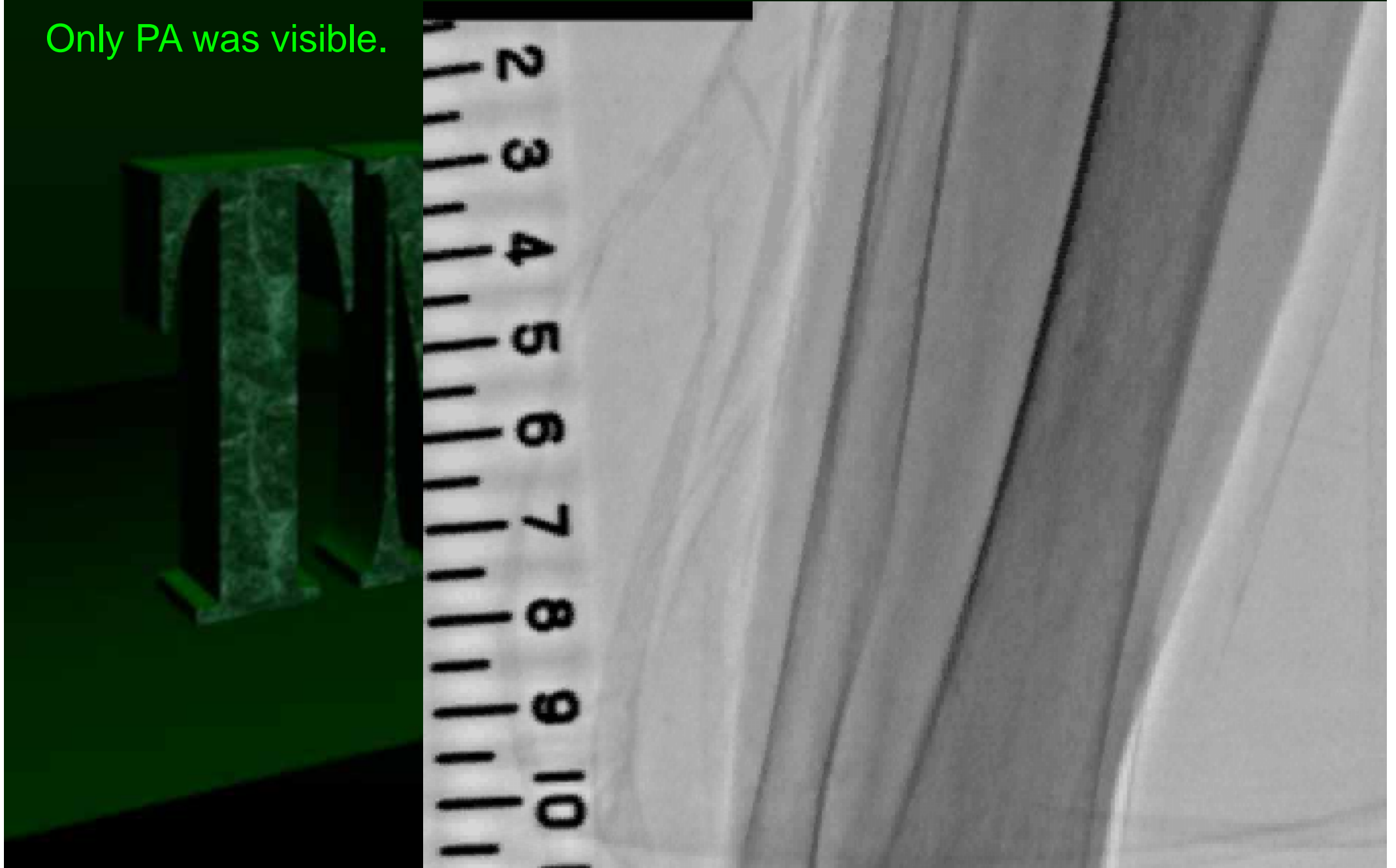
DSA of BTK area

PTA-PA bifurcation
was visible.



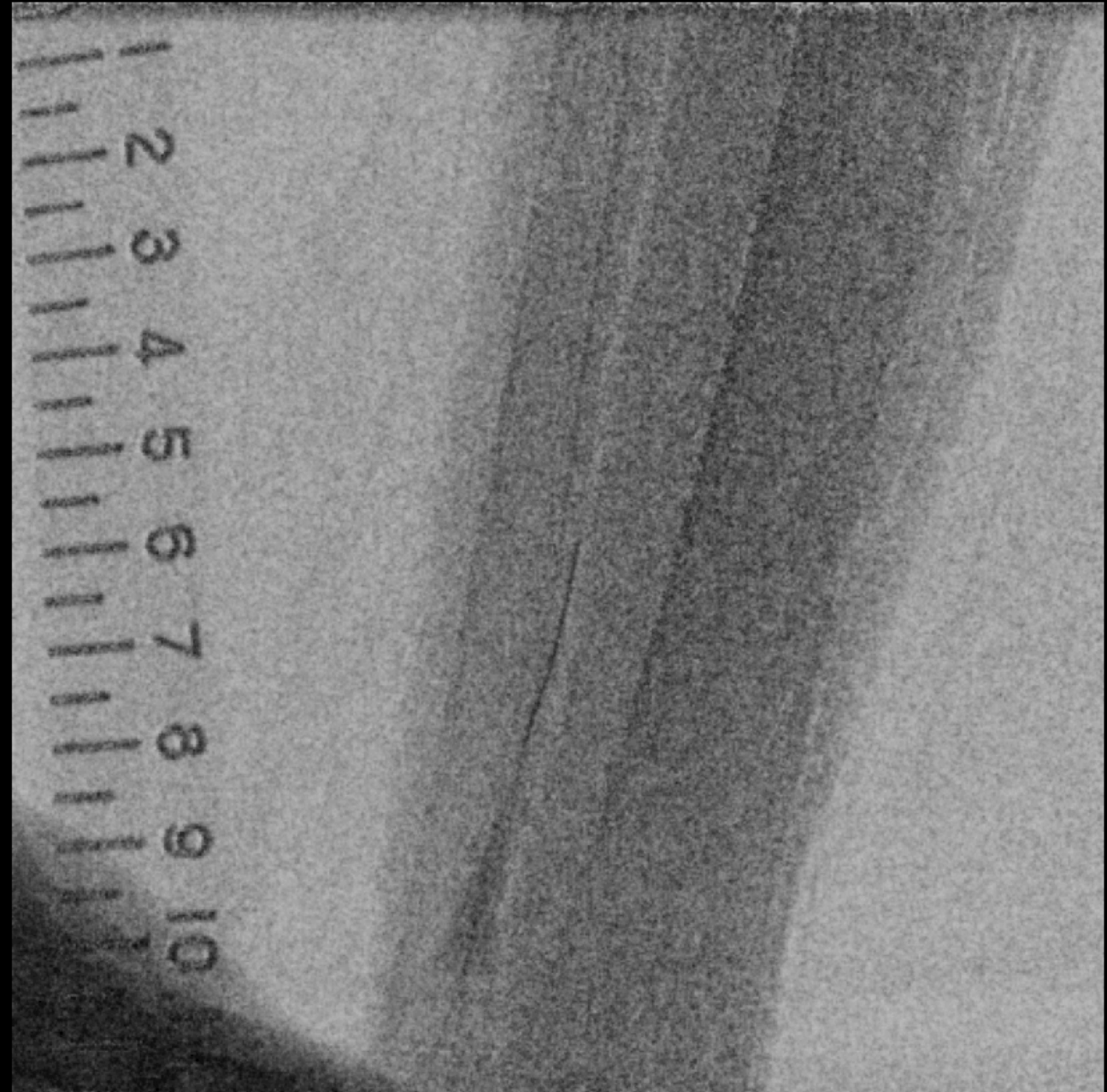
Angiography of distal BTK area

Only PA was visible.



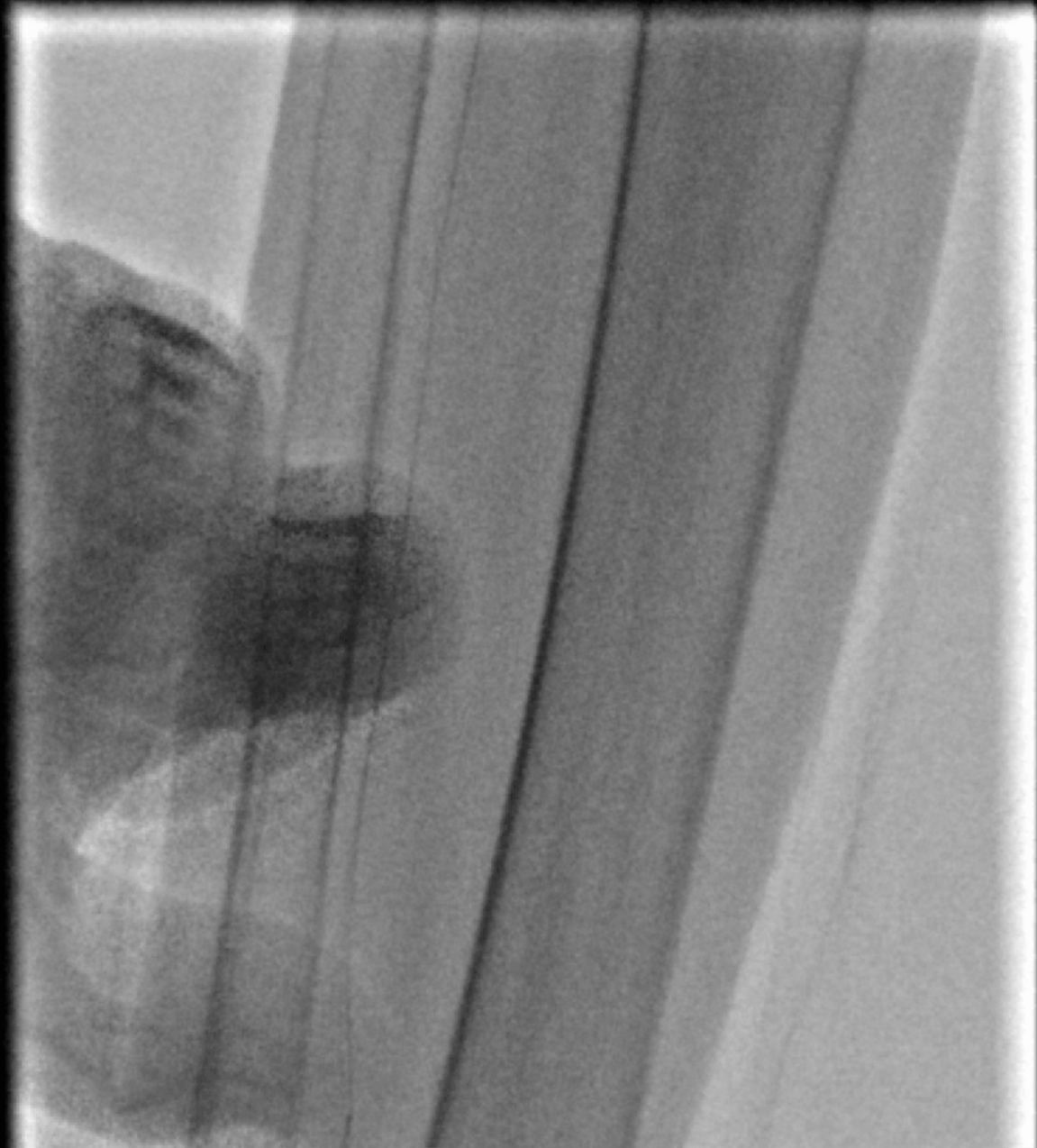
Distal puncture

Distal PA was punctured using 20G puncture needle.



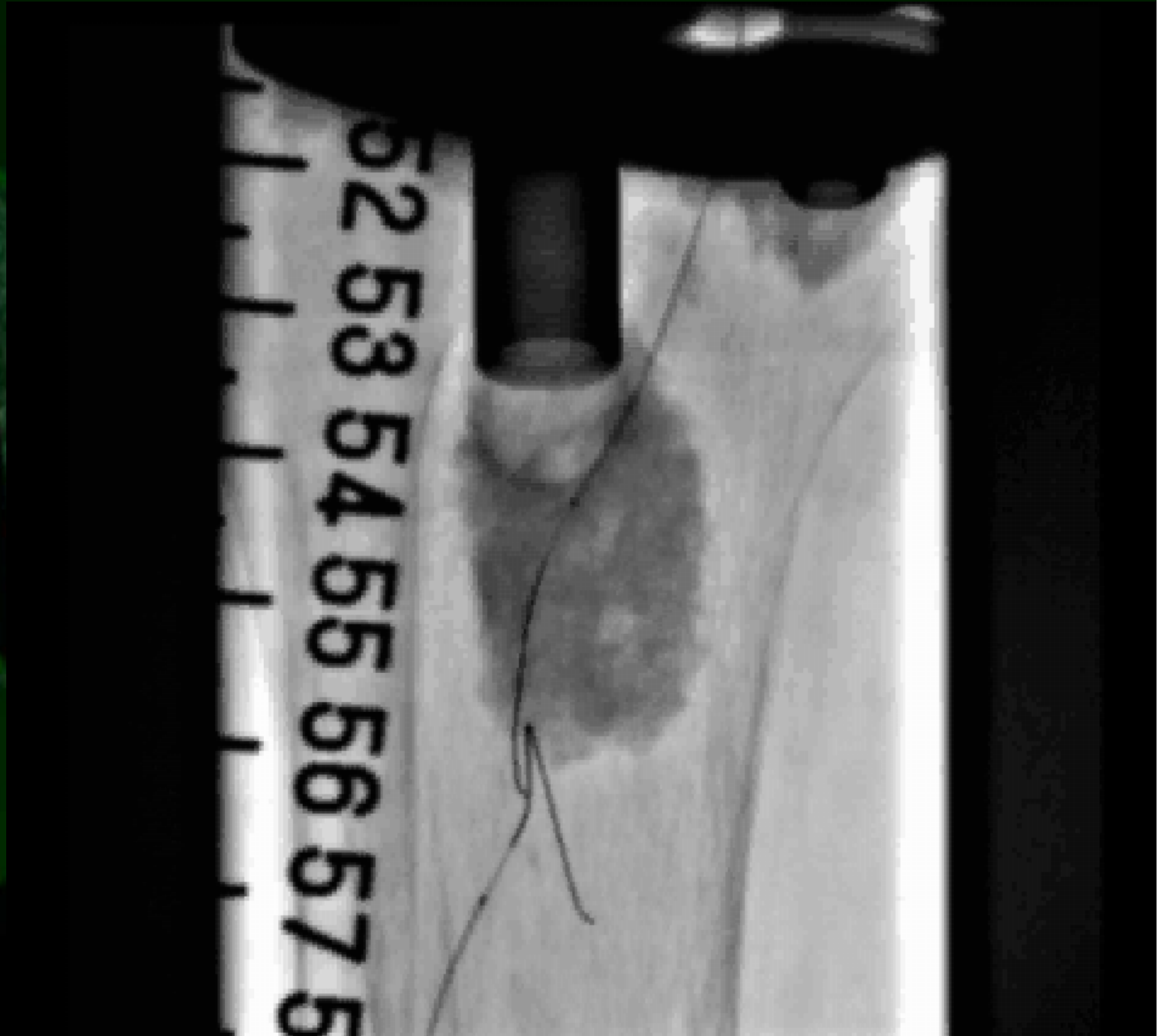
Retrograde wiring

Cruise was advanced.
Prominent was used
as a sheath.



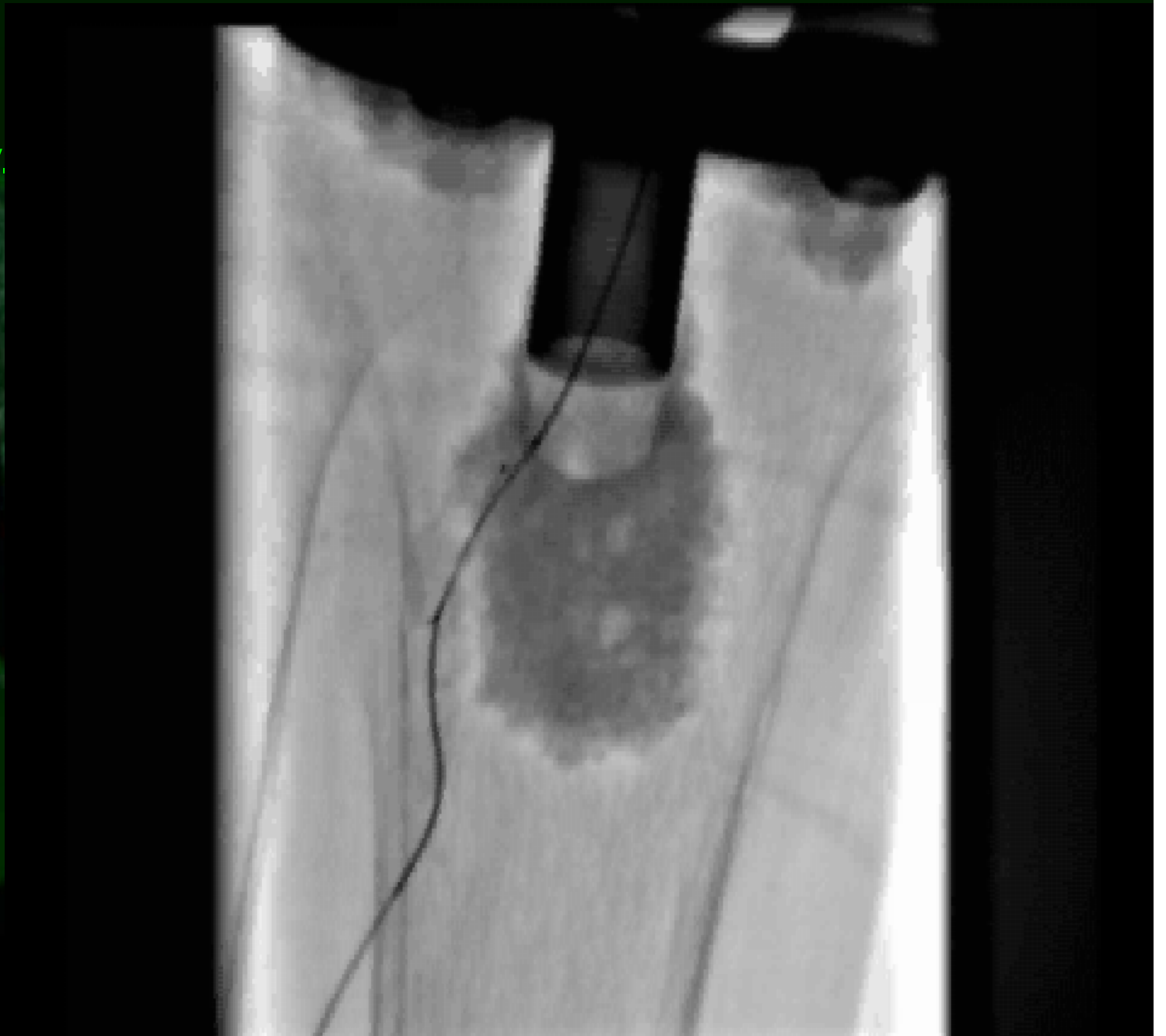
Bi-directional wiring

Retrograde wire
Advanced to the
bifurcation point.



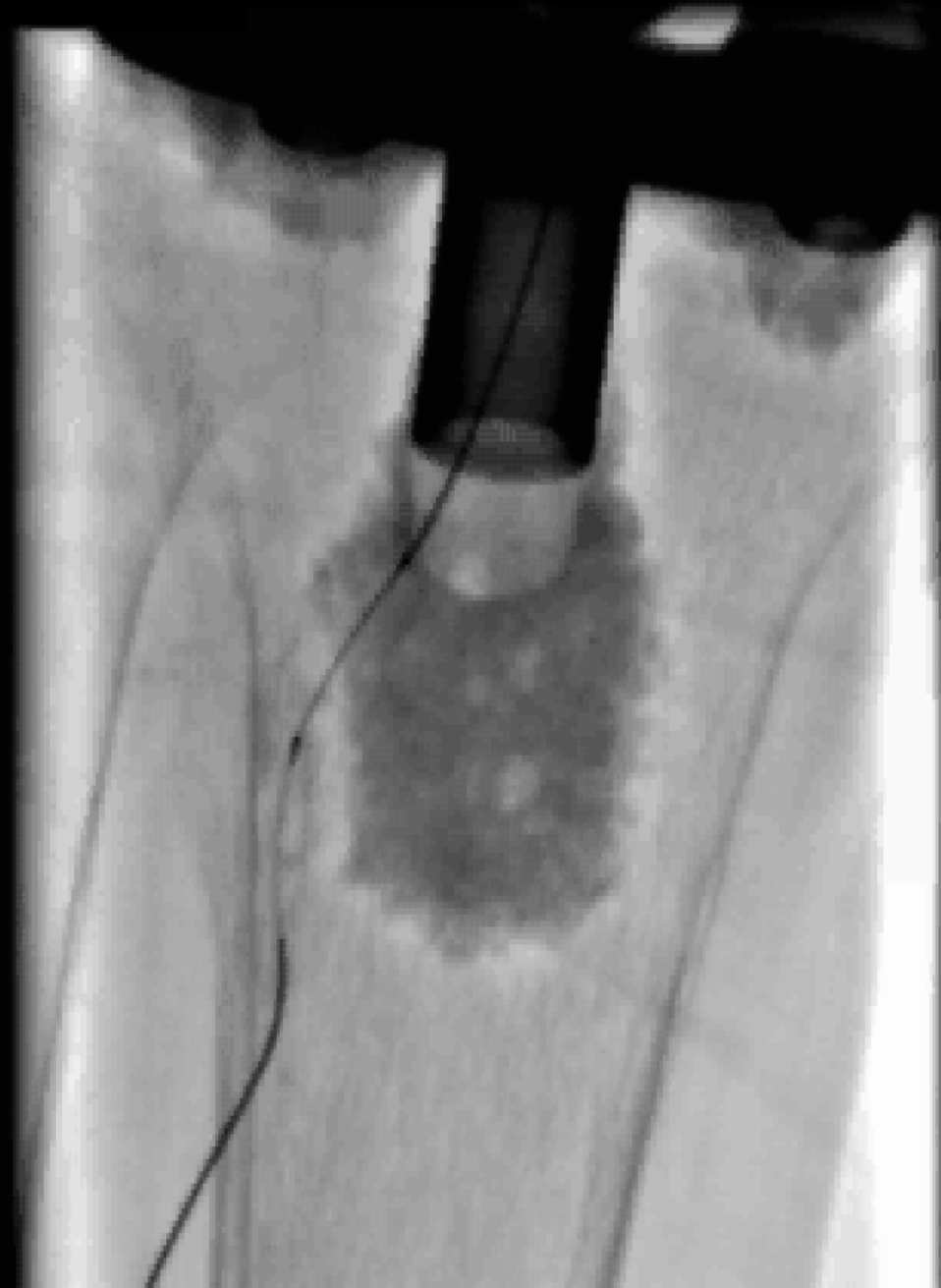
Bi-directional wiring

Two guidewire /
micro-catheter sets
were aligned coaxially.




Wire Rendez-vous

Antegrade Ruby hard
advanced into the
retrograde Prominent.

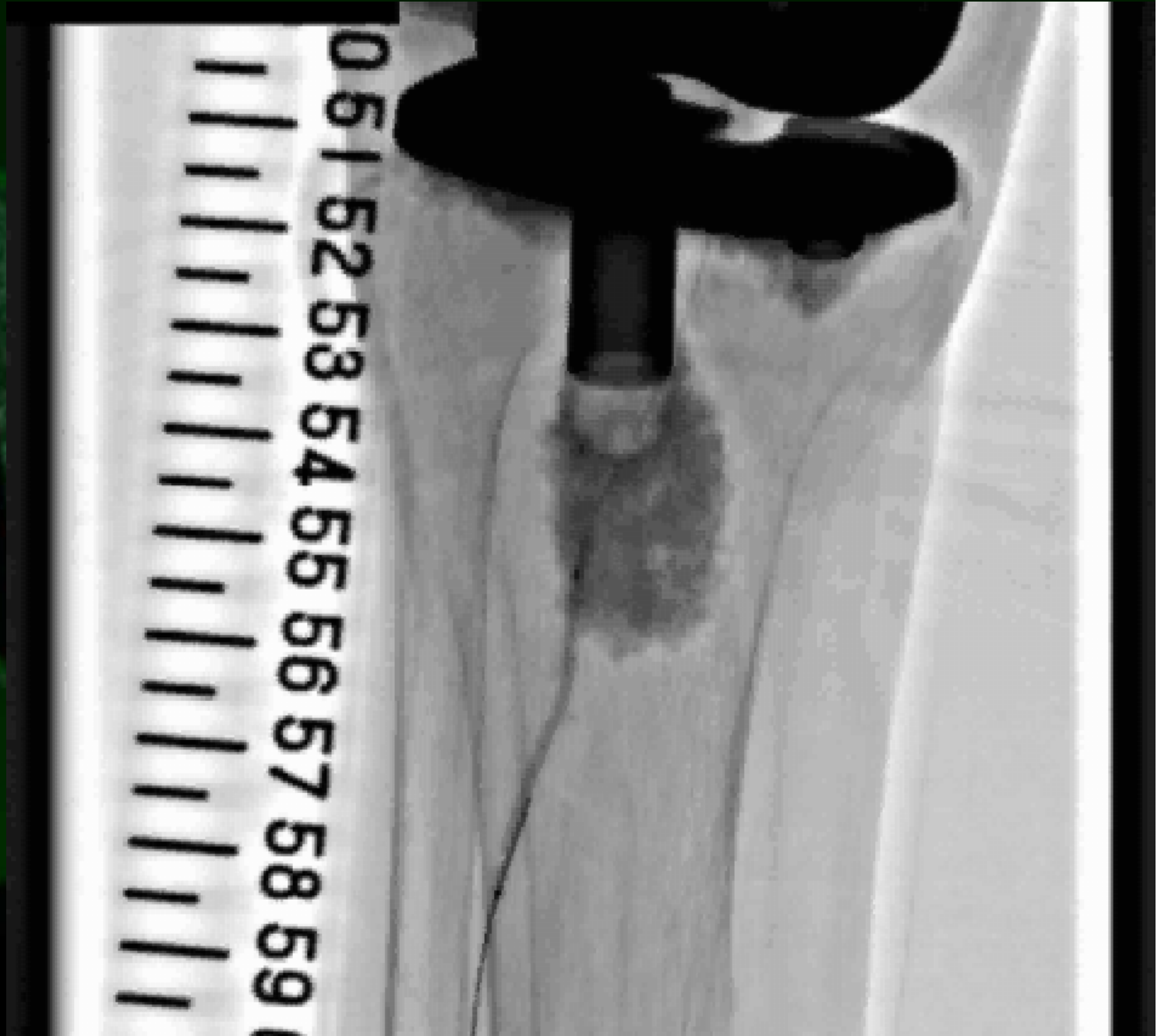


Antegrade wire was redirect to the distal PA



Balloon angioplasty


Fennec 2.0x40mm



Intravascular Ultrasound

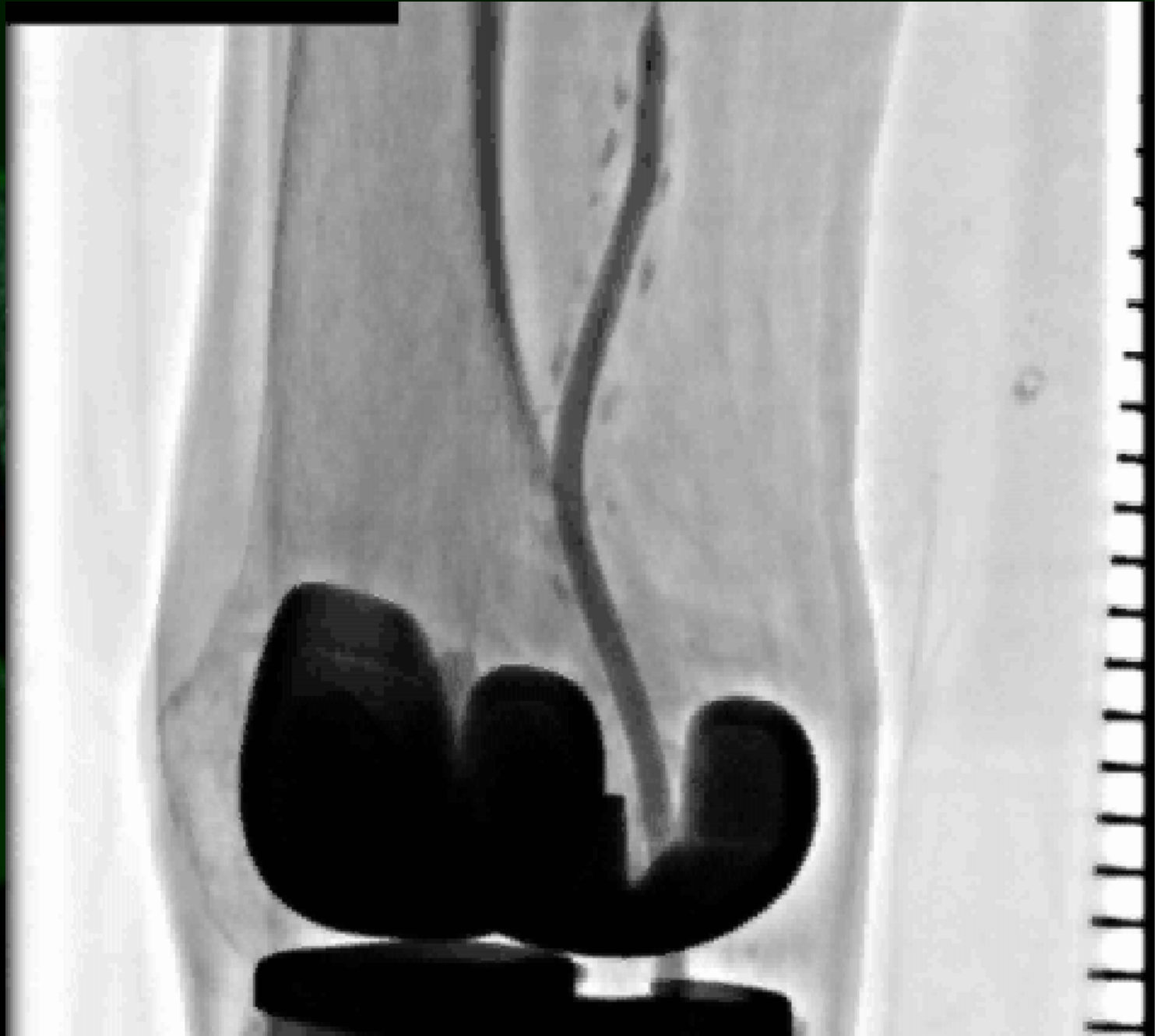
IVUS images showed the existence of thrombus within the CTO segment.

Manchette was wrap around the lower extremity to prevent distal embolism during following EVT procedure.



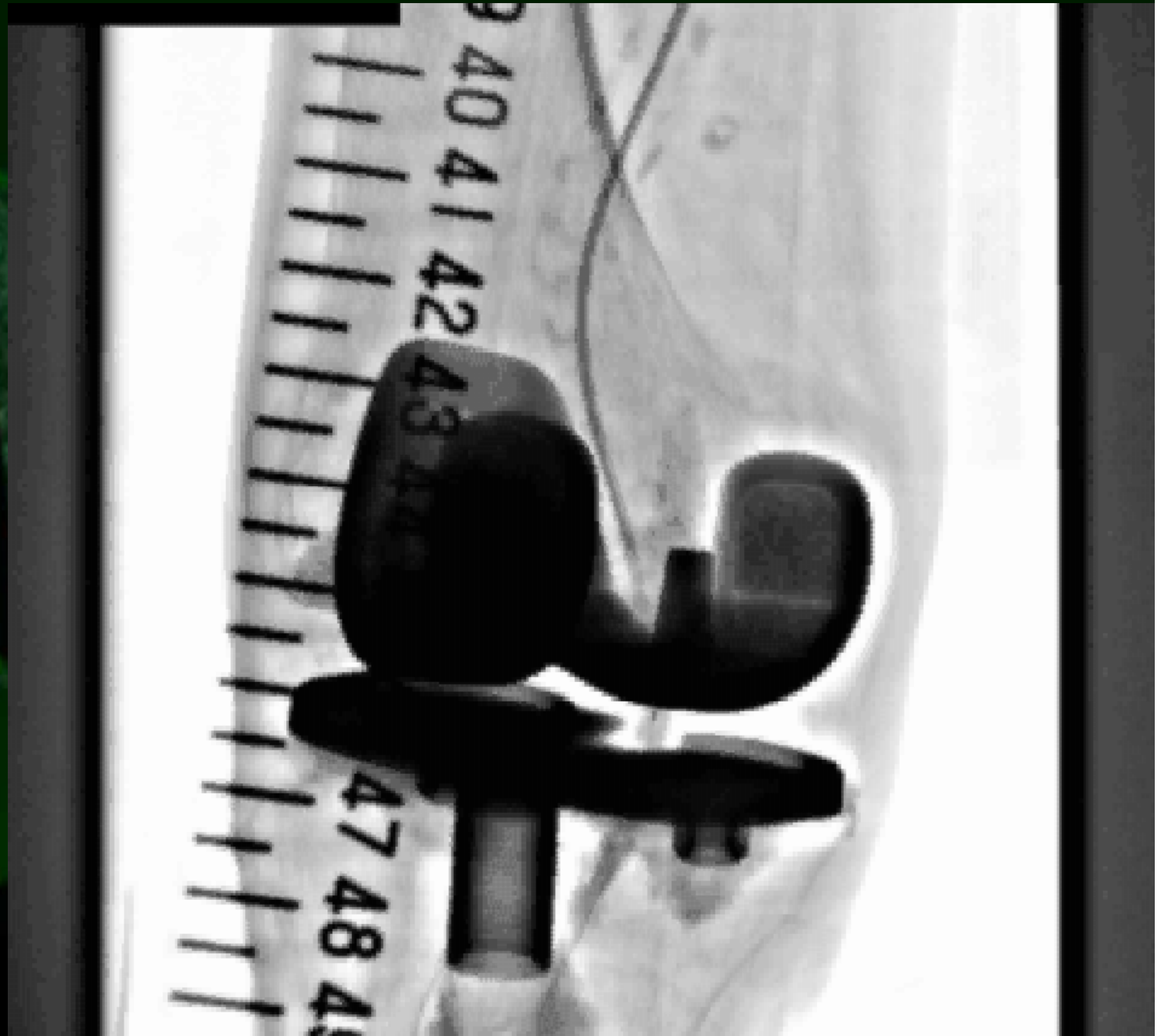Balloon angioplasty

Amphilion-deep
4.0x120mm
(Medtronic Invatec)

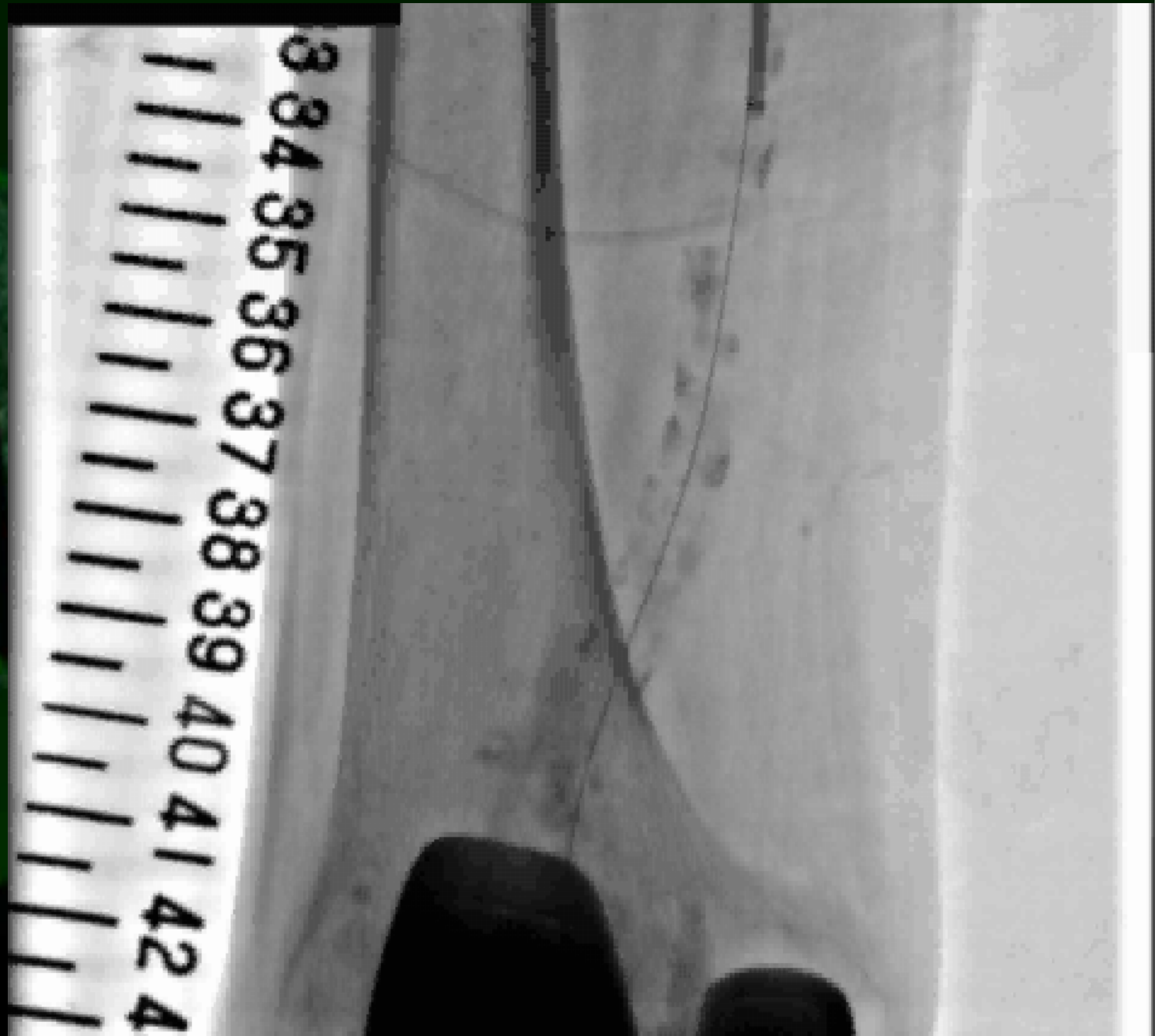


Reverse angiography

There was no contrast defect above the protection line.

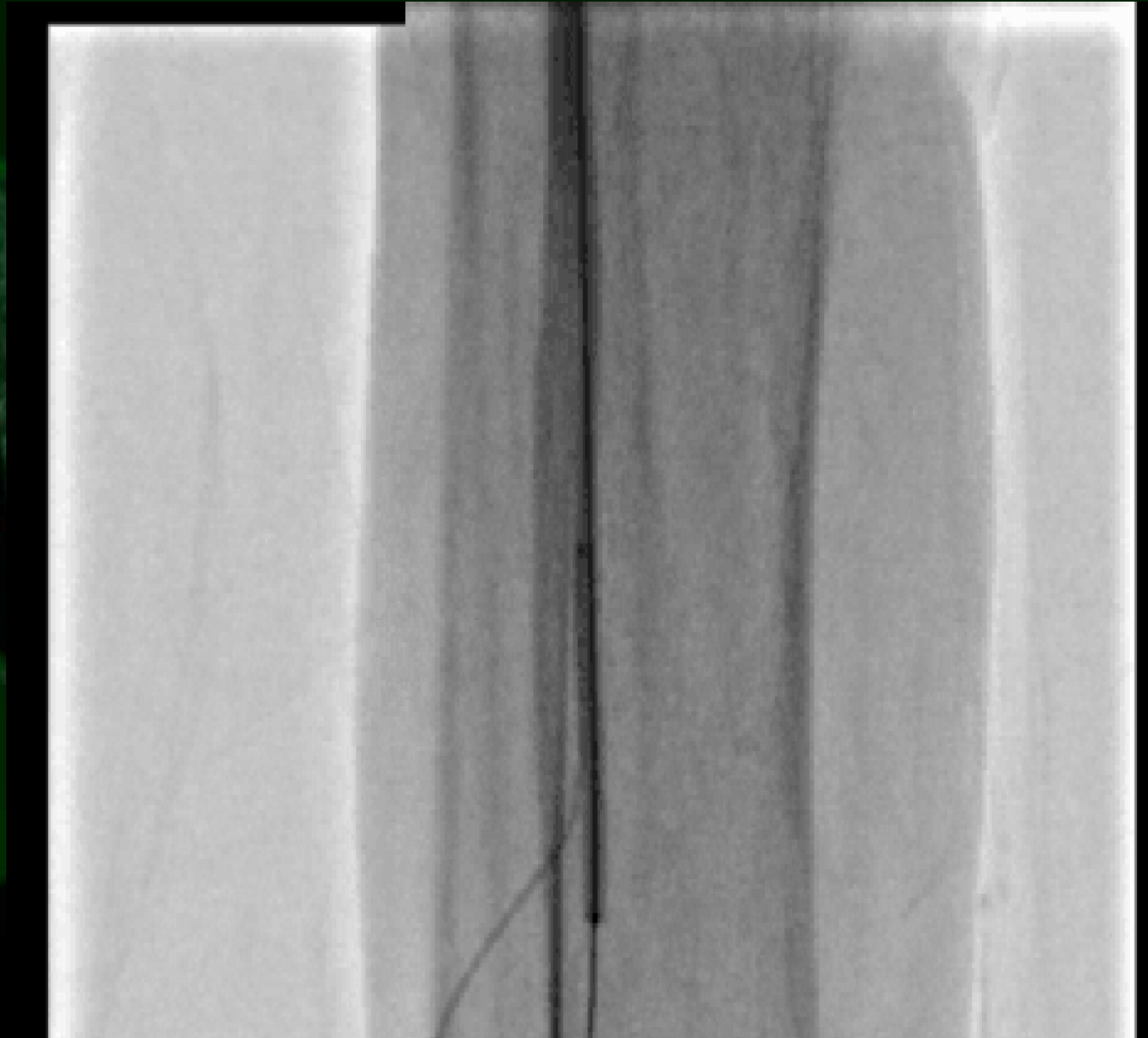


Angiography




Balloon angioplasty for POP-PA lesion & hemostasis

Shiden 2.0x200mm

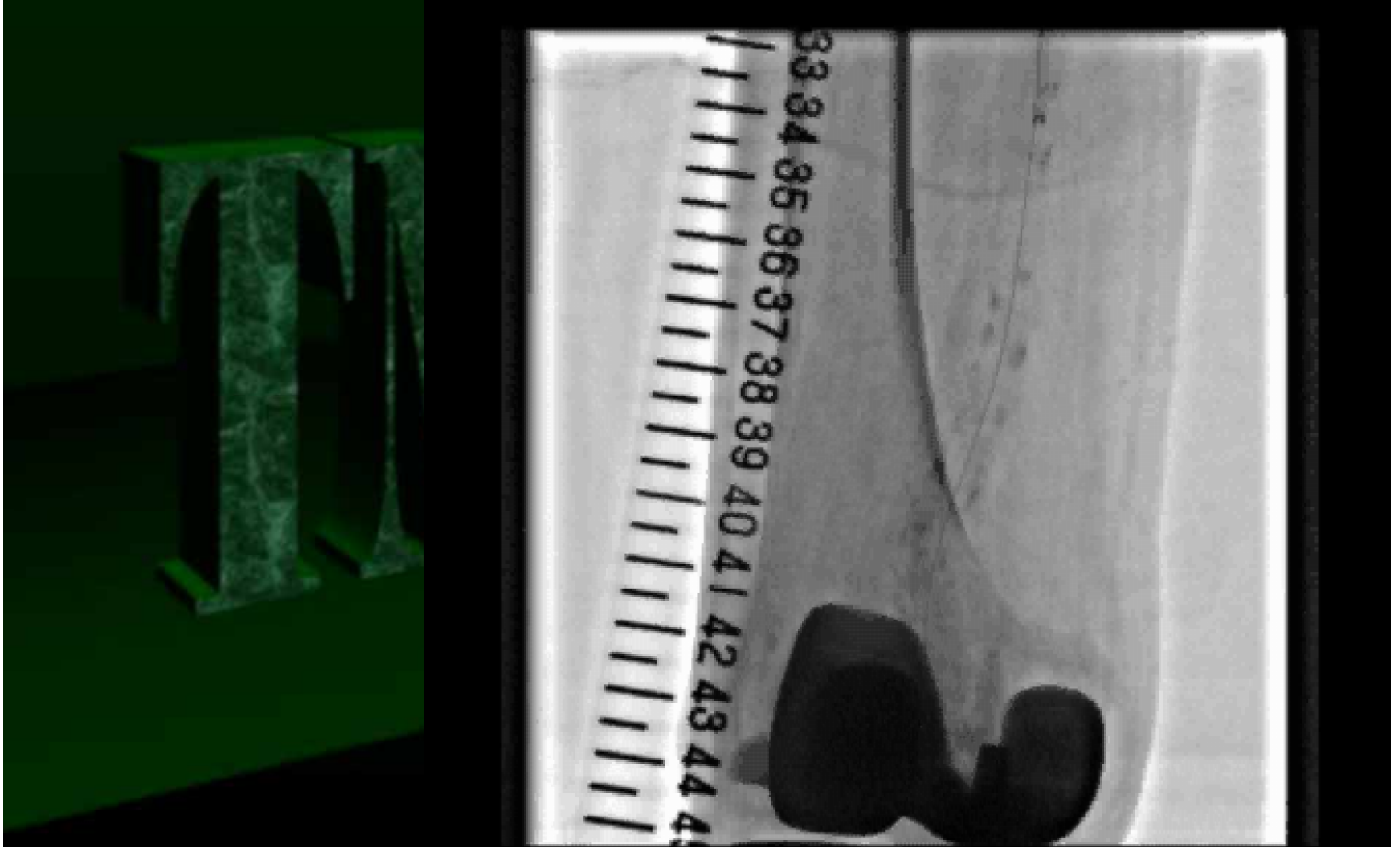


Balloon angioplasty

Shiden 2.0x200mm
(Kaneka)



Final angiography





More insane procedures

Digital artery puncture

Retrograde percutaneous digital artery access: pushing forward limits and indications for foot revascularization.

Marco Manzi, MD, Luis Mariano Palena, MD, Giacomo Cester, MD
Policlinico Abano Terme, Abano Terme(PD), Italy

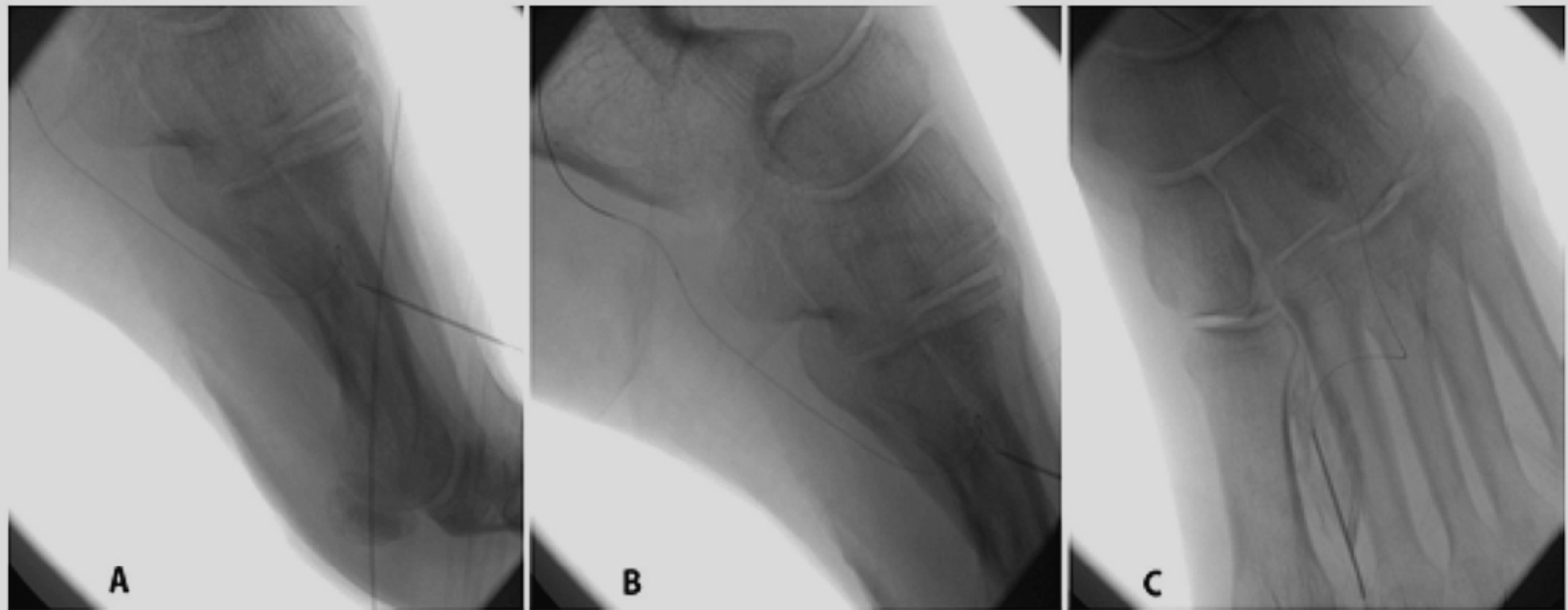
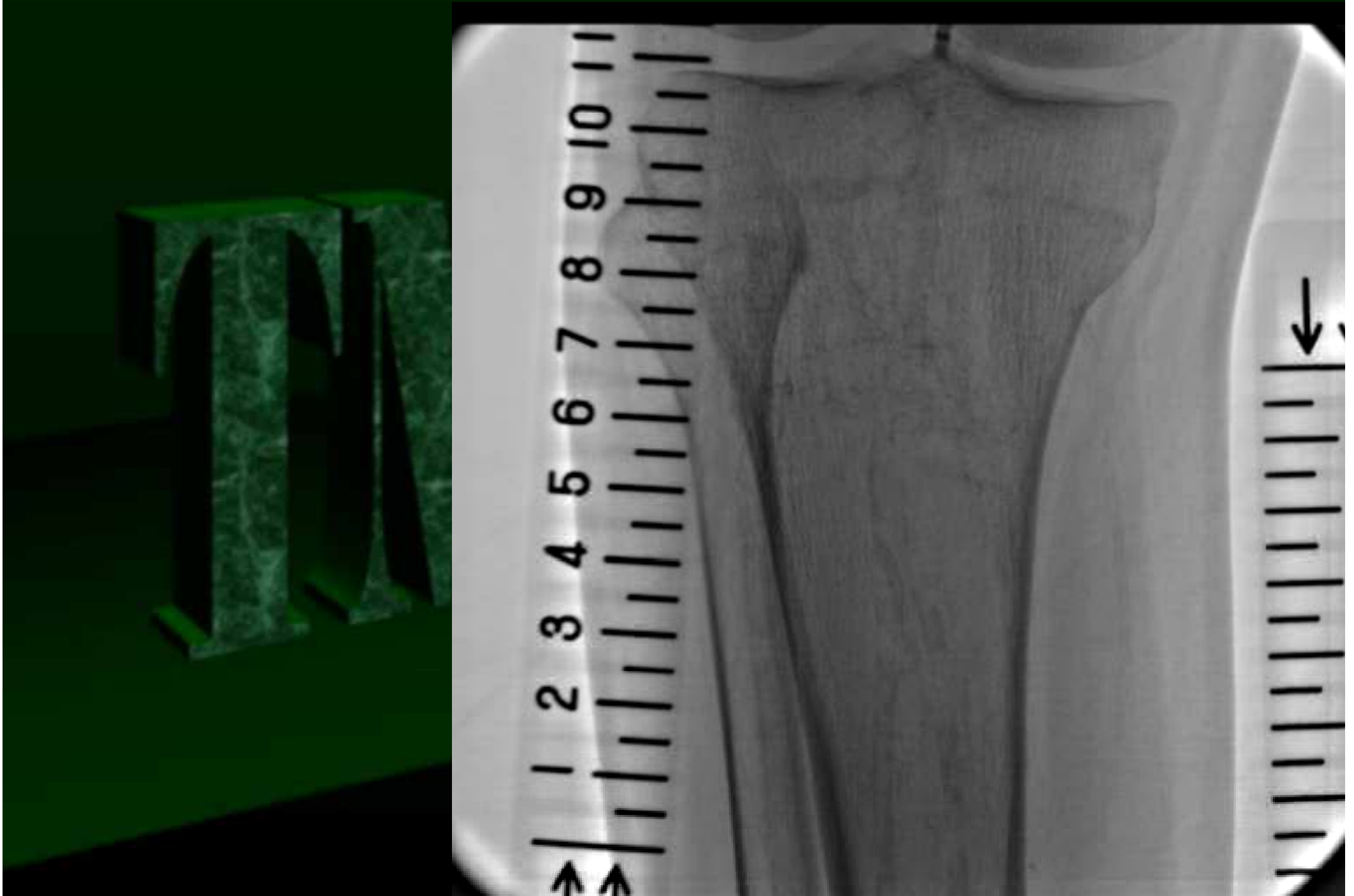


Figure 3. Puncture and wiring of first metatarsal artery. (A-B) latero-lateral view and (C) antero-posterior view, shows the guide-wire in the LOOP and lateral plantar artery, through the first metatarsal artery access.

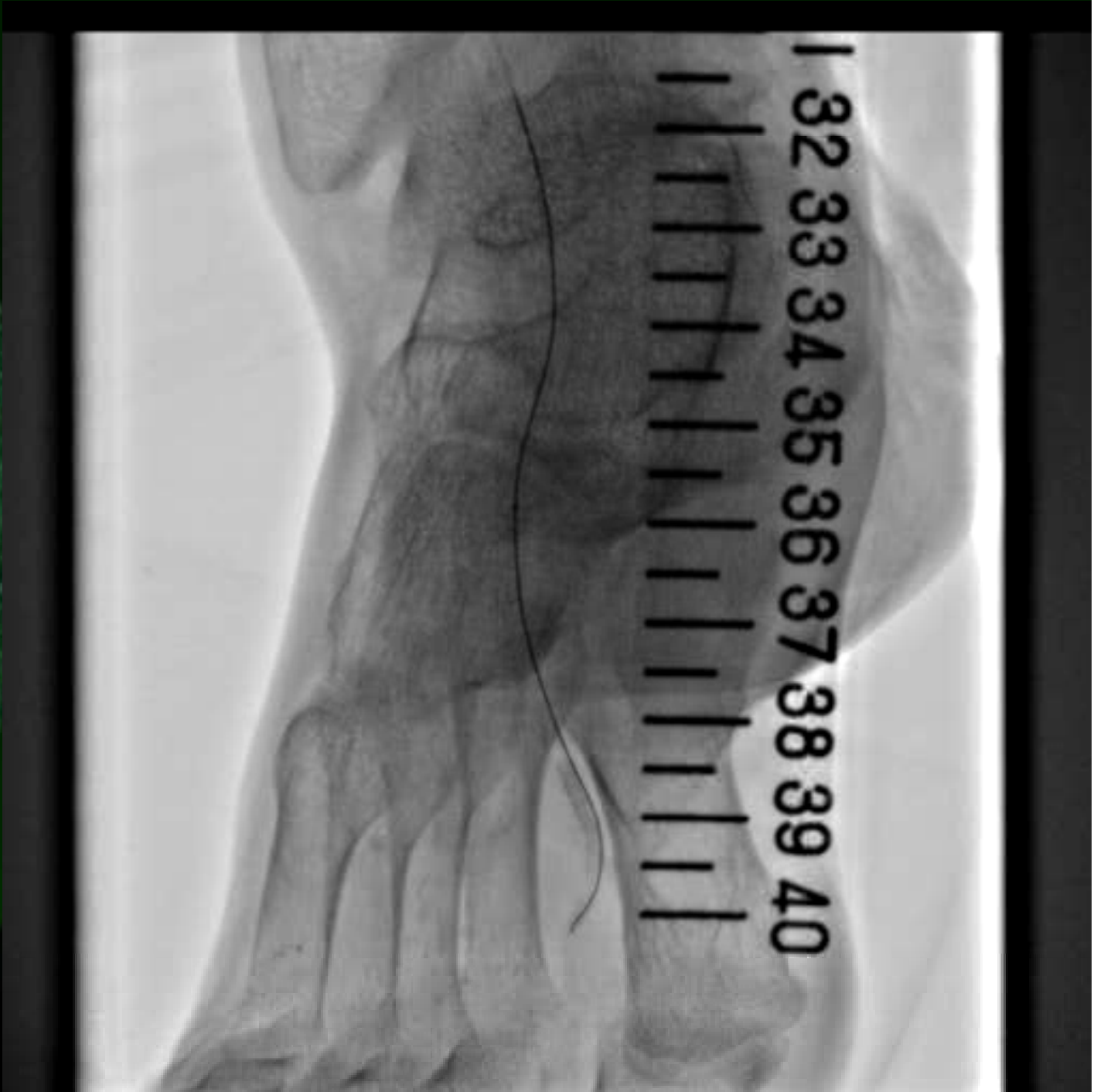Case: digital artery puncture

Case	59F
Diagnosis	PAD(CLI), IHD, CRF(HD), VTs
Severity	Fontain IV, Rutherford 5
Target	ATA & DP
Lesion type	Diffuse stenosis and CTO
Date of EVT	2013.1.17

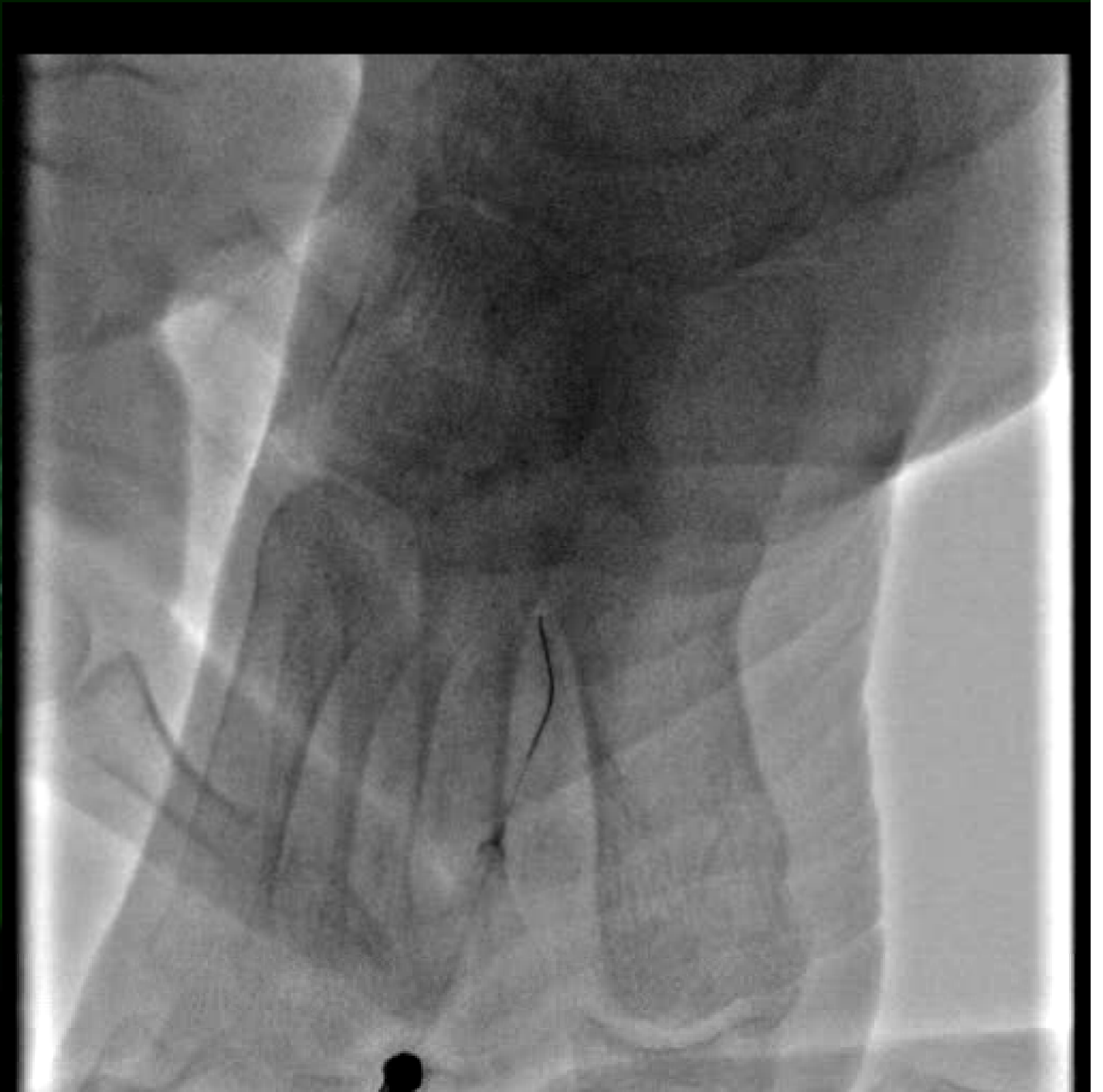

Control Angiography



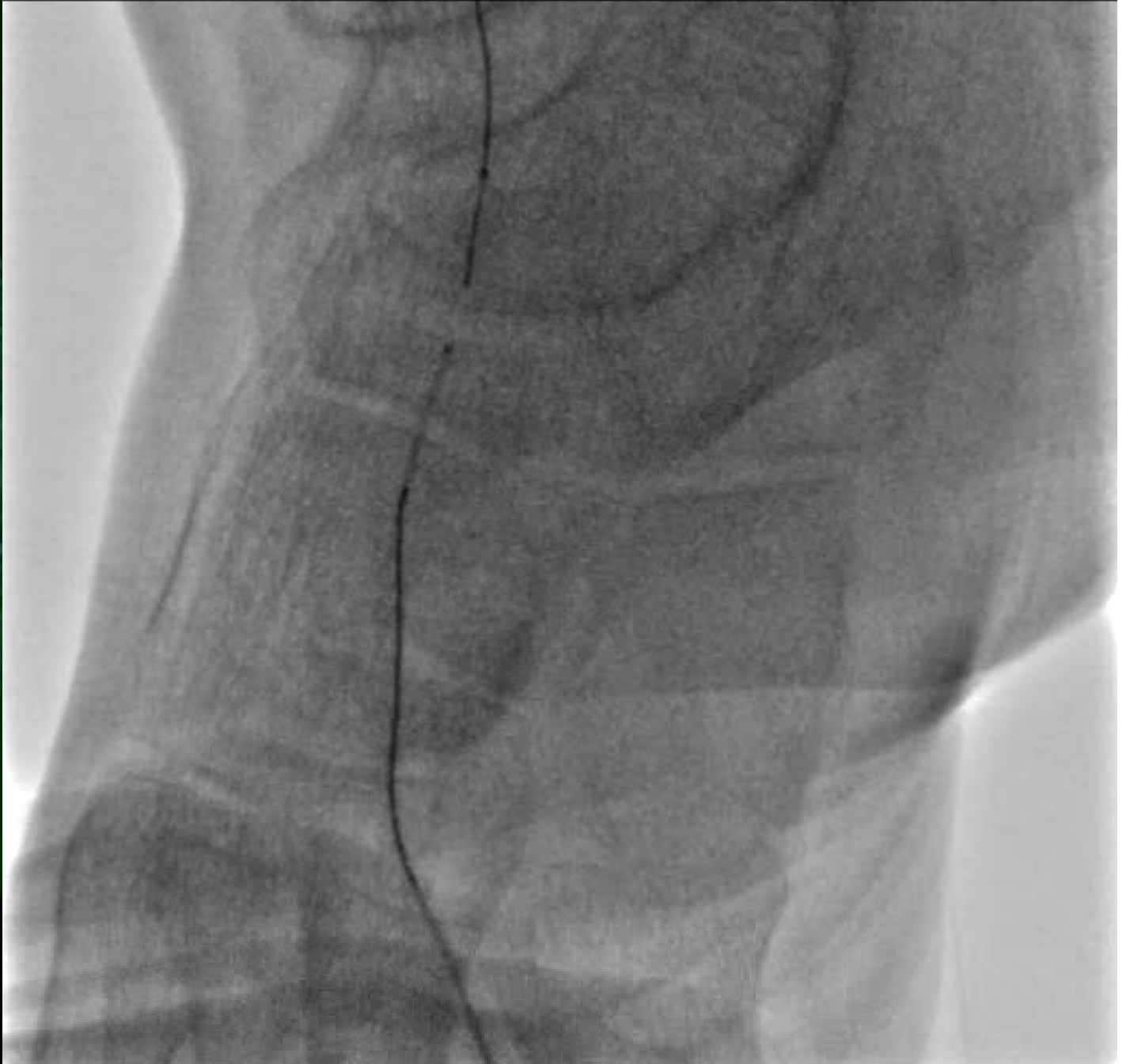Antegrade guidewire advanced into the sub-intimal space



Digital artery puncture and advance a retrograde guidewire

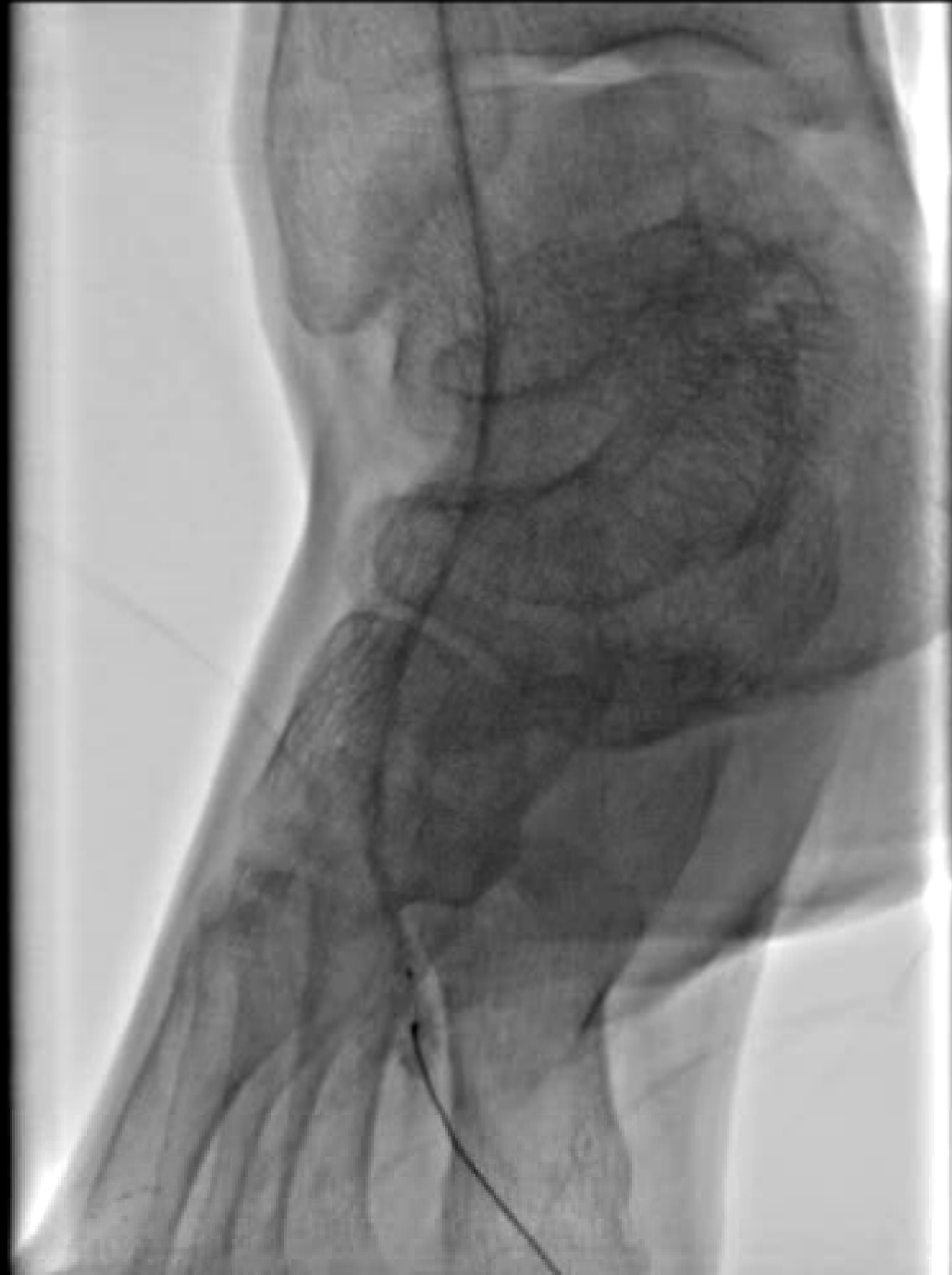

Wire Rendez-vous Method

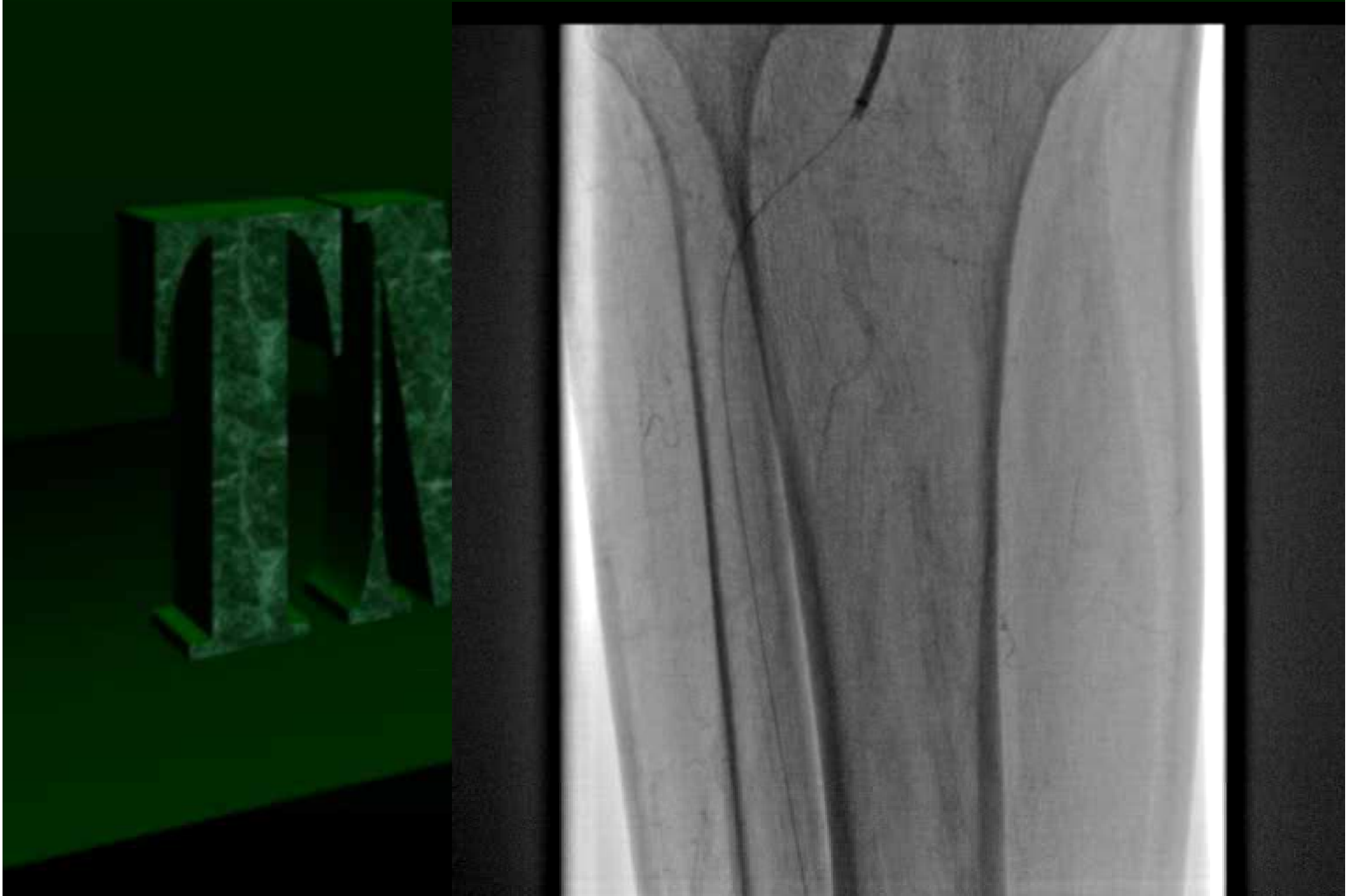


Balloon angioplasty of DP and ATA

Coyote 2.0x220mm
(Boston)



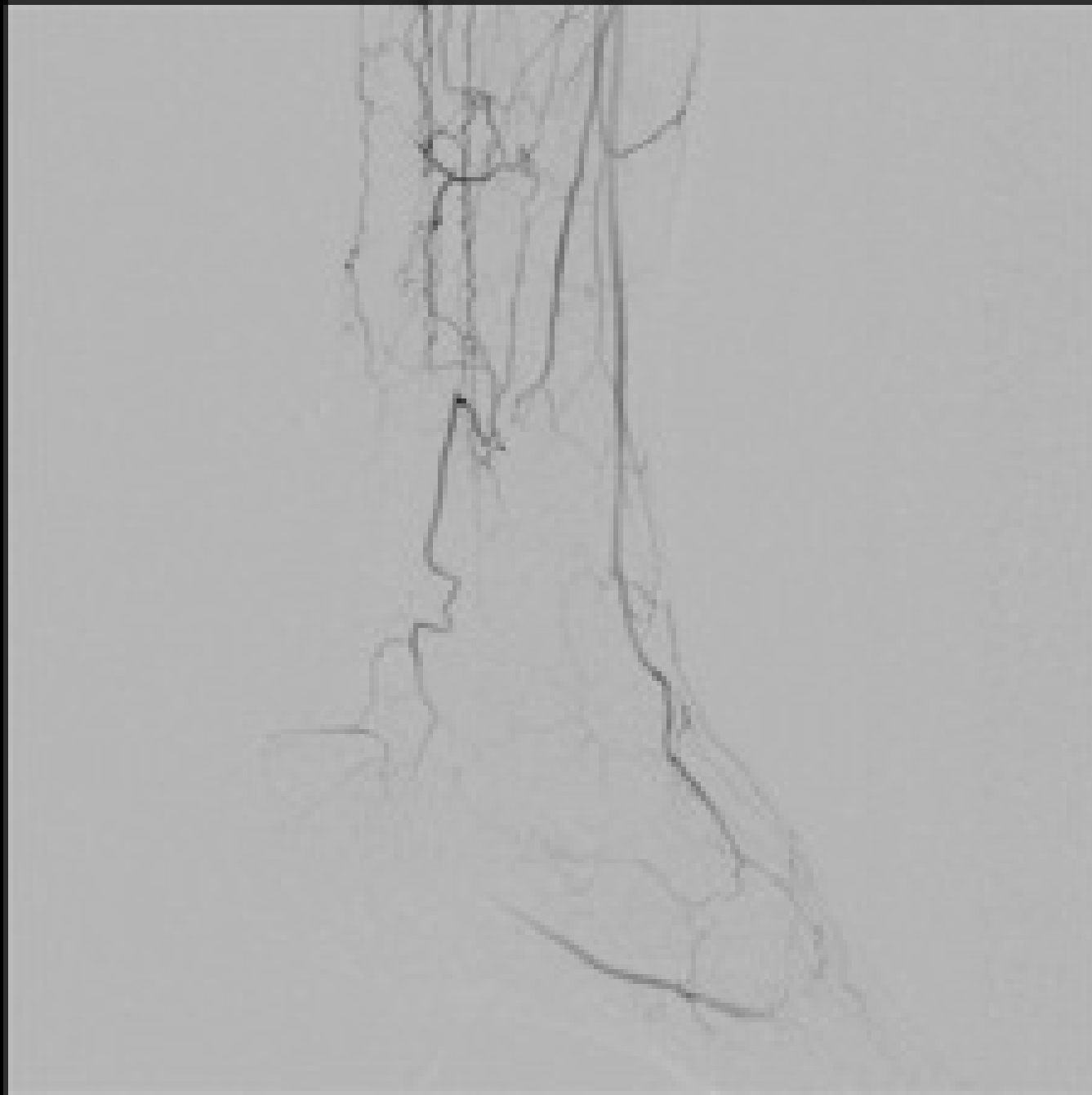
Final Angiography



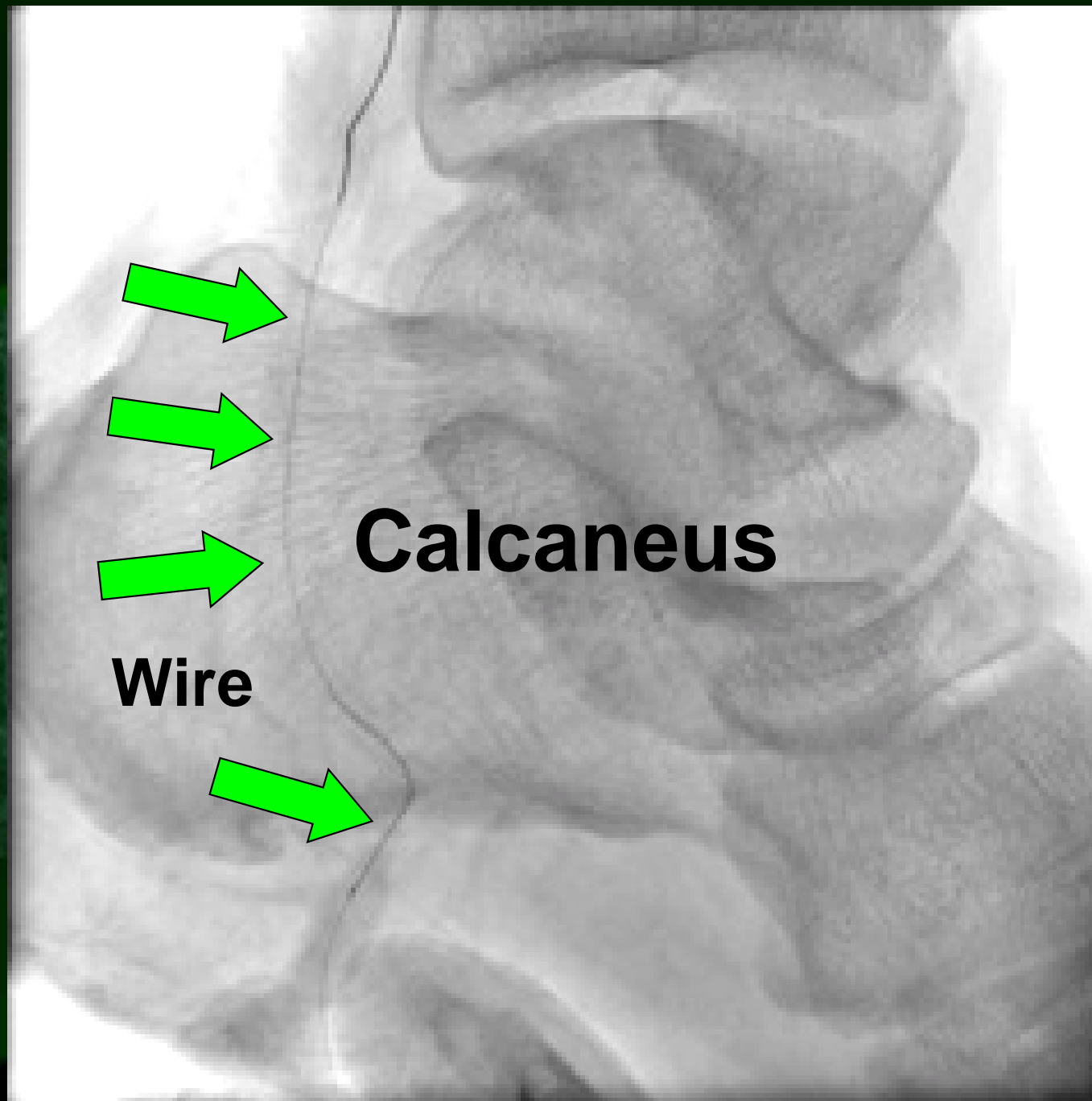
More insane procedures

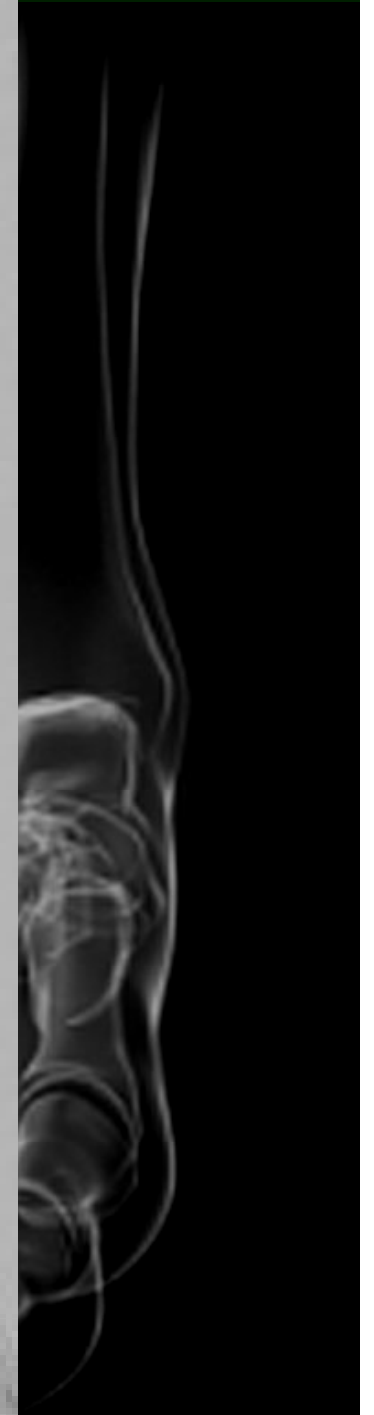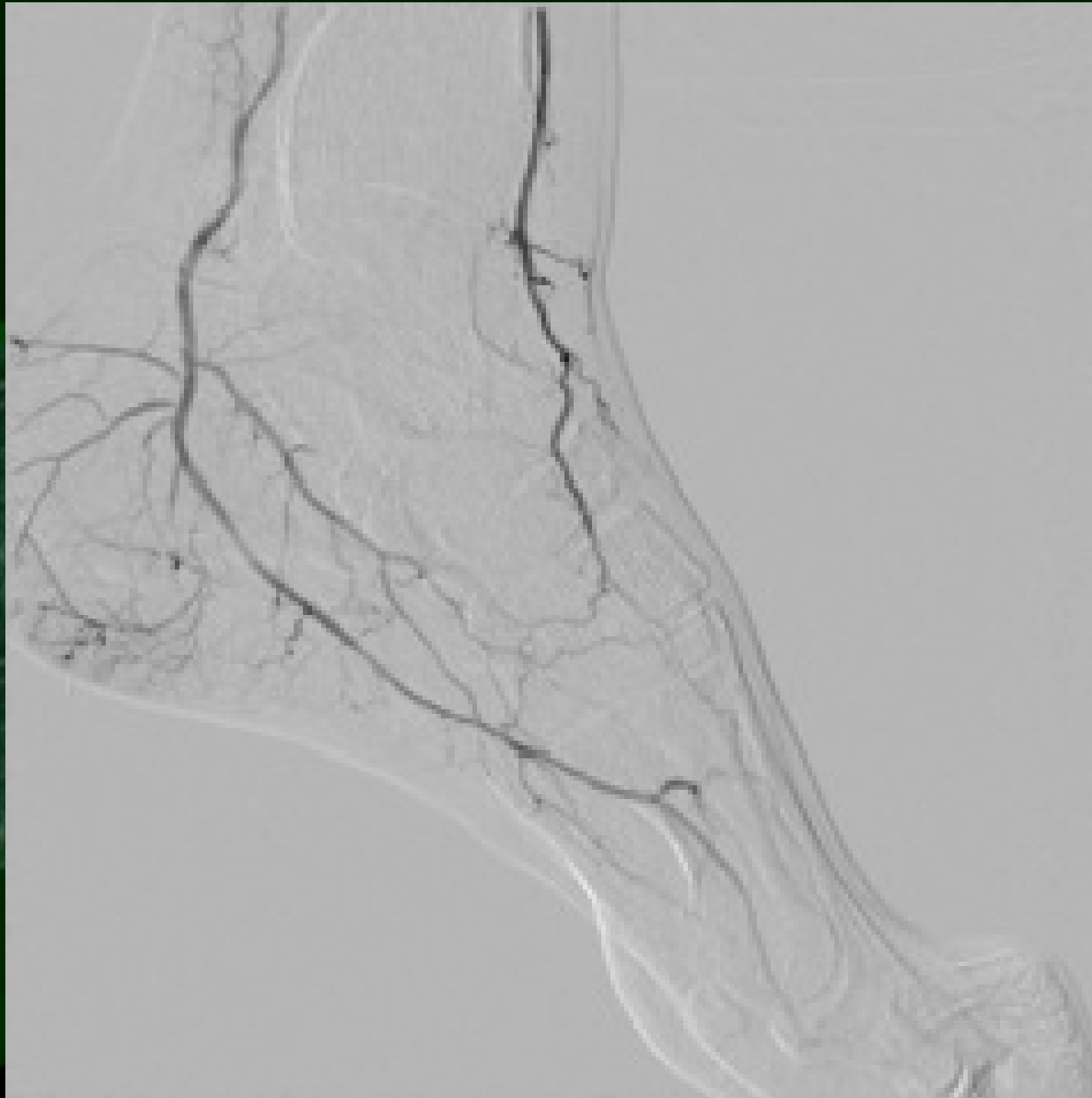
Plantar artery puncture

Plantar artery puncture



Plantar artery puncture





Summary

Bi-directional wiring is extremely useful to enhance the initial success rate of BTK intervention.

We must learn various distal puncture techniques including peculiar punctures to beat MIC (Mission Impossible Cases).

