



YOU DID IT, YOU FIXED IT CASE PRESENTATION

Partnership Session with International Society

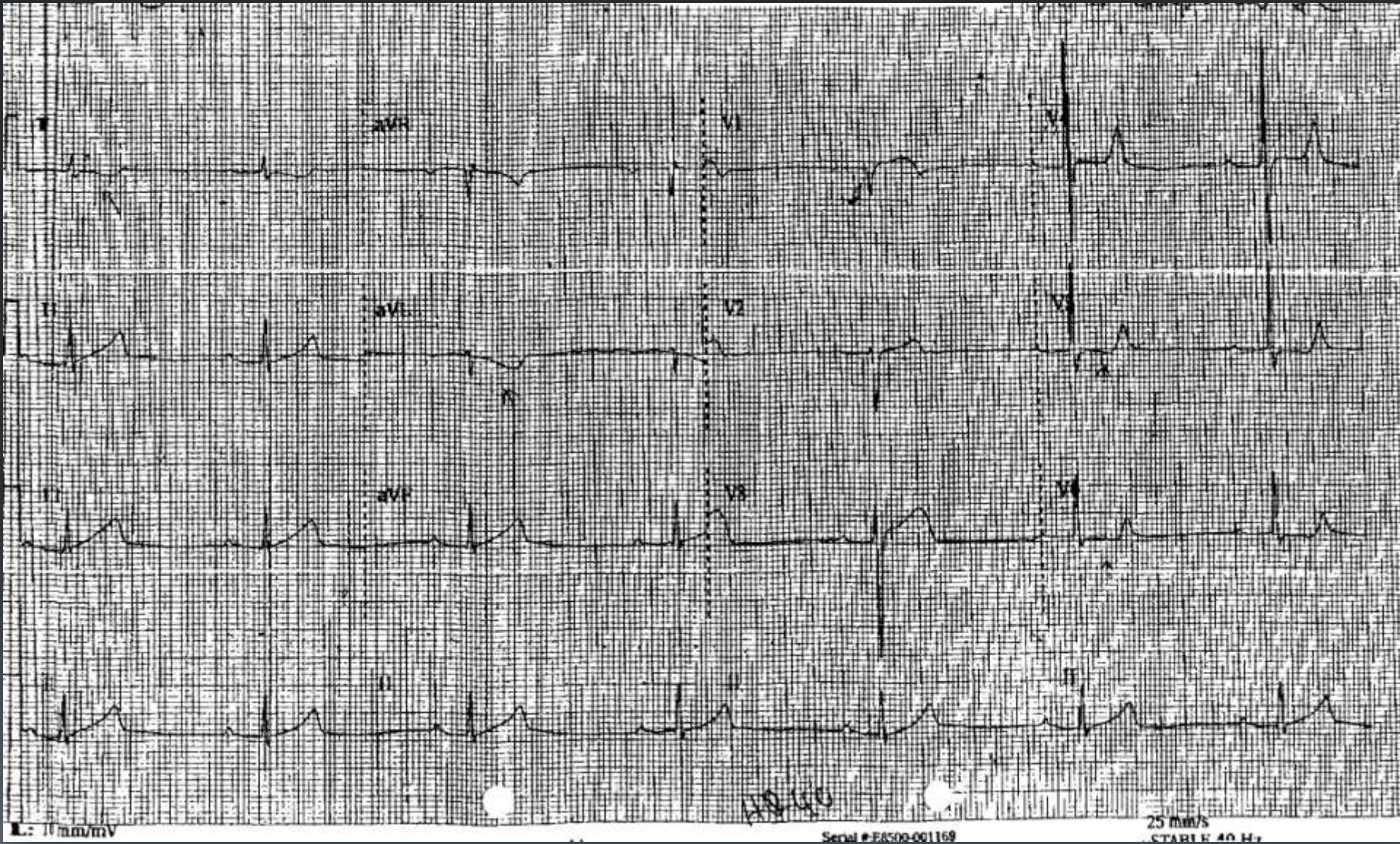
19TH TCTAP 2014

PIYANART PREEYANONT, MD
PERFECT HEART INSTITUTE
BANGKOK, THAILAND

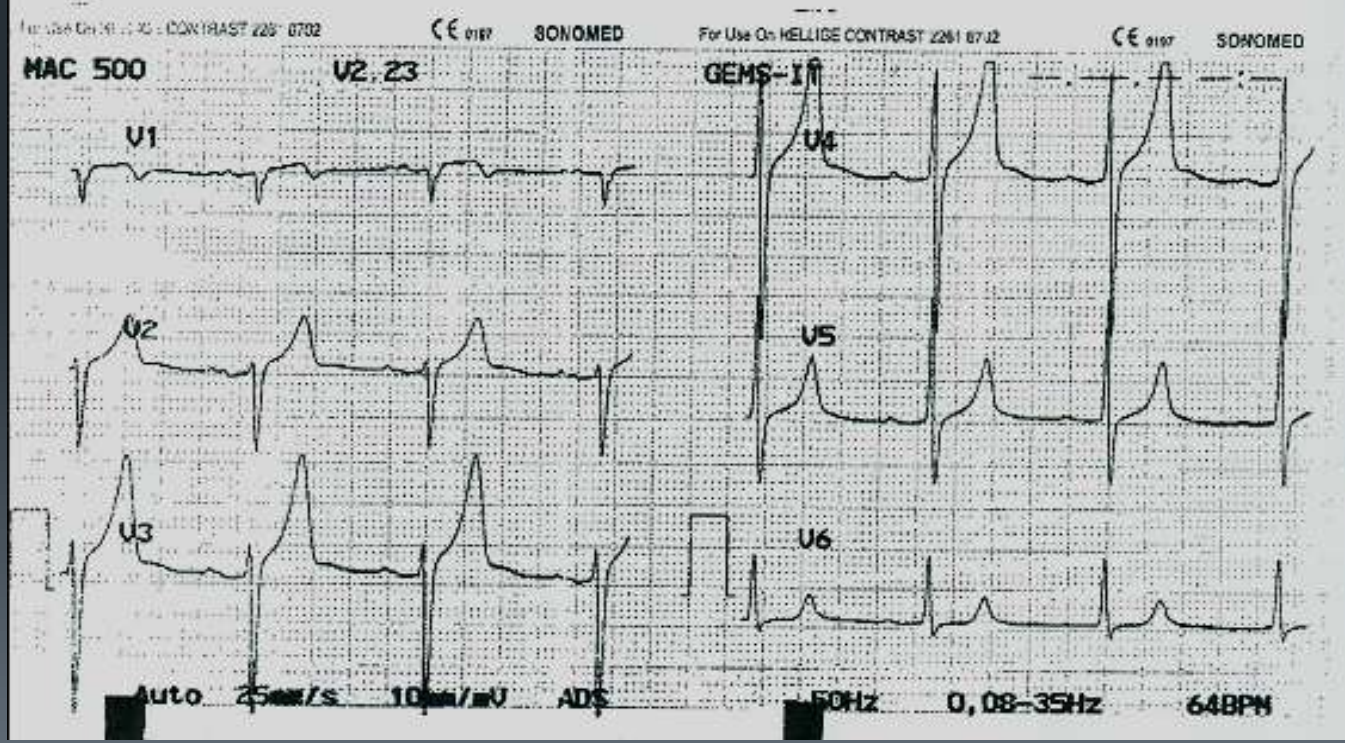
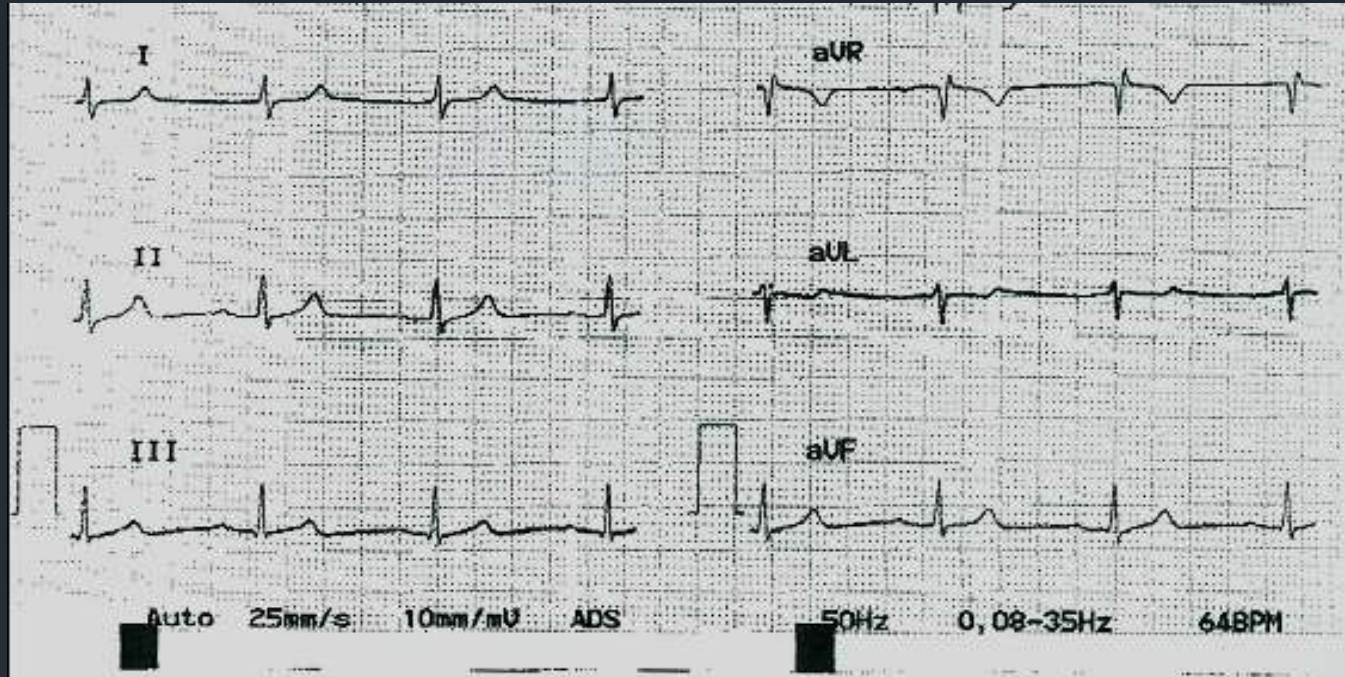
THE CASE

- A 63 y/o Thai male, heavy smoker, HTN, DLP
- Chest pain, nausea + vomiting then syncope
- Primary hospital : BP 70/40 mmHg, HR 40 bpm
- Resuscitated with IVF, atropine, dopamine then transferred to secondary hospital.

ECG



ECG

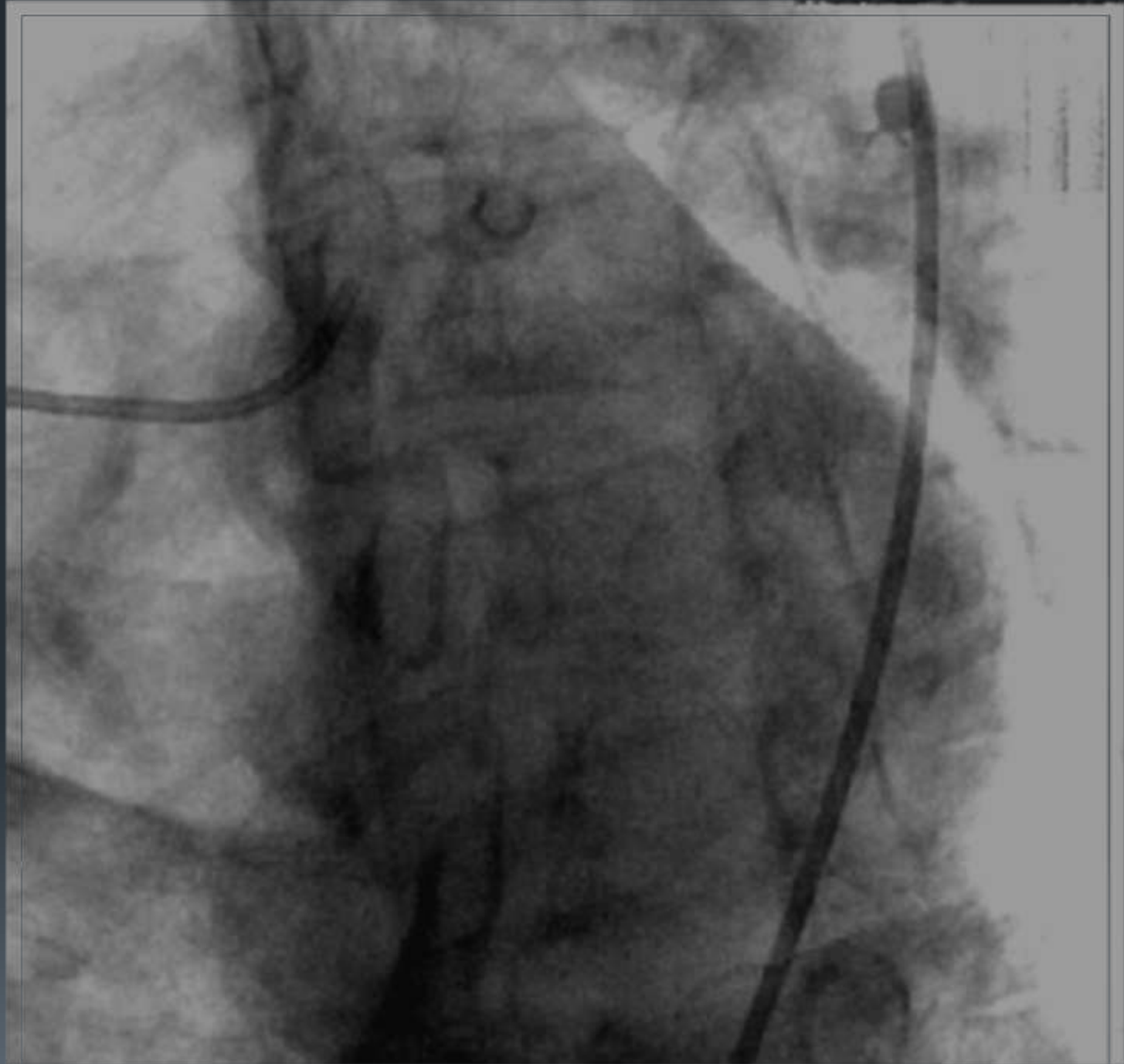


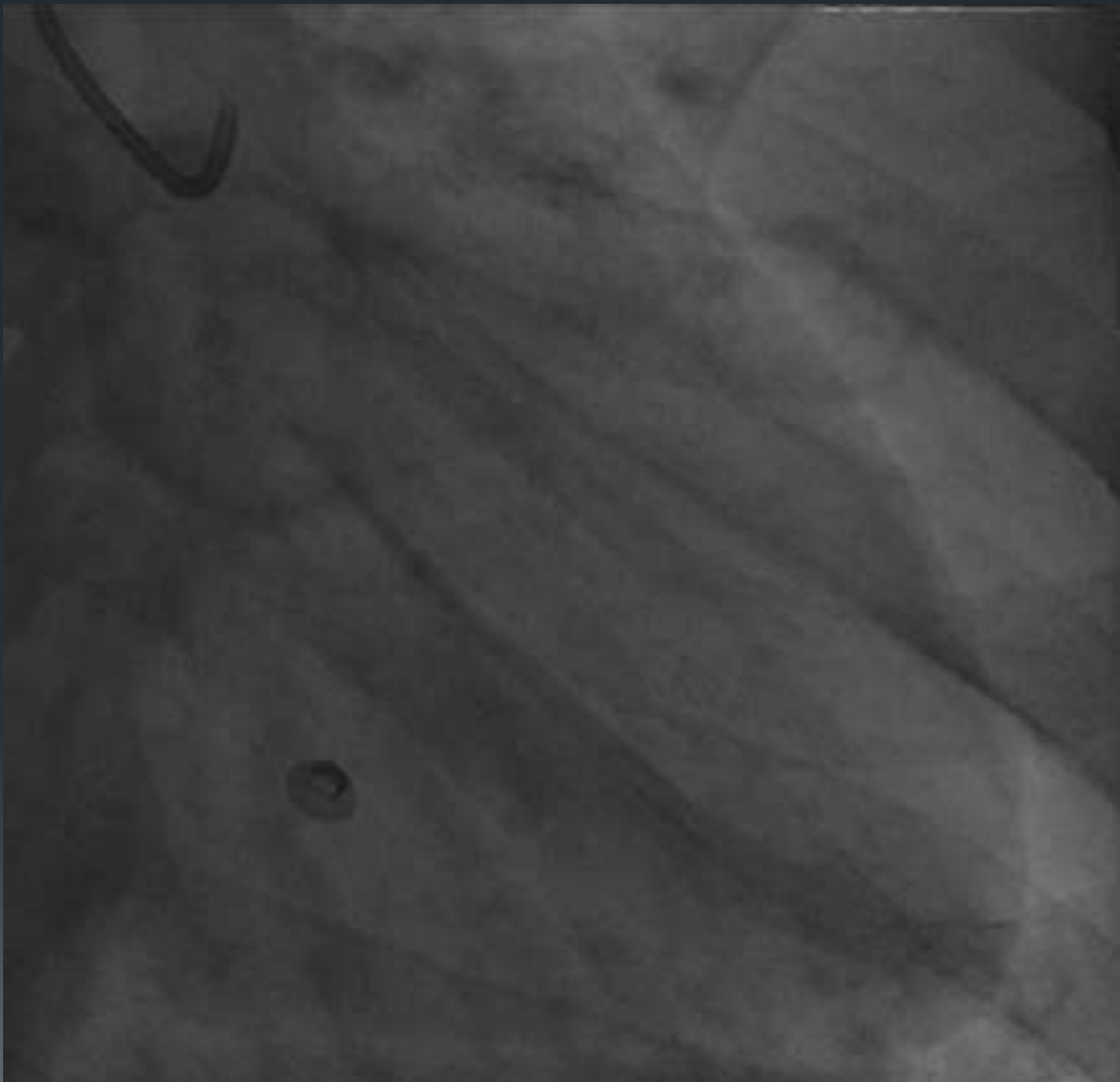
THE CASE

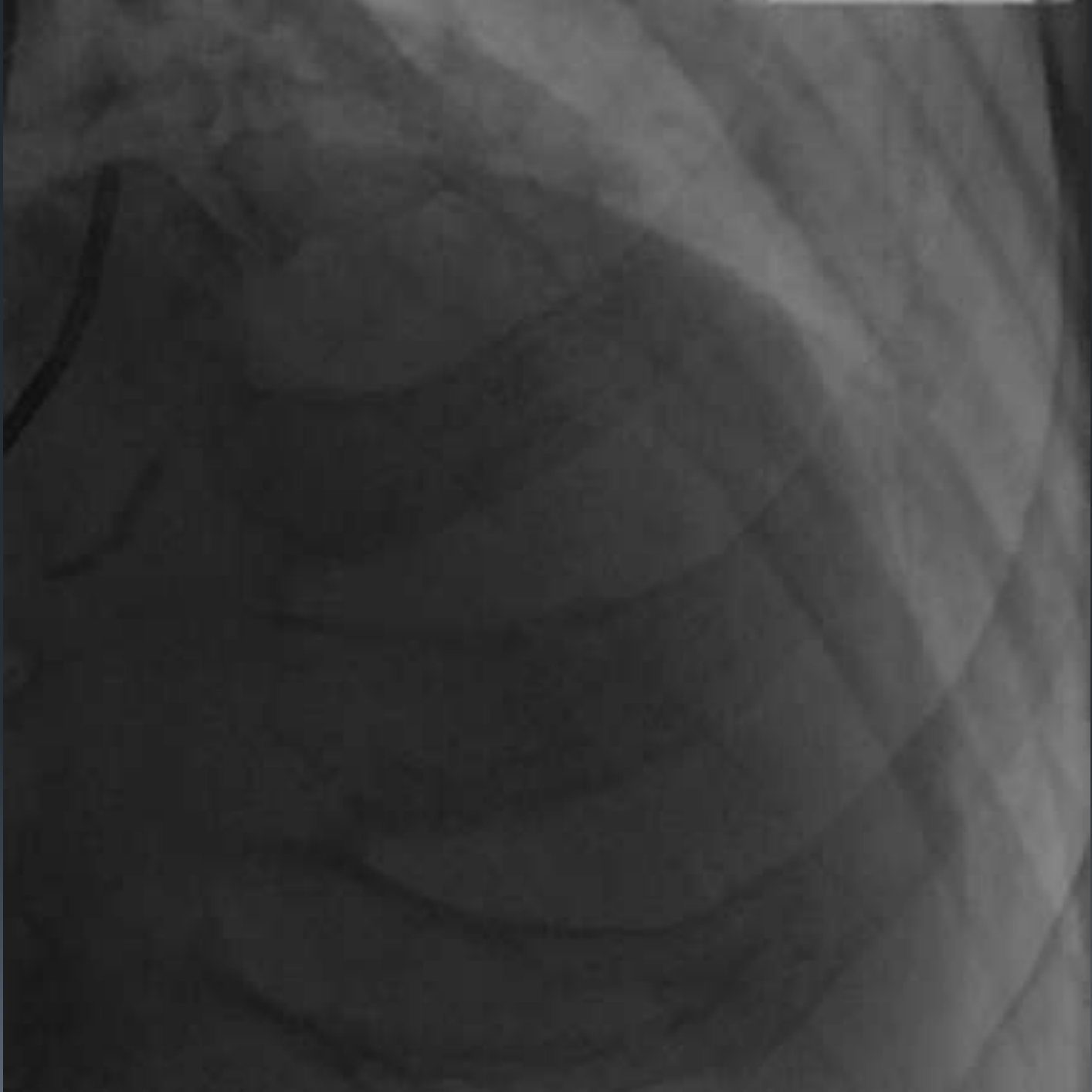- Patient was treated as NSTEMI
- Developed recurrent chest pain, symptomatic bradycardia with persistent hypotension
- Was transferred for coronary intervention

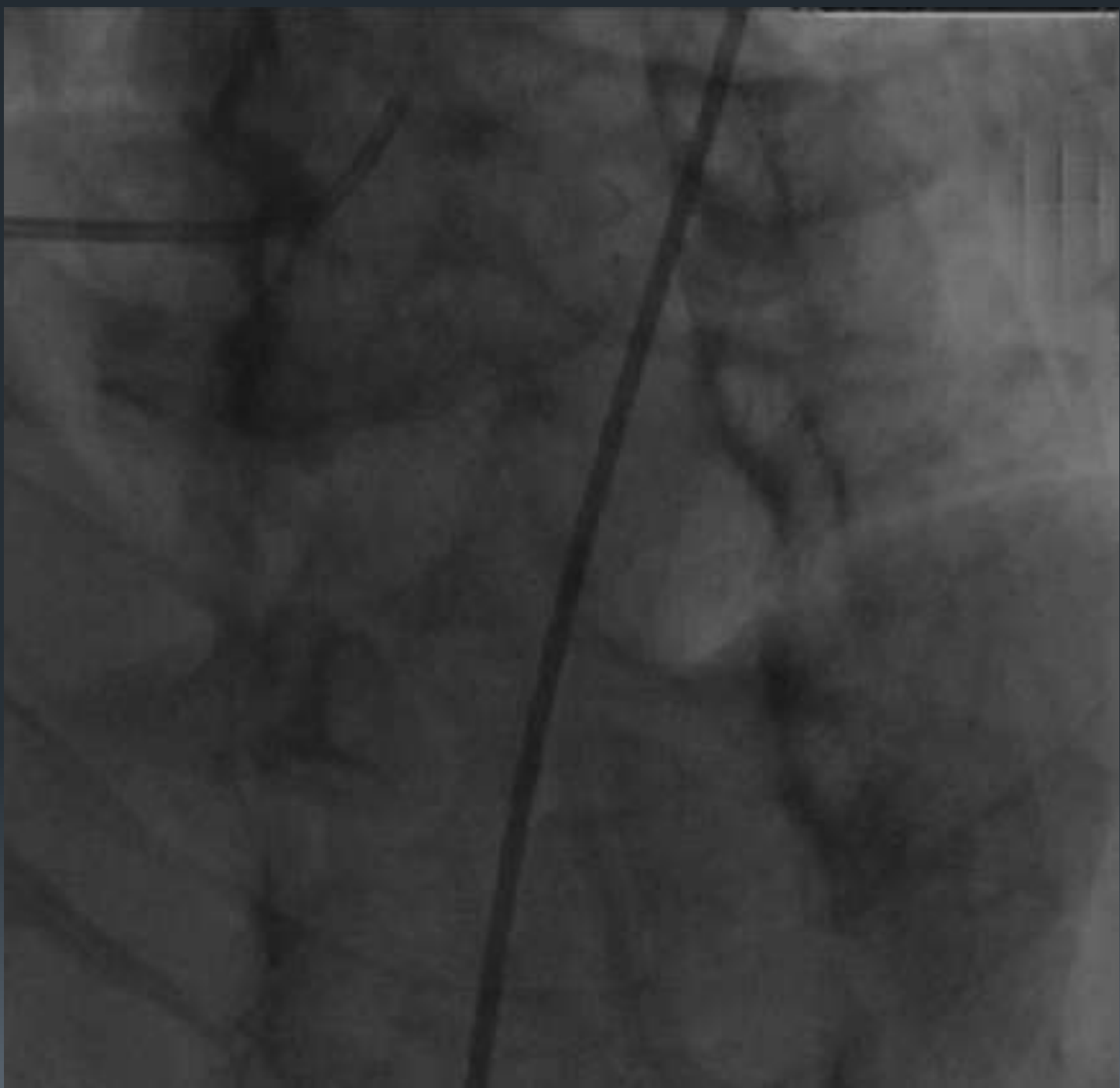
ANGIOGRAM

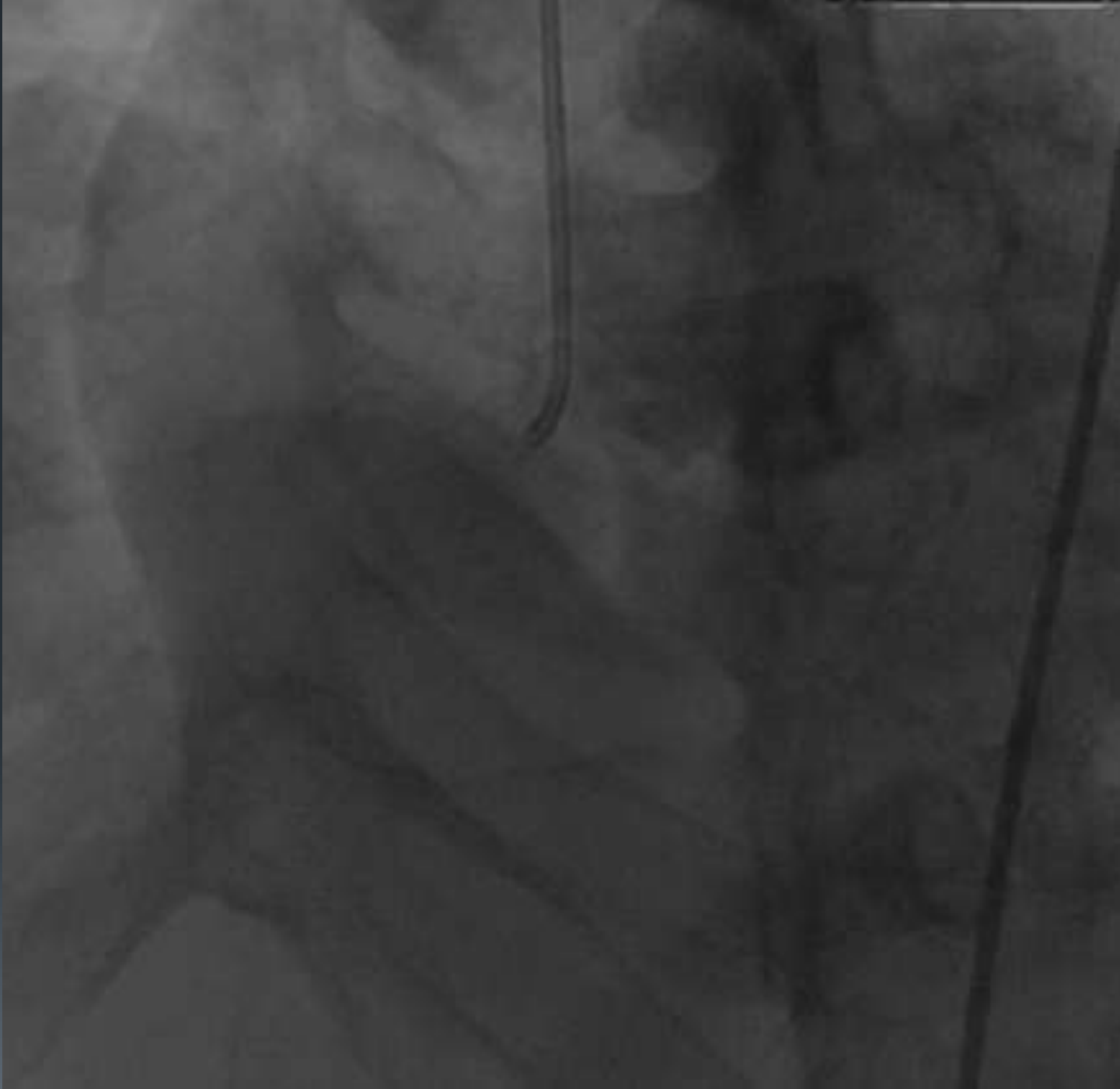


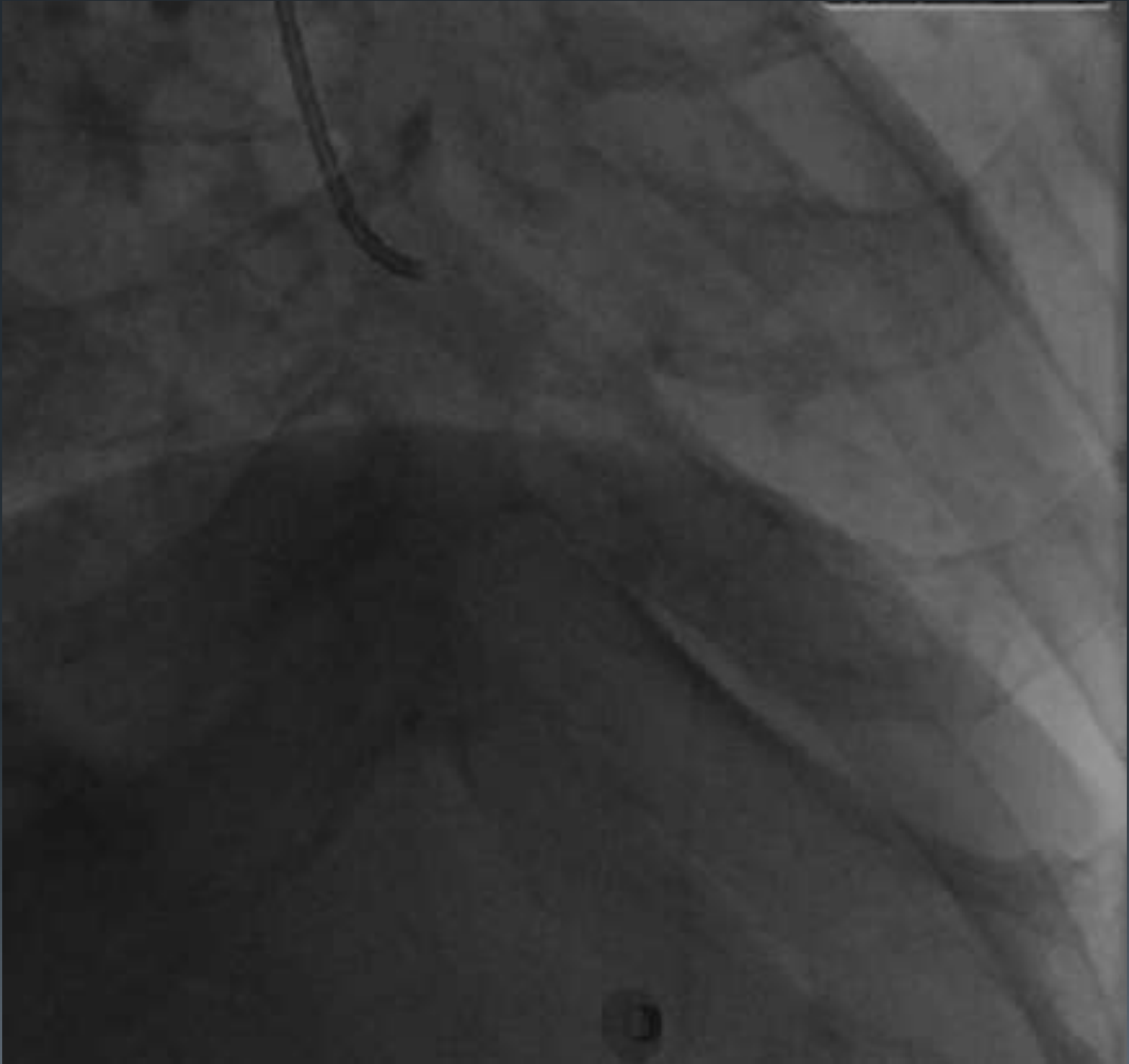


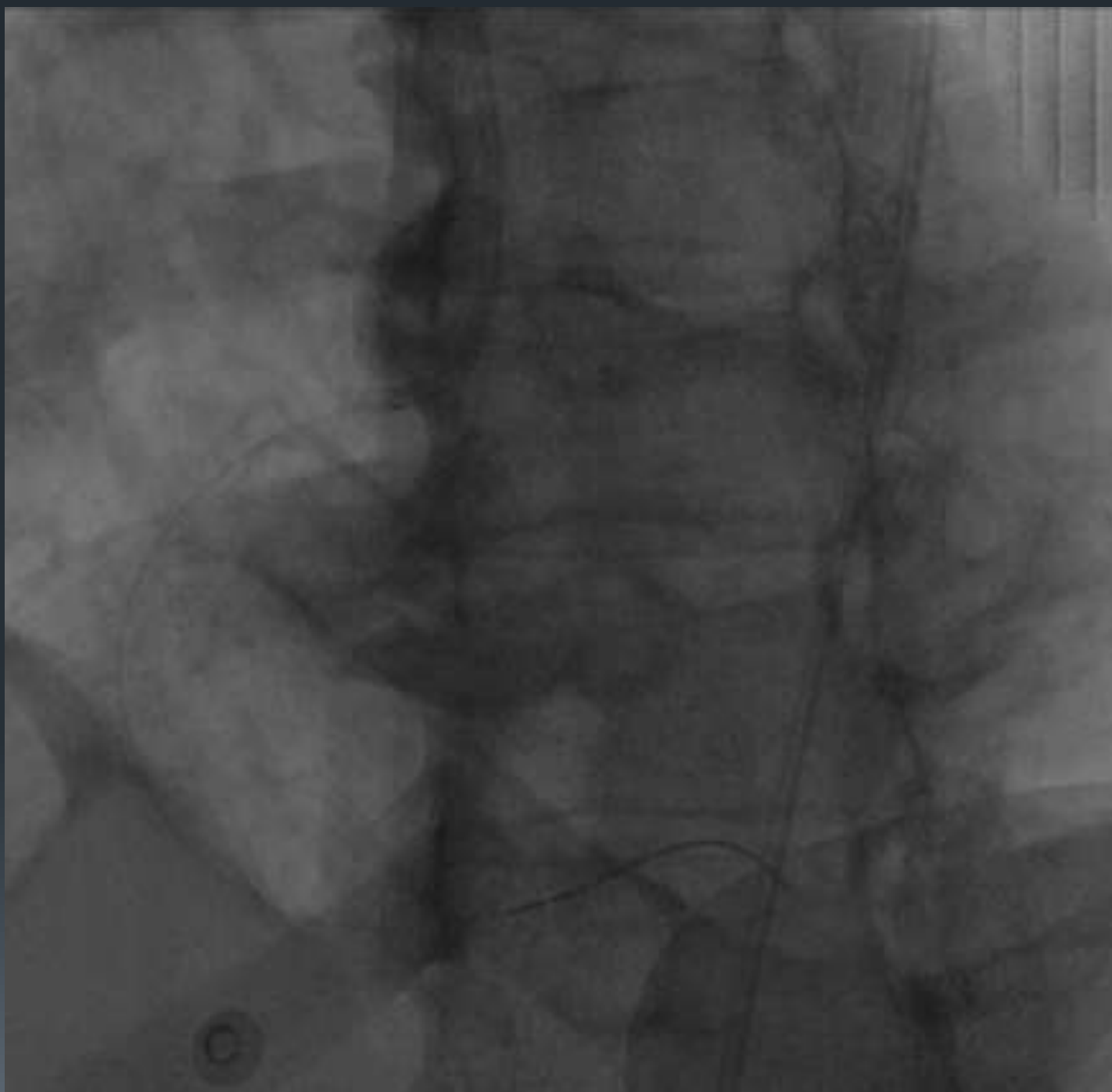


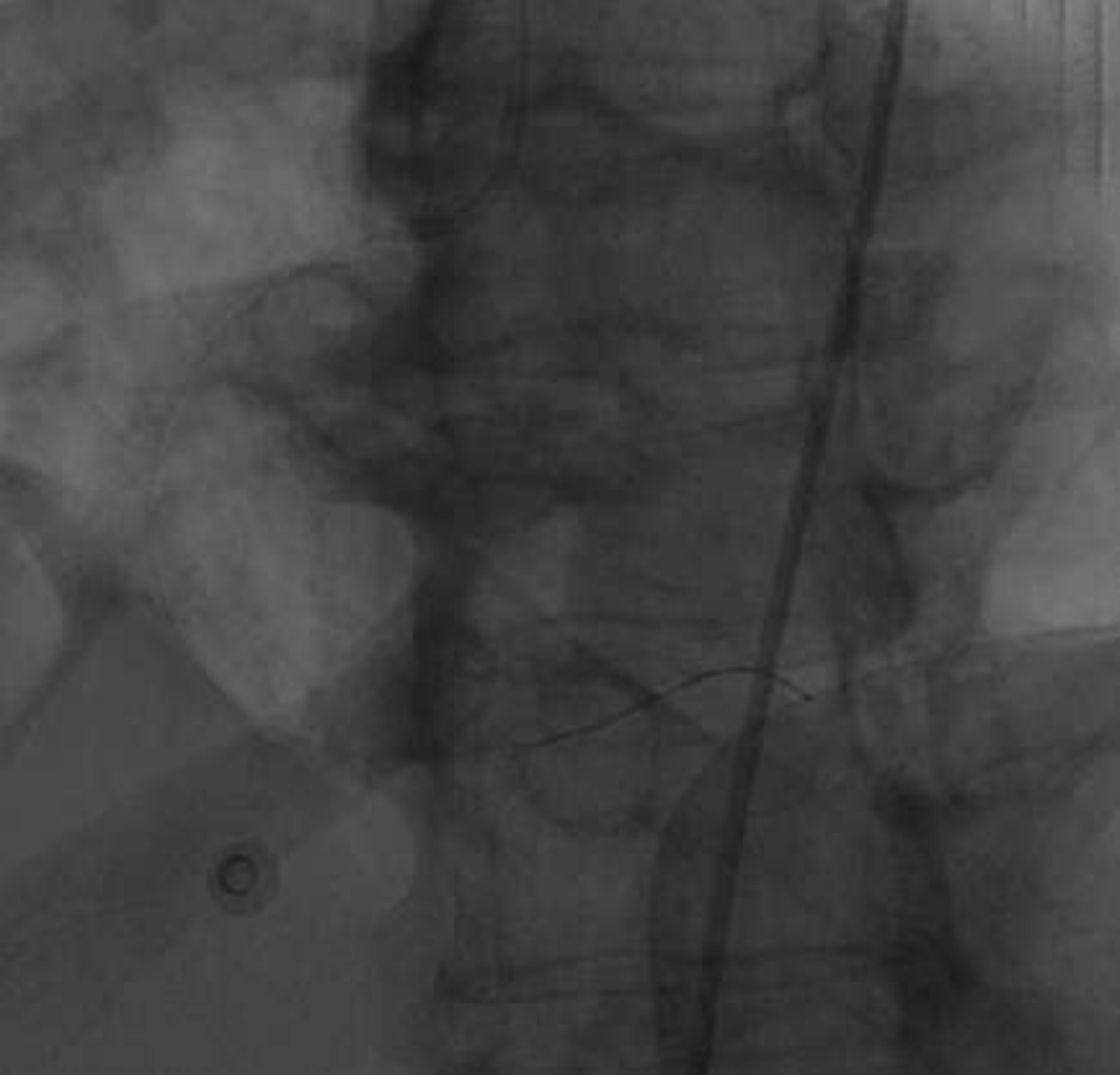
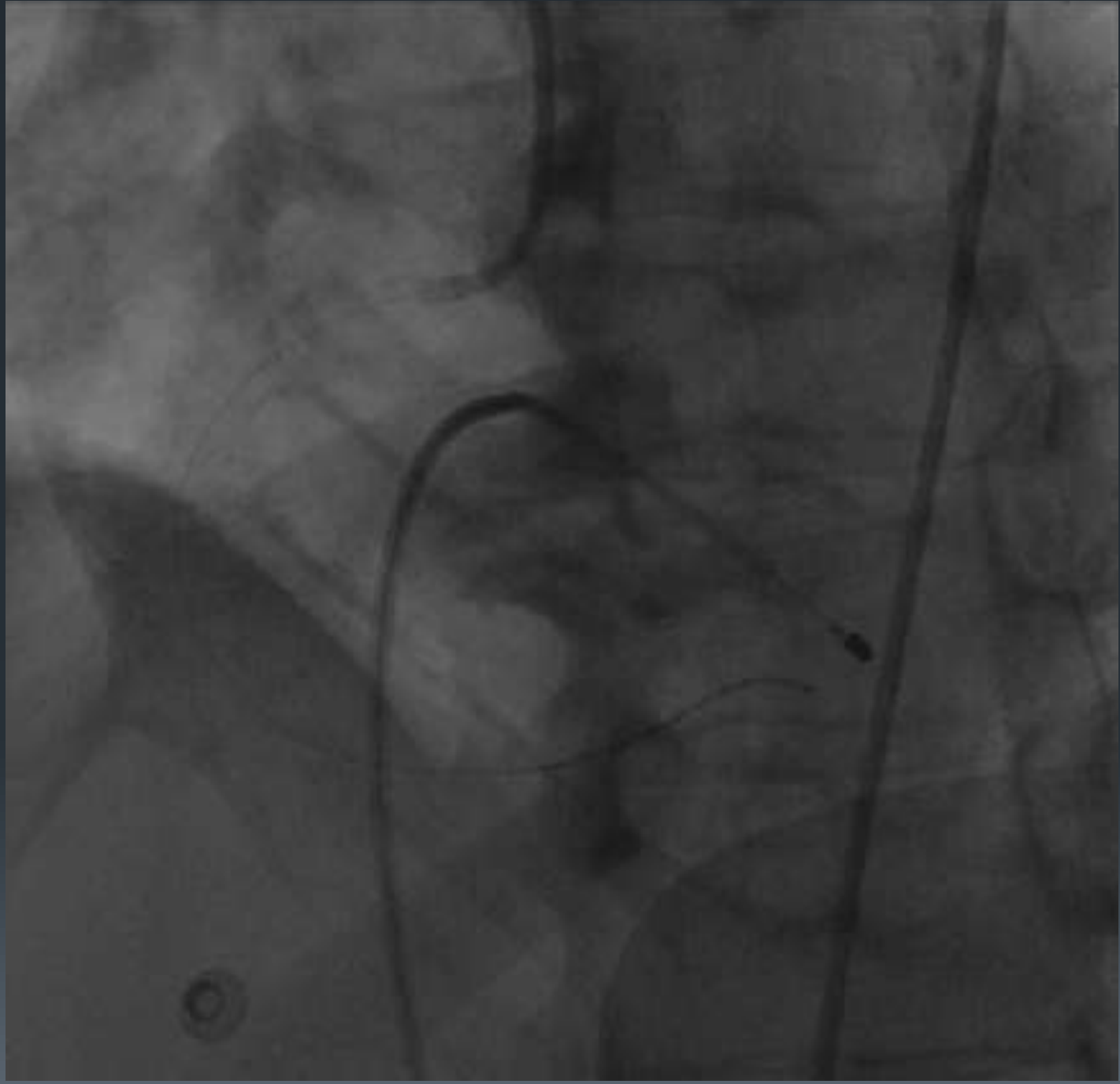


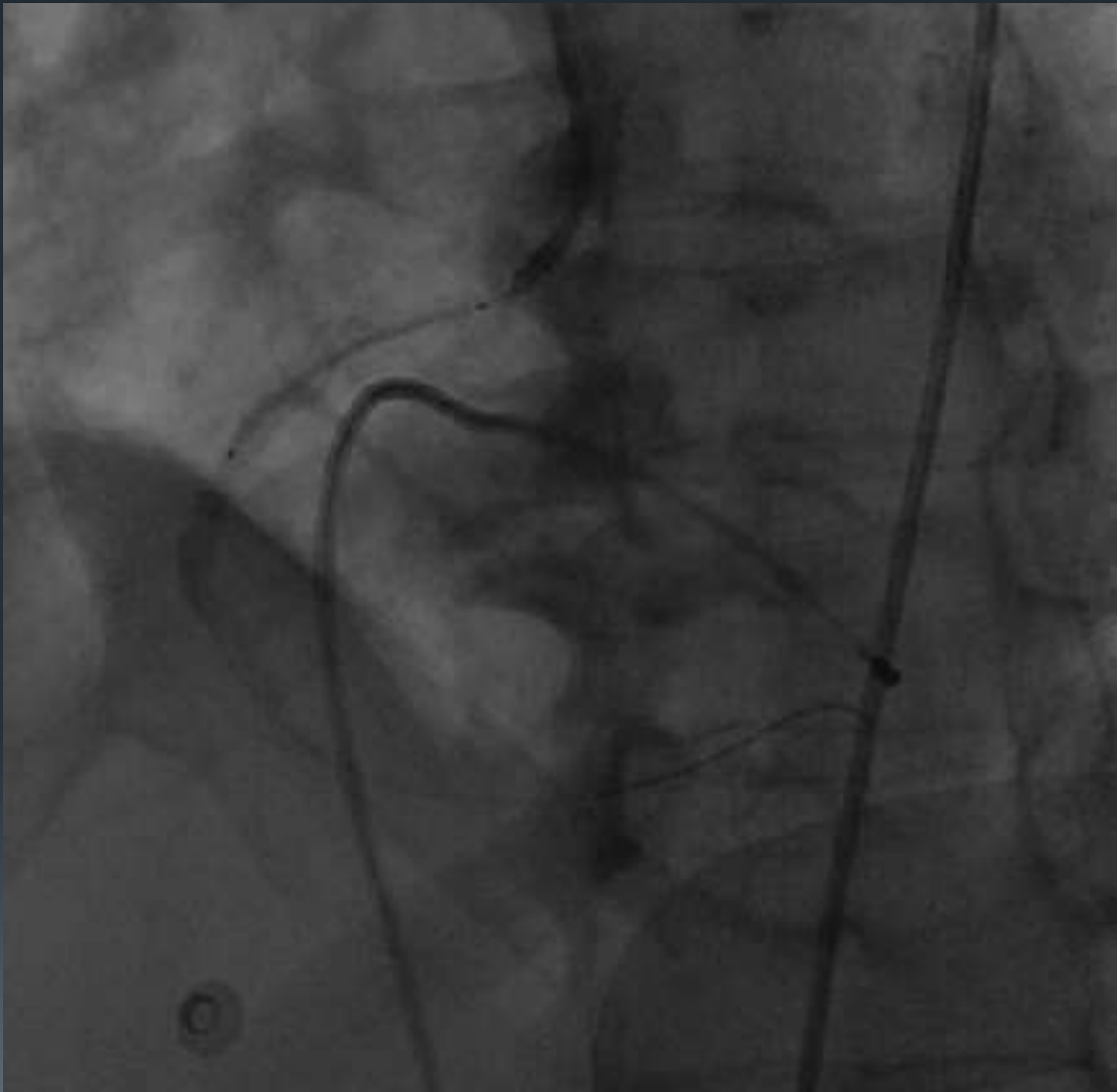


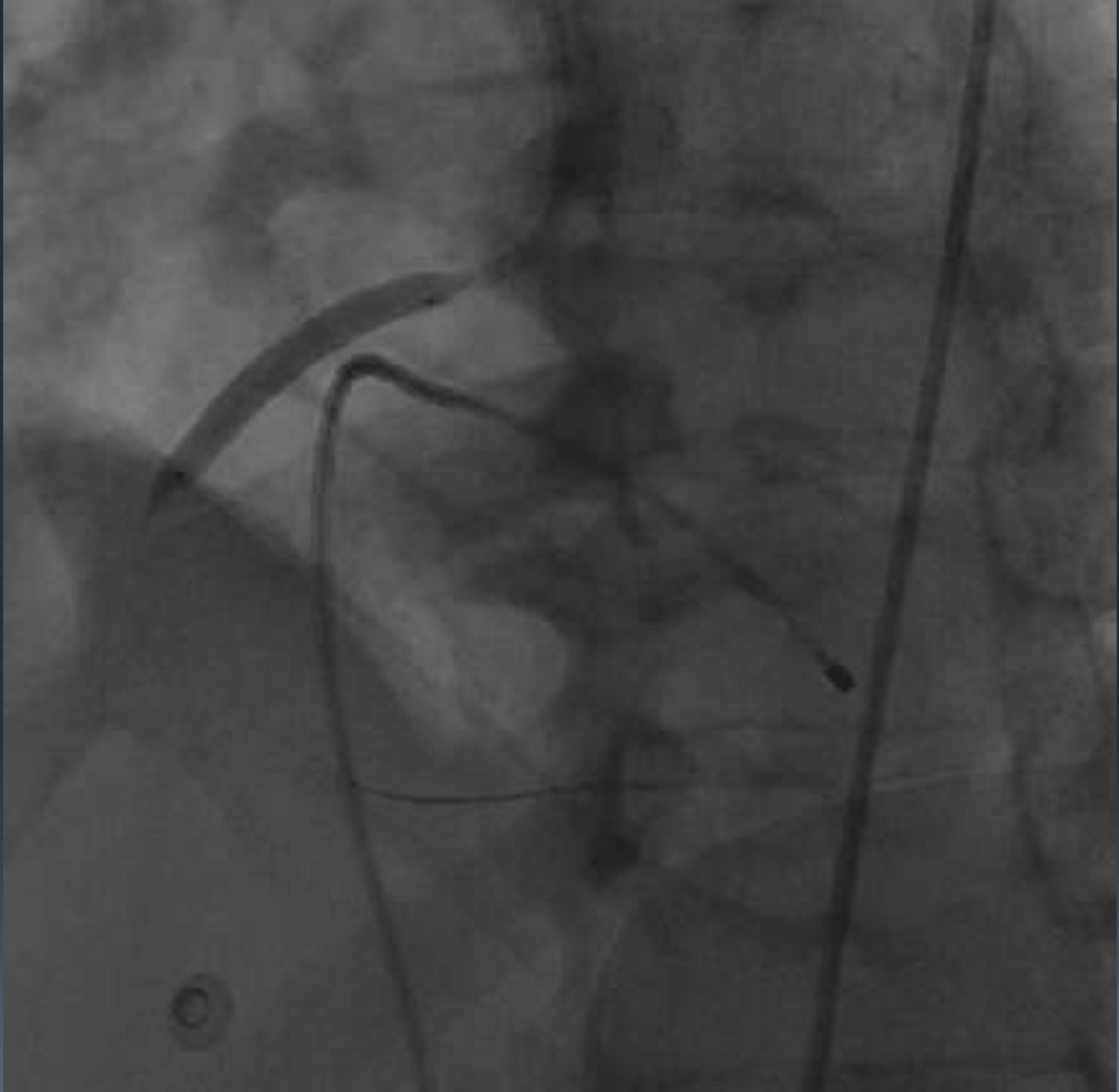


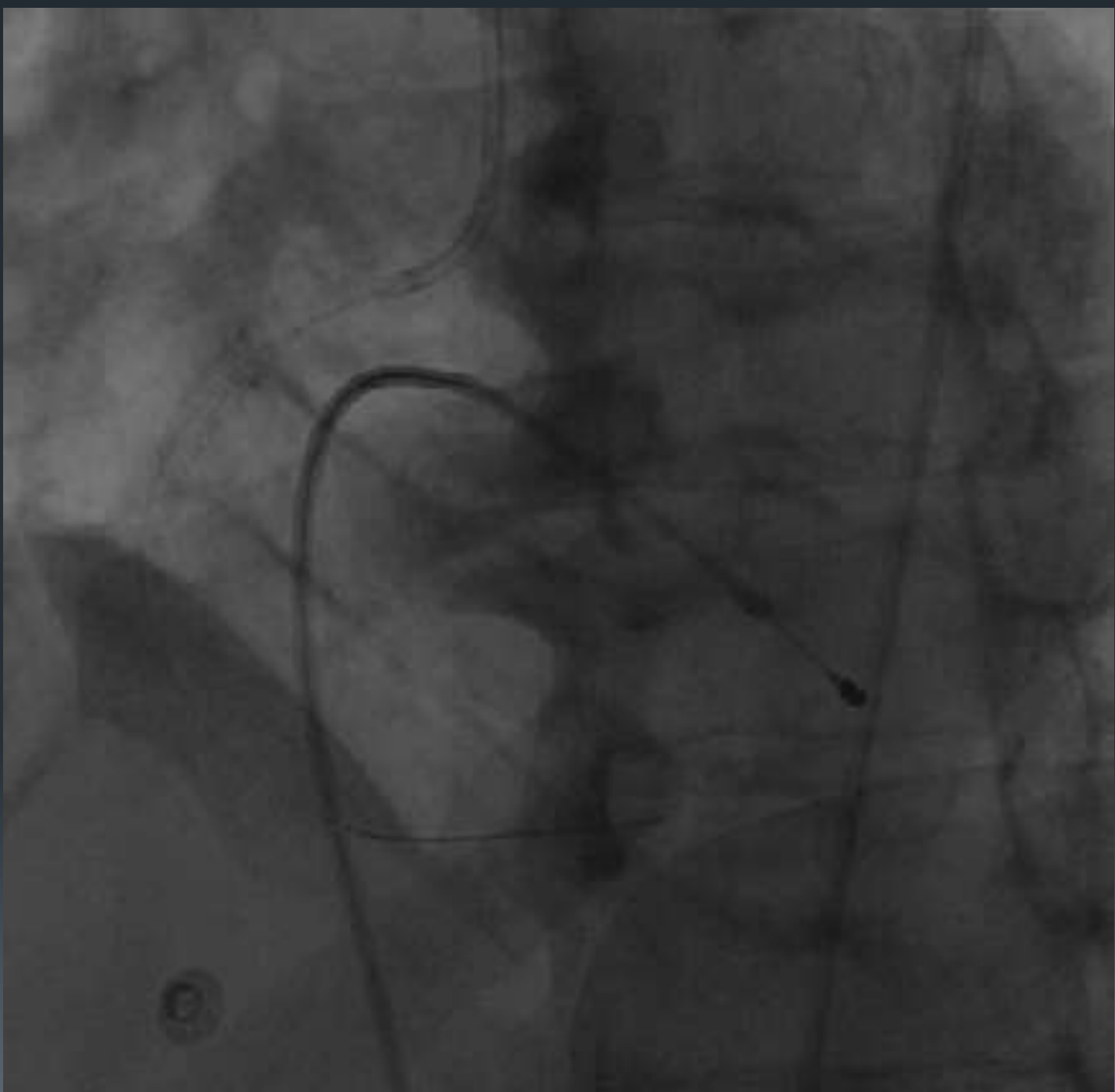




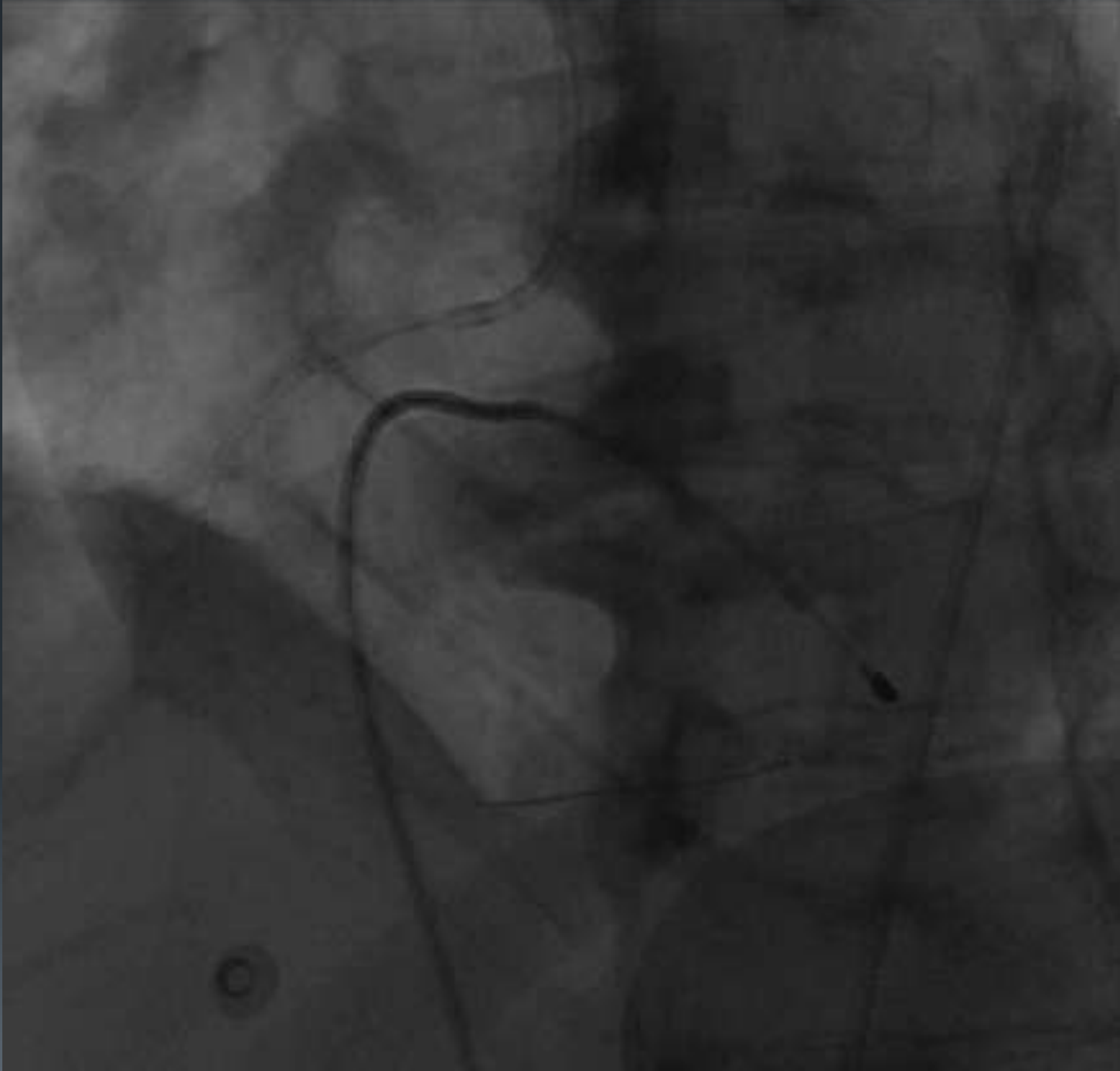


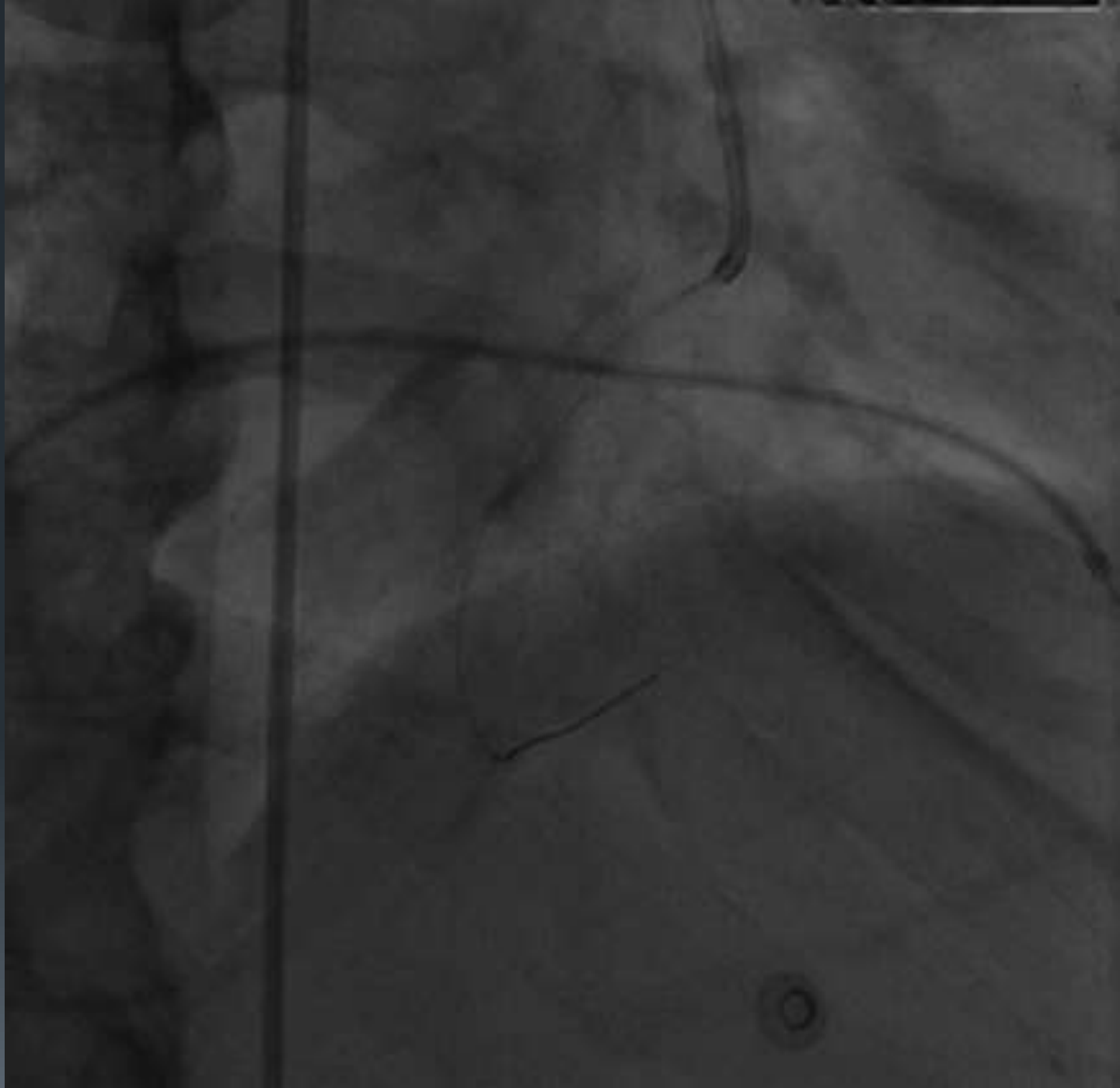
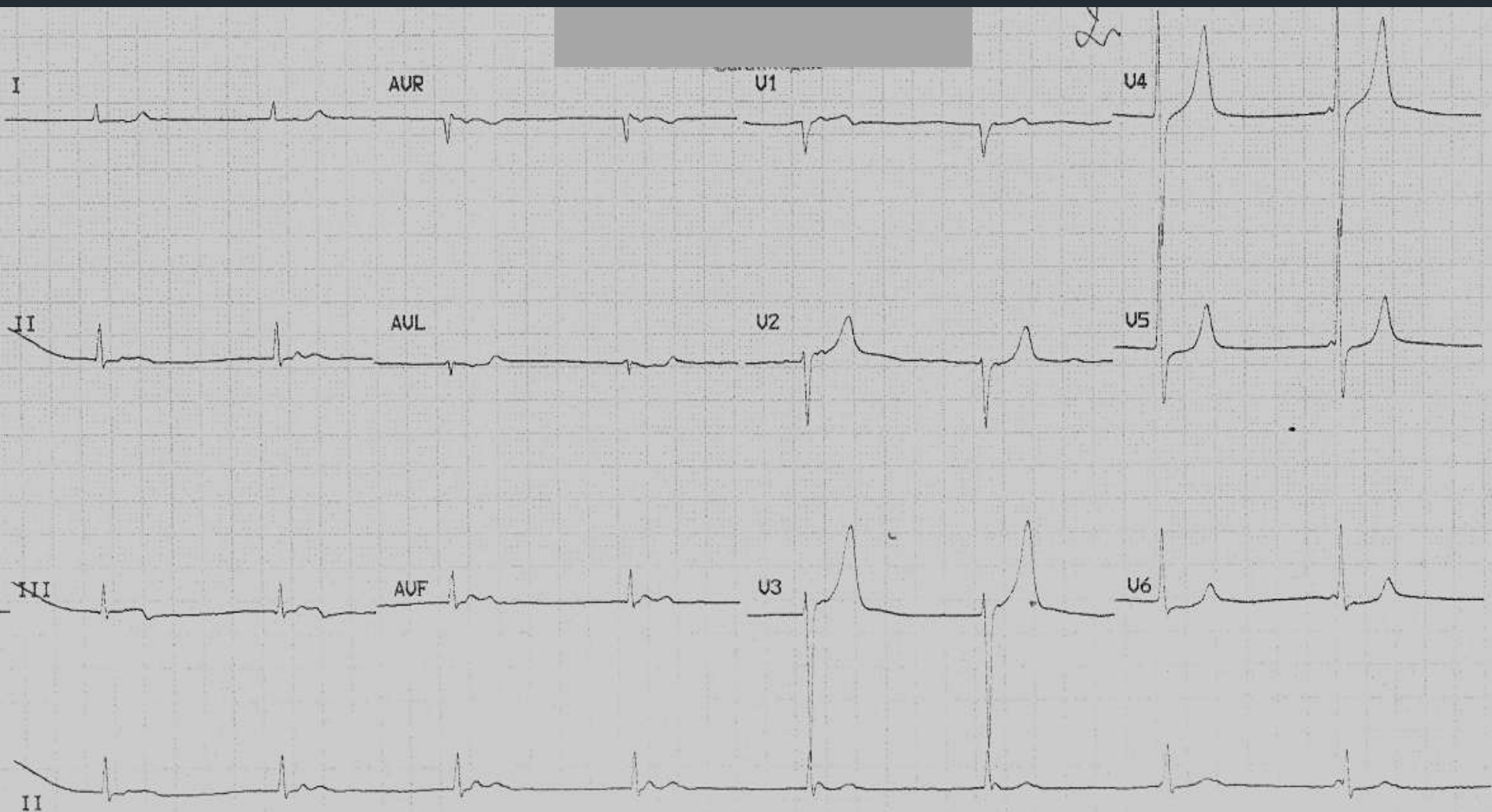








ECG





THANK YOU